


implants

international magazine of oral implantology

4²⁰¹⁰



| **research**

In vitro wear of human enamel opposing YTZP zirconia

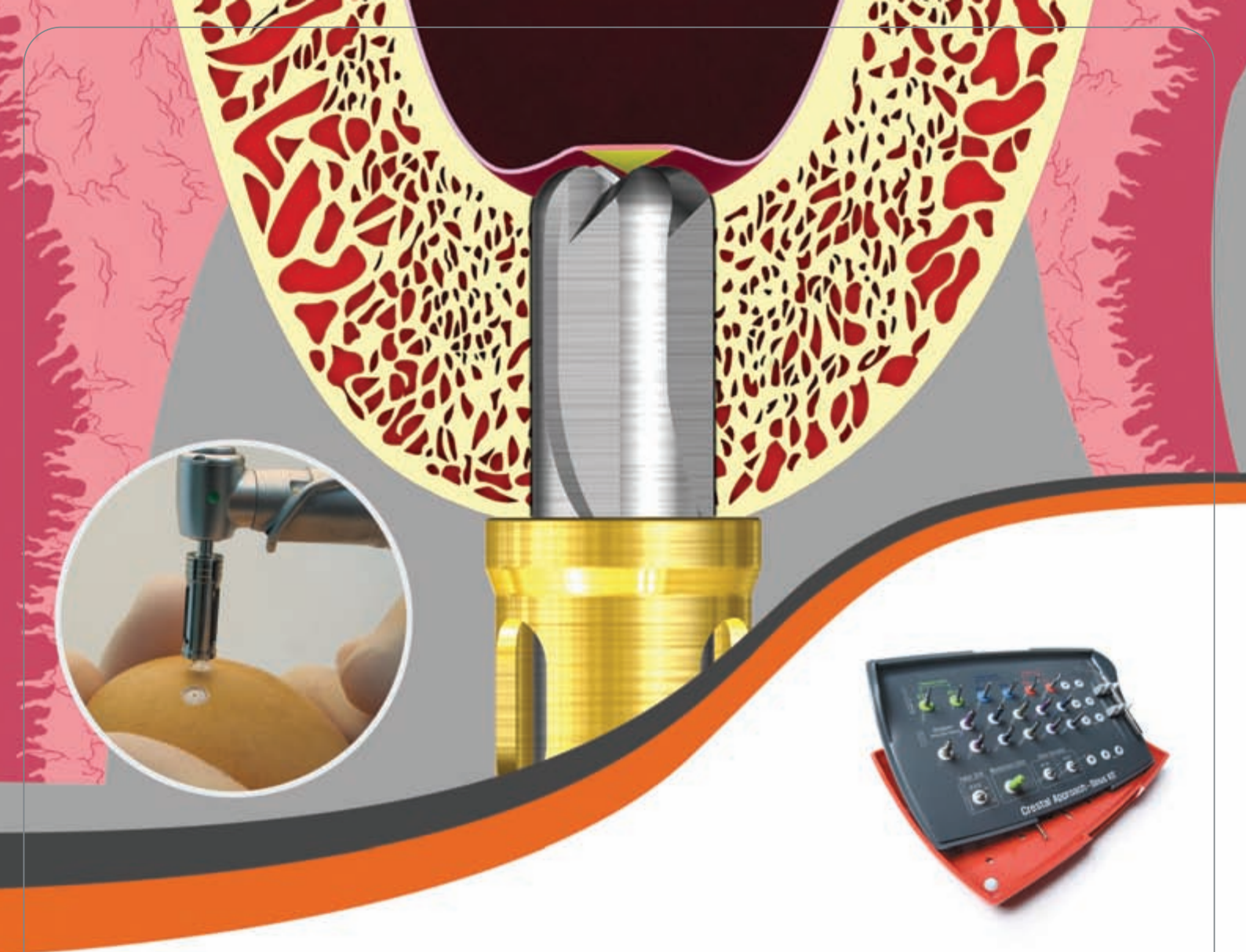| **user report**

3-D alveolar ridge reconstruction in a case with severe bone loss

| **meetings**

After 40 years, DGZI is in its prime





Crestal Approach - Sinus KIT

CAS-KIT

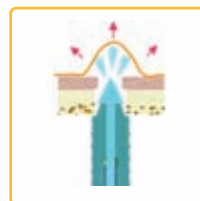The most clever and safest way to the sinus surgery



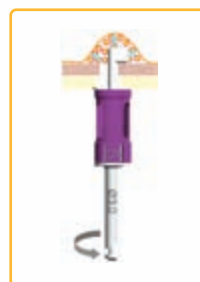Visit us at the IDS in
Cologne : Hall 04.1,
aisle A, booth 010
aisle B, booth 019



Unique Atraumatic Design



Hydraulic Lift System



Bone Spreading System

Making **history**



Dr Friedhelm Heinemann

Dear colleagues,

I think I can honestly say that we made history early in October at DGZI's 40th International Annual Congress in Berlin. Like no other implantological association, DGZI represents the extraordinarily successful development of implantology from an "unorthodox" treatment, faced with many opponents and supported by only a few enthusiasts, to a modern, renowned and scientifically-documented dental discipline.

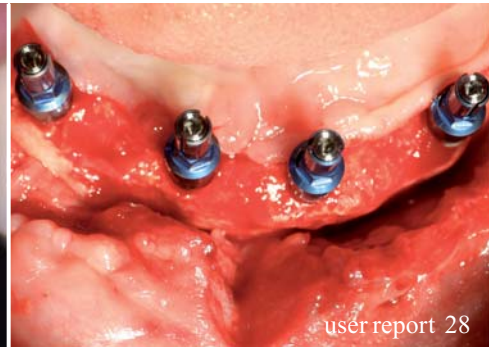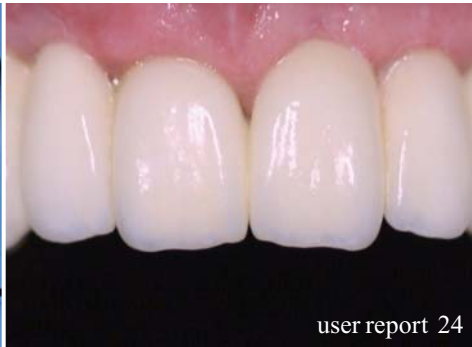In his speech, the President of the German Dental Medical Association, colleague Peter Engel, noted in particular the achievements of dental practitioners, while DGZI's President, colleague Hendrik Terheyden, commented that he does not see any contradiction between scientific research and dental practice, and on the contrary, a close relationship between the two has led to a very productive cooperation.

The expert associations keep in frequent and cooperative contact with each other, particularly through the Consensus Conference, whose current President is Mr. Roland Hille, which works hard to support the interests of dentists working in the field of implantology and implantology as a whole.

DGZI is aware of its responsibility for the further development of this special field and intends to face the coming years with momentum and a healthy self-confidence. We will draw on tried and tested methods to reach our potential and are especially dedicated to enhancing the work of junior staff as well as students. Apart from providing opportunities for expert colleagues to exchange thoughts and for universities to cooperate freely, DGZI's approved training curricula, regional study groups, congresses and many other training programs are an important basis for the future activities of our specialist implantology association.

Yours,

Dr Friedhelm Heinemann



| editorial

- 03 **Making history**
| Dr Friedhelm Heinemann

| research

- 06 **Single molar restoration**
| Prof Dr Amr Abdel Azim, Dr Amani Zaki,
Dr Mohamed el Anwar
- 12 **Implant fracture:**
A look at the physical mechanisms for failure
| Dr Dov M. Almog, Dr Odalys Hector, Dr Samuel Melcer,
Dr Kenneth Cheng
- 14 **In vitro wear of human enamel opposing
YTZP zirconia**
| T. R. Tamba, M. E. Razzoog, B. R. Lang, R. F. Wang,
B. E. Lang

| user report

- 24 **Sinus lift without scalpel**
| Dr Phillip Jesch, Dr Klaus Eder
- 28 **3-D alveolar ridge reconstruction in a case
with severe bone loss**
| Prof Dr Marcel Arthur Wainwright

- 32 **The use of polylactide-coated β -TCP**
| Dr Stefan Neumeyer, Dr Stefanie Neumeyer-Wühr

| meetings

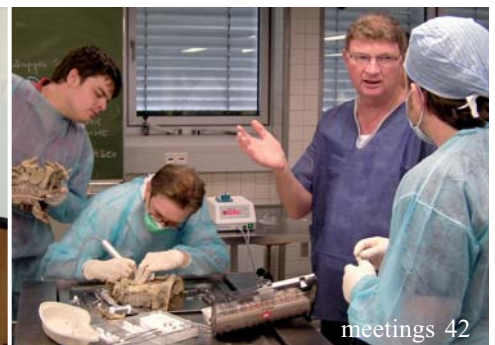- 37 **International events 2011**
- 38 **After 40 years, DGZI is in its prime**
| Dr Christian Ehrensberger
- 42 **The Anatomy Weekend is also in great
international demand**
| Dr Christian Ehrensberger

| news

- 44 **Manufacturer News**
- 48 **Congratulations and Happy Birthday
to all DGZI-members around the world**

| about the publisher

- 49 | submission guidelines
- 50 | imprint



NobelReplace™

The world's most used implant system.*

Internal tri-channel connection for accurate and secure prosthetic restorations.

TiUnite® surface and Groovy™ to enhance osseointegration.

Implant design that replicates the shape of natural tooth roots.



Color-coded system for accurate and fast component identification and ease of use.

Color-coding: step-by-step drilling protocol for predictable surgical procedures.

NEW

Now also available in 11.5 mm length

Versatility, ease-of-use and predictability have made NobelReplace Tapered the most widely used implant design in the world.* NobelReplace Tapered is a general use, two-piece implant system that performs both in soft and hard bone, one- and two-stage surgical procedures, while consistently delivering

optimal initial stability. NobelReplace Tapered is a system that grows to meet the surgical and restorative needs of clinicians and their patients – from single-tooth restorations to more advanced multi-unit solutions. Whether clinicians are just starting or are experienced implant users, they will benefit from a system that

is unique in flexibility and breadth of application.

Nobel Biocare is the world leader in innovative and evidence-based dental solutions.

For more information, or visit our website.

www.nobelbiocare.com

Single molar restoration

Wide implant versus two conventional

Authors_Prof Dr Amr Abdel Azim, Dr Amani Zaki, Dr Mohamed el Anwar, Egypt

The single-tooth restoration has become one of the most widely used procedures in implant dentistry.¹ In the posterior region of the oral cavity, bone volume and density are often compromised. Occlusal forces are greater in this region and, with or without parafunctional habits, can easily compromise the stability of the restorations (Fig. 1).^{2,3}

The single-molar implant-supported restoration has historically presented a challenge in terms of form and function. The mesiodistal dimensions of a molar exceed that of most standard implants (3.75 to 4.0 mm), creating the possibility of functional overload resulting in the failure of the retaining components or the failure of the implant (Figs. 2 & 3).⁴ Wider-diameter implants have a genuine use in smaller molar spaces (8.0 to 11.0 mm) with a crestal width greater than or equal to 8 mm (Fig. 4 a).⁵ Clinical parameters governing the proposed restoration should be carefully assessed in light of the availability of implants and components that provide a myriad of options in diameter, platform configurations and prosthetic connections. Many of the newer systems for these restorations are showing promising results in recent clinical trials.⁶⁻⁸ It has further been suggested by Davarpanah and others,⁹ Balshi and others,² English and others¹⁰ and Bahat and Handelsman¹¹ that

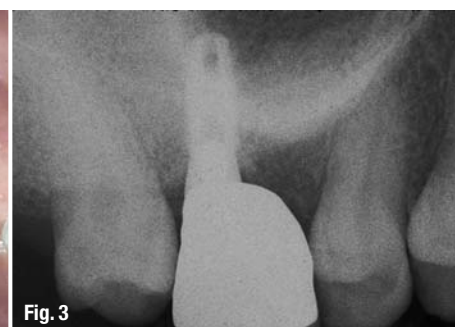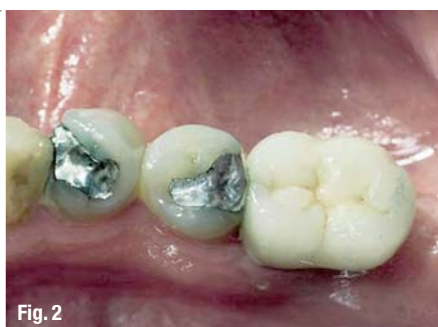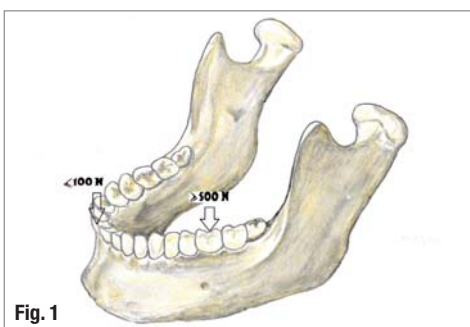
the use of multiple implants may be the ideal solution for single-molar implant restorations (Figs. 4 b & c). Most standard implants and their associated prosthetic components, when used to support a double implant molar restoration, will not fit in the space occupied by a molar unless the space has been enlarged (12 mm or larger).⁴ Moscovitch suggests that the concept of using 2 implants requires the availability of a strong and stable implant having a minimum diameter of 3.5 mm. Additionally, the associated prosthetic components should ideally not exceed this dimension.²

Finite element analysis (FEA) is an engineering method that allows investigators to assess stresses and strains within a solid body.¹⁰⁻¹³ FEA provides calculation of stresses and deformations of each element alone and the net of all elements. A finite element model is constructed by breaking a solid object into a number of discrete elements that are connected at common nodal points. Each element is assigned appropriate material properties that correspond to the properties of the structure to be modeled. Boundary conditions are applied to the model to stimulate interactions with the environment.¹⁴ This model allows simulated force application to specific points in the system, and it provides the resultant forces in the surrounding structures. FEA is

Fig. 1_Load distribution during mastication shows marked increase in the molar and premolar area.²³

Fig. 2_Occlusal view showing a missing first molar. The mesio-distal width is very wide and restoration couldn't compensate it leaving a space distally.

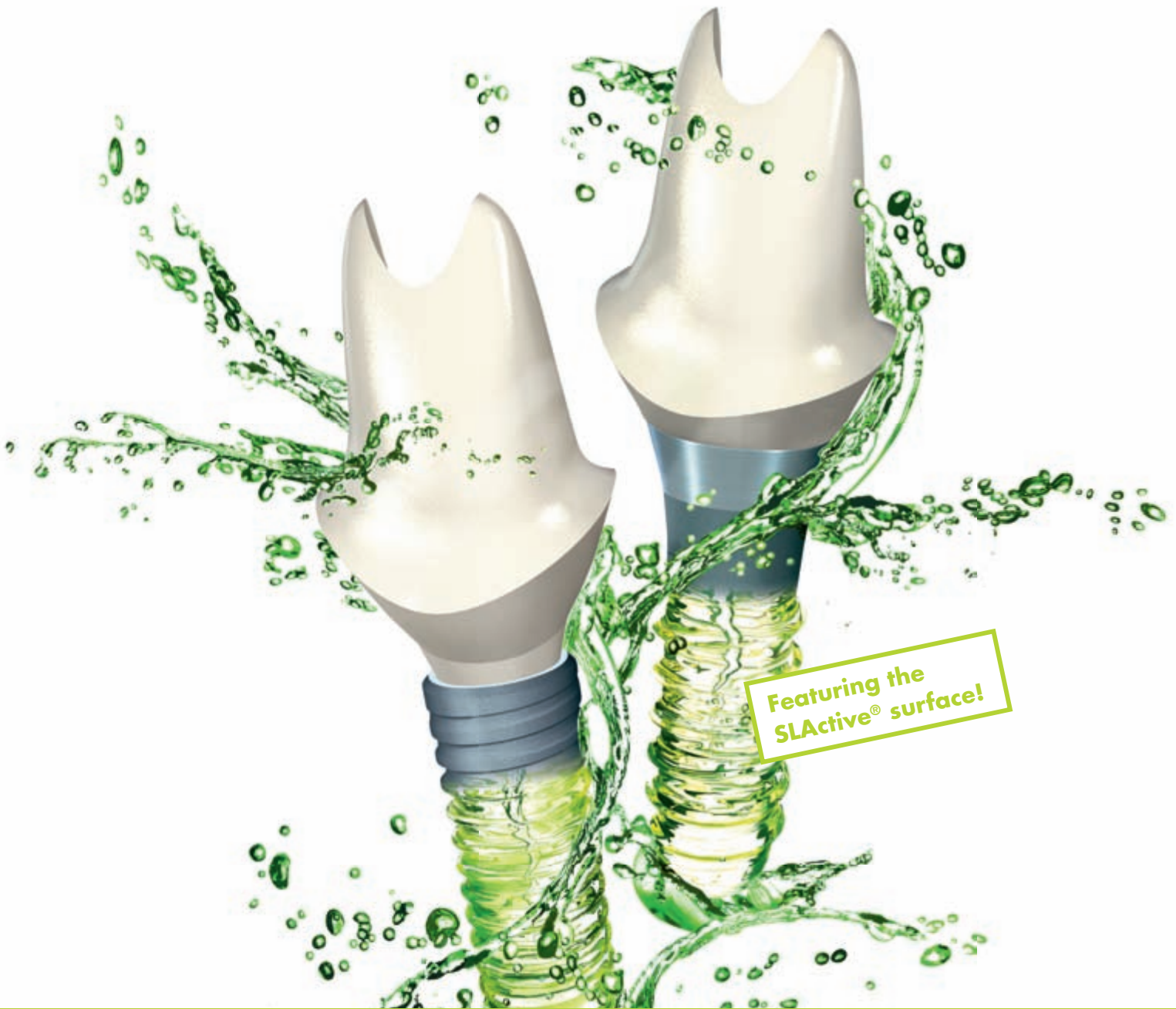Fig. 3_Proximal cantilever shown radiographic view of maxillary right first molar on standard Brånemark implant with standard abutment (Nobel Biocare).¹





PERFECT FIT BY DESIGN

In combining Soft Tissue and Bone Level implants with a comprehensive prosthetic portfolio, Straumann has devised one system for all indications. The **Straumann® Dental Implant System** – excellent product quality designed for convincing, naturally esthetic outcomes.



Featuring the
SLActive® surface!

COMMITTED TO
SIMPLY DOING MORE
FOR DENTAL PROFESSIONALS

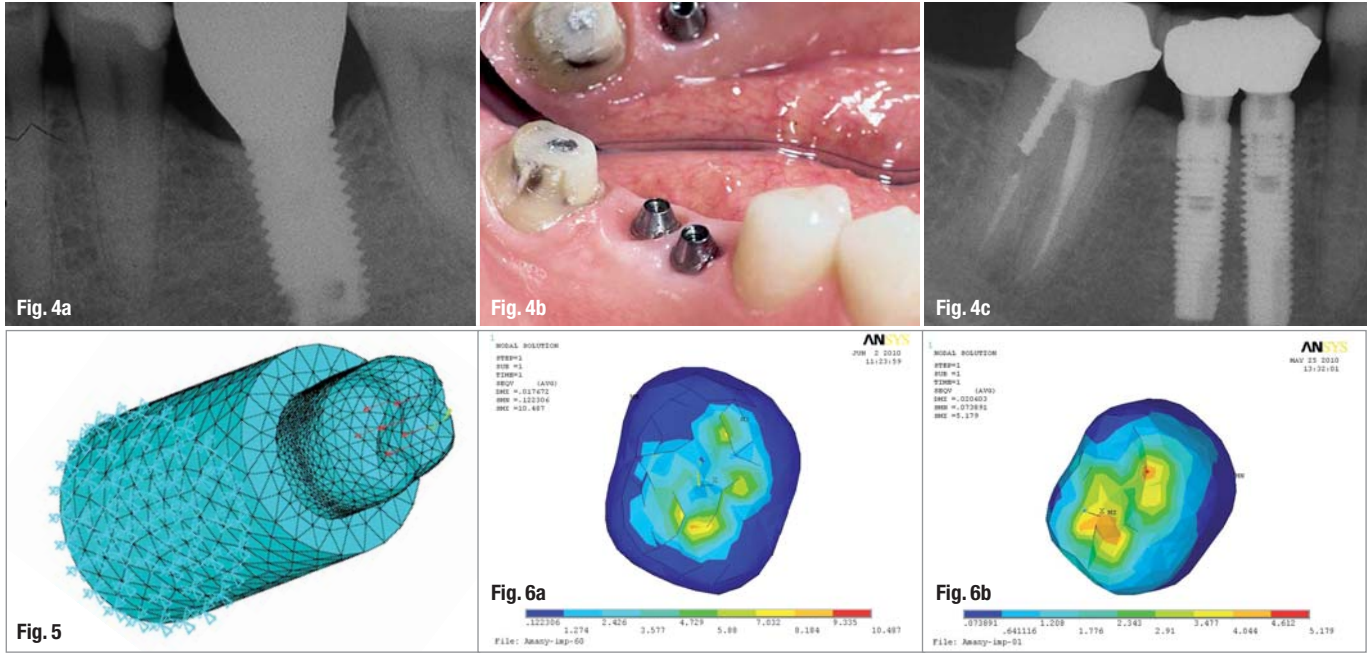


Fig. 4a_Radiographic view of wide implants used to restore missing lower first molars.^{1,24}
Fig. 4b_Buccal view of 2 standard 20-degree abutments on 3.5 mm Astra Tech implants for restoration of mandibular right first molar.^{1,24}
Fig. 4c_Radiographic view of the restoration.^{1,24}
Fig. 5_Crown, implants and bone assembled in a model (FEA software).
Figs. 6a & b_Von Mises stress on crown (a. wide implant; b. two implants).

particularly useful in the evaluation of dental prostheses supported by implants.¹³⁻¹⁶ Two models were subjected to FEA study to compare between a wide implant restoration versus the two implant restoration of lower first molar.

Material and Methods

Three different parts were modeled to simulate the studied cases; the jaw bones, implant/abutment assembly, and crown. Two of these parts (jaw bone and implant/abutment) were drawn in three dimensions by commercial general purpose CAD/CAM software "AutoDesk Inventor" version 8.0. These parts are regular, symmetric, and its dimensions can be simply measured with their full details.


On the other hand, crown is too complicated in its geometry therefore it was not possible to draw it in three dimensions with sufficient accuracy. Crown was modeled by using three-dimensional scanner, Roland MDX-15, to produce cloud of points or triangulations to be trimmed before using in any other application.

The second phase of difficulty might appear for solving the engineering problem, is importing and manipulating three parts one scanned and two modeled or drawn parts on a commercial FE package. Most of CAD/CAM and graphics packages deal with parts as shells (outer surface only). On the other hand the stress analysis required in this study is based on volume of different materials.³ Therefore set of operations like cutting volumes by the imported set of surfaces in addition to adding and subtracting volumes can ensure obtaining three volumes representing the jaw bone, implant/abutment assembly, and crown.² Bone was simulated as cylinder that consists of two parts. The inner part represents the spongy bone (diameter 14 mm and height 22 mm) that filling the internal space of the other part (shell of 1 mm thickness) that represents cortical bone (diameter 16 mm and height 24 mm). Two implants were modeled one of 3.7 mm diameter and the other of 6.0 mm. The implants/abutment design and geometry were taken from Zimmer dental catalogue (Fig. 5).

Linear static analysis was performed. The solid modeling and finite element analysis were performed on a personal computer Intel Pentium IV, processor 2.8 GHz, 1.0 GB RAM. The meshing software was ANSYS version 9.0 and the used element in meshing all three dimensional model is eight nodes Brick element (SOLID45), which has three degrees of freedom (translations in the global directions). Listing of the used materials in this analysis is found in Table 1. The two models were subjected to 120 N vertical load equally distributed (20 N on six points simulate the occlusion; one on each cusp and one in the central fossa). On the other hand, the base of the cortical bone cylinder was fixed in all directions as a boundary condition.¹⁷⁻²¹

Tab. 1 Material Properties.

Material	Poisson's ratio	Young's modulus MPa
Coating (porcelain)	0.3	67,200
Restoration (gold)	0.3	96,000
Implants (titanium)	0.35	110,000
Spongy bone	0.3	150
Cortical bone	0.26	1,500



Results and Discussion

Results of FEA showed a lot of details about stresses and deformations in all parts of the two models under the scope of this study. Figures 6a & b showed a graphical comparison between the crowns of the two models which are safe under this range of stresses (porcelain coating, gold crown, and implants showed the same ranges of safety). No critical difference can be noticed on these parts of the system. All differences might be found are due to differences in supporting points and each part volume to absorb load energy (equation 2).** Generally a crown placed on two implants is weaker than the same crown placed on one implant. This fact is directly reflected on porcelain coating and the two implants that have more deflections. Comparing wide implant model with the two implants from the geometrical point of view it is simply noted that cross sectional area was reduced by 43.3% while the side area increased by 6.5%. Using one implant results as a reference in a detailed comparison between the two models by using equation (1) resulted in Table 2 for porcelain coating, gold crown, implant(s), spongy and cortical bones respectively.

$$Difference \% = \{One\ implant\ Result - Two\ implants\ Result\} * 100 / One\ implant\ Result... (1)$$

Spongy bone deformation and stresses (Table 2) seems to be the same in the two cases. Simple and fast conclusion can be taken that using one wide implant is equivalent to using two conventional implants. On the other hand a very important conclusion can be exerted that, under axial loading, about 10% increase in implant side area can overcome reduction of implant cross section area by 50%. In other words, *effectiveness of increasing implant side area might be five times higher than the increasing of implant cross section area* on spongy bone stress level under axial loading. Starting from Figure 7 a & b, slight differences can be noticed on spongy bone between the two models results. The stresses on the spongy bone are less by about 5% in the two implants model than the one wide diameter implant. The exceptions are the relatively increase in maximum compressive stresses and deformations of order 12% and 0.3% respectively. The bone is known to re-

spond the best to compressive and the least to shear stresses²², so considering the difference in compressive stresses less significant, the *two implants were found to have a better effect on spongy bone*. Contrarily, Figures 8a & b, showed better performance with cortical bone in case of using one wide implant over using two implants, that, deformations in cortical bone are less by 20% while the stresses are less by about 40%. The stresses and displacements were significantly higher in the two implant model due to *having two close holes*, which results in *weak area in-between*.

Conclusions

This study showed various results between cortical and spongy bone. It was expected that the maximum stresses in the cortical bone was placed in the weak area between the two implants. In addition to be higher than the case of using one wide implant. Although the middle part of spongy bone was stressed to the same level in the two cases, using two implants resulted in *more volume of the spongy bone* absorbed the load energy** which led to reduction of stress concentration and rate of stress deterioration by moving away from implants. That is considered better distribution of stresses from the mechanics point of view, which may result in longer lifetime. Porcelain coating showed less stress in case of two implants, longer life for the brittle coating material

Fig. 7a & b Spongy bone deflection in vertical direction (a. wide implant; b. two implants).
Figs. 8a & b Cortical bone deflection in vertical direction (a. wide implant; b. two implants).

Tab. 2 Results.

Differences %	Porcelain coating (1mm)	Gold crown	Implants	Spongy bone	Cortical bone
U _{sum}	-17.86	-16.70	-8.18	-0.28	-19.57
U _z	-11.10	-11.10	-2.72	-0.03	-19.62
S ₁	31.59	-179.99	-6.72	5.96	-37.17
S ₃	0.71	-33.44	-310.74	-11.24	-70.43
S _{int}	-1.26	-18.08	-166.39	4.75	-31.82
S _{eqv}	0.25	-10.22	-196.86	4.00	-39.17

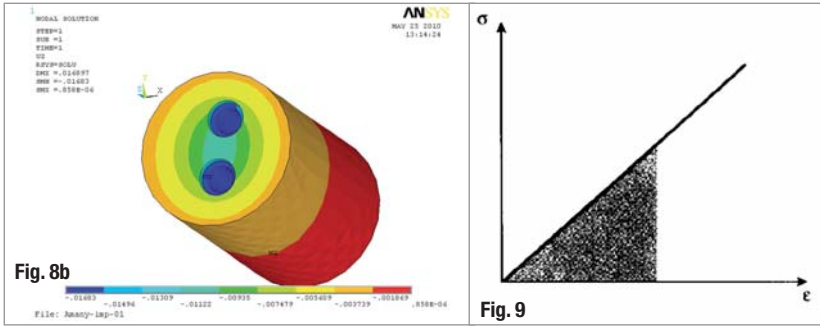


Fig. 9 Strain energy = area under stress strain curve.

is expected. Contrarily more stresses were found on the gold crown placed on two implants due to its volume reduction (less material under the same load). This is clearly seen in increasing stresses on the two implants, that more load effect was transferred through the weak crown to the two implants. That showed maximum stresses in the area under the crown, while the wide implant showed maximum stresses at its tip. Looking to energy** absorption and stress concentration on whole system starting from coating to cortical and spongy bone, although the stress levels found was too low and far from cracking danger, the following conclusions can be pointed out; the total results favourise the two implants in spongy bone and the wide implant in the cortical layer, but the alveolar bone consists of spongy bone surrounded by a layer of cortical bone. It's also well known that according to the degree of bone density the alveolar bone is classified to $D_{1,2,3,4}$ ²³ in a descending order. So, provided that the edentulous space after the molar extraction permits, it's recommended in the harder bone quality ($D_{1,2}$) to use one wide diameter implant and in the softer bone ($D_{3,4}$) quality two average sized implants. Therefore more detailed study to compromise between the two implants size/design and intermediate space can put this stress values in safe, acceptable, and controllable region under higher levels of loading.

lar sized implants were suggested. The aim of this study was to verify the best solution that has the best effect on alveolar bone under distributed vertical loading. Therefore, a virtual experiment using Finite Element Analysis was done using ANSYS version 9. A simplified simulation of spongy and cortical bones of the jaw as two co-axial cylinders was utilized. Full detailed with high accuracy simulation for implant, crown, and coating was implemented. The comparison included different types of stresses and deformations of both wide implant and two regular implants under the same boundary conditions and load application. The three main stresses compressive, tensile, shear and the equivalent stresses in addition to the vertical deformity and the total deformities were considered in the comparison between the two models. The results were obtained as percentages using the wide implant as a reference. The spongy bone showed about 5% less stresses in the two implants model than the one wide diameter implant. The exceptions are the relatively increase in maximum compressive stresses and deformations of order 12 % and 0.3 % respectively. The stresses and displacements on the cortical bone are higher in the two implant model due to having two close holes, which results in weak area in-between. The spongy bone response to the two implants was found to be better considering the stress distribution (energy absorbed by spongy bone**). Therefore, it was concluded that, using the wide diameter implant or two average ones as a solution depends on the case primarily. Provided that the available bone width is sufficient mesio-distally and bucco-lingually, the choice will depend on the type of bone. The harder $D_{1,2}$ types having harder bone quality and thicker cortical plates are more convenient to the wide implant choice. The $D_{3,4}$ types consist of more spongy and less cortical bone, are more suitable to the two implant solution.

Fig. 10 Equation 2 (stress energy).

**The area under the $\sigma-\epsilon$ curve up to a given value of strain is the total mechanical energy per unit volume consumed by the material in straining it to that value (Fig. 9). This is easily shown as follows in equation 2:

$$U^* = \frac{1}{V} \int P dL = \int_0^L \frac{P}{A_0} \frac{dL}{L_0} = \int_0^\epsilon \sigma d\epsilon$$

Fig. 10

Summary

Restoration of single molar using implants encounters many problems; mesio-distal cantilever due to very wide occlusal table is the most prominent. An increased occlusal force posteriorly worsens the problem and increases failures. To overcome the overload, the use of wide diameter implants or two regu-

Editorial note: The literature list can be requested from the author.

_contact	implants
<p>Amr A. Azim Professor, Faculty of Dentistry, Cairo University E-mail: drazim@link.net</p> <p>Amani M. Zaki GBOI. 2009, Egypt E-mail: amani.m.zaki@gmail.com</p> <p>Mohamed I. El-Anwar Researcher, Mechanical Engineering Department, National Research Center, Egypt E-mail: anwar_eg@yahoo.com</p>	



VARIO SR **SCREW-RETAINED**
COMPONENTS FOR
MORE **POSSIBILITIES**

For occlusally screw-retained crown and bridge restorations. Proven CAMLOG handling. Improves safety, saves time thanks to special aligning tool. CAMLOG offers more. Further information: www.camlog.com

a perfect fit™

camlog

Implant fracture:

A look at the physical mechanisms for failure

Authors_Dr Dov M. Almog, Dr Odalys Hector, Dr Samuel Melcer, Dr Kenneth Cheng, USA

The etiology and physical mechanism of fractured dental implants phenomenon have been reviewed and studied at length in recent years.¹⁻⁸ For the most part, the studies concluded that the crown-to-root ratio guidelines associated with natural teeth should not be applied to a crown-to-implant restorations ratio. According to these studies, the crown-to-implant ratios of those implants that were considered successful at the time the reviews took place were similar to those implants that failed. Apparently, according to some of these studies, the guidelines that are used by some clinicians to establish the future prognosis of implant supported restorations are usually empirical and lack scientific validation as far as the possible causes for implant fractures. However, as oral implantology has been the fastest growing segment in dentistry, the gaining of insight into these failure processes, including the accurate understanding of critical anatomical, restorative and mechanical information, might stimulate the clinicians' implementation of preventive action that may avoid the future fractures outcome with dental implants.

Case report

A 72-year-old Caucasian male recently presented to

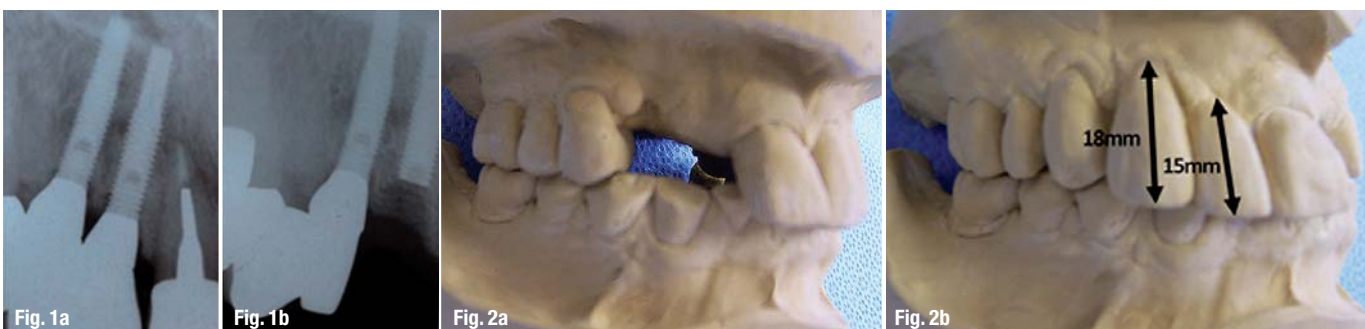our clinic. Consistent with the patient's chief complaint, a comprehensive oral and maxillofacial examination, including full-mouth X-rays, revealed, among other things, two fractured endosseous implants #6 and #7 (Fig. 1).

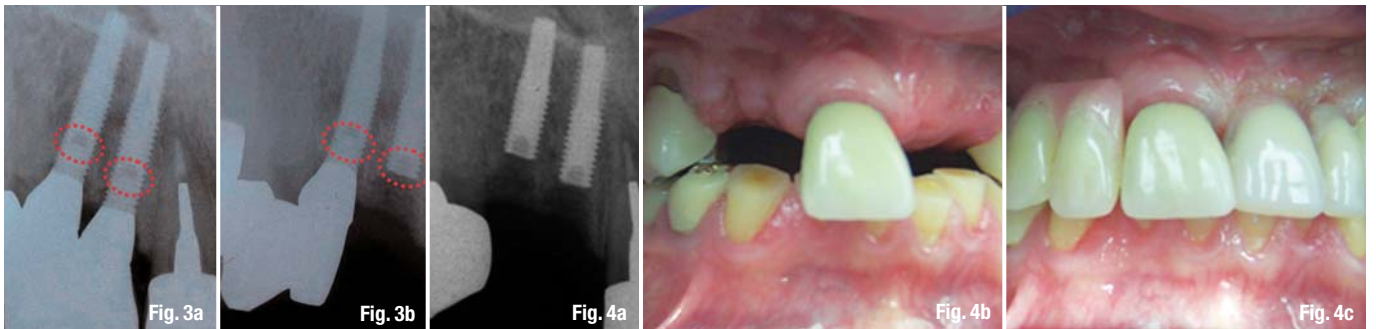
These 3.3 mm x 15 mm implants (Lifecore Biomedical, Chaska, Minn.) were placed and restored in 2003. The implants were placed as per protocol, utilizing a surgical template consisting of two guiding sleeves (De-Plaque, Victor, N.Y.). The implants were allowed to integrate for six months. No surgical complications were noted during this time. At the conclusion of the six-month waiting period, the implants were uncovered in the normal manner and healing abutments placed.

The implants were subsequently restored with implant-supported crowns that were functional for approximately six years until the implants fractured. While this treatment option was developed with an appreciation of the patient's occlusal and mechanical circumstances and habits, following the implants' fracture, a retrospective analysis of the site planned for the implants revealed extended inter-occlusal space on the articulated models and widespread occlusal wear of the opposing dentition (Fig. 2).

Figs. 1a & b_Implants #6 and #7 (Lifecore Biomedical, 3.3 mm x 15 mm) before (A) and after the fracture (B).

Figs. 2a & b_Retrospective analysis of the site planned for the implants #6 and #7 (A) revealed an extended overbite, requiring long crowns (B) to meet esthetic needs, and at the same time, the opposing occlusion presented extensive occlusal wear.





When the patient presented recently to our clinic, the only portion of the restoration that was still present in his mouth was abutment #6, which was still connected to one of the fractured implants, and was removed with a hex driver (Fig. 3). Proceeding with careful assessment of all the available retrospective diagnostic information and upon further discussion with the patient, several diagnostic assumptions and one follow-up treatment option were established that included replacement of the implant-supported crowns by a removable cast partial denture.

Considering the need for the removal of fractured implants must be balanced against the risk of increasing damage, a decision was made to remove the remaining abutment and the fractured piece of implant #6 allowing for primary closure of the soft tissue over the remaining implant bodies #6 and #7, i.e., "put them to sleep" (Fig. 4). This was followed by insertion of an immediate acrylic removable partial denture, and subsequently, a cast partial denture will be fabricated. This report attempts to provide an argument in favor of the consideration of physical mechanisms as potential contributors to implant fractures.

While controversy continues to exist as to whether crown-to-root ratio can serve as an independent aid in predicting the prognosis of teeth,⁹ the same certainly applies to crown-to-implant ratio, unless multiple other clinical indices such as opposing occlusion, presence of parafunctional habits and material electrochemical problems, just to name a few, are considered. Implant fractures are considered one potential problem with dental implants, especially delayed fracture of titanium dental implants due to chemical corrosion and metal fatigue.²

Following careful review of the referenced articles, which are very enlightening, we realized that to a great extent they support our theory that there are multiple factors involved in implant fractures. These factors include magnitude, location, frequency, direction and duration of compressive, tensile and shear stresses; gender; implant location in the jaw; type of bone surrounding the implant; pivot/fulcrum

point in relation to abutment connection; implant design; internal structure of the implant; length of time in the oral environment as it relates to metallurgical changes induced in titanium over time; gingival health and crown-to-implant ratio. Considering the multiple factors involved in implant fractures, both physical and biological, we can only assume that it can happen especially if the forces of the opposing occlusion and/or parafunctional habits are greater than the strength of the implant, especially over time. Therefore, it is imperative that the clinician be knowledgeable about the diversity of factors before recommending dental implants. Errors in diagnosing potential contributors to implant fractures are the most common reason that dental implants fail.

Conclusion

Although, according to the literature, the use of the crown-to-implant ratio in addition to other clinical indices does not offer the best clinical predictors, and even though no definitive recommendations could be ascertained, considering that dental implants are becoming increasingly popular, an increase in the number of failures, especially due to late fractures, is to be expected.⁸ This report attempted to provide an argument in favor of consideration of physical mechanisms as potential predictors to implant fractures. Therefore, it is essential for us to familiarize ourselves with the understanding, and diagnostic competence of the multiple factors involved in implant fractures. Once observed, this predictor would certainly lead to better diagnosis and treatment planning.

Editorial note: The literature list can be requested from the editorial office.

contact

implants


Dr Dov M. Almog, DMD

Chief, Dental Service (160)
VA New Jersey Health Care System (VANJHCS)
385 Tremont Ave., East Orange, N.J. 07018
E-mail: dov.almog@va.gov

In vitro wear of human enamel opposing YTZP zirconia

And various polished dental porcelain surfaces

Authors T. R. Tamba, M. E. Razzoog, B. R. Lang, R. F. Wang, B. E. Lang, UK



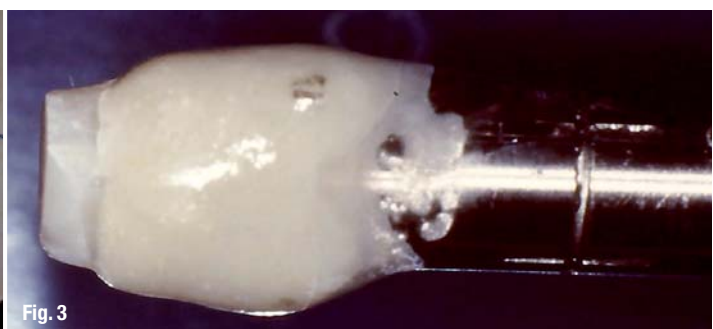
Introduction


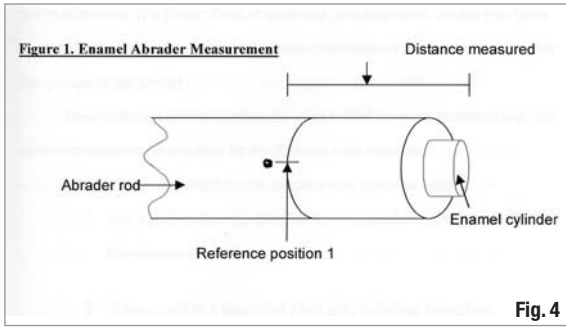
Porcelain fused to metal restorations are the most widely used restorations in dentistry today. However, in some clinical situations a lack of inter-occlusal space does not allow for the appropriate thickness of opaque and dentine porcelains to be applied to the metal substructure.

Consequently, the opaque layer may still be visible and imparts a matt, lifeless appearance to the final restoration. The dentist should also consider the effect the restorative surface will have on opposing enamel. The hardness of a ceramic material has been viewed as a predictor of its potential to abrade human enamel, and thus manufacturers have been pushed to develop ceramics with equivalent hardness to enamel to try and solve the wear issue.^{1,2} However, the microstructural elements of a ceramic as well as fracture toughness and hardness all influence the wear characteristics of the material.^{3,4,5} In an attempt to replicate the colour, texture, translucency and shape of the natural dentition a variety of

all ceramic systems have been developed. Many of these systems have a dense core material, replacing the metal substructure, onto which dental porcelain is veneered to achieve the desired aesthetics. Zirconia has rapidly become the material of choice for use as the core of all ceramic (implant and tooth borne) restorations. The translucency and colour of these cores allow the ceramist to produce a natural looking, aesthetic restoration. Yttrium-Stabilized-Zirconia (YTZP) is one such material and several companies have recently introduced CAD/CAM based systems for milling such units. The physical properties of zirconia have been widely documented: however, the effect of these materials on the natural dentition and on other restorative materials has not been fully investigated.

In normal masticatory function if the veneering porcelain is lost due to modification of the occlusion (chairside adjustment by the dentist or attrition) the zirconia core may come into direct contact with the opposing dentition. Another situation where this might occur is when there is insufficient interarch space for the veneering porcelain resulting in occlusal stops directly on the zirconia core material. One must then consider if it is possible to place the





forces of occlusion directly on the zirconia core material and the possible effects of direct contact with the zirconia core on the opposing dentition. In both situations two—surface (body) wear will occur resulting in loss of both enamel and restorative material. The goal of restorative dentistry is to develop a restorative surface that has the same wear characteristics as human enamel.

The specific aim of this study was to compare the *in vitro* wear characteristics of human enamel against a zirconia based core material with two surface finishes and various zirconia and aluminium oxide specific porcelains. The zirconia core material was studied in its as-manufactured state and after undergoing polishing with a proprietary polishing kit and diamond polishing paste. The dental porcelain surfaces underwent various surface treatments of which the polishing process was identical to that applied to the zirconia, allowing a direct comparison of zirconia and porcelain surfaces. A polished type IV gold surface acted as the control surface for the wear study. Laser videography (Mitutoyo / MTI corp. Aurora III™) was the method employed to assess the wear that occurred on the porcelain, gold and zirconia samples as a result of abrasion by human enamel, however, only the enamel wear data will be presented here.

Materials and Methods

Discs of YTZP stabilised zirconia core material 13.0 mm in diameter and 2.00 mm in thickness (Figs. 1 & 2) were supplied by the manufacturer (Procera;

Nobel Biocare, Kloten, Zurich, Switzerland). For the purposes of the article the term "zirconia" will equate to "YTZP stabilised zirconia core material". Discs of type IV gold of the same dimensions were fabricated by the examiner to serve as a control surface—"G" in the results tables and graphs. The zirconia samples were divided into two groups:


- The as manufactured group—"Za" in the results tables and graphs with the surface finish as delivered from the manufacturer (Procera; Nobel Biocare, Kloten, Zurich, Switzerland).
- The polished group—"Z" in the results tables and graphs—the test surface of the zirconia samples underwent polishing with a proprietary polishing system (Dialite ceramic polishing system, Braseler™) and diamond polishing paste (Ultradent™).

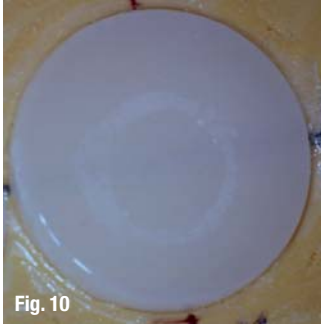
Discs of dental porcelains 20 mm in diameter and 3–5 mm in thickness were supplied by the various manufacturers outlined below (Fig. 3). The dental porcelains underwent three separate surface treatments, specifically:

- Application of an external glaze (powder glaze).
- Autoglazing (self glaze procedure).
- Mechanical polishing (same method used with the zirconia core material).

The dental porcelains evaluated in the study were:

- CZR Cerabien—Zirconia specific porcelain (Nori-take™)—"C" in results tables and graphs.





- Cerabien—alumina framework specific porcelain (Noritake™)—“C” in results tables and graphs.
- Willi Geller Creation AV—for use with aluminium oxide cores, InCeram Spinell and InCeram Zirconia core material (Jensen Industries™)—“J” in results tables and graphs.
- VITA Alpha 900 – alumina specific porcelain (VITA Zahnfabrik™)—“V” in results tables and graphs.

The test porcelains in Groups 1 and 2 (CZR Cerabien and Cerabien) are both designated “C”. Most porcelain systems have enamel porcelain as the final layer when fabricating a crown. However, Noritake™ has designed the CZR Cerabien and Cerabien systems to use a second distinct layer of super-fine particle sized enamel porcelain on top of the basic enamel porcelain in an attempt to improve the wear characteristics of the restoration. This layer is called the Luster porcelain. It is not an over-glaze. The rationale behind the development of the Luster porcelain is that the glass particle size is more important than the hardness of the porcelain in determining the wear characteristics of the material. The Luster layer utilized in both the CZR Cerabien and Cerabien is the same material forming the final surface finish of the restoration. For this reason only one set of test samples was fabricated from the Luster porcelain. The results produced by the wear study would apply to both porcelains as the Luster layer undergoes any and all surface treatments. Therefore, the designation “C” is given to both the CZR Cerabien (zirconia specific) and Cerabien (aluminous) porcelains. The polished surface treatment was the only surface treatment that the dental porcelains and the zirconia core material experienced so only this data will be presented here. The type IV gold control sample was polished to high shine finish using gold polishing compounds and a buffing wheel attached to a polishing lathe. A proprietary polishing system (Dialite®) was used to polish the porcelain and zirconia samples. The system consists of a series of colour coded, diamond impregnated, abrasive wheels of increasing fineness, blue—course, red—intermediate, grey—extra-fine. Once the Dialite® polishing sequence was completed a final polish was carried out using 1 micron grit diamond polishing paste (Ultradent™) and a flannel cloth wheel (Brasseler™).

A motor driven wear machine was fabricated to simulate the accelerated wear of human enamel against various surfaces (Fig. 4). The wear machine consisted of a variable speed motor connected to a rotating drum by a belt driven bearing assembly through which a series of abraders rods, on to which

the enamel samples were attached, could be fed. The test sample blocks were positioned beneath the rotating drum within a water bath. The water bath contained a solution consisting of 50 % Glycerine and 50 % Ethanol which was also the storage medium used to preserve the enamel samples.

The abraders rods were held in position by a holding sleeve that passed through the rotating drum parallel to the rotational axis of the drum but off centre. This resulted in the abraders rods producing a circular path of motion with an inner diameter of 7 mm and a maximum outer diameter of 12 mm. The variable speed motor allowed the wear machine to run at a frequency of 0–100 rpm. All test samples were run at a frequency of 65 rpm. A 500 g external load was applied to each enamel abraders sample by means of a weight placed on the abraders rod and all samples were run for a total of 10,000 cycles (Figs. 5 & 6). Newly extracted, caries free human third molars were used to obtain adequate enamel specimens. All teeth were stored in a solution consisting of 50 % Glycerine and 50 % Ethyl alcohol to avoid desiccation and maintain enamel integrity. A trephine bur (used to biopsy bone) was used to score the enamel surface to aid cutting samples of similar dimensions. All cutting was completed with high-speed diamond burs with copious irrigation to prevent overheating the enamel and desiccating the samples. The enamel was cut into 3 mm diameter cylinders that extended at least 5 mm into dentine and placed in the storage medium. The enamel cylinder was then attached to the reference end of an abraders rod with a small drop of cyanoacrylate resin and reinforced with polymethyl methacrylate resin (Fig. 7).

The dentine side of the enamel sample was pressed against the flat end of the abraders rod leaving the enamel exposed to wear. All enamel measurements (Fig. 8) were made using a digital travelling micrometer (Mitutoyo™) accurate to 0.001 mm as follows. At the reference end of each abraders rod a fine line was scribed around the circumference of, and 10 mm from the end of, the abraders rod. A second set of lines were then scribed parallel to the long axis of each abraders rod bisecting the initial scribe line at 90° intervals to produce four cross-hair marks. One of the cross hair marks had a further “dot-mark” placed and this was designated “reference position 1” (Fig. 8). Measurements of enamel length were made from each reference position to the edge of the enamel with the digital travelling micrometer.

The arithmetic mean of these four readings per sample was taken to be the overall sample length. By subtracting the post wear measurement from the

SAVE CELLS

NEW EMS SWISS INSTRUMENTS SURGERY – SAVING TISSUE WITH NEW INNOVATIONS IN IMPLANT DENTISTRY

The inventor of the Original Piezon Method has won another battle against the destruction of tissue when dental implants are performed. The magic word is dual cooling – instrument cooling from the inside and outside together with simultaneous debris evacuation and efficient surgical preparations in the maxilla.

COOLING HEALS

A unique spiral design and internal irrigation prevent the instrument's temperature from rising during the surgical procedure. These features combine effectively to promote excellent regeneration of the bone tissue.

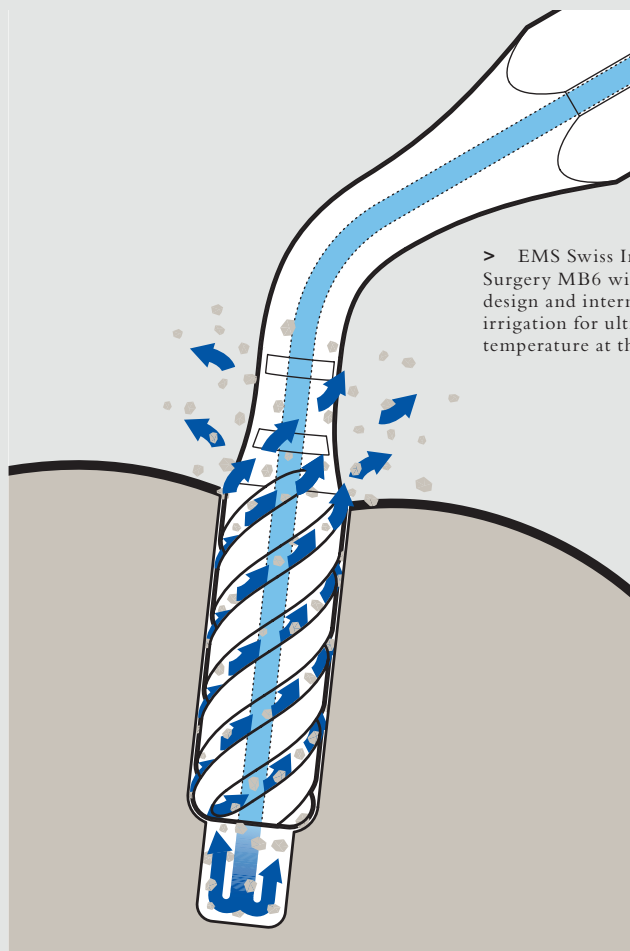
EMS Swiss Instruments Surgery MB4, MB5 and MB6 are diamond-coated cylindrical instruments for secondary surgical preparation (MB4, MB5) and final osteotomy (MB6). A spiral design combined with innovative dual cooling makes these instruments unique in implant dentistry.

CONTROL SAVES

Effective instrument control fosters atraumatic implant preparation and minimizes any potential damage to the bone tissue.

PRECISION REASSURES

Selective cutting represents virtually no risk of damage to soft tissue



> EMS Swiss Instrument Surgery MB6 with unique spiral design and internal instrument irrigation for ultralow temperature at the operative site

(membranes, nerves, blood vessels, etc.). An optimum view of the operative site and minimal bleeding thanks to cavitation (hemostatic effect!) further enhance efficacy.

The new EMS Swiss Instruments Surgery stand for unequalled Swiss precision and innovation for the

benefit of dental practitioners and patients alike – the very philosophy embraced by EMS.

For more information >
www.ems-swissquality.com



initial baseline measurement the amount of enamel wear that occurred during the experiment (in microns) was determined. A custom jig made from an aluminium block with a locking set-screw ensured that the abrader rod (and enamel sample) could be repositioned in the same location on the table of the digital micrometer (Fig. 9) when taking measurements. This meant all enamel measurements were made with the cross-hair marks on the abrader rod in the same focal plane for both the baseline and post-wear measurements. At each measurement "reference position 1" was lined up with the locking set screw on the custom jig so all measurements were completed in the same clockwise sequence. All measurements were completed by the same observer to avoid inter-observer error and each measurement for each reference position was made five times (arithmetic mean determined) to ensure all readings were accurate.

Each enamel sample was held perpendicular to the test substrate to ensure uniform wear. Enamel samples were initially run in the wear machine against 600 micron grit silicon carbide paper in the artificial saliva medium to produce a smooth, uniform flat surface with at least 0.5 mm thickness of enamel remaining. The sample was then removed from the wear machine and baseline enamel length figures were recorded as outlined above. The test

block was then placed in the water bath filled with saliva substitute and positioned on the wear machine. Enamel specimens were then passed through the rotating drum in the holding sleeve and lined up on the appropriate test sample. An unloaded test cycle (1 revolution) was carried out to ensure the enamel was abrading around the centre of the test specimen. The test block was then secured to the wear machine by means of two C-clamps. The 500 g load was applied to the abrader rod and the wear machine was activated at a speed of 65 rpm and run for exactly 10,000 cycles. The process was repeated for each test sample in each test group (Figs. 10 & 11).

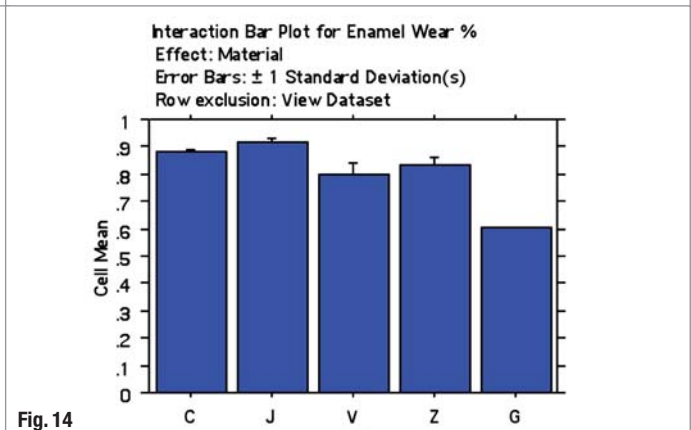
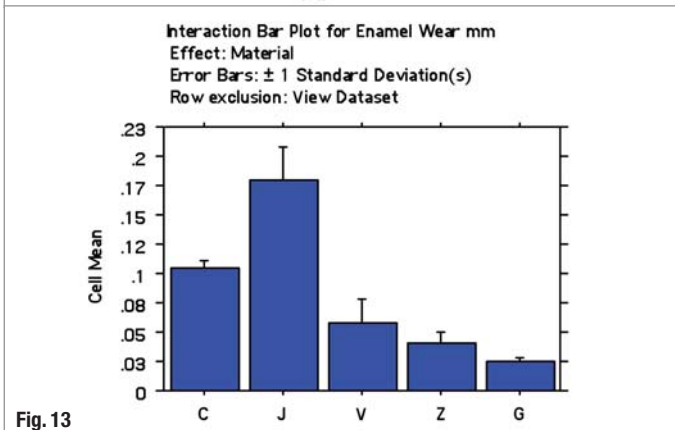
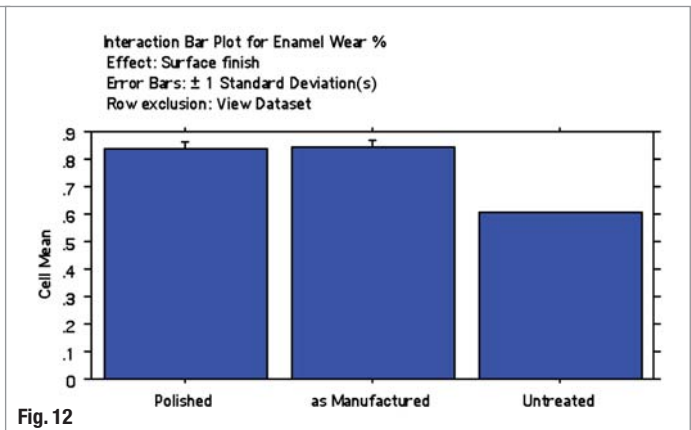
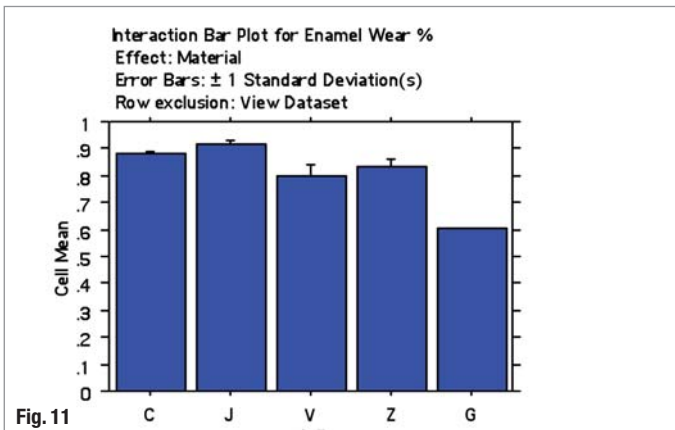
The amount of wear experienced by the test surface after being abraded by human enamel was also determined. This was achieved by using a laser videography procedure that involved scanning the sample surface (pre and post enamel abrasion) to determine how much wear the test surface experienced from abrasion by human enamel. Thus the total amount of wear in microns that occurred within this two-body wear system—enamel plus substrate—was determined. This was equal to 100% of the total wear occurring in that sample group. By converting the micron loss figures to a ratio the percentage enamel wear figures were determined. The data obtained was analyzed using a One-way ANOVA statistical analysis with a significance level of P=0.05.

Fig. 11_Enamel wear micron loss zirconia vs gold.

Fig. 12_Enamel wear percentage loss zirconia vs gold.

Fig. 13_Enamel wear wear micron loss polished surface finish.

Fig. 14_Enamel wear percentage loss polished surface finish.



_Results

Key for table headings: SS = Sum of Squares, MS = Mean Squares, SD = Standard Deviation, SE = Standard Error, MD = Mean Difference, CD = Critical Difference.

	Za	Z	G
Sample 1	0.030 mm	0.036 mm	0.023 mm
Sample 2	0.050 mm	0.055 mm	0.028 mm
Sample 3	0.051 mm	0.034 mm	0.021 mm
Sample 4	0.045 mm	0.036 mm	0.026 mm

Tab. 1

Tab. 1 Mean values for enamel loss in microns when opposing zirconia core material as manufactured and post-polishing.

	DF	SS	MS	F-Value	P-Value	Lambda	Power
Surface finish	2	0.001	4.28E.04	6.384	0.0188	12.768	0.774
Residual	9	0.001	6.71E.05				

Tab. 2

Tab. 2 One-way ANOVA on surface finish zirconia (Za, Z) gold control (G): p = 0.05). anova table for enamel wear mm row exclusion: view data set.

	DF	SS	MS	F-Value	P-Value	Lambda	Power
Surface finish	2	0.049	0.025	35.151	0.0005	70.303	1.000
Residual	6	0.004	0.001				

Tab. 3

Tab. 3 ANOVA Table for enamel wear % Row exclusion: view dataset.

	Count	Mean	SD	SE
Z	4	0.04	0.01	0.005
Za	4	0.044	0.01	0.005
G	4	0.025	0.003	0.002

Tab. 4

	Count	Mean	SD	SE
Z	4	0.834	0.028	0.014
Za	4	0.847	0.025	0.012
G	1	0.605		

Tab. 5

Tab. 4 Means table for enamel wear mm Effect: surface finish Row exclusion: view dataset

Tab. 5 Means table for enamel wear % Effect: surface finish Row exclusion: view dataset

	MD	CD	P-Value	
Z:Za	-0.004	0.013	0.5335	
Z:G	0.016	0.013	0.0236	S
Za:G	0.019	0.013	0.0083	S

Tab. 6

	MD	CD	P-Value	
Z:Za	-0.012	0.046	0.5427	
Z:G	0.229	0.073	0.0002	S
Za:G	0.241	0.073	0.0002	S

Tab. 7

Tab. 6 Fisher's PLSD for enamel wear mm Effect: surface finish Significance level: 5% Row exclusion: view dataset

Tab. 7 Fisher's PLSD for enamel wear % Effect: surface finish Significance level: 5% Row exclusion: view dataset

Tab. 8 One-way ANOVA on material, polished surface finish. P = 0.05
C (CZR, Cerabien), J (Willi Geller Creation AV), V (VITA Alpha 900), Z (zirconia), G (gold)
ANOVA table for enamel wear mm
Row exclusion: view dataset

	DF	SS	MS	F-Value	P-Value	Lambda	Power
Material	4	0.063	0.016	6.384	0.0188	12.768	0.774
Residual	15	0.004	2.760E-4				

Tab. 8

Tab. 9 ANOVA table for enamel wear %
Row exclusion: view dataset

	DF	SS	MS	F-Value	P-Value	Lambda	Power
Material	4	0.094	0.024	35.727	< 0.0001	142.906	1.000
Residual	12	0.008	0.001				

Tab. 9

Tab. 10 Means table for enamel wear mm
Effect: material
Row exclusion: view dataset

	Count	Mean	SD	SE
C	4	0.105	0.006	0.003
J	4	0.180	0.028	0.014
V	4	0.057	0.021	0.011
Z	4	0.040	0.010	0.005
G	4	0.025	0.003	0.002

Tab. 10

Tab. 11 Means table for enamel wear %
Effect: material
Row exclusion: view dataset

	Count	Mean	SD	SE
C	4	0.882	0.010	0.005
J	4	0.919	0.013	0.006
V	4	0.797	0.040	0.020
Z	4	0.834	0.028	0.014
G	1	0.605		

Tab. 11

Tab. 12 Fisher's PLSD for enamel wear mm
Effect: material
Significance level: 5%
Row exclusion: view dataset

	MD	CD	P-Value	
C, J	-0.075	0.025	< 0.0001	S
C, V	0.048	0.025	0.0010	S
C, Z	0.065	0.025	< 0.0001	S
C, G	0.081	0.025	< 0.0001	S
J, V	0.123	0.025	< 0.0001	S
J, Z	0.140	0.025	< 0.0001	S
J, G	0.155	0.025	< 0.0001	S
V, Z	0.017	0.025	0.1684	
V, G	0.033	0.025	0.0138	S
Z, G	0.016	0.025	0.1999	

Tab. 12

Tab. 13 Fisher's PLSD for enamel wear %
Effect: material
Significance level: 5%
Row exclusion: view dataset

	MD	CD	P-Value	
C, J	-0.036	0.040	0.0686	
C, V	0.085	0.040	0.0005	S
C, Z	0.048	0.040	0.0218	S
C, G	0.277	0.063	< 0.0001	S
J, V	0.122	0.040	< 0.0001	S
J, Z	0.084	0.040	0.0006	S
J, G	0.313	0.063	< 0.0001	S
V, Z	-0.037	0.040	0.0619	
V, G	0.192	0.063	< 0.0001	S
Z, G	0.229	0.063	< 0.0001	S

Tab. 13

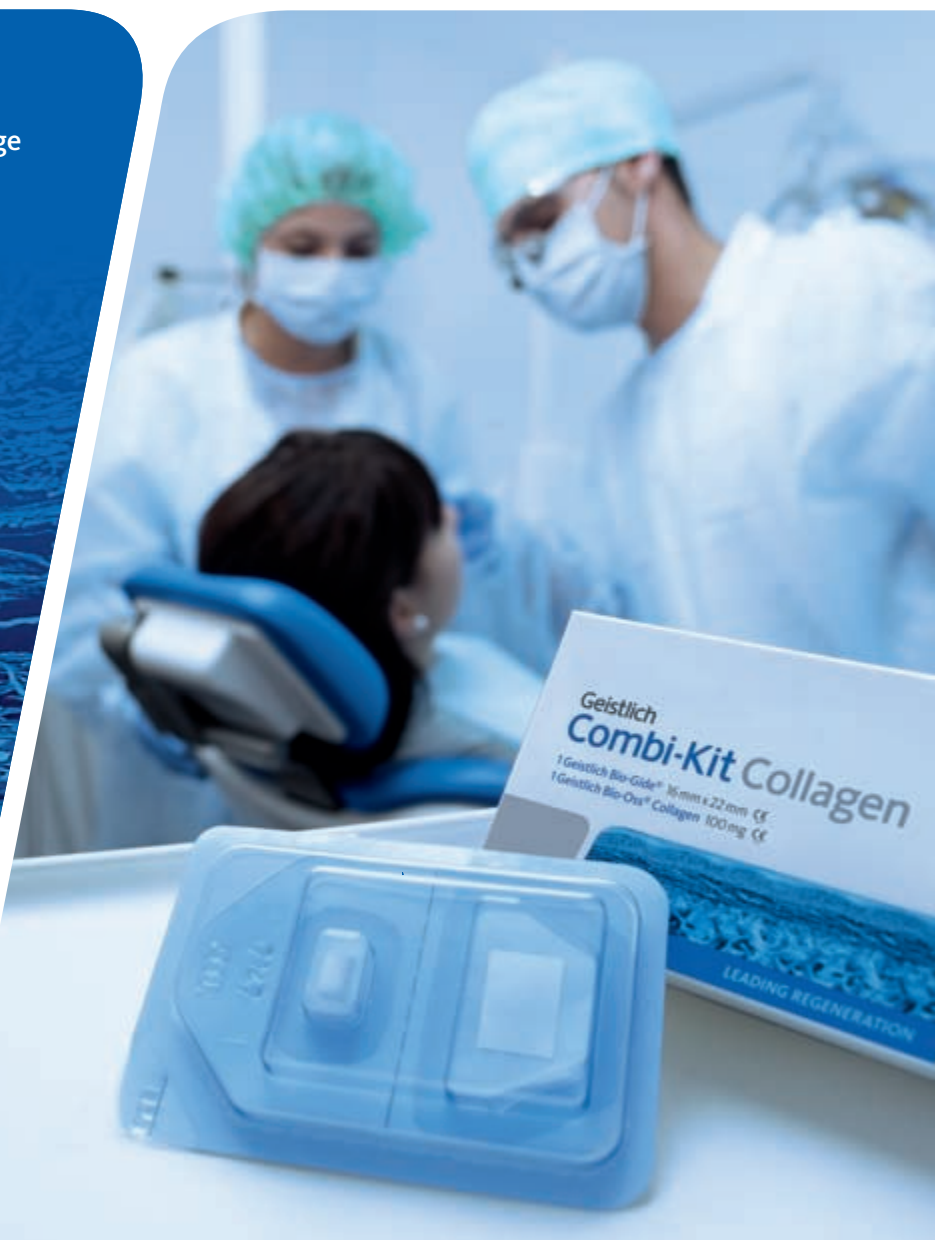TIP:

Please have a look at Figs. 11 & 12 after the Tabs. 6 & 7 and at Figs. 13 & 14 after Tabs. 12 & 13.

Geistlich Combi-Kit Collagen

The new kit for success.

Geistlich Combi-Kit Collagen – the best kit for successful and predictable results in ridge preservation and minor augmentations.



Discussion

Wear of dental hard tissues is a naturally occurring and inevitable phenomenon. However, when human enamel is opposed by ceramic (or other restorative material) the enamel experiences accelerated wear. Developing a material of equivalent hardness to human enamel was seen as the solution to the enamel wear problem.^{1,2} However, it has now been shown that microstructural differences and changes in surface topography are much more important than hardness.³ To account for these variables the chemical make up of the veneering porcelain was (and still is being) modified to produce the conventional aluminous porcelains e.g. VITADUR ALPHA, machinable ceramics e.g. VITA Mark II and the hydrothermal porcelains e.g. Duceram-LFC. Studies on the wear characteristics of these porcelains produced varying results^{13,14,15} with no significant reduction in abrasiveness to human enamel. The pattern of enamel wear varies according to the ceramic system used and its surface characteristics.^{4,6,7,8,9,13,16} The amount of wear that will occur on both the restored surface and opposing enamel is an important consideration in dentistry as this will affect tooth movement and the vertical dimension of occlusion. Restorative dentistry must therefore provide restored occlusal surfaces that are wear resistant themselves and more importantly, do not promote excessive wear of the opposing occlusion.^{4,5}

The major driving force in dentistry today is aesthetics. Several all ceramic systems have been developed. Most of these systems rely on a core material onto which a porcelain veneer is applied. Some of the most studied systems are Dicor™ (a castable glass ceramic), IPS Empress (leucite core, lithium disilicate core in Empress II and E-max) and In-Ceram (aluminium oxide core). The advent of improved zirconia systems such as Procera™ and Etkon™ shows a wide availability of systems on the market today. However, all these systems rely on veneering porcelains and several studies have demonstrated that these veneering porcelains are more abrasive to human enamel than the core material itself.^{4,6,7,8,9,13,16}

Zirconia based core materials have recently been introduced. Several companies have introduced CAD/CAM systems to produce cores for natural tooth restorations as well as abutments and bridges for implant based single and multiple unit restorations. This study examined the *in vitro* wear of human enamel against a zirconia (YTZP) core material with two surface finishes and various dental porcelains designed specifically for veneering zirconia and alumina cores to produce all ceramic restorations. A polished type IV gold surface acted as a con-

trol surface. The porcelain surface was compared to the zirconia surface to determine if the application of the veneering porcelain was beneficial or detrimental to human enamel i.e. is it less harmful to enamel to have the zirconia core exposed or veneered? Studies have shown that a polished dental porcelain surface is the least abrasive porcelain surface finish to human enamel.^{10,11,12} The entire study did evaluate the autoglaze and powder glaze surface finishes as well but only the polished finish was the same for both zirconia and the test porcelains so it was the only data presented here.

Wear does not occur in isolation. It is not just the enamel that is abrading but also the opposing restorative surface. The ideal situation is for the enamel and the opposing restorative material to have the same physical and mechanical properties. This way the restorative: enamel interface should wear at the same rate as an enamel: enamel interface. To date, the least abrasive surface to human enamel is a highly polished type IV gold surface.⁵ This is seen as the standard to which all other materials are compared. Most, if not all, studies show that dental porcelains (regardless of surface finish) and all the ceramic core materials are far more abrasive to human enamel than a polished type IV gold surface.^{4,6,7,9}

Zirconia has greater strength and flexibility compared to aluminium oxide, allowing thinner cores of equivalent strength to be fabricated. This allows the use of zirconia in situations where inadequate occlusal clearance exists for an aluminium oxide core. The only alternative would then be a metal-ceramic restoration with exposed metal occlusal contacts. Zirconia has now largely superseded aluminium oxide as the core material of choice for most all ceramic restorations. Initially the zirconia cores had a bluish white colour; however, shaded versions are now available to improve aesthetics.

The Power value for the one-way ANOVA data set for the polished zirconia and porcelain surfaces versus the type IV gold control is 1.00. The Power value for the one-way ANOVA data set for zirconia versus type IV gold is 0.774 for zirconia mm wear data set making the results statistically significant although the sample size is small. Considering the polished zirconia vs type IV gold results (Tab. 1) samples 1, 3 and 4 produced virtually identical levels of enamel wear (mean 0.035 mm) where as sample 2 produced significantly more wear (0.055 mm). Thus sample 2 had a significant negative impact on the data set.

The significance level for this study is $P = 0.05$. The results of this experiment show that the zirconia core material in its as-manufactured state and

after a proprietary polishing procedure produces minimal wear of human enamel. When compared directly with a polished type IV gold surface, the zirconia (both surface finishes) does produce statistically significantly more enamel wear than the control. When comparing the two zirconia surface finishes to each other, the polished zirconia surface produced less enamel wear than the as-delivered surface but the difference was not statistically significant.

Several all-ceramic veneering porcelains were also evaluated in this study. The polished zirconia surface underwent the same polishing procedure as the veneering porcelains allowing a direct comparison between gold, zirconia and porcelain. This was to determine whether the application of veneering porcelain would have a positive or negative impact with regards to the abrasiveness of the restorative surface. Firstly, when the polished porcelain surfaces were compared to the type IV gold control surface all the polished porcelain surfaces were statistically significantly more abrasive to human enamel. This result corresponds with earlier studies.^{8, 9, 10, 11, 12} Secondly, there was no statistically significant difference between the polished zirconia surface and the polished type IV gold control surface ($p > 0.05$) indicating that the polished zirconia surface was equivalent to a polished gold surface in its level of abrasiveness to human enamel.

In this study the application of veneering porcelain to the zirconia core material statistically significantly increased the abrasiveness of the zirconia surface to human enamel. The polished zirconia surface was statistically comparable to a polished gold surface in its degree of abrasiveness to human enamel indicating that it is beneficial to have polished zirconia forming the occlusal contact surfaces rather than applying a porcelain veneer.

Zirconia has far greater strength than aluminium oxide when in similar dimension. The possibility therefore exists to use zirconia as a core material in the posterior region of the mouth and in high occlusal load areas where the occlusion can be placed directly on the core material (cingulum of upper canines and occlusal surfaces of molars) if the restoration is opposing enamel. The porcelain veneer is then placed mainly for aesthetics. If the restoration is opposing another crown then the application of a porcelain veneer is optional.

The use of CAD/CAM technology allows fabrication of customized zirconia cores, abutments and bridges to restore natural teeth and dental implants with the appropriate reduction for veneering

porcelain. This is known as the "dual scan" technique where the technician uses either casting wax or a composite resin to build up the proposed restoration—crown or bridge—to full contour and in occlusion with the opposing arch. The wax or resin pattern is then "cut back" leaving all the centric stops intact and supporting the opposing occlusion. This modified pattern is then scanned to produce the customised zirconia framework with all the occlusal loads being borne directly on the core material. The increased thickness of the zirconia in these areas improves both the physical and mechanical properties of the core. This does not imply that one can simply rely on the strength of restorative materials to withstand high occlusal loads and simply ignore the underlying causes, such as bruxism and parafunctional habits. Diagnosis, treatment planning and prescribing the appropriate restorative surfaces are just as important today as they have been in the past.

Conclusions

Within the limitations of this study the following conclusions can be made:

- The type IV gold surface produced the least amount of enamel wear.
- The polished zirconia surface produced less enamel wear than the as-manufactured zirconia surface but the result was not statistically significant when compared directly to the type IV gold control surface.
- The polished and as-manufactured surfaces produced statistically significantly greater enamel wear than the type IV gold control surface.
- All the veneering porcelains produced statistically significantly more enamel wear than the type IV gold control surface.
- When viewing all the polished surface data (zirconia, porcelains and type IV gold) the polished zirconia surface was not statistically significantly more abrasive than the type IV gold control surface ($p > 0.05$). All the porcelains were significantly more abrasive than the type IV gold control surface.

Editorial note: The literature list can be requested from the author.

contact

implants

Dr Tussavir Tambra

Wolverhampton, UK

E-mail: dr.tambra@hotmail.co.uk

Sinus lift without scalpel

Authors_Dr Philip Jesch, Dr Klaus Eder, Austria

_Owing to the loss of vertical bone volumes in the maxillary sinus area, an implantation with sufficient primary stability is often not possible. In many cases a therapeutical consequence is introduction of a bone augmentation in the sinus area (sinus lift). Fear of this procedure and higher costs are often the causes of why patients resist having this operation done. Because of these reasons, our development moved to the next step. With the JEDER®-System it is possible to perform a sinus lift without the use of a scalpel. In comparison to the conventional lateral fenestration of the buccal sinus bone, in our procedure all one needs is a small opening on the crestal alveolar ridge. Over this opening it is possible to place the augmentation material and the implant itself. The risk of a rupture in the Schneiderian membrane can also be reduced through this innovative technique.

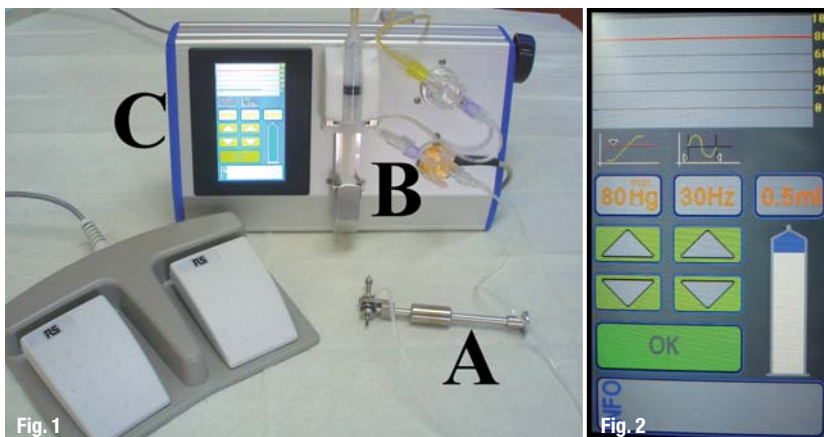
_Virtually bloodless procedure

In order to place implants, maxillary bone substance with sufficient height and diameter is required. Owing to atrophic processes it becomes increasingly

difficult to place implants after tooth loss. Under such atrophic conditions it is not possible to place implants with sufficient primary stability, especially when the maxillary bone height falls below 4 mm. In these cases an augmentation is unavoidable. Hence it is necessary to place augmentation material between the sinus floor and the Schneiderian membrane: the sinus lift.

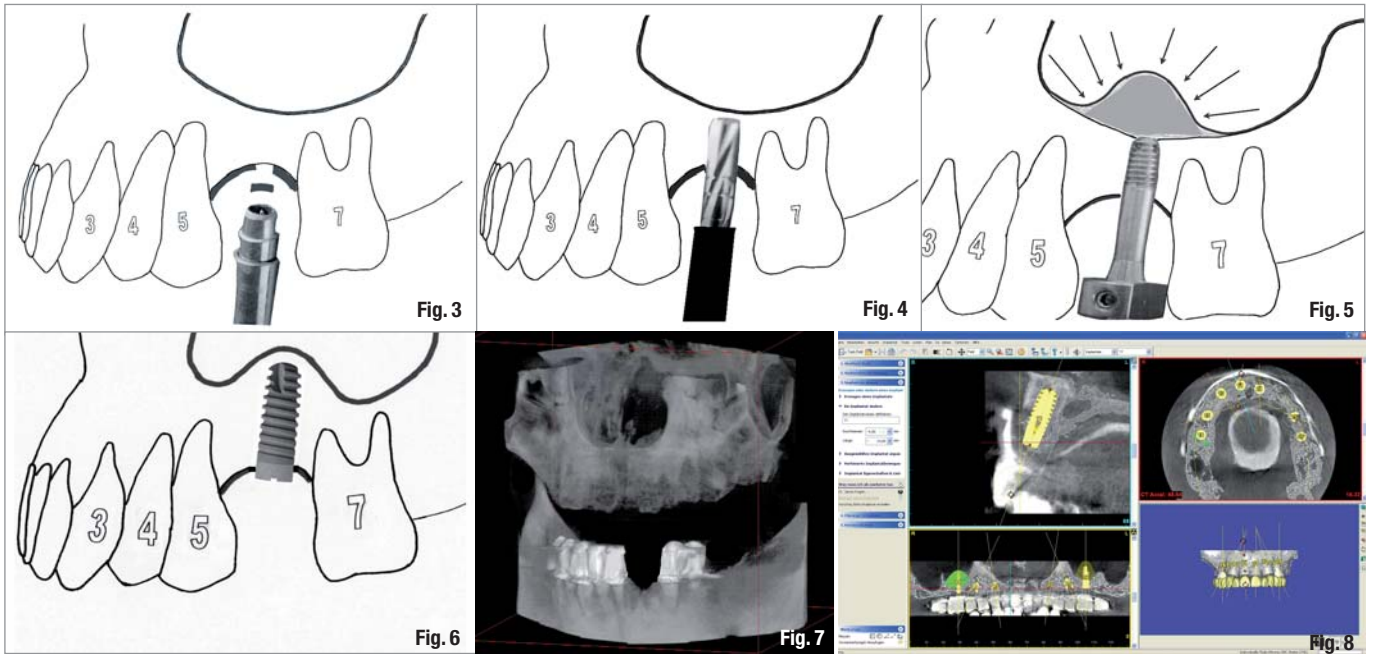
With this innovative surgical technique it is possible to simply lift the Schneiderian membrane in a gentle and safe manner through a 3.5 mm opening in the crestal bone with the use of the JEDER®-System (Fig. 1 A-C) (Patent AT 507208 & Patent AT 504552). After the membrane has been lifted with the aid of a pressurized, oscillating saline solution depicted graphically on the display (Fig. 2), the bone augmentation material can be inserted into the newly formed cavity above the hole of the initial drilling. A successive implantation immediately after augmentation poses no problem. This surgical technique drastically reduces postoperative pain and ensures the surgeon simultaneous feedback-control during the procedure itself. At the same time, the classical risks of swelling and membrane rupture are reduced. The surgical procedure is explained in the following three simple steps.

Fig. 1_The JEDER®-System.
Fig. 2_Pressure-, Frequency-, and Volume-Monitor.



1.) *A.T.P-Punch (Atraumatic Transgingival Perforation)*

After application of the local anaesthesia, the A.T.P-Punch (Fig. 3), developed by Prof Dr Wolfgang Jesch (sales: DENTSPLY Friudent) is used to punch through the mucoperiosteum. Simultaneously the punch makes a small incrementation in the crestal bone in which the primary drill for implantation can gain purchase. The advantages in perforating of the soft tissue in this manner are: a clean access to the alveolar ridge and a minimal invasive procedure that makes a smaller wound, resulting in fewer traumas and less pain for the patient. After the A.T.P-Punch is



used, the JEDER®-System is applied. This system is comprised of two components: The Pressure Bone Drill (P.B.D) and the Sinus Vibration Pump (S.V.P).

2.) The Pressure Bone Drill (P.B.D)

The drilling is continued until just below the sinus floor (Fig. 4). If necessary a panoramic X-ray can be done in order to examine the exact position of drill depth. After fixing the tight fitting P.B.D (Fig. 1A) measurable pressure is created using saline solution. In the inside of the P.B.D a drill moves forward at a rate of one tenths of a millimetre in the direction of the sinus floor. As soon as the slightest perforation is made through the remaining bone, the saline solution (which is under pressure) forces the schneiderian membrane upward and away from the pursuing drill that could damage the membrane. Since a resulting loss in pressure can be measured using the JEDER®-System, the forward-moving drill is abruptly stopped by the surgeon.

3.) Sinus Vibration Pump (S.V.P)

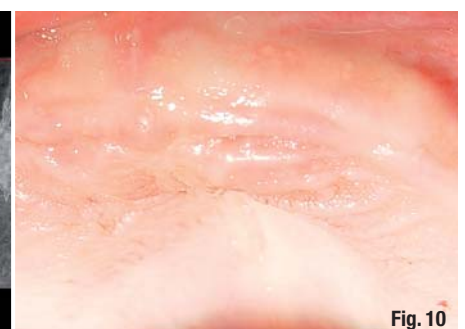
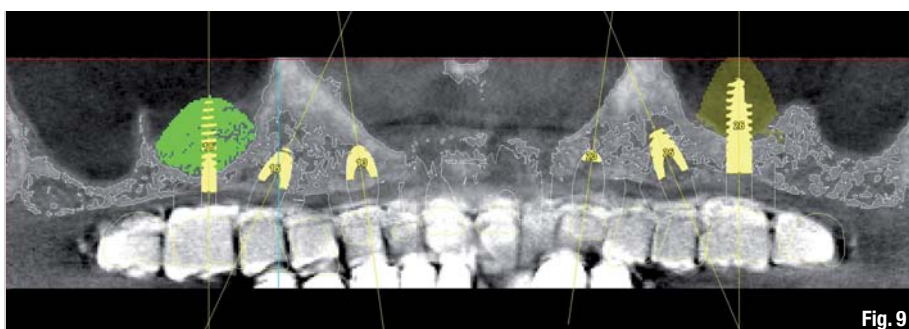
After successful "penetration" of the remaining bone volume a panoramic X-ray can be made to ensure that a bubble was made with the aid of the pressurized

saline solution. After this step, the saline solution is brought into oscillation with the aid of the S.V.P (Fig. 1B). At the same time the volume of the solution can be increased precisely (Fig. 1C). Through this method the Schneiderian membrane can be lifted more easily from the sinus floor (Fig. 5). After pumping the saline solution out of the cavity, this newly formed cavity can be filled with the bone augmentation material. According to our protocol we place the implants immediately after augmentation (Fig. 6).

The surveillance of the operation is monitored in its entirety through constant pressure and volume measurements. A simple technique to determine if a membrane rupture has taken place is the conventional valsalva test commonly practiced after wisdom tooth removal in the maxilla. An advanced way of checking a rupture was with the aid of an endoscope, which we used in the preliminary examinations. Setting the implants always went according to the guidelines of the implant manufacturer. The healing phase was set at three months in each case. Similar technology uses a balloon to lift the membrane. The difference in the Jeder®-System is the comparative reduction of fric-

Fig. 3 _A.T.P-Punch for the minimal invasive approach.
Fig. 4 _Drill until slightly below the sinus floor.
Fig. 5 _Schneiderian membrane being lifted through the saline solution.
Fig. 6 _Implant in place.
Fig. 7 _Preoperative volume tomography.
Fig. 8 _Digital planning of the implant positions.

Fig. 9 _Virtual measurement of sinus lift volume.
Fig. 10 _Maxilla before operation.



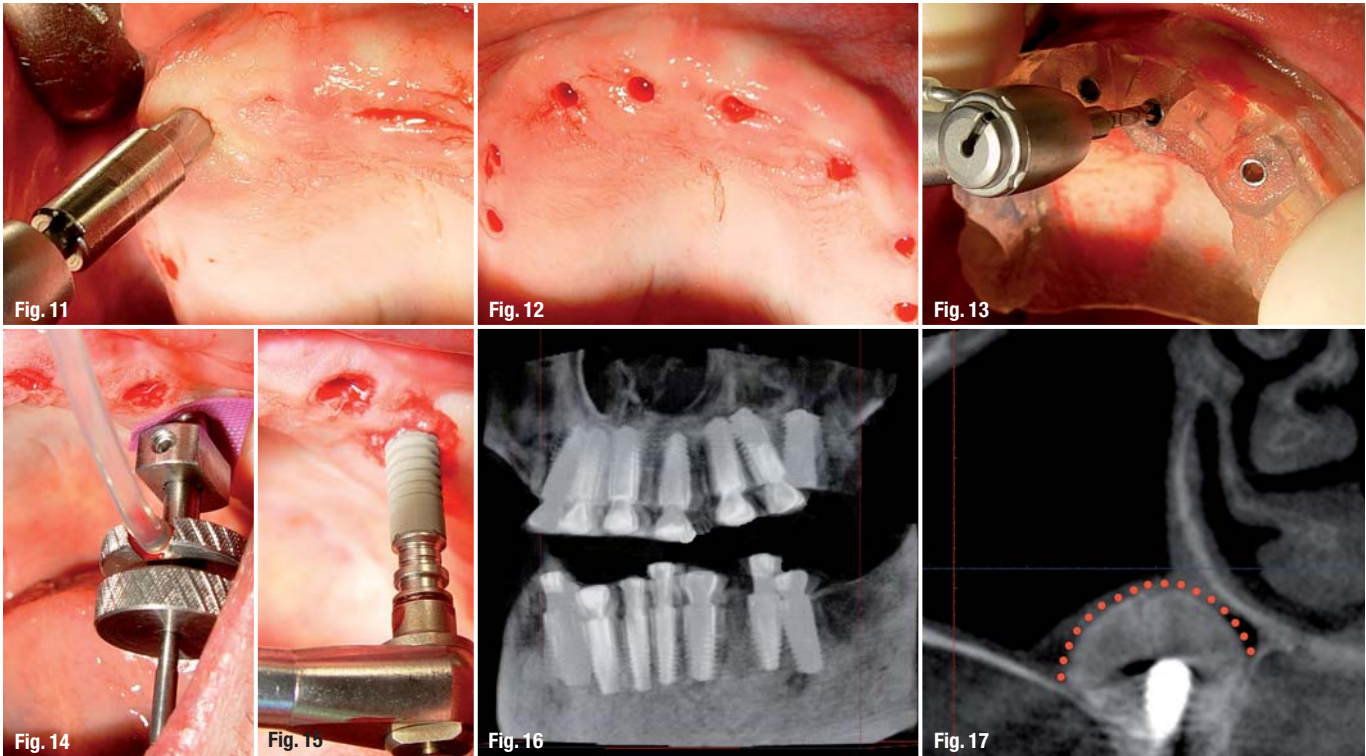


Fig. 11 Use of the A.T.P-Punch.
Fig. 12 All eight implant positions.
Fig. 13 Navigation splint in use.
Fig. 14 P.B.D in use.
Fig. 15 Placement of the implant after sinuslift.
Fig. 16 Postoperative volume tomography.
Fig. 17 Coronal view of the sinuslift.

tion that is placed upon the membrane: since only water creates the pressure, the risk of a rupture is reduced considerably. At the same time, the amount of saline solution volume is monitored, thus ensuring a very precise knowledge of how much bone augmentation material should be applied (Fig. 2). In 2009 alone, 30 patients with a total of 35 sinus lifts were successfully treated with the JEDER®-System.

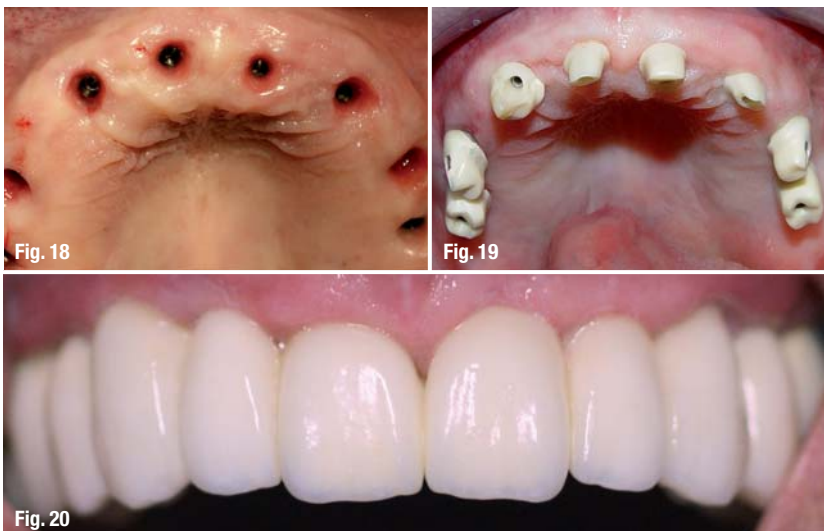
_Case report

A 64-year-old edentulous patient who was wearing a full denture for almost two years wished a fixed prosthetic solution. The bone volume assessment showed an inner-antral bone height of 14–18 mm. The

bone height in the sinus area was between 3–5 mm. Preoperative planning is essential for success. In order to accommodate the high aesthetic demands of the patient a detailed surgical and prosthetic plan was prepared. It was determined that wax-up and navigated implantation were essential for a positive outcome of this case.

The surgical procedure was divided into two parts: the implantation and the sinus augmentation. In order to assess the available bone volume a preoperative volume tomography was made (Planmeca; ProMax®, Helsinki; Fig. 7). Digital planning of the implant positions was made possible with the navigating software Materialise® (DENTSPLY Friadent). A further important tool in this software is the virtual measurement of the expected volume of the sinus lift. In so doing, a volume amount was calculated before the procedure itself, thus providing important knowledge of the saline solution volume and bone augmentation material required and how much of both will be required during the operation itself. In this case 0.88 ml for the right sinus, and 0.66 ml for the left sinus were calculated virtually (Fig. 8 and 9).

For the minimal invasive sinus lift the described components P.B.D and S.V.P (Fig. 1A and B) were applied. Because of the small crestal opening (3.5 mm diameter x 5 mm in height) only a paste-like bone augmentation material could be used. In our cases we used Ostim® (Heraeus Kulzer). The intraoperative drill-splint from Materialise® made an exact positioning of the implants possible (Fig. 10 to 15). A postoperative



volume tomography documents the implant positions as well as the minimal invasive sinus lift (Figs. 16 & 17). In order to manage the soft tissue for an optimal aesthetic result, following aids were used:

- _ The use of the A.T.P-Punch to avoid a mucoperiosteal flap and to reduce soft tissue trauma.
- _ The use of very large healing abutments (diam. 7 mm) to make space for the individual zirconium prosthetic abutments (Fig. 18).
- _ An optimal provisional bridge that contours the soft tissue as well.
- _ Using a fine burr to model the keratinized gingiva in the papilla areas.

Owing to the high primary stability of the eight implants (incl. sinuslift) an immediate loading of all implants was decided upon. Full ceramic individual abutments, zirconium framework and a ceramic finish (Dental Design Koczy, Figs. 19 & 20) made this bridge perfect in all aspects of the patient's aesthetic demands. The manufacturing of the bridge took three weeks and was cemented permanently using iCem® (Heraeus Kulzer).

Conclusion

In summary and according to our concept, the following is needed for an optimal management of soft and hard tissue.

- _ Flapless implantation (A.T.P)
- _ Flapless sinus lift (JEDER®-System)
- _ Navigated implantation (Materialise®)
- _ Individual abutments/Zirconium Framework
- _ Individual provisional solution

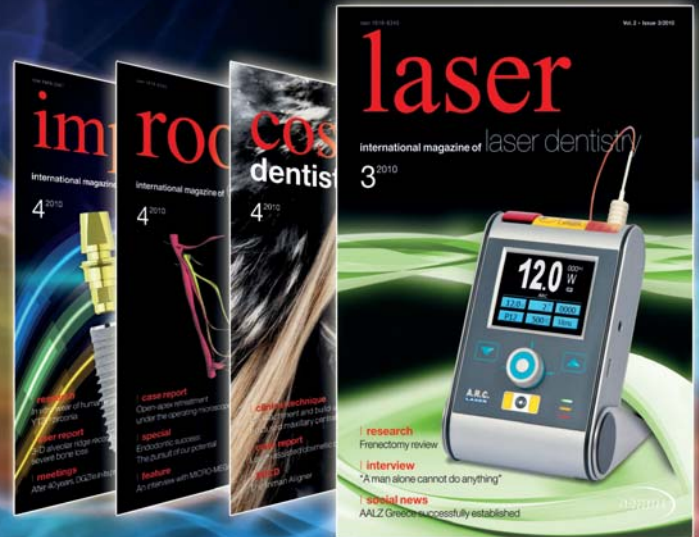Advantages using the JEDER®-System

- _ Minimal invasive technique
- _ No suture, no swelling
- _ No discolouration (haematoma)
- _ Short operation
- _ Almost no pain or discomfort after operation
- _ Large reduction of risk (membrane rupture)
- _ Simplified surgical procedure

_contact	implants
<p>Dr Philip Jesch Zahnambulatorium Wienerberg City Hertha Firnbergstr. 10/2/1 1100, Vienna, Austria E-mail: office@jesch.at Web: www.jesch.at</p>	
<p>Mag Andreas Bayerle abayerle@jedersystem.com</p>	

laser

international magazine of laser dentistry



One issue free of charge!

You can also subscribe via www.oemus.com/abo

 **Subscribe now!**

I hereby agree to receive a free trial subscription of **laser international magazine of laser dentistry** (4 issues per year). I would like to subscribe to **laser** for € 44 including shipping and VAT for German customers, € 46 including shipping and VAT for customers outside Germany, unless a written cancellation is sent within 14 days of the receipt of the trial subscription. The subscription will be renewed automatically every year until a written cancellation is sent to OEMUS MEDIA AG, Holbeinstr. 29, 04229 Leipzig, Germany, six weeks prior to the renewal date.

Reply per Fax +49 341 48474-290 to OEMUS MEDIA AG or per E-mail to grasse@oemus-media.de

Last Name, First Name	
Company	
Street	
ZIP/City/Country	
E-mail	Signature

Notice of revocation: I am able to revoke the subscription within 14 days after my order by sending a written cancellation to OEMUS MEDIA AG, Holbeinstr. 29, 04229 Leipzig, Germany.

Signature

IM 4/10



3-D alveolar ridge reconstruction in a case with severe bone loss

Author_Prof Dr Marcel Arthur Wainwright, Germany

_Introduction

A high clinical evidence of grafting procedures from extraoral autologous donor sites like i.e. from the iliac crest in difficult bone loss sites is still the practice in oral or oral-maxillofacial surgery. However, the invasive surgery combined with a prevalence of patients morbidity and suffer is an issue to discuss the persisting legitimation of this procedure. Since the appearance of reliable bone substitute materials with or without any autologous bone added, the positive results concerning longterm stability of regenerated bone even in difficult cases have become very predictable.

This article will point out in a case report the reliability of alternative and less invasive techniques for 3-D bone reconstruction in the mandible and question

the necessity of iliac hip grafts for intraoral bone augmentation.

_Materials and methods

A female patient aged 48 years old with a severe and advanced periodontitis in the maxilla and the mandible came into our clinic with the desire of a complex treatment plan with an implant retained denture in both jaws. This case report will pinpoint the treatment of the mandible. A CBVT was revealing massive bone loss in height and width in the mandible arch from canine to canine and apical cyst at tooth 23, 26 and 28 (Figs.1 & 2). According to our protocol we started with an initial scaling and HELBO®-Laser decontamination prior to the surgery to decrease the number of pathologic germs and post op infections. Tooth 18 and 19 in the

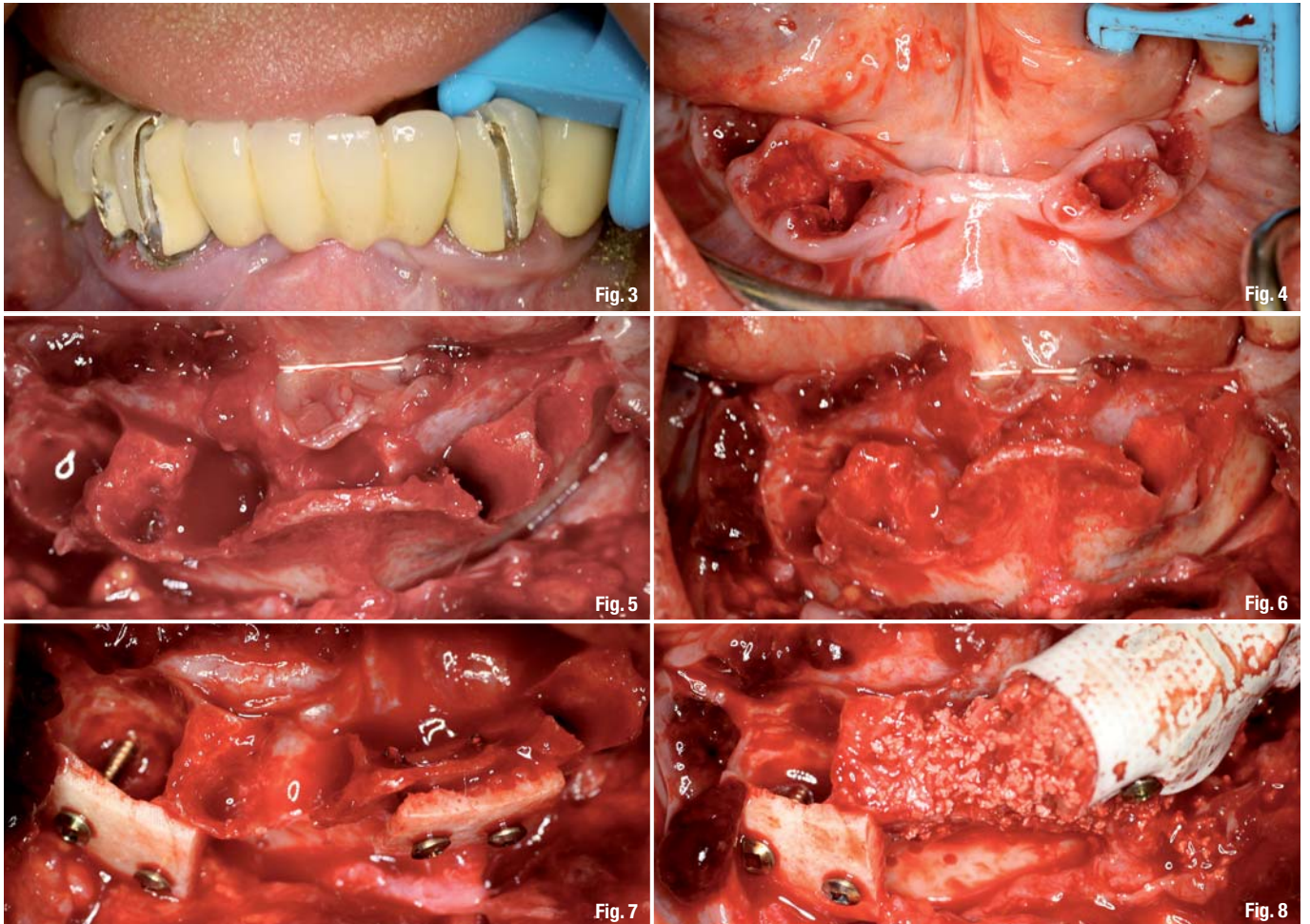
left mandible were intended to maintain until the finalization of the prosthetics to give some comfort during temporization with an immediate denture that was placed post op. Preoperative the patient received 1,200 mg of Clindamycin. The patient desired the surgery of tooth removal and ridge augmentation pursued under general sedation.

After nasal intubation and local anesthesia the bridge in the lower was removed and the remaining teeth despite from 18 and 19 as mentioned before (Figs. 3 & 4). After full flap preparation with crestal incision, releasing incisions and exposure of the mental nerve exit, the volume of the severe bone loss was revealed as well as the minor soft

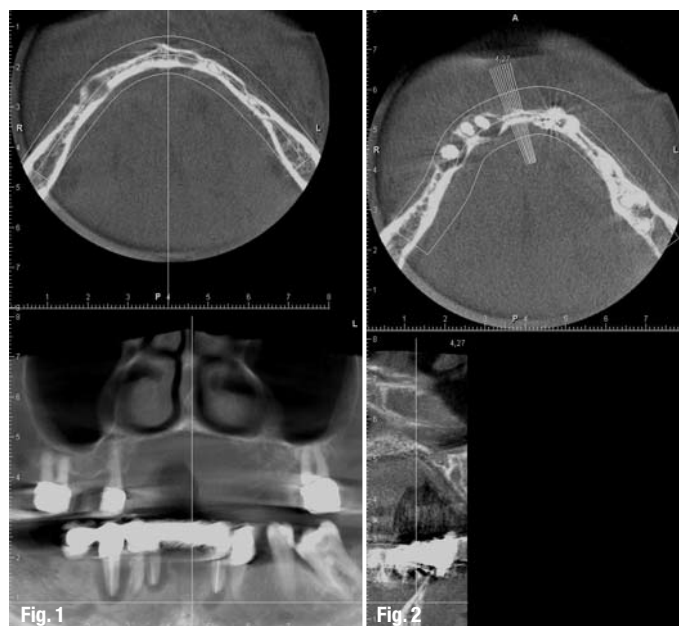

Fig. 1_Presurgical aspect revealing massive Periodontitis and bone resorption in region 32, 42, 44.

Fig. 2_The CB-Scan exposing region 32—with partial loss of the buccal and lingual wall region 32–44.



tissue conditions due to inflammatory tissue proliferation (Figs. 5 & 6). The success of 3-D bone augmentation is bonded to primary wound closure and tensionless flap adaptation. Thus, the periosteum is dissected with a scissor from the epiperiosteal connective tissue before augmentation procedures to reduce bleeding and guarantee a flap flexibility without compromising soft tissue and nutritive blood vessels.

For bone augmentation a bone block was harvested via ultrasonic surgery from the retro-molar region distal from 32 of the right mandible (Piezotome II, Acteon France).

This bone block was divided into two halves. One was used for two "bone shields" to create a mold for the grafting material, one was particulated with a bone mill and mixed with defect blood and a β -TCP (Nanobone[®], Artoss GmbH, Rostock, Germany). The bone blocks were fixed with two osteosynthesis screws (Fig. 7) and the mixture of autogenous bone plus β -TCP in mixing ratio 50:50 was used to fill the gaps and increase the ridge width and height. To increase the bone augmentation material volume an allograft block (Puros[®], Zimmer Dental) was particulated and added to the mixture. Before placing the material a non resorbable titanium-

reinforced membrane (Cytoplast Ti-250, Sybron Implant Solutions) was adapted lingually and folded to shape the augmentation complex according to the new and desired crest volume (Fig. 8). Upon the non resorbable membranes three xenogenous resorbable membranes (Tutodent[®], Zimmer Dental) were placed according to the sandwich membrane layer technique to create a better adaptivity to the flaps (Fig. 9) and enhance wound healing. Primary wound closure (Fig. 10) was achieved with a 4-0 metric suture (Gore-Tex[®], Gore). The patient carried a clamb retained provisional denture that was rebased with a soft material and was instructed to have no solid food for 10 days. Postoperative the patient continued with 1,800 mg Clindamycin, Ibuprofen 600 mg and a decongestant enzyme based medicine (Bromelain-Pos[®], Ursapharm, Germany). The next day the patient had an expected cheek swelling but was not suffering from pain, after 10 days the sutures were removed. However, 6 weeks later a membrane exposure of the non resorbable membrane was evident, but due to the fact that this is tolerable when the patient is instructed to maintain oral hygiene and re-called once a week, the success of the outcome was not threatened (Fig. 11a). The titanium pins and the titanium reinforced membranes were removed after 4 months.

Fig. 3 Site before bridge removal and extraction.

Fig. 4 Surgical Site after bridge removal and extraction of teeth 33, 32, 42, 43, 44.

Fig. 5 After Cystectomy the dramatic severe horizontal and vertical bone loss is visible.

Fig. 6 Frontal aspect of the compromised bone situation.

Fig. 7 Fixation of the autologous bone blocks which have been harvested ultrasonically from the retro-molar region of the right mandible.

Fig. 8 3-D crest reconstruction with the "mold-technique" with clearly visible horizontal and vertical augmentation. Fixation of a titanium reinforced ePTFE- membrane with pins.

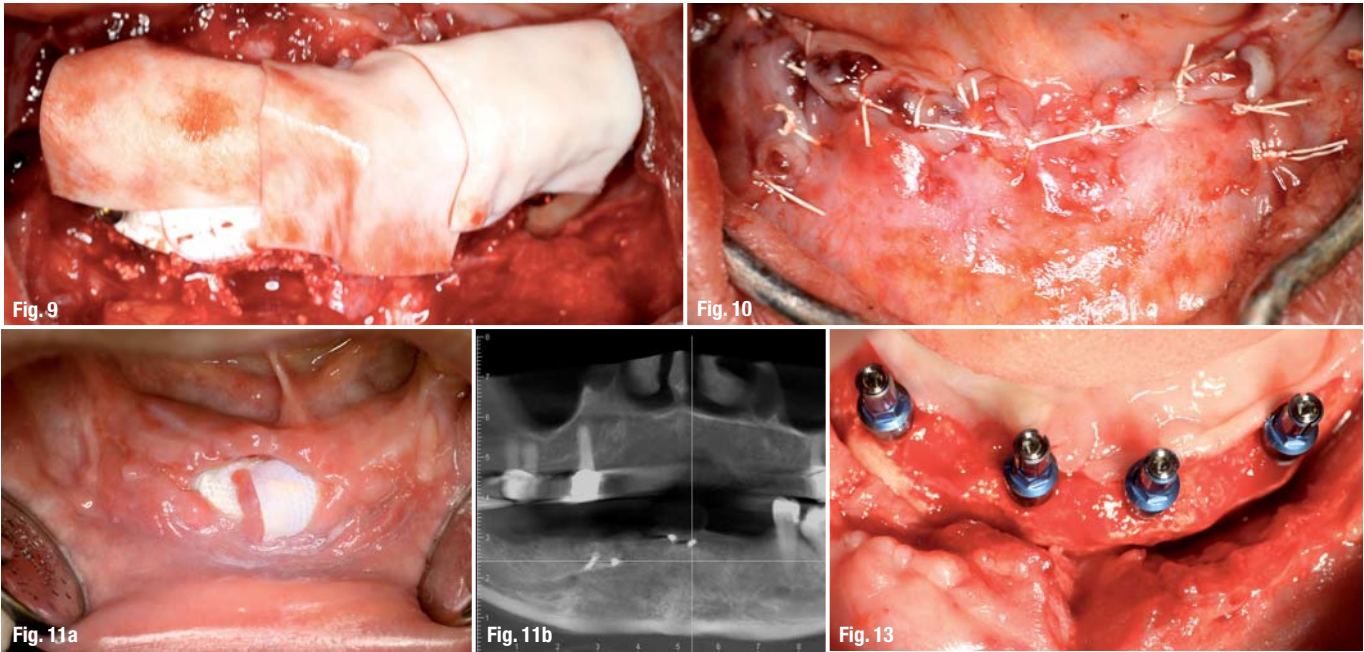


Fig. 9 Resorbable collagenous membranes are placed upon the non resorbable membranes.

Fig. 10 Wound closure with 4-0 metric GoreTex sutures after flap mobilisation.

Fig. 11a Membrane exposure of the non resorbable ePTFE membrane after 4 weeks. Clearly visible ist the enhanced soft tissue situation.

Fig. 11b 6 months post surgical the fully reconstructed bone situation is obvious.

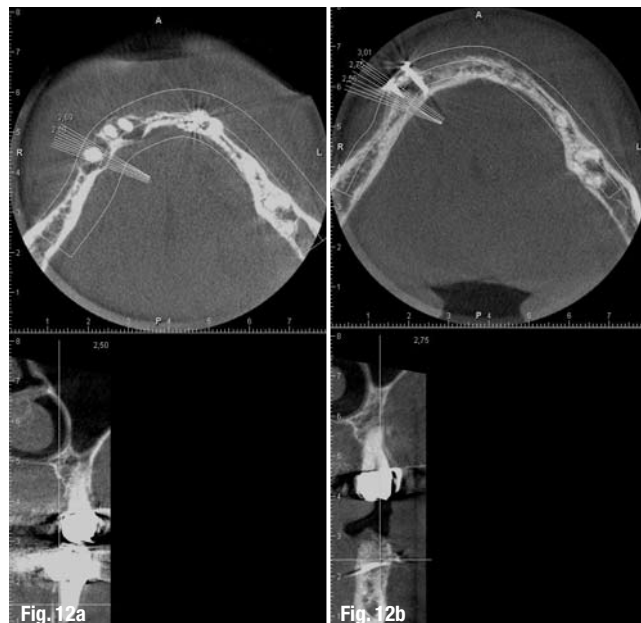
Fig. 12a CBS of the pre-op region 44 with entire loss of the buccal plate in region tooth 44.

Fig. 12b Region tooth 44 after 6 months of healing with fully reconstructed bone prior to implant surgery.

Fig. 13 Inserted implants in the fully reconstructed bone.

Eight months after augmentation the 2-D aspect of the CBVT showed clear evidence for entire ridge reconstruction of the deficient sites (Fig. 11b) with osteosynthesis screws in position. To emphasize the efficiency and predictability of this technique the pre-op scan of region 28 (Fig. 12a) and the reconstructed bone 8 months later (Fig. 12b) show clear an increase of bone height and width.

The well vascularized bone was used to insert 4 dental implants (4 x 3.75 x 13 BEGO Semados®, BEGO, Germany) for a later bar-retained denture, the healing time is estimated with 8 weeks (Fig. 13) and was not completed before publication, here my apologies to that.



_Discussion

3-D bone augmentation in cases with severe bone loss can be accomplished also with a less invasive surgical protocol than the iliac hip graft. The morbidity can be dramatically reduced with the use of ultrasonic devices. Regarding the donor site, which may be favored with the retromolar region patients have close to zero complains if a single incision procedure is performed. Allograft materials may enlarge the volume of the augmentation material and in addition to that the success of β -TCP is not to be questioned. Regarding the long term stability the regenerated bone is superior to pure autologous bone from the iliac crest, which resorption rate is much higher compared to intraoral bone or β -TCP. Reduced pain and postoperative complains should be reduced and enlarges the number of patients willing to undergo oral augmentative procedures.

_contact implants

Prof Dr Marcel A. Wainwright
 DDS, PhD
 Dentalspecialists
 Kaiserswerther Markt 25-27
 40474 Duesseldorf, Germany
 E-mail: Weinrecht@aol.com
 www.dentalspecialists.de

Universidad de Sevilla
 Facultad de Odontologia
 Calle Avicena s/n
 41009 Sevilla

It's Time for a ReThink: High Quality at factory-direct Prices



Spectra-System
Six application-specific implants
All-in-One Package: €115



Hexagon



Tri-Lobe



Octagon



Zimmer® Dental*
Legacy 1 Line
Legacy 2 Line
Legacy 3 Line
Implant: from €100



Nobel Biocare™*
RePlant Line
RePlus Line
ReActive Line
All-in-One Package: from €115



Straumann™*
SX-Plant Line
All-in-One Package: €145

All-in-One Package: includes implant, abutment, cover screw, healing collar, comfort cap and transfer

**In times of financial constraints –
look for innovation with the best value!**

Implant Direct sets new standards with high-quality implants with low prices and value added All-in-One™ Packaging for only 115 Euro per implant, including the corresponding prosthetic components. Besides the unique Spectra System, we offer compatible implant systems to Nobel Biocare™, Straumann and Zimmer® Dental. Make a decision today and choose a path of smart solutions and considerably more profit.

*Registered trademarks of Straumann, Zimmer® Dental and Nobel Biocare™



Tollfree Infoline: 00800 4030 4030
www.implantdirect.eu
Europe's No. 1 Online Provider for Dental Implants



**Implant
Direct™**

simply smarter.

The use of polylactide-coated β -TCP

Closure of oroantral communications

Authors_Dr Stefan Neumeyer, Dr Stefanie Neumeyer-Wühr, Germany

Abstract

Methods for the closure of oroantral communications that occur occasionally after tooth extraction are invasive and laborious. Here, we assessed a simple and efficient technique to close such perforations in nine patients. The oroantral communication at the bottom of the extraction socket was covered with oxygenized, degradable cellulose and the coronal two thirds of the socket were filled with in-situ hardening polylactide-coated β -tricalcium phosphate (β -TCP). An airtight, stable barrier could be established in all cases, and wound healing was uneventful. The novel procedure was minimally invasive and patient-friendly. Soft tissue covered the material after two weeks, and the biological width was reestablished after two months. Hard and soft tissue structures were preserved. The bone substitute has been partially replaced by alveolar bone at the end point of this case-cohort study. A complete regeneration of the alveolar bone can thus be expected.

third molars (Ehrl 1980; Amaratunga 1986). Left untreated, this may result in the formation of oroantral fistulae and chronic infection of the sinus cavities (Amaratunga 1986). An immediate and complete closure of the communication is thus indicated if the sinus cavities are not already infected (Kraut and Smith 2000; Greenstein et al. 2008).

Frequently, soft tissue flaps are used to close the communications, with good results (Lambrecht 2000). However, flap mobilization involves slitting of the mucosa and the periosteum and is rather invasive, post-operative swelling and pain are thus common (Gacic et al. 2009). Furthermore, the procedure leads to displacement of tissue and scarring. As a consequence, relocation procedures become necessary in most cases. Oroantral communication closure with tissue transplants and membranes represent an alternative to the flap-based methods. These surgical methods can be combined with augmentative measures to preserve the dimensions of the alveolar ridge (Becker et al. 1987; Watzek 2008). Membrane-based techniques and soft tissue transplantations are characterized by good alveolar hard- and soft tissue preservation and thus are becoming more popular (Schwarz et al. 2006; Cardaropoli and Cardaropoli 2008; Fickl et al. 2008). Nevertheless,

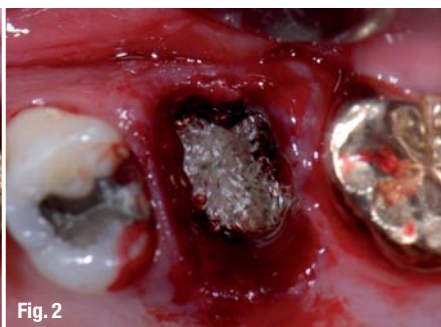
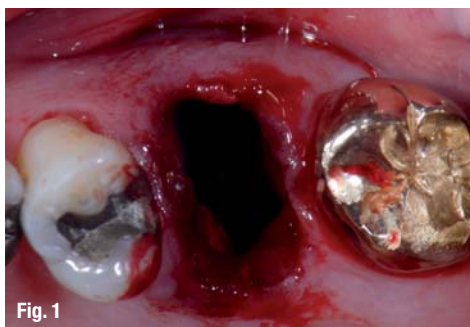
Background

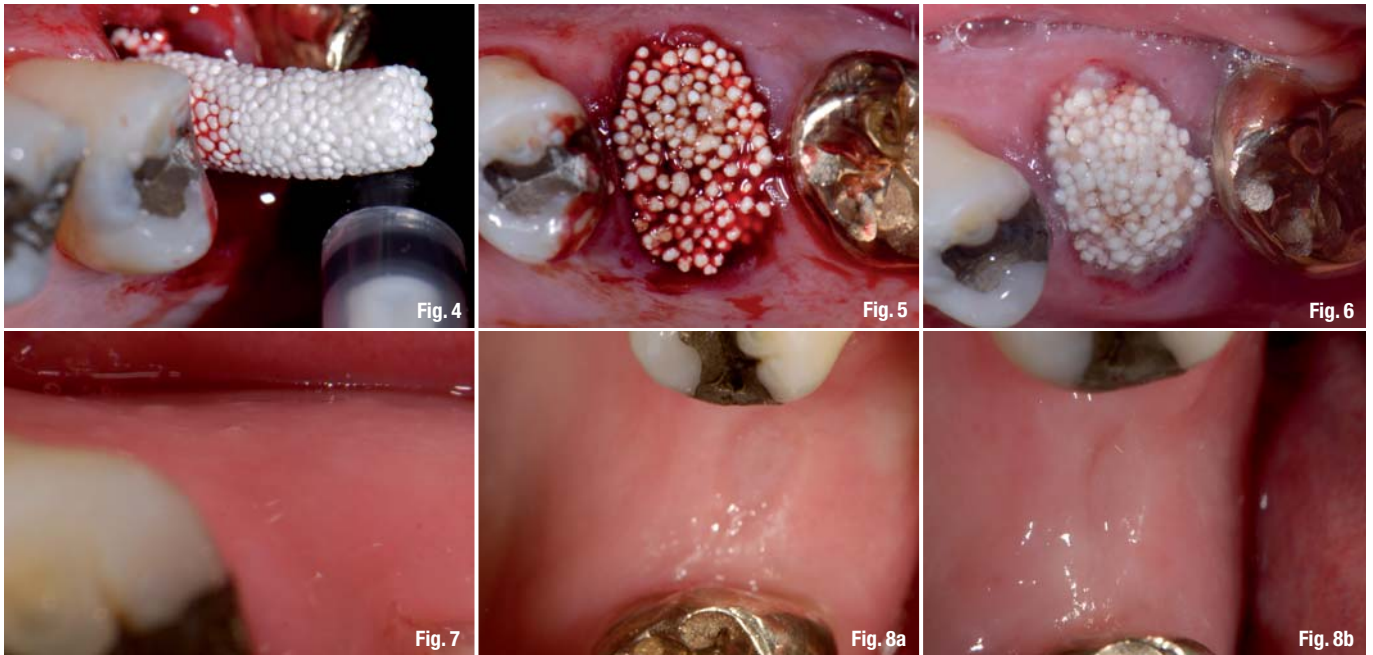
Oroantral communications (OACs) may occur after the extraction of the upper first molars and—less frequently—after extraction of premolars or second and

Fig. 1_OAC in region 26.

Fig. 2_Closure of the perforation with oxydized cellulose.

Fig. 3_The extruded bone graft substitute is flattened at its front.





these techniques are also intricate and invasive, and there is always a risk for dislocation of graft material into the sinus cavity (Thoma et al. 2006).

Frequently, the occurrence of an oroantral communication is not anticipated and therefore the intervention to close the perforation was not scheduled in advance. An easy, efficient and minimally invasive method would represent a benefit for both patients and clinicians alike. Communication closure by insertion of root analogs made chair-side from a porous β -tricalcium phosphate (β -TCP) composite fulfills these criteria (Thoma et al. 2006). The technique was shown to be fast and easy. Furthermore, less pain and swelling were observed compared to the patients that were treated with a buccal flap (Gacic et al. 2009). However, the fabrication of root analogs is only possible with unfractured roots as templates (Thoma et al. 2006).

Here, we present a template-independent technique for oroantral communication closure that uses a moldable polylactide-coated β -TCP. The initially soft bone substitute hardens in the defect and thereby forms a barrier between the oral and the nasal cavities. In this pilot study, we addressed the question whether the novel method is successful in closing the oroantral communications that have occurred in nine patients after tooth extraction. The safe establishment of a barrier, healing and regeneration of hard and soft tissue structures were evaluated.

Materials and methods

Subject population and clinical situation

All patients with an oroantral communication after tooth extraction between June 18, 2007, and October 17, 2008, in a private dental practice were treated with the described method. The study included 5 female and 4 male patients who were between 21 and 86 years old. The occurrence of oroantral communications was routinely checked by asking the patient to pressurize his or her nasal cavity. Positive findings were verified visually and with a blunt probe. Subjects were excluded from the study if the anamnesis or mucous nasal discharge indicated an acute infection of the maxillary sinus or if the residual height of the buccal plate was below 3 mm, which may interfere with stable fixation of the graft material. Based on these criteria, no patient had to be excluded. The dimensions of the extraction sockets were measured by probing, radiographically and on clinical pictures (Figs. 1 & 2). The extraction defects measured 6 to 14 mm in the mesio-distal and 8 to 12 mm in the bucco-oral direction. The height of the buccal plate in the socket was between 3 and 11 mm. All extraction sockets were surrounded by intact gingiva.

Closure of the oroantral communication

In a first step, the site of the perforation at the bottom of the extraction socket was covered with oxygenized cellulose (Tabotamp, Johnson & Johnson Medical, Gargrave, United Kingdom) (Fig. 2) in order to pre-

Fig. 4 Bone graft substitute in the defect.

Fig. 5 The defect is filled up to the gingival level.

Fig. 6 Slight expansion of the augmented one day after the operation.

Fig. 7 Superficial degradation of the bone graft substitute in the height of the biological width after two weeks.

Figs. 8a & b Complete soft tissue closure, occlusal view after 3 (left) and 8 months (right).

Region	18	17	16	15	14	24	25	26	27	28
OAC	1	–	1	1	–	1	–	3	2	–

Tab. 1 Localization of the OACs after tooth extraction.

vent a displacement of the graft material into the nasal cavity. Only after the formation of a stabilized coagulum the socket was filled with a fully synthetic bone graft substitute (easy-graft®, Degradable Solutions AG, Schlieren, Switzerland) to the gingiva level. The material consists of porous β -TCP granules that are coated with a 10 μ m thin film of a polylactide. By mixing the granulate in the syringe with a liquid plasticizer, the polymer layer is softened and the granulate is transformed into a moldable mass. Excess liquid has to be discarded prior to graft application by pressing it carefully into a sterile swab. The bone graft substitute was applied directly from the syringe into the defect. In cases of larger perforations, the putty-like mass was flattened at its front end in order to prevent compression or displacement of the cellulose-stabilized coagulum (Fig. 3). The bone substitute was pressed gently into the defect and adapted to the socket walls with a sharp spoon (Fig. 4). The putty-like material hardens in contact with blood and other aqueous liquids into an inherently stable, porous, defect-analog body within minutes (Fig. 5). The soft tissue was not sutured. Complete closure of the communication was verified by asking the patients to pressurize his or her nasal cavity. Defect filling was assessed radiographically. In order to minimize pressure onto the implant material, the patients were advised not to blow their nose at the day of the operation and to eat with care in order not to put a mechanical strain on the defect site. Six patients took a broad-spectrum antibiotic during 3 to 8 days; the other three patients declined the use of antibiotics for antibiotic prophylaxis (Table 2).

_Follow-up

Recall appointments were scheduled after one day, seven days, two weeks and five weeks. More appointments were fixed if the medical situation demanded close monitoring of the patient. One patient did not appear for the one-week control, two patients were not available for the two- and the five-week controls. All patients were seen at least once between week one and week two, and all but one patient were followed up for four weeks or more. Oroantral communication closure, healing and clinical outcome were documented photographically and radiographically. In one case, soft

and hard tissue samples taken during the placement of a dental implant were subjected to histological analysis.

_Results

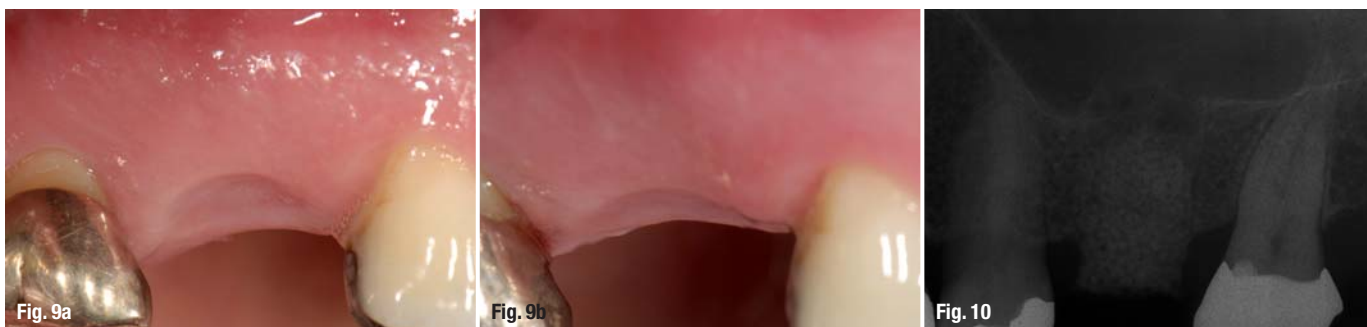Occurrence of oroantral communications

Mostly, the oroantral communications have occurred after extraction of the first molar (4/9), two oroantral communications were opened up due to extraction of the second molar, the remaining three oroantral communications were observed after removal of a first and a second premolar and a wisdom tooth, respectively.

Surgery and healing

The graft material hardened within minutes to an inherently stable body in the extraction socket. All subjects were able to pressurize the nasal cavities, which indicated a complete closure of the perforation. The patients reported weak pain on the first day after the operation and a weak sensation of warmth in the region where the perforation has been closed. Swelling was not observed in the operated region in any of the patients. Bloody nasal discharge, which would be a sign of bleeding into the nasal cavity, was not observed. The bone graft substitute material formed a stable block that was well adapted to the wound contours. The β -TCP composite swells slightly due to water uptake. The graft was thus tightly fixed in the extraction socket and protruded slightly above the gingiva level (Fig. 6). Within two weeks, the graft material was covered with soft tissue. Single β -TCP granules have been integrated into the covering tissue layer (Fig. 7). The vertical dimension of the material decreased due to the ongoing degradation procedure. However, the material always remained at the height of the biological width. After four to six weeks, a complete regeneration of the soft tissue could be observed. A collapse of the alveolar ridge could be prevented. After nine months, the initially convex buccal plate has receded slightly and appeared straight in the occlusal view (Figs. 7 & 8), indicating a marginal reduction in the width of the alveolar ridge. Nevertheless, the vertical and horizontal dimensions of the well-attached gingiva were maintained nearly completely (Fig. 9).

Figs. 9a & b Complete soft tissue closure, lateral view after 3 (left) and 8 months (right).
Fig. 10 Radiograph after OAC-closure.



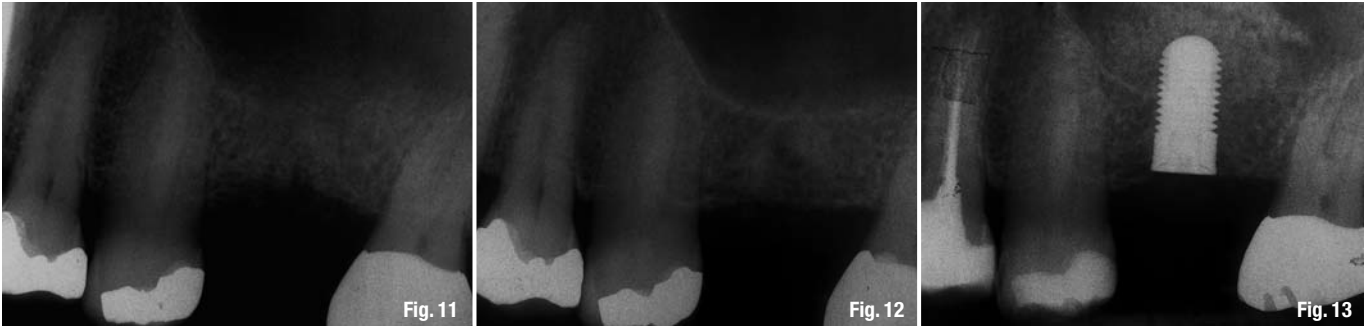


Fig. 11 Blurring of the outlines of the graft material after 3 months.

Fig. 12 Central remodelling after 18 months.

Fig. 13 Sinus floor elevation and insertion of an Aesthura® Classic implant in region 26 after 19 months with 25 Ncm.

Radiography

After closure of the oroantral communication, the bone graft substitute in the coronal two thirds of the extraction socket but not the oxygenized cellulose in the bottom of the extraction socket could be detected radiographically (Fig. 10). After three to four months, the outlines of the graft particles appeared blurred, the formation of a tissue radiologically identical to bone could be observed in the periphery of the graft material (Fig. 11). The vertical dimensions of the marginal bone structures were not altered (Figs. 10 & 12). Even after 18 months, variations in the radiopacity could be observed in the center of the former extraction socket (Figs. 12 & 13). However, an implant could be inserted at the former extraction site with sufficient primary stability (Fig. 13).

Histological analysis

In the hard tissue sample taken after 18 months, capillary structures in the central part and a rather compact lamellar bone of various mineralization

grades were detected (Fig. 14). The histological analysis of the soft tissue sample showed a connective tissue that is covered with an unkeratinized, stratified squamous epithelium. Remnants of graft material were not observed in either sample, which was expected given that the material was described to resorb completely within three to 14 months (Nair et al. 2006; Rothamel et al. 2007).

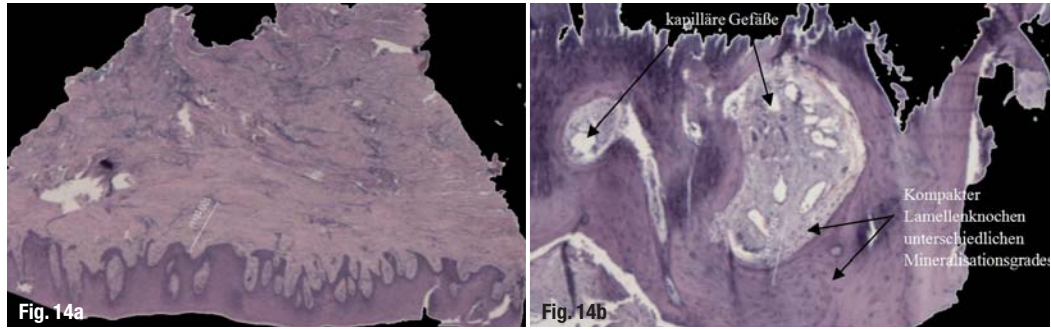
_Discussion

It has been shown that the incidence rate of oroantral communications after extraction of upper teeth ranges between 0.3 and 4.7% (Thoma et al. 2006). If the maxillary sinus is not already infected, immediate closure of the perforation is indicated in order to prevent contamination of the sinus cavity and a subsequent infection. The flap-based techniques according to Rehrmann-Wassermund or Axhausen are rather invasive and entail surgical tissue relocation procedures due to structural tissue changes. The results are often

Tab. 2 Patient overview.

	Patient 1	Patient 2	Patient 3	Patient 4	Patient 5	Patient 6	Patient 7	Patient 8	Patient 9
Age (y)	52	37	21	43	53	62	49	54	86
Sex	f	f	f	m	m	m	f	m	f
Region	15	26	26	16	26	27	24	18	27
Amount of easy-graft	1 x 0.4 ml	2 x 0.4 ml 1 x 0.15 ml	2 x 0.15 ml	1 x 0.4 ml	2 x 0.4 ml	1 x 0.4 ml	1 x 0.15 ml	1 x 0.4 ml	1 x 0.4 ml
Antibiotics	–	Isocillin 1.2 Mega	Isocillin 1.2 Mega	Sobelin 300 mg	Isocillin 1.2 Mega	–	–	Isocillin 1.2 Mega	Isocillin 1.2 Mega
Antibiotic intake	–	3 x 1 daily, 4 days	3 x 1 daily, 4 days	3 x 1 daily, 4 days	3 x 1 daily, 8 days	–	–	3 x 1 daily, 4 days	3 x 1 daily, 4 days

Figs. 14a & b_Histological analysis of soft (left) and hard tissue (right). Harvesting and preparation artifacts are visible.



not satisfying from an esthetic point of view. Therefore, a membrane-based approach in combination with a method to preserve the alveolar ridge after tooth extraction is favored. The perforation can be closed with a membrane and/or a tissue transplant and the extraction wound is filled with a material suitable for socket preservation (Becker et al. 1987; Watzek 2008). Finally, the wound is sealed towards the oral cavity with another membrane and/or soft tissue transplant. However, this technique is laborious, costly and is mastered mainly by experienced oral surgeons. Membrane-independent, minimally invasive subantral augmentation methods are simple and efficient one-step procedures for closure of oroantral communications (Thoma et al. 2006). The method presented in this case-cohort study critically depends on the unique features of the novel synthetic graft material. Initially it is moldable, and can be inserted into defects of any shape. In contact with blood, the material hardens and forms an inherently stable but openly porous body. Most likely, coagulated blood in the interconnected pores and the underlying, stabilized coagulum supports the formation of an airtight barrier. During the first days, the polymer layer that mediates the formation of a stable scaffold takes up water, which results in a slight volume increase and guarantees a tight contact between the defect walls and the graft material. The β -TCP composite is tissue-friendly and the phase-pure β -TCP is degraded in parallel with bone formation (Nair et al. 2006; Rothamel et al. 2007; Gläser 2009). Unlike other methods, the described subantral augmentation procedure does not inflict further damage to the soft- and hard tissues surrounding the defect site. Pain, swelling and increased risk of infection that results from soft tissue and periosteal slitting and the exposure of the underlying bone are avoided, which represents a major patient benefit. It took two weeks for the graft material to be covered with soft tissue whereas defect closure is immediate with other techniques. It could be argued that the delayed coverage with soft tissue may increase the risk of infection. However, neither in the present study nor in a larger study that used an identical, thermally molded β -TCP composite for oroantral communication closure did such infections occur (Gacic et al. 2009; Thoma et al. 2009). Further studies will need to compare larger patient groups to address this issue in more detail. The clinical and radi-

ographic controls showed an almost complete preservation of soft and hard tissue structures similar to membrane-based surgical techniques. Expansion of the sinus cavity towards the alveolar ridge was observed in one case 18 months after tooth extraction, making a sinus lift for stable implant placement necessary (Fig. 12). The β -TCP composite is replaced by bone that is subjected to physiological bone remodeling. Expansion of the sinus cavity thus occurred like it would be the case in any non-augmented edentulous setting.

The described minimally invasive method for oroantral communication closure is well suited for oroantral communications that are located above unproblematic extraction sites. However, it should not be applied if the size or the geometry of the defect does not allow stable anchorage of the material. Alternative methods should be considered in patients with very large oroantral communications that may result from the extraction of two or more molars. In such cases, the graft material may be lost or displaced into the sinus cavity by mastication forces. Also, safe anchorage of the material and efficient closure of the oroantral communication may not be given in shallow extraction sockets, e.g. if the buccal lamella is missing. A perforation with only 3 to 5 mm remaining vertical bone height could be successfully closed during this study. This patient was monitored more closely than described in the protocol. Defects shallower than this certainly should be treated with an alternative method.

In conclusion, the described minimally invasive method for closure of oroantral communications has several obvious advantages over conventional techniques. It is fast and efficient and does not inflict damage to the surrounding tissue since no additional surgery is needed. Nevertheless, alternative methods should be considered if an unsuitable defect geometry jeopardizes stable graft anchorage. Soft and hard tissue structures were mostly preserved, and no complications or failures to close the perforations were recorded during this retrospective case cohort study.

Article scheduled for publication, based on the article "Der Einsatz von poly(lactid-beschichtetem β -Tricalciumphosphat zum MAV-Verschluss", published in Quintessenz 08.

_contact	implants
<p>Dr Stefan Neumeyer Dr Stefanie Neumeyer-Wühr Lemminger Straße 10 93458 Eschlkam, Germany E-mail: praxis@dres-neumeyer.de</p>	

International events

2011

ITI Congress France

Where: Paris, France
Date: 21–22 January 2011
Website: www.iti.org

AEEDC Dubai

Where: Dubai, UAE
Date: 1–3 February 2011
Website: www.aeedc.com

26th Annual Meeting of AO

Where: Washington DC, USA
Date: 3–5 March 2011
Website: www.oesseo.org

IADR General Session & Exhibition

Where: San Diego, CA, USA
Date: 16–19 March 2011
E-Mail: sherren@iadr.org
Website: www.iadr.org

34th International Dental Show

Where: Cologne, Germany
Date: 22–26 March 2011
E-Mail: ids@koelnmesse.de
Website: www.ids-cologne.de

International Osteology Symposium

Where: Cannes, France
Date: 14–17 April 2011
Website: www.osteology-cannes.org

5th CAD/CAM & Computerized Dentistry International Conference

Where: Dubai, UAE
Date: 12–13 May 2011
Website: www.cappmea.com

FDI Annual World Dental Congress

Where: Mexico City, Mexico
Date: 14–17 September 2011
Website: www.fdiworldental.org

7th Arab German Implantology Meeting

Where: Beirut, Lebanon
Date: 21–24 September 2011
Contact: drtamimi@drtamimi.com

41th International Congress of DGZI

Where: Cologne, Germany
Date: 30 September–1 October 2011
Website: www.dgzi-jahreskongress.de

AAID 60th Annual Meeting

Where: Las Vegas, NV, USA
Date: 19–22 October 2011
Website: www.aaid-implant.org

AOS 8th Biennial Conference

Where: Adelaide, South Australia
Date: 9–11 November 2011
Website: www.aosconference.com.au



After 40 years, DGZI is in its prime

DGZI celebrates its anniversary with a top class congress

Author_Dr Christian Ehrensberger, Germany



_DGZI (German Association of Dental Implantology) celebrated its 40th Annual International Congress on October 1st and 2nd in Berlin. With over 500 participants it attracted wide interest and met all ambitious expectations. Highly qualified speakers from practice and science gave an insight into the status of and future opportunities in this booming field of dentistry. Not only did we celebrate the anniversary of our association, but DGZI's efforts in promoting the standing implantology in dentistry were also celebrated, as the success of this field is due in great deal to the efforts of DGZI.

In his opening speech DGZI President Dr Friedhelm Heinemann compared the associations development with human life: "In the beginning it was small with only seven founding members, then came the age of "puberty" with times of dramatic development, but now we are in our prime. We are established, respected and well equipped, and we deliberately assume the responsibility for our expert field." Many friendships with other associa-

tions have been established and developed over the years. Among others, Dr Heinemann underscored DGZI's excellent cooperation with the German Dental Medical Association (BZÄK), the Professional Association of Oral Surgeons e.V. (BDO), the German Association of Prosthodontics and Dental Materials (DGPro) and the German Association of Oral Implantology e.V. (DGI), which he calls "the little brother". "It is crucial to show common ground", said Dr Heinemann. "There have been many examples in the past where politics have succeeded in pitting one group against another, true to the motto 'divide et impera' (divide and rule)."

_Together we are strong— globally interconnected

The Board of Directors was particularly proud of DGZI's international reach. For example the entire Board of the Japanese Association AIAI was gathered in the auditorium. In his welcoming speech, BZÄK's President Dr Peter Engel expressed it so: "Implantology has mutated from a supposed ugly



duckling to a proud swan, and it is still gaining ground." DGZI has reached the proud number of over 4,000 members. On its 40th Annual Congress DGZI offered a program to suit diverse interests as well as its international participants. Science and practice and numerous different professional associations—this is the motivation which makes us reflect on how we can further develop implantology together. Just as Gauß once said, "It is not only the knowledge, but the learning, not the possessing, but the gaining, not the being, but the reaching, which gives the real enjoyment."

"The past was identified by respectful aloofness", characterized Prof Dr Hendrik Terheyden, but he went on: "As a young DGI President I am in the happy position to approach future cooperations in a much more unburdened way." Now that the conflict of interest between practitioners and scientists is obsolete, the question of which implantology association may claim one of the two fields for itself has also fallen away. According to Prof Terheyden, DGZI works together with qualified

university professors, and equally DGI has many practitioners among their members. "Does a competition between implantological associations make any sense? I leave this to anyone's guess," said Prof. Terheyden.

Dr Heineman thanked Prof Terheyden for his welcoming speech and "for the possibilities which result from it". Dr Heineman then moved on to a special feature of this congress. Though the Association generally agreed not to deliver tributes or present awards, an exception was made in celebration of its anniversary. The coveted DGZI Implant Dentistry Award was given to Dr Sönke Harder, Kiel, (3rd place), Prof Dr Thomas Gredes, Greifswald (2nd place), and Dr Stefanie Schwarz, Heidelberg (1st place) by Dr Roland Hille, DGZI Vice President and scientific chairman of the congress. The subject of the winning work was the "Immediate Loading of Implants".

One of the congress highlights was the short welcoming speech of Prof Dr Hans Grafelmann. Among other distinctions, he is an honorary doctor of the University of Istanbul and an associate professor in New York. But more than anything, it was he and six colleagues who founded DGZI on February 20th, 1970 in Bremen. "I still remember the Implantology Congress in 1969. There were 85 participants and two university professors who attended the congress. Today there are more than 500 participants and many university representatives. DGZI has a worldwide reputation for its reliable training programs", said Prof Grafelmann, considering the development of DGZI. In the name of his Prof Dr Grafelmann Foundation, Prof Grafelmann handed over a check of €20,000 to Dr Heinemann, which will serve as a basis for DGZI's future development. In his speech it became clear how close to his heart DGZI rests as he explained, "It was my life-work. I want to thank all of you."

"40 years ago titanium was known as the material of submarines"

Dr Hille had the opportunity to introduce one of his own academic mentors, Prof Dr Wilfried Schilli, Freiburg, who gave the first scientific speech of the conference. The subject of his speech was "Oral Implantology in 1970". Prof Schilli said, "Back then, we the dentists as well as the general population had to worry about so many things, and carrying out implantology was not a top priority. Titanium was known for being a material used in Soviet nuclear-powered submarines that rendered them invisible to radar. However, the problem was obvious, as shown in the following statistic. One quarter of the 40–50 year olds belonging to the Bosch company staff were already edentulous. Those patients suf-



ferred significantly, and we often could not help them satisfactory on a long term basis. The scientific consensus was that a bone transplanted to the alveolar process would melt like butter in the sun. Augmentation seemed to be nonsensical. The possibility of an implantation was kept under wraps, even in the specialist press. However, it was also the time when subperiosteal leaf- and/or pin-shaped implants, and enossal bone screws smoothed the way for implantology's subsequent success (for reference see studies made by Prof Grafelmann).

In comparison, Prof Dr Dr Frank Palm, Konstanz, summarized today's implantology status as follows: "Functional examination, possible augmentation, 3-D planning, and connective tissue transplants are routine implantological options used daily." In previous times the damaging of a nerve was not considered to be a crucial mistake, but today we are eager to avoid such damage. Simply dye it and make it visible in a three-dimensional image! Tissue regeneration has become much more certain, and long-term success really means long-term success, not just two years plus X. We also find solutions for more complex cases according to the patient's wishes. We still cannot completely avoid bone resorption after implantation, but it does not exceed the extent of common physiological resorption.

Prof Palm also spoke about a number of still-open questions: Immediate loading, periimplantitis therapy, unclear state of the art in case of reduced diameter implants. On the second day of the congress Prof Palm chaired a special panel of short presentations dedicated to "Minis, Shorties and others on trial". The speakers were Prof Dr Christoph Bourauel, Prof Dr Joachim Hermann (a "grandee" of implantology), DGPro chairman Prof Dr Michael Walter, Dr Dr Martin Bonsmann, and Prof Dr Dipl.-Ing. Ernst Jürgen Richter. Following this session there was a lively and at times even controversial discussion among the experts on the podium in response to questions from the audience, and a friendly but also pointed exchange of pros and cons was set forth. It became clear that many current is-

sues are still not resolved. Implantology remains a dynamic field, and there is still much left to be discovered, clinically examined and newly developed!

"We should offer implantology in a much more self-confident manner"

Overall, DGZI's 40th International Annual Congress provided an excellent overview of all relevant implantological topics under discussion today. Prof. Terheyden, Kassel, outlined aspects concerning the Le-Fort-I-osteotomy. In particular, he called on all dentists to show more self-confidence. Alveolar ridge atrophy is a disease which requires treatment and also essential financial support. If in doubt, even a three to four days hospital stay should also be incorporated—such a stay would never be called into question in the case of, for example, knee prosthesis, because it is common in other medical disciplines to inform patients in a much more aggressive manner.

Prof Dr Werner Götz, Bonn, explained the biological basics of osseointegration. "It is advantageous for a dentist carrying out an implantation that bone cells in the jaw are highly osteogenic. This is sometimes a reason to be envied by other medical disciplines." It is interesting that nowadays the old dogma of unloaded healing is of less importance. However, the implant-bone-interface, which enables deliberate healing, is not yet well understood. We know that osteoblasts prefer a medium rough implant surface. Osseointegration can be improved by blasting, etching or anodizing. In future, a completely different concept might come to the fore: a new periodontal apparatus could be constructed using a specially cultivated tissue.

Dr Stephen Wallace, USA, reported on the current possibilities of bone augmentation in the course of a sinus floor elevation, which are already applied overseas. He presented in particular the mushroom-shaped diamond-coated dental grinding instruments that are used for forming round and oval windows in the lateral walls. He also introduced artificially produced recombinant human growth factors



(rh-PDGF), which bind to bone substitutes, and BMPs (bone morphogenetic proteins) that improve the resorption of bone substitutes. However, at present, these materials are still very expensive (about €5,000 per treatment). At the moment these techniques do not improve long-term success, but they do help in achieving the desired result in less time.

The future: Interdisciplinary cooperation

In his discussion of the "Closing the Interdisciplinary Gap", Prof Dr Paul-Georg Jost-Brinkmann, Berlin, discussed the possibility of preparing orthodontic treatment before carrying out implantation. He also highlighted the alternative solution of a transplantation of one's own teeth.

Prof Palm talked about the latest developments in the GBR technique. He specifically addressed the question of whether future augmentations may be superfluous, with a clear "no". Guided bone regeneration instead of classic bone augmentation may work in some cases, but not in general. In his speech titled "Is the Implant's Length of any Importance?" Dr Achim W. Schmidt, MSc, Munich, considered whether short implants are an alternative to direct sinus lifting. His conclusion is that short implants function successfully with sintered surfaces, which feature the necessary porousness. He proved this with the example of many cases from his own practice.

Prof Dr Matthias Kern, Kiel, began his discussion with an almost heretical example. He integrated a Maryland bridge into the region of the anterior teeth of a 15-year-old patient. After 19 years the bridge is still in situ, and the patient does not require any implant! Afterwards he pointed out the pros and cons of full ceramic abutments. Esthetics and bio compatibility are clearly advantageous, but missing long-term experience, higher costs, and the more complicated and thus critical treatment (adhesive fixation of the abutment on a titanium basis with Panavia 21) are of disadvantage.

Dr Peter Gehrke, Ludwigshafen, considers individually manufactured abutments to be very attractive. They can be produced centrally and on an industrial scale by applying new digital techniques. "For CAD/CAM generated zirconium oxide mountings there are no restrictions on how to shape the momentum to mesial and distal."

In his speech on "Implants and General Medicine", Prof Dr Thomas Weischer, Essen, indicated the limits of implantology in cases of severe or chronic disease, and he explained their current development. Today, even HIV patients can be treated with implants, provided that certain conditions are observed. The conclusion is that in most cases a dental implant restoration can be performed, even in cases of existing general diseases like HIV, osteoporosis, cancer or diabetes mellitus. It is highly important to keep in contact with the patient's practitioner, oncologist or other expert physicians.

At the end of the congress Dr Heinemann and Prof Palm took turns evaluating the various scientific contributions made, considering the aspects that are important to practice—information which is of practical value to the user in optimizing his own implantological work. The result of this analysis can be downloaded from DGZI's homepage www.dgzi.de under "Scientific Review" along with additional literature for private review.

The scheduled podium program was complemented by a number of other events, including a pre-congress workshop on "Periodontology in Practice", workshops led by corporate sponsors, seminars, a symposium on "Digital Dental Technologies in Implant Prosthetics" for dental technicians, and a large dental exhibition housed directly in the venue itself, the Maritim Hotel.

The congress' participants could also enjoy a very special Friday evening event, which took place in the wonderful atmosphere of the Berlin Wasserwerk—after all, we had something very special to celebrate: 40 years of DGZI!

The Anatomy Weekend is also in great international demand

Author_Dr Christian Ehrensberger, Germany



_Refreshing one's knowledge and receiving updates at the same time—the clear structure of DGZI (German Association of Dental Implantology) "Anatomy" curriculum has made it a long-standing favourite. Including an insightful theoretical introduction, an impressive demonstration including a live video broadcast from the dissection room, and patient-side practice on human specimens, this weekend course (October 8 and 9 in Dresden) was once again a success. In addition, the number of international participants continues to rise—this year one quarter of the 40 participants came from abroad. A special pre-course-program started already on Thursday. Prof Dr Mazen Tamimi reported about the advantages of a modern navigation system. A hands-on-course and dinner sponsored by Schütz Impla Dental completed the program on Thursday.

A specially designed DGZI course module for anatomy has been a permanent feature of the Implantology curriculum for a decade. Following its success in recent years, colleagues for whom it has been some time since they passed their state examination or implantological exams, may have realised that they are no longer able to recall the enormous amount of knowledge required, and could benefit from this up-to-date weekend course—a two-day professional

training course to refresh their anatomical knowledge. Thus, many participants and "guest auditors" took part in the Implantology curriculum in Dresden. The contributions of anatomist Dr med habil Wolfgang Schwab of TU Dresden, oral biologist and anatomist Prof Dr Werner Götz of the University of Bonn, dissection assistant Ute Nimtschke, implantologists Dr Rainer Valentin and Dr Rolf Vollmer, and oral surgeons Dr Martina Vollmer and Dr Uta Voigt meant that the course was in competent hands, and ensured that from the beginning the different perspectives of various disciplines were considered. The first day of the course was dedicated to a thorough introduction to the anatomy of the skull, including an exact demonstration of the supply for nerves and blood vessels and the anatomy of bones, tongue, throat and larynx. In order to explain the particular surgical basics, the speakers demonstrated the procedures used for autologous and xenogenous augmentation as well as those for bone spreading. Various augmentation methods and techniques, e.g. the extraction of bone from different locations, were explained in detail on the course. The highlight of the day was the application by Dr med habil Schwab and Prof Dr Götz of theoretical knowledge to an actual anatomical specimen. Courtesy of certain modern technology, including a live video broadcast from the dissection room, the participants could ask

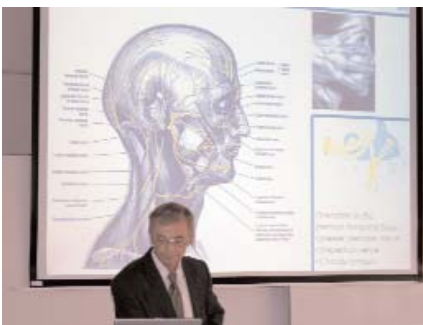

questions in real time during the presentation, including for example, what the route of the sural nerve is, which is used for nerve transplantations. After all gaps in knowledge had been addressed it was time to gather and enjoy a nice group dinner.

The second day of the course again began with a theoretical introduction—this time Dr Rolf Vollmer introduced a number of different implant techniques to the participants. Additionally, the sponsoring companies (Geistlich Biomaterials, Mectron, Resorba, Schütz Dental, Helmut Zepf Medizintechnik) explained the features of the instruments and working materials which they had provided, so that the participants could practice their newly-acquired techniques with

those products. In this way all structures relevant for dental anatomy and implantology could be shown and prepared. Throughout the course Ute Nimtschke, Prof Dr Götz and Dr med habil Schwab were prepared to answer all manner of questions. Towards the end, Dr Schwab and Dr Valentin demonstrated an autologous bone removal from the iliac crest. During the course these proven experts made clear how good planning and early trouble shooting can significantly minimize or even avoid the risk of later complications. This highly successful professional training weekend was concluded with an exam.

DGZI's next Anatomy Weekend will take place on September 15–17, 2011. _



Manufacturer News

Straumann

New Straumann® MembraGel™ for guided bone regeneration

Guided bone regeneration involves the use of a barrier membrane to help stabilize the bone graft and prevent unwanted growth of soft-tissue into the defect. Straumann MembraGel is designed to achieve undisturbed bone regeneration, which is a prerequisite for optimal clinical and esthetic outcome. Based on advanced polyethylene glycol (PEG) hydrogel technology, Straumann MembraGel is applied in liquid form and molds to the defect precisely. Within 20–50 seconds after application, the liquid components solidify, stabilizing the bone graft and providing an effective barrier to tissue infiltration.

Straumann MembraGel has completed preclinical and clinical trials including head-to-head compar-



isons with conventional materials. Further clinical data have been collected in an ongoing 'non-interventional' study and a multicenter clinical trial. Data from the clinical program include more than 40 centers in Europe and North America.

Throughout development, Straumann has worked closely with leading independent experts. The company is combining the launch with an education program that includes hands-on product training. Straumann MembraGel is being launched initially in key European markets, North America and Australia, where it has received regulatory approvals/clearances.

Institut Straumann AG

Peter Merian-Weg 12
4052 Basel, Switzerland
E-mail: info@straumann.com
Web: www.straumann.com

Implant Direct

New European Training Center

Implant Direct, Europe's No. 1 Online Provider for Dental Implants, continues its expansion with a brand-new European Head Office in Zurich, Switzerland. On the 1st of September the team of Implant Direct Europe AG moved into the new European Headquarter at the Hardturmstrasse 161 in Zurich.

The fast growth of Implant Direct's sales required the expansion of the customer service department, a centralized European logistics department, and foremost, a state-of-the-art training center for workshops and hands-on trainings with customers.

2011 will start with trainings and hands-on workshops in which Implant Direct will welcome speakers and customers in their training rooms with a spectacular view over the Swiss mountains. The new training center offers modern presentation facilities and is the ideal signboard for a young ex-



panding and innovative company in the implantology like Implant Direct. The tremendous growth is the result of Implant Direct's effort in constantly improving and developing new products. One of the most recent examples, is the new one-piece locator implant "GoDirect" that has been patented. This world first product includes modern attributes and accomplishments of future implantology. The implant unifies all the advantages of a one-piece construction. "GoDirect" implant is available in

Ø 3.0, 3.7 and 4.7 mm and the prosthetic part of the locator in 1.5 and 3.0 mm height. Furthermore it is prosthetical compatible with the system of Zest Anchor™.

Implant Direct Europe AG

Hardturmstrasse 161
8005 Zurich, Switzerland
E-mail: info@implantdirect.eu
Web: www.implantdirect.eu

BEGO Implant Systems

Competitively priced alternative for occlusal screw-retained crown and bridge solutions

The implant company BEGO Implant Systems, based in Bremen, Germany, offers its customers a competitively priced alternative to tried and tested gold cast-on abutments. Expensive high-gold alloys are not required and, instead, less costly non-precious alloys can be used. The patented Sub-Tec Universal abutment (available with and without anti-rotation protection) enables the practitioner to secure the superstructure, produced from all available dental alloys, intraorally with either a primary or occlusal screw fixation. The resulting oxide layers which form on non-precious alloys when casting or with ceramic firing and which have to be removed by machine do not affect the subsequent fit between the implant and the Sub-Tec Universal abutment. The dental technician completes the work as usual and adheres the Universal base produced from a titanium alloy to the custom-made structure. The seat of the screw is found in the cast part. Another benefit worthy of mention is the fact that the challenging



BEGO

Partners in Progress

removal of residual cement is no longer necessary. In contrast to cemented restorations where the subgingival removal of residual cement is essential, with these screw-retained designs this is not the case and, as such, the periimplant soft tissue is protected. As with all other BEGO superstructure components, these high-quality abutments come with two screws. The slotted screw is for dental processing in the laboratory, whilst the separately packaged hexagon socket screw is used for final placement of the restoration in the patient's mouth. "This ensures that a new screw is used for every single patient and, in turn, that he or she is completely satisfied with the implant in the long term", explained Christoph Staufenbiel, Product Manager at BEGO Implant Systems.

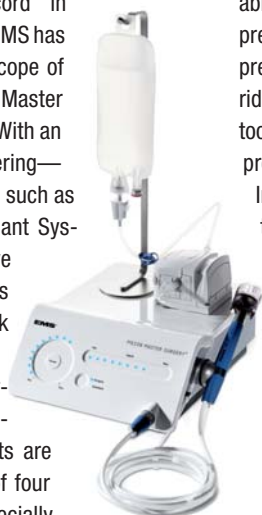BEGO Implant Systems GmbH & Co. KG

Technologiepark Universität
Wilhelm-Herbst-Str. 1
28359 Bremen, Germany
E-mail: info@bego-implantology.com
Web: www.bego-implantology.com

EMS

Piezon Master Surgery with three new instrument systems

Since it was introduced, Piezon Master Surgery—based on Piezon technology—has had a remarkable track record in many practices. Today, EMS has expanded the clinical scope of application of the Piezon Master Surgery product range. With an enhanced product offering—and special instruments such as Sinus System and Implant System—practitioners have access to technologies allowing them to work even more efficiently. With Piezon Master Surgery, additional application-specific instruments are now available: a total of four perio instruments especially



designed for resective and regenerative periodontal surgery, five advanced surgical instruments for gentle and uniform sinus lifts, as well as six special fully diamondcoated instruments for implant applications with dual cooling system and extraefficient debris evacuation.

These instruments are seen as particularly suitable for four clinical applications: implant site preparation following extraction, implant site preparation following splitting of the alveolar ridge, implant site preparation in the posterior tooth area, and implant site preparation in compromised areas, such as a narrow alveolar ridge. In principle, instruments can be used at low OP temperature of no more than 33 degrees centigrade. They provide drilling efficiency and precision in the maxillary area.

EMS

Electro Medical Systems S.A.

Chemin de la Vuarpillière 31
1260 Nyon, Switzerland
E-mail: welcome@ems-ch.com
Web: www.ems-dent.com

sticky granules
bionic



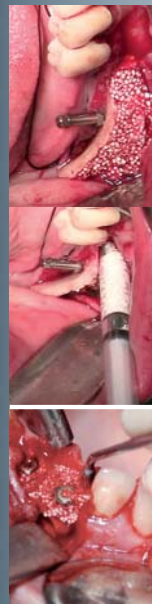easy-graft[®] CRYSTAL

Ingenious: Simple handling and accelerated osteoconduction for long-term volume preservation.

Order your free test sample over the internet!

Degradable Solutions AG
Wagistrasse 23
CH-8952 Schlieren
Phone: +41 43 433 62 60
www.degradable.ch
dental@degradable.ch

DS
DENTAL



AD
easy-graft[®]CRYSTAL

Nobel Biocare

Excellent initial stability and perfect aesthetic results

With its latest product NobelActive™ the Swiss company Nobel Biocare has created a 3rd generation dental implant. This innovative implant was developed to efficiently meet the high demands of dental implant surgery and implant prosthetics. Its positive effect of high initial stability is of benefit to immediate loading after insertion, setting NobelActive clearly apart from conventional implant systems.

With its novel thread design, NobelActive™ condenses the bone during insertion. The innovative implant design allows gradual and efficient bone condensing with each rotation. This benefit clearly differentiates NobelActive™ from other conventional, self-tapping implants available on the market. Further the expanding, tapered implant body of NobelActive™ features a double lead thread design, which also contributes to the high initial stability.



And the newly designed implant tip allows fine adjustments to implant orientation during insertion to optimise the final position of the implant in the bone, without jeopardising initial stability. The implant thread allows gradual atraumatic narrow ridge expansion and was developed to attain high initial stability even in compromised bone situations. Furthermore, NobelActive™ is provided with two reverse-cutting flutes. The coronal region of NobelActive™ is back-tapered and designed to maximize alveolar bone volume around implant collar for improved soft tissue support. These new attributes are very important advantages for the subsequent prosthetic management, in addition to ultimately facilitating the co-operation between surgical and prosthetic management.

Nobel Biocare Management AG

P.O. Box
8058 Zurich Airport, Switzerland
E-mail: info@nobelbiocare.com
Web: www.nobelbiocare.com

Degradable Solutions

Moldable, in situ hardening bone graft substitutes

easy-graft™ CLASSIC and easy-graft™ CRYSTAL are moldable, fully synthetic bone defect fillers for indications in oral surgery, implantology and periodontology. In contact with blood, the materials harden within minutes into a porous, inherently stable body. A membrane to contain the materials is not necessary in most cases. The easy-graft™ products are frequently used for ridge preservation after tooth extraction. The socket must be free of infected and inflamed tissue prior to graft insertion. The materials are applied directly from the syringe into the defect where they harden and seal the extraction wound. For most cases, a membrane or suturing of soft tissue are unnecessary. easy-graft™ CLASSIC and CRYSTAL are designed



to have different resorption characteristics. easy-graft™ CLASSIC is composed of phase-pure β -tricalcium phosphate (β -TCP). It degrades completely and is replaced by bone. easy-graft™ CRYSTAL contains 40% β -TCP and 60% hydroxyapatite (HA). It is degraded only partially and remains integrated in the newly formed bone for long-term volume preservation. In summary easy-graft™ combines established biomaterials for

bone regeneration with a unique handling advantage – moldable from the syringe, hardening in the defect.

Degradable Solutions AG

Wagistrasse 23
8952 Schlieren, Switzerland
E-mail: info@degradable.ch
Web: www.degradable.ch

CAMLOG

Prosthetic components for occlusally screw-retained restorations

With the introduction of the new Vario SR prosthetic components, users are now able to choose between cement-retained or screw-retained crown and bridge restorations on CAMLOG® implants. Vario SR abutments are available in straight and in 20° and 30° angled versions for implant diameters 3.8/4.3/ 5.0/6.0 mm.



Prefabricated Vario SR prosthetic components

Burn-out plastic copings can be used to fabricate crown, bridge and bar constructions. The titanium caps have a retention surface on the outside and are designed for temporary or final bridge restorations made of plastic. Titanium bar caps are available for laser-welded bar constructions.

For bridge and bar constructions, the impression can be taken using Vario SR impression

caps, open or closed tray, directly over the Vario SR abutment already in its final position in the implant. The retention screw of the impression cap, open tray, can be shortened by 3 mm extra-orally if space limitations are encountered.

For crown restoration, the impression can be taken directly over the implant shoulder using CAMLOG® impression posts, open or closed tray.

CAMLOG Biotechnologies AG

Margarethenstrasse 38
4053 Basel, Switzerland
E-mail: info@camlog.com
Web: www.camlog.com



Under the patronage of
H. H. Sheikh Hamdan Bin Rashid Al Maktoum
Deputy Ruler of Dubai, Minister of Finance
President of the Dubai Health Authority



“Delivering Science & Technology”

**DUBAI
2011**



**1-3
February**

Dubai International
Convention &
Exhibition Centre

**UAE INTERNATIONAL
DENTAL CONFERENCE &
ARAB DENTAL EXHIBITION**

“Where Oral Health Professionals Meet”

Supported by



- Keep up to date with the newest developments and techniques in dentistry through a series of lectures and specialized courses
- Enhance your dental practice with various management and clinical workshops
- Learn the optimal prevention and treatment services in the field of dental traumatology
- Visit 20,000 sqm. of exhibition space and explore the latest innovations and business practices
- Enjoy a panoramic view from Burj Khalifa, the world's tallest tower
- Ride the Metro and see Dubai !



www.aeedc.com

Organised by



Strategic Partner



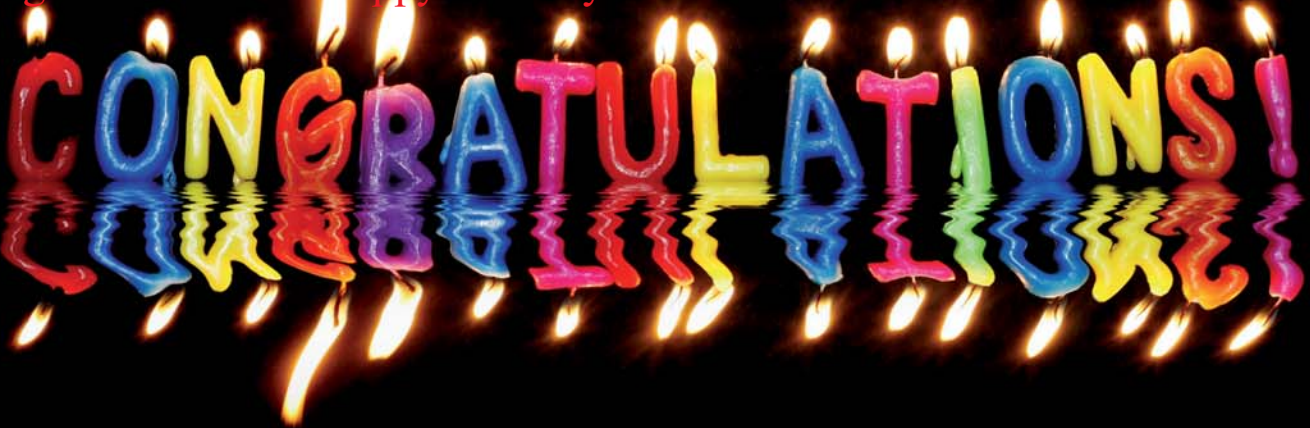Supported by



INDEX® Conferences & Exhibitions Organisation Est.

P.O. Box: 13636 | Ibn Sina Bldg. #27 Block B, Office 203, Dubai Healthcare City | Dubai - United Arab Emirates
Tel: +971 4 3624717 | Fax: +971 4 3624718 | E-mail: aeedc@index.ae | Website: www.index.ae

Congratulations and Happy Birthday to all DGZI-members around the world



OCTOBER 2010

65th Birthday

Dr Bernd Peter Wylutzki (01.10.)
ZA Hartmut Pickroth (20.10.)

60th Birthday

Dr Uwe-Alexander Lück (25.10.)

55th Birthday

Bricky Yosy (03.10.)
Dr Jamal Hajjar (14.10.)

Dr Holger Hanstein (18.10.)

Dr Joachim Malert (18.10.)
Dr Reinhold Waibel (30.10.)

50th Birthday

Dr Ludger Dietze (01.10.)
ZÄ Cornelia Batzer (08.10.)
Dr Klaus Köhler (11.10.)
Dr Rainer Hubertus Kreuzkamp (15.10.)
Dr Petra Hille (24.10.)

Dr Elke Behle (27.10.)

Dr Frank Flügge (31.10.)

45th Birthday

Dr Marcus Betz (06.10.)
Dr Haddad Tameem (07.10.)
Dr Holger Vicari (10.10.)
Dr Fernando Zurits (13.10.)
Dr Saad Mohammed Aboshagara (25.10.)
Dr Thomas Staudt (25.10.)

40th Birthday

Nina Bronik (07.10.)
Marc Mainka (20.10.)
Dr Ralf Schlichting (27.10.)
Achim Schmidt (28.10.)
Dr Thomas Martin (28.10.)
ZA Marcel Liedtke (28.10.)

NOVEMBER 2010

75th Birthday

Dr Meluid Ganz (16.11.)

65th Birthday

Dr Imamura Naoki (27.11.)
Dr Christian Damek (28.11.)

60th Birthday

Dr Ulrich Glaß (30.11.)

55th Birthday

Dr Waldemar Nitschke (07.11.)
Dr Alexander Axelrad (11.11.)
Dr Hideto Inoue (16.11.)
Dr Hajnalka Nagy (18.11.)

50th Birthday

Dr Matthias Thümmeler (19.11.)
ZA Ioannis Kiriazis (21.11.)

ZA Norbert Dreyer (30.11.)

45th Birthday

Dr Christoph Halfmann (06.11.)
ZÄ Eva Fezler (14.11.)
Andrea Wenker (15.11.)
Dr Rasmus Pöggeler (15.11.)
Dr Dr. Frank Dwornik (16.11.)
Dirk Haase (19.11.)

Dr Nils Knüppel (29.11.)

40th Birthday

Dr Andreas Kurrek (06.11.)
ZA Roman Paul Warwas (08.11.)
Dr Andreas Thonke (20.11.)
Dr Spyros Chryssikopoulos (23.11.)
Dr Jochen Heyen (30.11.)

DECEMBER 2010

70th Birthday

Dr Johannes Merk (18.12.)

65th Birthday

Dr Goran Skerlepp (16.12.)

60th Birthday

ZA Harald Perrin (01.12.)
Dr Knut Damerau (01.12.)
Dr Marlies Glahe (04.12.)
Dr Klaus Mayer (09.12.)
Dr Günter Schneider (10.12.)
Dr Imre Laszlo Mohos (12.12.)
Dr Bodo Heckroth (24.12.)

Dr Slawomir Sodczyk (25.12.)

Dr Karl Fehlner (25.12.)
Dr Manfred Janssen (30.12.)

55th Birthday

Dr Gerhard Kießler (06.12.)
Prof Dr Manfred Bender (10.12.)
Dr René Ecker (15.12.)
Dr Achim Frömel (16.12.)
Dr Suhail Lutfi (24.12.)

50th Birthday

Dr Malek Serlani (01.12.)
Dr Wolfgang Standhartinger (05.12.)

Dr Petra Furth (05.12.)

ZA Christian Nordheim (09.12.)
Dr Christian Dräger (10.12.)
Dr Jürgen Süllwold (11.12.)
Dr Norbert Weißen (12.12.)
Ingo Potthoff (14.12.)
Dr Stephan Jurisch (19.12.)
Dr Jörg Kutscher (24.12.)
Dr Hans-Joachim Schäfer (27.12.)
Dr Sven Görrissen (27.12.)
Dr Walter Quack (27.12.)
Dr Ulrich Eichberger (29.12.)

45th Birthday

Dr Antje Poblitzki (01.12.)
Dr Michael Sieper (17.12.)
Dr Raj Kumar (20.12.)
Dr Thomas Löffler (20.12.)
Dr Andreas Lindemann (22.12.)
Dr Detlef Granrath (30.12.)

40th Birthday

Dr Thomas Sons (11.12.)
Dr Thomas Reinscher (15.12.)
Alhariri Hase (22.12.)

submission guidelines:

Please note that all the textual components of your submission must be combined into one MS Word document. Please do not submit multiple files for each of these items:

- _ the complete article;
- _ all the image (tables, charts, photographs, etc.) captions;
- _ the complete list of sources consulted; and
- _ the author or contact information (biographical sketch, mailing address, e-mail address, etc.).

In addition, images must not be embedded into the MS Word document. All images must be submitted separately, and details about such submission follow below under image requirements.

Text length

Article lengths can vary greatly—from 1,500 to 5,500 words—depending on the subject matter. Our approach is that if you need more or less words to do the topic justice, then please make the article as long or as short as necessary.

We can run an unusually long article in multiple parts, but this usually entails a topic for which each part can stand alone because it contains so much information.

In short, we do not want to limit you in terms of article length, so please use the word count above as a general guideline and if you have specific questions, please do not hesitate to contact us.

Text formatting

We also ask that you forego any special formatting beyond the use of italics and boldface. If you would like to emphasise certain words within the text, please only use italics (do not use underlining or a larger font size). Boldface is reserved for article headers. Please do not use underlining.

Please use single spacing and make sure that the text is left justified. Please do not centre text on the page. Do not indent paragraphs, rather place a blank line between paragraphs. Please do not add tab stops.

Should you require a special layout, please let the word processing programme you are using help you do this formatting automatically. Similarly, should you need to make a list, or add footnotes or endnotes, please let the word processing programme do it for you automatically. There are menus in every programme that will enable you to do so. The fact is that no matter how carefully done, errors can creep in when you try to number footnotes yourself.

Any formatting contrary to stated above will require us to remove such formatting before layout, which is very time-consuming. Please consider this when formatting your document.

Image requirements

Please number images consecutively throughout the article by using a new number for each image. If it is imperative that certain images are grouped together, then use lowercase letters to designate these in a group (for example, 2a, 2b, 2c).

Please place image references in your article wherever they are appropriate, whether in the middle or at the end of a sentence. If you do not directly refer to the image, place the reference at the end of the sentence to which it relates enclosed within brackets and before the period.

In addition, please note:

- _ We require images in TIF or JPEG format.
- _ These images must be no smaller than 6x6 cm in size at 300 DPI.
- _ These image files must be no smaller than 80 KB in size (or they will print the size of a postage stamp!).

Larger image files are always better, and those approximately the size of 1 MB are best. Thus, do not size large image files down to meet our requirements but send us the largest files available. (The larger the starting image is in terms of bytes, the more leeway the designer has for resizing the image in order to fill up more space should there be room available).

Also, please remember that images must not be embedded into the body of the article submitted. Images must be submitted separately to the textual submission.

You may submit images via e-mail, via our FTP server or post a CD containing your images directly to us (please contact us for the mailing address, as this will depend upon the country from which you will be mailing).

Please also send us a head shot of yourself that is in accordance with the requirements stated above so that it can be printed with your article.

Abstracts

An abstract of your article is not required.

Author or contact information

The author's contact information and a head shot of the author are included at the end of every article. Please note the exact information you would like to appear in this section and format it according to the requirements stated above. A short biographical sketch may precede the contact information if you provide us with the necessary information (60 words or less).

Questions?

Kristin Urban (Managing Editor)
k.urban@oemus-media.de

implants
international magazine of oral implantology



Publisher

Torsten R. Oemus
oemus@oemus-media.de

CEO

Ingolf Döbbecke
doebbecke@oemus-media.de

Members of the Board

Jürgen Isbaner
isbaner@oemus-media.de

Lutz V. Hiller
hiller@oemus-media.de

Chief Editorial Manager

Dr Torsten Hartmann (V. i. S. d. P.)
hartmann@dentalnet.de

Editorial Council

Dr Friedhelm Heinemann
friedhelmheinemann@web.de

Dr Roland Hille
dr-hille@t-online.de

Prof Dr Dr Kurt Vinzenz
kurt.vinzenz@aon.at

Dr Torsten Hartmann
hartmann@dentalnet.de

Dr Suheil Boutros
SMBoutros@aol.com

Editorial Office

Kristin Urban
k.urban@oemus-media.de

Eva Kretschmann
e.kretschmann@oemus-media.de

Executive Producer

Gernot Meyer
meyer@oemus-media.de

Designer

Sarah Fuhrmann
s.fuhrmann@oemus-media.de

Customer Service

Marius Mezger
m.mezger@oemus-media.de

Published by

Oemus Media AG
Holbeinstraße 29
04229 Leipzig, Germany
Tel.: +49 341 48474-0
Fax: +49 341 48474-290
kontakt@oemus-media.de

Printed by

Messedruck Leipzig GmbH
An der Hebemärchte 6
04316 Leipzig, Germany

implants

international magazine of oral implantology
is published in cooperation with the German
Association of Dental Implantology (DGZI).

DGZI President

Dr Friedhelm Heinemann
DGZI Central Office
Feldstraße 80, 40479 Düsseldorf, Germany
Tel.: +49 211 16970-77
Fax: +49 211 16970-66
office@dgzi-info.de

www.dgzi.de
www.oemus.com

Copyright Regulations

_implants international magazine of oral implantology is published by Oemus Media AG and will appear in 2010 with one issue every quarter. The magazine and all articles and illustrations therein are protected by copyright. Any utilization without the prior consent of editor and publisher is inadmissible and liable to prosecution. This applies in particular to duplicate copies, translations, microfilms, and storage and processing in electronic systems.

Reproductions, including extracts, may only be made with the permission of the publisher. Given no statement to the contrary, any submissions to the editorial department are understood to be in agreement with a full or partial publishing of said submission. The editorial department reserves the right to check all submitted articles for formal errors and factual authority, and to make amendments if necessary. No responsibility shall be taken for unsolicited books and manuscripts. Articles bearing symbols other than that of the editorial department, or which are distinguished by the name of the author, represent the opinion of the afore-mentioned, and do not have to comply with the views of Oemus Media AG. Responsibility for such articles shall be borne by the author. Responsibility for advertisements and other specially labeled items shall not be borne by the editorial department. Likewise, no responsibility shall be assumed for information published about associations, companies and commercial markets. All cases of consequential liability arising from inaccurate or faulty representation are excluded. General terms and conditions apply, legal venue is Leipzig, Germany.

implants

international magazine of oral implantology



Subscribe now!

You can also subscribe via
www.oemus.com/abo

I hereby agree to receive a free trial subscription of **implants international magazine of oral implantology** (4 issues per year).

I would like to subscribe to **implants** for € 44 including shipping and VAT for German customers, € 46 including shipping and VAT for customers outside of Germany, unless a written cancellation is sent within 14 days of the receipt of the trial subscription. The subscription will be renewed automatically every year until a written cancellation is sent to OEMUS MEDIA AG, Holbeinstr. 29, 04229 Leipzig, Germany, six weeks prior to the renewal date.

▶ Reply via Fax +49 341 48474-290 to OEMUS MEDIA AG or per E-mail to grasse@oemus-media.de

Last Name, First Name

Company

Street

ZIP/City/County

E-mail

Signature

Notice of revocation: I am able to revoke the subscription within 14 days after my order by sending a written cancellation to OEMUS MEDIA AG, Holbeinstr. 29, 04229 Leipzig, Germany.

Signature

Official care provider
to the German Olympic teams
since 2002

GO FOR GOLD.



Bionic Engineering Design transfer of
optimal living nature solutions
to technical products

BEGO Semados®
Mini-Implant

BEGO Semados®
S-Implant

BEGO Semados®
RI-Implant

BIONIC ENGINEERING DESIGNED IMPLANTS

BEGO Semados® patented Implants embody:

- Indication-optimised contour design
- Function-optimised implant-abutment-connection
- High purity and ultra-homogenous-surface
- Polished rim for an inflammation-free gingiva-attachment
- 100 % German design – 100 % German manufacturing
- Value for money

Are You Interested?

info@bego-implantology.com

www.adwork.de

BEGO 
Partners in Progress

www.bego-implantology.com