

Full-arch: Full rehabilitation of the upper jaw—Part 1



Dr Dr Michael Rak, Norbert Wichnalek, Arbnor Saraci & Lukas Wichnalek, Germany

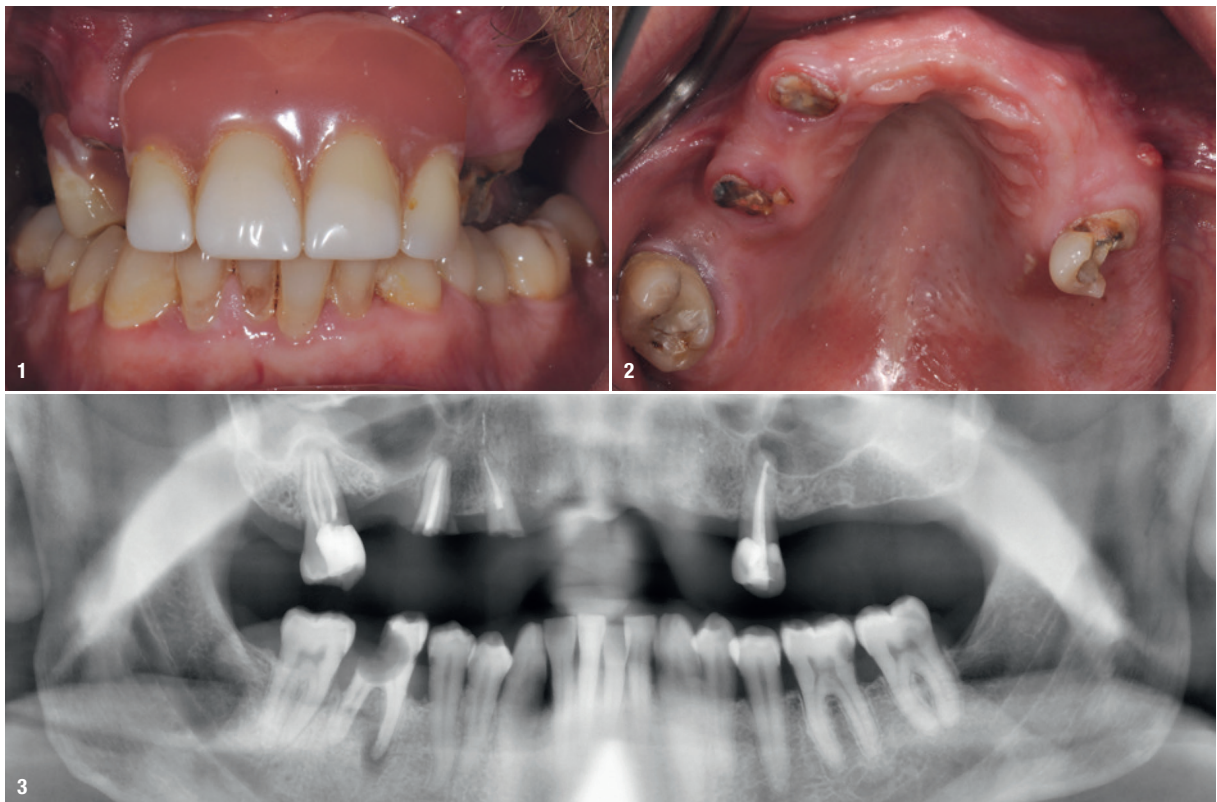The complete rehabilitation of a compromised residual dentition is a great challenge both implantologically, functionally and aesthetically. Especially the demand for fixed dentures with their aesthetically and functionally satisfactory implementation is high. In addition, there is a growing interest among patients for biocompatible dentures and surgical concepts that take biological criteria into account. Biological dentistry with metal-free implants and dental prostheses made of zirconium oxide can meet this demand at a high level. In the first part of the article, the authors discuss the assessment of the patient's condition, the preparation of the patient and the surgical procedure of extracting the remaining teeth as well as the immediate insertion of the implants. The second part describes the prosthetic restoration of the patient.

The case

The 41-year-old patient presented to our practice with the wish for a total rehabilitation of his periodontally and cariously compromised residual dentition in the upper and lower jaw. In addition, a biologically neutral and metal-free overall restoration was particularly important to him.

Clinical findings

In the upper jaw, there was a residual dentition in region 15 and 17 as well as two root remnants in region 13 and 15 *in situ* (Figs. 1 & 2). He had a partial denture in the upper jaw. All four remaining teeth had already undergone endodontic treatment and had been radiographically whitened to varying degrees apically. The root remnant in region 13 had an apical overcrowding of 4–5 mm in length and low bone density was noted in region 27 and 28.



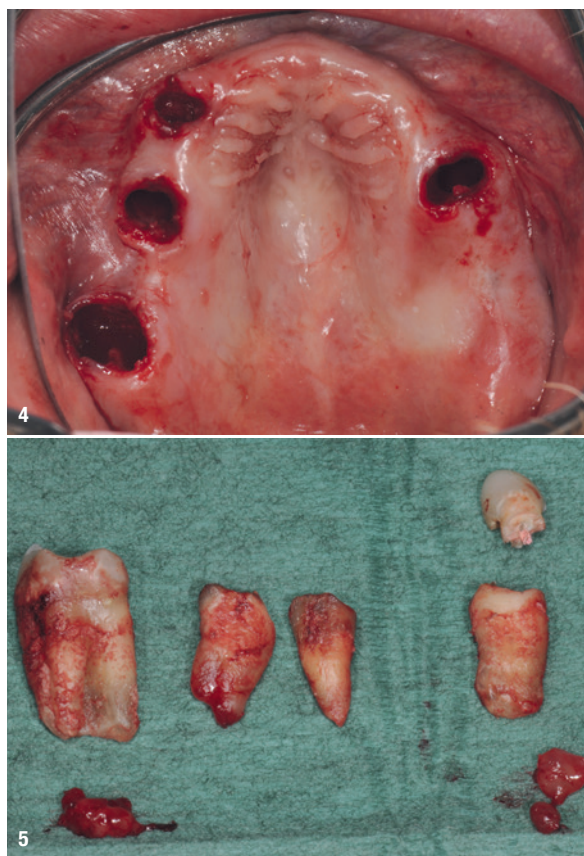
Figs. 1 & 2: In the maxilla, there was a residual dentition in region 15 and 17 and two root remnants in region 13 and 15 *in situ*. The patient was previously restored with an aging partial denture. **Fig. 3:** All four remaining teeth had already undergone endodontic treatment and had been radiographically whitened to varying degrees apically. The root remnant in region 13 had an apical overcrowding of 4–5 mm in length and low bone density was noted in region 27 and 28.

ened to varying degrees. The root remnant in region 13 had an apical overcrowding of 4–5 mm in length. Furthermore, a low bone density was detected radiographically in region 18 as well as 27 and 28 on the CBCT (Fig. 3). Overall, the remaining teeth in the upper jaw were no longer worth preserving. In the mandible, teeth 37, 36, 45 and 47 showed carious lesions. Tooth 46 was devitalised, cariously destroyed and showed extensive apical whitening radiographically. The remaining teeth in the mandible were vital. In region 38 and 48, a severely reduced bone density was also measured in the CBCT. During the examination, we found moderate chronic periodontitis in both the maxilla and mandible.

Biological dentistry

In addition to the functional and aesthetic aspects of the intended restoration, it is also important to consider the physiological and pathophysiological processes in modern treatment planning. Immunology, toxicology and the effect on the autonomic nervous system are of great importance for dentistry. Essentially, three important pillars of biological dentistry need to be considered: metal vs metal-free, endodontics and fatty degenerative osteolysis of the maxillary bone (FDOK).

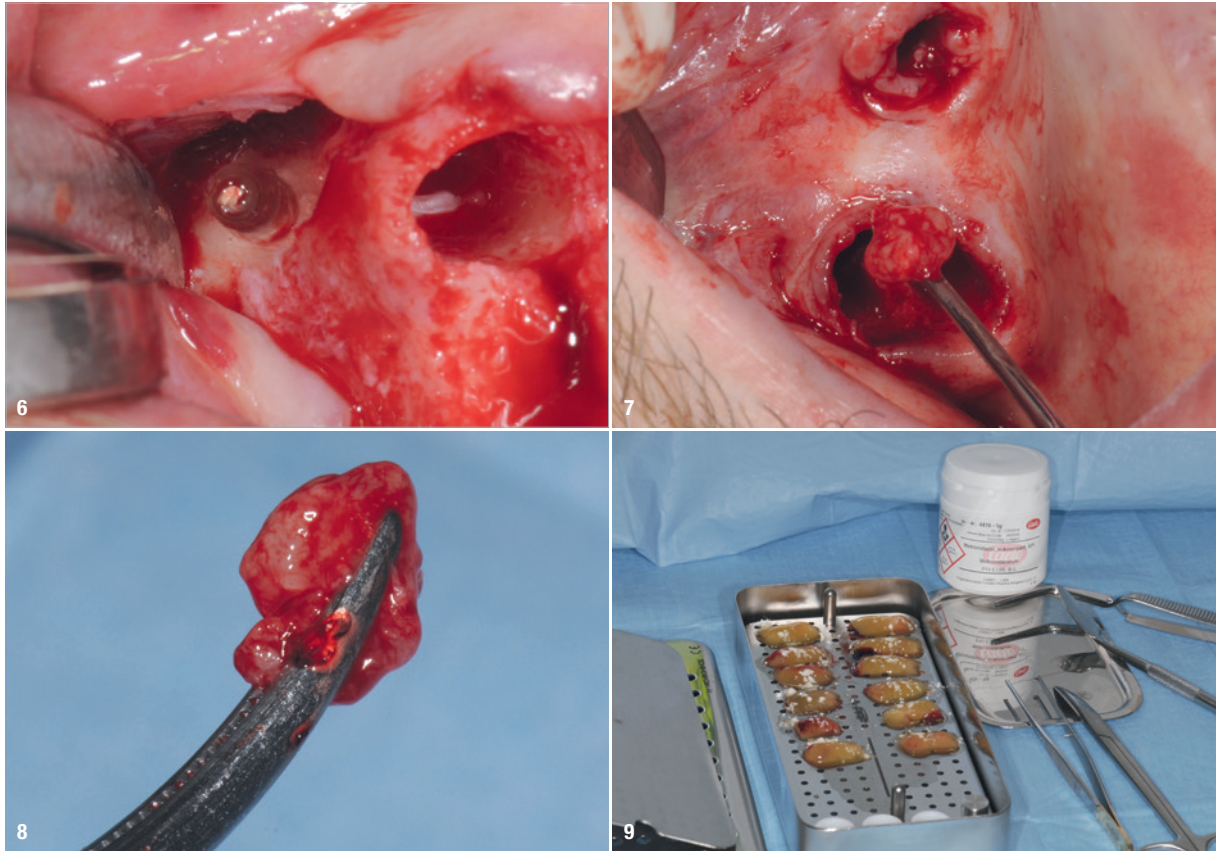
Chronic, cavity-forming fatty osteolytic diseases of the jaw such as FDOK or the neuralgia inducing cavity-forming osteolysis (NICO), which was first described pathologically, are still controversially discussed in oral and maxillofacial surgery today. FDOK in the medullary canals of the jaw bones can be identified as a lesser-known source of RANTES/CLL5 overexpression. The chemokine RANTES interferes with bone metabolism as a result of complex metabolic processes that are pathologically derailed (such as after tooth extraction), leading to osteolysis in the jaw areas affected by FDOK. Adipocytes have a pathogenetic effect via RANTES expression in the local FDOK and a systemic effect on the immune system.¹ The fields of biological dentistry offer healthy people appropriate treatment options that have minimal or no effect on the body. Even in chronically ill people, biological dentistry treatment approaches that address the individual causes can eliminate potentially stressful factors and restore the original situation in a biologically compatible way. This is done without compromising the aesthetic quality of the teeth, mouth and jaw, and allows for both local and systemic sustainable treatment. In our dental-technical team, we have been combining the principles of biological dentistry with the advantages of plasma treatment of all medical instruments (since 2017) since 2013 (laboratory side). This allows us to take a holistic approach to treatment. Ceramic implantology is a biologically neutral alternative to titanium implantology. Titanium has a high immunological tolerance and does not trigger allergy (lymphocyte nativation). In contrast to ceramics, however, titanium has the potential property of activating tissue macrophages



Figs. 4 & 5: Extraction of the residual dentition and cysts in the maxilla. In region 13, the overcrowded filling material in the jawbone was also removed from the buccal side, which was present apically of the root apex over 4 to 5 mm.

to varying degrees and promoting the release of proinflammatory cytokines such as TNF- α and interleukin-1. These key cytokines promote tissue and bone resorption and can lead to implant loss in the long term. The intensity of the inflammatory reaction of the tissue macrophages to the titanium particles further depends on the genetic tendency to inflammation, which is predisposed differently in each person.

Endodontic treatment is increasingly criticised because it often leads not only to local failures in the long term, but can also affect the overall system. For one thing, not only is the main nerve pulled during endodontic treatment, but the lymphatic system and blood supply are also cut off. This means that a sufficiently extensive supply of immune cells is no longer possible in the paro-endodontic area. As a result, bacteria settle in the tubular system without being reached by immune cells. This causes the bacteria to produce toxins, which release mercaptan and thioethers, which cause the pro-inflammatory cytokines INF-gamma and IL-10 to be released. A vicious cycle that usually leads to chronic inflammation. With modern immunological test methods such as the effector cell test, the triggers of these chronic inflammations can be found. In addition,



Figs. 6–9: The cysts were localised and removed in the maxilla in regions 15, 25 and 27. The A-PRF membrane was moistened with metronidazole and prepared for use.

the toxin load can also be measured directly locally by the OroTox on each root-filled tooth.

The fatty degenerative osteolysis of the jaw bone could be detected with current studies as an area that expresses the cytokine RANTES to a very high degree. The process of chronic inflammation puts the entire system under stress, so that the sympathetic part of the autonomic nervous system is permanently active. The consequences of this can promote the development of chronic disease symptoms. Furthermore, toxins of the FDOC stored in the fatty tissue can be transported via the axon into the brain by means of retrograde transport.

Planning and therapy

The surgical intervention was planned on the basis of a CBCT X-ray. In a first step, situation models of the upper and lower jaw were made and the dental planning was discussed. The aim was a prosthetic rehabilitation of the upper jaw made of zirconium oxide on eight SDS zirconium oxide implants and a single SDS zirconium oxide implant in the lower jaw. In order not to risk any blocking of the sutura palatina mediana and not to obstruct cranial breathing, the restoration in the upper jaw was divided into three parts. The grinding protocol of the tem-

porary restoration was to serve us for the transfer of the chewing pattern.

Supplements protocol

The patient was instructed to take a supplement protocol that significantly promotes both bone regeneration and healing. First and foremost, the intake of vitamin D3 and its co-factors—vitamin K2, magnesium, calcium and boron—is essential to optimise bone metabolism and increase the rate of bone formation. In addition, the patient should take amino acids and B vitamins to support regeneration and tissue formation. One day before the planned surgery, a four-day intake of a herbal preparation with antibiotic effect was started. This was to minimise the perioperative risk of infection. The measurement of the vitamin D3 level showed a value of 90 ng/ml.

Surgical intervention

On the day of the procedure, the patient received a single-shot infusion of Clindamycin 600mg for infection prophylaxis and a vitamin complex infusion for optimal bone regeneration. Afterwards, the patient's blood was drawn to prepare twelve plasma Choukroun's platelets (A-PRF = advanced platelet-rich fibrin).

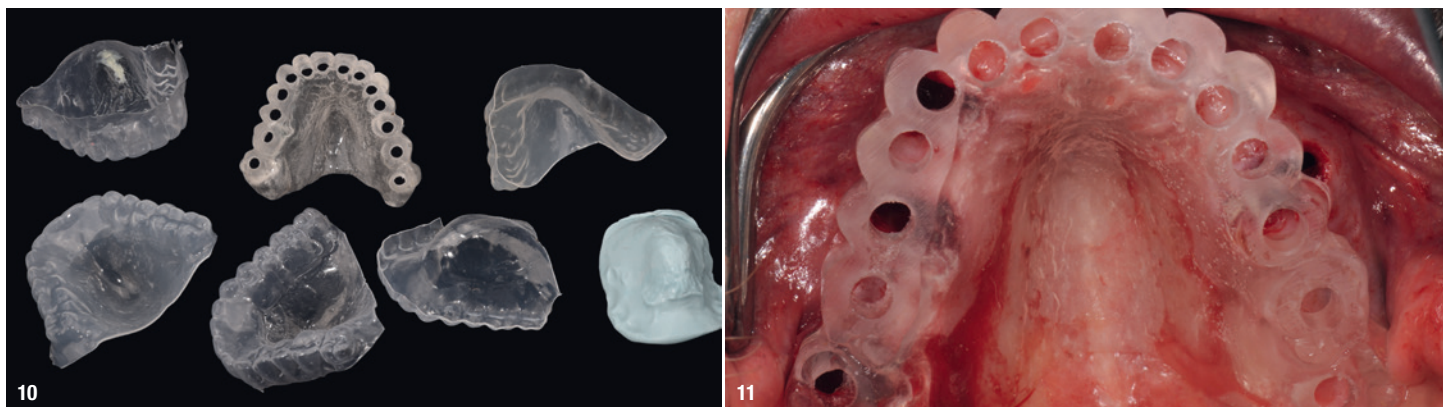


Fig. 10: The various surgical aids—an orientation drill guide and various transparent control foils—that the laboratory had prepared for us in advance were now used. **Fig. 11:** The orientation template showed us the optimal fit of the planned implants.

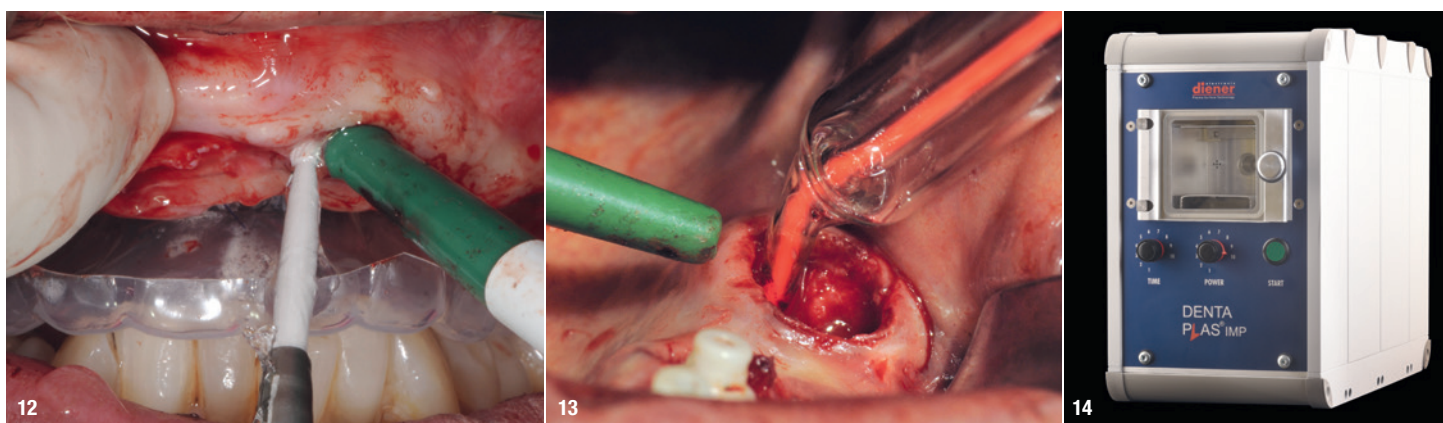
The preferred all-ceramic implant system (one-piece version SDS1.1 and two-piece version 2.0, Swiss Dental Solutions) consists of a Y-TZP-A material. This is an yttrium-stabilised, tetragonal zirconium oxide polycrystal. Both the one-piece and two-piece implant systems have a 3mm high tulip that is placed on tissue level. This gives the practitioner the opportunity to adjust the insertion depth according to the existing gingival height. In this case, a total of eight implants with a diameter of 4.6 and 5.4mm were used with a tulip width of 6mm. Before the surgical interventions, the situations with and without the inserted maxillary prosthesis were imprinted and a digital duplicate of the prostheses was made. Afterwards, the FDOK restoration was carried out first.

FDOK rehabilitation and implantation

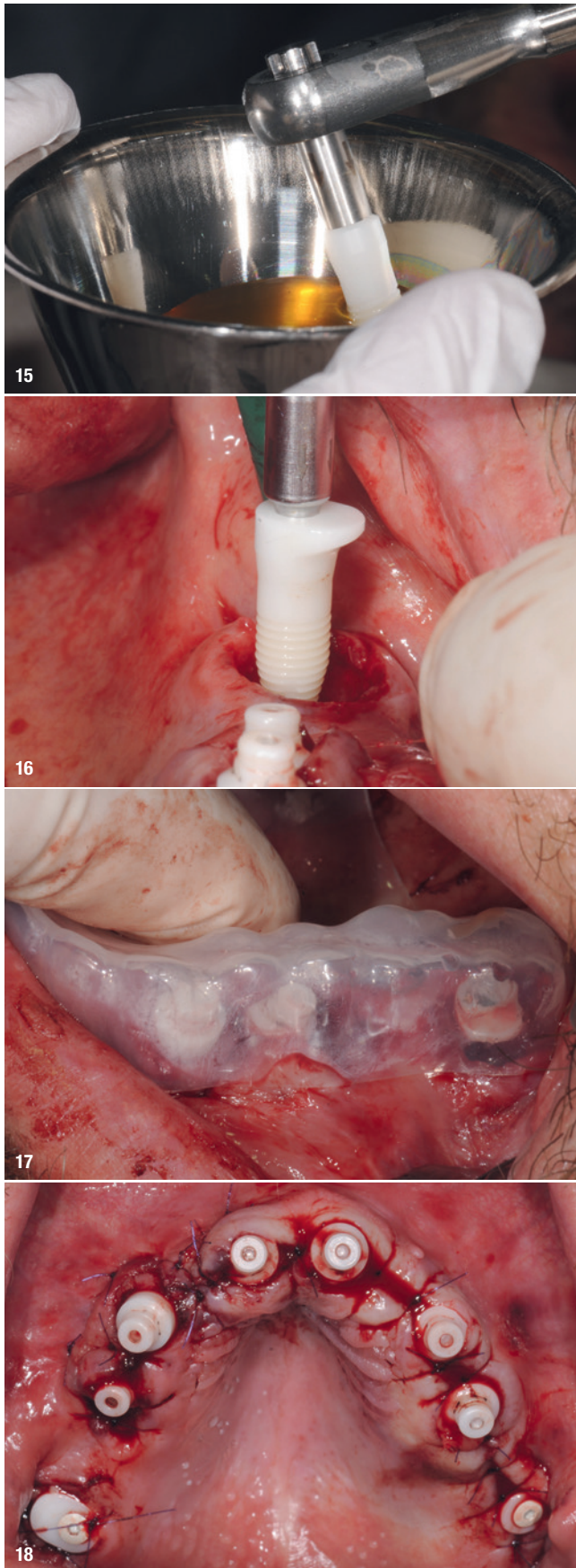
The term “fatty degenerative osteolysis of the jaw bone”, abbreviated FDOK, describes chronic inflammatory processes in which osteoimmunological expression of IL-6 and TNF- α are permanently under-regulated for optimal bone healing, but which would be necessary initial for optimal bone regeneration. Instead, the jawbone may re-

spond with RANTES overexpression, which acts as a stress factor if this overexpression persists. As a result, dissolution of the bone substance occurs, which manifests itself in the form of fatty degenerated bone. NICO treatment is of great importance because jawbone osteitis can have multiple negative effects on overall health. The ongoing inflammatory processes and abnormal structural changes in bone tissue release cytokines that interfere with important cellular functions throughout the body. The surgical approach follows a strict surgical protocol that is consistent with the principles of biological dentistry. The incision is gentle and respects the position of the blood vessels. NICO is removed using piezosurgery, followed by ozone therapy and the application of plasma membranes (A-PRF) and careful saliva-proof suturing. Successful treatment requires the use of an accompanying “bone healing protocol”. The prescription of vitamins and micronutrients helps the body to recover optimally.

In the present case, the extraction of the remaining teeth and cysts in the maxilla was carried out first. In addition, in region 13, the overcrowded filling material in the jaw-



Figs. 12–14: The markers were placed, the alveoli were ozonated and the eight SDS implants pre-treated with plasma were inserted one by one using A-PRF membranes.



Figs. 15–18: The cavities of the alveoli were filled with A-PRF, the implants wetted with the A-PRF exudate and inserted.

bone, which presented itself apically of the root tip over 4 to 5 mm, was removed from buccally (Figs. 4–9).

This was followed directly by minimally invasive NICO restoration in region 18, 28, 38 and 48 as well as in region 27, as already described, using piezosurgery. To do this, we first opened the respective ridge section and then the tuber in the upper jaw using piezosurgery and in the lower jaw retromolar using piezosaw. In region 27, the fatty degenerated tissue was removed circularly through the drill tunnel. It is very important to strictly follow our surgical protocol so that the inferior alveolar nerve is not further irritated. Now we loosened the FDOK areas until the cavities bled in without fat and only healthy bone presented itself in the cavity. The areas were then disinfected with ozone for one to three minutes to sterilise the area and stimulate bone metabolism. In dentistry, the natural gas ozone is used medically in a concentration compatible with health to kill germs and viruses.² In their study from 2020, Takao et al. documented another positive effect through the use of plasma in implantology. In this publication, the effects of treating nano-ZR implants with cold atmospheric plasma were investigated. While plasma treatment does not affect the roughness of the implant, superhydrophilicity could be achieved. *In vitro* and *in vivo* studies measured faster and better protein, cell and bone adhesion, suggesting that plasma treatment is useful as a prosthetic treatment option for patients with metal allergy.³ Plasma surface activation also improves the conditions for complete osseointegration.⁴ Now the buccal lamella in the maxilla is reduced to minimise the existing bone volume in the tuber in terms of recurrence prevention. Finally, A-PRF membrane is inserted in the maxilla and mandible. Now the various surgical aids—an orientation drill guide and various transparent control foils—that the laboratory had prepared for us in advance were used (Fig. 10). The orientation template showed us the optimal fit of the planned implants like a kind of drilling log (Fig. 11). For better healing, the alveoli were cleaned in advance using ozone and the SDS implants were inserted one by one using A-PRF membranes (Figs. 12 & 13). For this purpose, both the cavities of the alveoli were filled with A-PRF and the implants were wetted with the A-PRF exudate and inserted (Figs. 15–17). The advantages of A-PRF lie in its high protein and platelet content. Platelets in particular have a high amount of growth factors that accelerate bone regeneration. Various studies showed the advantages of A-PRF wetting in extraction sockets. In GBR (Guided Bone Regeneration)/GTR (Guided Tissue Regeneration), the A-PRF membrane provides improved dimensional stability of the bone com-

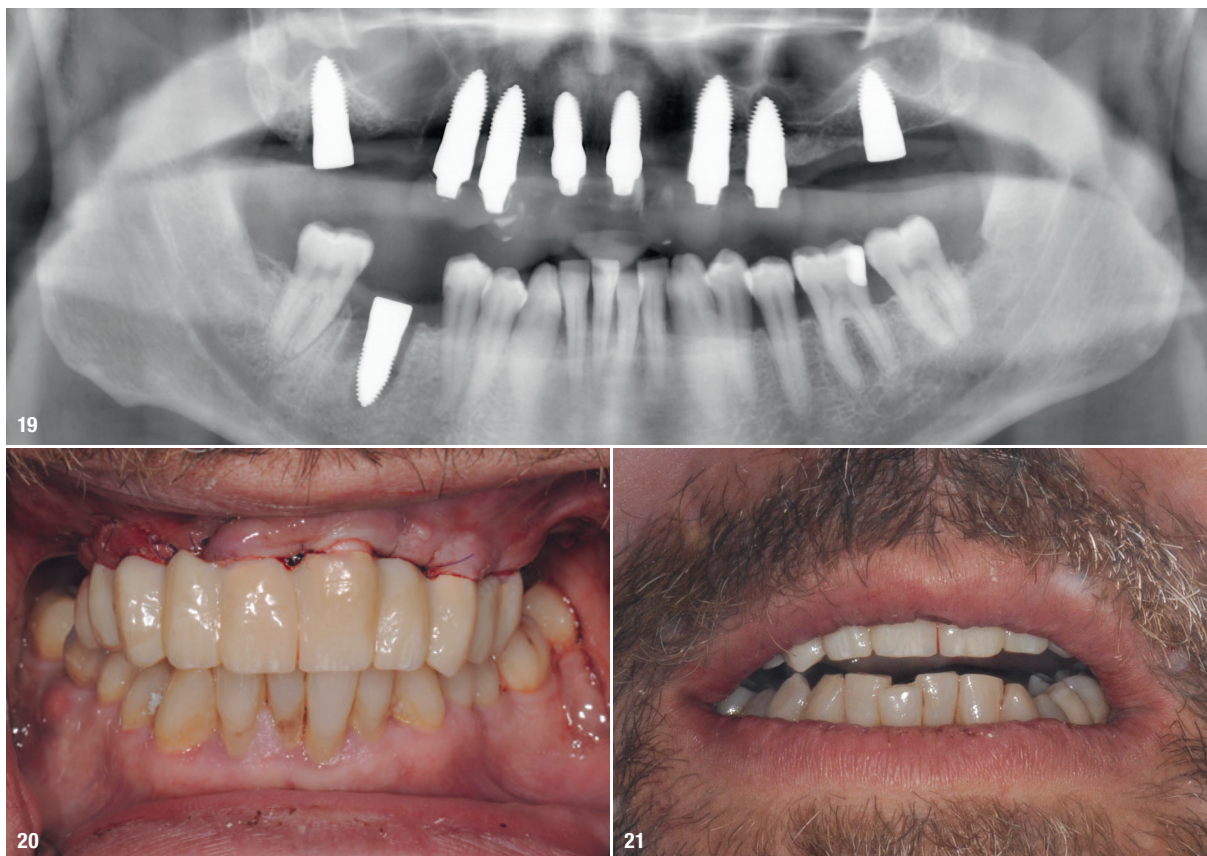

Fig. 19: Finally, the correct seating of all implants was checked with the help of an X-ray. **Figs. 20 & 21:** The inserted long-term provisional fixation presented the final result we were aiming for and a patient who was already happy.

pared to the natural healing process. It has been shown that filling the extraction sockets with PRF reduces the risk of osteomyelitis almost tenfold. Thus, the PRF membrane ensures improved and accelerated bone regeneration and healing, as well as maintaining the quality and density of the residual alveolar ridge. The risk of infection is also significantly reduced.⁵⁻⁸ Thus prepared, the best conditions were created for healing of the inserted implants without complications. The opened areas were closed with atraumatic sutures and a neural therapy with procaine and Traumel was started. Finally, the correct seating of all implants was checked with the help of an X-ray, the long-term provisional fixation was inserted and the occlusion meticulously checked and adjusted. The final result we were aiming for can already be seen at this point (Figs. 18-21).


Preview

While in the first part of the article the authors dealt with the special features of the patient's case during the assessment of the findings, the detailed preparation of the patient as well as the surgical procedure for extraction of the residual dentition and immediate placement of the implants, they will discuss the prosthetic restoration of the patient in the second part.

contact

Dr Dr Michael Rak

Practice for biological dentistry, environmental dentistry & ceramic implantology
 Wettersteinstraße 9
 82347 Bernried on Lake Starnberg
 Germany
 +49 8158 2656
 info@praxis-dr-rak.de
 www.praxis-dr-rak.de



Dental technology Norbert Wichnalek

Arbnor Saraci

Lukas Wichnalek

Hochfeldstraße 62, 86159 Augsburg, Germany
 +49 821 571212
 info@wichnalek-dl.de
 www.highfield.design

