

How reliable is immediate implant insertion after tooth extraction?

A prospective clinical longitudinal study

Authors Verena Stoll¹, Prof Dr Dr Peter Stoll², Dr Georg Bach³, Prof Dr Dr Wolfgang Bähr⁴ & Dr Kai Höckl⁵, Germany

Fig. 1 Bone dust harvested from the extraction socket

Fig. 2 Schematic drawing of extraction socket and implant.

Fig. 3 Fresh extraction socket after atraumatic surgical procedure (female, 56-year-old).

Fig. 4 Flapless implant insertion immediately after tooth extraction (Thommen Element 4,2).

Fig. 5 The use of bone dust harvested from the bore hole.

Fig. 6 Provisional immediately after implant insertion.

Abstract

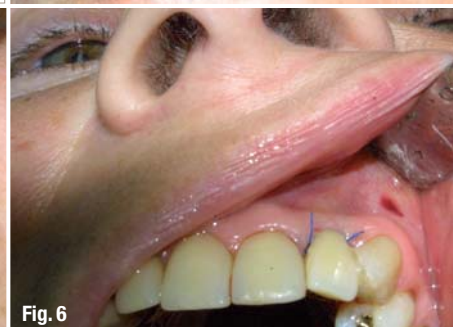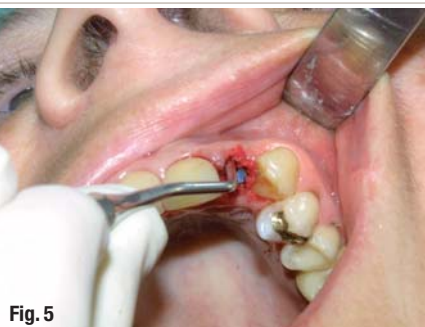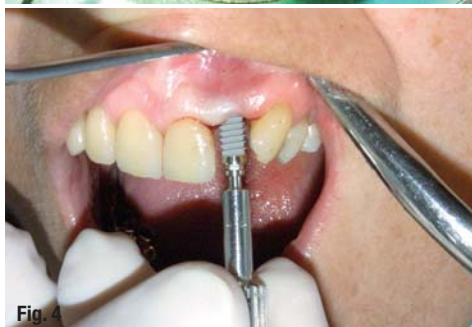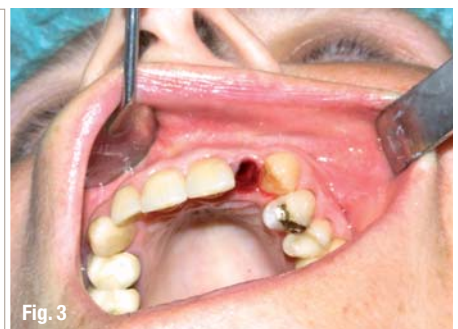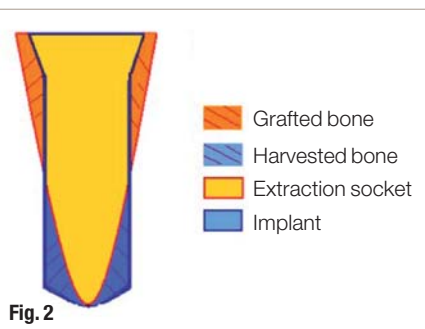
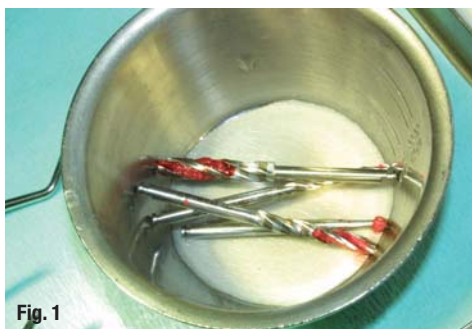Between 2001 and 2009 115 screw implants were inserted into fresh single root extraction sockets. The follow-up period ended at least 6 month after prosthetic treatment. In this prospective clinical multicenter study the results of two-piece titanium implants (Straumann, Thommen) and one-piece zirconium dioxide implants (Z-Systems) were compared in terms of osseous and soft tissue findings. Titanium implants showed the best ratio of osseo-integration (96%) in comparison to zirconium dioxide implants (72,7%), whereas all implants had a comparable success rate in terms of peri-implant

soft tissue outcome at the end of the follow-up period.

Background and aim

Conventional insertion of screw-shape implants is usually performed following a variable time interval after tooth extraction and bone healing of the extraction socket. On the contrary, immediate insertion is done immediately after extraction.

Here the incongruence between extraction socket and implant has to be taken into account. The choice of the implant size should avoid creating a





ADVANCED TISSUE-MANAGEMENT

The easy way to aesthetics.

PARASORB Sombrero®

Der Membrankegel.
The Membrane-Cone.



IDS
2011

34. Internationale Dental-Schau
34. International Dental Show
COLOGNE, 22. – 26.03.2011

Besuchen Sie uns!
Visit us!
Hall 3.2 / Stand A 48

 **RESORBA®**
REPAIR AND REGENERATE 

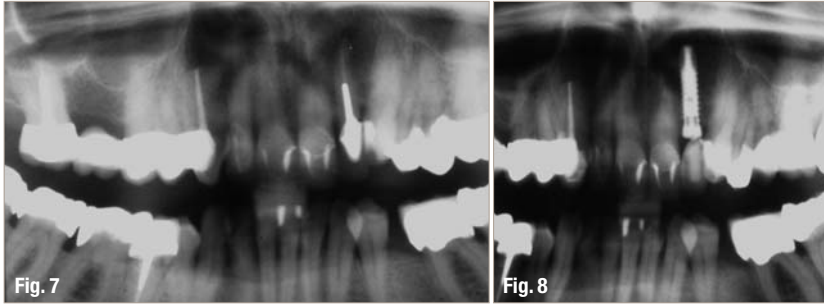


Fig. 7 X-ray prior to extraction of 22.
Fig. 8 X-ray immediately after implant insertion, correct position of the titanium implant (Thommen Element 4,2).

too "large bone jumping distance", in general not more than 1,5 mm.¹

During the implant insertion process it is easily possible to gain a certain amount of bone dust, which can be squeezed into the gap between implant and alveolus (Figs. 1 & 2).

Since consecutive bone remodeling processes after extraction lead to a reduction of the buccal crest, it is of advantage to place the implant whenever possible in a palatal respectively lingual position. An atraumatic surgical procedure is of high importance. To avoid additional bone loss a flapless operation is recommended. However, despite atraumatic extraction technique the resorption of buccal bone follows its own rules.^{2,3,4,5,6}

Conventional techniques with titanium screw implants show a successful longterm outcome between 94–96% independent from the manufacturer.⁷

The aim of this investigation was to assess, whether immediate implant placement after extraction leads to a success rate comparable to delayed (2 months) or late (4–6 months) insertion.

Fig. 9 Implant loss by manufacturer.

Fig. 10 Pocket depth 4–6 month after tooth extraction i.e. implant insertion.

Fig. 11a Periimplant soft tissue immediately before insertion of the crown (male, 58-year-old) (Straumann RN 4,1).

Fig. 11b Periimplant soft tissue with crown.

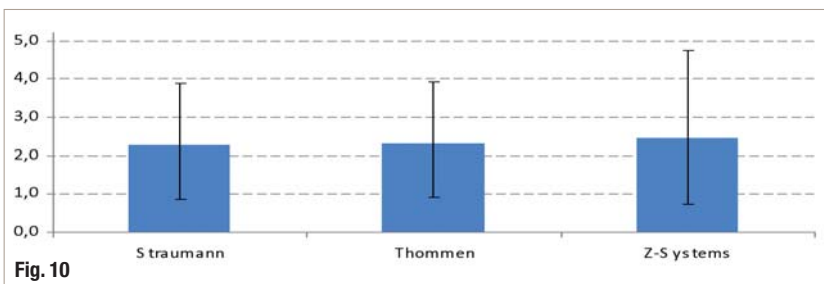


Fig. 10

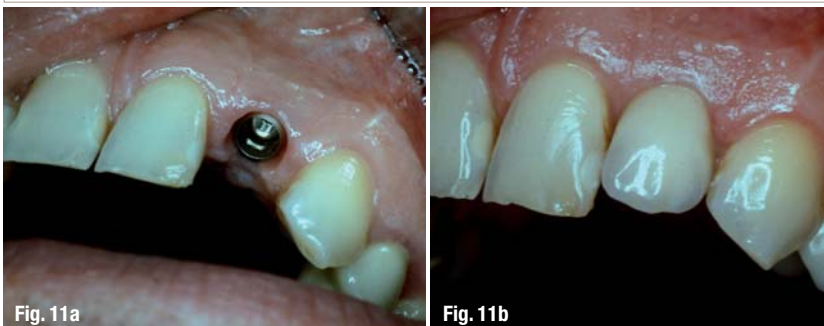

Fig. 11a

Fig. 11b

_Materials and methods

Between February 2001 and January 2010 120 screw shaped implants were inserted into single root extraction sockets in 109 patients, 78,3 % of them following flapless procedures (Figs. 3 & 4). 115 of the implants could be examined during the follow-up period (drop out = 4,1 %).

104 two-piece titanium (75 Straumann and 29 Thommen) and 11 one-piece zirconium dioxide implants (Z – Systems) were used.

Small periapical granulomas were not excluded from immediate implant insertion, but meticulously drilled out. The patient sample included 9 smokers (less than 10 cigarettes per day), 4 Patients with hepatitis B, 3 patients with diabetes mellitus (oral antidiabetics) and 1 Patient with inapparent HIV-infection.

The implants were placed utmost in a palatal or lingual position respectively. Bone remodeling after extraction had to be taken into account.⁸

The incongruence between extraction socket and implant surface was spanned by using autogenous bone dust/cancellous bone from the bore-hole (Fig. 5).

In none of the cases immediate loading of the implants was performed. Provisionals were fixed at the neighboring teeth (Fig. 6) whenever possible. Removable dentures were adapted to the situation required. In the case of zirconium dioxide implants resin splints were used to touchless shield the one-piece implant.

Regular clinical examination of stability and peri-implant soft tissue status was performed 1, 2, 3, 4 and 16 weeks after implant insertion, final assessment 6 month after definitive prosthetic loading. Radiological examination was done before tooth extraction, immediately after implant insertion (Figs. 7 & 8), after osseo-integration of the implants and not earlier than 6 months after prosthetic treatment.

_Results

7 of 115 implants (6,1 %) were lost during the osseous healing period, whereas later no implant loss occurred until now. The survival rate of Straumann titanium implants (n = 75) was 96,0%, of Thommen titanium implants (n = 29) 96,6% and of Z-Systems zirconium dioxide implants (n = 11) 72,7% (Fig. 9). No differences between the 3 implant types were found in the soft tissue. The mean pocket depth (PD) was 2,3 mm (Fig. 10). No peri-implantitis with

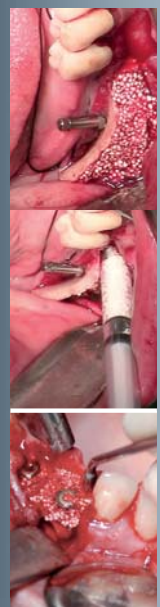
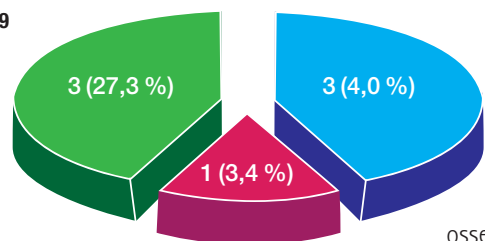


Fig. 9



■ Z-Systems ■ Thommen ■ Straumann

pathological secretion or bleeding occurred. X-ray evaluation indicated similar results in position and osseous healing of the implant types examined.

After osseo-integration the majority of the implants was covered by single crowns (57,4 %) (Fig. 11), followed by fixed bridge-work (21,3 %) and support of removable dentures (21,3 %).

Discussion and Conclusions

Immediate insertion of titanium screw-shape implants resulted in a success rate comparable to delayed or late insertion.⁷ The suboptimal results obtained with the small sample of one-piece ceramic implants were, in 2 cases, due to insufficient protection during the healing phase. In the authors opinion this was not due to the implant system. It can be only speculated, whether the different roughness of titanium and zirconium-dioxide implants has contributed to the significant worse results (early loss) of the latter. However, the small number of zirconium dioxide implants in this study does not allow a final conclusion.

After osseo-integration all implant types showed similar clinical and radiological results. The important advantage of immediate implant insertion for the patient is the time gain of the faster prosthetic loading. The remodeling processes of the alveolar bone have to be taken into consideration already at implant insertion planning.

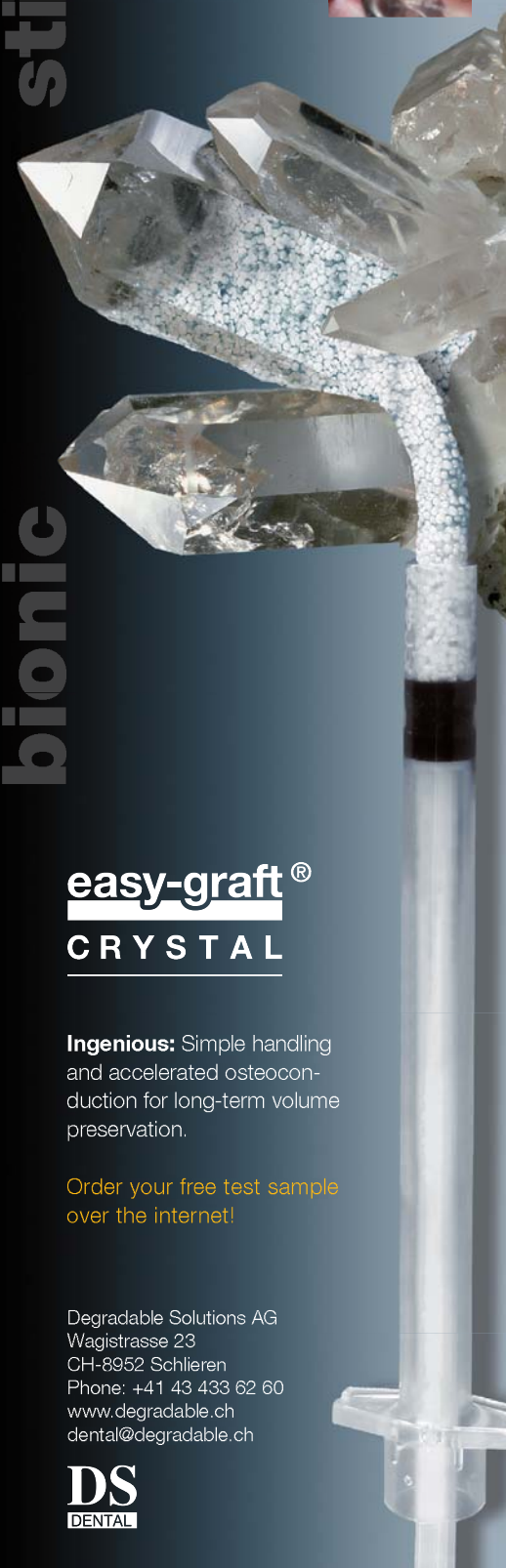References

1. Botticelli D, Berglundh T, Lindhe J (2004); Resolution of bone defects of varying dimension and configuration in the marginal portion of the peri-implant bone. An experimental study in the dog. J Clin Periodontol 31(4):309–17.
2. Araújo MG, Sukekava F, Wennström JL, Lindhe J (2006); Tissue modeling following implant placement in fresh extraction sockets. Clin Oral Implant Res 17(6):615–24.
3. Fickl S, Zuhr O, Wachtel H, Bolz W, Huerzeler M (2008); Tissue alterations after tooth extraction with and without surgical trauma: a volumetric study in the beagle dog. Clin Periodontol 35(4):356–63.
4. Stoll P (2008); Minimalinvasive Insertion von Zirkonoxidimplantaten. Implantol J Sonderdruck 6:28–38.
5. Chen ST, Darby IB, Reynolds EC, Clement JG (2009); Immediate implant placement postextraction without flap elevation. J Periodontol 80(1):163–725.
6. Sanz M, Cecchinato D, Ferrus J, Pjetursson EB, Lang NP, Lindhe JA (2009); Prospective, randomized-controlled clinical trial to evaluate bone preservation using implants with different geometry placed into extraction sockets in the maxilla. Clin Oral Implants Res 21:13–21.

Editorial note: The whole list of references is available from the publisher.

_contact	implants
<p>Gand med dent Verena Stoll verena-stoll@web.de</p> <p>¹ University of Freiburg, Germany; ² KOSMedics Interdisziplinäre Chirurgische Privatklinik, Freiburg/Stegen, Germany; ³ Private practice, Freiburg, Germany; ⁴ Private practice, Freiburg, Germany; ⁵ Private practice, Freiburg, Germany</p>	

bionic sticky granules



easy-graft®
CRYSTAL

Ingenious: Simple handling and accelerated osteoconduction for long-term volume preservation.

Order your free test sample over the internet!

Degradable Solutions AG
Wagistrasse 23
CH-8952 Schlieren
Phone: +41 43 433 62 60
www.degradable.ch
dental@degradable.ch

