

Implant therapy of edentulous sites

Authors _ Balint Török, Istvan Gera, Agnes Meszaros & Peter Windisch, Hungary

_Deep periodontal defects with advanced bone loss of the buccal cortical plate represent a challenge for periodontal treatment in the upper front region. Literature data suggest that one and two-wall periodontal defects do not have tendency for complete periodontal regeneration and bone fill (Eickholz *et al.* 1996, 1998, 2000). Remaining residual pockets can also jeopardize the long term result of periodontal treatment (Matulienė *et al.* 2008). Tooth extraction in the upper front region even without any periodontal defect will result in certain amount of oro-vestibular and eventually vertical shrinkage of the original soft tissue contour (Schropp *et al.* 2003). Due to bone remodelling appropriate implant placement cannot be achieved in most of the cases. Socket preservation and different alveolar site developments are used to offset this unfavourable feature (Camargo & Lekovic, 2004; Lekovic & Kenney, 1997). It is obvious that the application of one of these techniques can be of great importance when tooth extraction is being considered at periodontally compromised teeth with advanced buccal plate involvement. It is not clear that ridge preservation procedures are effective in limiting horizontal and vertical ridge alterations in postextraction sites. Comparing the clinical and histological results obtained by different preservation techniques there is no literature data to support the superiority of one technique over another (Darby *et al.*, 2009). Nevertheless each preservation technique provided better results than natural socket wound healing (Barone *et al.* 2008). The effect of extraction site

development on the changes of attachment level of neighbouring teeth has not been clarified yet.

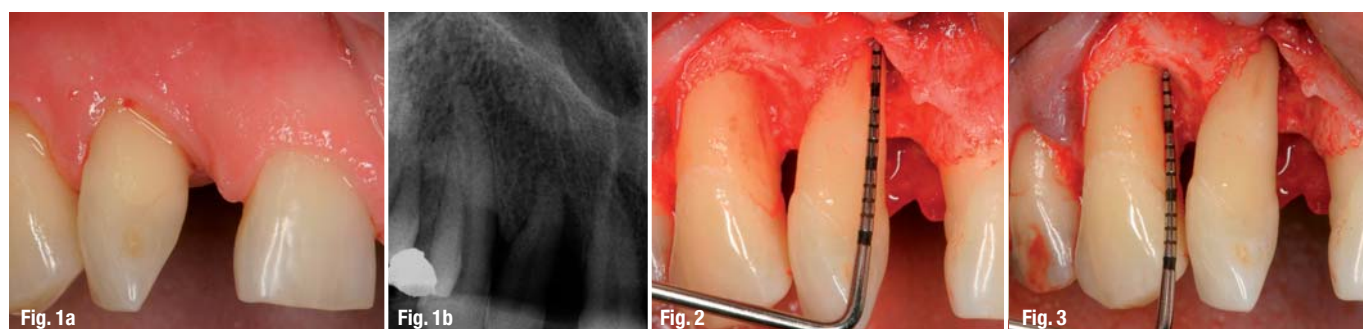
While supraalveolar periodontal regeneration is still unpredictable (Sculean *et al.*, 2004) vertical ridge augmentation has been successfully demonstrated in several publications (Barboza EP, 1999; Urban & Jovanovic, 2009; Merli & Lombardini, 2010; Beitlitum *et al.*, 2010). Treatment of vertical ridge deficiencies has been performed in edentulous areas without neighbouring teeth demonstrating advanced periodontitis. It was suggested that natural teeth with advanced periodontitis, may impose a risk for an infection of the augmented site and of membrane exposure originating from the neighbouring periodontally compromised teeth (Karoussis *et al.*, 2003; Hoffmann *et al.*, 2007). Nevertheless in certain clinical situations, teeth presenting deep intrabony defects are located in close vicinity of the compromised alveolar ridge.

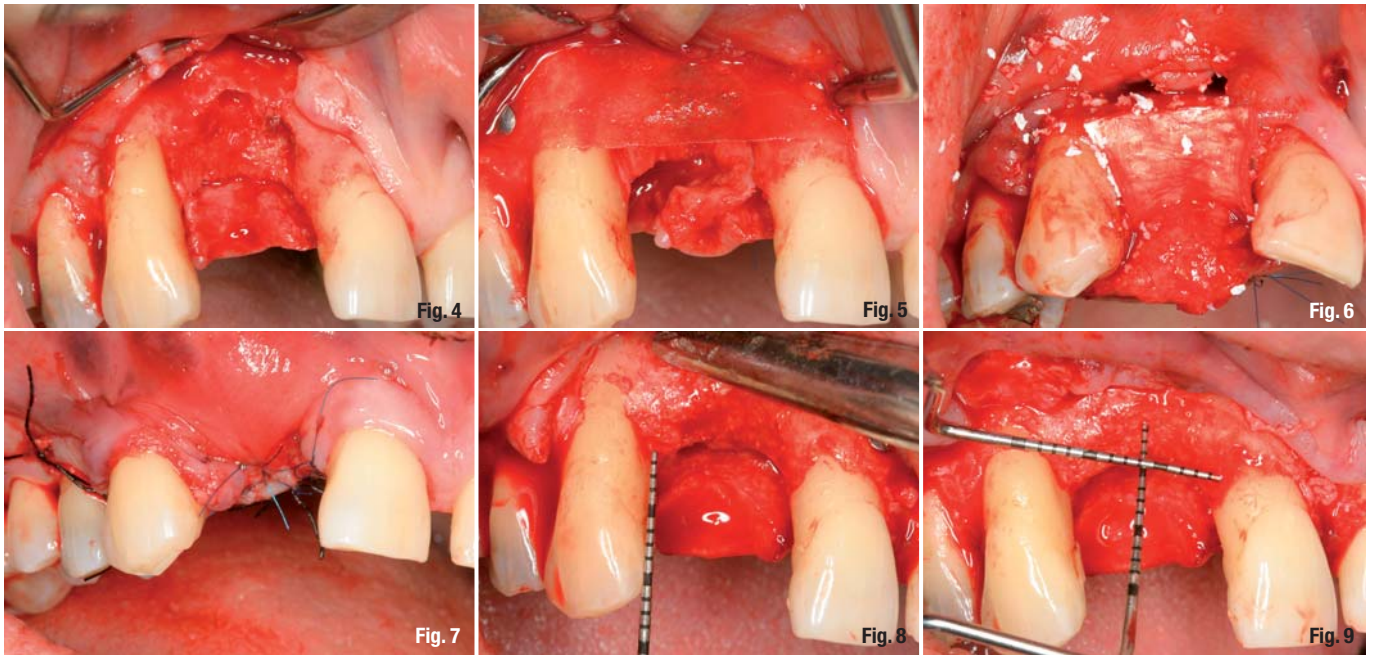
In these particular cases, it is of clinical interest to simultaneously reconstruct both the intrabony periodontal defect and the resorbed alveolar ridge, thus allowing proper insertion of dental implants. For those implant patients having a history of chronic periodontitis it is inevitably important to reduce periodontal pockets at natural teeth to 3 mm and even below to facilitate proper individual plaque control and to reduce the chance of periodontal reinfection (Carnevale *et al.*, 2007). The importance of proper implant positioning

Fig. 1a _ Clinical view of tooth 12 prior treatment with similar recession on tooth 13. Distal papilla of 11 is missing.

Fig. 1b _ Standardized X-ray at baseline. The #12 tooth has a deep intrabony defect on the mesial aspect.

Fig. 2 & 3 _ Advanced periodontal breakdown at the upper right lateral incisor. The bony defect involves the buccal plate of bone. The neighbouring tooth has also intrabony periodontal defect.





and adequate amount and quality of periimplant hard and soft tissues have to be considered to maintain long term stability around implants. Therefore, the aim of the present cases was to evaluate the effect of a new step-by-step surgical technique designed to simultaneously reconstruct resorbed alveolar ridge and the adjacent located intrabony defect to achieve a predictable clinical outcome and adequate peri-implant tissue stability.

Materials and methods

Three patients exhibiting chronic periodontitis with localized advanced periodontal bone loss were referred to the Department of Periodontology, Semmelweis University, Budapest, for comprehensive periodontal therapy. All three patients were middle aged Caucasian males (51, 50 and 49 years-old), systemically healthy and had never been smokers. Each patient presented at least one deep advanced periodontal bony defect in the upper front region. After initial therapy teeth were considered to be hopeless because of their disadvantageous pathomorphology. Before tooth extraction each patient had completed basic cause related periodontal therapy including full mouth scaling and root planning and oral hygiene training. Before surgery all exhibited high standards of oral hygiene. Treatment plan consisted of tooth removal followed by extraction site development (Surgery 1), and soft tissue augmentation (Surgery 2), and implant placement with simultaneous ridge augmentation (Surgery 3) and abutment connection with non resorbable membrane removal (Surgery 4). The following parameters were measured at baseline, immediately before augmentation procedure and 11–20 months after implant placement: plaque index (PI),

gingival index (GI), bleeding on probing (BOP), probing depths (PD) around the neighbouring teeth at 6 sites, gingival recession (GR), clinical attachment level (CAL) with a millimetre calibrated periodontal probe (PCP-UNC 15, Hu-Friedy, Chicago, IL, USA) and also intra-surgical direct measurements: the level of periodontal bone of neighbouring teeth, the width and height of the alveolar ridge. Standardized radiographs were taken with the long cone parallel technique preoperatively, between surgeries and postoperatively; for qualitative assessment of bone height.

The combined surgical technique

Surgery 1

Tooth extraction with extraction site development

Following tooth removal a full thickness flap was raised up to the mucogingival line and beyond a partial thickness flap was mobilised with a horizontal extension thus allowing a tension free soft tissue management and wound closure. This flap design let the operator to evaluate and treat the periodontal defects around the neighbouring teeth. A combined alveolar site preservation technique was used with a slow resorbable membrane (Resolut Adapt LT 2530, Gore-Tex®, Newark, DE, USA) fixed with titanium pins (Ti-pins; DENTSPLY Friadent, Mannheim, Germany) to cover the missing part of the buccal plate and to maintain the original form of the earlier arch. Following an appropriate-sized connective tissue graft was removed from the palatal mucosa by using the Hürzeler technique (Hürzeler & Weng, 1999). The harvested tissue was trimmed and sutured (5.0 non-absorbable polyamide monofilament, Braun AG, Tuttlingen, Germany) to the inner surface of the partial thickness mu-

Fig. 4 Clinical situation immediately after tooth extraction.

Fig. 5 & 6 A long term biodegradable membrane is fixed on the buccal aspect with titanium pins. Then the defect was filled with bovine derived xenograft (BDX) (BioOss) and covered with collagen membrane.

Fig. 7 Tension-free wound closure after alveolar socket preservation.

Fig. 8 The reentry revealed that the intrabony defect of the neighbouring tooth has also been filled with new bone.

Fig. 9 The horizontal dimension of the implant site is already satisfactory but its vertical dimension needs further augmentation.

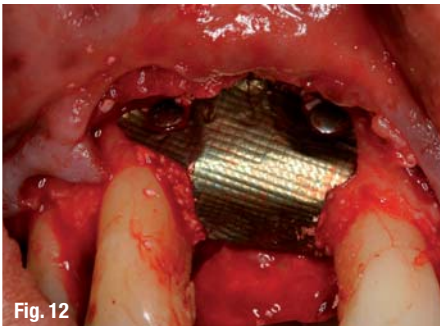
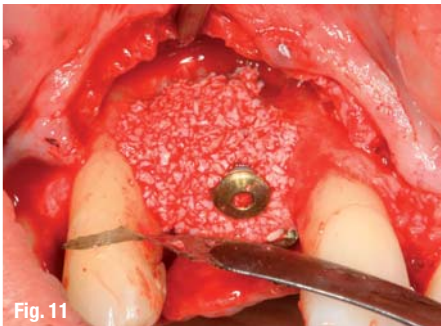
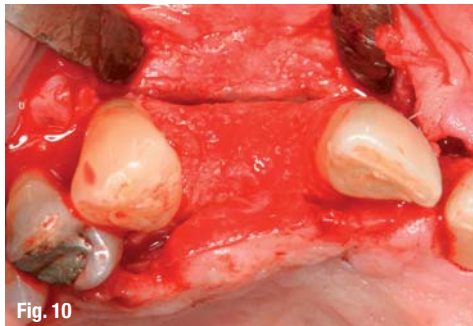


Fig. 10_ The horizontal dimension of the implant site is already satisfactory but its vertical dimension needs further augmentation.

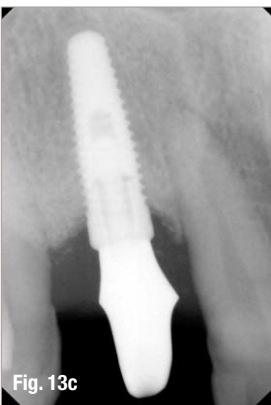
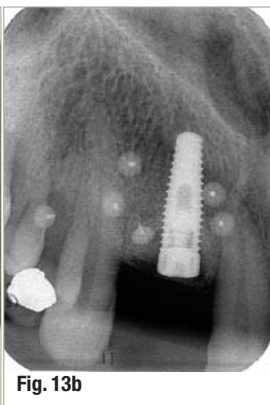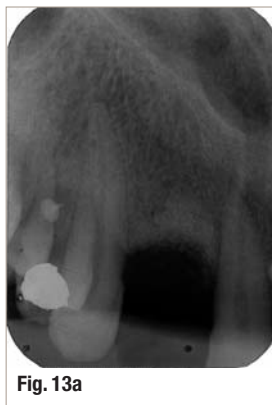Fig. 11 & 12_ Surgery 2: implantation with simultaneous hard tissue augmentation using a BioOss and titanium membrane.

cosal flap. Additionally the oral flap at the earlier tooth removal site was covered by a connective tissue graft with an epithelial collar. The periodontal defect and the edentulous ridge were either filled and overfilled vertically and horizontally with BDX (Bio-Oss®, particle size 0.25 to 1.0 mm, Geistlich AG, Wolhusen, Switzerland) (Case 1 and 3) or no bone grafting material was used (Case 2). After grafting, a biodegradable collagen membrane of porcine origin (Bio-Gide®, Geistlich AG, Wolhusen, Switzerland) was trimmed and adapted over the graft (Case 1 and 3). Finally the buccal mucoperiosteal and the oral "CTG reinforced" flaps were re-positioned by avoiding any extra flap mobilizing procedure and closed with vertical mattress sutures (5.0 non-resorbable polyamide monofilament, Braun AG, Tuttlingen, Germany).

**Surgery 2
Soft tissue augmentation**

Following the above mentioned procedures if the width of the keratinized soft tissue allowed proper coverage after augmentation procedure simultaneous augmentation and implant placement was performed. If the thickness and the width of the alveolar mucosa were not sufficient to provide predictable primary wound healing during hard tissue augmentation procedure, soft tissue augmentation was performed prior to implant placement. A free autogenous soft tissue graft or a xenograft (Alloderm®, BioHorizons, Birmingham, AL, USA) was used in order to gain enough keratinized gingiva and deepen the vestibule at the implant area using a modified tunnel technique

Fig. 13a-c_ Radiological follow up of the augmented site development.
a) Standardized X-way prior to implant placement. Radiographical bone fill can be seen in intrabony defects of the neighbouring teeth.
b) Radiological view after 9 months healing of implant placement and simultaneous hard tissue augmentation.
c) The platform shifted abutment is fixed to the implant.



(Azzi *et al.* 2009). The tissue harvesting technique has already been described before.

**Surgery 3
Implant placement with simultaneous hard tissue augmentation**

One implant (Straumann Bone Level, Straumann AG, Waldenburg, Switzerland, and Nobel Replace Tapered Effect, Nobel Biocare, Gothenburg, Sweden) was inserted with simultaneous 3-D hard tissue augmentation using BDX and a non-resorbable membrane (Titanium membrane—FRIOS® Boneshield; DENTSPLY Friadent®, Mannheim, Germany) or a slow resorbable membrane (Resolut Adapt LT2530, Gore-Tex®, Newark, DE, USA) was fixed over it. A tension free wound closure was achieved in all cases resulting in primary wound healing.

**Surgery 4
Abutment connection with non resorbable membrane removal**


The same split thickness flap design was applied for non-resorbable membrane removal and abutment connection.

After surgery patients were instructed to take antibiotics (Augmentin, 3 x 625 mg/day for 1 week). Post surgically mechanical plaque control was not performed in the surgical and adjacent area and chemical plaque control was maintained with a 0.2% chlorhexidine solution twice daily (Corsodyl, GlaxoSmithKline). Sutures were removed at 14 days after surgery. Additional recall appointments including supragingival professional tooth cleaning were scheduled biweekly for the first 6 postoperative weeks. Prior tooth extraction each patient received a resin bond prefabricated bridge to provide immediate provisional prosthodontic reconstruction after tooth extraction. Finally all patients received fixed prosthodontic restoration i.e. PFM crowns on each implant.

_Case 1 (Figs. 1-14)

A 51 years-old male patient was referred with generalized periodontitis for a comprehensive periodontal treatment. At the upper right lateral incisor an ad-

tiologic[®] easyClean Cleaning – so easy



world innovation

**Now possible:
machine preparation of the fully equipped surgical tray**

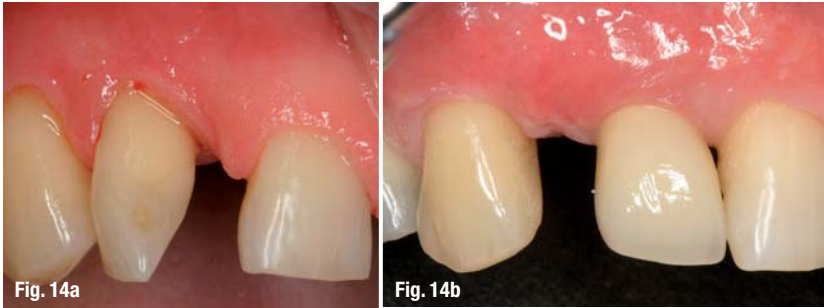

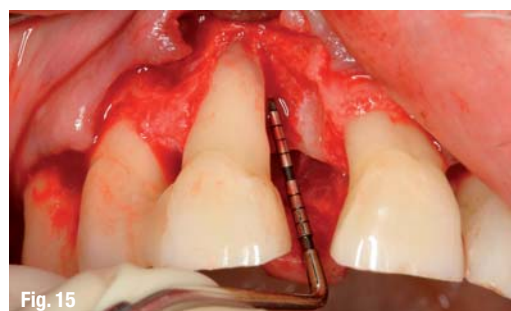Fig. 14a & b Post treatment view of the final PFM crown in place surrounded by optimal and harmonious soft tissues.

vanced periodontal defect was registered with tooth mobility III (see the standardised X-ray, Fig. 1a–b). Deep periodontal pocket depths were assessed on the adjacent teeth. After flap elevation a two-wall crater-like defect was found on the mesial aspect of the tooth with a missing buccal bony plate (Fig. 2 & 3). After tooth extraction the previously described step-by-step technique was carried out (Fig. 4–7). As a result of surgery 1, completed with a soft tissue augmentation, the alveolar ridge configuration allowed the implant placement with simultaneous further augmentation (Fig. 8–12). During abutment connection the 3-D reconstruction of alveolar ridge was observed around the previously supracrestally placed implant. This surgical approach allowed a re-entry procedure of adjacent periodontal defects, they presented bone fill and complete regeneration of earlier one-wall defects. After soft tissue healing a screw retained temporary crown was placed in situ to form an ideal emergence profile for further three months. This situation was then transferred to the cast to make the permanent PFM crown. See the final restoration on Fig. 14.

Case 2 (Figs. 15–17)

A 54 years-old male patient presented an advanced vertical bony defect on the mesial aspect of the right upper central incisor with excessive tooth mobility (Fig. 15). After tooth extraction an alveolar site development was performed in the same way like described before without any bone substitute material. The second surgical phase was the previously described soft tissue augmentation. During surgery 3 implant placement with simultaneous hard tissue augmentation was proceeded by. As an augmentation material BDx was used covered by a slow resorbable membrane. The

Fig. 15 The tooth 11 has got a deep one-wall bony defect that after extraction would cause tissue collapse influencing also the periodontal status of the neighbouring teeth.



width and height of the alveolar ridge became sufficient to promote long term stability for the implant borne restoration (Fig. 16a & b, 17).

Case 3 (Figs. 18–20)

The third case is a 49 years-old male patient who presented the left upper lateral incisor with an advanced horizonto-vertical bony defect on its mesial aspect (Fig. 18). Following tooth extraction an alveolar ridge preservation was performed and implant placement with simultaneous augmentation as described before. The augmentation material was BDx covered by a titanium membrane (Fig. 19). The final soft tissue augmentation was followed by the prosthodontic rehabilitation, a PFM crown was established (Fig. 20).

Results

After the cause related periodontal therapy the patients developed proper individual oral hygiene measures. Each patients' gingival and plaque index was under 20%, the mean of PI was 7,7%, and 12,7% of GI, respectively. At baseline the mean periodontal PD of the neighbouring teeth was 3,97 mm, GR 0,88 mm and CAL 4,78 mm. After the healing of the 3rd stage the neighbouring teeth's PD was 2,55, GR 2,13 and CAL 4,58. The clinical parameters showed slight improvement although the number of cases does not offer any statistical analysis. The intrabony component of the adjacent teeth is being eliminated clinically and radiologically and during re-entry. Optimal hard and soft tissue conditions were found around implants.

Discussion

The long term success of implant therapy depends on the adequate volume of bone around the implant site. The lack of mineralized tissue is an unfavourable condition for a predictable implant therapy (Lekholm *et al.*, 1986). Another key factor for maintaining the alveolar crest level around implant is the quantity and morphology of the covering soft tissues. Implant therapy in the aesthetic zone needs a comprehensive consideration of several contributing factors. In periodontal patients implant placement is even more challenging. Periodontally compromised teeth often show disadvantageous bone loss, especially if the buccal bony plate is missing. For achieving predictable healthy periodontal conditions tooth extraction cannot be avoided. Several techniques and materials have recently been developed for the purpose of extraction socket preservation. There are controversial data in the literature concerning the possible role of bone fillers in alveolar socket preservation. Several different techniques have been described to achieve this goal. There is a substantial ambiguity in the literature regarding the predictability of these kind of techniques. Several



dental
implants

TRI

Through Research Innovative

Learn more about a new revolutionary concept
in high-performance implantology

IDS

VISIT US

Hall 11.1
G011

*Come & Take
A FREE Test Drive!*

Register on www.tri-implants.com

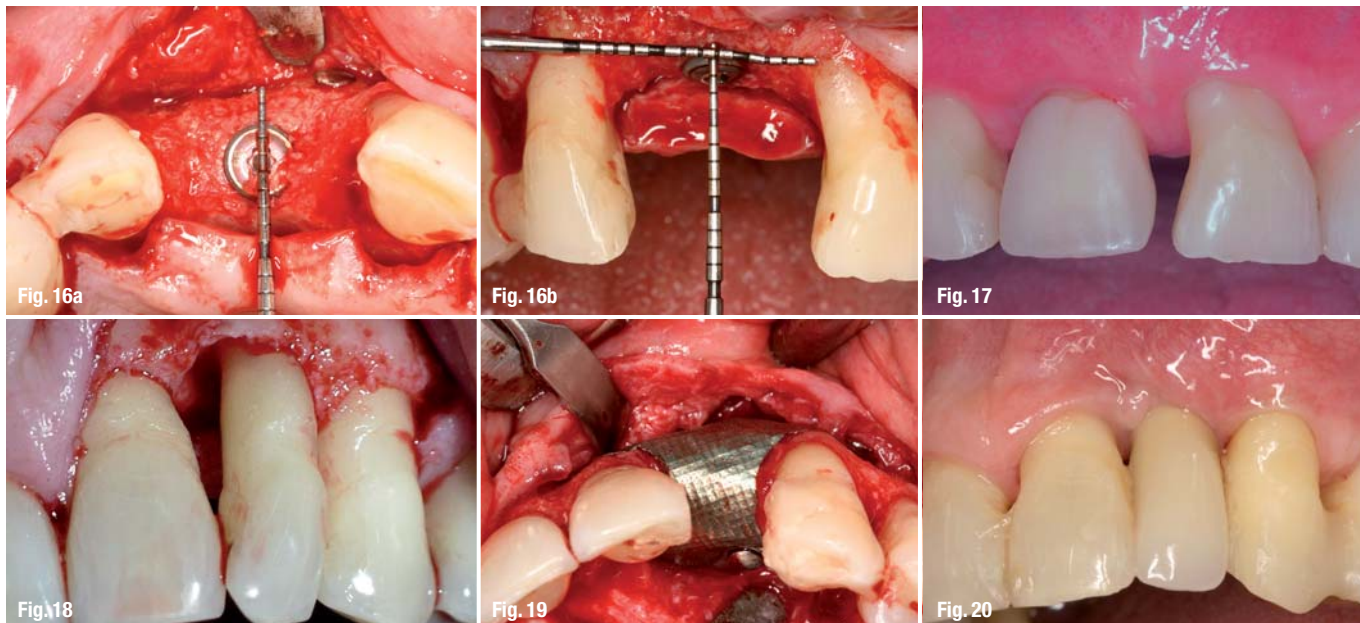


Fig. 16_ The optimally positioned implant in 3-D regenerated bone.

Fig. 17_ The final result.

Fig. 18_ The morphology of the osseous defect after flap elevation.

Fig. 19_ The optimally positioned Ti-membrane covering the augmented area.

Fig. 20_ The final prosthetic rehabilitation.

authors report positive findings on the effect of bone substitutes (Froum *et al.*, 2002). Different animal studies (Araújo & Lindhe, 2009; Fickl *et al.*, 2009) suggest that bone filler materials can to a certain extent retard or modify the resorption of the buccal bone. It is also the matter of discussion whether these grafting materials in the alveoli have an active role in the modulation of alveolar bone formation or they only slow down the vestibular bone resorption (Araújo & Lindhe, 2009). Other studies suggest the utilization of membranes. The biodegradable membranes have recently been increasingly applied because of its incorporation in the host tissues and providing better soft tissue healing. If it is exposed to the oral cavity the healing is less compromised and the risk of infection is low (Lekovic *et al.*, 1997, 1998). Tooth extraction always presents conditions where a complete wound closure is questionable. If the membrane is not able to maintain enough space for regeneration it should be supported with some grafting material (Case 3). Similar ridge configuration was achieved when using bone fillers (see our Case 1) or without any bone substitute (see our Case 2) (Chiapasco *et al.*, 2006).

The use of non-resorbable membrane became the gold standard for GBR with a need of 3-D reconstruction of the edentulous ridge (Simion *et al.*, 2007). One of the disadvantages of this technique that the gingival flaps should be sutured over the membrane in a way that a primary wound healing without any flap dehiscence could be achieved. Membrane exposure may severely compromise wound healing and also the consecutive regeneration and final treatment outcomes (Hämmerle *et al.*, 1998). The soft tissue coverage is a prerequisite for the management of hard tissue augmentation and for the final aesthetics of the implant borne restoration. The three demonstrated clinical

cases showed favourable hard and soft tissue alteration during the third surgery. During this step-wise surgical approach we managed to develop an ideal implant position in all the three dimensions covered by the required amount of hard and soft tissues (Buser *et al.*, 2004). Literature data suggest that survival and success rate of implants partially or fully placed into augmented bone is comparable to implants placed into non regenerated alveolar ridges (Mayfield *et al.*, 1998; Zitzmann *et al.*, 2001b). The biological mechanism of the alveolar regeneration is not fully investigated and understood and the role of this issue in the healing of neighbouring teeth's periodontal intrabony defects even needs further examination.

Conclusion

This stepwise series of surgical techniques could be successfully applied for correcting sever ridge deficiencies and also can facilitate the comprehensive regenerative therapy of periodontal defects at adjacent teeth.

Editorial note: A list of references is available from the publisher.

<u>_contact</u>	implants
<p>Dr Peter Windisch DMD, PhD Associate professor Departement of Periodontology Semmelweis University, Budapest 1088 Budapest, Szentkiralyi u 47, Hungary</p> <p>Phone/Fax: +36 1 267 4907 peter.windisch@gmail.com</p>	

SAVE CELLS

NEW EMS SWISS INSTRUMENTS SURGERY – SAVING TISSUE WITH NEW INNOVATIONS IN IMPLANT DENTISTRY

The inventor of the Original Piezon Method has won another battle against the destruction of tissue when dental implants are performed. The magic word is dual cooling – instrument cooling from the inside and outside together with simultaneous debris evacuation and efficient surgical preparations in the maxilla.

COOLING HEALS

A unique spiral design and internal irrigation prevent the instrument's temperature from rising during the surgical procedure. These features combine effectively to promote excellent regeneration of the bone tissue.

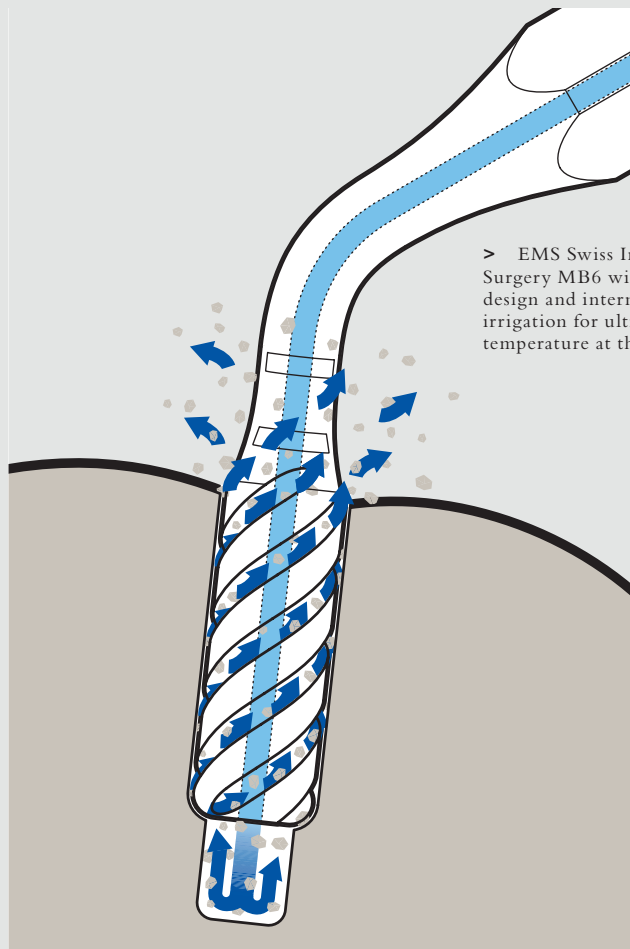
EMS Swiss Instruments Surgery MB4, MB5 and MB6 are diamond-coated cylindrical instruments for secondary surgical preparation (MB4, MB5) and final osteotomy (MB6). A spiral design combined with innovative dual cooling makes these instruments unique in implant dentistry.

CONTROL SAVES

Effective instrument control fosters atraumatic implant preparation and minimizes any potential damage to the bone tissue.

PRECISION REASSURES

Selective cutting represents virtually no risk of damage to soft tissue



> EMS Swiss Instrument Surgery MB6 with unique spiral design and internal instrument irrigation for ultralow temperature at the operative site

(membranes, nerves, blood vessels, etc.). An optimum view of the operative site and minimal bleeding thanks to cavitation (hemostatic effect!) further enhance efficacy.

The new EMS Swiss Instruments Surgery stand for unequalled Swiss precision and innovation for the

benefit of dental practitioners and patients alike – the very philosophy embraced by EMS.

For more information >
www.ems-swissquality.com

