

# A concept of laser assisted treatment of periimplantitis

Author\_Dr Gérald Mettraux, Switzerland

**\_Periimplantitis is a disease** with growing incidence which when untreated, leads to the loss of the implant. The ethological factors of periimplant infections are similar to periodontitis. What about the treatment? Classical treatment procedures in closed periimplant pockets have shown little success (Renvert, 2008). In open flap procedures the treatment of periimplantitis shows more promising data (Lindhe 2008). Although we gain better access to the implant surface in open procedures, we encounter the same limitations as in open periodontal therapy. Nevertheless, decontamination of the implant surface is much more complicated than decontamination a root surface. The sophisticated implant surface which is so promising at the moment of insertion will turn into a death trap in case of pocket formation. The instruments used in periodontal treatment are much too big to get rid of the bacteria on the implant surface. The classic treatment procedures show very strict limitations and their instruments are not useful for adequate decontamination of the implant surface.

What about the concept of the classical periodontal treatment? This concept integrates the cleaning of the root surface by means of mechanical instruments, the plaque control by the patient and the supportive periodontal therapy on a long term basis. Several studies have shown that this concept works very well in periodontal disease. This concept could theoretically work in the treatment of periimplantitis since the diseases share similar etiological factors; however, we have to use different and smaller instruments for decontamination. The instrument size should be equal to the size of the bacteria, since the goal is to decontaminate the implant surface and to create a biological acceptable surface.

## **\_The concept of laser supported treatment of Periimplantitis**

The lasers used in dentistry (Diode, CO<sub>2</sub> and Erbium lasers) have wave lengths which are similar in

the size of human cells and that of bacteria. Using their characteristic abilities of absorption, lasers are able to destroy cells. Lasers used in surgery leave behind a sterile wound surface. These lasers are also able to kill bacteria, viruses and fungi. The tissues involved in the periimplant infection contain water, pigments and hydroxylapatite. In order to achieve adequate surface decontamination and good treatment outcome, the laser wave length should match the absorption potential of water, pigments and hydroxylapatite. Understanding the characteristics of absorption, we know that CO<sub>2</sub> and the Erbium lasers absorb highly in water, the diode laser in pigments and the Erbium in addition in hydroxylapatite. The three laser systems correspond to the necessity for new smaller instruments in order to decontaminate the implant surface.

The goals of the treatment of periimplantitis are:

- \_Elimination of the periimplant inflammation
- \_Stabilization of the bony attachment (levels of osseointegration).

In order to achieve these goals; the implant surface should be free of any foreign cells and toxins. Consequently, the tissue inflammation resolves and the host cells may contact and adhere to the surface again. Therefore what we really need is a decontamination and detoxification of the implant surface.

Classical cleaning methods require the use of curettes, ultrasonic devices or prophylaxis however, we already have seen that these methods have their limitations (Renvert, Lindhe 2008). Studies using Diode, CO<sub>2</sub> or Erbium lasers have shown their efficacy *in vitro* as well as *in vivo*. Decontamination of implant and tooth surfaces have been shown by Coffelt (1997), Kato (1998) and Hauser (2010). Romanos (2006) and Deppe (2001) reported successful clinical treatment of periimplantitis after CO<sub>2</sub> laser decontamination. Implant surfaces with calculus deposits can also be treated with Erbium

laser exhibiting better absorption in hydroxylapatite and water (Schwarz 2003, 2006, Sculean 2005).

Literature shows that the use of an adequate laser wave length may solve our problem of creating a surface which is accepted by the host cells. In addition the wave length of the Diode laser has an important biostimulative effects which supports the host actions on the long way to regeneration.

Based upon the classical systematic treatment plan, the laser actions support the decontamination, detoxification and biostimulation.

The classical concept of the periodontal treatment procedures is performed in four established phases:

- \_Hygiene phase (Initial phase)
- \_Evaluation
- \_Surgical phase
- \_Supportive phase (Maintenance phase).

With the advantage of absorption characteristics of lasers, using the appropriate laser and the correct dosage we know now that it is possible to treat infection. The cases which are presented in this paper were treated following this concept using the lasers in the four different treatment phases (Graph1).

As periimplantitis often occurs with untreated periodontal disease, a full mouth periodontal treatment is essential before (inserting implants) or attempting to successfully treat periimplant infections.

During the *Hygiene phase* (nonsurgical phase) the patient is instructed in adequate plaque control around the teeth and the implants. Plaque, supra and subgingival calculus are removed from the teeth with sharp curettes according to periodontal treatment protocols. The implant surfaces should be debrided under local anesthesia with carbon curettes and the inflamed periimplant tissue is curetted with sharp curettes. Finally, the pockets around the teeth and implants are rinsed with a sterile saline solution.

The first laser treatment is performed with a diode laser (810 nm, 2.5W, 50 Hz, 3 x 30 seconds). The laser decontamination procedure occurs by systematically moving the laser tip along the surface. The laser tip should be checked from time to time for coagulation in order to prevent hotspots in the gingival tissue. This procedure is performed

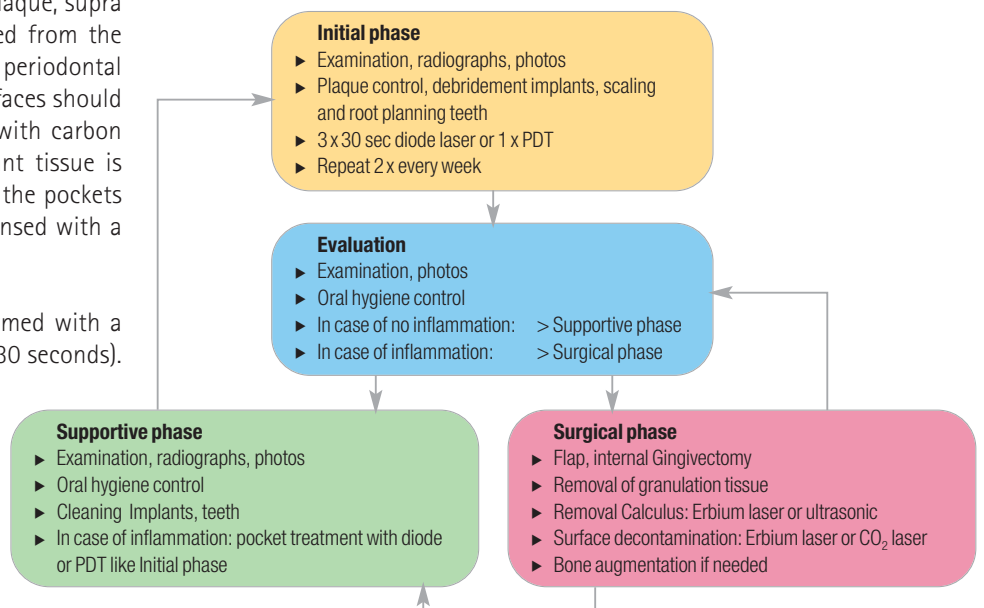
3 x 30 seconds in which the laser is alternately activated 2–3 seconds followed by 2–3 seconds of standby. Heat development should be avoided. Because of the high absorption of the diode laser in pigments, the effect is destruction of pigmented cells in close proximity and biostimulation of host cells in the surrounding tissue. The flexibility of the fiber allows for good access to the pockets. As opposed to diode laser, CO<sub>2</sub> or Erbium lasers are not useful in closed pockets, especially on implant surfaces with threads. The Diode decontamination is repeated twice weekly.

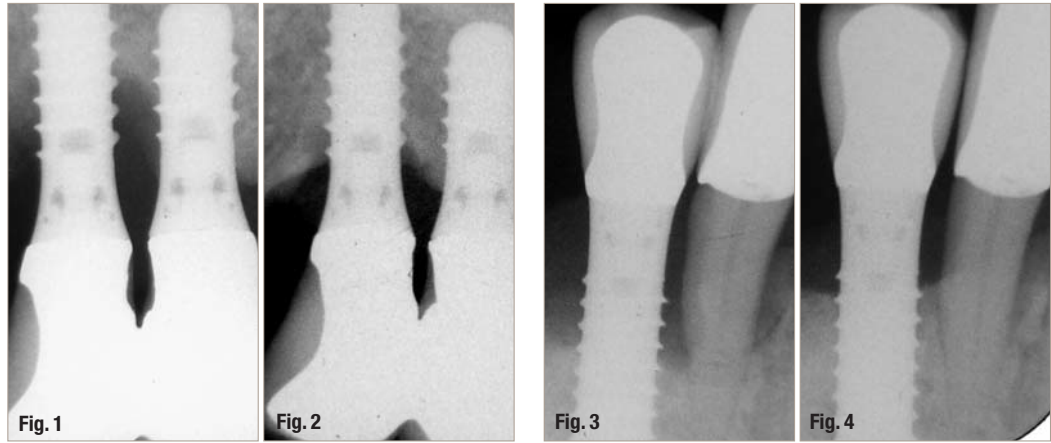
If there is no significant improvement after the third treatment (at week 2) a surgical intervention is planned (surgical phase). If clinical improvement can be noted, the patient is called back in 6–8 weeks for evaluation. The goal of the initial phase is the reduction of as much tissue inflammation as possible. The benefit of laser assisted debridement compared to a classical approach is the decontamination and the biostimulation.

An *evaluation* gives one the opportunity to record clinical parameters and oral hygiene status after initial treatment and to compare the periodontal situation with baseline. The patient can go into the supporting or maintenance phase when signs of improvement and reduction of inflammation can be noted. In case of persisting bleeding and pus formation a surgical laser assisted procedure should be planned.

Even if many periimplant lesions require surgical interventions it is important to start the treatment with the initial or hygiene phase in order to condition the tissues and reduce the inflammation around implants and teeth. As we know from peri-

Graph 1 \_ Protocol of the laser assisted periimplantitis treatment.





odontal treatment, it is possible to eliminate periodontal inflammation during the initial phase as long as we are able to remove plaque and calculus from the tooth surfaces. Accordingly, mucositis and moderate periimplantitis infection can be treated with laser assistance successfully using nonsurgical methods. Some cases treated non-surgically will be shown in the casuistic of this article.

The goal of the *supportive phase* is to gain full access to the implant surface for debridement, with the intent to remove calculus and to perform laser decontamination. At the same time, alveolar bone defects can be augmented when necessary. Surgical intervention is indicated in cases where the conditions around the implant failed to improve after initial phase, but plaque control is adequate, and there is a need to keep the contaminated implant.

It is helpful to remove the supra reconstruction of the implant in order to gain good access and keep as much soft tissue as possible to cover the area after surgery. The first incision is an internal gingivectomy, directed to the bony ridge, which separates the periimplant tissue from the mucosal flap. The flap is then raised to the level of the bony ridge gaining access to the entire implant surface. The

granulation tissue around the implant is carefully removed and the implant surface is inspected for calculus deposits. The bone defect is then exposed.

If calculus deposits are found, the implant surface is then carefully cleaned using an ultrasonic device at low settings. The 2 cases presented in this article were treated using the above procedure. Alternatively calculus removal and decontamination can be achieved with an Erbium laser. After checking the implant surfaces for residual deposits decontamination with the CO<sub>2</sub> laser is performed. The tip of the laser is systematically guided over the surface without contact. The settings are 2.5 W continuous wave (cw), (Deppe 2001), 10 sec. The area is rinsed with sterile saline solution and laser treatment is continued if needed. Avoid heating the implant. Bone augmentation is performed when necessary.

The goal of the *supportive phase* or recall is to maintain the treatment results long term. Regular examination of the soft tissues, plaque control, radiographs and minor local treatments are performed based upon the recall interval. If there is recurrence of minor inflammation around an implant the treatment with diode laser or antibacterial PDT is repeated. Graph 1 shows the protocol of the laser assisted periimplantitis treatment.

**Table I** Periimplantitis cases, bleeding on probing (BoP), pus, probing depth (PD), baseline and 2-4 years.  
T: Time (years) after treatment.  
AB: Antibiotics. diode laser and CO<sub>2</sub> laser were used as shown in Table 1.

| Case          | BoP/Pus | PD mm | Diode | CO <sub>2</sub> | AB | BoP/Pus | PD mm  | T years |
|---------------|---------|-------|-------|-----------------|----|---------|--------|---------|
| 1.124         | +       | 10    | +     | -               | +  | -       | 4      | 2       |
| 2.145         | +       | 9     | +     | -               | -  | -       | 3      | 2       |
| 3.124, 25, 26 | +       | 10-12 | +     | -               | -  | -       | max. 6 | 2       |
| 4.132, 42     | +       | 10    | +     | +               | -  | -       | 3      | 2       |
| 5.111         | +       | 11    | +     | +               | +  | -       | 3      | 4       |

## Casuistic

The following five clinical cases of periimplantitis were treated by the author following the presented treatment concept. In the initial phase the diode laser WhiteStar, 2.5 W (Orcos Medical AG, Switzerland) was used for decontamination and biostimulation. In both cases, which subsequently required open flap procedures (surgical phase), decontamination was performed with the CO<sub>2</sub> laser SpectraDenta with 2.5 W cw (Orcos Medical AG, Switzerland). Calculus removal in case 4 was performed with an ultrasonic device. The treatment in the supportive phase was performed with antibacterial photodynamic therapy (PDT) or the diode laser as needed. The results are shown in Table 1.

### Case 1 (Figs. 1 & 2)

Periimplantitis Implant 24: Treatment in 3 sessions, each with 3 x 30 sec using a diode laser, Flagyl 3 x 500 mg x 7, Evaluation, Recall. The radiographs show the situation at baseline and two years after therapy. No flap procedure was performed.

### Case 2 (Figs. 3 & 4)

Periimplantitis Implant 45 and severe chronic Periodontitis: Treatment in 3 sessions each 3 x 30 sec using a diode laser, scaling root planning of the teeth, Evaluation, Recall. No Antibiotics were administered. The radiographs show the situation at baseline and two years after therapy. No flap procedure was performed.

### Case 3 (Figs. 5 & 6)

Periimplantitis Implant 24, 25, 26 and severe chronic Periodontitis: Treatment in 3 sessions each 3 x 30 sec using a diode laser, scaling root planning of all teeth, Evaluation, Recall. No Antibiotics were administered. The radiographs show the situation at baseline and two years after therapy. No flap procedure was performed.

### Case 4 (Figs. 7–9)

Periimplantitis Implants 32, 42: Treatment in 3 sessions each 3 x 30 sec using a diode laser; at evaluation no success, therefore a surgical flap was raised, ultrasonic were used for calculus removal, decontamination with CO<sub>2</sub> laser. No Antibiotics were administered. The clinical situation at baseline, intraoperative and two years post treatment.

### Case 5 (Figs. 10–12)

Periimplantitis Implant 11: Treatment in 3 sessions each 3 x 30 sec using a diode laser, a surgical flap was raised, decontamination was performed with a CO<sub>2</sub> laser, as well as bone augmentation with BioOss and BioGide. Antibiotics were administered. The illustrations show the radiographic situation at

baseline, intra operative and four years after therapy.

## Discussion

The five cases presented were all treated following the laser assisted treatment protocol which was described above. The diode laser was used for the decontamination and biostimulation in the pockets (Initial phase) and the CO<sub>2</sub> laser was used in the surgical phase where the implant surfaces was nicely accessible. Much effort was put on oral hygiene instruction and plaque control around teeth and implants. All cases were treated successfully and showed stable conditions over two years. The lesions before treatment were advanced however, at least 50 % of the bone was still present around the implants. All patients were healthy and non-smokers. Antibiotics were administered in two cases; one of them because a simultaneous bone grafting procedure was performed. The periimplant infection had probably arisen from an untreated periodontitis or neglected maintenance care.

Cases 1–3 were treated primarily in the initial phase. The clinical conditions showed immediate improvement within the first two weeks after Diode laser application. The BoP was reduced, pus exudation ceased and the probing depths were reduced after two months. Thus no surgical phase was needed and patients went directly to the maintenance phase. The radiographs showed bone regeneration almost to the original level after two years. Accordingly, shallow probing depths were maintained and the bone attachment was stable. Since the wave length of the used diode laser (810 nm) has biostimulative properties, there is always an additional aspect of the energy which stimulates the proliferation of bone and soft tissue around the implant. Thus the diode laser is able to work on both sides of the lesion—on one side biofilm management and on the other side host management. In this manner, this wave length is beneficial to the tis-

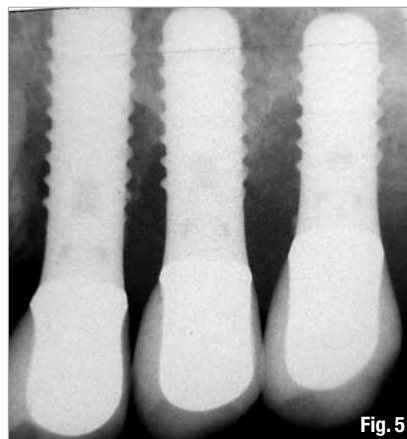


Fig. 5

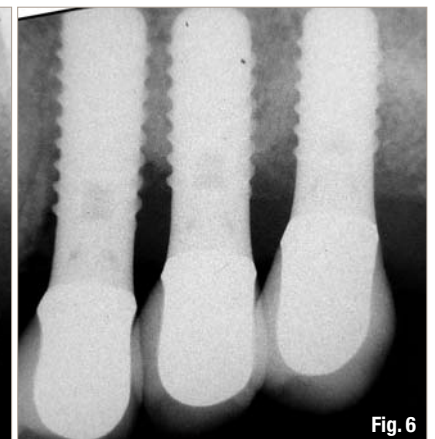
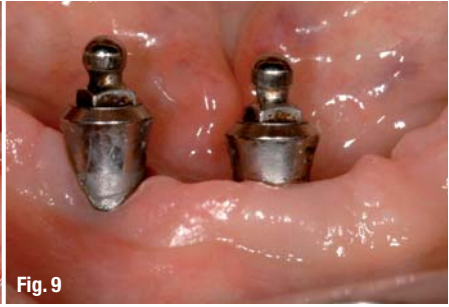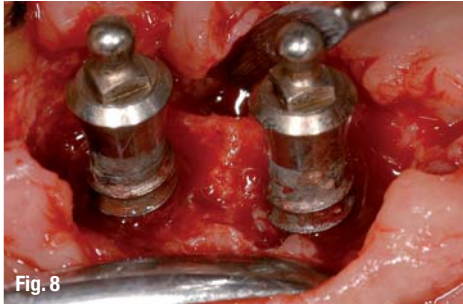

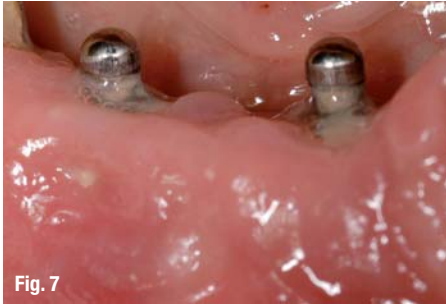
Fig. 6



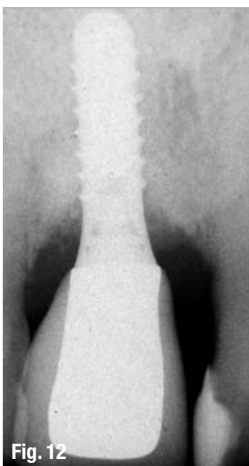
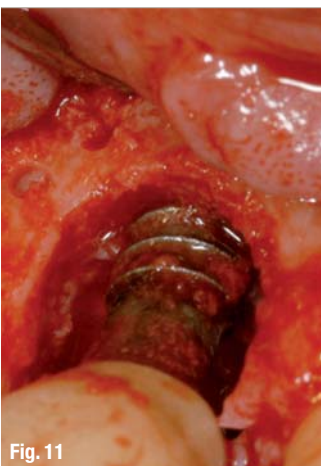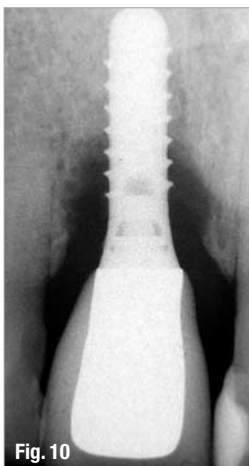
sue in order to bring the balance between tissue resorption and apposition to the right side. Studies have shown (Lindhe 2008) that periimplant lesions can only be treated by flap surgery. This may be true in the treatment protocol without laser. However, cases 1–3 show that nonsurgical treatments with the diode laser around implants are beneficial in that it actually kills bacteria below the host's critical mass and in turn stimulates cell proliferation. This may be a reasonable explanation for the nice bone regeneration seen in cases 1 to 3. However, keep in mind, this regeneration could only take place because the soft tissue was not opened and because the decalcified bony matrix around the implant was not removed. The applied laser energy regulated the balance in the tissue. The use of a Diode laser in the decontamination modus (no cutting) makes it possible to have additional beneficial effects than the classical treatment. Thus, it is always recommended to start the laser assisted treatment with the initial phase.

Treatment with the diode laser is not sufficient in all periimplantitis cases. In these cases there may be calculus or other deposits on the implant surface which cannot be removed performing closed therapy. If the lesion is advanced or the bony lesions should be augmented for esthetical reasons, then surgery is indicated. But even then it is of up most importance to complete first initial phase.

Cases 4 and 5 were treated with additional flap surgery. Case 4 showed no clinical improvement after the initial phase and was further treated surgically. The flap opening revealed large calculus deposits which were then removed with ultrasonic followed by decontamination with a CO<sub>2</sub> laser. This treatment made it possible to beam the energy systematically in a non-contact modus to the implant surface. Case 5 needed bone augmentation for esthetical reasons. There was no calculus found on the implant surface and the decontamination was performed with a CO<sub>2</sub> laser. A recent *in vitro* study (Hauser 2010) showed that a SLA implant surface can be decontaminated with a CO<sub>2</sub> Laser with the settings of (2.5W, cw) as used in this protocol. In the cases that required flap surgery the periimplant tissue received biostimulation from a low level laser (MED-700, 810 nm, 330 mW, Orcos medical AG, Switzerland) immediately after flap closure and one week after surgery.

It can be assumed that not only the bacterial load was reduced but also toxins were denaturated on the implant surface by the laser because all cases showed loss of the inflammation and proliferation of the tissue around the implant. This means that bacteria and toxin are well controlled through laser energy application. Moreover, the use of the laser rendered the implant surface biologically acceptable for host cells again. Consequentially proliferation of bone and soft tissue facilitated closure of the lesion. With this development, an important step in the treatment of periimplantitis is made.

As we know from the classical periodontal treatment the lesions should be treated as early as possible. This is even more important in regards to periimplant lesions because they tend to progress faster. The decontamination which is a limitation in the classical treatment on tooth and implant surfaces seems to be possible with the appropriate use of laser energy, and this can be successfully performed without opening a flap. This aspect makes it worthwhile to continue to pursue the idea of closed treatment of periimplant lesions. However, more (RCT) studies are needed to evaluate this protocol.



# implants

international magazine of oral implantology

## \_Summary

Epidemiologic Studies show an increase in Peri-implantitis. Without treatment implants are lost. As we know from the periodontal treatment protocol the surface of the implant must be decontaminated. What is difficult to perform on tooth surface is almost impossible on implant surface without the use of lasers. The mechanical methods for decontamination fail and clinical studies show that implant surfaces can be decontaminated with laser energy. This paper presents a treatment protocol which integrates laser energy for decontamination and biostimulation in the periodontal treatment concept. This concept puts more emphasis on the closed Initial phase where the diode laser is used for decontamination and biostimulation in contrast to studies which profess that periimplantitis always needs surgical interventions. Decontamination and biostimulation would be not possible using conventional methods.

The treatment begins with the initial phase including plaque control, debridement and decontamination of the implant surface, biostimulation with the diode laser (WhiteStar, Orcos Medical AG, Switzerland) and scaling and root planning as needed. Three cases with advanced periimplant lesions are presented with successful initial treatment. At time of evaluation, no pus, minor bleeding and pocket reduction was observed. After two years even bone regeneration was obvious. A surgical flap procedure was performed in order to gain access to the implant surface in cases where inflammation was still present at evaluation. The CO<sub>2</sub> laser (SpectraDenta, Orcos Medical AG, Switzerland) was used to decontaminate the implant surface. All treated cases showed no inflammation and stabilization of the bone attachment over two to four years. Even bone regeneration in non-surgical procedures was observed. The goal of the treatment which is to create a biological acceptable implant surface seems to be fulfilled with the use of appropriate laser energy.

*Editorial note: A list of references is available from the publisher.*

## \_contact

laser

### Dr med dent Gérald Mettraux

Periodontist in private practice  
Giessereiweg 9  
3007 Bern, Switzerland

mettraux@bluewin.ch  
www.mettrauxdent.ch



You can also subscribe via  
[www.oemus.com/abo](http://www.oemus.com/abo)

 **Subscribe now! One issue free of charge!**

I hereby agree to receive a free trial subscription of **implants international magazine of oral implantology** (4 issues per year). I would like to subscribe to **implants** for € 44 including shipping and VAT for German customers, € 46 including shipping and VAT for customers outside of Germany, unless a written cancellation is sent within 14 days of the receipt of the trial subscription. The subscription will be renewed automatically every year until a written cancellation is sent to OEMUS MEDIA AG, Holbeinstr. 29, 04229 Leipzig, Germany, six weeks prior to the renewal date.

▶ Reply via Fax +49 341 48474-290 to OEMUS MEDIA AG or per E-mail to: [grasse@oemus-media.de](mailto:grasse@oemus-media.de)

Last Name

First Name

Company

Street

ZIP/City/County

E-Mail

Signature

Notice of revocation: I am able to revoke the subscription within 14 days after my order by sending a written cancellation to OEMUS MEDIA AG, Holbeinstr. 29, 04229 Leipzig, Germany.

Unterschrift

OEMUS MEDIA AG  
Holbeinstr. 29, 04229 Leipzig  
Tel.: +49 341 48474-0  
Fax: +49 341 48474-290  
E-Mail: [grasse@oemus-media.de](mailto:grasse@oemus-media.de)