

Esthetic rehabilitation of anterior hypoplastic tooth using Er:YAG laser

Author_Dr Georgi Tomov, Bulgaria

Enamel hypoplasia (EH) is a defect in tooth enamel that results in less quantity of enamel than normal. The defect can be a small pit or can be widespread that the entire tooth is misshaped with affected mechanical properties.⁴ EH can occur on single or multiple teeth.⁶ It can appear white, yellow or brownish in color with a rough or pitted surface.^{6,8} In some cases, the quality of the enamel is affected as well as the quantity.⁸ Environmental and genetic factors that interfere with tooth formation are thought to be responsible for EH. This includes trauma to the teeth, infections during pregnancy or infancy, poor pre-natal and post-natal nutrition, hypoxia, exposure to toxic chemicals and a variety of hereditary disorders.⁶

Treatment of teeth with enamel hypoplasia must be determined on an individual basis. The enamel hypoplasia causes esthetic problems on anterior teeth resulting to psychological defects in young patients. Treatment for anterior teeth includes the following options:

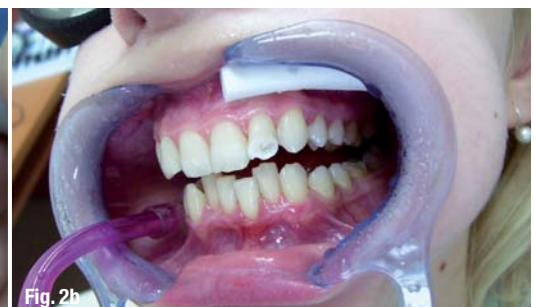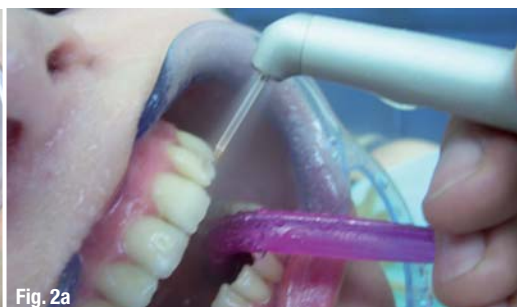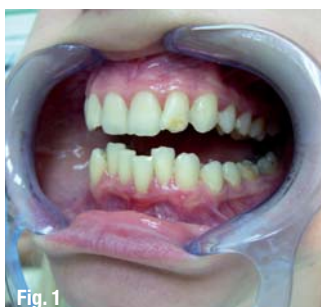- 1st: For sensitive teeth with no wear, applying of desensitizing agent (such as potassium nitrate) is needed.
- 2nd: If there are esthetic concerns, direct or indirect composite restorations, porcelain veneers or porcelain crowns may be bonded to the affected tooth after chemical etching.^{2,3,10}

Acid etching is widely used in clinical dentistry to facilitate the mechanical retention of resin-based materials to teeth, in particular enamel surfaces.^{2,3} For chemical etching the 37% phosphoric acid solution was the most effective, having produced the most consistent pattern of the enamel.¹¹ Enamel etching has a direct influence on the retention of the composite materials in adhesive dentistry. For etching it is possible to use phosphoric acid or other alternative methods such as air polishing, crystal growth, microretention with pressuring pumice and laser etching.^{1,5} Enamel etch by the acid can be complicated by the removal of surface, variability of penetration depth, and strong washing and drying affecting the bond strength.⁷

Etching of hypoplastic enamel

The successful bonding of resins to teeth may be very dependent on the response of the enamel to acid etching.⁹ Due to abnormal enamel the standard etching time and/or concentration of acid may not be appropriate for abnormal enamel.⁹ Studies have shown that the hypomineralized enamel did not exhibit the typical etching pattern seen in control enamel.^{7,9} Upon etching, there may be a uniform removal of hypomineralized enamel, rather than the differential etching patterns seen in the unaffected control enamel.^{7,9} This etching of a less

Fig. 1 _ Clinical appearance of the affected 22 tooth.
Figs. 2 a & b _ Laser preparation and etching with Er:YAG laser LiteTouch (Syneron, Israel) by "Hard tissue mode" (400 mJ/20 Hz; 8.00 W). View of air dried laser treated surface with "frosted" appearance.



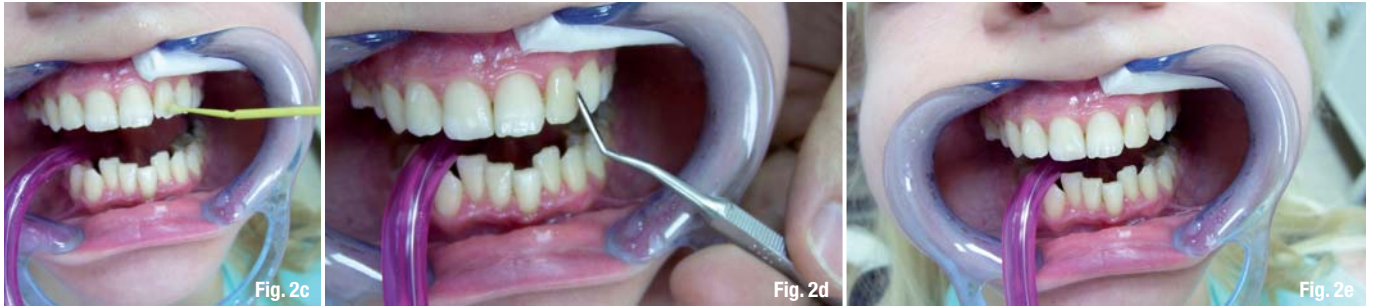

Fig. 2 c & d Adhesive agent application and final restoration view.

organized enamel structure may result in a pattern that is not the classic etched pattern, which may have a detrimental effect on bonding between the restorative/adhesive materials and the affected enamel.⁷ For that reason the dentist would like to find an alternative procedure for preparing the hypoplastic enamel. One of the effective methods may be to etch the hypoplastic enamel with Er:YAG lasers.

LiteTouch Er:YAG laser (Syneron, Israel) incorporates special software, which allows for the broadest range of energy and frequency settings. The unique LiteTouch optical system incorporated in the ergonomic handpiece prevents loss of energy and along with the precision control over pulse duration, pulse energy and repetition rate optimize, allows for a wide range of hard tissues procedures. Another characteristic of this laser is the wavelength (2,940 nm) which is absorbed mostly by the water and also sapphire tips, showing stability in providing focused energy of laser radiation. The mechanism of LiteTouch action is based on interaction between laser radiation and hard tissues incorporated water that results in microexplosions. It is believed that this process is the mechanism of ablating particles from dental tissues without overheating, and without smear layer formation.¹² This combination allows precise microinvasive cavity preparation with minimal heating and optimal rate of radiation absorption by the hydroxylapatite incorporated water.

The program "hard tissue mode" removes enamel, dentin and dental caries effectively and without visible carbonization or disturbance of the dental microstructure. Evaluated under SEM the dental tissues treated with LiteTouch Er:YAG laser showed rough and irregular surface without presence of smear layer.¹² Enamel shows preserved prismatic structure, but also strong retentions due to microexplosions on its surface.¹² The observed changes correspond to changes in hard dental tissues reported by other authors in previous studies on Er:YAG lasers.^{1,5} These results suggested Er:YAG lasers to be effective in treatment of hypoplastic enamel in order to avoid acid etching.

_ Case Report

16-years-old female patient was referred to the Clinic of Operative Dentistry and Endodontic, Faculty of Dental Medicine, Medical University, Plovdiv for examination. The patient had left lateral maxillary incisor with severely impaired esthetics and expressed lowered self-confidence. The Maxillary lateral incisors were asymmetric and discolored (Fig. 1).

The patient's history revealed trauma between the ages of 3 to 4. Therefore, the etiology of the existing pathology was associated with traumatic injury during enamel formation i.e. Turner's dysplasia. The patient was informed about the etiology of her complaint and treatment options were evaluated. The patient preferred a minimally invasive and esthetic treatment modality.

The treating team decided to restore the affected anterior tooth with the direct laminate technique using an adhesive bonding system and laser preparation and etching prior to restoration. Hypoplastic enamel and darkened dentin that may negatively affect the final esthetic appearance of the rehabilitation were removed, and suitable composite resin color was determined using the shade guides.

Preparation and etching was performed with LiteTouch Er:YAG laser (Syneron, Israel) for 10 seconds without anesthesia by "Hard tissue mode" (400 mJ/20 Hz; 8 W) (Figs. 2 a & b). The tooth was dried with air and primer (3M Scotchbond Multi-Purpose Primer; 3M ESPE, St. Paul, USA) was applied on the surfaces and spread-dried with an air spray for 20 seconds. Bonding agent (3M Scotchbond Multi-Purpose Adhesive; 3M ESPE, St. Paul, USA) was applied and polymerized with a light source for 10 seconds and increments of hybrid composite resin (Filtek Supreme; Body and Enamel, 3M ESPE, St. Paul, USA) were placed and light-polymerized for 40 seconds (Figs. 2 c & d). Finishing and polishing was accomplished with ultrafine diamond burs and composite rubber polishing burs. The final result corresponded to patient's esthetic expectations and no pain sensations during laser procedure was reported.




Fig. 3 a & b _The surface changes seen in the Er:YAG laser-etched enamel are non-uniform, but they result in a rough and porous surface (Magnification x 3,000). (Author's SEM photos archives).

_Discussion

The enamel hypoplasia causes esthetic problems on anterior teeth resulting to psychologic affect in young patients.¹⁰ This makes the problem urgent from psycho-social point of view. A great number of treatment modalities are known for the treatment of anterior teeth affected by the enamel hypoplasia.^{2,3,10} Tooth bleaching and microabrasion are non-invasive steps in achieving acceptable results in the removal of enamel stains and minor surface defects. When there is loss of tooth structure associated with defects, the use of composite resins produces excellent esthetic results and stable clinical longevity.

The traditional method for restoring hypoplastic areas is to prepare cavity and insert a restoration. Unfortunately, these techniques require cavity preparation with rotary instruments and additional acid etching procedures before placement. In this case report, the efficacy of a shortened method to restore hypoplastic tooth by using laser preparation and laser etching was presented.

This method would be particularly beneficial for patients with different enamel defects. Advantages of laser preparation and etching is the simplicity of use and short treatment time required to obtain retentive surfaces, without acid etching. This is important, because etching pattern of defective enamel is vague and has no resemblance to that of normal enamel.^{7,9} This could be due to difference in structure and composition of defective enamel. Seow W.K. and, Amaratunge⁹ suggested that variation of etching patterns could be due to differences in orientation of crystallites relative to the direction of attack together with differences in chemical composition between central and peripheral parts of enamel prisms. This explanation may highlight the variation in enamel structure that can occur not only between normal and defective enamel but also from tooth to tooth, or site to site, on a single tooth surface.¹¹ Also, variation of etching patterns for defective enamel could be a result of different etiology of the enamel defects in different teeth which is unknown.⁹ This variations may resulted in problems in bond strength.⁷

Variation of bond strengths between normal and defective enamel could be due to difference in etching patterns.⁷ In some cases, it could be due to bonding to exposed dentin rather than bonding to full enamel layer. The coefficient of variation of bond strength reported data are very high—47% and 59%.⁷ The high coefficient of variation suggests that the clinical classification of normal enamel does not predict in any specific manner that the composite will adhere better than when the enamel is classed as defective.

Different studies summarize the results of the interaction of Er:YAG laser radiation with the hard dental tissues.^{1,5,12} It has been demonstrated that the higher energy of Er:YAG laser radiation might etch very well the enamel.^{1,12} With proper cooling, the treated areas are clean without damage of the adjacent hard substances and without debris.¹² The Er:YAG laser produces minimal thermal damage to the pulp and surrounding tissues when used with water spray. Local anesthesia can be eliminated in most cases, which provides a more comfortable procedure for the patient. Surfaces prepared with Er:YAG laser LiteTouch are characterized by a rough and irregular topography without presence of smear layer (Figs. 3 a & b). Laser ablation procedures change enamel and the surfaces appeared strong retentive and suitable for adhesive restorations.

_Conclusion

Composite laminate technique should be considered the primary treatment option for enamel hypoplasia cases in an urgent attempt to improve the life quality of this group of patients. The Er:YAG laser preparation and etching at same time is easy to apply and allow to avoid any risks connected with acid etching. The time of preparation is acceptable and admitting that the laser preparation is painless, from the point of view of the patient it is beneficial. The initial results of this case-report have confirmed laser preparation to be a good alternative of acid etching for the esthetic rehabilitation of anterior teeth affected by enamel hypoplasia.

Editorial note: A list of references is available from the publisher.

_contact	laser
<p>Dr Georgi Tomov, PhD Department of Operative Dentistry and Endodontics, Faculty of Dental Medicine, Medical University, Plovdiv, Bulgaria</p>	