

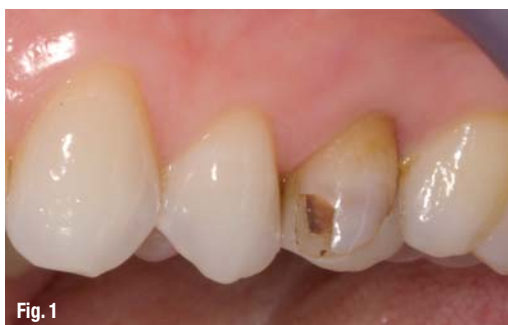# Computer-aided crown design

**Author\_** Dr Andreas Bindl, Switzerland

**\_CAD/CAM technology allows** dental professionals to manufacture solid all-ceramic crowns chairside. A digital image of the preparation is captured with an intra-oral camera and the crown is designed accordingly. A variety of ceramics are

(LS<sub>2</sub>) that demonstrates a flexural strength of 360 MPa. This ceramic is machined to the desired shape while it is still in its metasilicate or 'blue' state (approximately 130 MPa). Subsequently, the ceramic is crystallised for 20 minutes. During this process, the material attains its final state and develops its excellent mechanical and aesthetic properties.

**Fig. 1** Pre-op situation: The buccal wall of tooth #25 is cracked and features a large damaged composite filling, a clear indication for a crown.



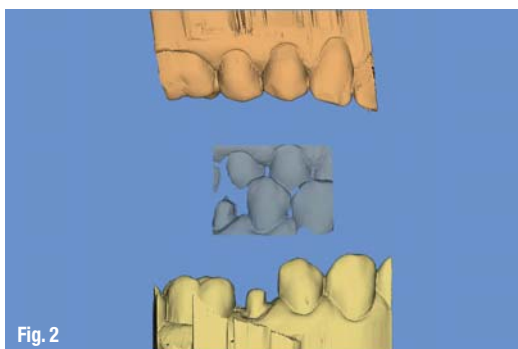
available for the construction of the crown, for example an aesthetic, easy-to-mill ceramic (IPS Empress CAD, Ivoclar Vivadent). As this leucite glass-ceramic is weaker than zirconium oxide, these crowns must be seated using the adhesive technique (for example with Syntac/Variolink II or Multilink Automix). This makes them strong enough to withstand the masticatory forces in the long term.

IPSe.maxCAD is available in a low-translucency (LT) version, which is suitable for the fabrication of crowns and implant-retained crowns. The high-translucency form is intended for the construction of inlays and partial crowns. The stains and glaze are applied before the crystallisation process. As a result, subsequent polishing is unnecessary. Owing to the high strength of the restoration, adhesive cementation with a separate dentine conditioner is not indicated as long as the thickness of the ceramic does not fall below 1.5 mm. Self-adhesive cementation materials can be used. The new self-adhesive composite cement SpeedCEM is particularly suitable for this purpose.

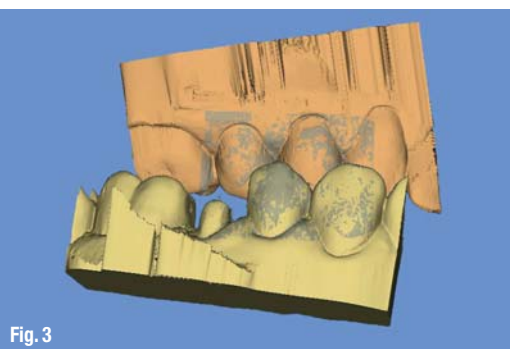
IPS e.max CAD, which has been on the market for some time, is a lithium-disilicate glass-ceramic

The chairside creation of a crown is described on the basis of a clinical case using IPS e.max CAD LT and the new SpeedCEM luting cement.

**Fig. 2** A digital impression is taken of the preparation, as well as the antagonists and the situation in centric occlusion (CEREC Bluecam, Sirona) from the buccal aspect (middle).

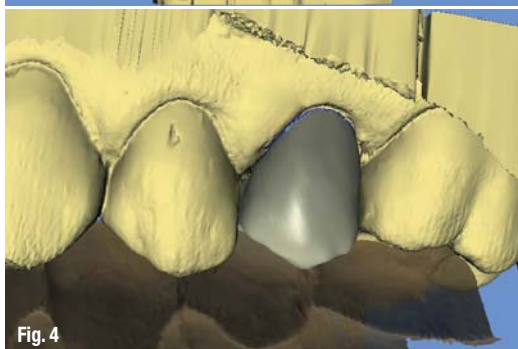


**Fig. 3**

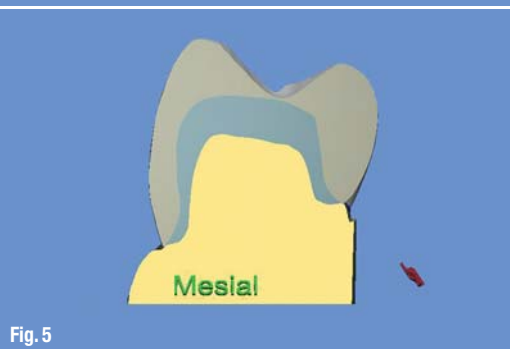

**Fig. 3** Semi-automatic alignment of the upper and lower jaw models with the help of the buccal image.

**Fig. 4** The biogeneric crown software designs an occlusal surface according to the individual situation.



**Fig. 5** Bucco-oral cross-section of the restoration. The minimum occlusal thickness of 1.5 mm is checked.



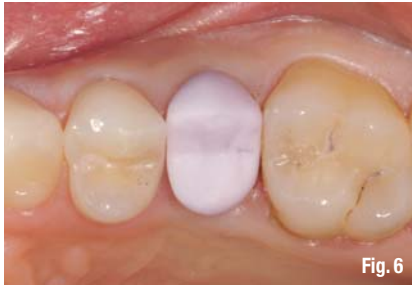

Fig. 6

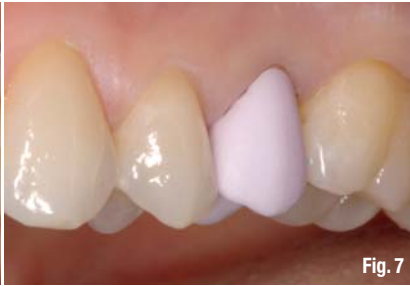

Fig. 7

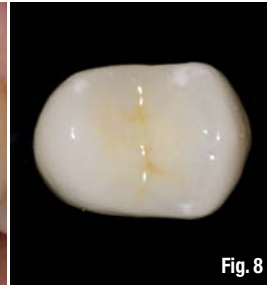


Fig. 8

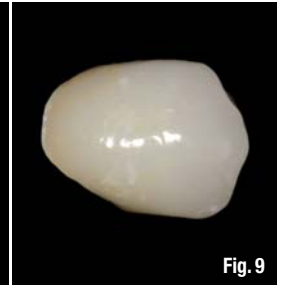


Fig. 9

## \_Clinical case study

Tooth #25 of a 32-year-old female patient was restored with a crown owing to extensive destruction of the dental hard tissue (Fig. 1). First, the tooth was prepared with a shoulder of approximately 1.0 mm in width (epigingivally). Subsequently, the preparation was dusted with IPS Contrast Spray and a digital impression was taken with the CEREC Bluecam camera (Sirona). The new CEREC software (version 3.80) generates a visual image of the an-

surfaces of the crown. The spray was applied several times. Once the restoration had been fully coated with a white-opaque glaze layer, the crown was fired in a combined crystallisation and firing process in the Programat CS furnace (Figs. 8 & 9). Before the restoration was cemented in place, the inner surface of the crown was etched with 4.9 % hydrofluoric acid (IPS Ceramic Etching Gel) for 20 seconds. Subsequently, it was silanised for 60 seconds (Monobond Plus). The crown lumen was filled with the self-adhesive SpeedCEM. Next, the

**Fig. 6**\_Occlusal view of the crown in the 'blue' state during try-in, before crystallisation firing.

**Fig. 7**\_Buccal view of the crown in the 'blue' state during try-in, before crystallisation firing.

**Fig. 8**\_Occlusal view of the crystallised and glazed crown on tooth #25.

**Fig. 9**\_Buccal view of the crystallised and glazed crown on tooth #25.

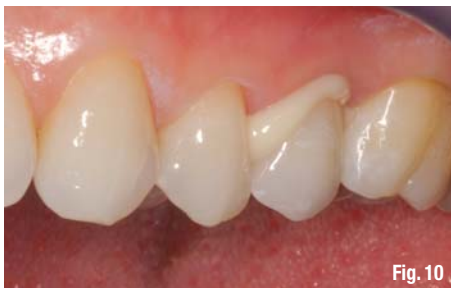

Fig. 10

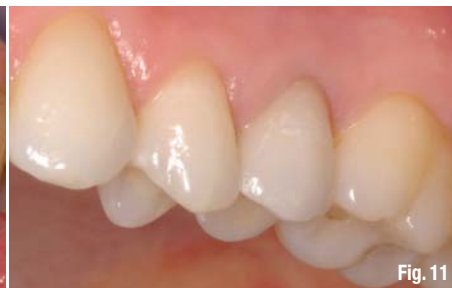

Fig. 11

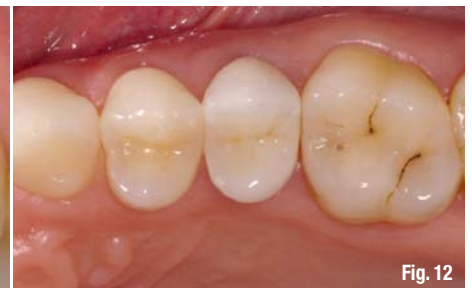

Fig. 12

tagonists, which replaces the centric bite record. In order to match the upper and lower teeth, an image of the centric situation is captured from the buccal aspect (Fig. 2). The upper and lower teeth are matched semi-automatically (Fig. 3). The 3.80 version is capable of designing biogeneric occlusal surfaces for full crowns. The software provides a design proposal for the tooth morphology, which is based on the occlusal surface of the distal neighbouring tooth and the antagonist (Fig. 4). The image of the bucco-oral cross-section of the crown allows the user to check the minimum occlusal thickness of 1.5 mm (Fig. 5). The minimal densification of the ceramic (0.2 vol%) during the crystallisation process is taken into account by the software and adjusted accordingly.

After the crown had been milled, the proximal and occlusal contacts were adjusted on the patient (Figs. 6 & 7). In this case, the 'white' and 'crème' materials from the corresponding stains assortment (IPS e.max CAD Crystall./Stains) were sparingly applied to the cusp tips and the 'sunset' material to the tooth neck and in the fissures. Immediately afterwards, a glaze in spray form (IPS e.max CAD Crystall./Glaze Spray) was applied to the outer

crown was securely seated on the prepared tooth by applying even pressure (Fig. 10). The cement residue was polymerised for one second per surface (mesio-oral, disto-oral, mesiobuccal, distobuccal) with a curing light (bluephase in the low-power mode) at a distance of about 5 mm. In this cured state, the cement was removed with great care using a scaler and a probe. The cement was fully cured with the bluephase in the high-power mode. Subsequently, the cement margin was polished. The final inspection revealed the restoration to be in harmony with the overall situation (Figs. 11 & 12).

**Fig. 10**\_Cementation of the crown with the dual-curing, self-adhesive luting composite SpeedCEM.

**Fig. 11**\_Buccal view of the crown seated with a self-adhesive luting cement after the clean-up of excess.

**Fig. 12**\_Occlusal view of the crown seated with self-adhesive luting composite.

## \_contact

## CAD/CAM



### Dr Andreas Bindl

Station für Zahnfarbene &  
Computer-Restaurationen  
Praxis am Zürichberg  
Attenhoferstrasse 8a  
8032 Zurich  
Switzerland

andreas.bindl@bluewin.ch