

Safety-first implant therapy

Authors_ Dr Neal S. Patel & Dr Jay B. Reznick, USA

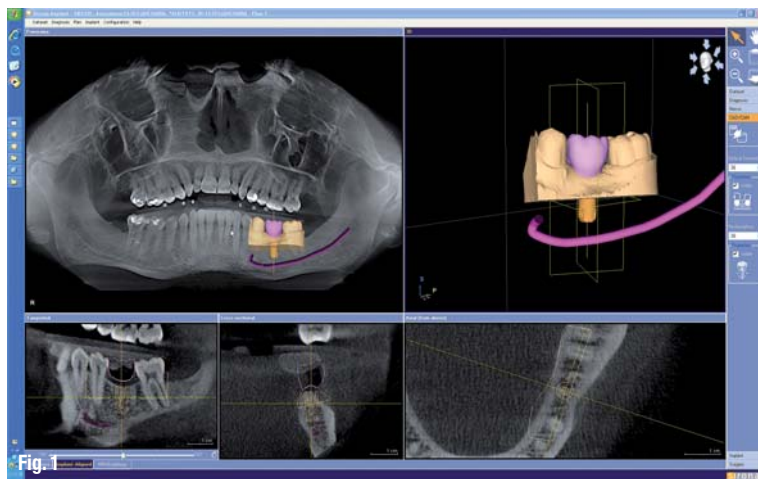


Fig. 1_3-D-scan of GALILEOS with imported CEREC crown.

_Cone-beam computerised tomography (CBCT) systems number amongst the most advanced imaging devices that are currently available on the market. The insight into the third dimension simplifies diagnostic procedures, enhances treatment safety and reduces radiation doses for patients. In addition, there are convincing forensic arguments in favour of CBCT. With the aid of 3-D CBCT images, users can interpret the clinical situation with much greater accuracy. They can evaluate the optimum drilling angles for various perspectives (sagittal, coronal, axial) and generate transversal slices and panoramic images. Compared with conventional CTs, CBCT systems are less sensitive to metal artefacts. Thanks to the availability of 3-D imaging, dentists are in a better position to assess the risks of treating certain cases in-house. In addition, CBCT users can create digital networks with their colleagues and advertise their services to referring dentists.

An important reason for purchasing a CBCT system is the time and effort involved in referring patients to external radiologists, both for the patient

and the dentist. In some cases, patients do not return after being referred. In addition, the diagnostic results are sometimes delayed and the reports are not directly assigned to the X-ray images. Referrals to external radiologists tend to disrupt the patient counselling process. Experience has shown that patients rate the expertise of a dental practice more highly when all services come from a single source and when the dentist is directly involved in the diagnosis of the X-rays. The higher costs of a CBCT image compared with a conventional panoramic X-ray can easily be justified by the clear diagnostic and therapeutic benefits. A convincing argument is that a CBCT contains 300 MB of information, compared with only 5 MB in the case of a digital panoramic X-ray.

Implant planning using GALILEOS and CEREC reduces the number of appointments. Less laboratory work is required. In most cases, it is not necessary to produce waxed-up prosthetic reconstructions. The combination of digital imaging and CAD generates all the necessary information for the dental laboratory, thus ensuring transparent working procedures. The decisive factor is that the integration of GALILEOS and CEREC streamlines the dentist's workflow and leads to reliable clinical results.

_Enhanced clinical reliability...

A very useful feature of the GALILEOS system is the built-in implant database, which contains the dimensional data of various commonly used endosseous posts (Astra, Straumann, BIOMET 3i, Bicon, BioHorizons and Z-look). By combining the GALILEOS image, the clinical CEREC scan and the virtual superstructure design, the user can dispense with a prosthetic wax-up model (Fig. 1). Instead, a template is used that is easily fixated in the patient's mouth (Fig. 2). The prosthetic planning is carried out fully

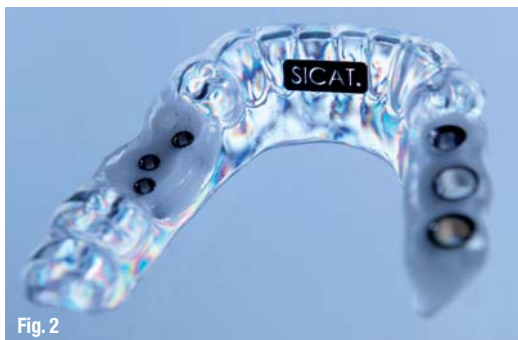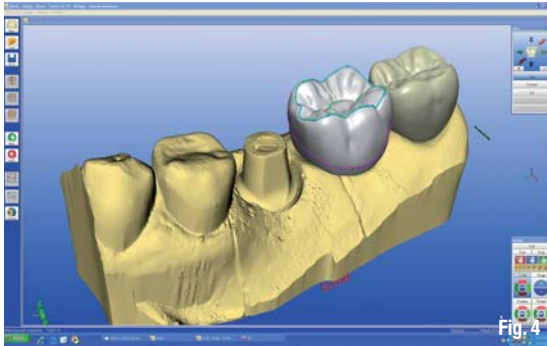


Fig. 2

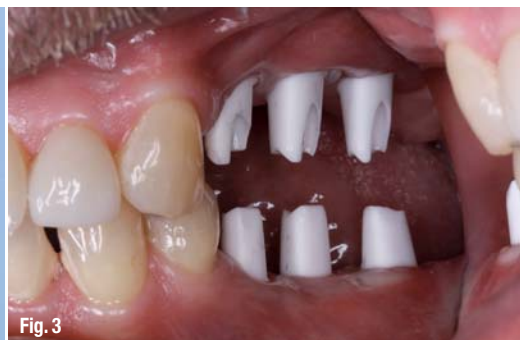
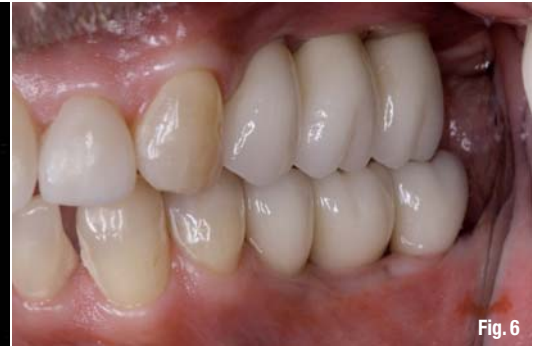
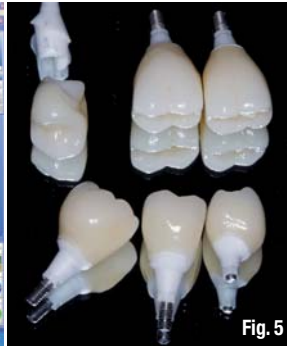Fig. 3

Fig. 2_SICAT surgery guide.
Fig. 3_Inserted ZrO₂ abutments.



digitally by using the CEREC software. Thereafter, the prosthetic planning data is imported into the CBCT scan, eliminating both the need to create an X-ray template and to form a barium-sulphate prosthetic model. This leads to results that are more precise. Moreover, since no barium sulphate is used, the CBCT image is of good quality. The positions of the endosseous drill holes are determined by means of plastic surgery guides (SICAT/Sirona). Minimally invasive flapless implantation eliminates the need for the elevation of the mucoperiosteal flap. This not only minimises surgical trauma, but also permits the immediate placement of the restoration on the implant.

...and less laboratory work

The ability to import the CEREC data into the CBCT image significantly streamlines the implant planning workflow. The interaction between GALILEOS and CEREC means that only two appointments are required, at an interval of five to seven days. Thanks to the surgery guide, the invasive surgical insertion of the endosseous post takes only 15 minutes, resulting in greater precision and reduced stress. Using the conventional method (that is, without a CBCT scan and surgery guide) each implant requires up to 45 minutes and is accompanied by greater risks.

Thus far, custom-made angled abutments with individual emergence profiles have often been required in order to compensate for divergences in the insertion angles between the implants and the superstructures. Thanks to the integrated implant planning process, it is now possible to deploy competitively priced, industrially prefabricated abutments (Fig. 3). The precise planning of the angulation in the CBCT image and the guided drilling process ensure a better fit between the endosseous post and the superstructure. If required, specially shaped abutments can be created out of zirconium oxide (ZrO₂) using the inLab system.

As a rule, the implants are luted directly to single-tooth implants. In order to protect the gingiva, overpressed luting residues must be carefully removed. Following the attachment of the abutment and the

closure of the screw access, it is advisable to place a retraction cord in order to expose the tissue and the abutment margin. The abutment is then conditioned with titanium powder in preparation for acquiring the intra-oral impression using the CEREC AC and designing the final implant crown (Fig. 4). The crown is then automatically milled to anatomical dimensions out of a lithium disilicate (LS₂) block (IPS e.max CAD, Ivoclar Vivadent). The try-in should be performed prior to crystallisation. This is followed by crystallisation, polishing/glazing and luting to the abutment (Fig. 5). If stringent aesthetic requirements have to be fulfilled (for example, in the anterior region) the LS₂ crown can be cut back and then individually veneered (Fig. 6).

Fig. 4 Screenshot of CAD construction for implant crowns.

Fig. 5 LS₂ crowns adhesively luted to the abutments.

Fig. 6 Implants with supra-structures *in situ*.

Conclusion

To a significant extent, GALILEOS and CEREC simplify implant planning and superstructure fabrication. The clinical outcomes are predictable. Compared with conventional methods, treatment is much faster. The 3-D images and the virtual prosthetic proposal play a valuable role in patient counselling. In addition, there is an increased likelihood that the patient will accept the plausibility of the proposed treatment and give his or her consent more quickly.

about the authors

CAD/CAM



Dr Neal S. Patel operates a dental practice in Powell, Ohio. He is a CEREC user, as well as an Advanced Trainer for the GALILEOS CBCT system.



Dr Jay B. Reznick runs a dental practice in Tarzana, California. He specialises in implantology, as well as tooth and skin transplants.