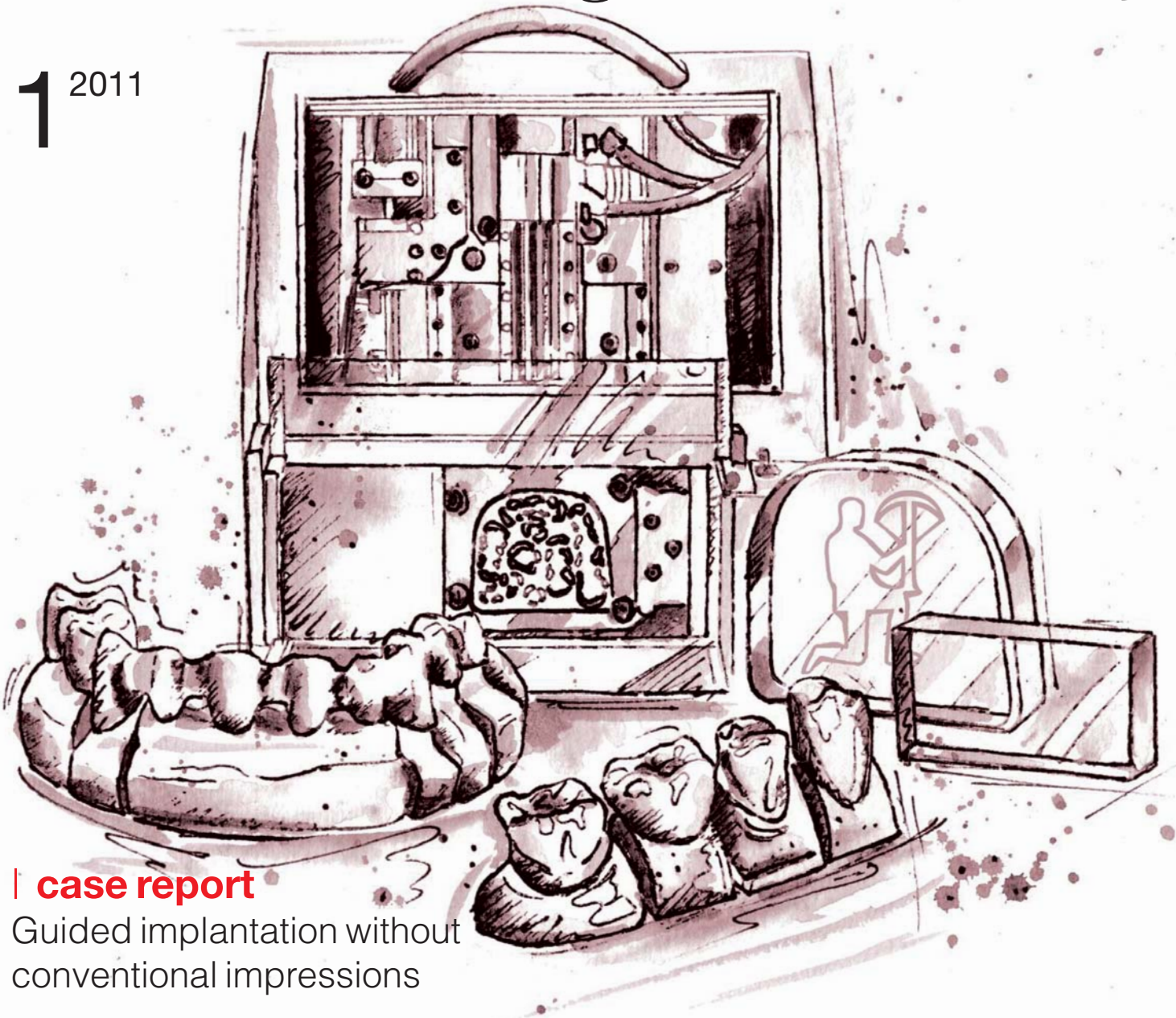


CAD/CAM

international magazine of digital dentistry

1 2011



| case report

Guided implantation without conventional impressions

| practice management

Six steps to a chartless practice

| industry report

Tizian CAD/CAM—No more one-way streets

IPS e.max[®]

**“THAT’S ALL
I NEED!”**

Galip Gürel, Dentist, Turkey.

Many different indications and many different materials to choose from – this scenario is a thing of the past. The IPS e.max system allows you to solve all your all-ceramic cases, from thin veneers to 12-unit bridges. Dental professionals all over the world are delighted.

all ceramic
all you need



www.ivoclarvivadent.com

Ivoclar Vivadent AG

Bendererstr. 2 | FL-9494 Schaan | Principality of Liechtenstein | Tel.: +423 / 235 35 35 | Fax: +423 / 235 33 60

ivoclar
vivadent[®]
passion vision innovation

Dear Reader,

Dental CAD/CAM technology has recently undergone enormous development. At the moment, it is the most innovative segment in dentistry and will again be the focal point of this year's International Dental Show (IDS), where plenty of manufacturers are going to showcase new systems and CAD/CAM solutions. While dental technology was the primary focus in the past, developers are now also looking at the manner in which these technologies can be applied to the dental practice. Digital impressions play a key role in this process. Manufacturers are currently making large investments in this technology and are thus able to constantly introduce new innovations. In this particular field—handheld systems for precise 3-D surface measurements—dentistry is the forerunner of all other engineering sciences, a fact that acknowledges the pioneer achievement of these developments.

While there was a level of caution with regard to the accuracy of full jaw scans, new clinical studies and trials confirm that intra-oral, 3-D systems now produce results that are almost comparable to conventional impression methods. In addition, handling and integration into the practice workflow have been developed to such a degree that these systems can now be used for the treatment of dental patients. Further examples are functional diagnostics with virtual articulators, implant treatment planning through the combination of DVT data and intra-oral scans that allow for chairside production of surgical guides, as well as facial scans serving as a base for a secure prosthetic planning.

However, CAD/CAM technology is not limited to the fabrication of dental restorations. Computerised dentistry is now also influencing other fields in dentistry, such as diagnostics, 3-D assessment and digital storage. Owing to these developments, complex approaches have become simplified and can better be integrated into the daily practice—all for the benefit of the patient. As a result of these new developments, which offer completely new opportunities for the daily workflow of the dental practice, dentists will have to become acquainted with these new technologies. Only well-educated dentists and dental technicians are able to assess the differences between the available systems and technologies. Just as studying material science enables confident handling of different materials, the basics of computerised dentistry must find their way into the dental curriculum. The upcoming IDS will prove that the time is ripe!

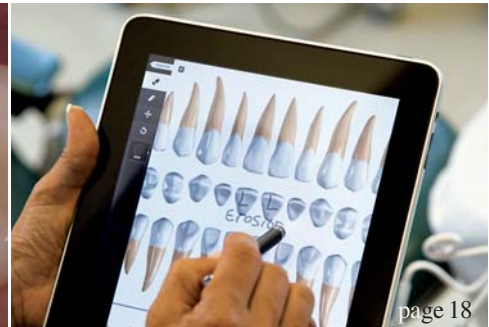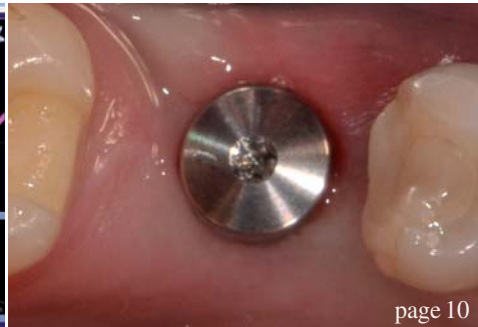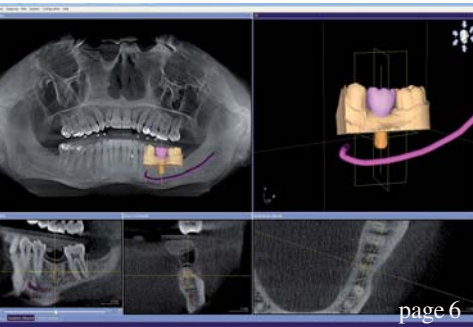
Yours faithfully,



Prof Albert Mehl
Center of Dental Medicine
University of Zurich



Prof Albert Mehl



| editorial

03 **Dear Reader**
| Prof Albert Mehl, Guest Editor

| opinion

06 **Safety-first implant therapy**
| Dr Neal S. Patel & Dr Jay B. Reznick

08 **25 years of proven clinical performance**
| Dr Dennis J. Fasbinder

| case report

10 **Guided implant placement** without conventional impressions
| Dr Jan-Frederik Güth *et al.*

| practice management

14 **Six steps to a chartless practice**
| Dr Lorne Lavine

| news

18 **iPad in business: Advancing digital dentistry**
| Apple Inc.

| feature

20 An interview with **Hermann Loos**

| industry report

24 **For a perfect fit—CAD/CAM bar restoration on XiVE implants**
| Björn Roland & Dr Peter Gehrke

30 **From the patient's perspective: Design, implementation and prosthetics**
| Dr Götz Grebe & Dr Melanie Grebe

38 **Computer-aided crown design**
| Dr Andreas Bindl

40 **No more one-way streets**
| Thomas Dürr

| industry news

42 **ZENOTEC easy—Cost effective and professional**
| WELAND

43 **Sensible Dental gets its IPS e.max on!**
| Sensible Dental

44 **3Shape releases Dental System 2010**
| 3Shape

45 **R-SI-LINE METAL-BITE—Perfect bite registration**
| R-dental

46 **NewTom VGi adds variable FOV feature**
| ImageWorks

47 **White Peaks Dental Systems**
| White Peaks

| meetings

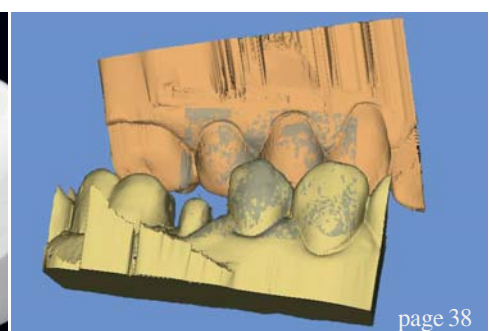
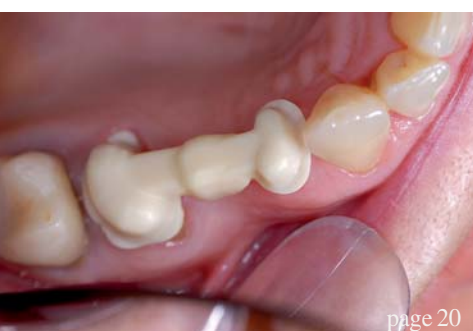
48 **International Events**

| about the publisher

49 | submission guidelines
50 | imprint



Cover image courtesy of Schütz Dental GmbH, www.schuetz-dental.de.





WHITE PEAKS

DENTAL SYSTEMS

White Peaks Dental Systems

your specialist for zirconium blanks – Made in Germany – exclusively made from raw materials of Tosoh – Japan.

Zirconium colouring liquids in 16 classic shades, chrome-cobalt, titanium, CEC-certified PMMA blanks, PMMA and wax blanks, Calidia CAD/CAM milling systems, free CAM software and scanners.

We are certified to the highest standards of CEC, US-FDA and DIN ISO 13485



34. Internationale Dental-Schau
34th International Dental Show
COLOGNE, 22. – 26.3.2011

Besuchen Sie uns!
Visit us!
Hall: 11.1 / Aisle: A
Stand: 059

White Peaks Dental Systems GmbH & Co. KG,
Langeheide 9, D-45239 Essen, Germany
www.white-peaks-dental.com
info@white-peaks-dental.com



Safety-first implant therapy

Authors_ Dr Neal S. Patel & Dr Jay B. Reznick, USA

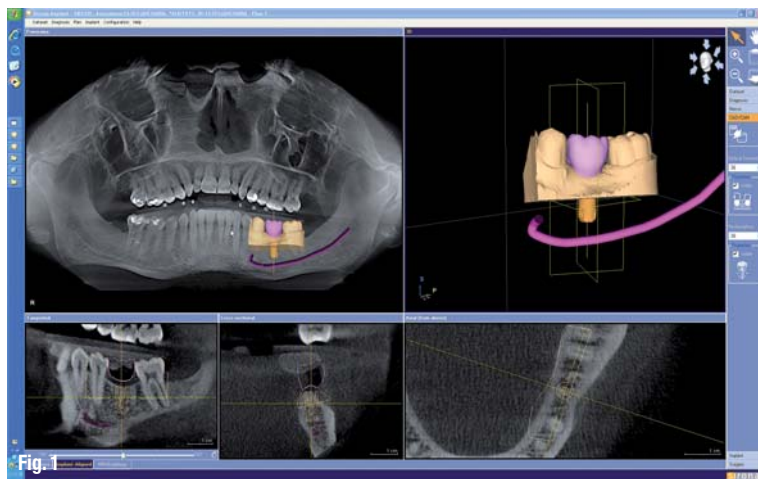


Fig. 1_3-D-scan of GALILEOS with imported CEREC crown.

_Cone-beam computerised tomography (CBCT) systems number amongst the most advanced imaging devices that are currently available on the market. The insight into the third dimension simplifies diagnostic procedures, enhances treatment safety and reduces radiation doses for patients. In addition, there are convincing forensic arguments in favour of CBCT. With the aid of 3-D CBCT images, users can interpret the clinical situation with much greater accuracy. They can evaluate the optimum drilling angles for various perspectives (sagittal, coronal, axial) and generate transversal slices and panoramic images. Compared with conventional CTs, CBCT systems are less sensitive to metal artefacts. Thanks to the availability of 3-D imaging, dentists are in a better position to assess the risks of treating certain cases in-house. In addition, CBCT users can create digital networks with their colleagues and advertise their services to referring dentists.

An important reason for purchasing a CBCT system is the time and effort involved in referring patients to external radiologists, both for the patient

and the dentist. In some cases, patients do not return after being referred. In addition, the diagnostic results are sometimes delayed and the reports are not directly assigned to the X-ray images. Referrals to external radiologists tend to disrupt the patient counselling process. Experience has shown that patients rate the expertise of a dental practice more highly when all services come from a single source and when the dentist is directly involved in the diagnosis of the X-rays. The higher costs of a CBCT image compared with a conventional panoramic X-ray can easily be justified by the clear diagnostic and therapeutic benefits. A convincing argument is that a CBCT contains 300 MB of information, compared with only 5 MB in the case of a digital panoramic X-ray.

Implant planning using GALILEOS and CEREC reduces the number of appointments. Less laboratory work is required. In most cases, it is not necessary to produce waxed-up prosthetic reconstructions. The combination of digital imaging and CAD generates all the necessary information for the dental laboratory, thus ensuring transparent working procedures. The decisive factor is that the integration of GALILEOS and CEREC streamlines the dentist's workflow and leads to reliable clinical results.

_Enhanced clinical reliability...

A very useful feature of the GALILEOS system is the built-in implant database, which contains the dimensional data of various commonly used endosseous posts (Astra, Straumann, BIOMET 3i, Bicon, BioHorizons and Z-Look). By combining the GALILEOS image, the clinical CEREC scan and the virtual superstructure design, the user can dispense with a prosthetic wax-up model (Fig. 1). Instead, a template is used that is easily fixated in the patient's mouth (Fig. 2). The prosthetic planning is carried out fully

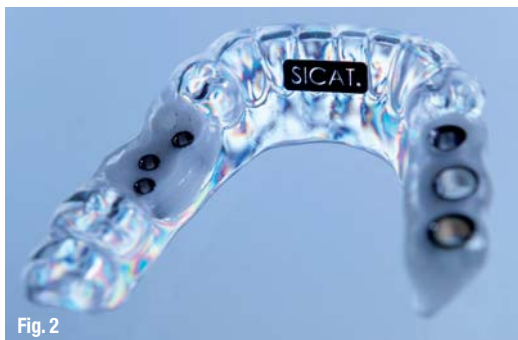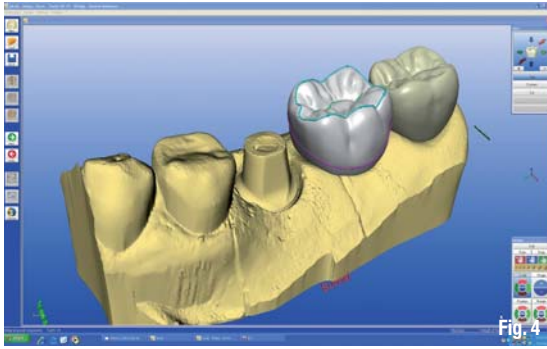


Fig. 2

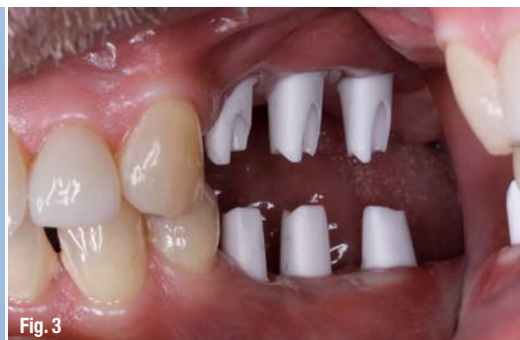
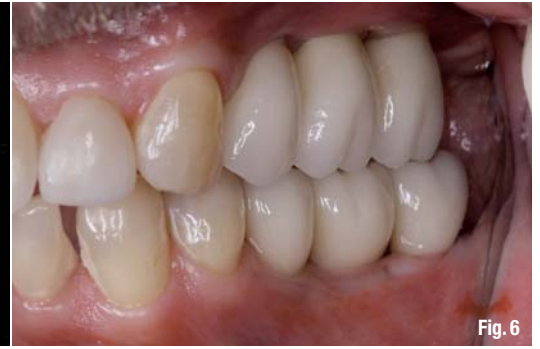
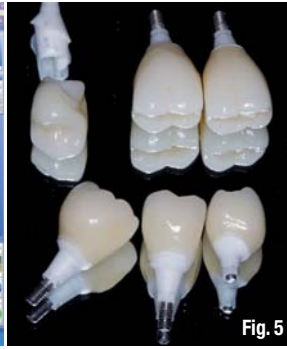Fig. 3

Fig. 2_SICAT surgery guide.
Fig. 3_Inserted ZrO₂ abutments.



digitally by using the CEREC software. Thereafter, the prosthetic planning data is imported into the CBCT scan, eliminating both the need to create an X-ray template and to form a barium-sulphate prosthetic model. This leads to results that are more precise. Moreover, since no barium sulphate is used, the CBCT image is of good quality. The positions of the endosseous drill holes are determined by means of plastic surgery guides (SICAT/Sirona). Minimally invasive flapless implantation eliminates the need for the elevation of the mucoperiosteal flap. This not only minimises surgical trauma, but also permits the immediate placement of the restoration on the implant.

...and less laboratory work

The ability to import the CEREC data into the CBCT image significantly streamlines the implant planning workflow. The interaction between GALILEOS and CEREC means that only two appointments are required, at an interval of five to seven days. Thanks to the surgery guide, the invasive surgical insertion of the endosseous post takes only 15 minutes, resulting in greater precision and reduced stress. Using the conventional method (that is, without a CBCT scan and surgery guide) each implant requires up to 45 minutes and is accompanied by greater risks.

Thus far, custom-made angled abutments with individual emergence profiles have often been required in order to compensate for divergences in the insertion angles between the implants and the superstructures. Thanks to the integrated implant planning process, it is now possible to deploy competitively priced, industrially prefabricated abutments (Fig. 3). The precise planning of the angulation in the CBCT image and the guided drilling process ensure a better fit between the endosseous post and the superstructure. If required, specially shaped abutments can be created out of zirconium oxide (ZrO₂) using the inLab system.

As a rule, the implants are luted directly to single-tooth implants. In order to protect the gingiva, overpressed luting residues must be carefully removed. Following the attachment of the abutment and the

closure of the screw access, it is advisable to place a retraction cord in order to expose the tissue and the abutment margin. The abutment is then conditioned with titanium powder in preparation for acquiring the intra-oral impression using the CEREC AC and designing the final implant crown (Fig. 4). The crown is then automatically milled to anatomical dimensions out of a lithium disilicate (LS₂) block (IPS e.max CAD, Ivoclar Vivadent). The try-in should be performed prior to crystallisation. This is followed by crystallisation, polishing/glazing and luting to the abutment (Fig. 5). If stringent aesthetic requirements have to be fulfilled (for example, in the anterior region) the LS₂ crown can be cut back and then individually veneered (Fig. 6).

Fig. 4 Screenshot of CAD construction for implant crowns.

Fig. 5 LS₂ crowns adhesively luted to the abutments.

Fig. 6 Implants with supra-structures *in situ*.

Conclusion

To a significant extent, GALILEOS and CEREC simplify implant planning and superstructure fabrication. The clinical outcomes are predictable. Compared with conventional methods, treatment is much faster. The 3-D images and the virtual prosthetic proposal play a valuable role in patient counselling. In addition, there is an increased likelihood that the patient will accept the plausibility of the proposed treatment and give his or her consent more quickly.

about the authors

CAD/CAM



Dr Neal S. Patel operates a dental practice in Powell, Ohio. He is a CEREC user, as well as an Advanced Trainer for the GALILEOS CBCT system.



Dr Jay B. Reznick runs a dental practice in Tarzana, California. He specialises in implantology, as well as tooth and skin transplants.

25 years of proven clinical performance

Author_Dr Dennis J. Fasbinder, USA

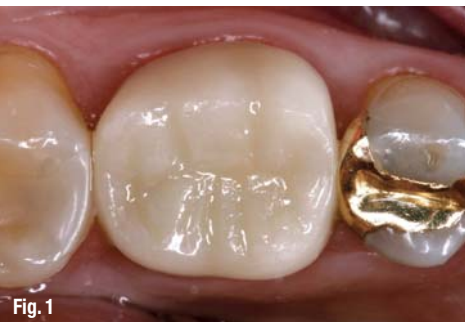

Fig. 1

Fig. 1 LS₂ crowns after the two-year recall visit.

In 1985, Prof Werner Mörmann, Dr Marco Brandestini and their team laid the foundations for a new treatment system consisting of optical impression-taking, CAD and numerically controlled milling. This new concept motivated large numbers of clinicians and prompted them to carry out their own follow-up investigations. Today, CEREC is one of the most closely scrutinised dental procedures, a fact reflected in more than 250 clinical studies and approximately 6,500 longitudinal studies of restorations.

Long-term observations indicate that adhesively bonded restorations fabricated using the first versions of the CEREC system (CEREC 1 and 2) achieved higher survival probability rates (according to Kaplan–Meier) than conventional layered ceramic restorations. CEREC restorations with service times in excess of 20 years still display a degree of clinical excellence, which is normally attributed to metal-based restorations. On the basis of this extensive long-term experience, there are convincing reasons for recommending CEREC-fabricated inlays, onlays, partial crowns, veneers, anterior crowns and posterior crowns as an alternative to conventional metal-based restorations.

Immediate treatment stabilises enamel

The goal was to deploy CAD/CAM technology to create immediate all-ceramic restorations chairside without the need for temporaries. Clinical experience has demonstrated that provisionally restored inlay cavities have a significant, negative influence on the integrity of the enamel. In the course of chewing simulations, cracks occurred in the oral and vestibular enamel surfaces. In addition, spalling was observed at the enamel margins. Such defects did not occur in cavities that had been treated immediately using chairside CEREC inlays. The conclusion was clear: the immediate treatment of the tooth cavity with chairside inlays and the elimination of the need for a temporary restoration reduce the risk of enamel cracking and marginal spalling. The micromechanical bond between the ceramic inlay and the hard tooth

tissue stabilises the cavity walls. In combination with the adhesive bond, the stabilising effect of the immediate CEREC restoration on the residual tooth obviously offsets the consequences of wider adhesive gaps, as evidenced in long-term clinical findings.

High-strength CEREC crowns

So far, long-term investigations have concentrated almost exclusively on CEREC crowns made of feldspar ceramic materials. At the School of Dentistry, University of Michigan, we set out to investigate the material suitability of lithium disilicate (LS₂, IPS e.max CAD, Ivoclar Vivadent) for full contour, monolithic crowns. Our aim was to utilise the enhanced flexural strength of LS₂ (360–400 MPa) in order to withstand the chewing forces in the premolar and molar regions. The full crown preparation included 2.0 mm functional cusp reduction, 1.5 mm occlusal reduction in the central fissure in combination with rounded shoulders and axial reduction of 1.2 mm. Using the CEREC 3 system, 62 crowns were created for 43 patients and then placed with the aid of dual-cure luting cement. There was a small degree of sensitivity reported in the first week post-operatively. This had subsided by the third week and there were no reports of sensitivity at the one- or two-year recall evaluation. After two years of clinical service, there were no clinically identified cases of crown fracture or surface chipping. Clinical monitoring revealed a positive long-term survival prognosis. Although two years *in situ* is a relatively short period of time, the survival rates are on par with those obtained in similar studies of ceramic crowns (Fig. 1).

about the author

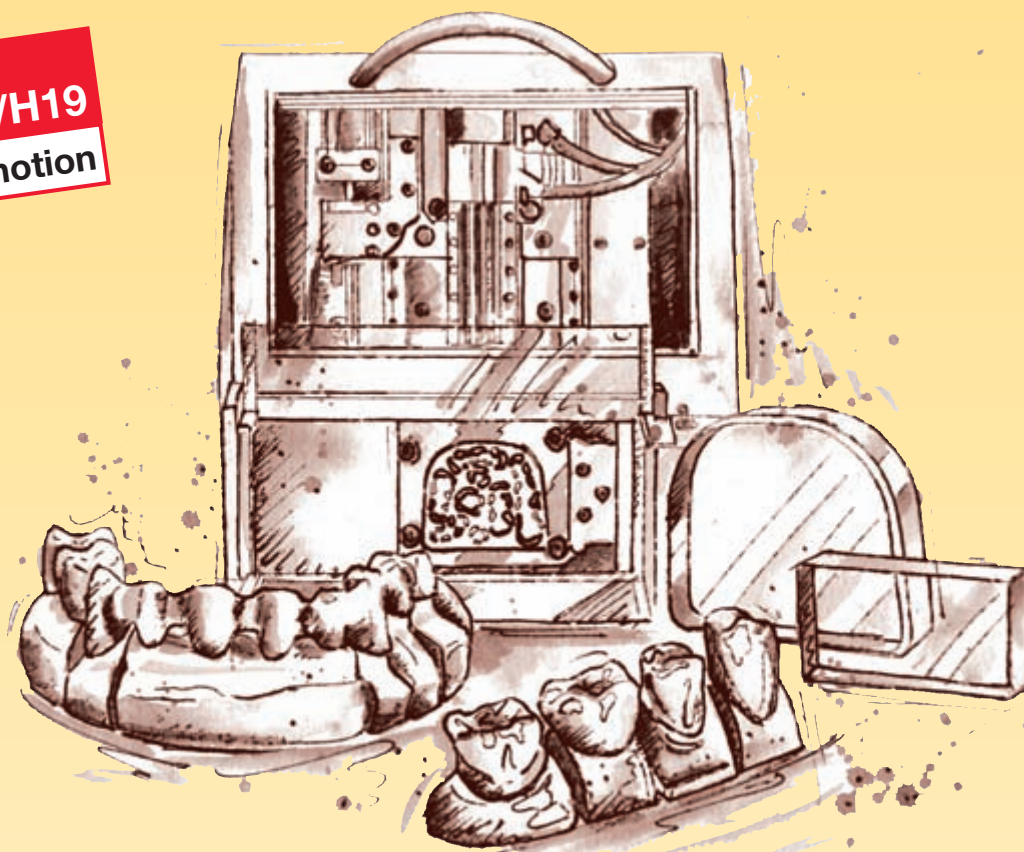

CAD/CAM



Dr Dennis J. Fasbinder is Clinical Professor in the Department of Cariology, Restorative Sciences and Endodontics at the University of Michigan.

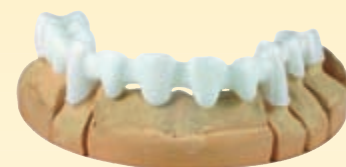

IDS hall 10.1
booth G10/H19
Visit us for special promotion



CAD/CAM - The right solution for you

Smaller, faster, better



Tizian™ Scan 102

- highly precise scan results
- works with virtual articulator

Tizian™ Creativ RT

- fast & easy CAD
- abutment designer
- exporting open STL data

Tizian™ Cut Eco plus

- 4 axes milling
- „Jäger” spindle

For more information, please visit our homepage
www.schuetz-dental.de
or request our catalog!



German Quality

Guided implant placement without conventional impressions

Authors_ Dr Jan-Frederik Güth, Dr Florian Beuer & Prof Daniel Edelhoff, Germany

Fig. 1_ Single missing tooth #36, inadequate fillings of teeth #35 and 37.

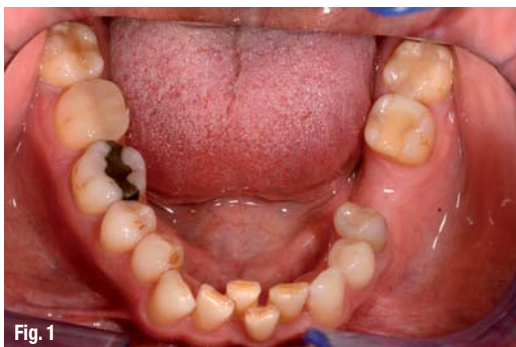

Fig. 1

Fig. 2_ Radiographic template with bite registration material.

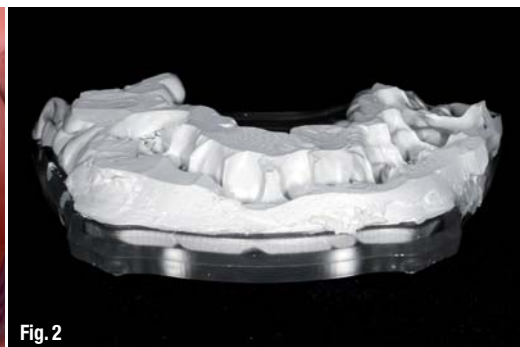

Fig. 2

Today, digital dentistry and CAD/CAM technology are widely used in dentistry, particularly in the field of implantology. While the last decade was entirely dominated by the CAD/CAM-supported fabrication of dental restorations, digital impressions have attracted increasing attention amongst dental surgeons and technicians in the last few years.^{1,2}

relied on conventional impressions. However, in recent years it has been possible to capture the clinical situation with digital impressions using intra-oral scanners, which may replace the conventional method for several indications.

Fig. 3_ CAD data of the designed crown based on an intra-oral scan with CEREC AC Bluecam.

Fig. 4_ Virtual model of the maxilla and the mandible.

Figs. 5a & b_ Intra-oral scan data (SSI) and 3-D X-ray data (DICOM) before fusion.

Prosthetic-oriented planning of the implant position meets the standard in implantology. Previously, this type of backward planning and subsequent navigated implant placement

In the following case study, information on the clinical situation was captured using intra-oral digital imaging. A virtual crown was designed chairside. The CAD data was combined with data obtained from CBCT. Based on optical scan, virtual crown and 3-D X-ray data, implant planning took place and the information was translated into a corresponding surgical guide.

The present case study outlines the steps based on the example of an implant in region 36 using the implant planning software SICAT Implant, the optical scanner CEREC AC Bluecam and DICOM data obtained from a GALILEOS 3D System (both Sirona).

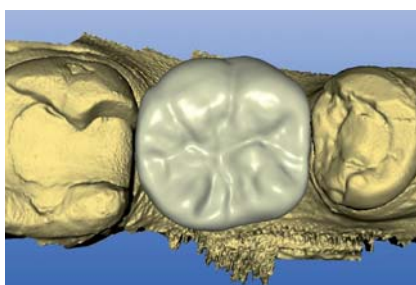


Fig. 3

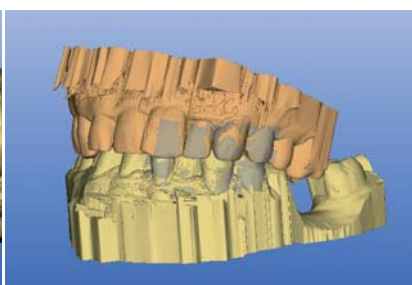


Fig. 4



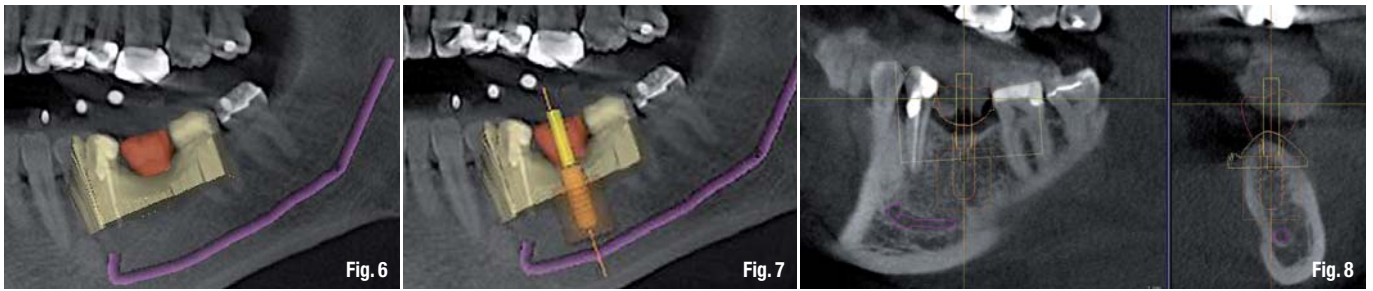
Fig. 5a

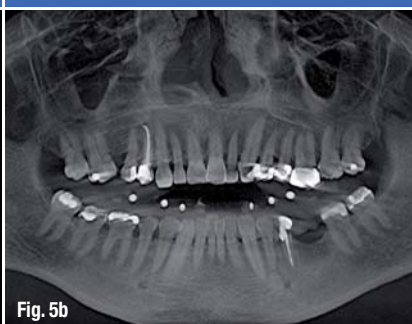

Fig. 5b

_Case presentation

The patient was referred to the Department of Prosthetic Dentistry of the Ludwig Maximilian University in Munich (LMU) after extraction of tooth #36. After an extensive case history had been taken, possible treatment alternatives were discussed. The patient opted for an implant-supported crown in region 36 along with further prosthetic work (inlay on teeth #35 and 37). Figure 1 shows the condition of the lower



jaw before treatment. The patient categorically turned down any augmentation.

Owing to the patient's strong pharyngeal (gag) reflex and the desire for the highest possible level of safety, short incapacity periods and minimal restrictions during and after implantation, the restorative team in consultation with the patient opted for backward planning, combining intra-oral scanning and CBCT.

Method

1. 3-D X-ray imaging using CBCT: A 3-D X-ray scan was taken with GALILEOS CBCT. For future referencing, a standardised radiographic template (SICAT) was used during the X-rays scan. The template with radiographic markers was fixated in the patient's lower jaw using bite registration material (Futar Scan, Kettenbach; Fig. 2).

2. Intra-oral scan for implant planning: An intra-oral scan of the second and third quadrants including a vestibular scan was taken with the CERECAC Bluecam during one session. A crown in region 36 (Fig. 3) was then designed based on the virtual model. The optical impression and the virtual crown were exported to be combined with the 3-D X-ray scan in the implant planning software (SICAT Implant).

3. Intra-oral scan of entire jaw: A further intra-oral scan of the entire upper and lower jaw (Fig. 4) was taken to produce a physical model for the creation of the surgical guide at SICAT. The intra-oral scan was sent to the LMU Department of Prosthetic Dentistry's laboratory via the CEREC

Connect online portal, which ordered a stereolithographic (SLA) model.

To begin the implant planning, the DICOM data from the CBCT and CAD data from CEREC was imported into SICAT Implant. Using neighbouring teeth as markers, both data sets were then superimposed and merged (Figs. 5 & 6). On the basis of this information, the 3-D planning procedure took place following bone and prosthetic requirements, in compliance with safety distances. The exact gingival margin displayed within the software helped to determine the soft-tissue situation, allowing precise planning of the emergence point (Figs. 7 & 8).

In the present case, the dental team opted for the navigated placement of a Straumann Standard Implant with a 4.8 mm diameter (Straumann Guided Surgery). Once planning had been completed, the planning data was burned onto a CD and sent to SICAT along with the SLA model, radiographic template and order form.

The company uses the planning data to translate the radiographic template into a surgical guide (Figs. 8–11). Before delivery, the surgical guide is tested using high frequency testing in order to ensure that it meets the manufacturer's guaranteed production accuracy of less than 500 µm at the apical end of the implant (Fig. 12).

With the surgical guide, the dental team received a surgical protocol indicating which drills and sleeves of the Straumann Guided Surgery Kit to use. In order to ensure a minimally invasive procedure, it was decided to opt for a flapless surgery procedure. The implant bed was then

Fig. 6 Merged data in planning software (SICAT). The path of nervus alveolaris inferior is marked.

Fig. 7 Selection of the virtual implant directly from the implant library of the planning software.

Fig. 8 Precise display of soft-tissue contour, safety margin around implant and drill path.

Fig. 9 Centralised fabrication of surgical guide by converting radiographic template (right) using CNC technology.

Fig. 10 Completed surgical guide.

Fig. 11 Detailed view of drilling template: polymerised sleeve for the implantation using the Straumann Guided Surgery Kit.



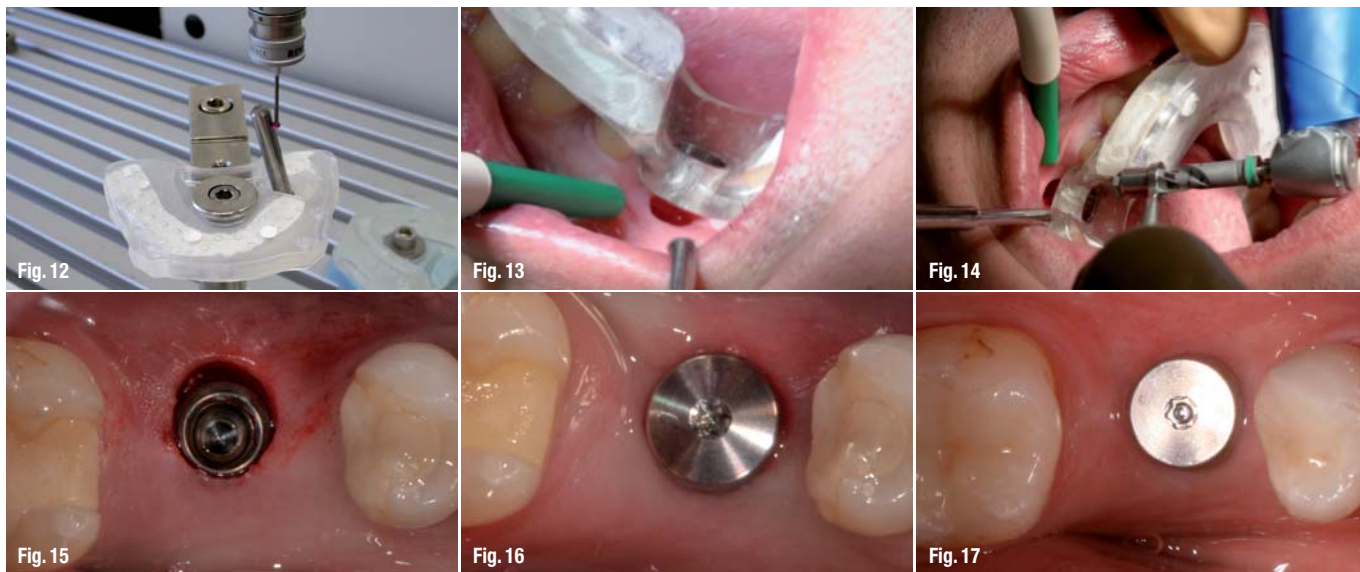


Fig. 12

Fig. 13

Fig. 14

Fig. 15

Fig. 16

Fig. 17

Fig. 12 Quality control: measurement of sleeve position.

Fig. 13 Surgical guide after tissue punch *in situ*.

Fig. 14 Preparation of implant bed.

Fig. 15 Implant *in situ* without healing cap/gingival former.

The punch-out hole appears oval as a result of distortion by the mirror.

Fig. 16 Implant with gingival former immediately post-op.

Fig. 17 Situation after ten-week healing period and inclusion of CEREC chairside inlays at teeth #35 and 37.

prepared using the Straumann Guided Surgery Kit, in accordance with the surgical protocol supplied by SICAT (Figs. 13 & 14). Figures 15 and 16 show the implant bed immediately after placement with and without healing cap, respectively. During the ten-week healing period, the neighbouring teeth were supplied with chairside-fabricated CEREC inlays (Fig. 17). The final prosthetic is created using a conventional impression since intra-oral scanning of implants—although technologically possible—has not yet been released by the manufacturer (Sirona).

Discussion

Planning of the implant position based on scan data of the clinical situation was already described a few years ago. However, the data in question was gathered from extra-oral digitalised stone models.³

What is really interesting now for dentist and patient alike is the merging of data generated from an intra-oral scan with CT- or CBCT-generated DICOM data, as in the case presented. This provides a number of advantages: it eliminates the need for conventional impressions, the fabrication of stone models and elaborate fabrication of conventional radiographic templates by a dental technician. This means not only greater patient comfort but also a reduction in the number of patient visits.

In addition, guided implantology has additional advantages, such as greater safety; a more predictable aesthetic outcome; a minimally invasive procedure through flapless surgery, which in turn means less pain; and a reduction in downtime for the patient. A sharp outline and much

more precise imaging of the gingival margin via the imported intra-oral scan also helps to make a better assessment of the emergence profile of the implant during the planning phase.



Presently, a physical model is still required to fabricate a surgical guide for navigated implantation, currently mostly made using a conventional impression. Instead, the present case used an SLA model fabricated from the intra-oral digital impression, in order to be able to work entirely without conventional impressions. Preferable for clinicians would be a fabrication of surgical guides without the need for a physical model. According to the manufacturer (SICAT), further developments in this direction are already underway and will be introduced at the IDS 2011.

In summary, it can be said that guided implantology for specific indications is already possible today without any conventional impression by combining intra-oral scans, CBCT and an SLA model.

Editorial note: A list of references is available from the publisher.

_contact	CAD/CAM
<p>Dr Jan-Frederik Güth Poliklinik für Zahnärztliche Prothetik, LMU München Goethestraße 70 80336 München Germany</p> <p>jan_frederik.gueth@med.uni-muenchen.de</p>	

Any
CAD



- open STL-format
- modular:
scanner and software or
complete process chain
incl. milling and sintering furnace
- easy to use
- only small space required
- very good price-performance-ratio
- for implants, telescopes, inlays,
onlays, etc.

IDS
2011

34. Internationale Dental-Schau
34th International Dental Show
Cologne, 22.-26.3.2011

Besuchen Sie uns!
Visit us!

Hall 10.2 / Stand L050/M051

REITEL

T R U S T I N Q U A L I T Y

AnyCAD-System • www.anycad.de

Six steps to a chartless practice

Author_ Dr Lorne Lavine, USA

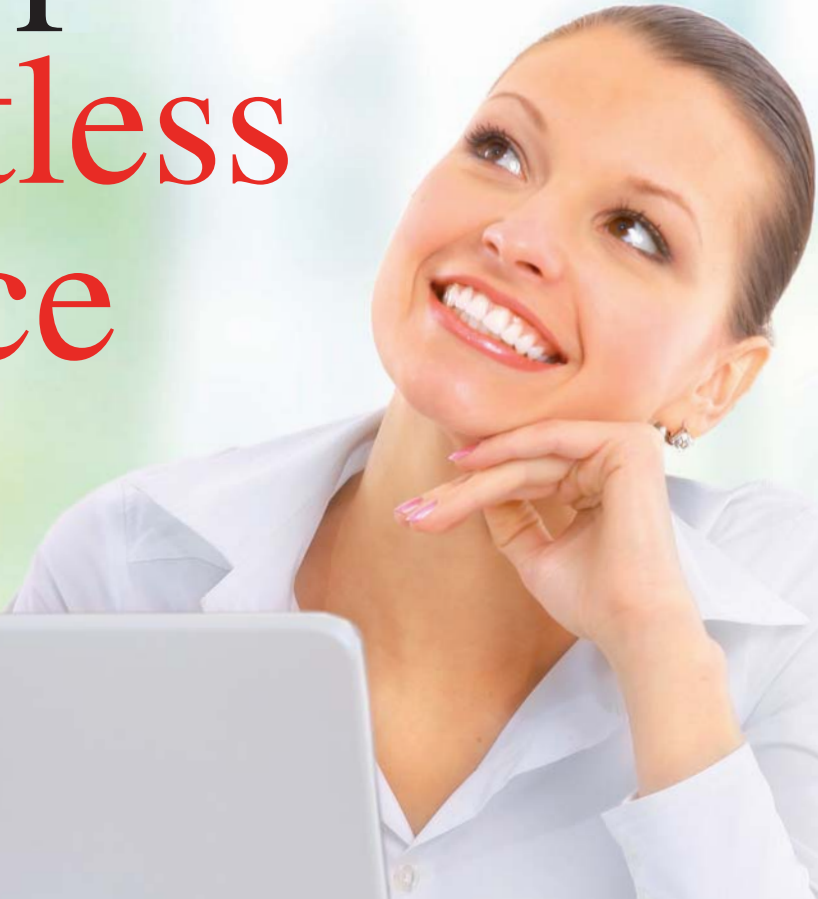

Photo: EDHAR

_There is no doubt that the modern dental practice has changed rapidly over the past fifteen years. Dentists have come to realise that with new technology, they can create a practice that is more efficient, costs less to run, and allows for decentralisation of the front office. Records that were primarily paper- and film-based are being replaced by digital radiography, electronic records, and there is a move towards a paperless, or at the very least, chartless practice. Most offices realise that there will always be paper in a dental practice. Whether it is walkout statements, insurance forms or printed copies of images, paper will forever be part of the dental practice. That being said, there are a number of practices that have truly eliminated their paper charts. While the process is easier for a start-up practice, with proper planning, existing practices can achieve this goal as well.

Many dentists are probably aware that the Federal Government is mandating that all patient records be paperless by the end of the year 2014. The challenge for most practices is evalu-

ating their current and future purchases to ensure that all the systems will integrate properly together. While many dentists are visually oriented and thus tend to focus on the criteria that they can actually see and touch, some of the most important decisions are related to more abstract standards. I have therefore developed a six-point checklist that I feel is mandatory for any dentist adding new technologies to his or her practice, and I recommend that each step be completed in order.

_I Practice management software

It all starts with the administrative software that is running the practice. To develop a chartless practice, this software must be capable of some very basic functions. For practices that wish to eliminate paper, dentists need to consider every paper component of the dental chart and try to find a digital alternative. For example, entering charting, treatment plans, handling insurance estimation and processing through e-claims, ongoing patient retention and recall

activation, scheduling, and dozens of other functions that are used on a daily basis. Many older programs do not have these features and if practices wish to move forward, dentists will have to consider more modern practice software.

It is important to understand that as much as we would all prefer that our practice management software programs could handle all of these functions, most fall short of this. Fortunately, there are a number of third-party programs that can provide functionality where the practice management programs cannot, such as programs that allow digitisation of forms that require patient signatures and programs that can reduce the process of entering progress notes to a few clicks of a mouse.

_II Image management software

This is probably the most challenging decision for any practice. Most practice management programs offer an image management module. Eaglesoft has Advanced Imaging, Dentrix has Dexis, Kodak has Kodak Dental Imaging, and so on. These modules are closely integrated with the practice management software and tend to work best with digital systems sold by the company.

For example, having an integrated image module makes it very easy to attach images to e-claims with a few clicks of a mouse. However, there are also many third-party image programs that will bridge very easily to the practice management software and offer more flexibility and choices, although with slightly less integration. There is no perfect system. The choice really is between paying a premium for greater integration or paying less for greater flexibility. Some of the better known third-party image programs include Apteryx XRayVision, XDR and Tigerview.

_III Operatory design

The days of a single intra-oral camera and a TV in the upper corner are being replaced by more modern systems. The majority of practices place at least two monitors in the operatories, one for the patient to view images or for patient education or entertainment, and one for the dentist and staff to use for charting and treatment planning and any sensitive information concerning the Health Insurance Portability and Accountability Act, such as the daily schedule or other information that dentists would prefer that the

patient not see. Microsoft Windows has built-in abilities to allow dentists to control exactly what appears on each screen.

There are numerous ergonomic issues that must be addressed when placing monitors, keyboards and mice. For example, a keyboard placed in a position that requires the dentist to twist his or her back around will cause problems, as will a monitor that is improperly positioned. Another important decision for the practice will involve deciding whether the dentist prefers patients to see the monitor when they are completely reclined in the chair. If this is the case, then the options are a bit more limited for monitor placement. There are some very high-tech monitor systems that not only allow the patient to see the screen, but also create a more relaxing environment for patients considering long procedures.

_IV Computer hardware

After the software has been chosen and the operatories designed, it's time to add the computers. Most practices will require a dedicated server in order to protect their data and with the necessary power to run the network. The server is the lifeblood of any network and it is important to design a server that has redundancy built-in for the rare times that a hard drive might crash and can easily be restored. The workstations must be configured to handle the higher graphical needs of the practice, especially if the practice is considering digital imaging.



Photo: Konstantin Chagin



Photo: Minerva Studio

The computers placed in the operatories are often different from the front desk computers in many ways. They will have dual display capabilities, better video cards to handle digital imaging, smaller cases to fit inside the cabinets, and wireless keyboards and mice. An often-overlooked consideration is that the smaller the computer, the more heat it generates. Heat is the number one enemy of computers, and since many dentists will place their computers inside a cabinet at the 12 o'clock position, having proper ventilation is critical.

_V Digital systems


The choice of image software will dictate which systems are compatible. Digital radiography is the hot technology at this time owing to many factors. Dentists with digital radiography report greater efficiency by having the ability to capture and view images more rapidly, better diagnostics, cost savings by the elimination of film and chemicals, and higher case acceptance through patient co-diagnosis of their dental

needs. All systems have pros and cons, and dentists will have to evaluate each system based on a set of standards that are important to that practice. For some dentists, it might be image quality. For others, it may be the cost of the systems, the warranty of the sensor, the company's reputation, or the compatibility of the sensors with their existing image management software. Keep in mind that intra-oral cameras are still an excellent addition to any practice, since they allow patients to see the things that typically only a practitioner could see.

_VI Data protection

With a chartless practice, protecting data is crucial to preventing data loss due to malware or user errors. Every practice, at a minimum, should be using antivirus software to protect against the multitude of known viruses and worms, a firewall to protect against hackers, who try to infiltrate the network, and have an easy-to-verify backup protocol in place to be able to recover from any disaster. The different backup protocols are as varied as the number of practices, but it is crucial that the backup is taken offsite daily and can be restored rapidly. The modern term is *practice continuity*. It is not only the data that is being backed up that is important, but also critically, the speed with which the system can be restored and the practice can be up and running following a disaster such as a server crash, fire or flood.

For practices that wish to be chartless or paperless, it is crucial to evaluate all the systems that need to be replaced with a digital counterpart, and to adopt a systematic approach to adding these new systems to the practice. Most practices would be well advised to replace one system at a time, and become comfortable with this new system before adding new technologies to the practice. The typical practice will take 9 to 18 months to transition from a paper-based practice to a chartless one.

_contact		CAD/CAM
	<p>Dr Lorne Lavine 2501 W. Burbank Blvd., #303 Burbank, CA 91505 USA</p> <p>drlavine@thedigitaldentist.com www.thedigitaldentist.com</p>	

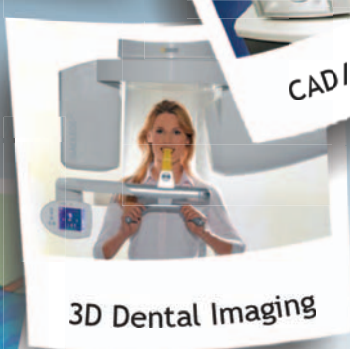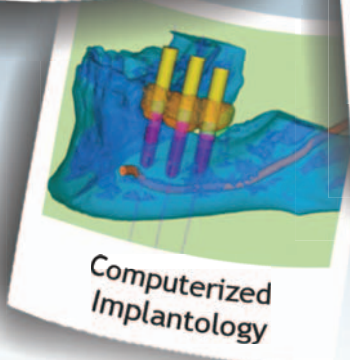
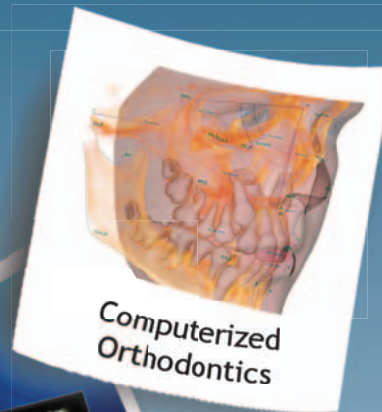
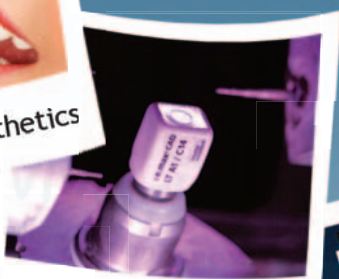

Estimated 14 CME Hours

20 % Discount
for the Readers
of the Magazine

5th CAD/CAM & Computerized Dentistry International Conference

12-13 May 2011


The Address Hotel Dubai Marina
Dubai UAE



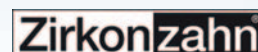PLATINUM SPONSOR



GOLD SPONSORS



SPONSORS



Tel: +971 4 3616174 | Fax: +971 4 3686883 | Mob: +971 50 4243072

www.cappmea.com/cadcam5 | info@cappmea.com

iPad in business: Advancing digital dentistry



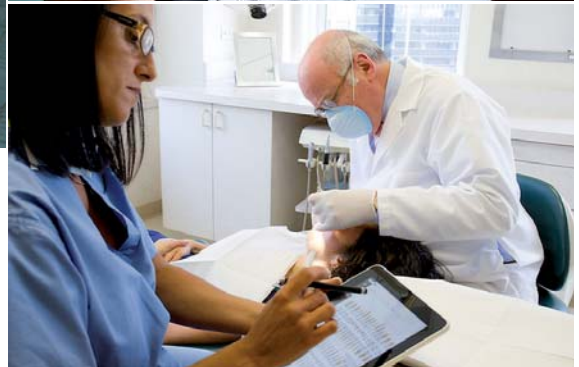_When new patients enter Dr Jonathan Ferencz's thriving prosthodontics practice in midtown Manhattan, they are greeted with a smile—and an iPad.

For Dr Ferencz, the latest technology has always driven quality patient care. As an early iPad adopter, Dr Ferencz knew the device could launch a new era in digital dentistry. iPad has become central to all aspects of the practice. In addition to simplifying patient forms and record-keeping, iPad enables Dr Ferencz to show his clients photos of treatment options. And his technicians refer to digital images on iPad to create perfect-looking dental prosthetics.

_Painless patient records

iPad simplifies the record-keeping process for both patients and staff. Rather than designing, filling out, scanning, and then shredding paper forms, Dr Ferencz and his staff have created a fast, efficient system using iPad.

Patients complete their intake forms directly on iPad using the Adobe Ideas app, and can even sign the form using a stylus on the iPad screen. From there, a member of his staff emails the forms into the practice's database. There is no paper and nothing to file. "It is efficient," Dr Ferencz says. "With iPad, we save so much time—and space."



And patients can stay productive and up-to-date with their personal lives during their visits. "If there is any kind of wait before the appointment, we give them an iPad," Dr Ferencz says. "They can check their email, surf the Internet, read the *New York Times*—all the rich content that is available on iPad."

Putting iPad into patients' hands also helps emphasize Dr Ferencz's commitment to the latest and best dental practices. "It conveys a subliminal message that this office is up-to-date technologically," he says. "So they know that we are up-to-date in our dentistry as well."

_Visual conversations

When patients enter the treatment room, iPad takes on another role: communication tool. Prosthodontics deals with aesthetic and reconstructive dentistry, such as crowns and veneers. Dr Ferencz's challenge is to get patients to see what he sees, and to show them what he can do. With iPad, he can effortlessly display photo-

graphs and X-rays to patients during consultations. And using the Adobe Ideas app, he can annotate the images onscreen while pointing out areas of interest.

"iPad is ideally suited to this kind of visual conversation," he says. "The patient and I can flip through the X-rays and clinical photos together, and I can illustrate my points as we go." Because the patient has a visual idea of the procedure and a sense of what the outcome will look like, the result is a direct improvement in care. "With iPad, I can greatly enhance patient acceptance of my proposed treatment," Dr Ferencz says.

Helping him in the conversation are two iPad features that Ferencz can not match elsewhere: high resolution and zooming. "The resolution of iPad is so incredible that I can see details I could not on a conventional X-ray," he says. Zooming also allows Dr Ferencz to focus a patient's attention on one aspect of the image. "To do that with your fingers is absolutely invaluable, compared to a laptop or a conventional display."

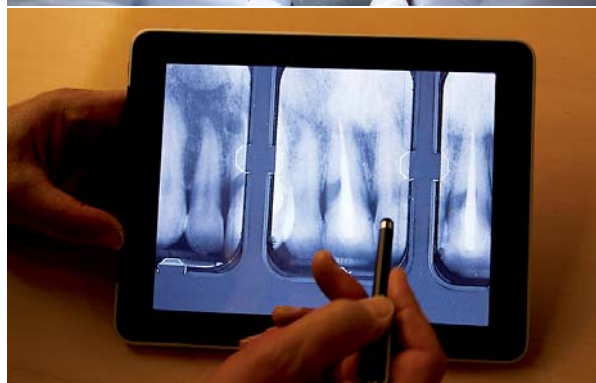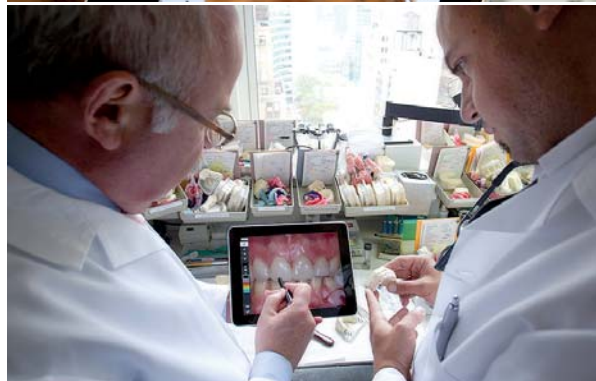
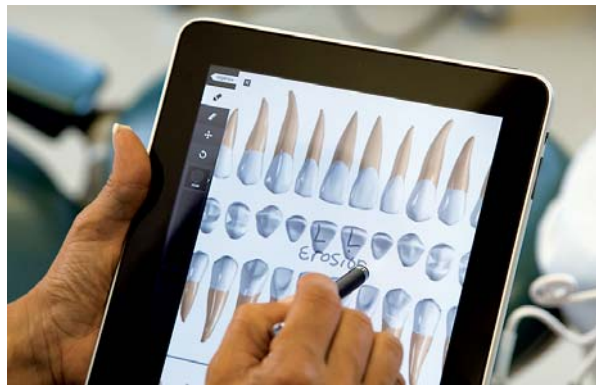iPad in the laboratory

Dr Ferencz's iPad use does not end in the treatment room. Immediately after a discussion with a patient using iPad, Dr Ferencz might bring the device to his in-house laboratory to demonstrate an issue to one of his technicians. "On a dental restoration, the most effective way to make a correction is to show the photograph to my technician and say, 'Here is how I would like you to reshape it,'" he says. "That way, we are having a conversation about a clinical photograph, not a drawing or a diagram."

From there, the technician can get to work. "The technician just takes out an iPad, pulls up the images, and goes to work," Dr Ferencz says.

A business of trust

iPad is also a powerful, persuasive way to share images during doctor-patient conversations about treatment options. "On our first day with iPad, I used it three times to show patients X-rays and photographs of clinical conditions," Dr Ferencz explains. "And in each case the patient booked the procedure immediately." When he asked the patients whether the presentation on iPad had an impact on their decisions, one of them said, "I trust Dr Ferencz, and I would have done what he said, but the way the images appeared was just amazing. I had to schedule the procedure immediately."



In a single day, iPad paid for itself. "As a business owner, I think iPad is a no-brainer," Dr Ferencz says. "With its high resolution and ease of use, iPad has the ability to make a major impact on oral health care."

And this is just the beginning. "I think we have just begun to scratch the surface with iPad applications," he says. "It really is totally revolutionary." _

_contact

CAD/CAM

Apple Inc.
1 Infinite Loop
Cupertino, CA 95014
USA

www.apple.com

“The entire process runs more smoothly”

An interview with Hermann Loos

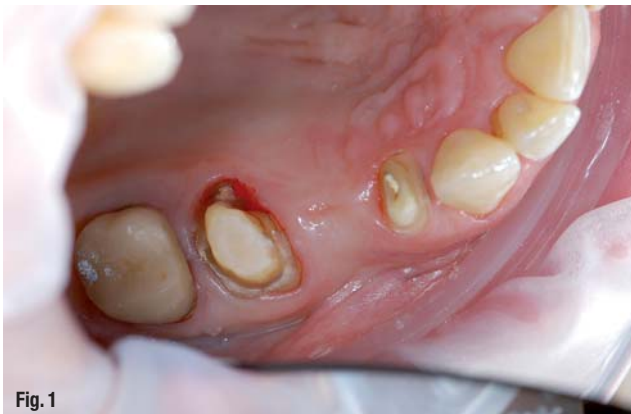

Fig. 1

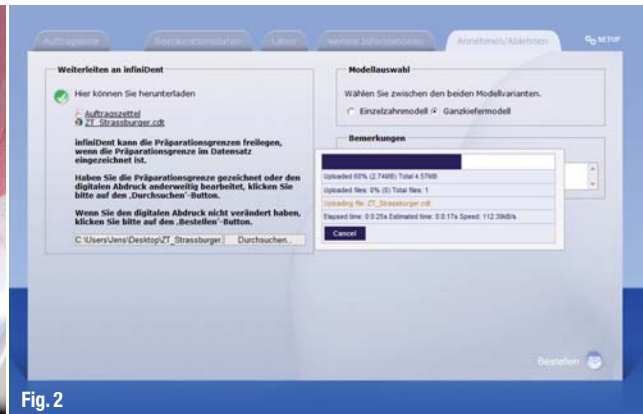

Fig. 2

Fig. 1 The patient is to receive a three-unit multilayer bridge. With the aid of the intra-oral camera, digital impressions of the initial situation are acquired.

Fig. 2 The bridge is ordered from the dental laboratory. For this purpose, the digital impression data is sent via the CEREC Connect web portal.

Fig. 3 With the aid of the inLab software (version 3.80), the DT designs the multilayer bridge. The software computes the design data for the framework and the veneer facing.

Fig. 4 The DT can edit the framework data (photo) and veneer data separately. This allows for an evaluation of the restoration result in advance.

Efficient processes are key to the success of a dental practice. They are prerequisite for the optimal utilisation of financial resources, time and capacity. Against this background, German-based dentist Hermann Loos decided to switch from conventional impressions with an impression tray to digital impressions captured using the CEREC Bluecam intra-oral camera (Sirona).

For the past six months, Mr Loos has been collaborating closely with dental technician (DT) Jens Richter at Kerstin Strassburger dental laboratory, based at an external dental laboratory, via the CEREC Connect web portal from Sirona. With the aid of the CEREC Bluecam, he scans patients' teeth and transmits the data electronically to the dental laboratory, which then fabricates prosthetic restorations on his behalf. This treatment

method has elicited a positive response amongst patients. For Mr Loos, digital impression-taking has streamlined the workflow between his dental practice and the dental laboratory.

CAD/CAM: Mr Loos, what prompted you to choose CEREC Connect?

Mr Hermann Loos: I give top priority to utilising new technology in the interests of my patients. My goal is to work as efficiently as possible in order to deliver top-quality results and at the same time make the most of the skills of DTs. A close working relationship with a dental laboratory is absolutely indispensable, especially with regard to complex all-ceramic restorations.

CEREC Connect makes this possible. The stated aim of this web portal is to enhance and

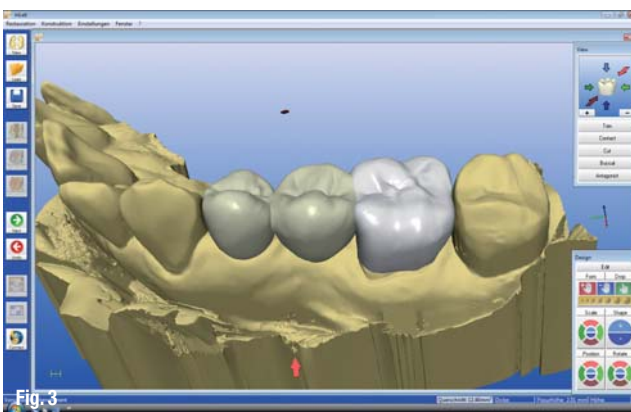


Fig. 3

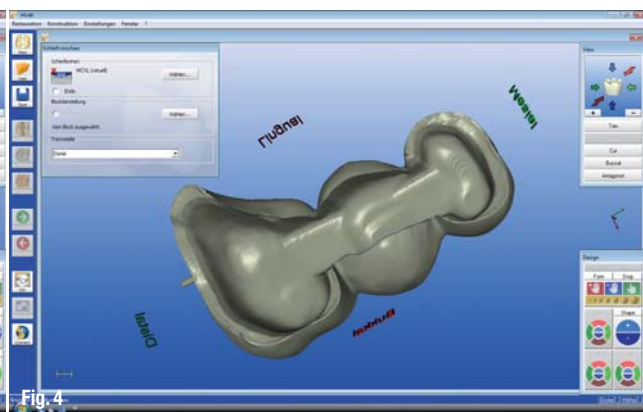


Fig. 4

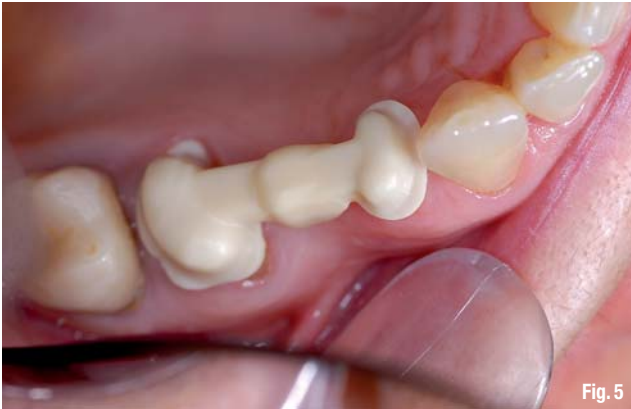

Fig. 5

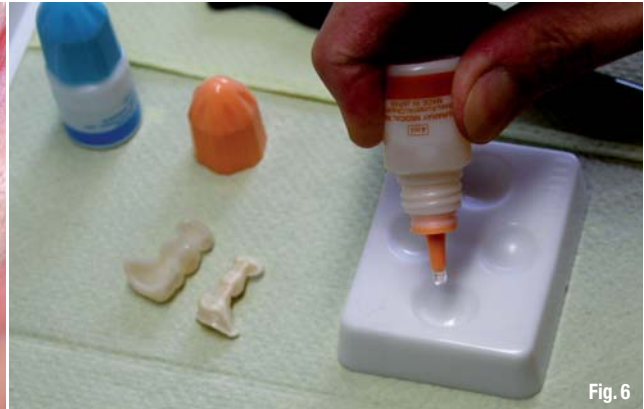

Fig. 6

streamline collaboration between the dentist and the DT. The resulting workflow is quicker and simpler.

How have you measured this?

CEREC Connect facilitates an all-digital workflow, from the initial impression to the finished restoration. In the case of conventional tray impressions, numerous intermediate steps are required in order to create a working model. Therefore, considerable scope for error exists, beginning with the initial impression and ending with the fabrication of the stone model.

CEREC Connect reduces this process to three simple steps: the application of CEREC Optispray (Sirona), the acquisition of the digital impression via the intra-oral camera, and the completion of the order form on the computer monitor. With a single click of a mouse, I can send the virtual model data to the DT in just a few seconds. This eliminates the shipping times to and from the dental laboratory.

A further advantage is that the intra-oral scan reproduces the situation in the patient's mouth with a high degree of accuracy. This eliminates any deviations attributable to the physical properties of the silicone impression compound. In the final analysis, CEREC Connect rules out

potential errors and hence benefits all those concerned, above all, the patient, who receives a perfect dental restoration.

How have patients reacted to this new impression-taking procedure?

My patients have found this new impression-taking procedure with the intra-oral camera much more pleasant. And they have given voice to this clearly. Most patients are horrified at the prospect of having a conventional impression tray in their mouths, which can take up to four minutes until the impression compound has finally set. This step has now been eliminated, much to the relief of my patients. With the aid of the intra-oral camera, I can acquire practically contact-free scans of the preparation, antagonist and bite situation. The camera only needs to be placed on the teeth briefly. This is quick and does not cause any discomfort.

Which restoration types do you delegate to CEREC Connect?

I delegate all restorations in excess of a certain size to my dental laboratory. Smaller restorations such as inlays, partial crowns, crowns and small-sized bridges are fabricated in-house on the CEREC system. In the case of complex work, I rely on the DT's expertise.

Fig. 5 As it has been fabricated on the basis of the data supplied by the dentist, the framework fits perfectly.

Fig. 6 The all-ceramic framework and veneer facing are adhesively bonded (multilayer technique). Before they are bonded, the two components are silanised.

Fig. 7 The two components are bonded using a two-component adhesive.

Fig. 8 The bridge is placed in the patient's mouth.

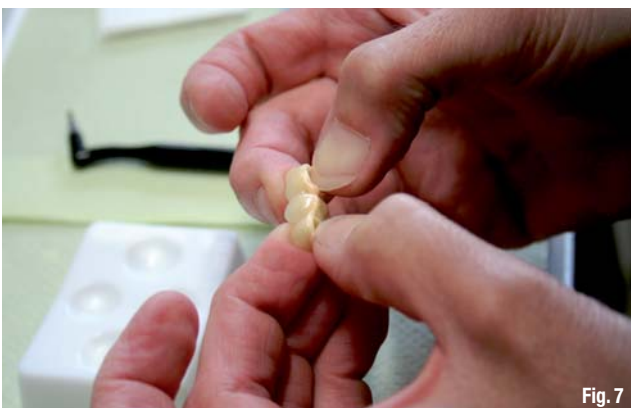

Fig. 7

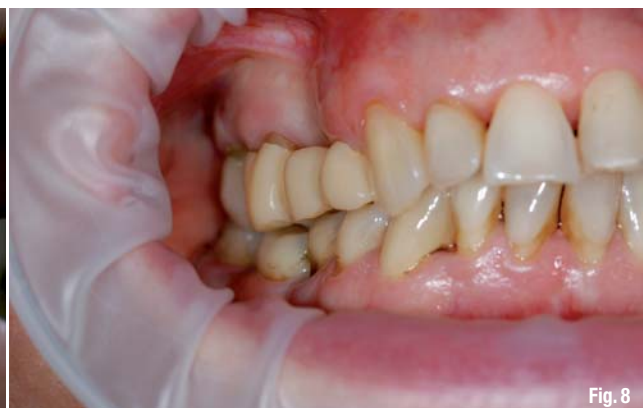

Fig. 8

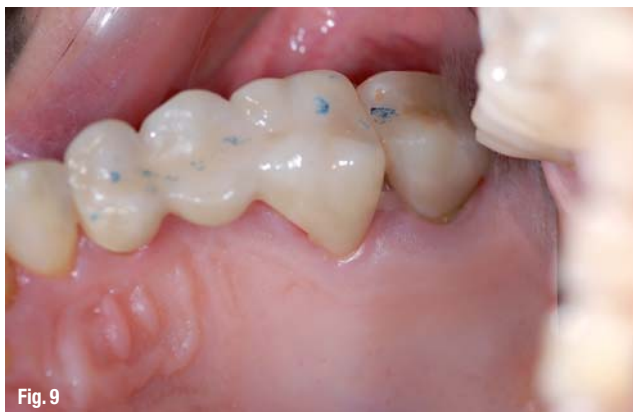

Fig. 9

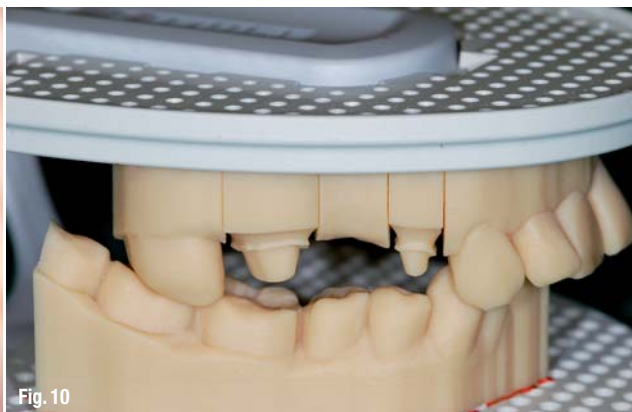


Fig. 10

Fig. 9 The contact check indicates that the bridge has been optimally integrated.

Fig. 10 The DT can order a polymer (SLA) model from infiniDent. This model is based on the digital impression data.

In other words, everyone concentrates on what he or she does best.

Could you give us a specific example of how this division of labour functions?

We use CEREC Connect for the fabrication of all-ceramic bridges using the new multilayer method. In this case, the framework and the veneer facing are milled out of different ceramic materials and then adhesively bonded. I begin by acquiring impressions of the initial situation with the aid of the CEREC Bluecam (Fig. 1). Based on this data, the software generates a virtual model, which I then edit on the monitor. In addition, I enter all the important information for the DT, for example, the preparation margins. This is not an absolute 'must'. However, as I have direct access to the patient and am familiar with his or her dental situation, I can provide valuable assistance to the DT.

I then send the data to the dental laboratory and fill in an electronic order form (Fig. 2). The DT is notified via e-mail that a new order has been received. Based on my data, he then fabricates the restoration (Figs. 3 & 4). The occlusal surfaces and veneer facing are computed using the patient's individual dentition and the patented biogeneric model. The bridge framework and veneer facing are milled out of ceramic blocks. Two to five days later, the finished framework and veneer facing arrive at my dental practice by special delivery. I check the fit in the patient's mouth (Fig. 5), bond the components (Figs. 6 & 7) and then place the restoration (Figs. 8 & 9).

I can rely on receiving very good results, as the DT uses my original data. All potential sources of error in the conventional method are eliminated, for example the conversion from a negative to a positive model and possible damage during transit. All in all, the entire process runs more smoothly.

But surely the dentist requires a model in order to check the occlusion and articulation?

Yes, that is correct, but this does not pose a problem. Via CEREC Connect, the dental laboratory has the option of ordering a model based on the impression data (Fig. 10). Made of a polymer material, this stereolithographic (SLA) model is fabricated within three working days by Sirona's infiniDent central production service. It fulfils exactly the same criteria as a conventional stone model. While waiting for the model to be delivered, the DT can design the restoration framework and veneer facing.

How do dentists and DTs benefit from CEREC Connect?

CEREC Connect speeds up workflow. Digital impression-taking eliminates numerous processing steps and simplifies collaboration between the dentist and DT. Each has access to the same set of data. And each can exploit his special skills and expertise. In this regard, CEREC Connect fosters a productive working relationship between experts. The patient does not have to suffer the discomfort of a conventional impression tray, and the final result is less likely to have errors.

Editorial note: All images courtesy of Loos/Richter.

_about the interviewee

CAD/CAM



Hermann Loos studied dentistry in Jena and Dresden and qualified as a dentist in 1980. He was employed in the town of Grüna in Germany until 1991, where he subsequently set up his own dental practice.

As a stomatology specialist, he has used the CEREC system for the past ten years. He has reported on his experiences of all-ceramic CAD/CAM restorations at conferences in Germany and abroad and has published numerous scientific papers.



Federation Dental International Annual World Dental Congress

NEW HORIZONS IN ORAL HEALTH CARE
14 - 17 SEPT. 2011



www.fdi2011.org
info@fdi2011.org

For a perfect fit—CAD/CAM bar restoration on XiVE implants

Authors_ Björn Roland & Dr Peter Gehrke, Germany

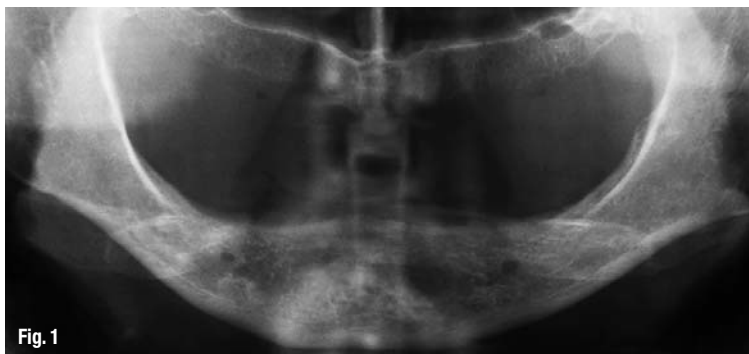


Fig. 1

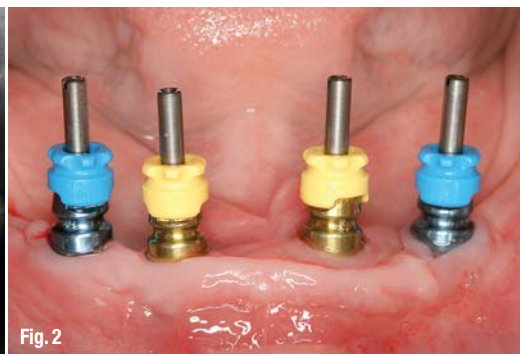

Fig. 2

Fig. 1 _The panorama image shows the situation prior to insertion of the XiVES implants.

Fig. 2 _Two weeks after being uncovered, an open pick-up impression is made at implant level with an individual tray.

_Conventional or CAD/CAM? Today, dental technicians and implantologists ponder this question more frequently than ever. More and more often, they tend towards CAD/CAM. Owing to their tension-free fit, CAD/CAM-fabricated solutions are particularly well suited for the restoration of larger jaw sections. Deciding in favour of or against a CAD/CAM restoration should thus always be a team decision. With his expertise and training, the dental technician is able to contribute considerably to an aesthetic and technically perfect result.

To ensure successful prosthetic restorations, all the steps of a procedure—from planning through impression to insertion—need to be performed with utmost care. This is equally true for both conventionally cast work and CAD/CAM-fabricated structures. With both methods, only a precise transfer of the oral situation to the model guarantees success. Precision is vital for both methods, particularly when restoring larger jaw sections. Outstanding results can also be obtained with conventional casting technology if the work is done accurately and

with sufficient experience. However, the risk of an ill fit is substantially higher compared with modern CAD/CAM procedures. Furthermore, wide-spanning and solid frameworks in particular enable cavities to arise and the framework to warp. Also, (partial) overheating of the melt, another potential quality flaw, is often observed with large volumes. These problems do not occur with CAD/CAM technology.

_Therapy decision

Our patient wished to regain a firm bite and unimpaired speech. She had already been wearing mucosa-supported complete dentures for 20 years, but was comfortable only with the maxillary denture. The grip of the mandibular prosthesis was inadequate owing to the resorbed alveolar ridge (Fig. 1) and obstructed eating and speaking. There were no general medical findings ruling out an implantation. After detailed consultation, we opted for a bar denture on four implants placed inter-foramally in the mandible. A fixed restoration was not possible owing to cost considerations. A prosthesis

Fig. 3 _In order to check the accuracy of transfer, a bar made from autopolymerisable is manufactured on a screwed-in Friadent MP abutment and split into segments.

Fig. 4 _The individual tray for the pick-up impression with fixed pick-up screws.




Fig. 3

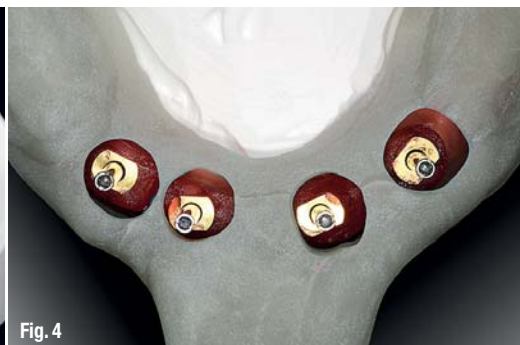

Fig. 4

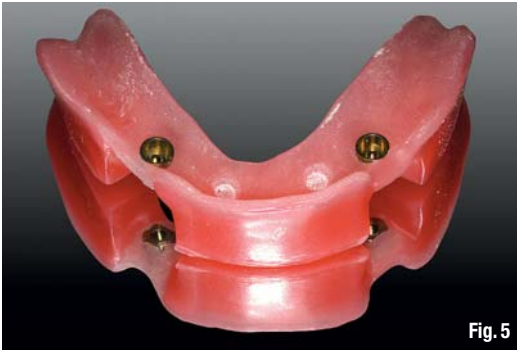

Fig. 5

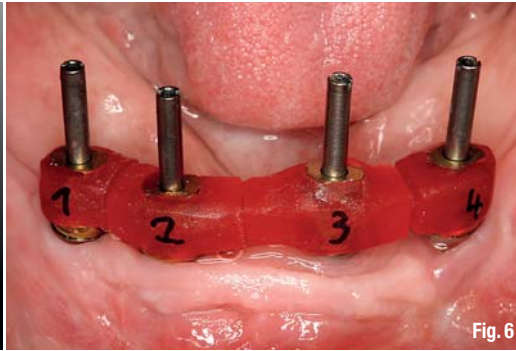


Fig. 6

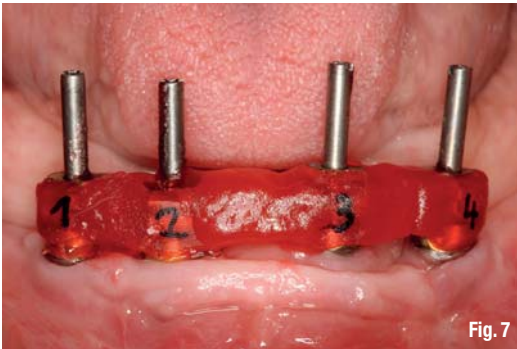


Fig. 7

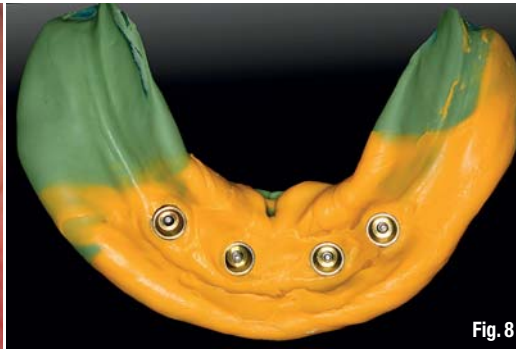

Fig. 8

Fig. 5_ The bite template is fixed in the mouth on two implants.

Fig. 6_ Preparation for pick-up impression: The four separate parts of the bar are screwed-in in the mouth.

Fig. 7_ The segments are splinted with a small amount of autopolymerisate. The Friadent MP abutments are not removed afterwards.

Fig. 8_ Double-mix impression.

on two implants, which would be more economical, was not an alternative from a medical perspective. The patient desired as stable a restoration as possible and we had to avoid degradation of the implant site through tilting motions in each case.

In the current case, the precision, which can only be achieved with this procedure, turned the balance in favour of a CAD/CAM-produced bar construction. This is also the reason that our dental laboratory, whenever possible, uses wide-span superstructures that are fabricated industrially. The result becomes ultra-predictable in conjunction with the two-stage impression process that we have been implementing with a conventionally cast framework for years. We frequently use the two-stage method whenever there are high demands on accuracy of the impression.

Transfer of implant positions

Four months after insertion, the osseointegrated implants (XIVE S, length: 13 mm; diameter: distal 4.5 mm, mesial 3.8 mm) were restored with gingiva

formers. The situation was impressed and an individual tray created. The impression at implant level was made two weeks after uncovering (Fig. 2). The DENTSPLY Friadent pick-up transfer copings were then screwed onto the analogues in the dental laboratory. Precisely transferring the oral situation with the abutments onto the model requires a second impression with an appropriate control key. A bar made from autopolymerisate was used for this. In order to reconcile any tensions, which develop during polymerisation, the bar is divided into four parts (Fig. 3). We went on to make a second individual tray (Fig. 4) and a plastic-based template to determine the relation. We designed the template in such a way that it can be secured with two impression copings onto the Friadent MP abutments (DENTSPLY Friadent) fixed in the mouth (Fig. 5). This is the only way to test the bite reliably, as well as the aesthetics, function and phonetics during the later wax-up.

During the session to determine the relation, an impression was also made at gingiva level using the plastic bar. The individual parts were screwed on the

Fig. 9_ The master cast with removable gingiva mask.

Fig. 10_ The wax-up.

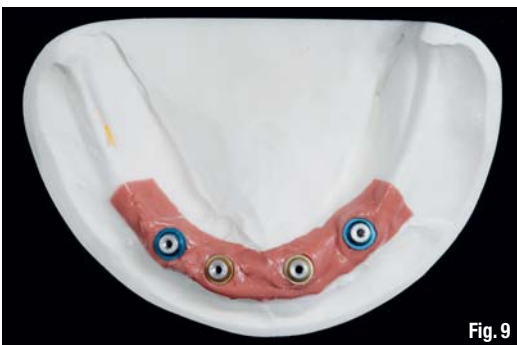

Fig. 9

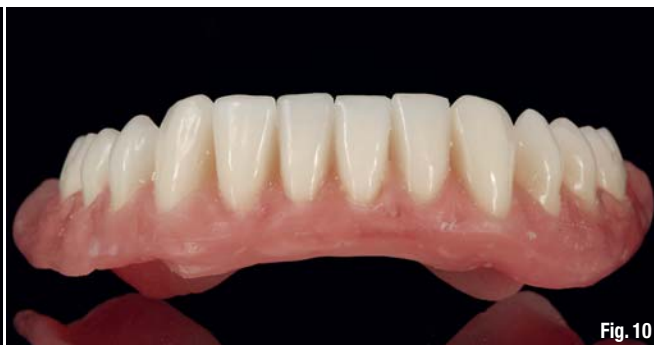

Fig. 10

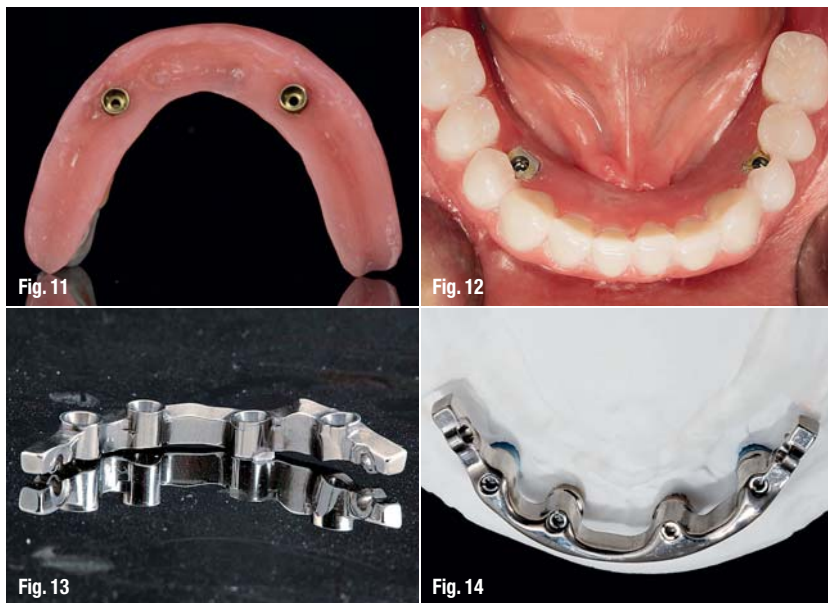


Fig. 11 _The basis of the wax-up with the sunken impression copings.

Fig. 12 _Screw-retaining the wax-up with the two distal implants ensures the correct position when fitting.

Fig. 13 _The construction proposal supplied by DENTSPLY CAD/CAM centre.

Fig. 14 _The bar milled according to the dental laboratory's specifications fits perfectly on the laboratory analogue. The bolt eyes for the planned MK1 locking bolts are clearly recognisable in the distal extensions.

Friadent MP abutment (Fig. 6) and splinted together using as little autopolymerisate as possible (Fig. 7). The final abutments always remain in the mouth from this point in time onwards. This has the benefit that peri-implant bone resorption is limited and the soft tissues can heal undisturbed. The impression was made with two-phase silicon (Aquasil Ultra, DENTSPLY DeTrey; Fig. 8). The master cast was made of class IV dental stone. Making a gingival mask is part of the standard procedure (Fig. 9). Fabricating two precision impressions allows maximum accuracy to be achieved with wide-span superstructures. If any inaccuracies are perceived during the impression and model manufacturing process, the corresponding step has to be repeated in each case.

Manufacture and try-in of the bar

In order to fabricate the XIVE CAD/CAM bar, only the result of the wax try-in was still necessary. This was performed in a separate session using a plastic-based template (Figs. 10 & 11). The wax try-in is fixed onto two implants to facilitate better and definite positioning (Fig. 12). Together with the master cast, the set-up was then sent to the DENTSPLY CAD/CAM centre, where both were scanned in with a cus-

tomised system. The data records resulting from the scan served as a basis for constructing the bar. At the latest, the construction proposal leaves the DENTSPLY CAD/CAM centre one day after receipt of the model by e-mail. The construction is checked with the viewer software provided by DENTSPLY Friadent at no cost (Fig. 13). The jaws, bar and set-up can easily be shown, hidden and viewed from all angles with the software providing optimal control. At this point, the DENTSPLY CAD/CAM centre still accepts corrections.

After the design has been approved, the data record is e-mailed back to the DENTSPLY CAD/CAM centre. The CAD/CAM structure is delivered within seven days after the approval has arrived. In our experience, any conceivable bar solution in any size and type can be realised with the DENTSPLY Friadent range, for example Dolder bars, round bars or even bars with different retaining elements. At delivery, the bar already exhibited a quality of finish equal to a highly polished state (Fig. 14).

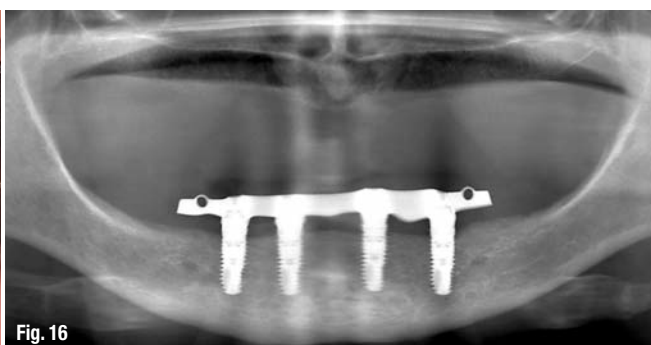
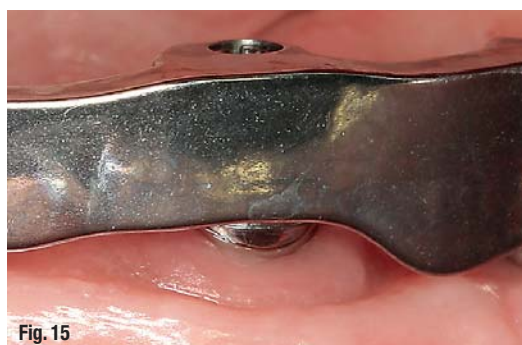We first checked the accurate fit on the master cast before we sent the bar for a try-in at the dental practice. In order to detect any gap formations on the opposite side, the bar was first screwed in (Sheffield test) on one side. The fit also proved to be very accurate, even intra-orally (Fig. 15). X-ray control of the completely screw-retained bar provided additional security (Fig. 16).

Completion

After the bar was slightly revised and given a final polish, the Galvano intermediate layer could be made (Fig. 17). After making the model casting scaffold for the denture, the bolts were fitted (Fig. 18). Before completing the bar denture, a second wax try-in was carried out for functional fine adjustment. In order to ensure optimal stability, we always make the basal portions of dentures from cold polymerisate. During the finishing process, the soft tissues were replaced with individually fashioned plastic. As patients recognise the clear aesthetic difference to their previous dentures, individual

Fig. 15 _The bar fits accurately onto the implants and has tissue-friendly adaptation to the alveolar ridge.

Fig. 16 _The X-ray control after screwing the bar in.



No Pre-Registration Fee

2011

87th Annual Session

Greater New York Dental Meeting™

Scientific Meeting:
Friday, November 25 -
Wednesday, November 30



Exhibits:
Sunday, November 27 -
Wednesday, November 30

The Largest Dental Meeting/Exhibition/Congress in the United States

Fig. 17_The Galvano intermediate layer.

Fig. 18_The scaffold with the MK1 locking bars.

Fig. 19_The finished bar denture from basal direction.

Fig. 20_The finished dentures.

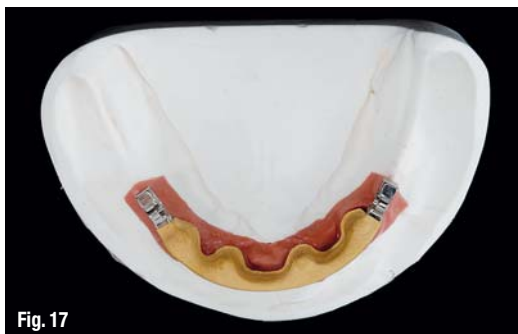

Fig. 17

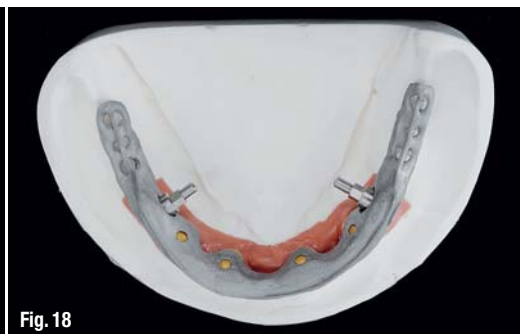


Fig. 18

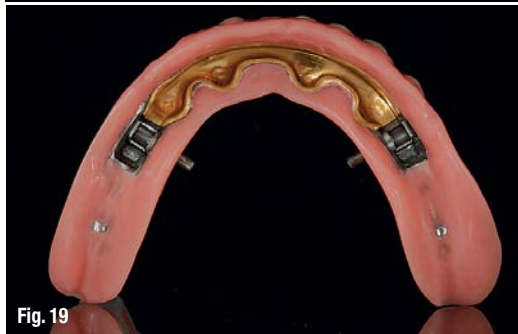

Fig. 19

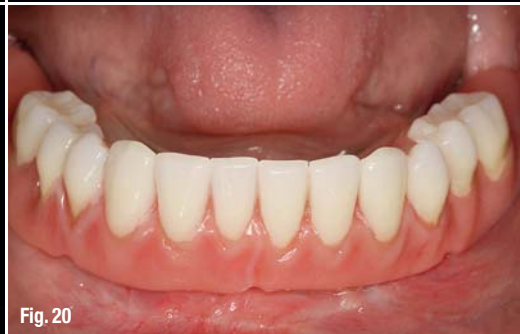

Fig. 20

creation increases their satisfaction quite considerably. This also helps them to better accept the, as yet, relatively high costs of implant restoration. Figure 19 shows a basal view of the finished denture; and Figure 20, the inserted work.

Process control

The introduction of CAD/CAM-fabricated structures (bars, bridge framework) does not change the cooperation between dentists or oral surgeons and dental technicians. However, producing the superstructure industrially necessitates rethinking the dental laboratory in one respect. The framework is no longer waxed up, but conceived on screen or, as in our case, processed on the dental laboratory PC according to a proposal from the CAD/CAM centre and, if required, modified to fit individual wishes. External production requires appropriate scheduling.

Steps determining aesthetics and function, such as approving framework design and producing the superstructure, remain in the dental laboratory as it used to be with the conventional procedure. As before, the treatment team controls the entire process. The DENTSPLY CAD/CAM centre is merely an external supplier and has no influence on the therapy. The manufacturer's warranty on CAD/CAM structures is also of interest since it is for up to ten years. This is possible because industrial standardisation ensures the high quality of the blanks' material and industrial milling guarantees maximum precision. Thus, the risk of material failure or faulty manufacturing, and hence economically difficult re-manufacture, is minimised.

Conclusion

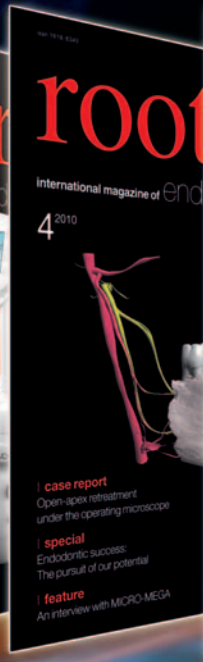The patient was enthusiastic about her new denture. Her wishes for improved function and phonetics were fully met. The procedure described here, developed in "conventional times" according to our experience, has a permanent place in our team. Furthermore, with DENTSPLY CAD/CAM solutions we have a reliable system at our disposal. It substantially simplifies work procedures, increases precision and ensures full control over all working steps.

Editorial note: This article was first published in IDENTITY 2/10. A list of references is available from the authors.

<u>contact</u>		CAD/CAM
	Björn Roland, MDT Dental Design Schnellbächer & Roland GmbH & Co. KG Raiffeisenstraße 7 55270 Klein-Winternheim Germany b.roland@gmx.de	
	Dr Peter Gehrke Professor Dr Dhom & Partner Dental Practice Bismarckstraße 27 67059 Ludwigshafen Germany dr-gehrke@prof-dhom.de	

implants

international magazine of oral implantology



You can also subscribe via
www.oemus.com/abo

 **Subscribe now!**

I hereby agree to receive a free trial subscription of **implants international magazine of oral implantology** (4 issues per year).

I would like to subscribe to **implants** for € 44 including shipping and VAT for German customers, € 46 including shipping and VAT for customers outside of Germany, unless a written cancellation is sent within 14 days of the receipt of the trial subscription. The subscription will be renewed automatically every year until a written cancellation is sent to OEMUS MEDIA AG, Holbeinstr. 29, 04229 Leipzig, Germany, six weeks prior to the renewal date.

▶ **Reply** via Fax +49 341 48474-290 to OEMUS MEDIA AG or via E-mail to grasse@oemus-media.de

One issue free of charge!

Last Name, First Name

Company

Street

ZIP/City/County

E-mail

Signature

Notice of revocation: I am able to revoke the subscription within 14 days after my order by sending a written cancellation to OEMUS MEDIA AG, Holbeinstr. 29, 04229 Leipzig, Germany.

Signature

From the patient's perspective: Design, implementation and prosthetics

Authors_ Dr Götz Grebe & Dr Melanie Grebe, Germany

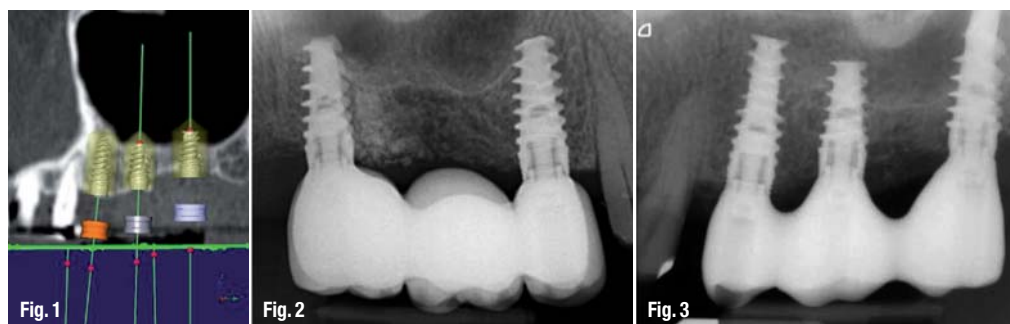


Fig. 1_ Owing to precise NobelGuide 3-D planning, a sinus lift was not necessary.

Figs. 2 & 3_ NobelActive implants enable high primary stability even in compromised bone.

The cases presented in this article differ in level of difficulty in order to illustrate that navigated implant placement is the procedure of choice for many cases. We also wish to demonstrate that template-guided navigated implant placement is advisable not only in very complex cases. From the very first time the patient presents to the dental office, the focus of the entire team contributing to the treatment is on thinking and acting from the patient's perspective and his or her foremost wish to receive a treatment that is safe, not time-

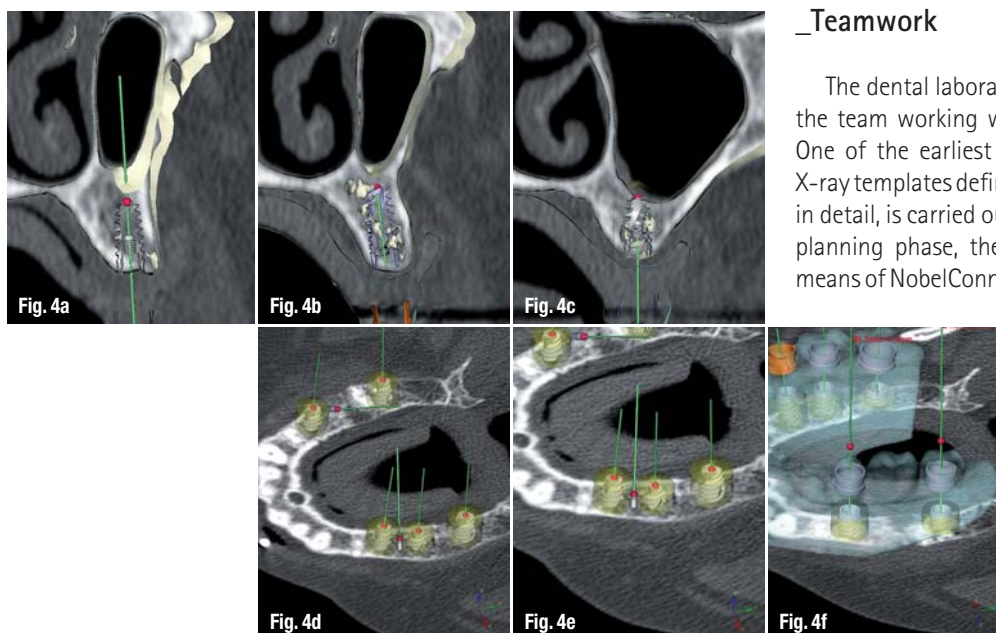
consuming, and associated with as little pain as possible.

The advantages of case planning with the NobelGuide software (Nobel Biocare) in combination with template-guided navigated implant placement include:

- _backward planning;
- _pre-surgical planning in the dental laboratory;
- _maximal certainty of the diagnosis;
- _minimally invasive intervention;
- _evaluation of complications ahead of time, to the extent possible; and
- _optimal prosthetic preparation (Figs. 1–3).

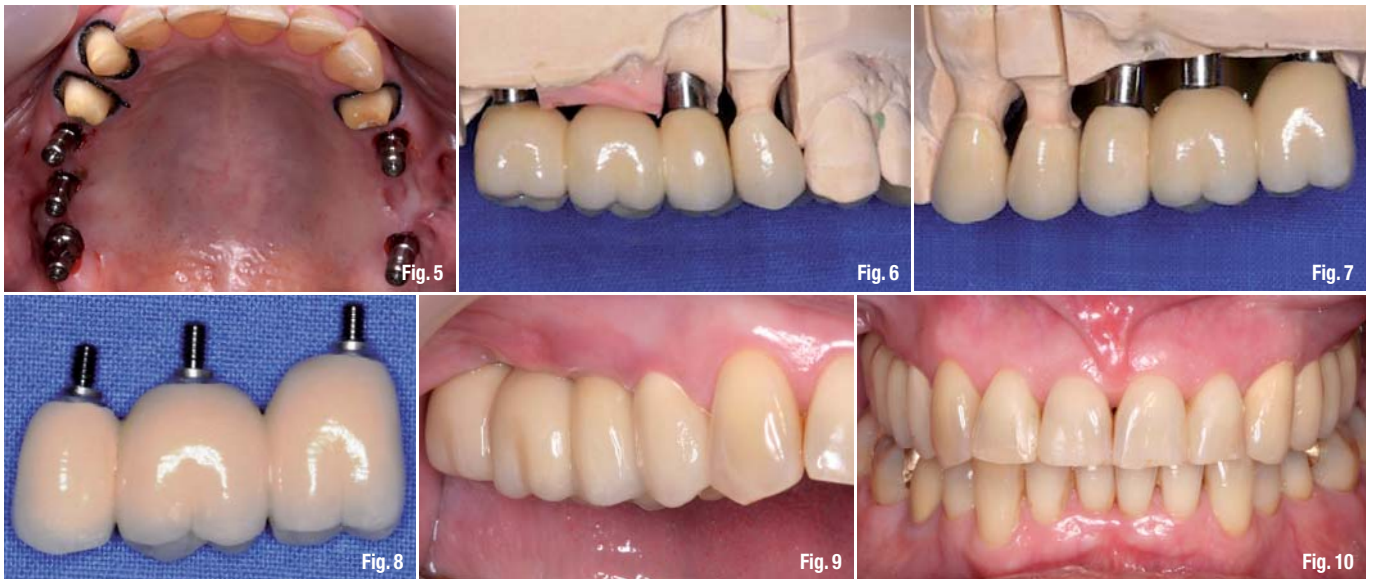
As a concept, navigated implant placement can even be utilised for the purposes of patient marketing, mainly through word-of-mouth communication, as will become evident in case II.

Figs. 4a–f_ Treatment plan.



_Teamwork

The dental laboratory is an important partner in the team working with the NobelGuide software. One of the earliest steps, the preparation of the X-ray templates defining the later prosthetic targets in detail, is carried out in the laboratory. During the planning phase, the results can be discussed by means of NobelConnect, an Internet-based network of all participating specialists, and the necessary decisions concerning the fine-tuning between surgery and later prosthetic requirements can be made. Accordingly, the resulting case designs were developed on the basis of teamwork and are therefore supported by the entire team.



The NobelGuide team always includes the dental technician, the prosthetic expert, the surgeon, the patient, and, if applicable, the radiologist recording the 3-D images. The advantages of integrating 3-D diagnostics, 3-D planning and 3-D templates outweigh the disadvantages, such as increased radiation exposure and associated costs, which are the ones most mentioned.

The definite advantages of this approach include certainty of diagnosis, precise surgical implementation, avoidance of angular deviations at depth during the surgery, expansion of the range of indications, and prevention of clinical and prosthetic complications to a large degree, especially in the application of NobelActive implants, as is described below. The NobelActive implant system was developed for experienced surgeons in order to be able to attain high primary stability even in compromised bone and under difficult conditions.

Two new tools—NobelClinician and NobelConnect—enable even better networking between the participating team partners for collaborative purposes by granting each partner access to the current state of the case—from 3-D planning to the insertion of the implant restoration—through a dedicated software interface. This facilitates communication, especially if team members do not work in the same locale.

After taking the history and arriving at a clinical diagnosis, the 3-D analysis is performed and the results are discussed to determine the treatment plan. NobelGuide, being both a surgical and a prosthetic system, is advantageous in that it allows a temporary restoration to be fabricated by the

dental laboratory prior to surgical intervention, provided this is needed and indicated. The laboratory can utilise the drilling template made in a centralised industrial production facility to transfer the planned implant positions to a model such that the temporary restoration can be fabricated without the risk of transfer losses.

Case I: Lateral tooth restoration

The first case presented concerns a 75-year-old female patient and documents a situation that is commonly encountered. The plan was to treat tooth #14 with a single crown and place a bridge on two implants. Furthermore, teeth #23 and 24 were each to receive single crowns and, in addition, an implant bridge on three implants was planned (Figs. 4a–f). In this case, what made the use of NobelGuide so attractive for patient, dental technician and surgeon?

Easier handling

Owing to the exact 3-D design with NobelGuide, the surgeon was able to proceed despite the reduced amount of available bone. A sinus lift was not necessary. It was possible to place all five implants without having to generate a flap, mini-

Fig. 5_The impression for preparation of the master model over teeth and implants was taken in the same surgical session.

Figs. 6 & 7_Procera Crowns Alumina and Procera Implant Bridges with screw retention at implant level.

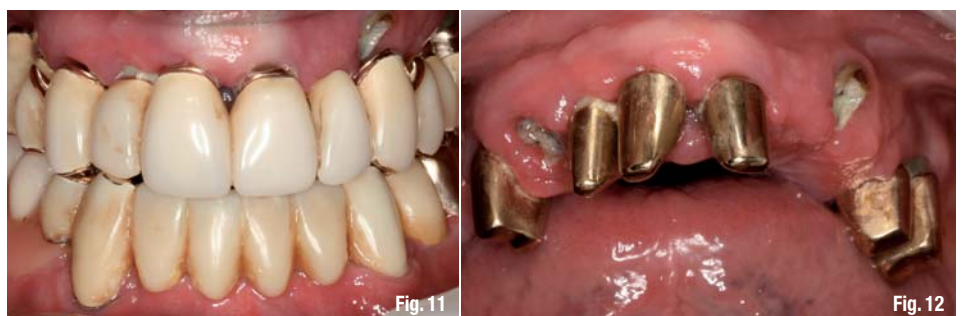Fig. 8_Screw-retained abutment and bridge are made of the same material.

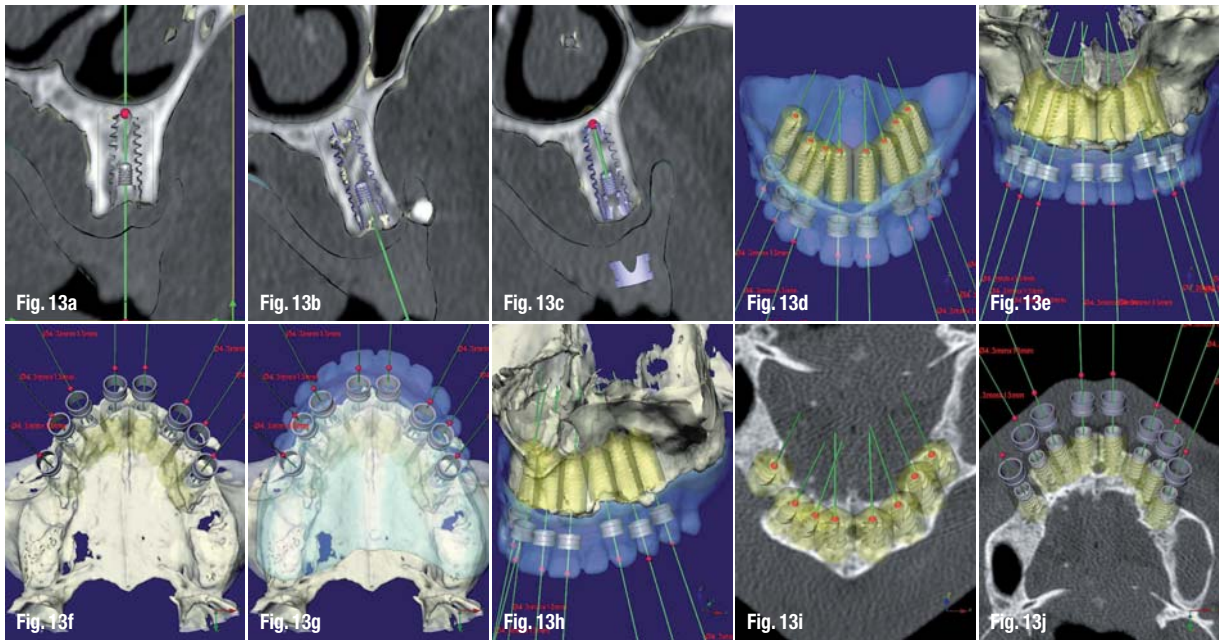
Fig. 9_Very high quality milled titanium material and no gingival irritation is caused by a cement gap, since there is no such gap.

Fig. 10_Optimal aesthetics and integration of restoration.

Fig. 11_Disastrous clinical situation.

Fig. 12_Teeth could not be conserved and had to be removed.





Figs. 13a–n_ Treatment plan.

misgiving the post-operative consequences such as pain, swelling and the formation of haematomas. Moreover, it allowed the impression for preparation of the master model over teeth and implants to be taken in the same surgical session (Fig. 5). The dental laboratory contributed to the production of the X-ray templates early in the planning phase, was familiarised with the case and involved in the discussion about the desired implant positions. The benefits for the patient included a safe operation, since the surgeon planned the entire operation beforehand and thus expected a predictable result. A difficulty in the present case was the relatively soft quality of the bone. Under these circumstances, NobelActive is beneficial for the experienced surgeon since it rotates into the bone much like a compression screw, which allows good primary stability to be attained.

The NobelActive implant

The TiUnite surface of NobelActive implants affords osseointegration down to the level of the implant shoulder rather than to just below the implant shoulder owing to the biological width of at least 1 mm as is customary for conventional

implants. This is associated with significant advantages for the aesthetics of the red–white transition. The gingiva is more stable and resection is less pronounced, which leads to the volume being maintained. This effect is of crucial importance for the success of an implant treatment in the anterior region, where aesthetic appearance is extremely significant.

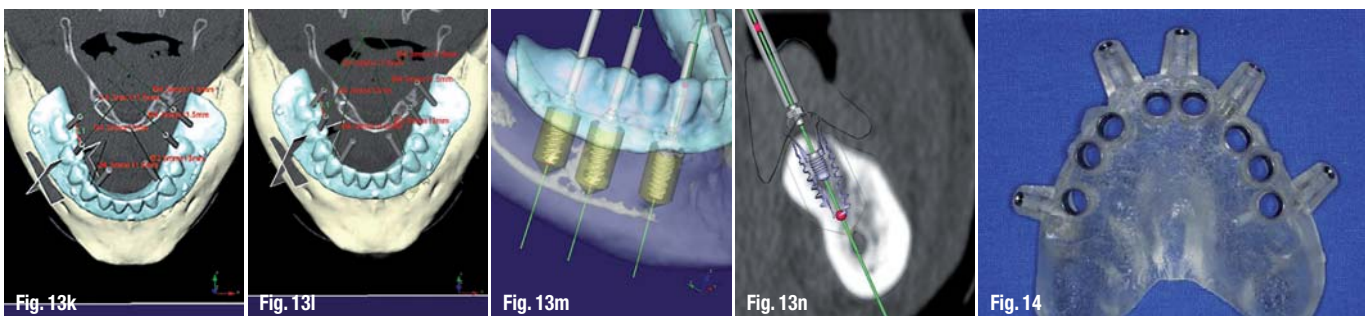
Ceramic-veneered and screw-retained implant bridges made of titanium

For dental management of the final restoration, CAD/CAM-fabricated Procera Implant Bridges with screw retention at implant level were produced. The available framework materials for this purpose are zirconium-oxide ceramics and titanium. Titanium was selected in the present case (Figs. 6 & 7).

Additional advantages of this technique are:

- _screw-retained abutment and bridge (Fig. 8);
- _tension-free framework;
- _bridge construction and implant are made of the same material;

Fig. 14_ Surgical template upper jaw.



DenTech China 2011


www.dentech.com.cn

The 15th China Int'l Exhibition & Symposium on Dental Equipment, Technology & Products

The 5th Asian Dental Lab Outsourcing Exhibition

October 26~29, 2011

The Expo Theme Pavilion, Shanghai, China



Approved by: Ministry of Science and Technology of the People's Republic of China

Sponsored by: China Association for Science and Technology / Chinese Stomatological Association / Shanghai Stomatological Association

Organized by: China International Conference Center for Science & Technology / Ninth People's Hospital, School of Medicine, Shanghai Jiao Tong University

Co-organized by: College of Stomatology, Shanghai Jiao Tong University / School of Stomatology, Tong Ji University /
Shanghai Stomatological Disease Center / Shanghai ShowStar Exhibition Service Co., Ltd.

If you are interested in participating or visiting the Exhibition, please fill the form below and fax or post to: Shanghai ShowStar Exhibition Service Co., Ltd.
Room 22C/D, Jiali Mansion, No. 1228, Yan'an Road (W), Shanghai 200052, China
Tel: 86-21-6294 6966 / 6294 6967 / 6294 6968. Fax: 86-21-6280 0908. E-mail: mail@showstar.net

I am interested in DenTech China 2011, please send me more information on

EXHIBITING

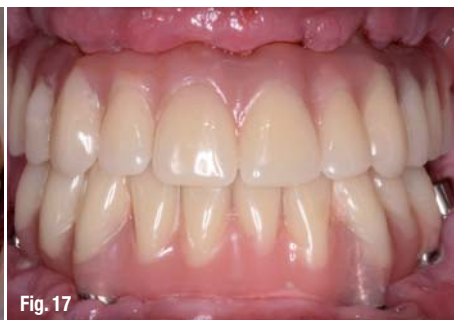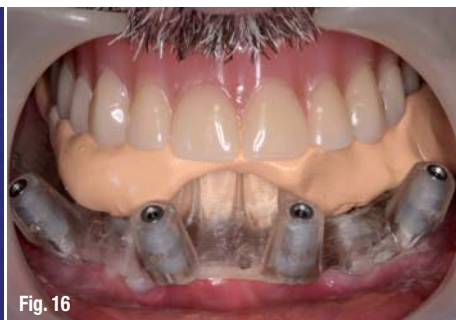VISITING

Name _____ Company _____

Address _____

Telephone _____ Fax _____

Zip _____ E-mail _____



Figs. 15 & 16 _A surgical template in combination with a specifically matched surgical kit allowed for exact transfer of the 3-D computer planning to the patient's mouth.
Fig. 17 _Fixed temporary bridges.

_very high quality milled titanium material;
_no problems with chipping;
_bridges are aesthetically pleasing and easy to remove; and
_no gingival irritation is caused by a cement gap, since there is no such gap (Fig. 9).

were tried-in during the same session. The definitive incorporation of the final restoration was only effected after a healing time of three months though. Owing to this specific surgical and prosthetic protocol, no additional session for try-in was required, which the patient considered very convenient (Fig. 10).

Screw-retained bridges and milled titanium are very popular forms of management today. Their production in the dental laboratory is no longer fraught with the earlier difficulties of cast titanium restorations, such as an alpha case layer. Accordingly, the veneering with titanium ceramic materials, made by VITA in the present case, has become much simpler. In a template-guided implant placement procedure, the axes are aligned such that the screw retentions can be implemented later exactly according to plan. This makes the work much easier and improves the quality of the restorations. Consequently, implant restorations can be achieved that are attractive to the patient owing to their reasonable pricing and high quality aesthetic appearance.

_Case II: Management of upper and lower jaw

It was easy to conclude from the initial situation of this case that the patient, a 63-year-old male, had eschewed visiting a dentist for a long time. Accordingly, the teeth were in need of much dental work (Fig. 11). Following a comprehensive diagnostic work-up, all teeth had to be removed, since they could not be conserved (Fig. 12). The patient was phobic and well aware of the poor condition of his teeth but had not perceived an adequate treatment option for his needs in the past. Talking to an acquaintance, he had been made aware of the availability of surgery with a template without "cutting" and detailed pre-surgical planning on a PC in order to minimise the attendant risks. By his own account, he would not have made the decision to have classical surgery. For the surgeon, the outcome obtained in this case would not have been possible without this technique except with much difficulty and significantly more surgical effort and trauma.

Procedure according to treatment plan

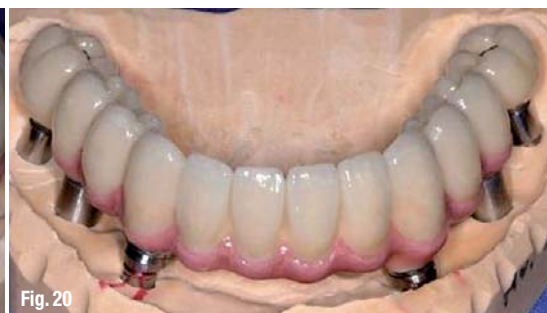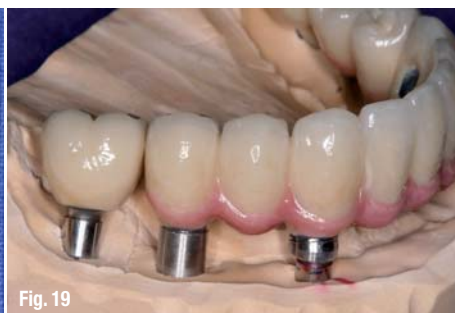It is very convenient for the treatment team to be able to proceed according to a detailed plan. Each member of the team is aware of all tasks and

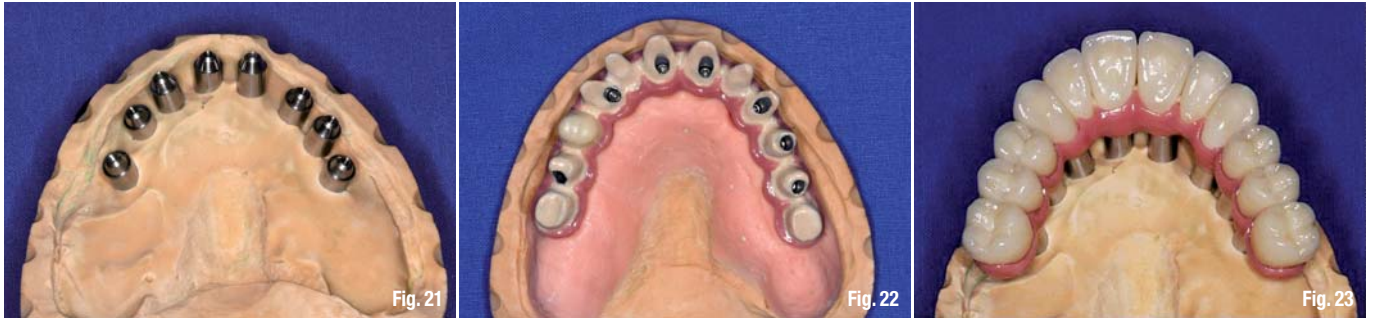Figs. 18a & b _The terminal molars (teeth #36 and 46) were fabricated as titanium single tooth crowns and screw-retained at implant level.

Fig. 19 _Distal-splinting in the lower jaw.

Fig. 20 _The Procera Implant Bridge Titanium on multi-unit abutments was veneered completely, including gingival regions, using VITA titanium ceramic.

In this case, the master impression was taken during the surgical session. With respect to the skull, the models were mounted in an articulator by means of face-bow transfer via the impression posts. The natural teeth were treated with NobelProcera Crowns Alumina, which is another CAD/CAM-based method for fabricating all-ceramic dental restorations. For this purpose, a framework coping and the implant frameworks were tried-in at the subsequent session. At the third session already, the tooth-borne crowns were incorporated and the finished implant bridges





when they need to be addressed. In particular, the prosthetic pre-surgical planning, which is of great importance, attains a completely new function as it can be compared, in a quality management approach, to the final result obtained after the treatment is completed in order to determine the degree to which the plan was actually implemented. Following radiological digitalisation of the patient by means of a double-scanning procedure and conversion to virtual 3-D models, the surgeon can start to design the implants. In the present case, we planned to place six implants in the lower and eight in the upper jaw (Figs. 13a–n). The transitional dentures required after extraction of the residual teeth also served as scanning templates (Fig. 14).

Surgery

In cases of a large number of implants to be placed, our team likes to implement a two-stage implant placement procedure. The lower jaw implants are inserted on the first and the upper jaw implants on the subsequent day. The patient was not subjected to general anaesthesia. It was possible to treat the phobic patient only with local anaesthesia without any problems. The surgical template used in combination with a specifically matched surgical kit allowed for exact transfer of the 3-D computer planning to the patient's mouth (Figs. 15 & 16). As in the first case, NobelActive implants were inserted, which afforded good primary stability even under the strongly reduced bone conditions present in this case. This is owing to the special surface and the design of the implants. Following surgery, fixed temporary

bridges, which had been fabricated ahead of time based on the existing planning, were inserted (Fig. 17).

Procera Implant Bridge

As before, the definitive form of management selected in this case was a NobelProcera CAD/CAM restoration. There were some particularities to take into account in the management of both the lower and the upper jaw. The true quality of the teamwork of dental office and laboratory becomes evident in the smooth production of very sophisticated rehabilitative restorations that can be fabricated without complication and incorporated into the stomatognathic system of the patient without any difficulties.

As part of the production of the restorations for the lower jaw, the terminal molars (teeth #36 and 46) were fabricated as titanium single tooth crowns and screw-retained at implant level (Figs. 18 a & b). It was thus possible to take into account the 3-D twist of the arching lower jaw bone such that tensions at the level of the distal implants were prevented, which might otherwise have caused bone loss or even implant loss. We only splinted inter-foraminally in the lower jaw, between teeth #35 to 45 (Fig. 19). A distal cantilevered pontic substituting for teeth #36 and 46 was not used in this case, as implants #45 and 35 were only NobelActive implants with a diameter of 3.5 mm. The Procera Implant Bridge Titanium on multi-unit abutments from teeth #35 to 45 was veneered completely, including gingival regions, using VITA titanium ceramic (Fig. 20). As before,

Figs. 21 & 22_The framework was veneered with a gingiva-coloured ceramic material and opaquer was attached in the region of the stumps.
Fig. 23_Model with Procera alumina single crowns.

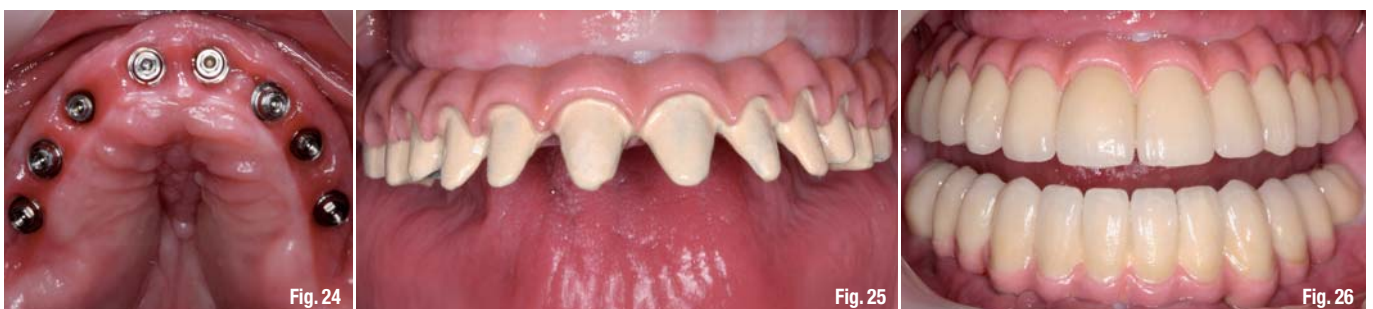

Fig. 24_Situation *in situ* with multi-unit abutments.
Fig. 25_Procera Implant Bridge *in situ* before crown cementation.
Fig. 26_Aesthetic appearance at the red–white transition.

it was feasible to implement the screw retentions exactly according to plan such that no adverse aesthetic effects arose. The far-reaching bridge was fabricated at the Nobel Biocare milling centre and was prepared for the veneering steps with only little time required for minor details of post-production processing. Thanks to CAD/CAM technology, it is possible to generate frameworks that are truly free of tension. In this context, Nobel Biocare guarantees a precision of fit of less than 25 µm.

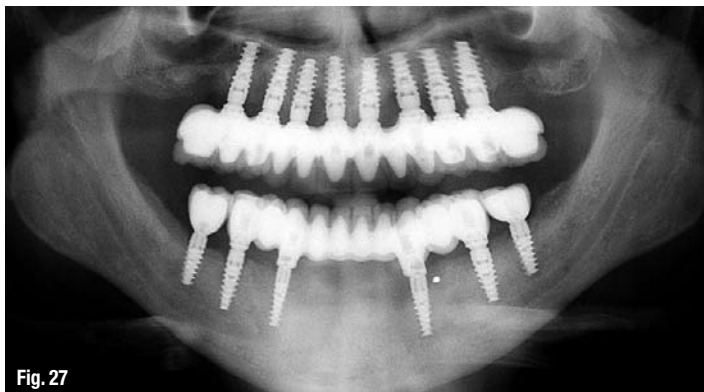

Fig. 27

Fig. 27_Panoramic X-ray.

For aesthetic reasons, an elaborate form of restoration was selected for the upper jaw. A Procera Implant Bridge Titanium on multi-unit abutments was produced. The bridge was designed to allow all-ceramic NobelProcera Crowns Alumina to be cemented to them. For this purpose, the framework was veneered with a gingiva-coloured ceramic material and opaquer was attached in the region of the stumps by firing (Figs. 21 & 22). In the next step, the single crowns were prepared (Fig. 23). After completion of the entire restoration, the basic framework was screw-retained in the mouth (Fig. 24) and the aesthetic Procera alumina single crowns were cemented in the mouth using conventional cement (Durelon, 3M ESPE; Fig. 25). Accordingly, the patient's restoration was still conditionally removable in the dental office, since the crowns covering the screw channels remained removable. This is advantageous for the patient in that the aesthetic appearance of the upper jaw can be improved even further, while no screw channels are visible. This resulted in an excellent aesthetic appearance at the red-white transition (Figs. 26 & 27).

Conclusion

In this article we have demonstrated a dental team being able to offer treatment based on a one-provider concept that starts with a 3-D diagnostic work-up, allows for template-guided navigated implant placement, keeps in stock all implant and prosthetic components (as typifies the concept of

Nobel Biocare), and offers numerous advantages, including:

- _ application of a broad range of different techniques from a single supplier;
- _ only a single supplier needs to be contacted;
- _ implant and prosthetic components match;
- _ interfaces match;
- _ materials match;
- _ final result has a high precision of fit;
- _ generous solutions if difficulties are encountered; and
- _ custom-made designs for special needs.

Approaching the planning and implementation of an implant-borne restoration from the patient's perspective and his or her needs will always cause the treatment team to place safety very high up on the list of its priorities. Based on the reliable NobelGuide concept, the success of the team becomes a matter of planning. To have but a single supplier to contact for all necessary components saves time and the attending team can rely on the perfect match of all components. Another aspect that should not be underestimated is the increasing number of litigations after unsuccessful outcomes. Products that have been tested in numerous scientific studies provide the needed validity. 3-D planned and template-guided implant placement, aesthetically pleasing forms of restoration, and a long service life of the restorations also appeal to the patients.

The dental office of Drs Grebe periodically organises courses in 3-D implantology and CAD/CAM prosthetics for dentists and dental technicians. If you are interested, please enquire about the dates of upcoming events by e-mail.

We would like to thank our dental technicians Michaela Schenker, Frank Rödel and Jörg Parsaksen for their support.

Editorial note: A list of references is available from the authors.

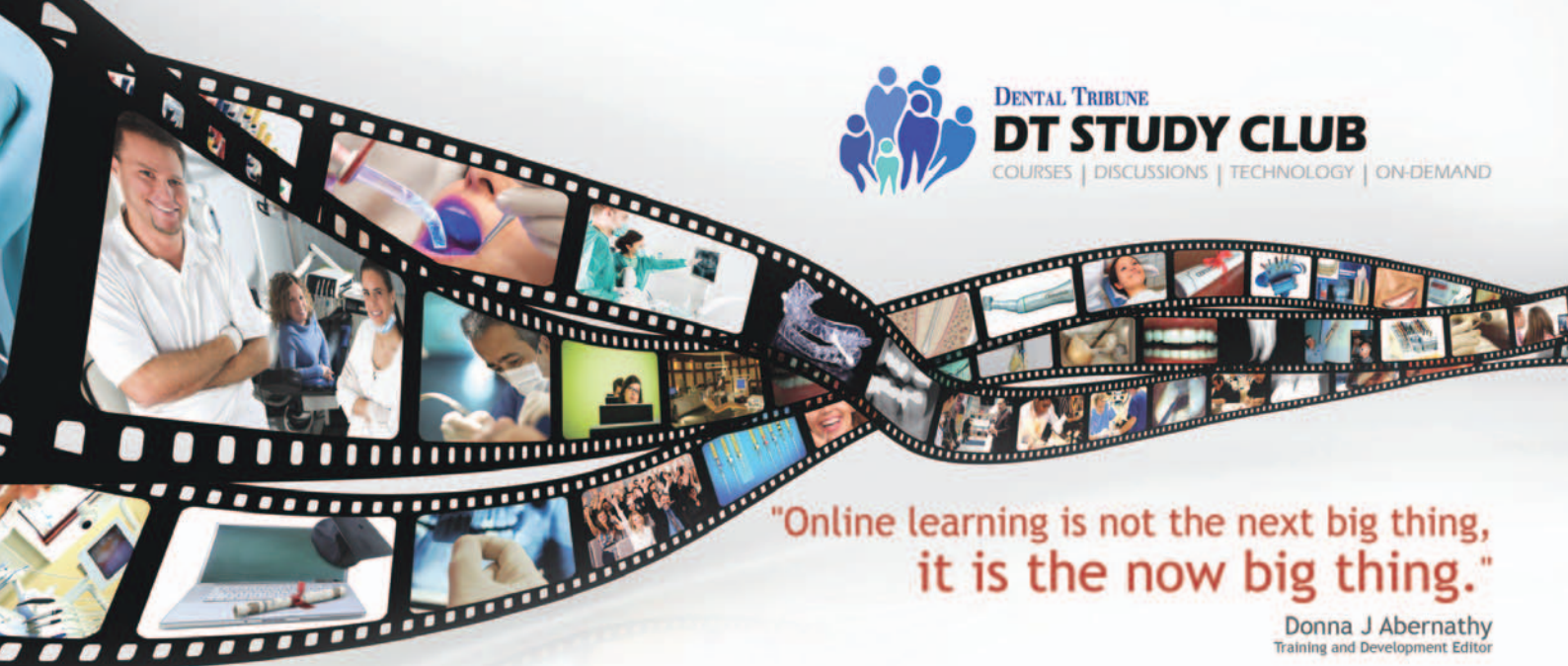_contact	CAD/CAM
<p>Dr Götz Grebe & Dr Melanie Grebe Schwanenwall 10 44135 Dortmund Germany</p> <p>praxis@dr-grebe.de www.dr-grebe.de</p>	



DENTAL TRIBUNE

DT STUDY CLUB

COURSES | DISCUSSIONS | TECHNOLOGY | ON-DEMAND



**"Online learning is not the next big thing,
it is the now big thing."**

Donna J Abernathy
Training and Development Editor

DTSC - COURSES, COMMUNITY, TECHNOLOGY, ON-DEMAND

The DT Study Club makes all of this is possible from the comfort of your own computer and without travel expenses. In other words, welcome to the community!

The purpose of this study club is to provide practitioners like yourself an opportunity to learn and network with like-minded colleagues in a friendly, non-threatening environment. We encourage you to take advantage of Dental Tribune's global outreach to access a variety of fresh perspectives and cultures, enhancing your educational mix.

24/7 LIVE AND INTERACTIVE ONLINE COURSES

Fulfill your yearly CE requirements with our growing list of archived ADA CERP approved courses.



DISCUSSION FORUMS

focused on helping today's practitioners to stay up to date. Networking possibilities that go beyond borders to create a truly Global Dental Village



VIDEO REVIEWS OF PRODUCTS

Our opinion leaders unveil new products, services, and give you their first impressions of the industry's hottest topics.



PEER REVIEWED CASE STUDIES

Upload, comment, participate. We encourage you to share your cases for review with like-minded practitioners.



 REGISTER FOR FREE ON WWW.DTSTUDYCLUB.COM

CONTESTS WITH CHANCES TO WIN FREE TUITION FOR ADA/CERP C.E. ACCREDITED WEBINARS

SPONSORSHIP AND SPEAKING INQUIRIES:
JULIA WEHKAMP, J.WEHKAMP@DTSTUDYCLUB.COM, (416) 907-9836.

ADACERP
CONTINUING EDUCATION RECOGNITION PROGRAM



PRACTICE MANAGEMENT



GENERAL DENTISTRY



COSMETICS



ENDODONTICS



IMPLANTOLOGY



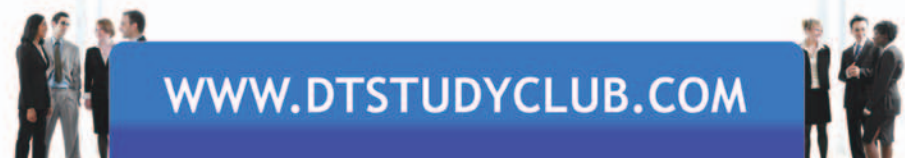
PERIODONTICS



ORTHODONTICS



DENTAL HYGIENE



WWW.DTSTUDYCLUB.COM

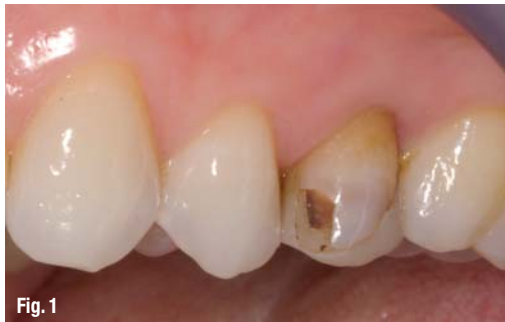Computer-aided crown design

Author | Dr Andreas Bindl, Switzerland

CAD/CAM technology allows dental professionals to manufacture solid all-ceramic crowns chairside. A digital image of the preparation is captured with an intra-oral camera and the crown is designed accordingly. A variety of ceramics are

(LS₂) that demonstrates a flexural strength of 360 MPa. This ceramic is machined to the desired shape while it is still in its metasilicate or 'blue' state (approximately 130 MPa). Subsequently, the ceramic is crystallised for 20 minutes. During this process, the material attains its final state and develops its excellent mechanical and aesthetic properties.

Fig. 1 Pre-op situation: The buccal wall of tooth #25 is cracked and features a large damaged composite filling, a clear indication for a crown.



available for the construction of the crown, for example an aesthetic, easy-to-mill ceramic (IPS Empress CAD, Ivoclar Vivadent). As this leucite glass-ceramic is weaker than zirconium oxide, these crowns must be seated using the adhesive technique (for example with Syntac/Variolink II or Multilink Automix). This makes them strong enough to withstand the masticatory forces in the long term.

IPSe.maxCAD is available in a low-translucency (LT) version, which is suitable for the fabrication of crowns and implant-retained crowns. The high-translucency form is intended for the construction of inlays and partial crowns. The stains and glaze are applied before the crystallisation process. As a result, subsequent polishing is unnecessary. Owing to the high strength of the restoration, adhesive cementation with a separate dentine conditioner is not indicated as long as the thickness of the ceramic does not fall below 1.5 mm. Self-adhesive cementation materials can be used. The new self-adhesive composite cement SpeedCEM is particularly suitable for this purpose.

IPSe.max CAD, which has been on the market for some time, is a lithium-disilicate glass-ceramic

The chairside creation of a crown is described on the basis of a clinical case using IPSe.max CAD LT and the new SpeedCEM luting cement.

Fig. 2 A digital impression is taken of the preparation, as well as the antagonists and the situation in centric occlusion (CEREC Bluecam, Sirona) from the buccal aspect (middle).

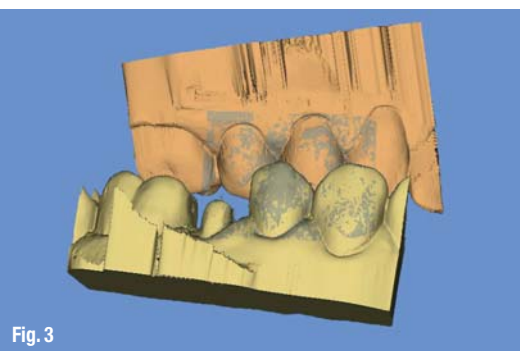
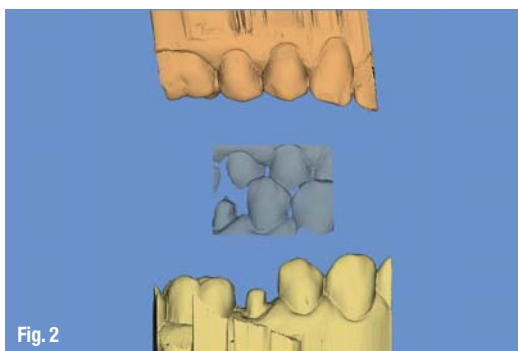


Fig. 3 Semi-automatic alignment of the upper and lower jaw models with the help of the buccal image.

Fig. 4 The biogeneric crown software designs an occlusal surface according to the individual situation.

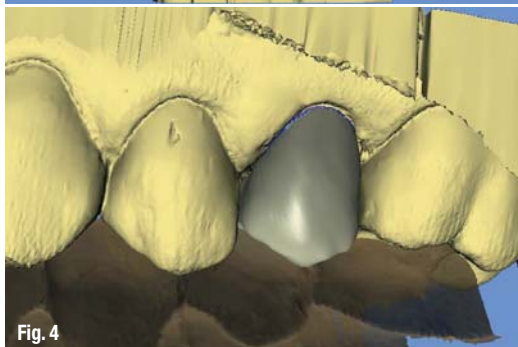
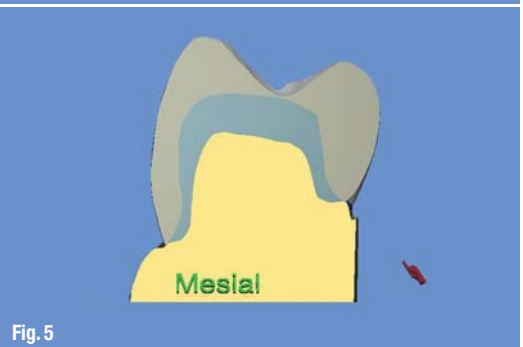
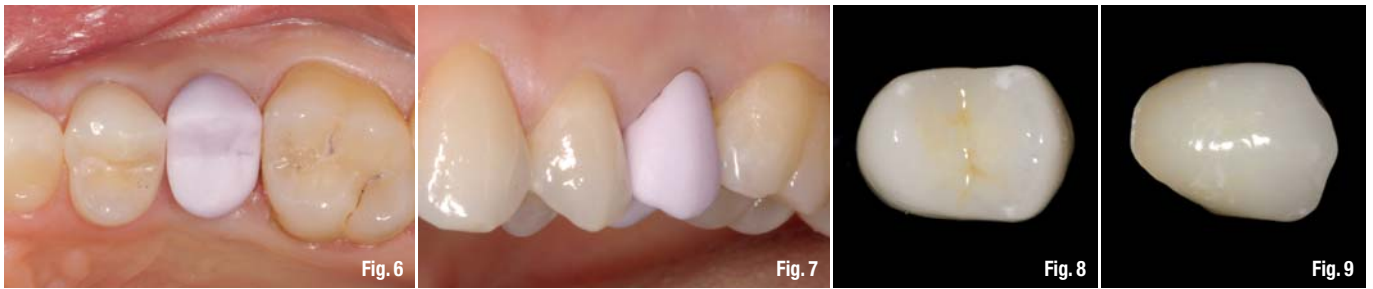

Fig. 5 Bucco-oral cross-section of the restoration. The minimum occlusal thickness of 1.5 mm is checked.





Clinical case study

Tooth #25 of a 32-year-old female patient was restored with a crown owing to extensive destruction of the dental hard tissue (Fig. 1). First, the tooth was prepared with a shoulder of approximately 1.0 mm in width (epigingivally). Subsequently, the preparation was dusted with IPS Contrast Spray and a digital impression was taken with the CEREC Bluecam camera (Sirona). The new CEREC software (version 3.80) generates a visual image of the an-

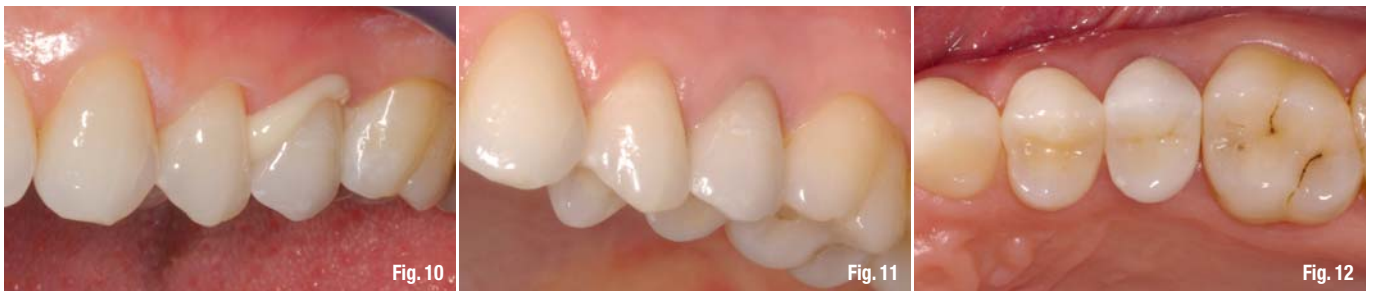surfaces of the crown. The spray was applied several times. Once the restoration had been fully coated with a white-opaque glaze layer, the crown was fired in a combined crystallisation and firing process in the Programat CS furnace (Figs. 8 & 9). Before the restoration was cemented in place, the inner surface of the crown was etched with 4.9 % hydrofluoric acid (IPS Ceramic Etching Gel) for 20 seconds. Subsequently, it was silanised for 60 seconds (Monobond Plus). The crown lumen was filled with the self-adhesive SpeedCEM. Next, the

Fig. 6_Occlusal view of the crown in the 'blue' state during try-in, before crystallisation firing.

Fig. 7_Buccal view of the crown in the 'blue' state during try-in, before crystallisation firing.

Fig. 8_Occlusal view of the crystallised and glazed crown on tooth #25.

Fig. 9_Buccal view of the crystallised and glazed crown on tooth #25.



tagonists, which replaces the centric bite record. In order to match the upper and lower teeth, an image of the centric situation is captured from the buccal aspect (Fig. 2). The upper and lower teeth are matched semi-automatically (Fig. 3). The 3.80 version is capable of designing biogeneric occlusal surfaces for full crowns. The software provides a design proposal for the tooth morphology, which is based on the occlusal surface of the distal neighbouring tooth and the antagonist (Fig. 4). The image of the bucco-oral cross-section of the crown allows the user to check the minimum occlusal thickness of 1.5 mm (Fig. 5). The minimal densification of the ceramic (0.2 vol%) during the crystallisation process is taken into account by the software and adjusted accordingly.

crown was securely seated on the prepared tooth by applying even pressure (Fig. 10). The cement residue was polymerised for one second per surface (mesio-oral, disto-oral, mesiobuccal, distobuccal) with a curing light (bluephase in the low-power mode) at a distance of about 5 mm. In this cured state, the cement was removed with great care using a scaler and a probe. The cement was fully cured with the bluephase in the high-power mode. Subsequently, the cement margin was polished. The final inspection revealed the restoration to be in harmony with the overall situation (Figs. 11 & 12).

Fig. 10_Cementation of the crown with the dual-curing, self-adhesive luting composite SpeedCEM.

Fig. 11_Buccal view of the crown seated with a self-adhesive luting cement after the clean-up of excess.

Fig. 12_Occlusal view of the crown seated with self-adhesive luting composite.

After the crown had been milled, the proximal and occlusal contacts were adjusted on the patient (Figs. 6 & 7). In this case, the 'white' and 'crème' materials from the corresponding stains assortment (IPS e.max CAD Crystall./Stains) were sparingly applied to the cusp tips and the 'sunset' material to the tooth neck and in the fissures. Immediately afterwards, a glaze in spray form (IPS e.max CAD Crystall./Glaze Spray) was applied to the outer

_contact

CAD/CAM



Dr Andreas Bindl

Station für Zahnfarbene & Computer-Restaurationen
Praxis am Zürichberg
Attenhoferstrasse 8a
8032 Zurich
Switzerland

andreas.bindl@bluewin.ch

No more one-way streets

Author _ Thomas Dürr, Germany

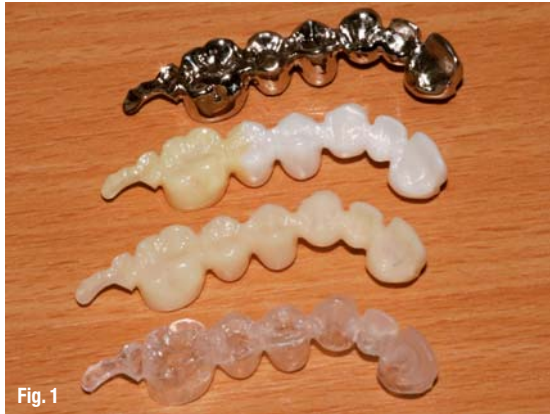

Fig. 1

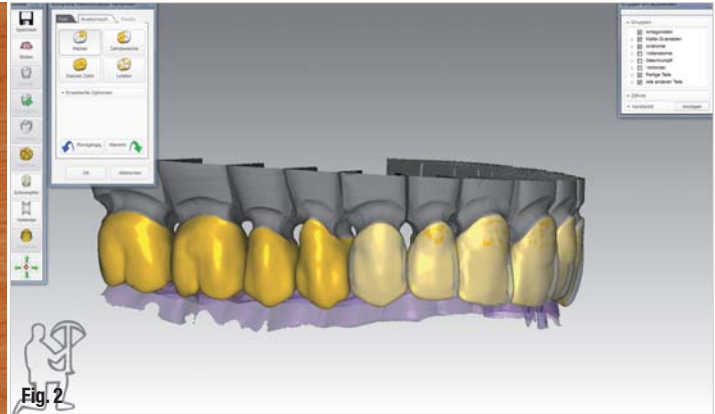


Fig. 2

Fig. 1 _ A versatile system, Tizian mills metal, ZrO₂, composite, burn-out plastics and PMMA.

Fig. 2 _ Quick assistance—the restoration is created digitally in only a few work steps.

_Dental technicians, who wish to produce high-class dental restorations and therefore need to select a particular CAD/CAM system, will quickly discover that the choice of materials and production procedures is limited. This is quite disagreeable, especially because in the majority of cases the cost of such systems is enormous. Presently, the market provides an abundance of mechanical and CAD/CAM systems. To prevent losing track of the choices, one must be aware that CAD/CAM is only profitable if expenditure is low and the system is suitable for a large range of applications. Furthermore, it is important that the added value remain with the laboratory and that the software is easy to use, even for dental technicians with little previous computer knowledge. For these reasons, master dental technician (MDT) Michael Anger uses the open Tizian CAD/CAM system (Schütz Dental), which offers a high degree of personal and creative freedom.

Zirconium dioxide (ZrO₂) is the material of choice for dental restorations. The material is strong, biocompatible, free of corrosion and long-lasting, the edges do not darken and it conducts heat in a simi-

lar way to natural teeth. The dense, smooth surface is conducive to a hygienic and clean situation inside the mouth. However, ZrO₂ is difficult to handle. It is so hard that it is extremely difficult to machine once it has been sintered. Therefore, it is advisable to mill the restorations before sintering the material.

_Flexibility without narrow confines

Anger and the 32 employees of his laboratory in Remagen in Germany have specialised in restorations produced from this next-generation material for quite some time. Aside from crowns and bridges, they produce inlays, as well as implant and attachment restorations from ZrO₂. For this purpose, Anger invested in a Tizian CAD/CAM system, which he and his colleagues use to scan, design and mill. The reason for his decision is that in contrast to other systems, Tizian CAD/CAM is not limited or regulated in its possibilities. "The scanner features an open data interface, which means that we are not dependent on certain software or on only one single manufacturing method," Anger states. He appreciates this freedom, as it allows him to react flexibly to his customers'

Fig. 3 _ Efficient material saving—optimal use of blanks with Tizian CAD/CAM.

Fig. 4 _ Reacts flexibly—Anger has had success using pin attachments in cases of strongly divergent insertion directions.




Fig. 3

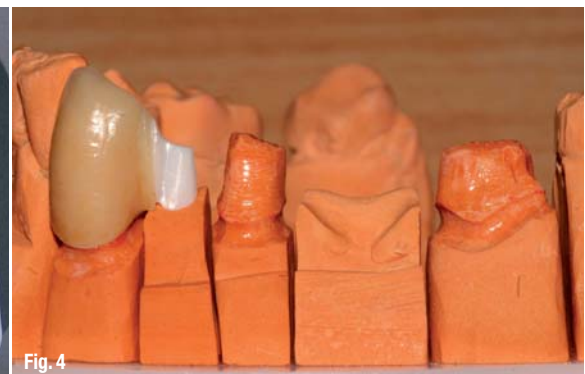


Fig. 4

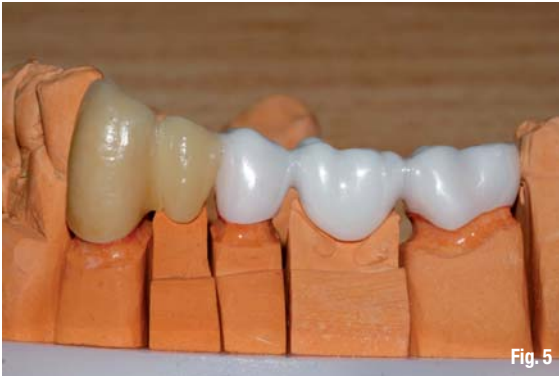

Fig. 5

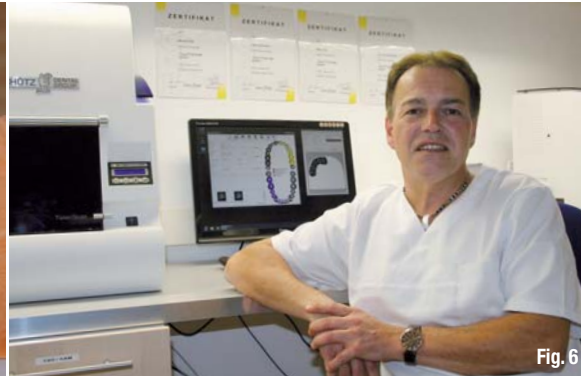

Fig. 6

wishes and their individual requirements (Fig. 1). "Tizian CAD/CAM allows us to machine not only ZrO₂ blanks, but also blanks made of wax, composite or PMMA." In addition, Anger is able to have restorations produced from gold, non-precious alloys and titanium at any specialised milling centre.

Simply a matter of greater choice

The system's procedure is easy. A saw-cut model made from plaster is fixed inside the scanner. Then, the customer's data is entered and an outline scan is carried out. Subsequently, Tizian Scan scans the details. The scanner recognises even complicated geometries after determining separate points. "It takes only eight minutes to scan a three-unit bridge. The scan of a complete jaw takes no longer than 24 minutes, depending on the remaining dentition," Anger describes and adds, "At the same time, the model is displayed on screen so that the user can optionally create fully anatomic crowns and bridges, telescopes and conic crowns, inlays, onlays and veneers or even Maryland bridges and models for the overpressing technique." To make this even easier, Tizian users have open access to tooth and pontic libraries (Fig. 2). "This way, the desired restoration is created in only a few work steps and the user can adjust the diameters of connectors, the wall thicknesses and the sizes of the cement gaps up to the very last step and determine them individually," according to Anger.

Mill at low cost, offer at low cost

As all data is created in the universal STL format, Anger can send it to specialised production centres of his choice. However, as all Tizian components are exceptionally well matched and give Anger the full choice of materials, he mills the restorations at his own laboratory. In addition, he does subcontractor jobs for other laboratories. At the same time, the production cost with Tizian Cut is so low that Anger can offer high-quality, biocompatible ZrO₂ restorations to his patients at competitive prices. He is even offering a special promotion on uncoloured ZrO₂ as a white alternative to silver-coloured non-precious alloy

frameworks. The vestibular surfaces of these uncoloured ZrO₂ restorations are veneered at such a favourable price that this is fully covered by the patient's health insurance.

Anger can mill bridges of up to 16 units with Tizian Cut and at the same time work economically with regard to raw material, as Tizian Cut uses the blanks optimally (Fig. 3). He has also had success with pin attachments, which he uses in cases in which the prosthetic insertion direction of a prepared stump is so divergent that it cannot be treated using conventional restoration techniques (Figs. 4 & 5). The dental technicians at Anger dental laboratory prefer to use ZrO₂ for primary crowns in combination with secondary parts made from galvanic gold or in conjunction with implant abutments.

Fascinating freedom

ZrO₂ is the perfect material for almost all forms of dental restoration. Its physical and biological properties account for the fact that the material can be used almost without limit in dental technology. "The Tizian system offers a great basis for our work and a multitude of different scopes for design." Anger further states that the system's easy menu navigation and free choice of all important parameters give him and his colleagues the necessary freedom of design they need and desire (Fig. 6). "This finally gets us out of the one-way street of the dependency of closed systems."

Fig. 5 White alternative— Anger offers pure white ZrO₂ as an alternative to silver non-precious alloy frameworks and integrates pin attachments in cases of divergent insertion directions.

Fig. 6 Appreciates his freedom of design—MDT Michael Anger.

contact

CAD/CAM

Schütz Dental GmbH
Dieselstr. 5–6
61191 Rosbach
Germany

info@schuetz-dental.de
www.schuetz-dental.de

Please visit us at IDS: Hall 10.1, Booth G010

ZENOTEK easy— Cost effective and professional

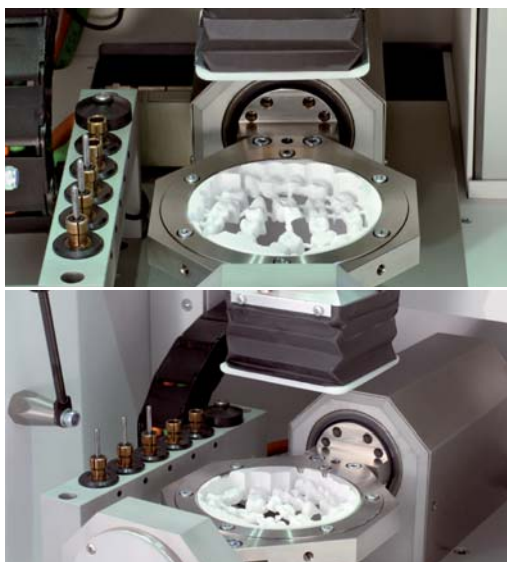The ZENOTEK easy milling unit offers users the opportunity to enter the world of CAD/CAM professional technology at a low cost level. It is space-saving and mills efficiently, even full contour restorations using four-axis machining. The reduced operating interface of the control PC supplied with the unit makes it very easy to use, without limiting its possibilities. ZENOTEK easy provides integrated, highly precise tool length measurement, as well as new control software and thus improves safety with manufactured restorations.

ZENOTEK easy allows for a free choice within the WIELAND material range, which covers the whole spectrum: zirconia or alumina discs, plastic (PMMA) or wax discs.

ZENOTEK CAM 3.2 advanced is a license free, easy-to-use software. Jobs are selected for milling using the drag & drop function and can be sent directly from the CAM interface to the milling unit. The software automatically selects the right



milling strategy for the restoration, depending on the material. Experienced users have the option of adapting milling strategies to their needs. A special software strategy has been developed for ZENOSTAR restoration to balance both quality and milling speed. Fully anatomical ZENOSTAR restorations are possible with the aid of the coordinated peripheries of scanners, CAD/CAM programmes, a sintering furnace and a broad, indication-specific material range.



_contact

CAD/CAM

WIELAND Dental + Technik GmbH & Co. KG
Schwenninger Str. 13
75179 Pforzheim
Germany

www.wieland-dental.de

Please visit us at IDS: Hall 10.1, Booth F018

Sensable Dental gets its IPS e.max on!

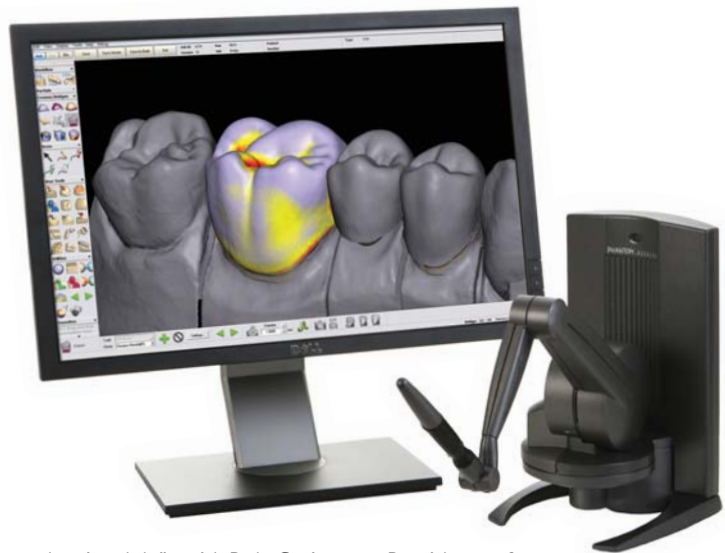The award-winning Intellifit Digital Restoration System manufactured by Sensable Dental, a division of Sensable, now offers more choice and flexibility in designing dental restorations for pressing in the popular IPS e.max all-ceramic material from Ivoclar Vivadent. Dental laboratories using Intellifit can design and fabricate pressed veneers, full-ceramic crowns and bridges in-house extremely efficiently, using IPS e.max to create strong and highly aesthetic restorations.

With restorations fabricated in glass-ceramic materials like IPS e.max skyrocketing—growing from 40% to an estimated 70% of the overall ceramic market by 2015 as measured by number of ceramic units—laboratories are seeking new options using IPS e.max. As Intellifit supports multiple restoration types and fabrication techniques, including pressing IPS e.max, dental laboratories of all sizes can now gain a competitive advantage by offering these restorations. The IPS e.max pressing material is especially well-suited for creating ultra-thin veneers, crowns and bridges because of its colour, translucency and exceptional strength.

"We use the Intellifit system to create IPS e.max pressable restorations that we offer including monolithic crowns, bridges, and prepped veneers," said Kristine van Cleve, President of Dental Prosthetic Services in Cedar Rapids, Iowa. "The system streamlines the pressing process by allowing us to quickly create customised digital tooth designs that perfectly match adjacent teeth and include a tremendous level of surface detail. And, if a mis-press occurs, we can instantly print another resin pattern and re-press much faster than if we had to re-wax the design by hand."

Pressing IPS e.max is another fabrication choice for laboratories using the Intellifit Digital Restoration System. With new veneer design capabilities and integrated digital tooth libraries, technicians can easily design restorations that are printed in 3-D investable resins and then pressed in IPS e.max. Laboratory technicians of varying skill levels can deliver consistent, precise-fitting restorations in

a fraction of the time of hand-waxing, since the Intellifit workflow speeds up and streamlines the number of steps required to produce high-quality pressed restorations. "Intellifit, with its virtual waxing paradigm and our commitment to system integration, provides more design flexibility and more proven fabrication choices than any other dental CAD/CAM system in the market, allowing for a truly



productive lab," said Bob Steingart, President of Sensable Dental. "With tremendous materials like IPS e.max, we want to enable laboratories to use it their way and for a variety of restorations. As the economy forces dental laboratories to re-examine their productivity, Sensable offers laboratories practical solutions to better serve their doctors while achieving a strong return on investment."

_contact

CAD/CAM

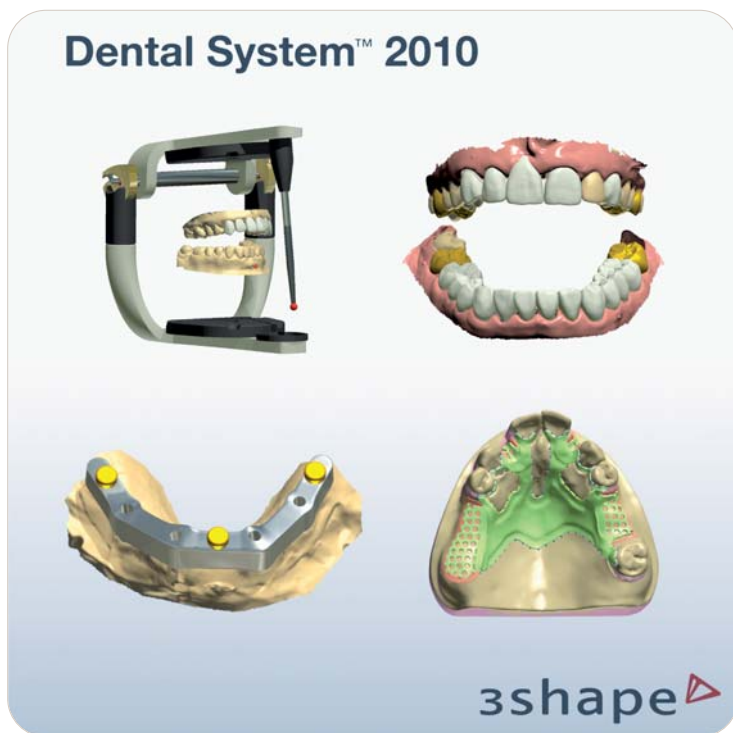Sensable Dental

181 Ballardvale Street
Wilmington, MA 01887
USA

www.sensabledental.com

Please visit us at IDS: Hall 4.1, Booth F031

3Shape releases Dental System 2010



3Shape A/S has released its next generation Dental System 2010. This software for Dental CAD/CAM solutions brings new and highly sophisticated indications never before seen in the digital arena, offering productivity and business gains for dental laboratories.

New Dental System 2010 features include simultaneous modelling on the upper and lower jaw, Dynamic Virtual Articulation, the market's fastest digital design of removable partials, SmileComposer with mirror and clone functionality for designing aesthetic full anatomy bridges, sophisticated design of implant bars, virtual addition of attachments for any indication and many more powerful features.

Tais Clausen, CTO and 3Shape co-founder, has already demonstrated Dental System 2010 to hundreds of dental professionals at seven different locations in the US. "Attendees were very impressed with the many new features," Clausen

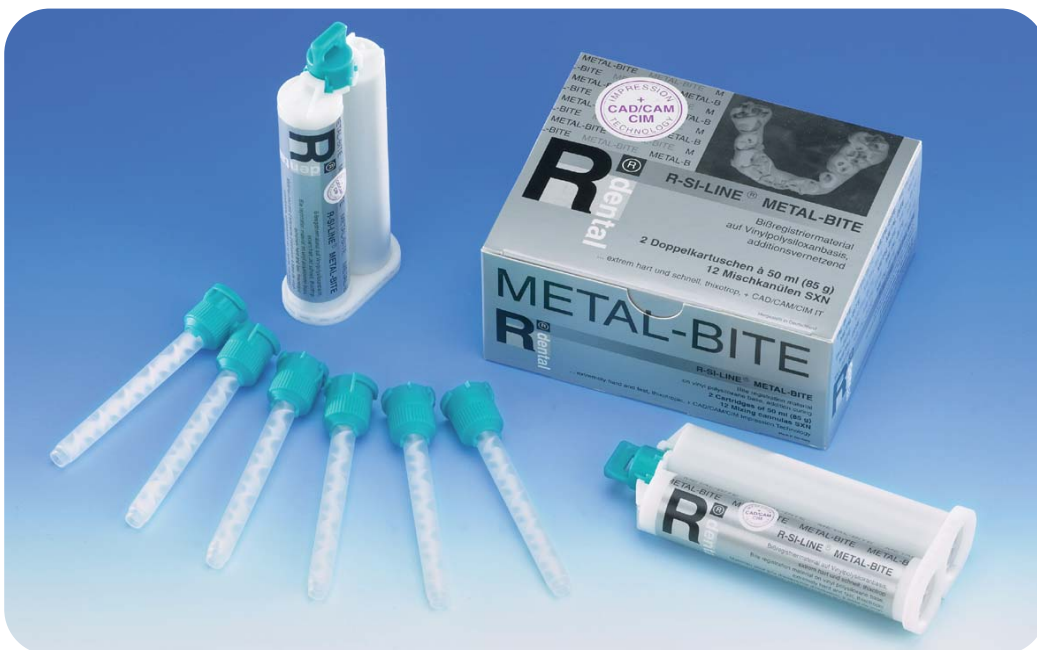commented, "but they were also very happy to see that 3Shape has improved and strengthened Dental System's basic engine functionalities such as copings, bridges and abutment design, making these essential indications even faster and easier to design."

Selected dental laboratories have been using Dental System 2010 and evaluating its performance with actual customer cases. Kurt Reichel, founder and owner of Kurt Reichel Dental Lab, is already providing restorations using the latest Dental System 2010 features. "It's like driving a sleek vehicle with enormous engine power," Reichel said. "Dental System 2010's new SmileComposer and Dynamic Virtual Articulation have speed up our workflow significantly, while ensuring new levels of aesthetics and consistent results. The new partial design software has opened up a whole new profitable service area for my business."

The new Dental System 2010 cements 3Shape's position as market leader in the rapidly evolving CAD/CAM dental business environment. 3Shape has released Dental System 2010 to its partners, who will be providing it to end-users in the course of the next few months. Please contact your local supplier, or visit www.3shape.com regarding availability, reseller and purchasing information.

_contact	CAD/CAM
<p>3Shape A/S Holmens Kanal 7 1060 Copenhagen K Denmark</p> <p>info@3shape.com www.3shape.com</p> <p>Please visit us at IDS: Hall 10.2, Booth M039</p>	

R-SI-LINE METAL-BITE— Perfect bite registration



For more than a decade, R-dental has offered METAL-BITE, a universal and the first scanable registration material recommended by Sirona for CEREC applications. METAL-BITE is the standard in dental registration and dental CAD/CAM registration. While it can be used for universal registration, according to German opinion leader Prof Alexander Gutowski, it is suitable for the biteplate of face-bow registration, as well as for dynamic registration (FGP technique).

The scanable METAL-BITE offers ideal physical properties: it is extremely fast-setting and hard, thixotropic and high standable. The snap-set guarantees the highest precision. Once cured, METAL-BITE is inflexible and strong, with a sufficiently long working time. It can also easily be cut and contoured. A high Shore D hardness (40) and high dimension stability are convincing

advantages of the dark grey A-silicone. This universal registration material is available in commercial cartridges. The company R-dental Dentalerzeugnisse GmbH was founded in Hamburg in 1995 with the aim of providing high-quality, premium products to dentists.

_contact

CAD/CAM

R-dental Dentalerzeugnisse GmbH

Winterhuder Weg 88
22085 Hamburg
Germany

info@r-dental.com
www.r-dental.com

Please visit us at IDS: Hall 4.2, Booth N090

NewTom VGi adds variable FOV feature

_ImageWorks has added a new feature to the NewTom VGi, the professional's choice of Cone Beam 3-D scanners, making it the first 3-D scanner unit to capture both high resolution

images and large volume functionality in a single machine. The new collimation allows the NewTom VGi to obtain resolutions as fine as 0.075 mm voxel, giving the operator the ability to acquire a large 15 cm X 15 cm field of view (FOV) scan when needed. Additionally, it offers four new FOV options, with each of the now seven FOV's having four separate possible voxel sizes.



Already known for its superb image quality amongst oral and maxillofacial radiologists, imaging centres and the new entrepreneurial mobile imaging centres, the new variable FOV feature further enhances the value these experts place on the NewTom VGi.

Michael Ellison, Director of Marketing and Sales for NewTom commented, "This is one of the most significant upgrades we have seen from any CBCT manufacturer to date. This new feature pushes the envelope in the industry by adding an even higher resolution to the NewTom VGi, a feature which up to now, was typically seen in only the implant-specific or small FOV units."

"It is now the highest resolution CBCT of all the units in the large FOV category. Anyone who is considering a CBCT, regardless of specialty, should want to take a look at the NewTom VGi with this amount of flexibility," Ellison added.

For additional information, please visit our website on www.imageworkscorporation.com.

_contact	CAD/CAM
ImageWorks 250 Clearbrook Road, Suite 240 Elmsford, NY 10523 USA www.imageworkscorporation.com Please visit us at IDS: Hall 11.2, Booth N060	

White Peaks Dental Systems

White Peaks Dental Systems, a German manufacturer, specialising in the production of dental zirconium blanks, exclusively uses raw materials from Tosoh (Japan), the world leader in zirconium technology. White Peaks' blanks are certified to the highest standards (CE, FDA and DIN ISO 13485). The Copran ZR zirconium blanks are compatible with almost all CAD/CAM milling and manual systems. A large variety of blanks of high strengths, high translucency, as well as pre-coloured blanks in shades A1 and A3 leave nothing to be desired.

White Peaks offers a variety of related products, such as zirconium colouring liquids in 16 classic shades, intensive shades for full contour shading, Cr-Co, titanium, CE certified PMMA blanks, PMMA and wax blanks for casting



techniques, extremely long-lasting milling burs, and scan spray.

The brand new range of CAD/CAM milling systems—Calidia Raptor Professional 7x, Calidia Raptor 5x and Calidia Predator 5x—are specially designed for dental laboratories and milling centres. With a weight of approximately 700 kg, the Raptor series is sufficiently small to fit into the average laboratory, but sufficiently heavy to perform at high milling speed. They offer the highest accuracy and are capable of milling zirconium, Cr-Co, titanium, lithium disilicate and feldspathic ceramic blocks. The Predator series is a smaller, interestingly priced system. All CAD/CAM milling systems, materials and components offered by White Peaks, are obligation and royalty free. If you already own a CAD/CAM system, check out the new CAM software White CAM 5.0—your way to independence. The software enables free choice of zirconium and other materials for your system. There is no need to touch the run-

ning system. Simply install the software parallel to your system and use it when required. Owing to the new inter-connection design, up to 50 units can be placed in one blank.

For additional information on our furnaces, scanners, equipment and materials, please visit our website www.white-peaks-dental.com.

contact

CAD/CAM

White Peaks Dental Systems GmbH & Co. KG

Langeheide 9
45239 Essen
Germany

info@white-peaks-dental.com
www.white-peaks-dental.com

Please visit us at IDS: Hall 11.1, Booth A059

International Events

2011

International Dental Show

Cologne, Germany
22–26 March 2011
www.ids-cologne.de

**ACE Tampa 2011 Conference on
Social Media & Marketing for Dentistry**

Tampa, FL, USA
1 & 2 April 2011
www.acesthetics.com

**CAD/CAM & Computerized Dentistry
International Conference**

Dubai, UAE
12 & 13 May 2011
www.cappmea.com

AACD Boston 2011

Boston, MA, USA
18–21 May 2011
www.aacd.com

EAED Spring Meeting

Istanbul, Turkey
2–4 June 2011
www.eaed.org

IACA 2011

San Diego, CA, USA
28–30 July 2011
www.theiaca.com

Live 3-D Dentistry Forum

Anaheim, CA, USA
29 & 30 July 2011
www.i-cat3d.com

AAED Annual Meeting

San Juan, Puerto Rico
2–5 August 2011
www.estheticacademy.org

FDI Annual World Dental Congress

Mexico City, Mexico
14–17 September 2011
www.fdiworldental.org

IFED World Congress

Rio de Janeiro, Brazil
21–24 September 2011
www.ifed.org

**Dental-Facial Cosmetic
International Conference**

Dubai, UAE
27 & 28 October 2011
www.cappmea.com

International Congress on 3-D Dental Imaging

Dallas, TX, USA
4 & 5 November 2011
www.i-cat3d.com

Greater New York Dental Meeting

New York, NY, USA
25–30 November 2011
www.gnydm.org



submission guidelines:

Please note that all the textual components of your submission must be combined into one MS Word document. Please do not submit multiple files for each of these items:

- _ the complete article;
- _ all the image (tables, charts, photographs, etc.) captions;
- _ the complete list of sources consulted; and
- _ the author or contact information (biographical sketch, mailing address, e-mail address, etc.).

In addition, images must not be embedded into the MS Word document. All images must be submitted separately, and details about such submission follow below under image requirements.

Text length

Article lengths can vary greatly—from 1,500 to 5,500 words—depending on the subject matter. Our approach is that if you need more or less words to do the topic justice, then please make the article as long or as short as necessary.

We can run an unusually long article in multiple parts, but this usually entails a topic for which each part can stand alone because it contains so much information.

In short, we do not want to limit you in terms of article length, so please use the word count above as a general guideline and if you have specific questions, please do not hesitate to contact us.

Text formatting

We also ask that you forego any special formatting beyond the use of italics and boldface. If you would like to emphasise certain words within the text, please only use italics (do not use underlining or a larger font size). Boldface is reserved for article headers. Please do not use underlining.

Please use single spacing and make sure that the text is left justified. Please do not centre text on the page. Do not indent paragraphs, rather place a blank line between paragraphs. Please do not add tab stops.

Should you require a special layout, please let the word processing programme you are using help you do this formatting automatically. Similarly, should you need to make a list, or add footnotes or endnotes, please let the word processing programme do it for you automatically. There are menus in every programme that will enable you to do so. The fact is that no matter how carefully done, errors can creep in when you try to number footnotes yourself.

Any formatting contrary to stated above will require us to remove such formatting before layout, which is very time-consuming. Please consider this when formatting your document.

Image requirements

Please number images consecutively throughout the article by using a new number for each image. If it is imperative that certain images are grouped together, then use lowercase letters to designate these in a group (for example, 2a, 2b, 2c).

Please place image references in your article wherever they are appropriate, whether in the middle or at the end of a sentence. If you do not directly refer to the image, place the reference at the end of the sentence to which it relates enclosed within brackets and before the period.

In addition, please note:

- _ We require images in TIF or JPEG format.
- _ These images must be no smaller than 6x6 cm in size at 300 DPI.
- _ These image files must be no smaller than 80 KB in size (or they will print the size of a postage stamp!).

Larger image files are always better, and those approximately the size of 1 MB are best. Thus, do not size large image files down to meet our requirements but send us the largest files available. (The larger the starting image is in terms of bytes, the more leeway the designer has for resizing the image in order to fill up more space should there be room available.)

Also, please remember that images must not be embedded into the body of the article submitted. Images must be submitted separately to the textual submission.

You may submit images via e-mail, via our FTP server or post a CD containing your images directly to us (please contact us for the mailing address, as this will depend upon the country from which you will be mailing).

Please also send us a head shot of yourself that is in accordance with the requirements stated above so that it can be printed with your article.

Abstracts

An abstract of your article is not required.

Author or contact information

The author's contact information and a head shot of the author are included at the end of every article. Please note the exact information you would like to appear in this section and format it according to the requirements stated above. A short biographical sketch may precede the contact information if you provide us with the necessary information (60 words or less).

Questions?

Claudia Salwiczek (Managing Editor)
c.salwiczek@dental-tribune.com

CAD/CAM

international magazine of digital dentistry



Publisher

Torsten R. Oemus
t.oemus@dental-tribune.com

Managing Editor

Claudia Salwiczek
c.salwiczek@dental-tribune.com

Product Manager

Bernhard Moldenhauer
b.moldenhauer@dental-tribune.com

Executive Producer

Gernot Meyer
g.meyer@dental-tribune.com

Designer

Franziska Dachsel
f.dachsel@dental-tribune.com

Copy Editors

Sabrina Raaff
Hans Motschmann

International Administration Marketing & Sales

Peter Witteczek
p.witteczek@dental-tribune.com

Executive Vice President

Finance
Dan Wunderlich
d.wunderlich@dental-tribune.com

International Media Sales

Western Europe
Antje Kahnt
a.kahnt@dental-tribune.com

Eastern Europe
Grzegorz Rosiak
g.rosiak@dental-tribune.com

Asia Pacific
Peter Witteczek
p.witteczek@dental-tribune.com

The Americas
Jan M. Agostaro
j.agostaro@dental-tribune.com

International Offices

Europe
Dental Tribune International GmbH
Contact: Nadine Parczyk
Holbeinstr. 29, 04229 Leipzig, Germany
Tel.: +49 341 4 84 74 302
Fax: +49 341 4 84 74 173

Asia Pacific
Dental Tribune Asia Pacific Ltd.
Contact: Tony Lo
Room A, 26/F, 389 King's Road
North Point, Hong Kong
Tel.: +852 3113 6177
Fax: +852 3113 6199

The Americas
Dental Tribune America, LLC
Contact: Anna Wlodarczyk
116 West 23rd Street, Suite 500
NY 10011, New York, USA
Tel.: +1 212 244 7181
Fax: +1 212 244 7185

Editorial Board

Prof Albert Mehl, Switzerland
Prof Gerwin Arnetzl, Austria
Dr Stefan Holst, Germany
Hans Geiselhöringer, Germany
Dr Ansgar Cheng, Singapore

Printed by

Löhnert Druck
Handelsstraße 12
04420 Markranstädt, Germany

www.dental-tribune.com

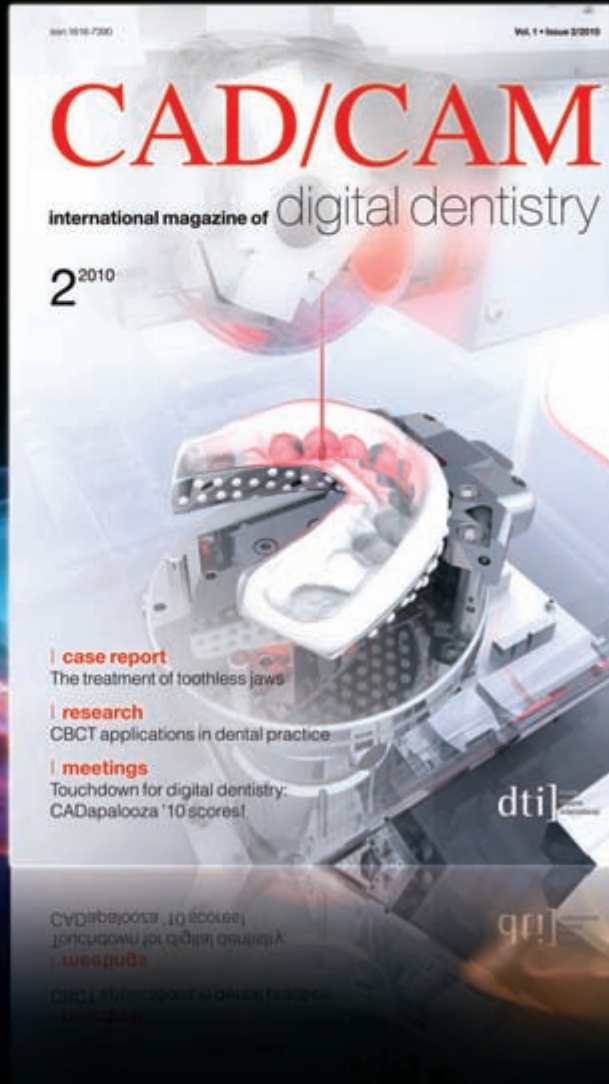Copyright Regulations

CAD/CAM international magazine of digital dentistry is published by Dental Tribune Asia Pacific Ltd. and will appear in 2011 with four issues. The magazine and all articles and illustrations therein are protected by copyright. Any utilisation without the prior consent of editor and publisher is inadmissible and liable to prosecution. This applies in particular to duplicate copies, translations, microfilms, and storage and processing in electronic systems.

Reproductions, including extracts, may only be made with the permission of the publisher. Given no statement to the contrary, any submissions to the editorial department are understood to be in agreement with a full or partial publishing of said submission. The editorial department reserves the right to check all submitted articles for formal errors and factual authority, and to make amendments if necessary. No responsibility shall be taken for unsolicited books and manuscripts. Articles bearing symbols other than that of the editorial department, or which are distinguished by the name of the author, represent the opinion of the afore-mentioned, and do not have to comply with the views of Dental Tribune Asia Pacific Ltd. Responsibility for such articles shall be borne by the author. Responsibility for advertisements and other specially labeled items shall not be borne by the editorial department. Likewise, no responsibility shall be assumed for information published about associations, companies and commercial markets. All cases of consequential liability arising from inaccurate or faulty representation are excluded. General terms and conditions apply, legal venue is North Point, Hong Kong.

CAD/CAM

international magazine of digital dentistry



Subscribe now!

I would like to subscribe to **CAD/CAM** for €44 including shipping and VAT for German customers, €46 including shipping and VAT for customers outside Germany, unless a written cancellation is sent within 14 days of the receipt of the trial subscription. The subscription will be renewed automatically every year until a written cancellation is sent to Dental Tribune International GmbH, Holbeinstr. 29, 04229 Leipzig, Germany, six weeks prior to the renewal date.

Reply via Fax +49 341 48474-173 to Dental Tribune International GmbH or per E-mail to n.parczyk@dental-tribune.com

Last Name, First Name

Company

Street

ZIP/City/County

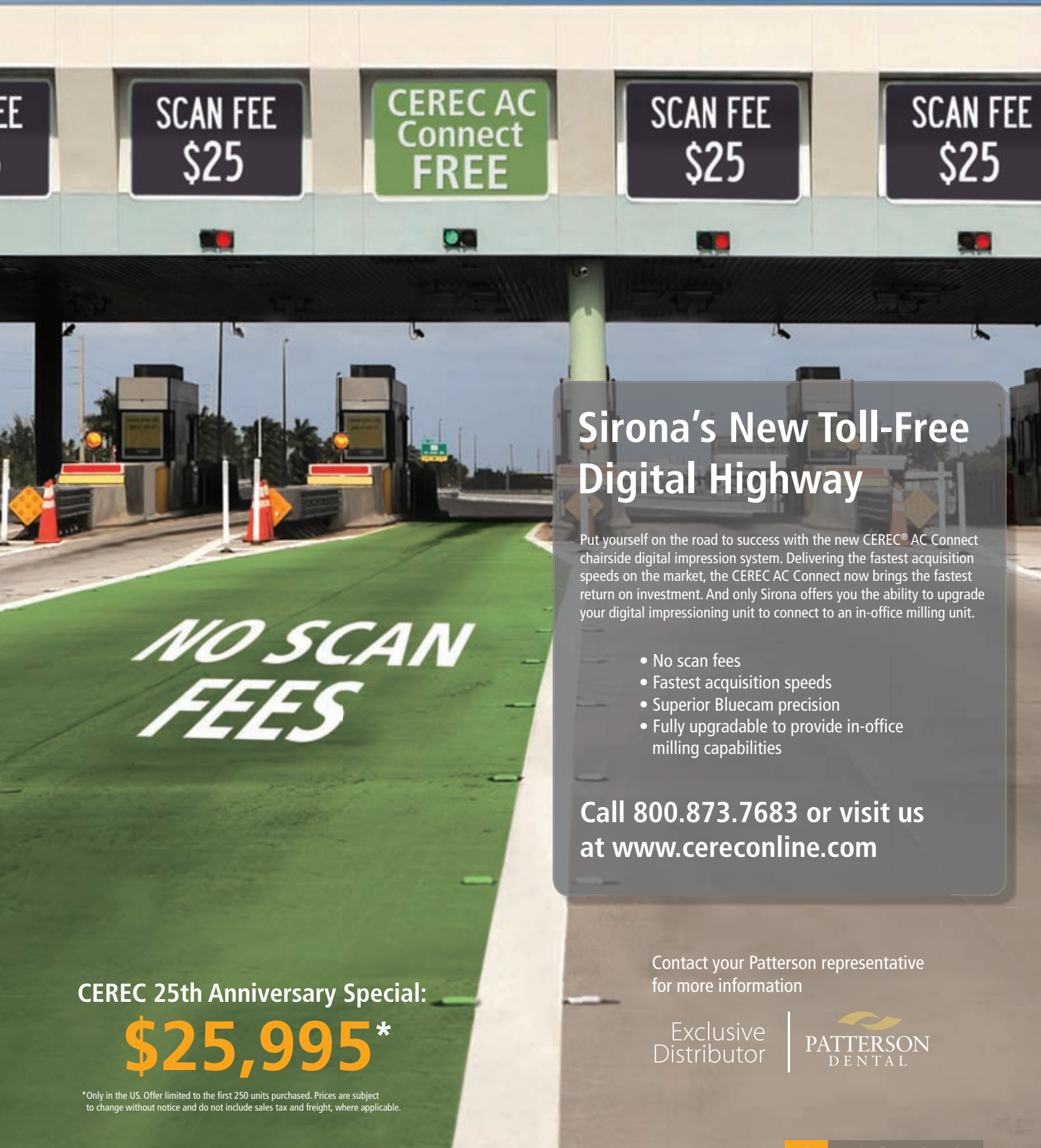E-mail

Signature

Notice of revocation: I am able to revoke the subscription within 14 days after my order by sending a written cancellation to Dental Tribune International GmbH, Holbeinstr. 29, 04229 Leipzig, Germany.

Signature

CEREC® AC Connect. Impress Everyone.



Sirona's New Toll-Free Digital Highway

Put yourself on the road to success with the new CEREC® AC Connect chairside digital impression system. Delivering the fastest acquisition speeds on the market, the CEREC AC Connect now brings the fastest return on investment. And only Sirona offers you the ability to upgrade your digital impressing unit to connect to an in-office milling unit.

- No scan fees
- Fastest acquisition speeds
- Superior Bluecam precision
- Fully upgradable to provide in-office milling capabilities

Call 800.873.7683 or visit us at www.cereconline.com

Contact your Patterson representative for more information

Exclusive Distributor


PATTERSON
DENTAL

CEREC 25th Anniversary Special:

\$25,995*

*Only in the US. Offer limited to the first 250 units purchased. Prices are subject to change without notice and do not include sales tax and freight, where applicable.

sirona.
The Dental Company