

Root-canal anatomy of the permanent mandibular first molar—Clinical implications and recommendations

Authors_ Dr Carlos Heilborn, Paraguay; Dr Óliver Valencia de Pablo & Dr Roberto Estevez, Spain & Dr Nestor Cohenca, USA

The world of endodontics has incorporated new technologies, instruments and materials in the past decade, such as operating microscopes, digital radiography, CBCT, NiTi rotary shaping files, sonic and ultrasonic instruments, and new irrigation delivery systems. However, despite all these improvements, the overall outcome, especially of non-surgical endodontics, has not increased significantly.¹⁻⁸

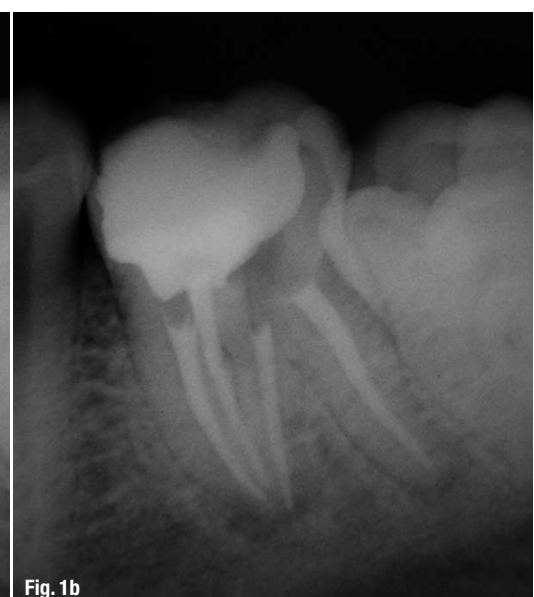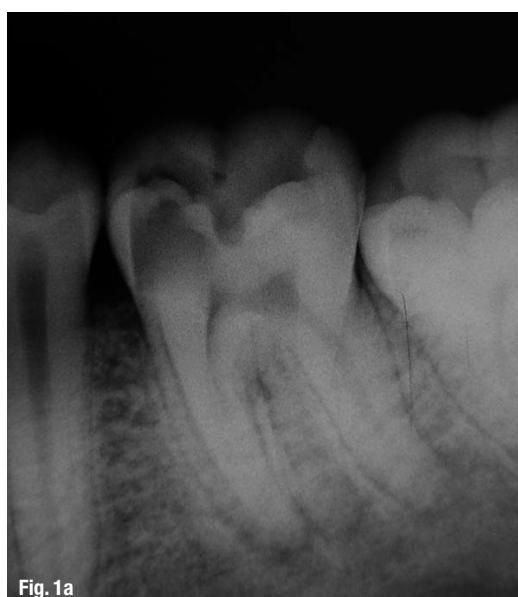
Why? If we consider this critically, we can determine that there are two important factors directly related to prognosis that have limited our advancement: predictable eradication of microorganisms and access to the full anatomy of the canal system in which they might be harboured.

The mandibular first molar (MFM) is the more frequently endodontically treated tooth.⁹⁻¹¹ In a

study by Swartz *et al.*, the success rate of endodontically treated teeth was 87.79%, with a significantly lower success rate of 81.48% for MFMs.¹² It is well accepted that a unique cleaning and shaping technique is not suitable for all cases. Therefore, the endodontist should be able to fully understand the tooth morphology and root-canal configurations in order to select the most appropriate treatment modality for a particular case,¹³ thereby increasing the healing rate.¹⁴⁻¹⁶

Based on the above information, our group recently published a systematic review on root anatomy and canal configuration of the permanent MFM with reference to 41 studies and a total of 18,781 teeth.¹⁷ A summary of the data obtained is presented in Table I. This review provided significant information directly related to our clinical procedures.

Figs. 1a & b_Root-canal treatment on a three-rooted MFM: pre-op radiograph (Fig. 1a); post-op radiograph (Fig. 1b).



Number of roots					
<i>Number of molars studied</i>	18,781	3-rooted molars in %		13 % (2,450)	
Total number of canals					
<i>Number of molars studied</i>	4,745	61.3 % 3 canals	35.7 % 4 canals	0.8 % 5 canals	
Number of canals in mesial root					
<i>Number of mesial roots studied</i>	4,535	3.3 % 1 canal	94.2 % 2 canals	2.6 % 3 canals	
Mesial and distal roots. Canal system configuration					
		Type I (1-1)	Type II (2-1)	Type IV (2-2)	Type VIII (3-3)
<i>Number of mesial roots studied</i>	4,331		35 %	52.3 %	0.9 %
<i>Number of distal roots studied</i>	2,992	62.7 %	14.5 %	12.4 %	
Number of foramina in mesial and distal roots					
		1 foramen	2 foramina	3 foramina	
<i>Number of mesial roots studied</i>	4,817	38.2 %	59.2 %	1.6 %	
<i>Number of distal roots studied</i>	3,378	77.2 %	22.2 %		
Intercanal communications. Type V isthmuses					
		Mesial root		Distal root	
<i>Number of molars studied</i>	1,615	54.8 % middle & apical 1/3		20.2 % middle 1/3	

Table I

Number of roots

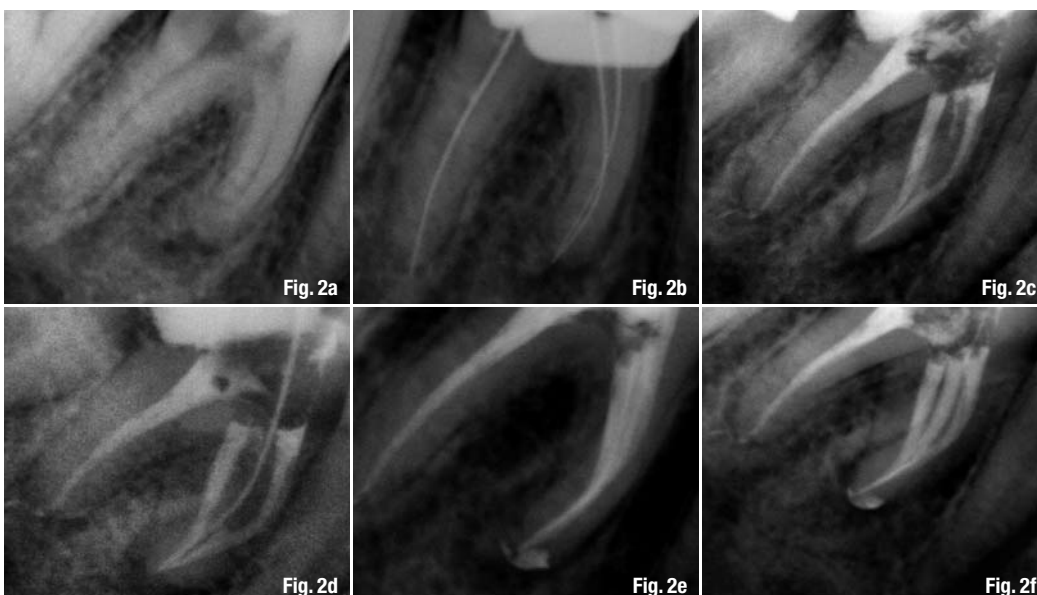
A literature review revealed a strong correlation between the presence of a third root in 13% of teeth and the ethnicity of the patients, particularly Asians, Mongolians and Eskimos.¹⁸

In order to determine the presence of additional roots visually, several radiographic exposures are required. Initial off-angle radiographs are essential during MFM treatment (Fig. 1a).^{19,20} Initially, a file located in the extra root, may give the appearance of a perforation.²¹ If radiographic findings are not defin-

itive, information provided by electronic foramen locators provides reliable readings to make a differential diagnosis and confirm the presence of the additional canal. Walker and Quackenbush conclude that simple analysis of bitewings allows for the detection of disto-lingual (DL) roots in 90% of cases.¹⁸

In 1990, Carlsen and Alexander reported on a study of 398 permanent mandibular molars with a lingually located supernumerary root.²² This macrostructure, the radix entomolaris, presents high variation in regards to shape and curvature. When the position of this third root is buccal, it is called the radix paramo-

Table I Results of mandibular first lower molar systematic review (Valencia de Pablo *et al.*, 2010).



Figs. 2a-f Root-canal treatment on an MFM: pre-op radiograph (Fig. 2a); working length radiograph (Fig. 2b); post-op radiograph demonstrating a fine projection of sealer between MB and ML (Fig. 2c); working length radiograph of middle mesial canal (Fig. 2d); post-op, ortho-radial radiograph (Fig. 2e); post-op, off-angle radiograph demonstrating three canals treated on mesial root (Fig. 2f).

laris. Its shape and curvature are highly variable (Fig. 1b).²³⁻²⁵ Typically, the axis of the root faces the buccal aspect of the molar. Therefore, it could be easier to select the disto-buccal cusp as a reference point, instead of the typical DL. The combination of the slope present at the orifice and the buccal curvature at the apical third results in a highly complex canal to be instrumented and irrigated. To prevent mishaps, it is advisable to choose a small and highly flexible instrument when treating the apical portion.

Diagnosis, access and proper treatment of the third root within the complex canal system are essential in order to achieve successful endodontic treatment. In cases of endodontic surgical procedures, the third root will be a significant challenge.¹⁹ In a recent publication, Tu *et al.* report high DL root prevalence amongst the Taiwanese population.²⁶ The authors found that the inability to recognise and treat this extra root was directly correlated to treatment failure, leading to tooth extraction.

Table I summarises the findings of a systematic review compiling data on 4,745 MFMs.¹⁷ On average, three canals were present in 61.3% of cases, followed by four canals in 35.7% of cases and five canals in almost 1% of cases. *In vivo* studies performed by endodontists demonstrated the presence of four canals in 45% of the treated cases.²⁷⁻³⁰ Five canals were found in 0.8% of the samples, while case reports have demonstrated the possibility of six- and even seven-root canals.^{31,32}

Mesial root morphology

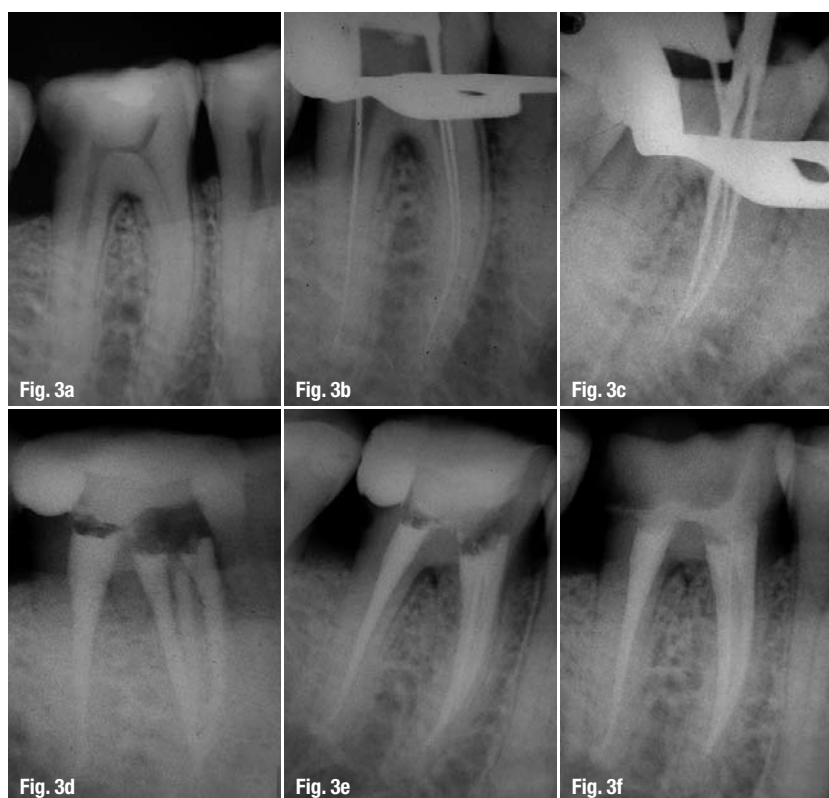A systematic literature review of studies concerning more than 4,000 mesial roots confirmed the presence of two root canals in 94.2%.¹⁷ These canals merge in a common apical foramen (type II) in 35% of cases or remain independent with separate apical foramina in 52.3% of cases (type IV of Vertucci's classification; Table I). A clinical approach to identifying the internal canal configuration should include evaluation of the distance between the main orifices. The short distance between mesiobuccal (MB) and mesiolingual (ML) orifices often leads to confluence and termination in a common foramen. An increased distance is directly correlated to type IV configuration with two separate foramina.³³

When facing a type IV configuration (2-2), the clinician should treat the canals independently. For merging canals, Castellucci explains that initially the canals should not be instrumented to working length, thus preventing unnecessary removal of dentine.³⁴ In addition, full instrumentation of both canals to working length will create an hour-glass preparation, with the narrowed area at the junction and widening canal space apical to the junction. The 3-D obturation in this case is much more complicated and poses a risk of extrusion, as well as leaving some empty space in the most apical divergent zone.²⁹ It is clinically safer and easier to instrument the ML canal to working length and the MB to the level of the confluence, since the latter is the closest to the outer surface of the root and also presents more severe curvatures than the ML.^{35,36}

Marroquin *et al.* report that the average size of the maximum diameter is 0.31 mm when the apical foramen is common.³⁷ In contrast, the average maximum diameter does not exceed 0.25 mm when two separate foramina are present. This data suggests that treating a type IV configuration could allow a more conservative apical preparation. Nevertheless, canal preparation must always be correlated to the anatomy and the microbiological status of the canal. While vital cases should be treated more conservatively, infected canals may require larger apical preparations to allow efficient irrigation and disinfection.^{38,39}

Several publications report the presence of three canals in the mesial root.^{40,41} Our systematic review reports an incidence of 2.6% (Figs. 2 & 3).¹⁷ In order to localise it, access modifications are required. Briefly, once the main canals have been localised and their access instrumented, small burs or ultrasonic tips are used to remove the dentinal bridge that connects both entries, providing a direct view of the angle formed by the mesial wall and the floor of the pulp

Figs. 3a-f _ Root-canal treatment on an MFM: pre-op radiograph (Fig. 3a); working length radiograph (Fig. 3b); working length off-angle radiograph after location of three canals on mesial root (Fig. 3c); post-op, off-angle radiograph demonstrating three canals treated on mesial root (Fig. 3d); post-op, ortho-radial radiograph (Fig. 3e); final restoration control (Fig. 3f).



chamber, exposing the developmental groove between the two main canals. An endodontic explorer is then used, followed by negotiation with small files. Additionally, the use of operating microscopes further improves the possibility of finding and treating this accessory canal.⁴² Taking into consideration the distal concavity of the mesial root, instrumentation of the third medial canal must be done carefully using small instruments to avoid stripping perforations.²⁷ The middle mesial is an entirely independent canal in up to 25% of cases.¹⁷

Distal root morphology

Gulabivala *et al.* evaluated 139 MFMs and found that 74.8% of the distal roots had a flattened MD morphology.²¹ They also noted that conical distal roots frequently presented a single canal, while the vast majority had more complex configurations. Therefore, routine access openings should be modified in search of a second or a ribbon-shaped canal. The access design has evolved from the classic triangular to a rectangular shape shifted to the MB.^{27,43}

Martinez-Berna and Badanelli were the first to report a third canal in the distal root and termed it the disto-central (DC) root canal.⁴⁴ A literature review sets the incidence of DC at 1%.^{21,31,39,45-50}

Intercanal communications

The morphology and buccolingual width of the mesial root allow for intercanal communications and isthmuses (Fig. 4). An isthmus (anastomosis) is defined as a pulpal passageway that connects two or more canals in the same root.⁵¹ In young patients, we should expect to find large canals with wide isthmuses. As secondary dentine is deposited throughout the maturation of the tooth, these large communications are divided into smaller ones and, eventually, its frequency decreases after age 40.⁵²

Of the 1,615 MFMs reviewed, 50% of the mesial and 20% of the distal roots presented isthmuses of type V. Type V is recognised as a true connection or wide corridor of tissue between the two main canals.⁵³ Therefore, the presence of isthmuses should be considered the rule rather than the exception when treating young MFMs.

Given the extreme difficulty in disinfecting these inaccessible spaces,⁵⁴ our efforts should be focused on improving our irrigation protocols with the more efficient systems available today. The clinical importance of recognising, treating and disinfecting isthmuses was recently pointed out by Von Arx, who identified complete cross-anastomosis in 29% of cases of failed root-canal therapies requiring apical surgery.⁵⁵

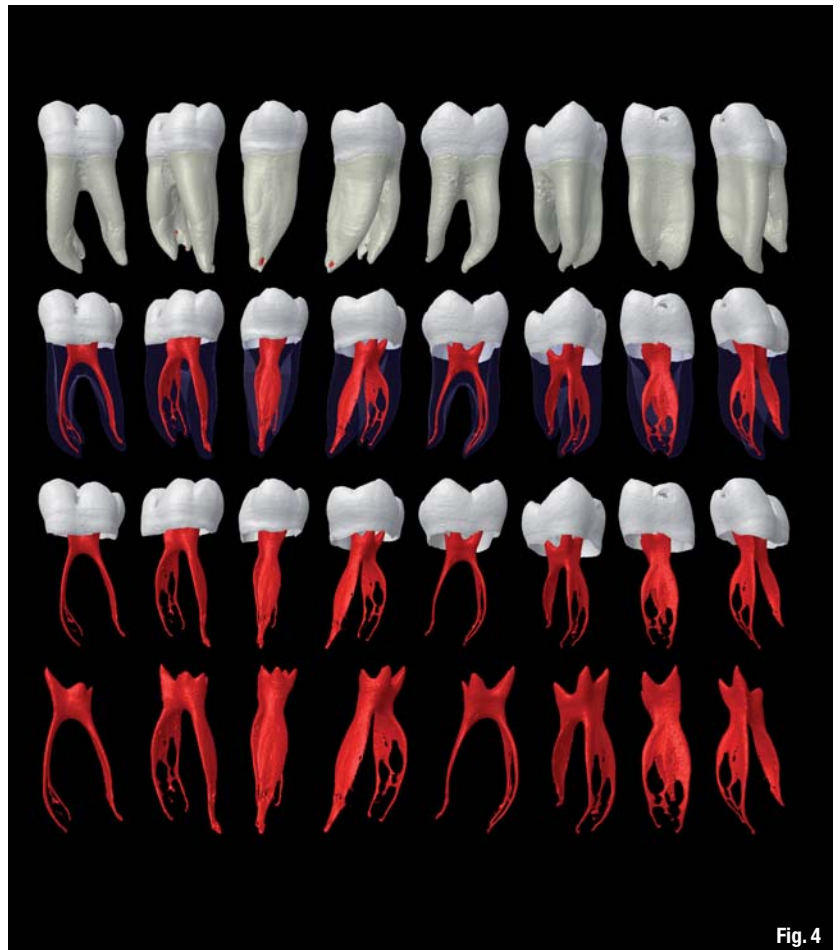


Fig. 4

Conclusion

The following is a summary of the findings of our review:

1. The number of roots in the MFM is directly related to the ethnicity of the population studied.
2. The instrumentation of the third root requires a different access and the use of small and flexible instruments, considering the curvature at the apical third.
3. Mesial roots present two canals on a regular basis, with 2-2 and 2-1 the most frequent configurations. A third canal might be present in 2.6% of the population.
4. The most common configuration in the distal root is 1-1 (62.7%), followed by 2-1 (14.5%) and 2-2 (12.4%).
5. Access modifications are required in order to find extra roots and/or canals.
6. The presence of isthmuses is 55% in the mesial root and 20% in the distal root. This anatomical configuration should be taken into consideration during endodontic treatment and peri-apical surgery.

Editorial note: A complete list of references is available from the publisher.

Fig. 4 Micro-computed tomography of an MFM with 3-D reconstructions on different projections showing the very complex anatomy of the root-canal system (Image courtesy of Prof Marco Versiani and Prof Manoel D. Sousa Neto, Ribeirão Preto Dental School, University of São Paulo).

_contact	roots
<p>Dr Nestor Cohenca Department of Endodontics University of Washington Box 357448 Seattle, WA 98195-7448 USA</p> <p>cohenca@uw.edu</p>	