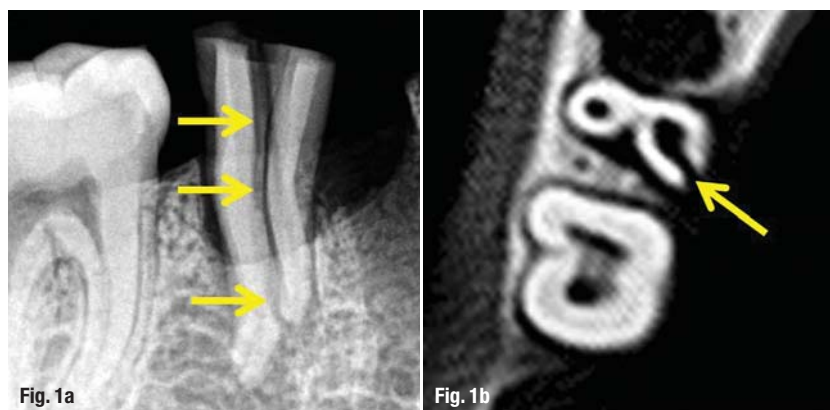


Diagnosis of **vertical root fractures** using CBCT and an alternative treatment modality

Author_ Dr Senem Yiğit Özer, Turkey



Figs. 1a–d An intra-oral radiography image of an experimentally induced VRF of 0.4 mm thickness (a). Arrows indicate the VRF and it is difficult to determine whether the fracture is on the buccal or on the palatal root. CBCT images of an experimentally induced VRF, axial view (b). Note that the VRF obviously includes the palatal root and this finding may change the treatment modality. Sagittal view showing the extent of the VRF (c). Coronal view (d). Arrows show the fracture lines through the entire root surface.

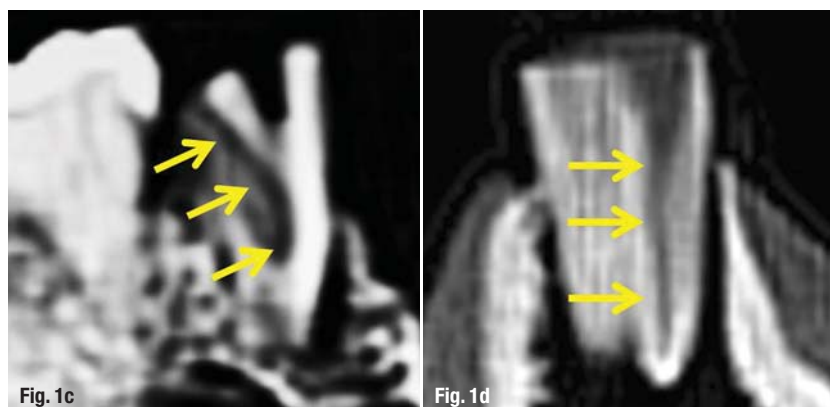
_Longitudinal root fractures are confusing to both the clinician and the patient, and it is often more a case of prediction rather than diagnosis. In order to provide a global terminology and to prevent bias, five types of root fractures with different treatment modalities have been classified, from least to most severe: craze lines, cuspal fractures, cracked teeth, split teeth and vertical root fractures (VRFs).¹

Craze lines, which are asymptomatic, affect only the enamel and often do not need to be treated. *Cuspal fractures* on the cusps and the cervical margins of the root are usually reinforced by a crown or an onlay restoration to keep the separated segments in

their original positions. A *cracked tooth* occurs on the crown with variable symptoms. Cuspal reinforced restorations represent an appropriate treatment modality. If the fracture continues to develop, a *split tooth* is formed and wedging of the separated fragments can be identified visually and clinically with pain in mastication. If the fracture lies through the middle to the cervical third of the root without extending apically, the mobile segment can be removed and the tooth can be preserved. Crown lengthening and orthodontic extrusion of the remaining root are further treatment alternatives.¹

A *VRF* is the most severe type of longitudinal defect, originating from the apical end of the root and continuing coronally. A VRF extends to the periodontal ligament and soft tissue grows into the fractured fragments over time. As the separations between fractured fragments increase over time, resorption areas become enlarged, which has a negative effect on the prognosis of the affected area for further treatment.² Thus, a rapid decision is required to prevent additional bone loss, which might cause difficulty in reconstructing the area for further treatment, such as implant placement. Clinical signs, radiographic features and symptoms observed in VRFs are very similar to those in a failed root-canal treatment and manifestations of periodontal disease, making an accurate diagnosis difficult.³ Referring these patients for periodontal therapy or endodontic retreatment results in a loss of time and patience, as well as greater bone resorption.

Today, the three major indications for the extraction of endodontically treated teeth are unrestorable teeth (43.5%), endodontic failures (21.1%) and VRFs (10.9%).^{4–6} Recently, high prevalence rates of VRFs have been reported.^{2,4–6} A VRF can be treated by many treatment modalities, such as tooth extraction, removal of the fractured root and replantation of the tooth after bonding the fractured fragments extra-orally.^{4,7–9}



Saving a tooth via intentional extraction causes minimal damage to periodontal tissues. 4-META/MMA-TBB resin is generally used to bond the separated fragments and afterwards, replantation is performed.^{8,9} The distance between separated fractures is an important factor to determine whether surgery will be planned with simultaneous flap operation or with normal extraction without flap reflection.⁴ In addition, determining the position and extent of the fracture might be helpful for deciding when to recommend extraction.

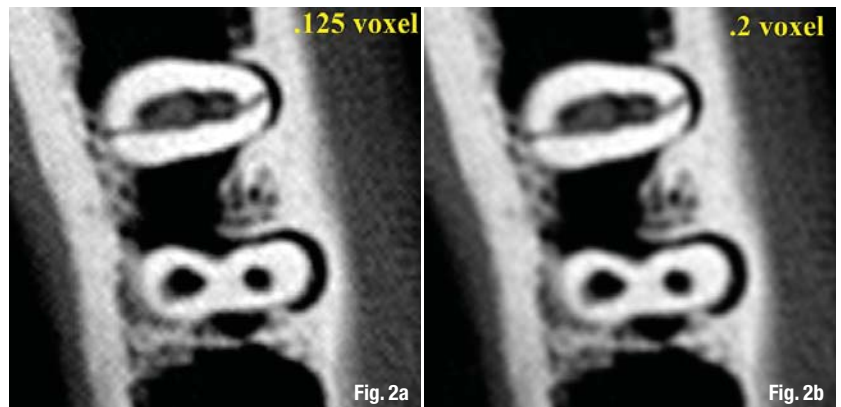
A root fracture can be overlooked if the X-ray beam does not pass along the fracture line.¹⁰ Furthermore, the interpretation of root fracture on radiographs is problematic, especially if there is no oedema and granulation tissue between the separated fragments.¹¹ Another major problem for conventional intra-oral radiography is the superimposition of other structures, which limits the sensitivity of diagnosis.¹²

Cone-Beam Computed Tomography (CBCT) units have become commercially available recently, in which all data is acquired at one time, providing a 3-D scan of the patient's head.¹³⁻¹⁵ Previous studies have indicated the superiority of CBCT to intra-oral conventional film and digital radiography for detecting VRFs.^{12,14-17} A recent study reported that CBCT scans had provided more accurate results than intra-oral radiography during the diagnosis of VRFs with 0.2 to 0.4 mm thicknesses, which may indicate the early stages of the problem (Figs. 1a-d).¹⁶

Choosing the appropriate radiation dose using CBCT in detecting VRFs is a major and critical concern. ALARA is the acronym for *as low as reasonably achievable*, which constitutes the basic principle for diagnostic radiology in all fields. One must consider keeping the dose as low as possible while still obtaining the information needed.¹⁸ It is reported that with smaller voxel sizes, radiation exposure would be higher.¹⁹⁻²¹ Without sacrificing image quality and adopting the ALARA principle, changing the voxel settings would be helpful in reducing the radiation dose.

Recent studies comparing the diagnostic accuracy of different voxel sizes for the detection of VRFs report that voxel sizes equal to or smaller than 0.2 mm are the best choice, with a shorter scanning time and reduced radiation exposure of the patient (Figs. 2a-d).^{22,23}

After diagnosing the VRF, a rapid decision has to be made whether to extract or retain the tooth. Extra-oral VRF treatment that includes resin cement bonding and intentional replantation is an alternative treatment modality. This alternative treatment method in particular is reported to be appropriate for anterior teeth.^{4,8,24,25} A clinical report by Hayashi *et al.* demon-



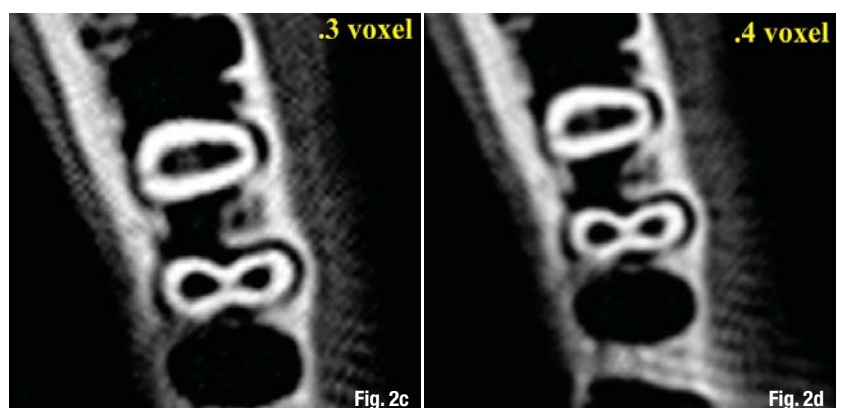
strated no failure in vertically fractured incisors treated with this method, although failures occurred in premolars and molars in that the posterior teeth were negatively affected by strong occlusal forces.²⁵

For a vertically fractured incisor, Öztürk and Ünal reported a successful four-year outcome clinically.⁴ Similarly, Arıkan *et al.* reported a successful 18-month outcome for VRF treatment and recommended the procedure described in this article.²⁴ They also demonstrated that the use of a dual-curing material instead of 4-META/MMA-TBB resin shortened extra-oral working time and preserved the vitality of the periodontal ligament, thereby increasing the probability of long-term replantation success. In addition, Özer *et al.* reported success after two years in treatment outcomes of VRFs treated in the same manner as above.²⁶

Alternative treatment of VRFs

The alternative treatment plan for VRFs consists of the following steps:

1. Extraction of affected teeth;
2. Bonding of the separated segments with a self-etching, dual-cure adhesive resin cement extra-orally; and
3. Intentional replantation of the reconstructed teeth.



Figs. 2a-d CBCT images of a fractured root with four different voxels in the axial plane. 0.125 mm voxel (a); 0.2 mm voxel (b); 0.3 mm voxel (c); 0.4 mm voxel (d). Fracture lines are difficult to detect when compared with the 0.125 mm and 0.2 mm voxels.

The following surgical protocol is helpful during the process:

1. Local anaesthesia using a solution of 2% articaine with 0.1% epinephrine and a full-thickness mucoperiosteal flap for better visualisation;
2. Circumferential dissection of the supra-alveolar fibres;
3. Gentle extraction of the tooth with minimum damage to the periodontium and immersion in saline solution; and
4. Curettage of the socket walls adjacent to the fracture region and irrigation with saline solution for the removal of inflamed tissue.

For the treatment of VRFs, the following steps are recommended:

1. The root-filling material and granulation tissue are removed with a sharp scalpel through the entire root. During this process, in order to prevent dehydration, tooth fragments should be kept in gauze moistened with saline.
2. The sealant should be applied in small amounts to avoid covering the periodontal ligament on the root-canal dentine, which is dried prior to sealing.
3. The self-etching, dual-cured adhesive resin cement should be cured for 20 seconds for proper setting of the material. In addition, this will help to reduce the working time extra-orally.
4. After fragment attachment, the root surfaces may be treated with tetracycline for 30 seconds to enhance periodontal ligament cell attachment.²⁷
5. In the final step, the reconstructed tooth is replanted in its original position.^{4,8,24}

After the surgical procedure, patients are prescribed a chlorhexidine-digluconate mouth rinse and 500 mg amoxicillin (3 tablets) plus 550 mg naproxen (2 tablets) daily for one week. Following intentional replantation, clinical examinations should be performed in intervals to evaluate tooth mobility and sensitivity to percussion. The percussion tone can be compared with healthy adjacent teeth.

Clinical success is defined by a lack of sensitivity to percussion, percussion tone that does not differ from the healthy adjacent teeth, and mobility within normal limits at six months. Failure is defined as clinical conditions that do not meet the requirements for success and/or increased discomfort of the patient.

In cases in which the tooth has been treated extra-orally, healthy cementum on the root surface and periodontal membrane vitality are important factors in preventing ankylosis.^{4,28} Solutions such as citric acid, tetracycline and EDTA have been advocated for root-surface modification to produce a surface that is

conducive to cellular adhesion and growth.²⁹ A 30-second application of tetracycline has been reported to remove the smear layer, leaving clean and open tubules.²⁷

During evaluation of the CBCT images for VRFs, as previously reported by Hassan *et al.*, axial slices have proven to be more accurate than coronal and sagittal slices (Fig. 1b).³⁰ Thus, it is important to pay attention to axial plane images in particular. Sagittal plane images are useful for determining the extent and direction of each fracture line (Fig. 1c).

Conclusion

1. Early and accurate diagnosis of a VRF is important in preventing bone destruction. CBCT imaging allows the clinician to accurately detect these problems and inform the patient about alternative treatment modalities.
2. Bonding the separated fragments of VRFs extra-orally followed by intentional replantation of the reconstructed tooth is an innovative method that provides an alternative to tooth extraction, especially for anterior teeth.
3. Scanner units with higher resolutions are advisable for use in detecting VRFs and in the follow-up period for better evaluation during the recovery phase.

Editorial note: A complete list of references is available from the publisher.

about the author

roots



Dr Senem Yiğit Özer

graduated from Selçuk University's Dental Faculty in Konya, Turkey, in 1997. She completed her PhD in 2004 at the Department of Endodontics at Ege University in İzmir, Turkey, and worked at the Dental Hospital of the Ministry of Health in Diyarbakır, Turkey, between 2005 and 2008. Thereafter, she began working at the Department of Operative Dentistry and Endodontics at Dicle University in Diyarbakır, and still serves there as Assistant Professor. Her research interests are root-canal instruments, root-canal obturation materials, survival analysis of endodontic treatment outcomes, diagnosis and treatment of VRFs, and use of CBCT in endodontics. Dr Özer can be reached at senemygt@hotmail.com.


TOOLS TO KEEP SMILING

No less than ...
...4 launches !




D-RaCe

Desobturation made easy



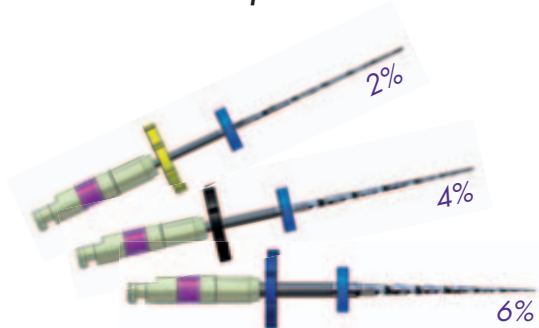
Scout-RaCe

Mechanical scouting sequence




FKG RaCe ISO 10

Glide path files



SMG handle

Indicator of uses



www.fkg.ch

FKG
FKG DENTAIRE
Swiss Dental Products

