

Laser-assisted cosmetic dentistry—A case report

Author _ Dr Hugh Flax, USA



As aesthetics are absolutely critical to a patient's external appearance and inner emotions, orchestrating a bio-aesthetic result is mandatory. Too often, this is complicated when aesthetic desires infringe on the health of the periodontal complex. This is often true when biologic width violations have occurred iatrogenically.

Many factors may contribute to these failures; the two main culprits are intra-crevicular margin location and over-contoured restorations. Not only is plaque accumulation problematic, but the supra-crestal fibres also become interrupted, causing the tissues to become further inflamed and aesthetically unmanageable. Kois' landmark study defined the total dento-gingival complex (DGC) as clinically predictable at 3 mm on the direct facial aspect and at 3 to 5 mm inter-proximally when measured from the free gingival margin to the osseous crest.

It is critical anteriorly that the gingival margin mimics the osseous scallop while maintaining the DGC.¹ Further complicating these complex situations is the degree of inflammation in the soft tissue, affecting the clinical development of health and aesthetic symmetry.

An ideal result

Often, the patient is frustrated with his/her previous poor cosmetic results. However, to improve the periodontal framework in order to create an ideal result, they must be referred to yet another doctor. Even more challenging is the extended

healing time created by reflective mucoperiosteal surgery. This not only affects the chronology of final restorative care, but also delays the patient's ultimate satisfaction and happiness for a minimum of two to three months.

Fortunately, dental lasers have evolved considerably as an adjunctive and alternative treatment to safely, conservatively and reliably decrease bacterial levels and improve the hard and soft-tissue contours. Studies of Er:YSGG lasers by Rizoio and others have shown that thermal coagulative results and bony ablation characteristics are similar to those resulting from use of a dental bur.² From a patient-friendly standpoint, less need for suturing and shorter healing times improve case acceptance for doing ideal dentistry. In selected cases, such as the one presented in this article, minimally invasive laser procedures, with precise restorative planning and technique, can satisfy aesthetic and functional parameters. Furthermore, patients can enjoy optimal results more comfortably and within a shorter time.

For this case, a conservative strategy was devised that would allow us to correct the problems and causes by completing multiple task simultaneously.

Case presentation

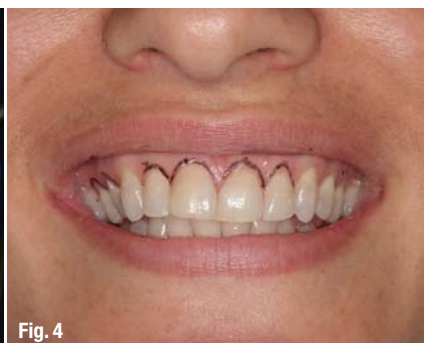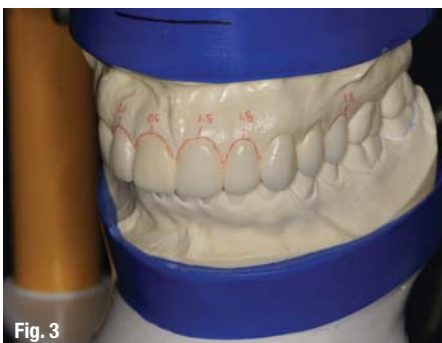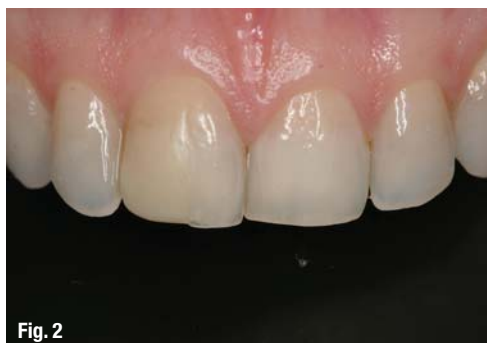A 38-year-old female patient presented for correction of what she termed her "tilted smile" (Fig. 1). Given that she was starting a new sales career, she also wanted to make her teeth brighter and her smile much broader. The patient shared her frustration

Fig. 1_Visualising the entire oral-facial composition helps to diagnose less harmonious features of the smile.

Fig. 2_Close-up photography is essential to planning periodontal-restorative care.

Fig. 3_A mounted diagnostic wax-up is a critical guide for planning a realistic result.

Fig. 4_Outlining the desired gingival margins prior to anaesthesia communicates a blueprint to the patient and restorative team.



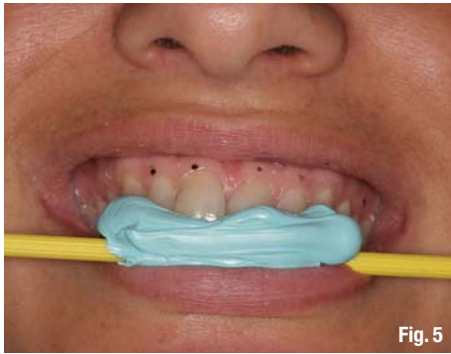

Fig. 5

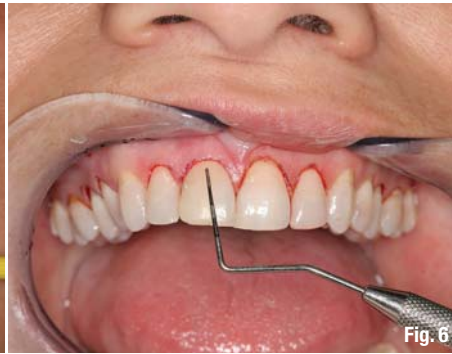

Fig. 6

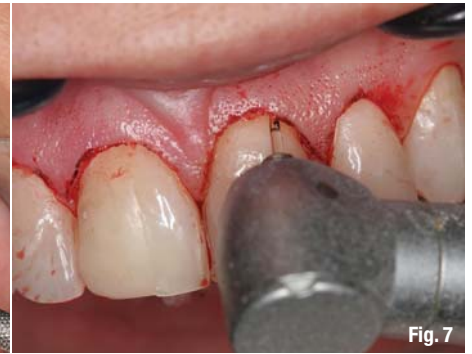

Fig. 7

about previous dental consultations that had focused solely on orthodontic or surgical solutions without considering a more practical approach that would suit her busy lifestyle.

Her smile analysis established a collapse of the bicuspid in the buccal corridor. Furthermore, the axial inclinations, irregular gingival margins and incisal edges created a downward tilt to the patient's right owing to tooth positioning. Close-up imaging demonstrated healthy gingival tissues, as well as a right central incisor weakened by a large composite (Fig. 2).

_ Findings

A full clinical examination with radiographs and mounted models revealed the following:

- _ biomechanically, the majority of her teeth remained strong despite previous dental care;
- _ periodontally, soft and hard tissues were healthy;
- _ occlusally, load testing was normal (after muscle relaxation) and there was obvious CR-CO anterior-vertical slide due to premature contact at tooth #30;
- _ aesthetically, the width-to-length ratio of the upper centrals was 1:2, far from the ideal range of 0.75:1.0, and tooth shade was VITA A2.

_ Treatment plan

Given the patient's previous history and her desire for minimally invasive dental care, a conser-

vative strategy was devised that would allow us to correct the problems and causes by conducting multiple tasks simultaneously:

- _ muscle and bite therapy with a Tanner appliance, followed by careful equilibration aided by the T-scan (Tekscan System);
- _ 3-D wax-up on a Stratos articulator (Ivoclar Vivadent; Fig. 3);
- _ home bleaching of the lower teeth with Opalescence 15% (Ultradent);
- _ 'closed flap' periodontal modification with the Waterlase Er,Cr:YSGG (Biolase), while the first three items were being accomplished (the combination of these four steps was a tremendous time saver and allowed us to monitor progress carefully on a weekly basis); and
- _ definitive restorative care with porcelain veneers and a crown on tooth #8.

_ Treatment

For the initial closed periodontal lift, the Er,Cr:YSGG laser was used in three modes (gingival sculpting, osseous recontouring, and bio-stimulation). Prior to anaesthesia, the desired framework was planned and outlined using a fine marker (Fig. 4). Furthermore, a stick-bite was used, not only to establish an ideal incisal plane, but also to align the gingival margins properly (Fig. 5).

With the settings at 2.0 W, 20 pulses per second, 20% air and 20% water, a G-6 tip (600 µm in diameter) was used to shape the labial gingival

Fig. 5 A stick-bite helps to verify that incisal and gingival planes will be parallel.

Fig. 6 The tissues are treated atraumatically with the Waterlase.

Fig. 7 Using the black mark as a reference following the gingival scallop, a very tight up-and-down movement is performed to modify the bone.

Fig. 8 A curette helps clean and smooth the sulcus of any debris.

Fig. 9 A 'laser bandage' is placed along the treated area to improve the healing time and decrease the patient's discomfort. Note the immediate improvement of the geometric progression of gingival embrasures.

Fig. 10 Detailed information helps the laboratory to translate clinical results to the porcelain restorations.

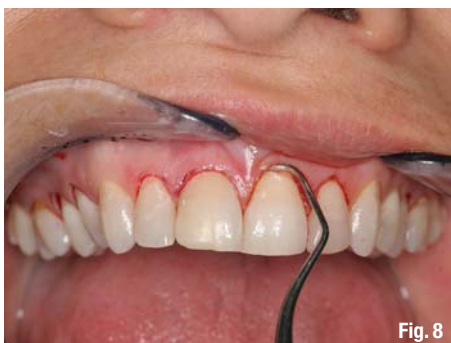

Fig. 8

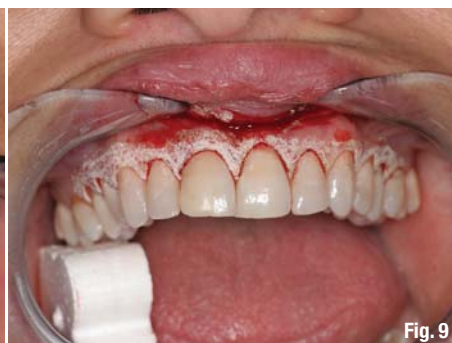

Fig. 9

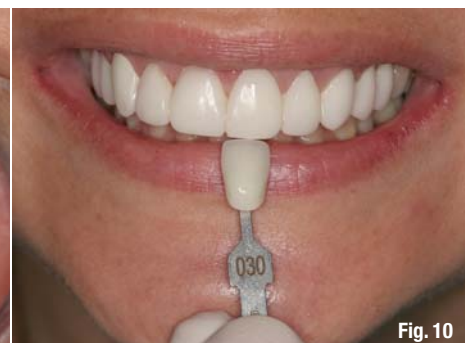

Fig. 10



Fig. 11

Fig. 11 _The great improvement in aesthetics boosted the patient's self-confidence and pride in her dental hygiene.

Fig. 12 _Ideal proportions and emergence profiles will create long-term healthy tissues and bio-aesthetics.

region. No tissue necrosis or significant bleeding occurred as a result of using the laser's relatively lower settings. All areas were 'sounded' using a periodontal probe (Fig. 6).

At the facial margins, osseous sculpting required great precision in order to maintain a 3 mm DGC. A specially tapered T-4 tip (400 µm in diameter) was used at a 25 % higher wattage of 2.5 W. Prior to usage, the tip was measured and marked to 3 mm in order to maintain controlled adjustments within the gingival sulcus during periodontal probing movement of the tip (Fig. 7). The resection was smoothed with a 7/8 curette (Fig. 8). Using low-level laser therapy at a setting of 0.25 W, a decrease in the release of inflammatory histamine and increased fibroblasts for junctional epithelial growth was achieved by 'frosting' the outer epithelium and injection sites (Fig. 9). The patient was placed on a vigorous home-care regimen (Oxygel,

Oxyfresh) and closely monitored for a month, while occlusal therapy and bleaching procedures were performed.

Four weeks after surgery, the tissues had healed and restorative care could be initiated. The patient's teeth were prepared for veneers and a crown with mild soft-tissue reshaping in order to make adjustments to our previous treatment. After taking impressions and bite registrations, prototype provisionals (Luxatemp Plus, Zenith DMG) were fabricated using the 'shrink-wrap' technique. The patient was sent home with the same home-care regimen as mentioned previously and instructed to 'test-drive' her new smile for aesthetics and function. She returned in a week for the prototype's occlusion, colour and morphology to be perfected. Photographs and models were sent to the laboratory, providing a final blueprint for the porcelain restorations (Fig. 10).

_Satisfied patient

Four weeks later, the provisionals and cement were carefully removed from the teeth. All restorations were tried in individually and as a group to verify fit and aesthetics. After the patient's enthusiastic approval, the porcelain was bonded using the two-by-two technique and isolation. Margins were smoothed and polished and occlusion balanced with the T-scan. A protective night-time appliance was created to bring longevity to the rehabilitation. Our very satisfied patient said that we had exceeded her expectations (Figs. 11 & 12).

A hard- or soft-tissue laser is a wonderful adjunctive tool for cosmetic and restorative dentistry. The case discussed here demonstrates that this type of laser technology gives dentists the ability to make significant hard- and soft-tissue changes while being minimally invasive. These changes not only improve the final aesthetic outcome of the case, but also provide the physiological functional parameters required for successful dentistry.

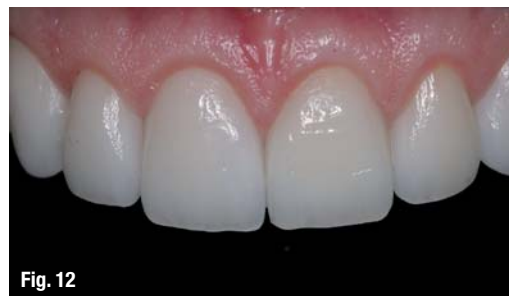

Fig. 12


_Acknowledgments

I would like to thank my office team and laboratory technician, Mr Wayne Payne (Payne Dental Lab), for continually enhancing the lives of many patients such as the one presented here. I am also thankful to my family, who allow me to contribute to the education of other dentists and their teams.

Editorial note: This article is reprinted with permission from the Journal of Cosmetic Dentistry, ©2010 American Academy of Cosmetic Dentistry (Tel.: +1 608 222 8583; Fax: +1 608 222 9540; www.aacd.com). All rights reserved.

A list of references is available from the publisher.

_about the author
cosmetic
dentistry



Dr Hugh Flax has been an Accredited Member of the American Academy of Cosmetic Dentistry (AACD) since 1997. He served as Co-chair of the AACD's Conference Advisory Committee for the 2003 and 2008 Annual Scientific Sessions. He served on the AACD Board of Directors, serves on the editorial board of the *Journal of Cosmetic Dentistry* and chair the AACD's Disaster Relief Fund in 2005 and 2006. Dr Flax is also a member of the American Dental Association, Academy of General Dentistry, Academy of Laser Dentistry, L.D. Pankey Alumni Association and Pierre Fauchard Academy. He is a Fellow of the International Academy for Dental Facial Esthetics. Dr Flax practises full time in Atlanta, USA, focusing on functional and aesthetic conditions and advanced laser dentistry.


kuraray

Master of the molecules

We research and develop for your success!



The MDP Monomer



MDP – the secret of PANAVIA™, CLEARFIL™ SA CEMENT and many other Kuraray products.

The patented adhesive monomer MDP stands for Kuraray's technological strength and innovation. After the phenomenal success of PANAVIA™, MDP also gives other products such as the bonding system CLEARFIL™ SE Bond or the self-adhesive resin cement CLEARFIL™ SA CEMENT its excellent adhesive properties.

**Experience the world of Kuraray at the IDS 2011
Hall 11.3 / Stand D 010**

For over 85 years now, the Japanese company Kuraray has been using its extensive experience and technologies to develop innovative and sophisticated solutions at the highest technical level for the world market – and for the past 38 years it has been equally successful in the area of dental materials.