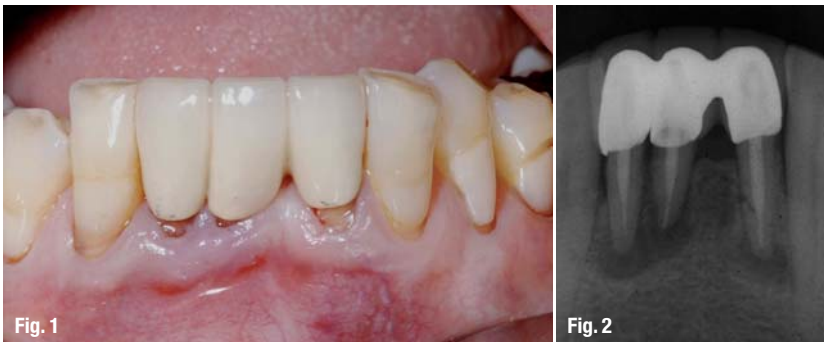

# Restoring missing mandibular incisors with implants— What makes you hesitate?

**Authors\_** Dr Chonghwa Kim & Sangwoo Lee, Korea



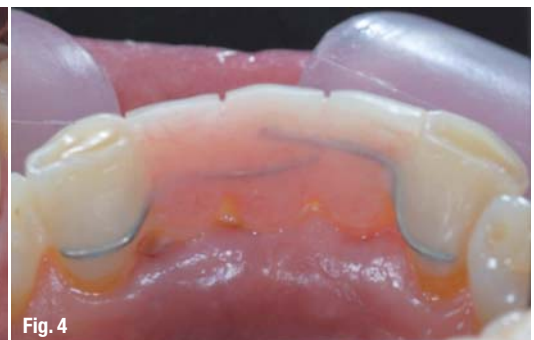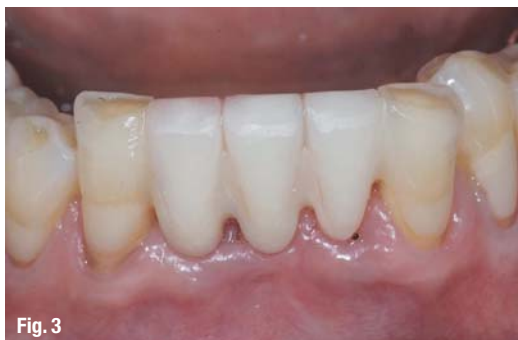Preparing mandibular incisors for bridge abutments is an extremely delicate procedure that often leads to root-canal treatment due to pulp damage that might occur during the procedure. Even without the risk of pulp damage, it is still quite a challenge to recreate natural contour and shade on such tiny dentition.

Dental implants have, in many cases, become the treatment of choice for restoring missing teeth and have been documented to have a high degree of success. With implant therapy, the preparation of healthy teeth adjacent to the edentulous area can be avoided. An additional advantage to the implant restoration is the maintenance of the alveolar bone, which otherwise would undergo resorption with other restorative options, hence, often complicating aesthetics.

What's happening in the real world? Are we comfortable enough placing implants in the mandibular anterior region? In spite of understanding both the disadvantages of conventional fixed bridgework and the advantages of implant restorations, we often make the treatment choice for missing mandibular incisors in favour of the bridge. Why is that? What hinders us from providing an implant option for patients in such cases? Restoring mandibular incisors with implants can be one of the most difficult dental

**\_Mandibular incisors can be** vulnerable to early loss due to their inherently weak periodontal support and high prevalence with respect to periodontal disease. What are the most common treatment options for missing mandibular incisors? Aside from removable prosthetic options, the restorative options for a fixed prosthesis include a conventional bridge, a resin-bonded bridge (Maryland Bridge) and implants. For a case in which one or two mandibular central incisors are missing, a three- or four-unit bridge has often been the treatment of choice. A resin-bonded bridge, in these cases, can be a reasonable alternative to a conventional bridge; whereas implant treatment, more often than not, is not suitable due to insufficient space. When more than two incisors are missing, the implant option may become the first choice for most clinicians these days.

**Fig. 1**\_Pre-op.  
**Fig. 2**\_Pre-op peri-apical X-ray.



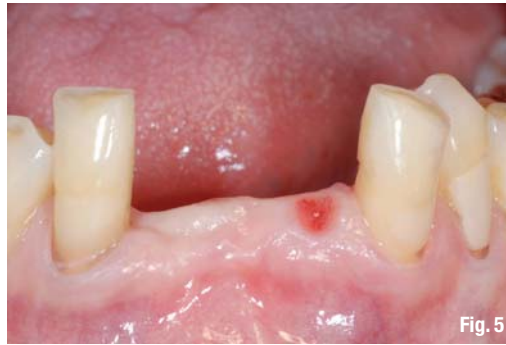**Fig. 3**\_Resin-bonded provisional restoration.  
**Fig. 4**\_Lingual view.

treatments to perform due to the limited amount of bone and interdental space. Placing implants in the mandibular anterior region can be challenging due to:

1. insufficient facio-lingual bone volume;
2. insufficient mesio-distal space between adjacent teeth;
3. insufficient height of remaining alveolar bone;
4. the presence of mento-labial depression, which limits the facio-lingual angulation of implants; and
5. the preservation or recreation of the interdental papilla being an extremely delicate procedure.

One of the prerequisites for the successful placement of an implant is the presence of adequate bone volume. Tarnow *et al.* stated that a submerged implant, following the delivery of the prosthesis, will create circumferential or horizontal bone resorption of 1.3 to 1.4 mm. Grunder *et al.* also stated that at least 2 mm of lateral alveolar bone must be present beyond the body of the implant to compensate for the effects of bone remodelling. If this amount of bone is not present, part or all of the facial or buccal bone plate will be lost after remodelling, with the subsequent risk of soft-tissue recession. This amount of bone around an implant rarely exists in the mandibular anterior region. Therefore, ridge augmentation procedures are often required to create adequate bone volume to maintain a 2 mm alveolar thickness following implant placement.

Another prerequisite for successful implant treatment is sufficient interdental space. The creation of a natural-looking implant restoration largely depends on the appropriate placement of the implant during surgery. In order to achieve this goal, careful planning and precise implant placement are essential. An implant requires a minimum distance of 1.5 mm between the implant and adjacent tooth to maintain interproximal bone and interdental papilla. Standard diameter implants of 4 mm or greater there-

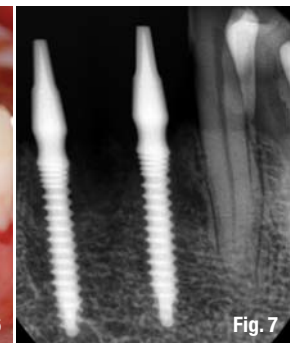
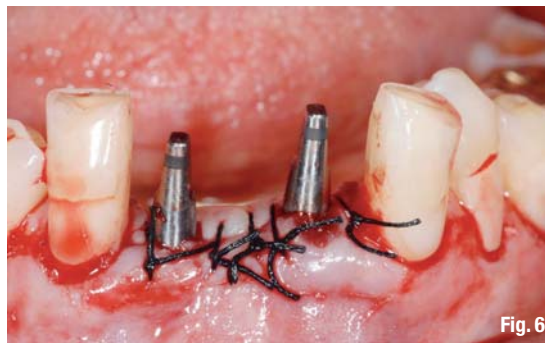

**Fig. 5** Twelve weeks post-extraction.

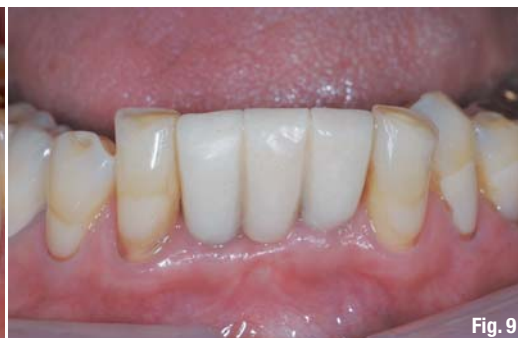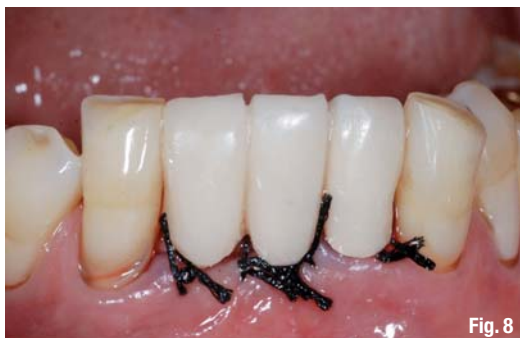fore require a mesio-distal space of at least 7 mm to place an implant. For an interdental papilla between two adjacent implants to be established, the inter-implant distance should be more than 3 mm. Thus, a minimum mesio-distal space of 14 mm is required to place two standard-diameter implants adjacent to each other.

Implant manufacturers have introduced narrow-diameter implants (3.0 to 3.5 mm) in an attempt to solve these problems. However, these

**Fig. 6** Following implant placement.  
**Fig. 7** Peri-apical X-ray at implant insertion.



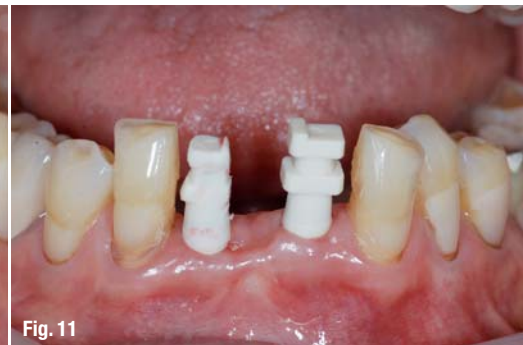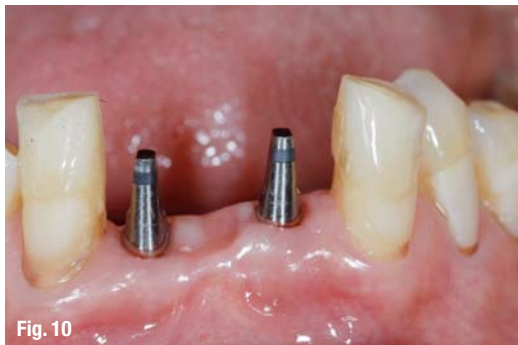implants still require a minimum mesio-distal space of 6.0 to 6.5 mm to allow adequate implant-to-tooth distance. With the exception of mandibular incisors, narrow-diameter implants present a solution for the aforementioned requirements of adequate bucco-lingual bone volume and proper implant spacing. For missing mandibular incisors, it would be beneficial to use implants with an even smaller diameter than narrow-diameter implants.



**Fig. 8** Immediate provisionalisation.  
**Fig. 9** Modification of provisional restoration.

**Fig. 10**\_ Eight weeks post-implant placement.

**Fig. 11**\_ Friction-fit impression caps.



**Fig. 10**

**Fig. 11**

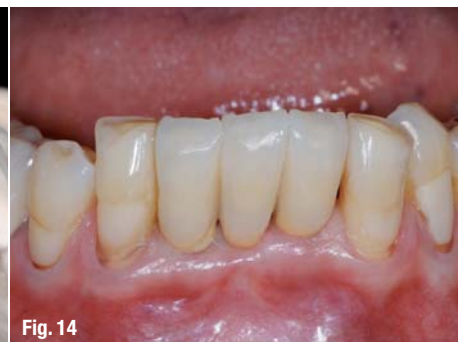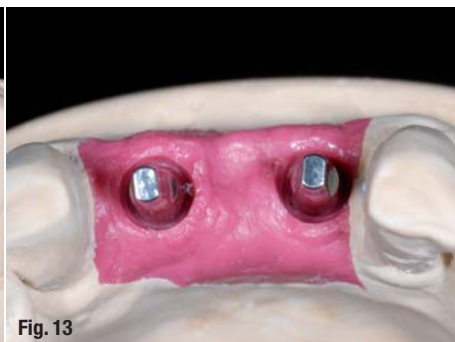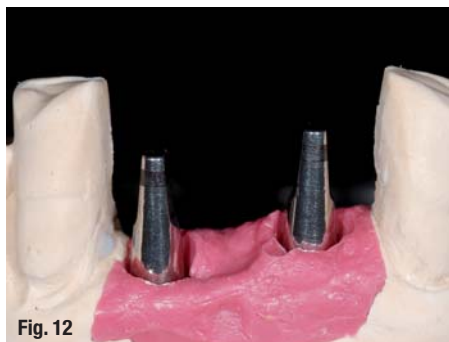
Mini-diameter implants (MDI) are not synonymous with narrow-diameter implants. MDIs are smaller in diameter than narrow implants and have a diameter of 2.7 mm or less. Because of their smaller diameters, MDIs require minimal interdental space while preserving more of the alveolar bone following the osteotomies for implant placement. MDIs were initially developed to support transitional prostheses and were ultimately intended to be removed. However, these implants

MDIs of less than 3 mm in diameter are fundamentally challenged as two-piece designs due to the insufficient strength of their component parts. When the diameter of an implant approaches 3 mm or less, either the abutment screw becomes too small or the internal axial walls of the implant become too thin to withstand the functioning load. These concerns can be overcome with a one-piece design. One-piece implants have recently received substantial

**Fig. 12**\_ Working cast.

**Fig. 13**\_ Top view.

**Fig. 14**\_ Final prosthesis.



**Fig. 12**

**Fig. 13**

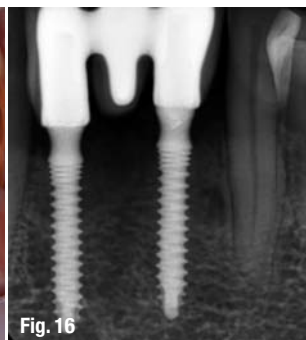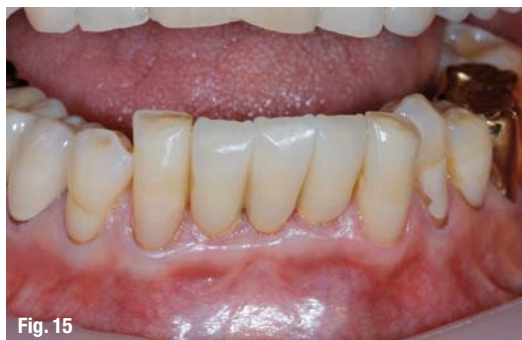**Fig. 14**

exhibited a bone-to-implant contact similar to that of implants with conventional diameters. Numerous studies have indicated that MDIs appear to be an effective treatment option for missing mandibular incisors. Nevertheless, one of the primary disadvantages of MDIs is the reduced resistance to occlusal loading. The retention of an implant, however, is correlated to the length of the implant and not the diameter. This implies that MDIs may be used in situations where excessive occlusal loading is not present.

attention in implant dentistry; yet, one-piece implants are not new to implant dentistry. While the use of one-piece implants has been controversial, they have been used for decades with reasonable clinical success.

**Fig. 15**\_ Thirteen-month follow-up.

**Fig. 16**\_ Peri-apical X-ray.



**Fig. 15**

**Fig. 16**

Recent variations from early designs have created a renewed interest in this old, but not obsolete concept. Most one-piece implants are composed of three portions—the bone-anchoring (fixation thread) portion, transmucosal portion and prosthetic abutment portion.

The primary disadvantage of one-piece implants is related to the fact that these implants must be placed with a one-stage protocol. Therefore, the angulation of the abutment cannot be altered and only minimal modification of the abutment is possible. Without the prosthetic freedom of the abutment choices, the initial surgical positioning of one-piece implants becomes critical in obtaining an optimal result.

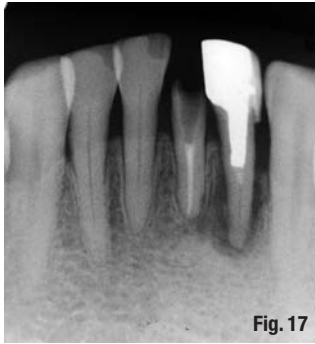

Fig. 17

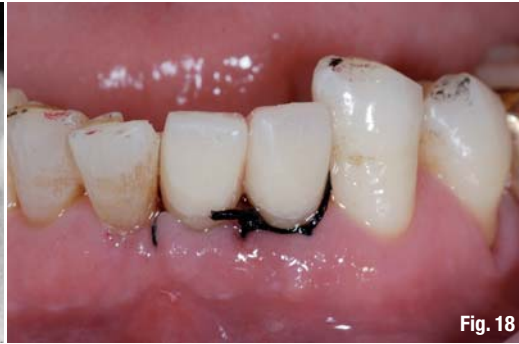

Fig. 18

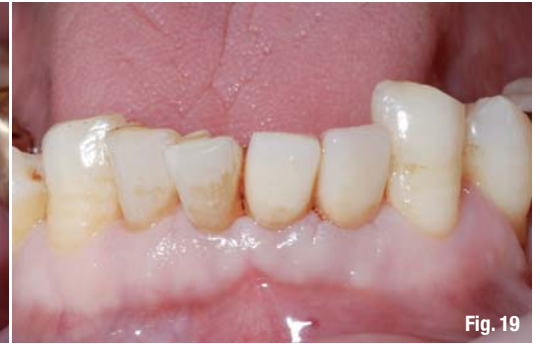

Fig. 19

The advantages of one-piece implants include minimally invasive surgery, simple restorative procedures and no screw loosening. Furthermore, the amount of crestal bone resorption may be minimised, since there is no micro-gap or micro-movement between the implant and its abutment. This becomes even more critical for long-term aesthetic results in the anterior region. In order to demonstrate the successful use of one-piece implants, this article describes the restoration of mandibular incisors with one-piece MDIs.

## \_Case reports

### Case I

A 67-year-old female patient presented with occasional throbbing pain in the mandibular anterior region. The patient's medical history was non-contributory. Clinical and radiographic evaluation revealed two separate peri-apical lesions on teeth #23, 25 and 26 (Figs. 1 & 2). The patient reported that tooth #24 had been extracted 15 years ago. The incisors were deemed non-restorable and treatment planned for extraction. Owing to the size and duration of the peri-apical lesions, delayed placement of implants was planned. The teeth were carefully luxated with a periosteal elevator and atraumatically extracted, preserving the thin facial bone. A wire-embedded provisional restoration was fabricated and bonded to the adjacent canines with flowable resin (Figs. 3 & 4). After ten weeks of healing, the provisional restoration was removed. The distance measured

between the two mandibular canines was 15 mm (Fig. 5).

A crestal incision was made and a limited soft-tissue flap was reflected to expose the alveolar crest of bone. In this fashion, the patient experiences reduced post-operative swelling and discomfort. With a 1.6 mm twist drill and copious irrigation, osteotomies were performed at a speed of 1,500 rpm. The angulation of the twist drill was carefully monitored throughout the osteotomies. Following completion of the prepared implant sites, visual and tactile inspection of the internal bony walls was performed to ensure the absence of any fenestration or dehiscence at the cervical area. Two 2.5 mm-diameter implants (MS implant, Osstem) were then placed in the ideal 3-D position and torqued to 25 Ncm with a manual torque wrench. The superior margin of the transmucosal portion was positioned 2 mm apical to the soft-tissue margin (Figs. 6 & 7). Immediately following implant placement, provisional restorations were fabricated at chairside using prefabricated temporary abutments and acrylic resin.

The provisional restorations were snapped into position using the friction-fit temporary abutments, eliminating the use of cement (Figs. 8 & 9). This could remove the risk of cement being forced into the gap between the implant fixture and soft tissue. The provisional restorations had no centric or eccentric occlusal contacts. The patient was instructed to avoid any function of the implant for eight weeks.

Fig. 17\_Pre-op X-ray.

Fig. 18\_Resin-bonded provisional restoration after extraction of teeth #23 and 24.

Fig. 19\_Eleven weeks post-extraction.

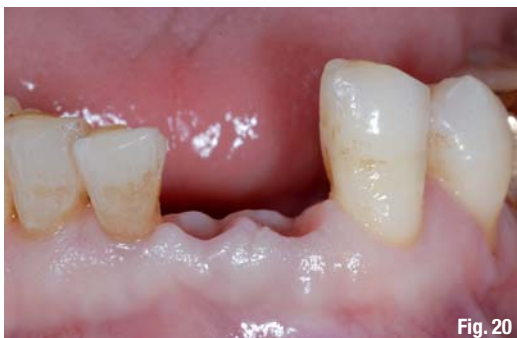

Fig. 20

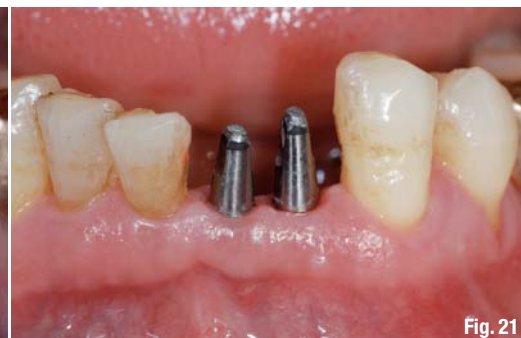
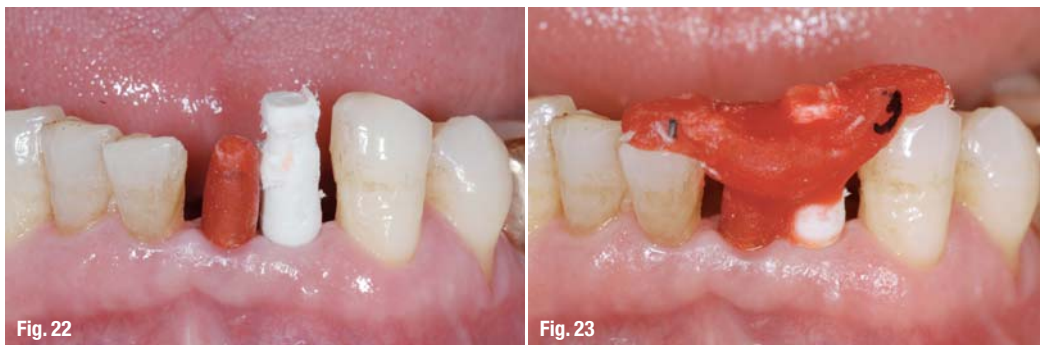
Fig. 21

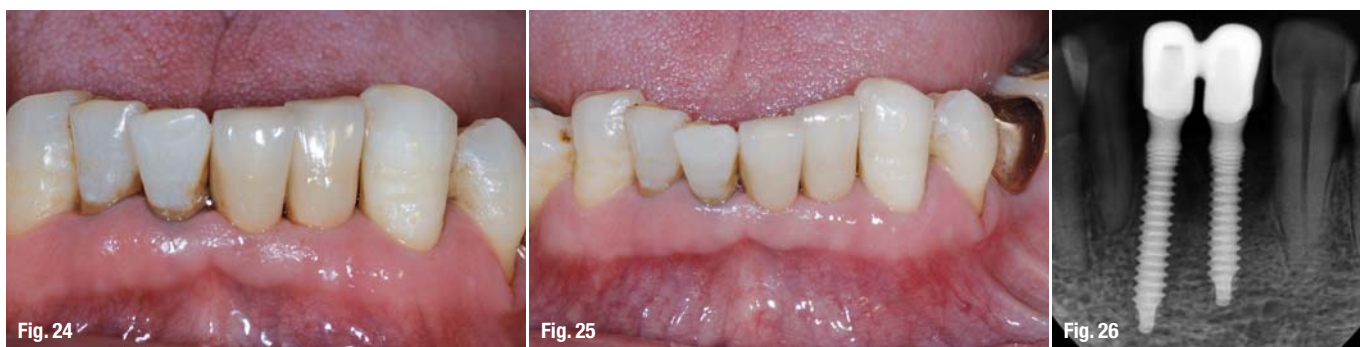Fig. 20\_Papilla preservation with ovate pontics.

Fig. 21\_Eight weeks post-implant placement.

**Fig. 22** Modified impression caps.  
**Fig. 23** Indexing jig.



**Fig. 24** Final prosthesis.  
**Fig. 25** Eleven-month follow-up.  
**Fig. 26** Peri-apical X-ray.



After a healing phase of two months, a final impression was produced using friction-fit impression caps (Figs. 10 & 11). Definitive restorations were then fabricated on the working cast and adjusted to have slight occlusal contacts

altered cast was made, and a definitive prosthesis was fabricated. The clinical and radiographic evaluation at 11 months demonstrated a good aesthetic result with no significant peri-implant bone loss (Fig. 24).


in centric occlusion and excursive movements (Figs. 12–14). The clinical re-evaluation demonstrated a minimal gingival change around the prosthesis, and a stable horizontal bone level was observed radiographically at the 13-month follow-up (Figs. 15 & 16).

*Case II*

A 58-year-old male patient presented with severe mobility and peri-apical lesions on teeth #23 and 24 (Fig. 17). A provisional restoration was fabricated and bonded to the adjacent natural teeth immediately following extraction (Fig. 18). The provisional restoration was left undisturbed for 11 weeks and the interdental papillae were preserved with ovate pontics (Figs. 19 & 20). The interdental distance measured between teeth #22 and 25 was 8 mm, and two 2.5 mm-diameter implants were placed in position. The superior margin of the transmucosal portion was positioned sub-gingivally, and the height of the abutments was reduced to ensure adequate incisal clearance (Fig. 21). Owing to the limited interdental space, the impression caps were modified (Fig. 22). An indexing jig was used to avoid any undue stress applied to implant fixtures during the impression procedure (Fig. 23). An

**Conclusion**

Based on the clinical cases presented in this article, the utilisation of one-piece MDIs appears to be a good treatment option for replacing missing mandibular incisors. Considering the simplicity, ease of implant placement and immediate provisionalisation, this treatment offers a new option for patient care.

<b>about the author</b>		<b>cosmetic dentistry</b>
	<p><b>Dr Chonghwa Kim</b> specialises in prosthodontics and implantology. He works in a private practice in downtown Seoul, Korea. He graduated from the University of Michigan School of Dentistry in 1997 and completed prosthodontic training at the University of Minnesota. Dr Kim is Co-director of the Global Academy of Osseointegration and serves as a Director of international relations for the Korean Academy of Esthetic Dentistry. He can be contacted at <a href="mailto:kimchonghwa@hotmail.com">kimchonghwa@hotmail.com</a>.</p>	



Reproducción autorizada por el Instituto Nacional de Bellas Artes y Literatura, 2011

# Federation Dental International Annual World Dental Congress

**NEW HORIZONS IN ORAL HEALTH CARE**  
14 - 17 SEPT. 2011



[www.fdi2011.org](http://www.fdi2011.org)  
[info@fdi2011.org](mailto:info@fdi2011.org)