

CLEARFIL SA CEMENT— Easy to remove, hard to forget!

Author _ Dr Jürgen Garlichs, Germany

In past years, adhesive technology has progressed substantially, especially in the area of direct, aesthetic composite restorations. The basis for enamel adhesion through acid etching was laid by Dr Michael Buonocore in the 1950s. Since then, the procedure has established itself as a safe and permanent method for adhesion in dentistry. For a long time, dentine adhesion was not able to provide even nearly as good results as enamel adhesion. Only in the 1990s were products developed that enabled reliable dentine adhesion.

Furthermore, most all-ceramic systems require an adhesive bond with the hard tooth substance to stabilise the ceramic framework.

CLEARFIL SA CEMENT

CLEARFIL SA CEMENT is a self-adhesive, dual-curing composite cement for the cementation of indirect restorations, such as crowns and bridges; inlays and onlays made of metal, ceramic and composite; as well as root-canal posts. The material is applied directly from the

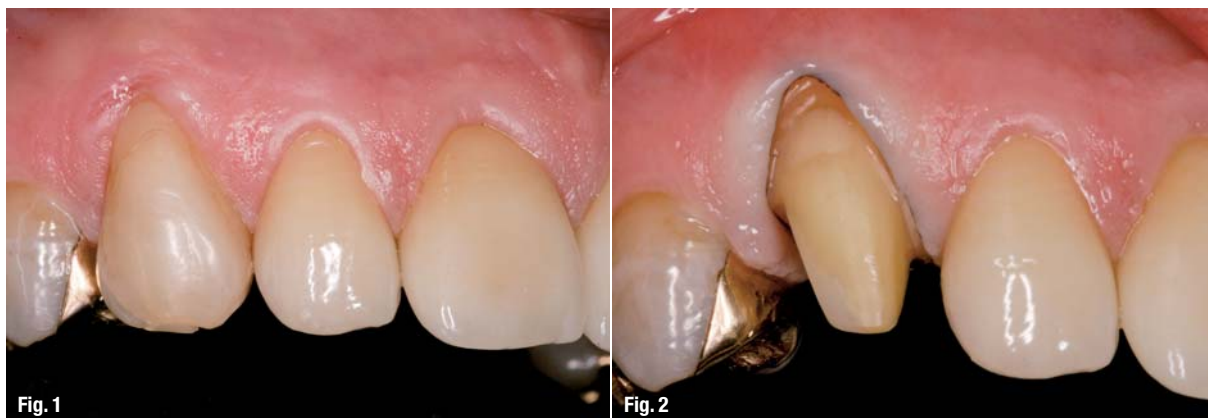

Fig. 1 _Initial situation. Tooth #13 with approximal caries, apical osteitis and poor cervical restoration. Prosthetic provision planned after endodontic treatment.

Fig. 2 _Prepared situation before insertion. Adhesive build-up fillings were placed in the cervical and disto-incisal areas. A retraction cord was used in order to ease cementation and drying.

Owing to the great results with direct adhesive techniques, they were also implemented for the adhesion of indirect prosthetic restorations. The aim was to combine the simple and quick handling properties of conventional cements with the good adhesion of modern composite provisions. This first led to the further development of classic composite cements and finally to the development of self-adhesive composite cements that do not require extensive pre-treatment of tooth structures.

The reasons for focusing on self-adhesive cements include numerous clinical trials, which prove that the bond and stability of metal-free crowns on prepared teeth are significantly higher with adhesive composite cements than with conventional cements, such as zinc phosphate, glass ionomer or polycarboxylate ce-

Automix delivery syringe without prior etching or bonding to the hard tooth substance. Furthermore, CLEARFIL SA CEMENT releases fluoride ions into the surrounding tooth substance. Compared with other fixing cements, CLEARFIL SA CEMENT provides an excellent bonding strength to enamel (23.2 MPa) and dentine (18.1 MPa),¹ as well as mechanical stability, in addition to its easy handling properties. Owing to its self-adhesive ability, the dentine tubules are sealed and hypersensitivities thus prevented.

CLEARFIL SA CEMENT mainly contains Bis-GMA, TEGDMA, hydrophobic dimethacrylate and MDP. Its self-adhesive ability is achieved reliably and effectively through the unique adhesive monomer MDP as tried and tested in CLEARFIL bonding cements and PANAVIA (both

Kuraray). Owing to the affinity of CLEARFIL SA CEMENT to and good wettability of the tooth surface, the MDP penetrates into the tooth structure effectively and ensures even adhesion. Multifunctional monomers and the dual-curing catalyst system provide a high cross-linking rate and good polymerisation characteristics. The mixed, uncured cement has a mildly acidic pH value. After application, the pH value rises until it is neutral in its polymerised state. CLEARFIL SA CEMENT contains 66 wt% (45 vol%) of filler material in and below the micro-metre range with an average size of 2.5 μm , and therefore has exceptional mechanical properties in combination with a thin layer of only 19 μm .

Clinical case reports have proven the excellent material properties of CLEARFIL SA CEMENT. In an investigation, Dr Cornelis Kleverlaan at the Academic Centre for Dentistry Amsterdam recorded a flexural strength of 81 MPa for CLEARFIL SA CEMENT. A trial by Yamamoto *et al.* at the University of Osaka demonstrated that

metal posts and glass-fibre posts. CLEARFIL SA CEMENT is available in Universal (A2) and White colour shades.

Advantages of CLEARFIL SA CEMENT

The most significant clinical advantage is good adhesion through the MDP monomer and the resulting secure mechanical and chemical bond to enamel and dentine. CLEARFIL SA CeMENT is a universally applicable material and, owing to the thin layer it creates, allows for an adhesion cement layer of only 19 μm and thus high dimensional stability. The low water resorption in combination with excellent margin qualities supports long-term stability.

CLEARFIL SA CEMENT was developed on the basis of PANAVIA, a gold standard adhesive composite cement, whose properties have already been proven over a long period of time. The handling parameters were the main focus during the development of CLEARFIL SA CEMENT. The resulting advantages are undoubtedly its simple

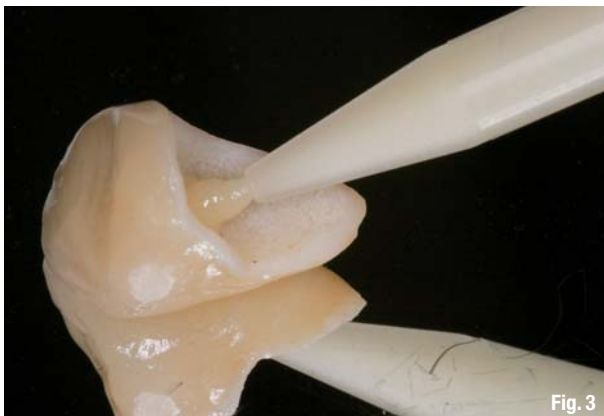

Fig. 3

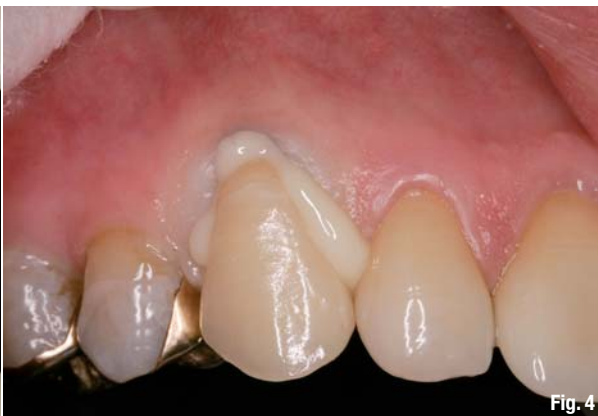

Fig. 4

CLEARFIL SA CEMENT has a low linear expansion rate (0.26%) and low water absorption (27.7 $\mu\text{g}/\text{mm}^3$).² A survey on the quality of the margins by Sadr *et al.* at Tokyo Medical and Dental University found perfect margins on all samples even after 3,500 thermal cycles.³ (For complete trial results, please refer to the detailed scientific product information of the manufacturer.)

Application range

CLEARFIL SA CEMENT is suitable for a wide range of indications involving indirect restorations and a wide range of materials, such as the cementation of crowns, bridges, inlays, onlays made of ceramic (zirconia, alumina, silica-based ceramic, etc.), hybrid ceramics, composite resin and metal, as well as metal cores, resin cores,

handling properties, the quick implementation of the treatment steps, the Automix application and flexible working times.

CLEARFIL SA CEMENT can be applied exactly portioned into the prepared restoration or onto the prepared tooth, directly after fitting the mixing tip. According to an internal trial, the relative moisture of the hard tooth substance is of secondary importance. CLEARFIL SA CEMENT provides very good bonding values on both dry, moist and wet enamel and dentine. Thanks to the dual polymerisation mechanism, the curing time can be controlled. After a short initial polymerisation of two to five seconds with the curing lamp, excess material can be easily removed.

After light-curing the margin for 20 seconds, the restoration will be set tight and saliva-proof

Fig. 3 Bubble-free application of CLEARFIL SA CEMENT (Universal) directly from the Automix syringe into the silane-treated, lithium-disilicate glass-ceramic crown. The hard tooth structure requires no conditioning.

Fig. 4 Ceramic crown directly after insertion. Excess CLEARFIL SA CEMENT can be easily squeezed out and remains at the crown margin without flowing away.

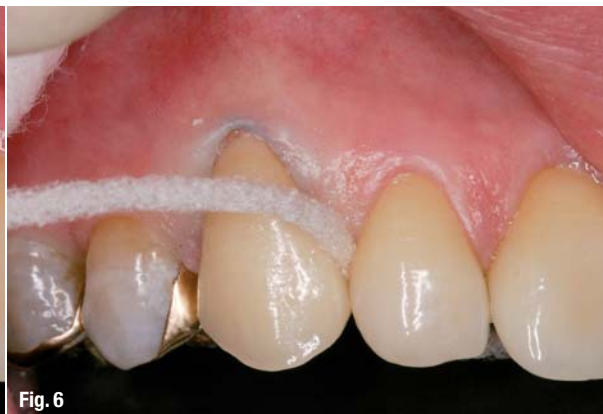
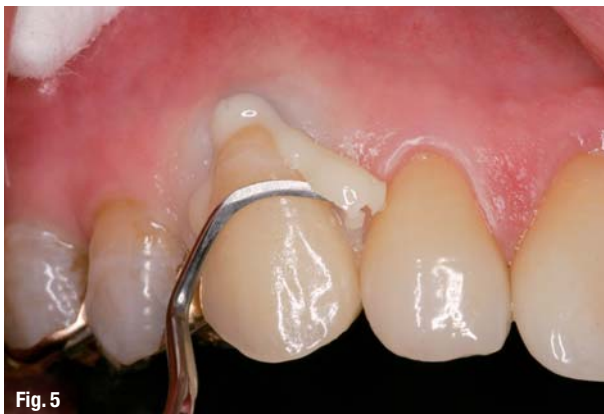
Fig. 5 After two to five seconds of light-curing, the excess material becomes gel-like and can be easily removed in one piece without leaving any residue.

Fig. 6 The approximal spaces are carefully cleaned with SuperFloss. The final light polymerisation phase takes 20 seconds.

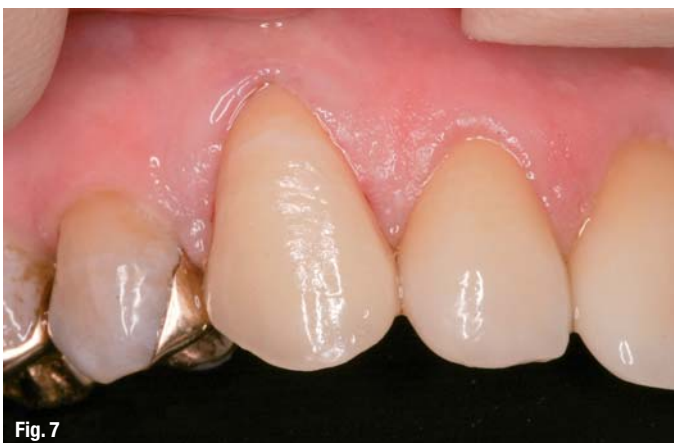in situ. Cement not reached by the light will polymerise within five minutes. Owing to the thinness of the CLEARFIL SA CEMENT layer, the cement will not alter the natural colour of the ceramic restoration. In general, the Universal (A2) colour shade is used. White, which shows a better contrast with the gingiva when removing excess material, is used to shield against dark dentine colours or under metal restorations.

Clinical case

A 65-year-old patient presented with pain in tooth #13. After examination and X-ray analysis, profound approximal caries and apical osseitis were diagnosed. Furthermore, the existing cervical filling showed an insufficient marginal seal (Fig. 1). The neighbouring teeth #12, 11 and 22 had already been treated with ceramic crowns.

Tooth #13 first received endodontic treatment in several sessions. After all signs of inflammation had ceased, the root canal was permanently filled and a provisional crown placed in order to ensure a non-irritated state of the root-canal filling before placing the permanent crown.

Fig. 7 Situation directly after insertion of restoration and removal of retraction cord.

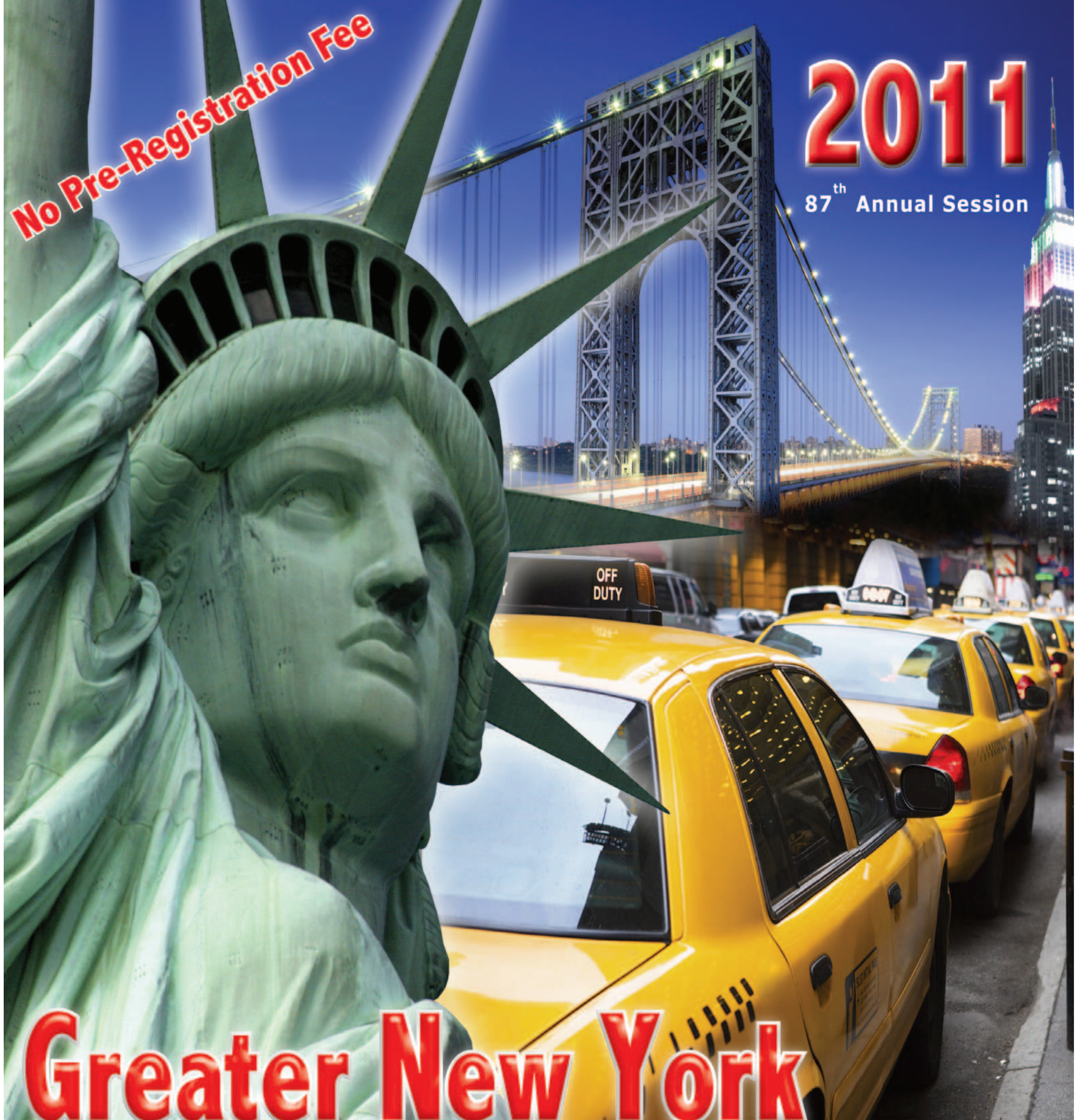


Prior to definitive stump preparation, the provisional distal and cervical crown parts received adhesive build-up fillings. For the restoration, we used the universal composites CLEARFIL MAJESTY Esthetic and CLEARFIL MAJESTY Flow. The self-etching, two-step adhesive CLEARFILSE BOND was used for the adhesive pre-treatment of the dentine. The preparation was completed and the colour of the crown defined using a VITA shade guide.

The impression was taken as a one-step, putty-wash impression. Tooth #13 received a temporary crown until the ceramic crown was inserted. The temporary crown on tooth #13 was removed and the core thoroughly cleaned directly before the crown was inserted. A retraction cord was used in order to ease the insertion of the crown, as well as for contamination control purposes.

The gingiva appeared to be free of any irritation, the resin core was free of any clefts and the preparation margin was exactly and clearly defined (Fig. 2). An IPS e.max Press (Ivoclar Vivadent) crown was provided by the laboratory ready to use (Fig. 3). Try-in showed that the fit was good so that the crown could be inserted permanently. The crown was cleaned and treated according to manufacturer's instruction. The stump was cleaned with water and any excess water removed (Fig. 2).

After fitting the mixing tip, CLEARFIL SA CEMENT in Universal (A2) was directly applied into the crown with the Automix syringe (Fig. 3). CLEARFIL SA CEMENT is supplied bubble free in the container. Ideally, the mixing tip of the Automix syringe should remain in the cement during application in order to avoid incorporating any air bubbles. After application of the cement into the restoration, the dentist has one minute of working time in which to insert the restoration. When cementing inlays, onlays or



No Pre-Registration Fee

2011

87th Annual Session

**Greater New York
Dental Meeting™**

Scientific Meeting:
Friday, November 25 -
Wednesday, November 30



Exhibits:
Sunday, November 27 -
Wednesday, November 30

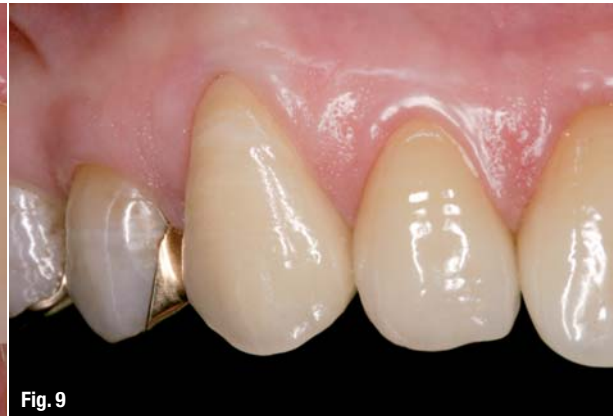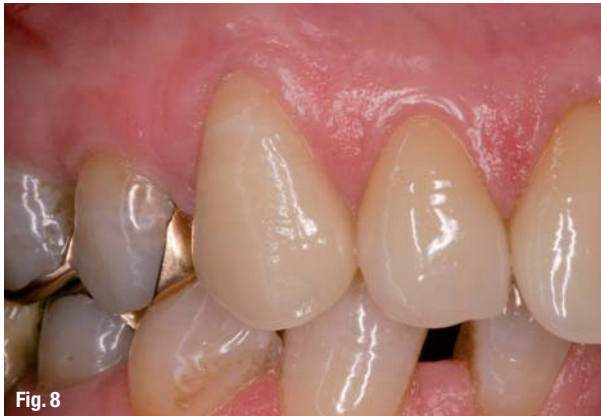The Largest Dental Meeting/Exhibition/Congress in the United States

root-canal posts, CLEARFIL SA CEMENT can also be applied directly into the cavity. Owing to the higher temperature in the oral cavity, the available working time is thus reduced to approximately 40 seconds.

The thixotropic properties of CLEARFIL SA CEMENT enable easy insertion and positioning into the final position, as the material flows under pressure (Fig. 4). Nevertheless, excess material will remain at the crown margin without flowing

_Summary

In the case described, IPS e.max Press, a lithium-disilicate glass-ceramic restoration, was inserted with the self-adhesive composite cement CLEARFIL SA CEMENT. This product is distinguished by its efficient Automix application and its dual polymerisation mechanism. The application of the material and the insertion of the restoration are made easier thanks to the thixotropic effect.



Figs. 8 & 9 One week after insertion of the ceramic crown on tooth #13 the gingiva appears to be free of irritation. The marginal fit is tight and the transition cannot be seen with the naked eye. The natural colour of the ceramic is not influenced by CLEARFIL SA CEMENT.

away and can be coagulated slightly by applying a polymerisation lamp for two to five seconds, depending on the lamp's power, so that it can be easily removed with an instrument, usually in one piece (Fig. 5). It is important that while removing the excess material, the crown be held fast in its final position.

For ceramic and composite crowns, light polymerisation occurs for 20 seconds from both sides after removal of excess material. As CLEARFIL SA CEMENT is dual-curing, the final chemical polymerisation of the areas that cannot be reached by light is achieved after five minutes, meaning that CLEARFIL SA CEMENT can also be used under metal restorations.

Cleaning of the approximal spaces with SuperFloss (Oral-B) and the removal of the retraction cord are carried out after complete light- and chemical curing (Fig. 6). CLEARFIL SA CEMENT ensures a tight marginal fit and does not influence the colour shade of the ceramic or composite restoration.

Figure 7 shows the completed restoration *in situ* directly after insertion and removal of the retraction cord. Figures 8 and 9 show the non-irritated state at one week after insertion of the prosthetic provision for tooth #13. The marginal fit is tight and the transition cannot be seen with the naked eye.

CLEARFIL SA CEMENT provides secure mechanical and chemical bonding to tooth structures and restorations. It can be used in many application areas ranging from metal, ceramic and composite restorations to root-canal posts. The thin layer of CLEARFIL SA CEMENT and low solubility ensure long-term prosthetic success.

_References

1. Iwamoto N, Uctasli S, Ikeda M, Nakajima M, Tagami J. Shear Bond Strength of New Self Adhesive Cement to Enamel and Dentin. International Symposium for Adhesive Dentistry 2008 in Kanazawa. Abstract #P-24.
2. Yamamoto H, Nakamura T, Wakabayashi K, Okada A, Kinuta S, Yatani H. Mechanical Properties of New Self-adhesive Resin Based Cement. International Symposium for Adhesive Dentistry 2008 in Kanazawa. Abstract #P-28.
3. Sadr A, Shimada Y, Tagami J. Micro leakage of Class-V Inlays using an Experimental Self-Adhesive Resin Cement. IADR Meeting in Toronto, 2008. Abstract #0404.

_contact

cosmetic
dentistry

Kuraray Europe GmbH

BU Medical Products
Hoechst Industrial Park/F 821
65926 Frankfurt/Main
Germany

dental@kuraray.eu
www.kuraray-dental.eu

The 30th Moscow International Dental Forum

Moscow 2011

The 30th Moscow International Dental Forum



Dental-Expo
international dental fair

September 26-29

Crocus Expo exhibition grounds

more than
450
exhibitors

more than
25000
attendees

more than
35
countries

www.dental-expo.com

DENTALEXPO[®]

