

cosmetic dentistry

_ beauty & science

1²⁰¹¹

| **clinical technique**

Reattachment and build-up of fractured maxillary central incisors

| **case report**

Laser-assisted cosmetic dentistry

| **industry report**

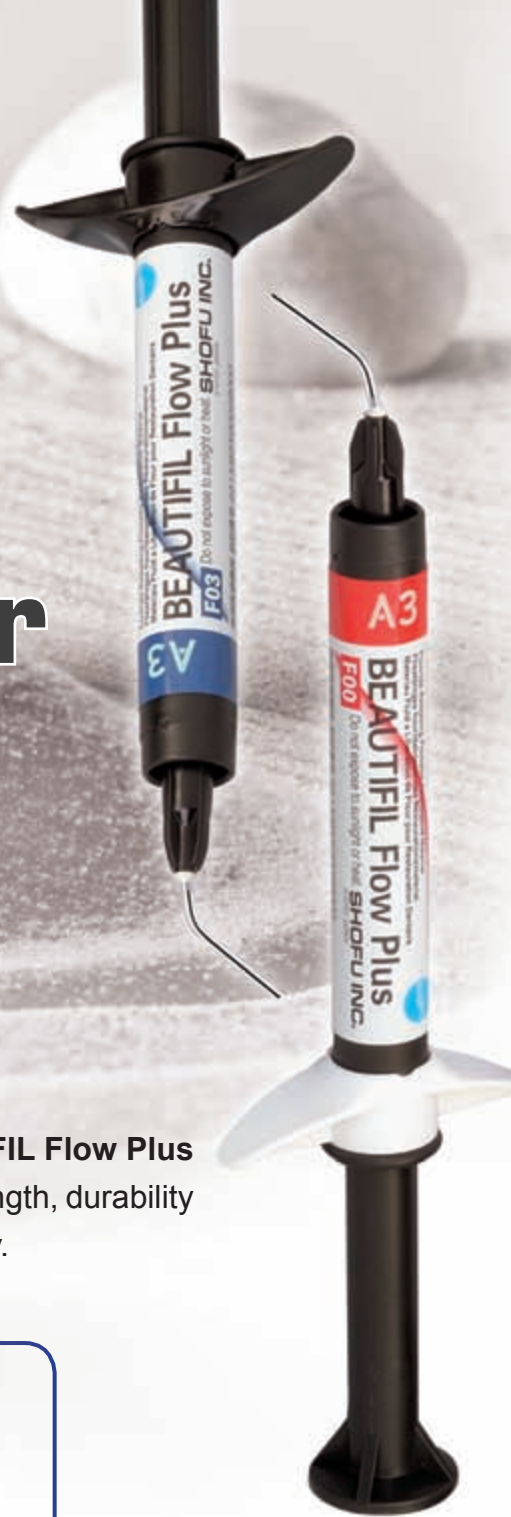CLEARFIL SA CEMENT—
Easy to remove, hard to forget!

kuraray

0277113

Strength *of a Hybrid ...*

... Deliver *like a flow*



BEAUTIFIL Flow Plus

Yet another milestone in the Giomer family of restoratives, **BEAUTIFIL Flow Plus** is an injectable hybrid aesthetic restorative that exhibits superior strength, durability and aesthetics for enhanced applications in direct cosmetic dentistry.

The Plus benefits for you ■■■

- Ideal density and stackability for effortless sculpting
- Remarkable mechanical properties
- Easy injectable delivery
- Extensive application capabilities including load-bearing surfaces
- Simulates life-like aesthetics with excellent shade match
- Benefits of fluoride with anti-plaque effect

Official Partner



Minimally Invasive
Cosmetic Dentistry

*For further information, contact your Shofu dealer
TODAY!*



SHOFU INC.

Singapore Branch 10 Science Park Road, #03-12 The Alpha, Science Park II, Singapore 117684
Tel: 65-6377 2722 Fax: 65-6377 1121 eMail: mailbx@shofu.com.sg www.shofu.com.sg

Dear Reader,

_Welcome to this year's first edition of **cosmetic dentistry**!

As we all know, the American Dental Association (ADA) has played an important role in dentistry not only in America, but also worldwide. On 13 October 2010, Dr Raymond Gist was installed as the 147th President of the ADA. Dr Gist made ADA history as the first African-American President to serve in this role. In a recent interview, Dr Gist stated: "I am looking forward to continuing to create a history that will be embraced [...] I see nothing but positives for the future of dentistry."

Likewise, I see many positives for the future of aesthetic/cosmetic dentistry. For the past two decades, aesthetic dentistry has been well led by the International Federation of Esthetic Dentistry (IFED). IFED's ultimate purpose has been to contribute to the progress and development of worldwide aesthetics and oral health and to enhance communication between all member academies. Amongst IFED members are the Asian Academy of Aesthetic Dentistry, Japan Academy of Esthetic Dentistry, Korean Academy of Esthetic Dentistry, Taiwan Academy of Aesthetic Dentistry, and Indian Academy of Aesthetic and Cosmetic Dentistry. Personally, I hope more Asia-Pacific countries such as China, Singapore, Thailand, Nepal, Sri Lanka, Australia and New Zealand will join the Federation to contribute to dentistry and enhance communication worldwide.

In February, Dr Dan Nathanson (USA) passed the IFED Presidency to Dr José Moura (Brazil) with a new executive committee of nine members. Amongst the current executive committee members, Dr Akira Senda (Japan) and Dr Sushil Koirala (Nepal) will be representing Asia.

I am sure that this edition of **cosmetic dentistry** will meet your expectations in seeking critical clinical tips to improve on your everyday clinical work especially in the area of bonding in the aesthetic zone. Please send your invaluable feedback and participate in improving our journal's quality to the highest level of excellence.

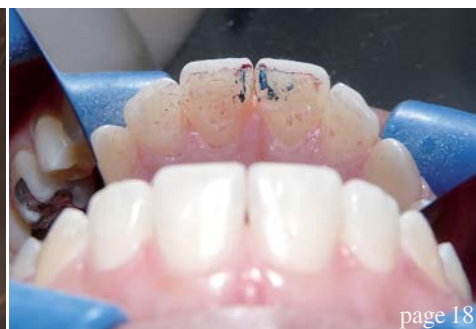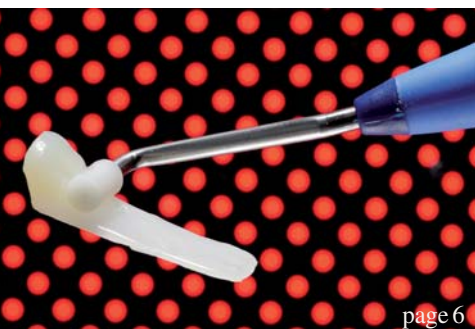
Yours faithfully,



Dr So-Ran Kwon
Co-Editor-in-Chief
President, Korean Bleaching Society
Seoul, Korea



Dr So-Ran Kwon
Co-Editor-in-Chief



| **editorial**

- 03 **Dear Reader**
| Dr So-Ran Kwon, Co-Editor-in-Chief

| **clinical technique**

- 06 **Reattachment and build-up** of fractured maxillary central incisors
| Dr Irfan Ahmad

| **case report**

- 14 **Laser-assisted** cosmetic dentistry—A case report
| Dr Hugh Flax
- 18 **Integration of aesthetics and function** with composite resins
| Dr Rony Hidalgo Lostanau *et al.*
- 20 **Restoring missing mandibular incisors with implants**—What makes you hesitate?
| Dr Chonghwa Kim & Sangwoo Lee

| **feature**

- 26 **An interview with Dr José Roberto Moura, IFED President**
- 28 **An interview with Olaf Sauerbier, CEO of VOCO GmbH**

| **MICD**

- 30 **The Inman Aligner**—Alignment, bleaching, bonding: **A progressive approach to smile design** (Part II)
| Dr Tif Qureshi

| **industry report**

- 36 **CLEARFIL SA CEMENT**—Easy to remove, hard to forget!
| Dr Jürgen Garlachs
- 42 **Aesthetic restoration** created with composite
| Dr Anna Salat Vendrell
- 44 **Class II fillings** in everyday clinical work
| Dr Sylvain Mareschi

| **industry news**

- 46 **Lithium disilicate** meets **zirconium oxide**
| Ivoclar Vivadent

| **meetings**

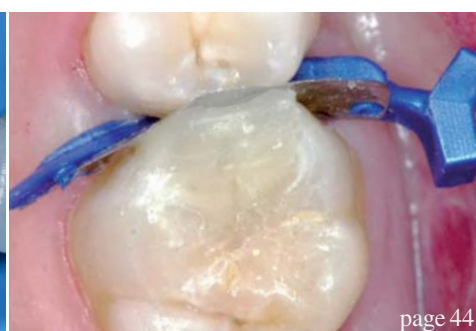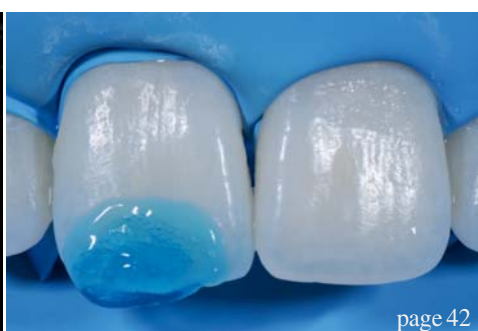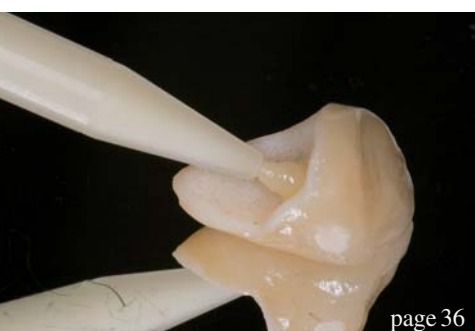- 48 **International Events**

| **about the publisher**

- 49 | submission guidelines
- 50 | imprint



Cover image courtesy of Kuraray Europe GmbH, www.kuraray-dental.eu.

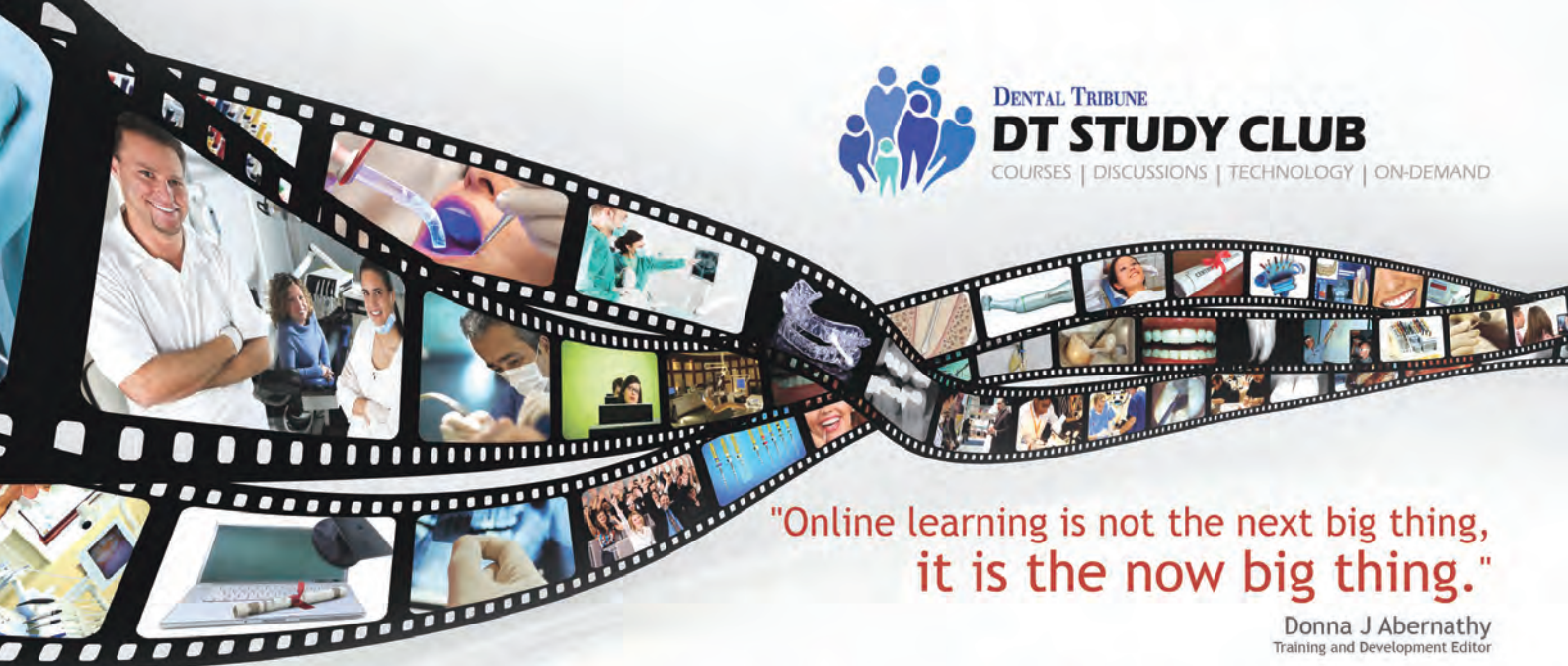



DENTAL TRIBUNE

DT STUDY CLUB

COURSES | DISCUSSIONS | TECHNOLOGY | ON-DEMAND



**"Online learning is not the next big thing,
it is the now big thing."**

Donna J Abernathy
Training and Development Editor

DTSC - COURSES, COMMUNITY, TECHNOLOGY, ON-DEMAND

The DT Study Club makes all of this possible from the comfort of your own computer and without travel expenses. In other words, welcome to the community!

The purpose of this study club is to provide practitioners like yourself an opportunity to learn and network with like-minded colleagues in a friendly, non-threatening environment. We encourage you to take advantage of Dental Tribune's global outreach to access a variety of fresh perspectives and cultures, enhancing your educational mix.

24/7 LIVE AND INTERACTIVE ONLINE COURSES

Fulfill your yearly CE requirements with our growing list of archived ADA CERP approved courses.



DISCUSSION FORUMS

focused on helping today's practitioners to stay up to date. Networking possibilities that go beyond borders to create a truly Global Dental Village



VIDEO REVIEWS OF PRODUCTS

Our opinion leaders unveil new products, services, and give you their first impressions of the industry's hottest topics.



PEER REVIEWED CASE STUDIES

Upload, comment, participate. We encourage you to share your cases for review with like-minded practitioners.



REGISTER FOR FREE ON WWW.DTSTUDYCLUB.COM

CONTESTS WITH CHANCES TO WIN FREE TUITION FOR ADA/CERP C.E. ACCREDITED WEBINARS

SPONSORSHIP AND SPEAKING INQUIRIES:
JULIA WEHKAMP, J.WEHKAMP@DTSTUDYCLUB.COM, (416) 907-9836.

ADACERP
CONTINUING EDUCATION RECOGNITION PROGRAM



PRACTICE MANAGEMENT



GENERAL DENTISTRY



COSMETICS



ENDODONTICS



IMPLANTOLOGY



PERIODONTICS



ORTHODONTICS



DENTAL HYGIENE



WWW.DTSTUDYCLUB.COM



Reattachment and build-up of fractured maxillary central incisors

Author_ Dr Irfan Ahmad, UK

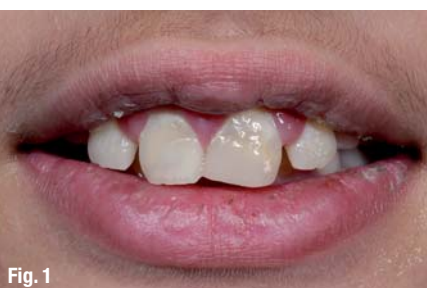

Fig. 1

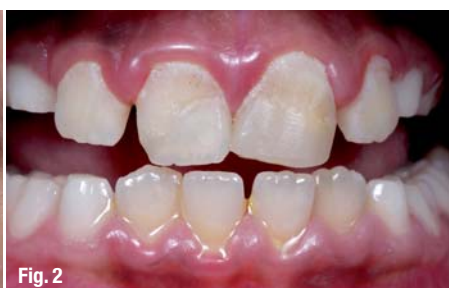

Fig. 2

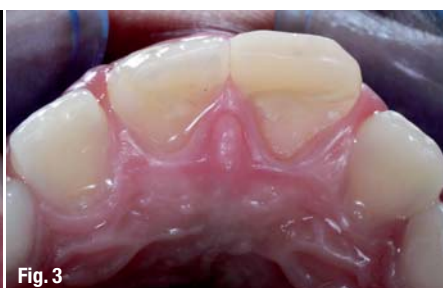

Fig. 3

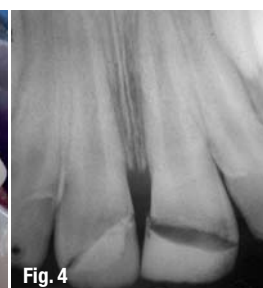


Fig. 4

Fig. 1 _Dentofacial view, showing immediate treatment of the two maxillary central incisors, following a sporting accident.

Fig. 2 _Pre-op status, showing extensive plaque deposits, acute gingivitis, reattachment of the coronal fragment on the right central incisor and a defective composite build-up on the left central incisor.

Fig. 3 _Incisal pre-op view, showing the reattached right fragment on the right central incisor and an over-contoured composite build-up on the left central incisor.

Fig. 4 _Peri-apical radiograph, showing large defects between the composite resin fillings and remaining tooth substrate, with large pulp chambers and immature, open apices.

Figs. 5-7 _Post-scaling and polishing, showing improvement of gingival

_Acute dental trauma of anterior teeth is a common occurrence in children under the age of 12. The most frequently fractured teeth are the maxillary incisors, involving solely enamel, enamel and dentine or, in extreme cases, pulpal exposure, very often without root fractures. Unlike the relatively slow tooth loss due to dental caries or tooth wear, acute dental trauma is an immediate, often painful loss of natural tooth substrate. Furthermore, involvement of the pulp complicates initial and long-term treatment, placing the affected teeth in jeopardy and requiring periodic monitoring.

The sequential treatment strategy for acute dental trauma is restoring health (H), followed by function (F) and lastly, achieving acceptable aesthetics (A); the HFA triad. Contemporary dental composites and direct adhesive techniques allow replication of the tooth morphology, as well as optical (colour, translucency, opalescence, fluorescence) and mechanical properties.

The advantage of a direct approach is that it is minimally invasive, not requiring additional removal of tooth substrate; however, it is technique sensitive, requiring patience and meticulous execution.

_Clinical case

A ten-year-old boy was involved in a sporting accident that resulted in acute dental trauma to the maxillary central incisors. The fractured fragment of the left central incisor was lost, while that on the right central incisor was located. The patient was treated at the accident and emergency department of a local hospital, where tetanus inoculation was verified and composite resin used to reattach the right central incisor fragment and to build-up the left central incisor (Figs. 1-3).

The patient presented to my practice a few weeks later, complaining of poor aesthetics and

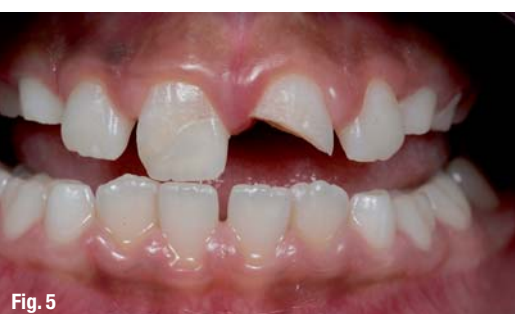

Fig. 5

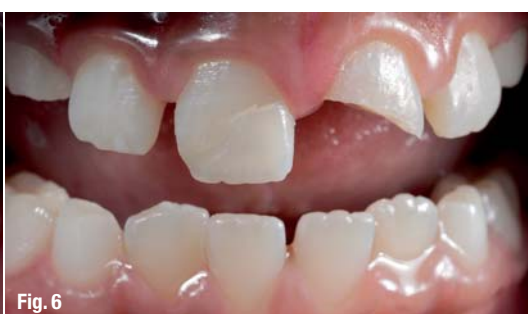

Fig. 6

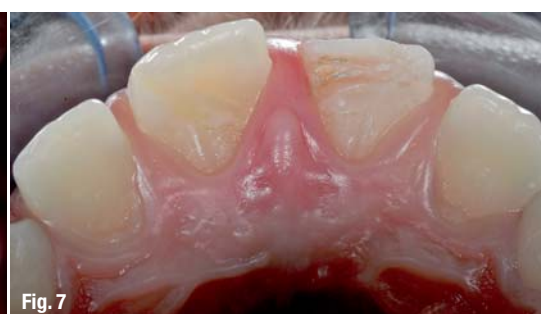

Fig. 7

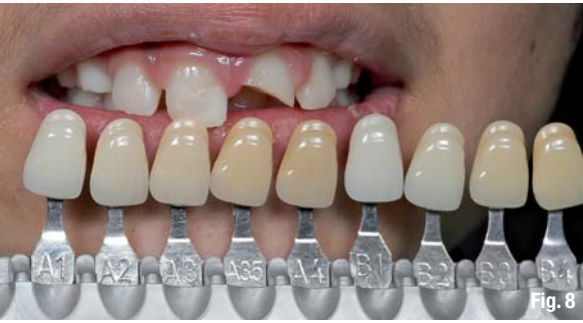

Fig. 8

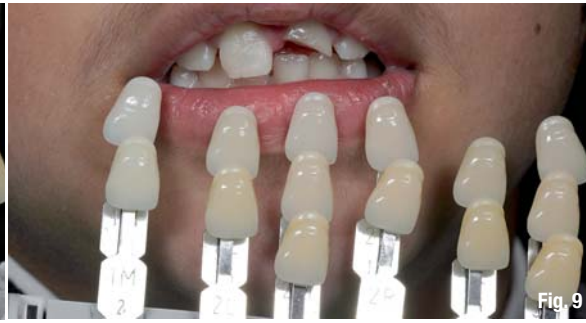

Fig. 9



Fig. 10

a dull ache in the buccal sulcus above the left central incisor. Intra-oral examination revealed poor contours of the composite fillings, with incorrect colour and texture. In addition, the patient's oral hygiene was unsatisfactory, with extensive plaque and calculus deposits causing acute gingivitis. The left central incisor was sensitive to gentle percussion, as well as to hot and cold stimuli.

Radiographs showed substantial defects between the composite filling and remaining tooth substrate, allowing ingress of oral pathogens (Fig. 4). The periodontal ligament was intact, no root fractures were evident and a typical solid cortical bone appearance, consistent with an acute dental trauma, was apparent.

Initial therapy

Before considering definitive treatment, the initial items requiring attention are the periodontal and endodontic status. Assessing the endodontic condition following acute trauma is essential for treatment planning. Following an accident, the patient is distressed, anxious and mentally traumatised. In addition, the shock of the physical trauma often results in a transient anaesthesia or paraesthesia of the pulpal neural fibres.

For these reasons, assessing pulp vitality with thermal or electrical stimuli, which are highly subjective, yields unreliable results. In addition, a false-negative result is often obtained with traumatised teeth owing to the transient

paraesthesia of nerve fibres. Conversely, a false-positive result is elicited when necrosis of the pulpal vascular tissues has occurred, leaving vital nerve fibres, which are more resilient. This may delay diagnosis and treatment of the affected tooth, often leading to root absorption.

A reliable and objective method for determining pulp vitality is pulse oximetry. Pulse oximetry measures the blood oxygen saturation levels or circulation within the pulp. The pulse oximeter consists of light-emitting diodes (LED) of two wavelengths (red light – 640 nm and infrared light – 940 nm) and a receptor for recording the spectral absorbance of the oxygenated and deoxygenated haemoglobin in the tooth pulp. A computer calculates the percentage of oxygen saturation levels, which is approximately 75 to 80 % for vital teeth, compared to values at the fingers or ear lobes of 98 %. The tooth oxygen saturation levels are lower than soft tissues of the body owing to the dentine and enamel, which scatters the LED light. A reading of 78 % was obtained for this patient, indicating that there was adequate vascularity for eventual regeneration of the pulp. At this stage, root-canal therapy was not necessary.

In order to resolve the acute gingivitis, the teeth were scaled and polished, and the patient counselled about home oral-hygiene procedures. Impressions for the diagnostic wax-up were delayed until gingival health had improved.

health and detachment of the defective composite build-up on the left central incisor. Notice the clearly visible dentine mamelons and incisal edge lobes of the reattached fragment on the right central incisor.

Fig. 8_Dento-facial view with VITA Classic shade guide.

Fig. 9_Dento-facial view with VITA 3D Shade Guide.

Fig. 10_Photograph of patient before the sporting injury. Notice the blatant maxillary midline diastema.

Fig. 11_A large overjet of 7 mm, making the maxillary incisors vulnerable to external trauma.

Fig. 12_Facial view of pre-op plaster model.

Fig. 13_Incisal view of pre-op plaster model.




Fig. 11

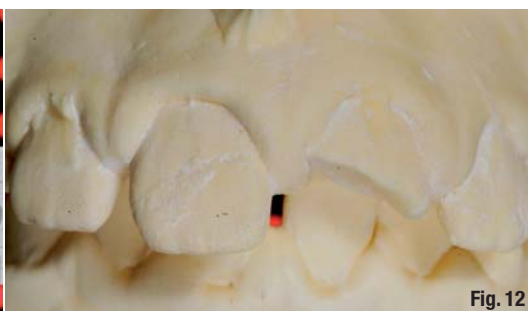

Fig. 12



Fig. 13

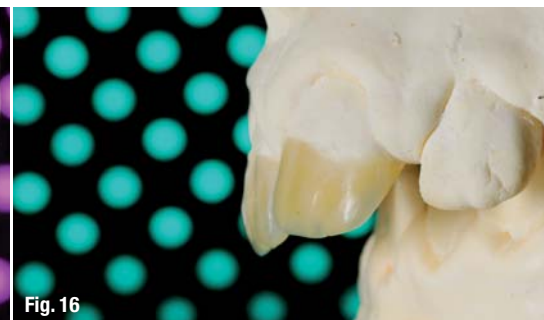
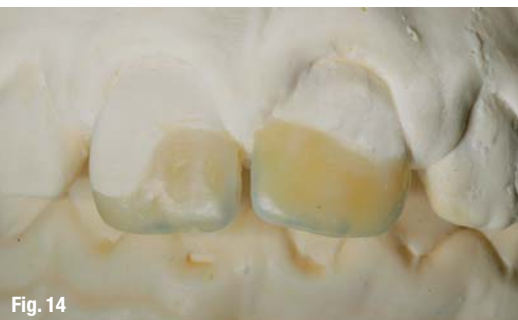
Fig. 14 _Facial view of diagnostic wax-up.

Fig. 15 _Right lateral view of diagnostic wax-up.

Fig. 16 _Left lateral view of diagnostic wax-up.

_Diagnostic wax-up and silicone index

At the next appointment the following week, the gingivitis had resolved but the composite build-up on the left central incisor had detached from the remaining tooth substrate (Figs. 5–7). In order to prevent sensitivity and bacterial invasion, the exposed dentine on the left central incisor was etched with 37% phosphoric acid for 20 seconds and immediately sealed with a dentine-bonding agent (OptiBond Solo Plus, Kerr). The gingival condition had improved following prophylaxis and oral-hygiene instruction, and upper and lower impressions were taken using an accurate, soft, distortion-free material (AlgiNot FS, Kerr). Concurrently, reference photographs were taken with VITA Classic and VITA 3D Shade Guides (VITA) for shade analysis (Figs. 8 & 9).

The impressions were cast with hard plaster for the diagnostic wax-up. The patient was asked to supply photographs of his teeth prior to the accident (Fig. 10), which are an invaluable guide for assessing tooth anatomy and for guiding the dental technician during the wax-up process. The patient displayed a large overjet of 7 mm, which obviously places the central incisors in a precarious situation, highly susceptible to traumatic injury (Fig. 11).

In the dental laboratory, the preoperative models of the fractured incisors were waxed-up to the proposed facial and palatal morphology (Figs. 12–17). An index was fabricated, using a heavy body, addition silicone impression ma-

terial and sectioned at the incisal edge, ensuring that a ledge was present at the incisal edge to support the intra-oral composite build-up (Figs. 18 & 19).

_Composite build-up on the left central incisor

Choice of composite

The two basic criteria for selecting an appropriate composite filling material are satisfaction of function (resilience, mechanical and thermal properties) and aesthetics (replicating enamel, dentine and characteristics such as translucency, opalescence and fluorescence). In this instance, the new Herculite XRV Ultra (Kerr) was chosen for its superior mechanical and optical properties. Herculite XRV Ultra is a nano-hybrid composite, updated from its predecessor Herculite XRV, which was introduced over two decades ago.

The endearing feature of nano-composites is the very small particle size of the filler, 25 to 75 nm smaller than in micro-hybrids. The reduced filler size particles confers superior aesthetics by allowing excellent surface gloss after polishing, as well as advantageous optical properties, such as opalescence and fluorescence. In addition, Herculite XRV Ultra offers favourable wear resistance, compressive strength, fracture toughness and flexural strength with good adaptability, sculptability and thixotropic properties. Furthermore, it is available in a large range of enamel, dentine and incisal shades for

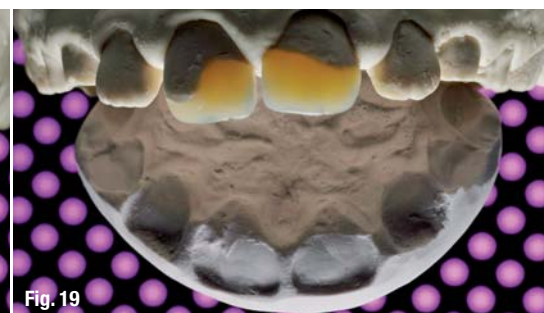
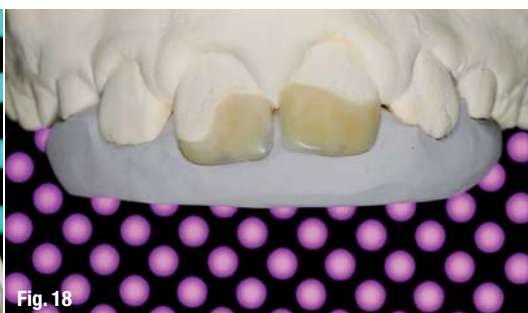
Fig. 17 _Incisal view of diagnostic wax-up.

Fig. 18 _Facial view of diagnostic wax-up with silicone index *in situ*.

Fig. 19 _Facial view of diagnostic wax-up and palatal aspect of silicone index, showing the palatal anatomy with incisal ledge to support the intra-oral composite build-up.

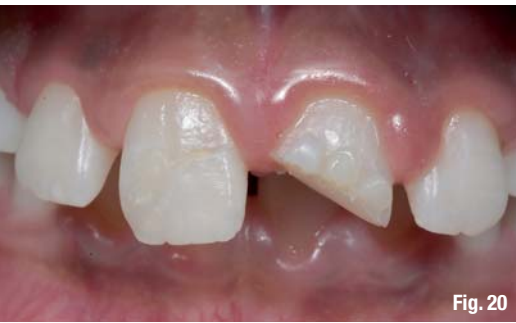

Fig. 20

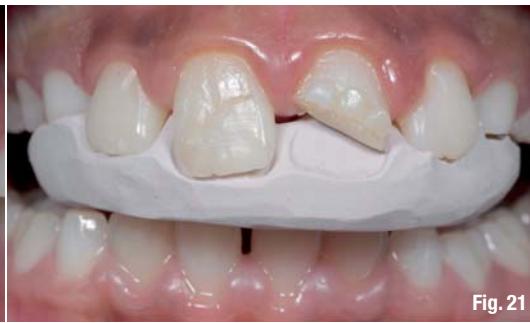

Fig. 21

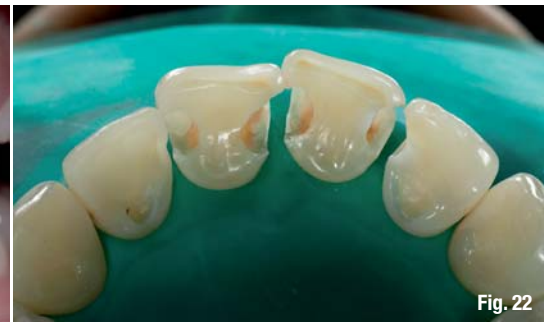


Fig. 22

incremental layering or stratification placement. The latter techniques are commonly utilised to reduce polymerisation stresses by lowering the C-factor and for emulating the shade nuances and characterisations within natural teeth, for example incisal halos, mamelons and translucencies.

Clinical technique

After two weeks, the symptoms associated with the left central incisor had subsided (that is, sensitivity and buccal tenderness), and no response was elicited with gentle percussion.

In addition to the preoperative colour analysis with shade tabs carried out earlier, small beads of Herculite XRV Ultra shades Incisal, Enamel A1, and Dentine A2 were directly placed on the tooth and light-cured to ensure a precise shade match (Fig. 20). This method allows a direct comparison of set composite on the natural tooth substrate and is an excellent method for selecting the correct enamel and dentine shades of composite. Next, the silicone index was placed against the teeth to confirm correct location and exact seating (Fig. 21).

Isolation is essential for composite resin fillings to accomplish a moisture-free environment. Various methods are available, including gingival retraction cords, cotton wool rolls, aspiration and a rubber dam. Several techniques are advocated for rubber dam use, including complete isolation of individual teeth (Fig. 22) and the split-dam technique for isolating a

number of teeth (Fig. 23). However, when building-up anterior teeth, for which aesthetics is of paramount concern, using a rubber dam can be disadvantageous owing to excessive dehydration of teeth, making accurate shade assessment challenging. Therefore, for this patient, a dry retraction cord was carefully eased into the gingival sulcus to absorb the crevicular fluid, together with cotton wool rolls in the sulci and continuous aspiration to maintain a dry field. This protocol prevented desiccation of the teeth, allowing a precise shade assessment during the layering placement of the composite build-up.

After composite shade selection, silicone index verification and tooth isolation, the tooth was prepared for resin build-up. The reattached fragment on the right central incisor was left untouched and served as a guide to mimic shape, colour and characterisations of the build-up on the left central incisor (Fig. 20). Several designs are suggested for preparing the tooth substrate, including no preparation, simple chamfer or the stair-step chamfer. In this instance, a simple 1 mm chamfer was created on the buccal and lingual surfaces using a tapered round-ended diamond bur (Fig. 24). The prepared tooth was etched with phosphoric acid and dried (not desiccated), and OptiBond Solo Plus was applied according to the manufacturer's instructions (Figs. 25 & 26). The stages for the layered composite build-up are as follows:

Step 1: Using the CompoRoller (KerrHawe SA), a thin layer (1 to 1.5 mm) of Herculite XRV Ultra

Fig. 20 Beads of different shades of Herculite XRV Ultra (Kerr) placed and set directly onto the left central incisor (from left: Incisal, Enamel A1, Dentine A2 shades).

Fig. 21 Silicone index placed onto placed surfaces of incisors to ensure correct seating.

Fig. 22 Complete isolation of each tooth with a rubber dam.

Fig. 23 Split-dam technique used to isolate the anterior maxillary sextant.

Fig. 24 A 1 mm chamfer being prepared around the circumference edge of the fracture. Notice the visible gingival retraction cord on the mesial aspect.

Fig. 25 Enchant is applied for 20 seconds using the total etch technique.

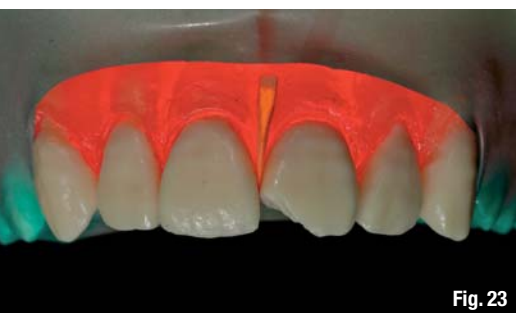

Fig. 23

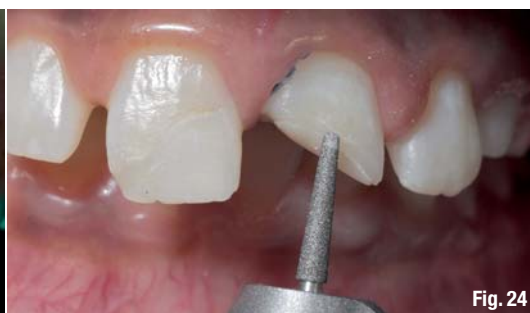

Fig. 24

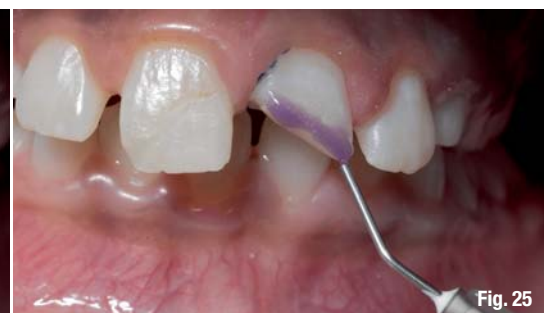

Fig. 25

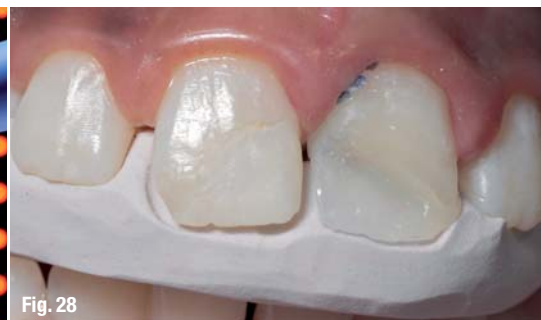
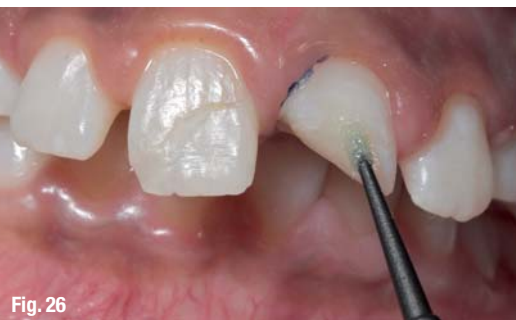

Fig. 26 Dentine bonding agent is applied on all surfaces and light-cured.

Figs. 27 & 28 The CompoRoller (KerrHawe) is used to form a thin layer (1 to 1.5 mm thick) of incisal shade to place into the silicone index, which is used as a template to guide placement of the palatal incisal layer and ensure the correct length of the tooth.

Incisal shade was rolled out (Fig. 27) and placed into index to build-up the palatal aspect and incisal edge, and subsequently light-cured with the index *in situ* (Fig. 28).

Step 2: The index was removed and the palatal incisal layer inspected to ensure that it was not too thick and that sufficient space was available for the remaining layers (Fig. 29), and subsequently light-cured from the palatal aspect.

Step 3: A thin layer of Herculite XRV Ultra Dentine A1 was placed at the incisal edge, mesial and distal aspects to re-create the incisal halo effect (Fig. 30).

Step 4: Using a suitably shaped instrument, Dentine A2 shade was used to copy the mamelon effect of the reattached fragment on the right central incisor (Fig. 31).

Step 5: CompoRoller tips of various shapes, for example conical and cylindrical, were used to sculpt the Enamel A1 covering layer (Figs. 32–34).

Step 6: The reconstruction was completed with a thin covering layer (0.5 mm) of Incisal shade at the incisal third of the build-up (Fig. 35).

Fig. 29 Silicone index removed, showing the initial build-up layer.

Fig. 30 A thin layer of dentine shade is placed at the mesial, incisal and distal edges to simulate an incisal halo.

Fig. 31 A rounded conical-shaped hand instrument is used to create dentine mamelons.

The final contouring and finishing were postponed for one week. This allows re-evaluation of the shade and characterisations by both the patient and clinician. Necessary changes were performed before proceeding with the finishing and polishing. Composite layering is a lengthy and painstaking process, requiring meticulous attention by the operator and protracted endurance by the patient. Both these factors contribute to tiredness and loss of concentration, and finishing and polishing after

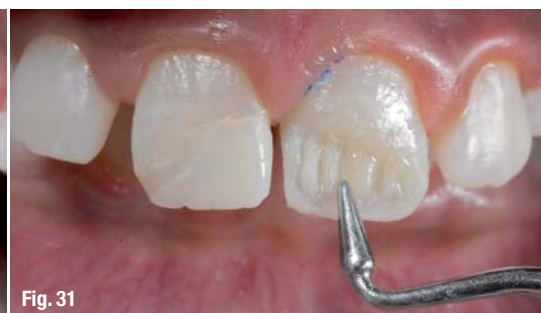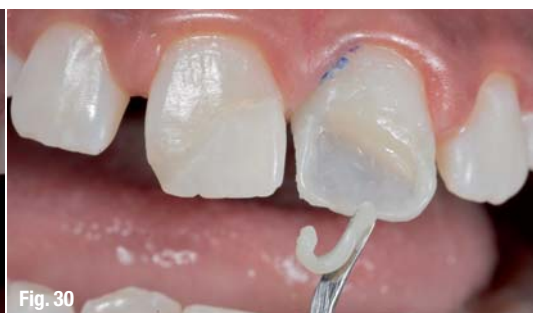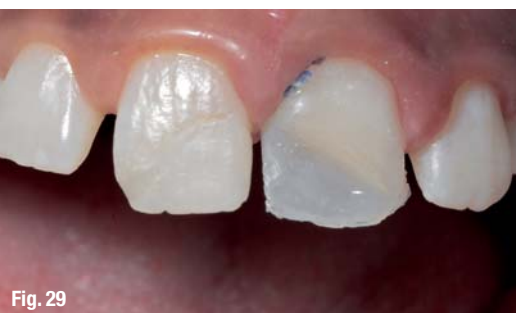a long treatment session is inadvisable. The shade and characterisation of the build-up a week later was satisfactory, ready for adjusting morphology and finalising surface texture (Figs. 36 & 37).

Reattachment of fractured tooth segment

The reattachment of fractured segments is a conservative approach to restoring health, function and aesthetics. It is particularly advantageous for aesthetic appearance, since the natural tooth fragment is used to restore the original morphology and colour. However, if the remaining tooth substrate has discoloured owing to breakdown of the pulpal blood vessels, there may be a colour transition between the tooth and the reattached fragment. Depending on the amount of remaining tooth, this is usually not a concern, since the cervical aspects of teeth are darker than the incisal aspects.

Clinical technique

The procedure for reattaching a fragment is similar to a free-hand composite build-up but with the following differences. Firstly, the colour transition of the sandwiched composite between the remaining tooth and reattached fragment should be seamless. Secondly, to improve the fracture strength of the repaired complex (remaining tooth/composite/fragment), it is advisable to re-hydrate the fragment for at least 30 minutes prior to bonding with the resin composite. The sequence was as follows:



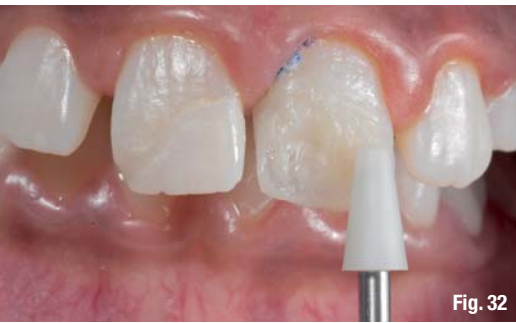

Fig. 32

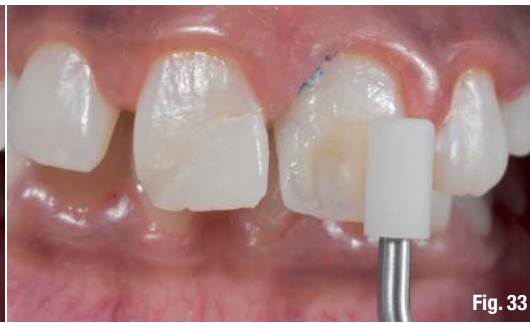

Fig. 33

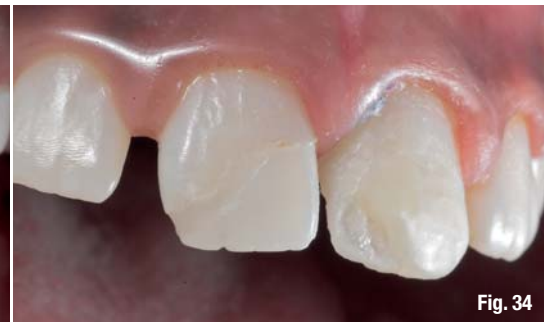

Fig. 34

Step 1: The fractured fragment was carefully removed without damaging the remaining tooth or the fragment (Fig. 38) and hydrated in sterile water for 30 minutes.

Step 2: The silicone index was placed onto the teeth and aided the correct location of the dislodged fragment (Fig. 39).

Step 3: The retraction cord was placed around the right central incisor, and both the remaining tooth and fragment were etched and coated with OptiBond Solo Plus. A thin layer of Herculite XRV Ultra Incisal shade was placed into the index to 'link' the tooth and fragment and subsequently light-cured. The index was removed, and the position of the fragment verified from both facial and palatal aspects (Figs. 40 & 41).

Step 4: The chasm between the tooth and fragment was filled with a combination of Dentine A2 and Enamel A2 shades to create an unnoticeable colour transition (Figs. 42 & 43).

Finishing and polishing

The final stage of a composite filling is finishing and polishing, which ensures longevity and superior aesthetics. The finishing procedure, which ensures a high gloss and smooth surface roughness (Ra), is important not only to prevent surface discolouration, but also to ensure oral health by reducing plaque accumulation and gingival irritation. Furthermore, polishing is also beneficial for achieving good marginal adaptation, reduced micro-leakage and for retaining morphology and occlusal contacts owing to improved wear resistance. The type of inorganic

filler, particle size and the degree of loading influence the polishability of a composite. Furthermore, the difference in hardness between the resin matrix and filler content and amount of conversion of the polymer also contribute to the degree of surface roughness.

Other factors affecting the finish are the flexibility and hardness of the finishing materials, force applied, speed and cooling of rotary instruments, and duration of the polishing procedure. However, contemporary light-cured composites with finer particles (for example, nano-filled) and fine grit rotary instruments allow a durable, smooth and high lustre texture to be readily attainable.

Although using cellulose acetate matrices or Mylar strips mitigates the finishing procedures, most free-hand composite build-ups usually require finishing and polishing to remove excess composite and alter morphology and occlusion. In addition, the superficial oxygen inhibition layer requires removal to improve the surface hardness of the composite for resilience and improved aesthetics. But how smooth is smooth? The degree of micromorphology irregularities to which a filling should be finished is debatable. Some authorities suggest that the microscopic surface irregularities should be smaller than the critical bacterial adhesion threshold of $Ra = 0.2 \mu m$, while others state that it should equal the Ra of natural enamel-to-enamel occluding surfaces. Another threshold for smoothness is that in order for a filling surface to appear smooth optically, its Ra value should be less than

Fig. 32_The CompoRoller with a conical tip is used to sculpt the surface anatomy.

Fig. 33_The CompoRoller with a cylindrical tip is used to sculpt the surface anatomy.

Fig. 34_The dentine mamelon effect created by using a dentine shade is clearly visible at the mesial aspect before being covered with an enamel shade overlay.

Fig. 35_The completed reconstruction with a thin overlying incisal shade at the incisal third of the build-up.

Fig. 36_A week later, the colour of the build-up on the left central incisor is acceptable and ready for finishing and polishing.

Fig. 37_Incisal view of the build-up on the left central incisor, one week later. (The cervical gingival margin of the left central incisor shows a trapped cornhusk, which was subsequently removed.)

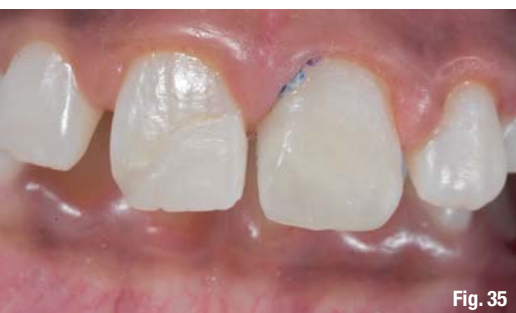

Fig. 35

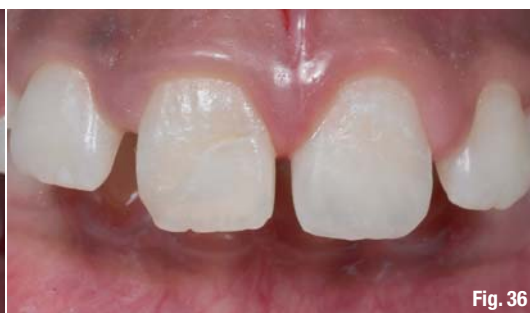

Fig. 36

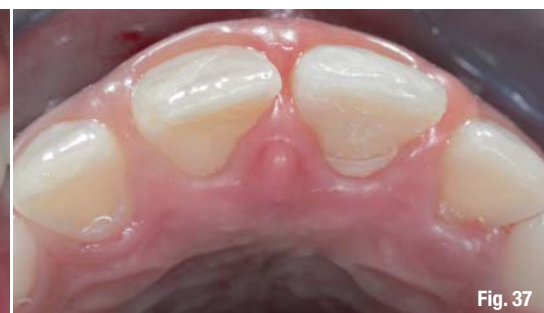

Fig. 37

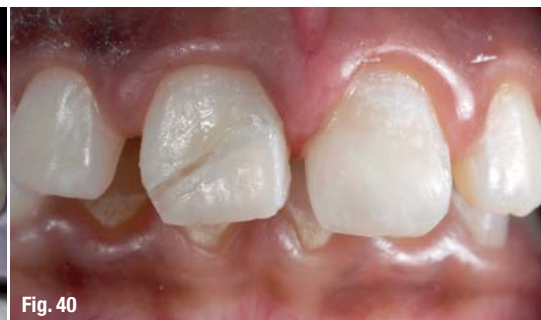
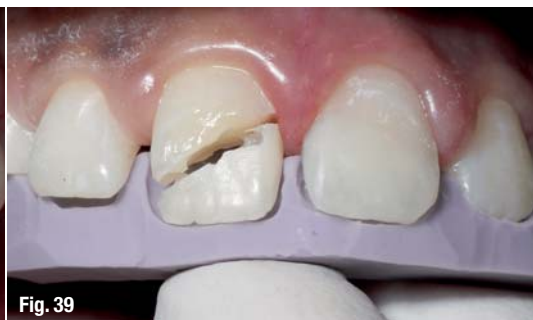
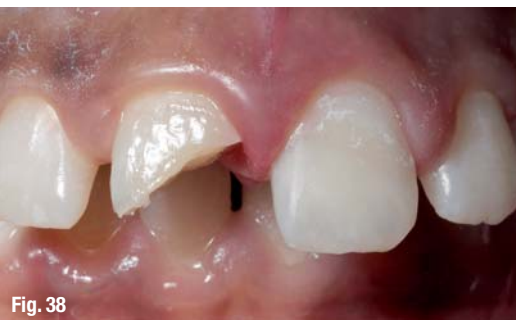Fig. 38

Fig. 39

Fig. 40

Fig. 38 Removal of the fractured segment on the right central incisor.

Fig. 39 After re-hydration, the fragment is correctly located in position with the silicone index.

Fig. 40 Facial view of the fragment secured to the existing tooth with Herculite XRV Ultra Incisal shade.

1 μm , which is similar to natural enamel surface roughness of Ra 0.3 μm to 0.5 μm .

Many methods have been advocated for finishing and polishing composite restorations, including multi-fluted (16 to 30) tungsten carbide burs, fine grit (<25 μm) diamond burs, aluminium oxide (Al_2O_3) coated abrasive discs, silicone and rubber points, felt discs with diamond paste, and unfilled resins to coat the surface layer of the restoration. The type of polishing system depends on the type of composite, the degree of contouring required for aesthetics and occlusion, and the operator's experience and familiarity with a specific finishing system.

Generally, micro-filled and nano-filled composites can be polished to a very high gross finish compared to hybrid and condensable varieties. If the contours of the restoration require extensive alteration, a diamond bur is preferable (rather than a fluted carbide) followed by silicone tips, discs and polishing pastes. Conversely, if the morphology and surface topography require little modification, the ideal starting point is with fluted carbide burs, followed by silicone tips, discs and polishing pastes. Also, condensable composites may require more abrasive instruments compared to micro-filled or nano-filled composites.

Clinical technique

The polishing system used for this case study was the Hawe Composite Surface Treatment Kit

(KerrHawe SA) consisting of OptiDisc, Al_2O_3 -coated inter-proximal strips (Fig. 44), fluted finishing burs, HiLuster tips, and brushes for diamond polishing paste. The sequence was as follows:

- _Step 1: All rotary instruments were copiously irrigated with water at a speed not exceeding 50,000 min^{-1} and gingival retraction cord was placed around the teeth to prevent laceration of the soft tissues. Excess composite was removed and the anatomy refined with OptiDisc, starting with the black centre super coarse disc and ending with the blue centre coarse/medium disc. The discs were also used to create the incisal lobes of the build-up on the left central incisor, guided by the incisal lobes of the reattached fragment on the right central incisor.
- _Step 2: The facial and palatal topography (undulations) was formed with the fluted finishing burs and polished with the HiLuster tips.
- _Step 3: Inter-proximal composite excess and overhangs were smoothed with Al_2O_3 -coated inter-proximal strips of varying coarseness.
- _Step 4: The restoration was polished with diamond paste for a high gloss and lustre.

The finished and polished restoration demonstrates correct anatomical form; seamless colour transition between the composite build-up/reattached fragment and the remaining tooth structure; incisal lobes on the left central incisor, mimicking those of the incisal edge of the right central incisor; and correct lustre and texture (Fig. 45). The patient was supplied with

Fig. 41 Incisal view of the fragment secured to the existing tooth with Herculite XRV Ultra Incisal shade.

Fig. 42 Facial view of reattached fragment with remaining tooth substrate. Observe the seamless colour transition.

Fig. 43 Incisal view of reattached fragment with remaining tooth substrate. Observe that the cornhusk at the cervical gingival margin of the left central incisor has been removed (compare with Fig. 37).

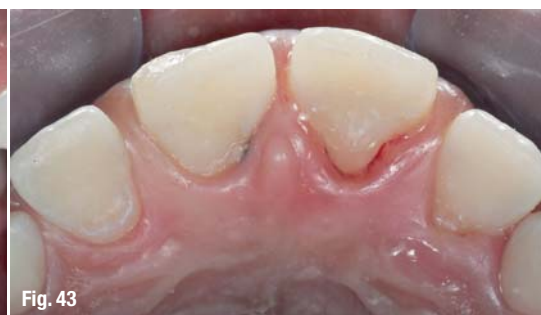
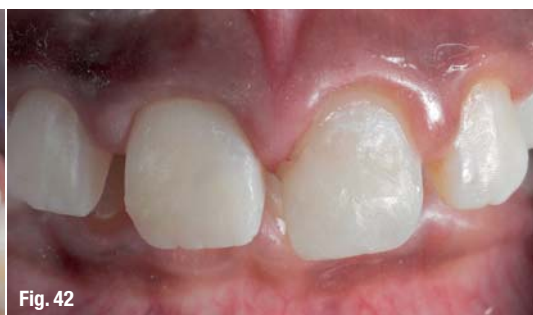
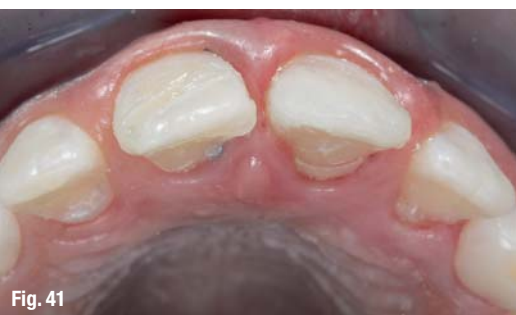Fig. 41

Fig. 42

Fig. 43



Fig. 44

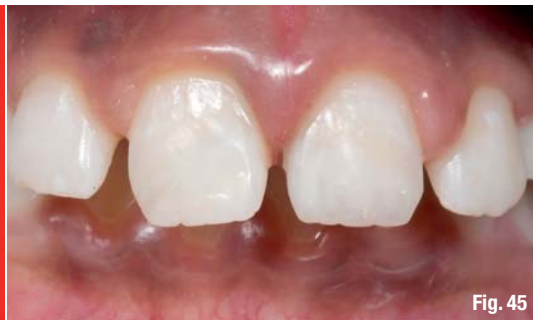

Fig. 45

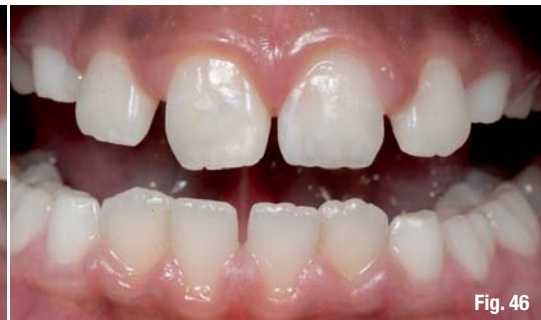

Fig. 46

a mouth guard and advised to attend for periodic review appointments, or earlier, if endodontic symptoms developed. In addition, oral-hygiene procedures were re-enforced.

_Post-operative results

Figures 46 to 48 demonstrate the post-operative results at two weeks. Observe the impeccable gingival health; correct anatomical form of the composite build-up on the left central incisor; a seamless transition between the composite and natural tooth substrate; dentine mamelons in the coronal build-up on the left central incisor and an incisal halo, opalescence, incisal edge translucency within the build-up on the left central incisor, mimicking the reattached natural tooth fragment on the right central incisor.

It is important to note that the composite build-up on the left central incisor is similar but not identical to the right central incisor. It is clinically difficult to produce a facsimile by direct free-hand composite build-up, and it is unusual to find identical teeth in any one individual dentition, and slavishly copying an existing tooth appears contrived and artificial, which is rarely observed in nature. Nature is creative, rather than perfect. Finally, any artificial prostheses or restoration should broadly conform to the existing dentition by blending with the surrounding teeth.

The full-face images show restitution of dental aesthetics that are in harmony with the surrounding lips (Figs. 49 & 50).

_Conclusion

Acute dental trauma is distressing for the patient and challenging for the clinician. Following initial emergency treatment to alleviate pain and sepsis, the goal is salvaging as much natural tooth as possible. The restoration of health, function and aesthetics is achievable with direct composite restorations and is less destructive

than many indirect approaches that remove additional tooth substrate, which further compromises the damaged tooth. The free-hand build-up, guided by a silicone index, is conservative and minimally invasive, but requires

Fig. 44_OptiDiscs of varying coarseness with an inter-proximal strip.
Fig. 45_The finished and polished restorations, showing correct anatomy and surface texture,

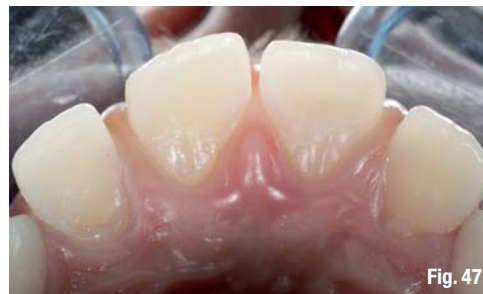

Fig. 47

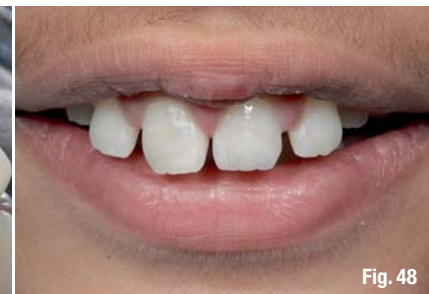

Fig. 48



Fig. 49



Fig. 50

a degree of patience and expertise of the operator, and endurance of lengthy appointments by the patient. Salvaged and usable fragments of fractured teeth are ideal for reconstructing teeth to their former morphology and aesthetics._

as well as seamless transition between the remaining tooth and composite fillings.

Fig. 46_Post-op facial view (compare with Figs. 2 & 5).
Fig. 47_Post-op incisal view (compare with Figs. 3 & 7).
Fig. 48_Post-op dento-facial view (compare with Fig. 1).
Fig. 49_Pre-op full-face view.
Fig. 50_Post-op full-face view.

_contact

cosmetic
dentistry

Dr Irfan Ahmad

The Ridgeway Dental Surgery
173 The Ridgeway
North Harrow
Middlesex, HA2 7DF
UK

iahmadbds@aol.com
www.irfanahmadtrds.co.uk

Laser-assisted cosmetic dentistry—A case report

Author _ Dr Hugh Flax, USA



Fig. 1 _ Visualising the entire oral-facial composition helps to diagnose less harmonious features of the smile.

Fig. 2 _ Close-up photography is essential to planning periodontal-restorative care.

Fig. 3 _ A mounted diagnostic wax-up is a critical guide for planning a realistic result.

Fig. 4 _ Outlining the desired gingival margins prior to anaesthesia communicates a blueprint to the patient and restorative team.

As aesthetics are absolutely critical to a patient's external appearance and inner emotions, orchestrating a bio-aesthetic result is mandatory. Too often, this is complicated when aesthetic desires infringe on the health of the periodontal complex. This is often true when biologic width violations have occurred iatrogenically.

Many factors may contribute to these failures; the two main culprits are intra-crevicular margin location and over-contoured restorations. Not only is plaque accumulation problematic, but the supra-crestal fibres also become interrupted, causing the tissues to become further inflamed and aesthetically unmanageable. Kois' landmark study defined the total dento-gingival complex (DGC) as clinically predictable at 3 mm on the direct facial aspect and at 3 to 5 mm inter-proximally when measured from the free gingival margin to the osseous crest.

It is critical anteriorly that the gingival margin mimics the osseous scallop while maintaining the DGC.¹ Further complicating these complex situations is the degree of inflammation in the soft tissue, affecting the clinical development of health and aesthetic symmetry.

An ideal result

Often, the patient is frustrated with his/her previous poor cosmetic results. However, to improve the periodontal framework in order to create an ideal result, they must be referred to yet another doctor. Even more challenging is the extended

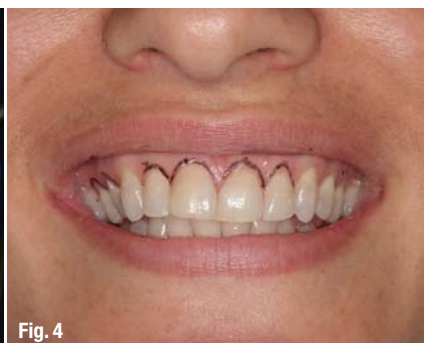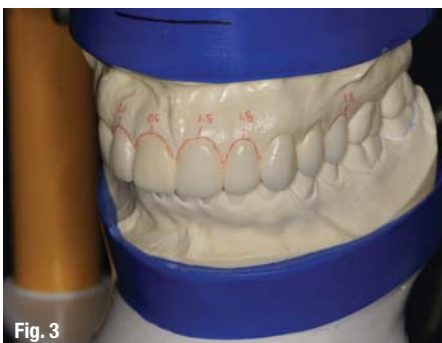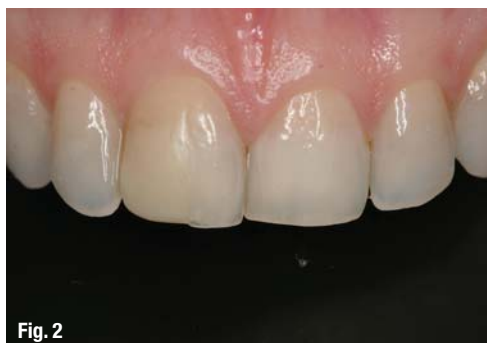healing time created by reflective mucoperiosteal surgery. This not only affects the chronology of final restorative care, but also delays the patient's ultimate satisfaction and happiness for a minimum of two to three months.

Fortunately, dental lasers have evolved considerably as an adjunctive and alternative treatment to safely, conservatively and reliably decrease bacterial levels and improve the hard and soft-tissue contours. Studies of Er:YSGG lasers by Rizoio and others have shown that thermal coagulative results and bony ablation characteristics are similar to those resulting from use of a dental bur.² From a patient-friendly standpoint, less need for suturing and shorter healing times improve case acceptance for doing ideal dentistry. In selected cases, such as the one presented in this article, minimally invasive laser procedures, with precise restorative planning and technique, can satisfy aesthetic and functional parameters. Furthermore, patients can enjoy optimal results more comfortably and within a shorter time.

For this case, a conservative strategy was devised that would allow us to correct the problems and causes by completing multiple task simultaneously.

Case presentation

A 38-year-old female patient presented for correction of what she termed her "tilted smile" (Fig. 1). Given that she was starting a new sales career, she also wanted to make her teeth brighter and her smile much broader. The patient shared her frustration



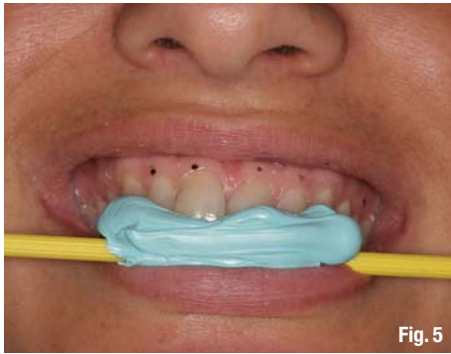

Fig. 5

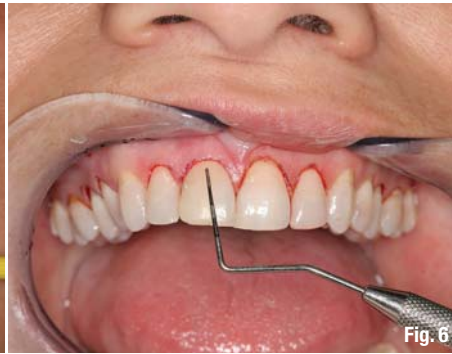

Fig. 6

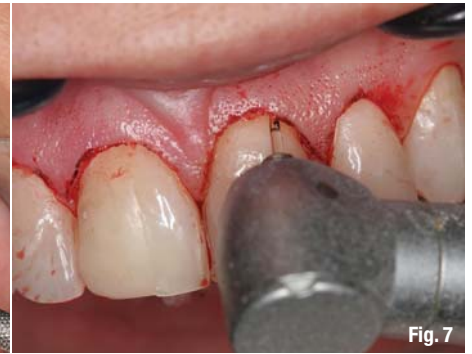

Fig. 7

about previous dental consultations that had focused solely on orthodontic or surgical solutions without considering a more practical approach that would suit her busy lifestyle.

Her smile analysis established a collapse of the bicuspid in the buccal corridor. Furthermore, the axial inclinations, irregular gingival margins and incisal edges created a downward tilt to the patient's right owing to tooth positioning. Close-up imaging demonstrated healthy gingival tissues, as well as a right central incisor weakened by a large composite (Fig. 2).

Findings

A full clinical examination with radiographs and mounted models revealed the following:

- biomechanically, the majority of her teeth remained strong despite previous dental care;
- periodontally, soft and hard tissues were healthy;
- occlusally, load testing was normal (after muscle relaxation) and there was obvious CR-CO anterior-vertical slide due to premature contact at tooth #30;
- aesthetically, the width-to-length ratio of the upper centrals was 1:2, far from the ideal range of 0.75:1.0, and tooth shade was VITA A2.

Treatment plan

Given the patient's previous history and her desire for minimally invasive dental care, a conser-

vative strategy was devised that would allow us to correct the problems and causes by conducting multiple tasks simultaneously:

- muscle and bite therapy with a Tanner appliance, followed by careful equilibration aided by the T-scan (Tekscan System);
- 3-D wax-up on a Stratos articulator (Ivoclar Vivadent; Fig. 3);
- home bleaching of the lower teeth with Opalescence 15% (Ultradent);
- 'closed flap' periodontal modification with the Waterlase Er,Cr:YSGG (Biolase), while the first three items were being accomplished (the combination of these four steps was a tremendous time saver and allowed us to monitor progress carefully on a weekly basis); and
- definitive restorative care with porcelain veneers and a crown on tooth #8.

Treatment

For the initial closed periodontal lift, the Er,Cr:YSGG laser was used in three modes (gingival sculpting, osseous recontouring, and bio-stimulation). Prior to anaesthesia, the desired framework was planned and outlined using a fine marker (Fig. 4). Furthermore, a stick-bite was used, not only to establish an ideal incisal plane, but also to align the gingival margins properly (Fig. 5).

With the settings at 2.0 W, 20 pulses per second, 20% air and 20% water, a G-6 tip (600 µm in diameter) was used to shape the labial gingival

Fig. 5 A stick-bite helps to verify that incisal and gingival planes will be parallel.

Fig. 6 The tissues are treated atraumatically with the Waterlase.

Fig. 7 Using the black mark as a reference following the gingival scallop, a very tight up-and-down movement is performed to modify the bone.

Fig. 8 A curette helps clean and smooth the sulcus of any debris.

Fig. 9 A 'laser bandage' is placed along the treated area to improve the healing time and decrease the patient's discomfort. Note the immediate improvement of the geometric progression of gingival embrasures.

Fig. 10 Detailed information helps the laboratory to translate clinical results to the porcelain restorations.

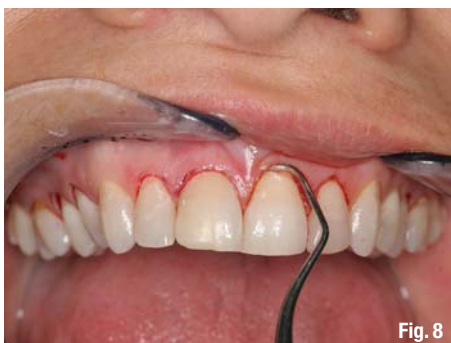

Fig. 8

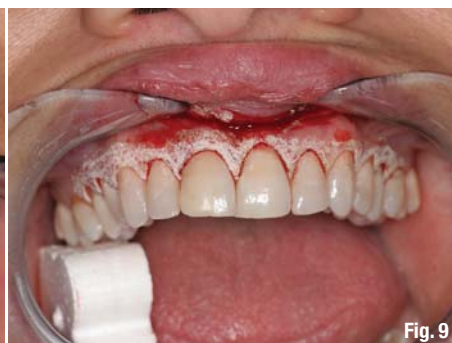

Fig. 9

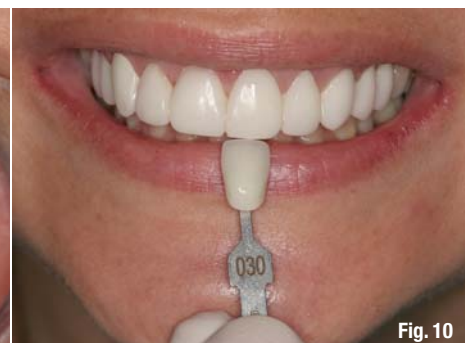

Fig. 10



Fig. 11

Fig. 11 _The great improvement in aesthetics boosted the patient's self-confidence and pride in her dental hygiene.

Fig. 12 _Ideal proportions and emergence profiles will create long-term healthy tissues and bio-aesthetics.

region. No tissue necrosis or significant bleeding occurred as a result of using the laser's relatively lower settings. All areas were 'sounded' using a periodontal probe (Fig. 6).

At the facial margins, osseous sculpting required great precision in order to maintain a 3 mm DGC. A specially tapered T-4 tip (400 µm in diameter) was used at a 25 % higher wattage of 2.5 W. Prior to usage, the tip was measured and marked to 3 mm in order to maintain controlled adjustments within the gingival sulcus during periodontal probing movement of the tip (Fig. 7). The resection was smoothed with a 7/8 curette (Fig. 8). Using low-level laser therapy at a setting of 0.25 W, a decrease in the release of inflammatory histamine and increased fibroblasts for junctional epithelial growth was achieved by 'frosting' the outer epithelium and injection sites (Fig. 9). The patient was placed on a vigorous home-care regimen (Oxygel,

Oxyfresh) and closely monitored for a month, while occlusal therapy and bleaching procedures were performed.

Four weeks after surgery, the tissues had healed and restorative care could be initiated. The patient's teeth were prepared for veneers and a crown with mild soft-tissue reshaping in order to make adjustments to our previous treatment. After taking impressions and bite registrations, prototype provisionals (Luxatemp Plus, Zenith DMG) were fabricated using the 'shrink-wrap' technique. The patient was sent home with the same home-care regimen as mentioned previously and instructed to 'test-drive' her new smile for aesthetics and function. She returned in a week for the prototype's occlusion, colour and morphology to be perfected. Photographs and models were sent to the laboratory, providing a final blueprint for the porcelain restorations (Fig. 10).

_Satisfied patient

Four weeks later, the provisionals and cement were carefully removed from the teeth. All restorations were tried in individually and as a group to verify fit and aesthetics. After the patient's enthusiastic approval, the porcelain was bonded using the two-by-two technique and isolation. Margins were smoothed and polished and occlusion balanced with the T-scan. A protective night-time appliance was created to bring longevity to the rehabilitation. Our very satisfied patient said that we had exceeded her expectations (Figs. 11 & 12).

A hard- or soft-tissue laser is a wonderful adjunctive tool for cosmetic and restorative dentistry. The case discussed here demonstrates that this type of laser technology gives dentists the ability to make significant hard- and soft-tissue changes while being minimally invasive. These changes not only improve the final aesthetic outcome of the case, but also provide the physiological functional parameters required for successful dentistry.

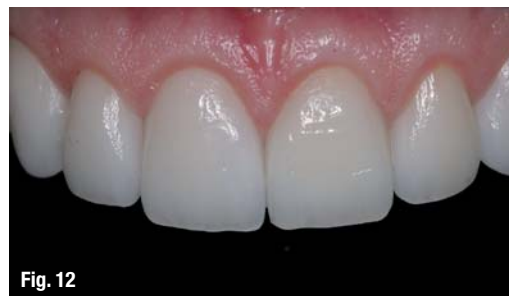

Fig. 12


_Acknowledgments

I would like to thank my office team and laboratory technician, Mr Wayne Payne (Payne Dental Lab), for continually enhancing the lives of many patients such as the one presented here. I am also thankful to my family, who allow me to contribute to the education of other dentists and their teams.

Editorial note: This article is reprinted with permission from the Journal of Cosmetic Dentistry, ©2010 American Academy of Cosmetic Dentistry (Tel.: +1 608 222 8583; Fax: +1 608 222 9540; www.aacd.com). All rights reserved.

A list of references is available from the publisher.

_about the author
cosmetic
dentistry



Dr Hugh Flax has been an Accredited Member of the American Academy of Cosmetic Dentistry (AACD) since 1997. He served as Co-chair of the AACD's Conference Advisory Committee for the 2003 and 2008 Annual Scientific Sessions. He served on the AACD Board of Directors, serves on the editorial board of the *Journal of Cosmetic Dentistry* and chair the AACD's Disaster Relief Fund in 2005 and 2006. Dr Flax is also a member of the American Dental Association, Academy of General Dentistry, Academy of Laser Dentistry, L.D. Pankey Alumni Association and Pierre Fauchard Academy. He is a Fellow of the International Academy for Dental Facial Esthetics. Dr Flax practises full time in Atlanta, USA, focusing on functional and aesthetic conditions and advanced laser dentistry.


kuraray

Master of the molecules

We research and develop for your success!



The MDP Monomer



MDP – the secret of PANAVIA™, CLEARFIL™ SA CEMENT and many other Kuraray products.

The patented adhesive monomer MDP stands for Kuraray's technological strength and innovation. After the phenomenal success of PANAVIA™, MDP also gives other products such as the bonding system CLEARFIL™ SE Bond or the self-adhesive resin cement CLEARFIL™ SA CEMENT its excellent adhesive properties.

**Experience the world of Kuraray at the IDS 2011
Hall 11.3 / Stand D 010**

For over 85 years now, the Japanese company Kuraray has been using its extensive experience and technologies to develop innovative and sophisticated solutions at the highest technical level for the world market – and for the past 38 years it has been equally successful in the area of dental materials.

Integration of **aesthetics** and **function** with composite resins

Authors_ Dr Rony Hidalgo Lostaunau & Rafael Barrantes Alarcon, Peru

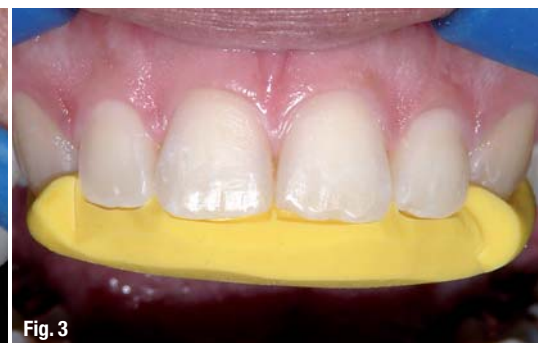
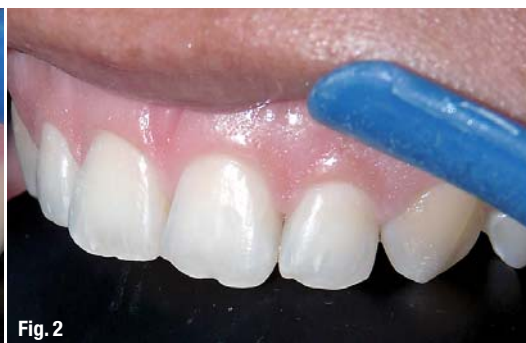
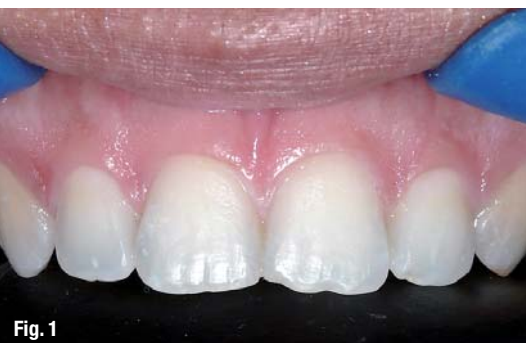Fig. 1

Fig. 2

Fig. 3

Careful integration of the different dental specialties is the basis of modern dentistry, especially when the treatment goal is an aesthetic and functional oral rehabilitation of the patient.^{1,2} Today, aesthetic oral rehabilitation integrates three basic concepts—bio-compatibility, mechanics and, of course, beauty—in order to preserve the anatomical structures of the stomatognathic system and to fulfil functional purposes. At the same time, utmost attention is paid to achieving aesthetic goals in accordance with the current trends in aesthetic dentistry and thus fulfilling the patients' expectations.³

With comprehensive oral rehabilitation as our main goal, utilisation of the different areas in dentistry becomes extremely important in order to establish a precise diagnosis, treatment plan and finally treatment. Orthodontics, for example, has clearly defined objectives, such as the establishment of a functional occlusion, the preservation of periodontal health and the achievement of a stable result within the boundaries given by physiology and dentofacial harmony.^{4,5} When the case is pre-

sented to the patient prior to any intervention, individual limitations of that particular case must be considered in order to avoid unreal expectations. The patient needs to have a clear idea of the treatment plan, realistic expectations with regard to the final result, and previous and posterior dental needs. Therefore, meticulous examination and good communication with the patient are of utmost importance.^{4,5}

There are a number of different cases in which the combination of orthodontics and restorative dentistry is advisable, such as Bolton's and vertical discrepancies, peg-shaped teeth, discrepancies in height and width, diastemas, agenesis, malformations, extrusions, intrusions, attrition, etc.⁶⁻⁸ Not solving the problems mentioned above might result in failure of the orthodontic therapy due to relapse, periodontal complications, occlusal instability or overall dissatisfaction.^{9,10} However, the careful planning and combination of aesthetics and orthodontic functionality in combination with the new restorative materials available today enable us to obtain harmonic results.^{2,11}

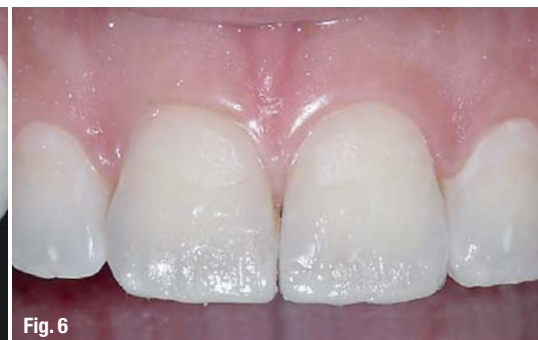
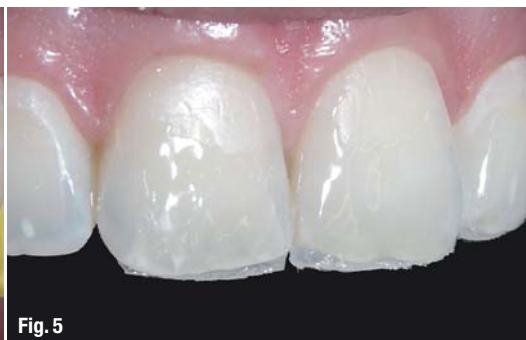
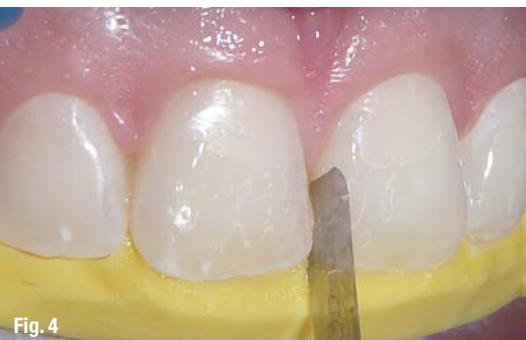Fig. 4

Fig. 5

Fig. 6

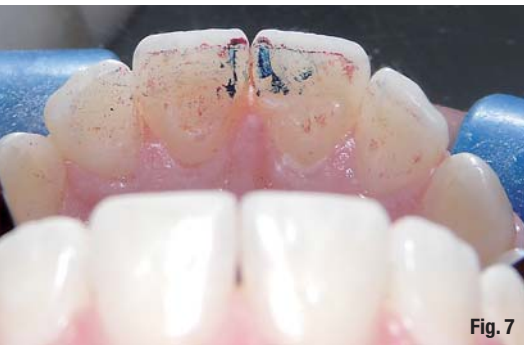

Fig. 7

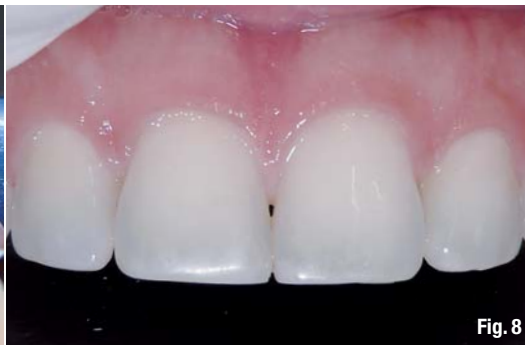

Fig. 8

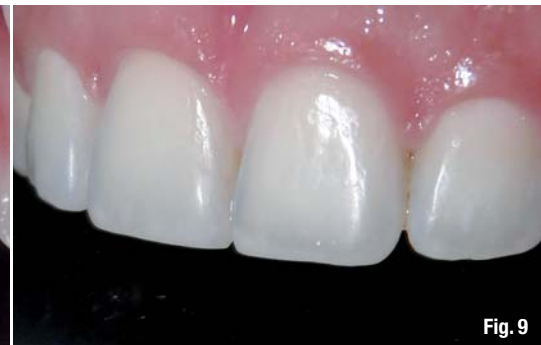

Fig. 9

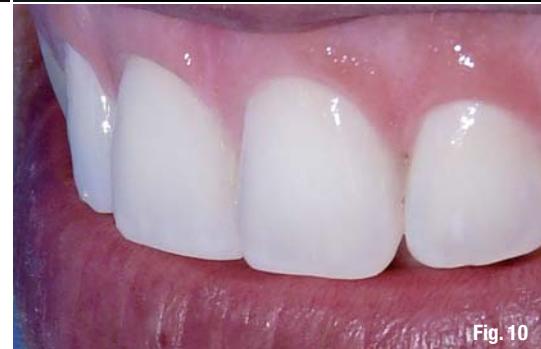

Fig. 10

This article seeks to demonstrate the manner in which the goals of an orthodontic treatment were fulfilled in a clinical case. A multidisciplinary approach is indispensable for the achievement of the therapeutic goals of functionality and aesthetics, which are obtained thanks to modern direct restorative dentistry as part of a comprehensive treatment plan and followed by an aesthetic and functional execution of that plan.

Case report

The patient was unhappy with her dental aesthetics after completion of fixed orthodontic treatment. In addition, she did not like the appearance of her incisal edges, nor the texture or translucency of the incisal third of her central incisors (Figs. 1 & 2).

After gaining a clear understanding of the patient's expectations and having informed her of the therapeutic possibility of treating the case with composite resin, it was decided to make a diagnostic wax-up, elongating the height of the clinical crowns to correct the irregularities of the incisal edges. We then proceeded to take a pattern of the future restorations with putty polyvinyl siloxane (PVS). This pattern was then tried in to gain a better idea of the quantity of composite needed to restore the teeth (Fig. 3).

Following adequate cotton roll isolation, and after gaining complete cooperation from the patient, the adhesive protocol for the enamel was followed and restoration with composite resin AMARIS (VOCO) was decided upon. The first increment of restorative material was placed in the PVS pattern and seated with gentle pressure on the palatal aspect of the pattern. AMARIS Translucent was placed in such a way that all the palatal surfaces of the restoration were completed on teeth #11, 21 and 22. In order to restore the central incisors simultaneously, a partially thinned matrix (OptraMatrix, Ivoclar Vivadent) was lodged in the PVS pattern and each incisal edge was light-cured for 30 seconds (Figs. 4–6).

The pattern that rapidly gave us all the anatomic features of the lingual aspect was then removed to

continue stratifying the layers of this composite (AMARIS Opaque), seeking to insinuate the mamelons very slightly at the incisal third but close to the incisal edge itself, and at the same time spreading the composite onto the surface of the enamel, in order to hide the excessive translucent aspect that these teeth showed naturally (Fig. 6). In addition, we applied several brushstrokes of AMARIS Flow High Opaque (VOCO) in areas where it was necessary to hide the translucency, and at the same time it was useful for us to generate small areas of hypoplasia of enamel, resembling the natural characteristics of the lateral incisor.

Finally, the whole surface of the incisal edge and the facial surface were covered with AMARIS Translucent again. Thereafter, the whole restoration was brushed up and light-cured for 60 seconds. Next, the occlusion was adjusted and the composites finished (Figs. 7 & 8).

The patient was very pleased with the final result and was informed of the necessary appointments for follow-ups and maintenance, occlusion check-ups, as well as photographic monitoring. The accompanying photographs were taken three months post-operatively, the first one with dried teeth and the second in natural conditions during smile (Figs. 9 & 10).

Editorial note: A complete list of references is available from the publisher.

contact

cosmetic
dentistry



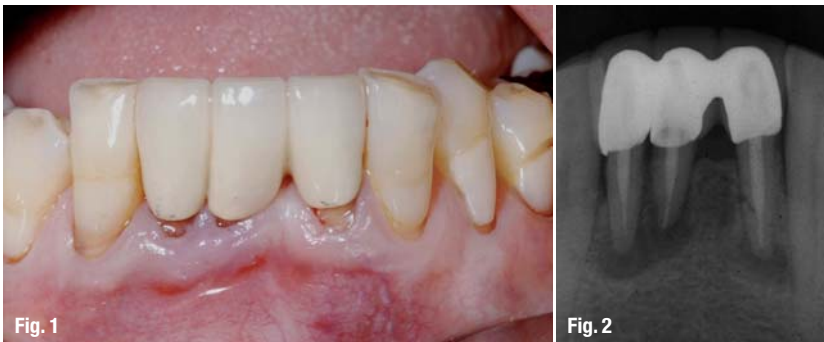Dr Rony Hidalgo Lostaunau

Alameda del Crepúsculo 195
Alborada – Surco
Lima 33
Perú

hidalgo@endoroot.com

Restoring missing mandibular incisors with implants— What makes you hesitate?

Authors_ Dr Chonghwa Kim & Sangwoo Lee, Korea



Preparing mandibular incisors for bridge abutments is an extremely delicate procedure that often leads to root-canal treatment due to pulp damage that might occur during the procedure. Even without the risk of pulp damage, it is still quite a challenge to recreate natural contour and shade on such tiny dentition.

Dental implants have, in many cases, become the treatment of choice for restoring missing teeth and have been documented to have a high degree of success. With implant therapy, the preparation of healthy teeth adjacent to the edentulous area can be avoided. An additional advantage to the implant restoration is the maintenance of the alveolar bone, which otherwise would undergo resorption with other restorative options, hence, often complicating aesthetics.

What's happening in the real world? Are we comfortable enough placing implants in the mandibular anterior region? In spite of understanding both the disadvantages of conventional fixed bridgework and the advantages of implant restorations, we often make the treatment choice for missing mandibular incisors in favour of the bridge. Why is that? What hinders us from providing an implant option for patients in such cases? Restoring mandibular incisors with implants can be one of the most difficult dental

_Mandibular incisors can be vulnerable to early loss due to their inherently weak periodontal support and high prevalence with respect to periodontal disease. What are the most common treatment options for missing mandibular incisors? Aside from removable prosthetic options, the restorative options for a fixed prosthesis include a conventional bridge, a resin-bonded bridge (Maryland Bridge) and implants. For a case in which one or two mandibular central incisors are missing, a three- or four-unit bridge has often been the treatment of choice. A resin-bonded bridge, in these cases, can be a reasonable alternative to a conventional bridge; whereas implant treatment, more often than not, is not suitable due to insufficient space. When more than two incisors are missing, the implant option may become the first choice for most clinicians these days.

Fig. 1_Pre-op.
Fig. 2_Pre-op peri-apical X-ray.

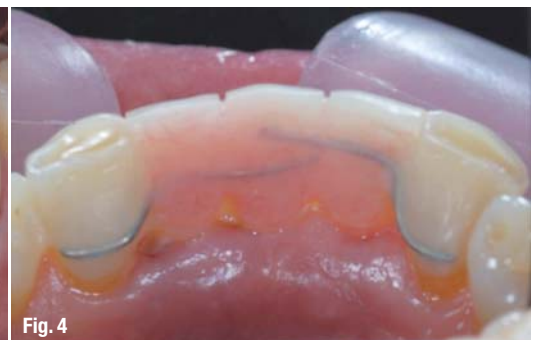
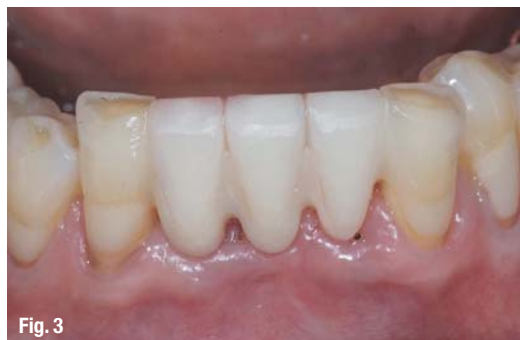
Fig. 3_Resin-bonded provisional restoration.
Fig. 4_Lingual view.

treatments to perform due to the limited amount of bone and interdental space. Placing implants in the mandibular anterior region can be challenging due to:

1. insufficient facio-lingual bone volume;
2. insufficient mesio-distal space between adjacent teeth;
3. insufficient height of remaining alveolar bone;
4. the presence of mento-labial depression, which limits the facio-lingual angulation of implants; and
5. the preservation or recreation of the interdental papilla being an extremely delicate procedure.

One of the prerequisites for the successful placement of an implant is the presence of adequate bone volume. Tarnow *et al.* stated that a submerged implant, following the delivery of the prosthesis, will create circumferential or horizontal bone resorption of 1.3 to 1.4 mm. Grunder *et al.* also stated that at least 2 mm of lateral alveolar bone must be present beyond the body of the implant to compensate for the effects of bone remodelling. If this amount of bone is not present, part or all of the facial or buccal bone plate will be lost after remodelling, with the subsequent risk of soft-tissue recession. This amount of bone around an implant rarely exists in the mandibular anterior region. Therefore, ridge augmentation procedures are often required to create adequate bone volume to maintain a 2 mm alveolar thickness following implant placement.

Another prerequisite for successful implant treatment is sufficient interdental space. The creation of a natural-looking implant restoration largely depends on the appropriate placement of the implant during surgery. In order to achieve this goal, careful planning and precise implant placement are essential. An implant requires a minimum distance of 1.5 mm between the implant and adjacent tooth to maintain interproximal bone and interdental papilla. Standard diameter implants of 4 mm or greater there-

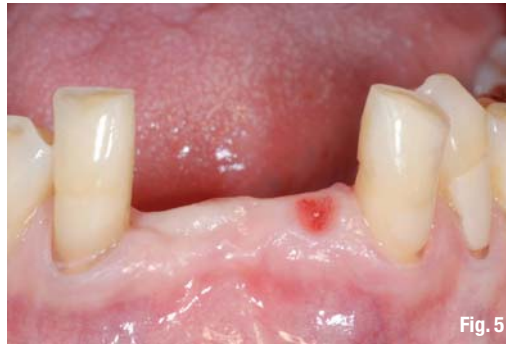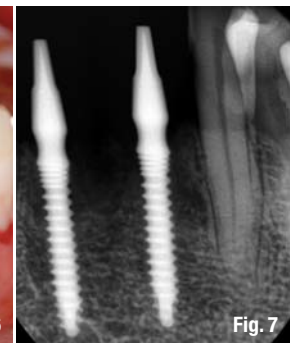

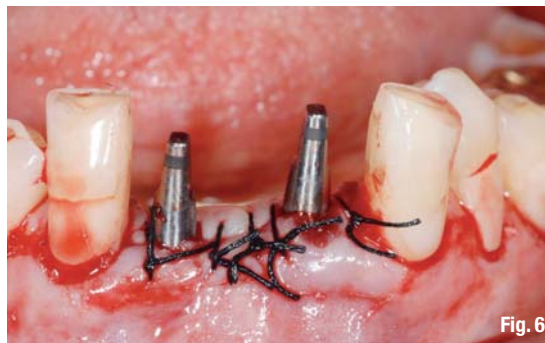
Fig. 5 Twelve weeks post-extraction.

fore require a mesio-distal space of at least 7 mm to place an implant. For an interdental papilla between two adjacent implants to be established, the inter-implant distance should be more than 3 mm. Thus, a minimum mesio-distal space of 14 mm is required to place two standard-diameter implants adjacent to each other.

Implant manufacturers have introduced narrow-diameter implants (3.0 to 3.5 mm) in an attempt to solve these problems. However, these

Fig. 6 Following implant placement.
Fig. 7 Peri-apical X-ray at implant insertion.



implants still require a minimum mesio-distal space of 6.0 to 6.5 mm to allow adequate implant-to-tooth distance. With the exception of mandibular incisors, narrow-diameter implants present a solution for the aforementioned requirements of adequate bucco-lingual bone volume and proper implant spacing. For missing mandibular incisors, it would be beneficial to use implants with an even smaller diameter than narrow-diameter implants.

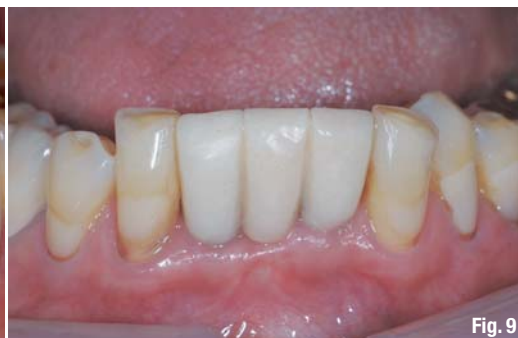
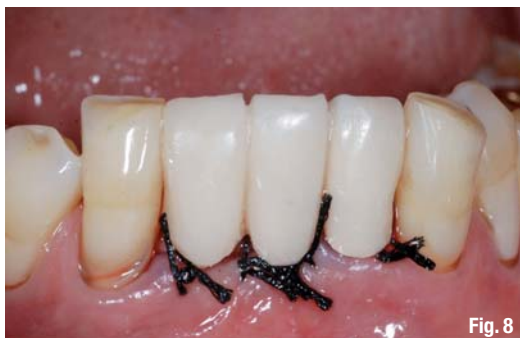
Fig. 8 Immediate provisionalisation.
Fig. 9 Modification of provisional restoration.

Fig. 10_ Eight weeks post-implant placement.

Fig. 11_ Friction-fit impression caps.

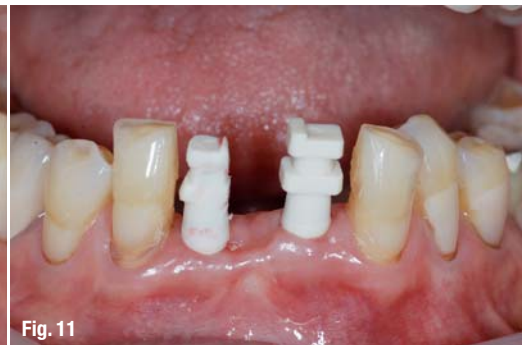
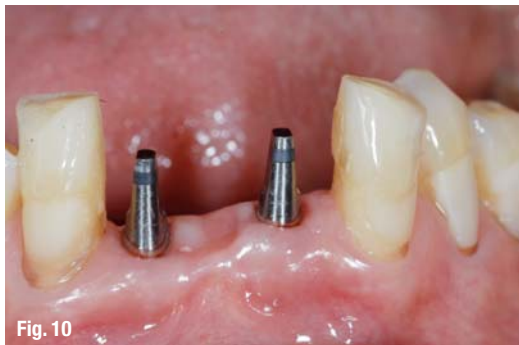
Fig. 10

Fig. 11

Mini-diameter implants (MDI) are not synonymous with narrow-diameter implants. MDIs are smaller in diameter than narrow implants and have a diameter of 2.7 mm or less. Because of their smaller diameters, MDIs require minimal interdental space while preserving more of the alveolar bone following the osteotomies for implant placement. MDIs were initially developed to support transitional prostheses and were ultimately intended to be removed. However, these implants

MDIs of less than 3 mm in diameter are fundamentally challenged as two-piece designs due to the insufficient strength of their component parts. When the diameter of an implant approaches 3 mm or less, either the abutment screw becomes too small or the internal axial walls of the implant become too thin to withstand the functioning load. These concerns can be overcome with a one-piece design. One-piece implants have recently received substantial

Fig. 12_ Working cast.

Fig. 13_ Top view.

Fig. 14_ Final prosthesis.

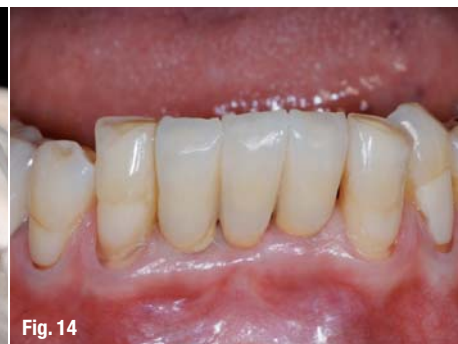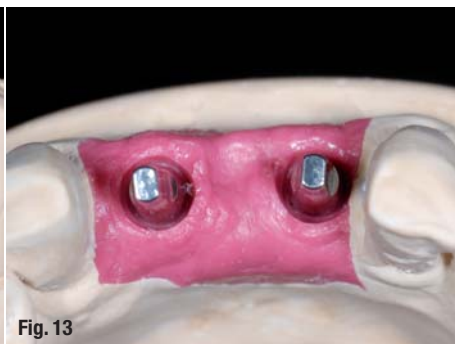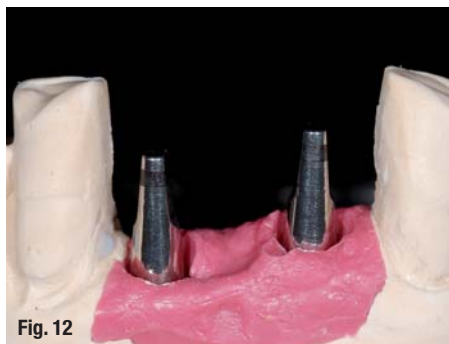


Fig. 12

Fig. 13

Fig. 14

exhibited a bone-to-implant contact similar to that of implants with conventional diameters. Numerous studies have indicated that MDIs appear to be an effective treatment option for missing mandibular incisors. Nevertheless, one of the primary disadvantages of MDIs is the reduced resistance to occlusal loading. The retention of an implant, however, is correlated to the length of the implant and not the diameter. This implies that MDIs may be used in situations where excessive occlusal loading is not present.

attention in implant dentistry; yet, one-piece implants are not new to implant dentistry. While the use of one-piece implants has been controversial, they have been used for decades with reasonable clinical success.

Fig. 15_ Thirteen-month follow-up.

Fig. 16_ Peri-apical X-ray.

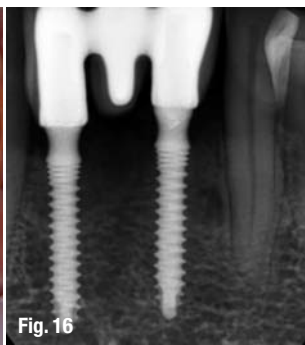
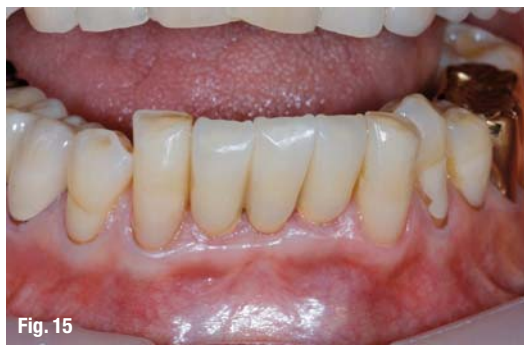
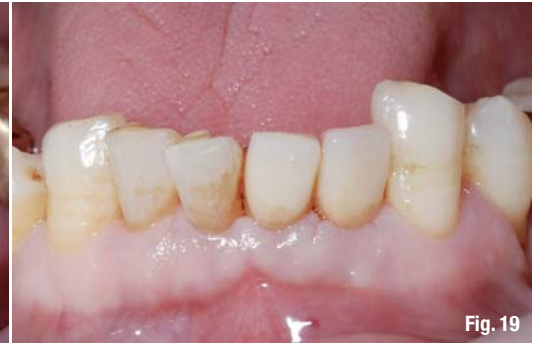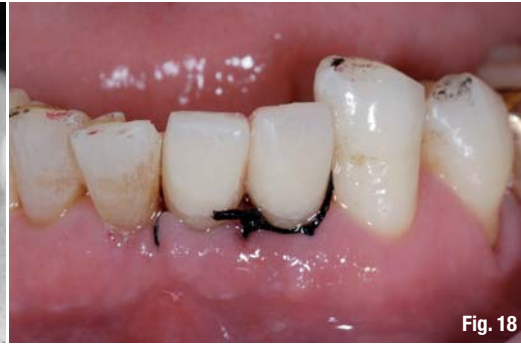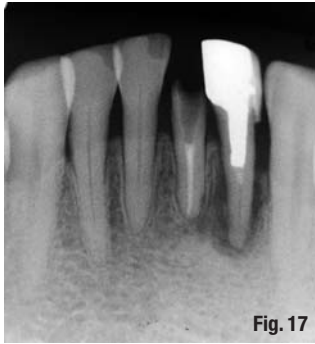Fig. 15

Fig. 16

Recent variations from early designs have created a renewed interest in this old, but not obsolete concept. Most one-piece implants are composed of three portions—the bone-anchoring (fixation thread) portion, transmucosal portion and prosthetic abutment portion.

The primary disadvantage of one-piece implants is related to the fact that these implants must be placed with a one-stage protocol. Therefore, the angulation of the abutment cannot be altered and only minimal modification of the abutment is possible. Without the prosthetic freedom of the abutment choices, the initial surgical positioning of one-piece implants becomes critical in obtaining an optimal result.



The advantages of one-piece implants include minimally invasive surgery, simple restorative procedures and no screw loosening. Furthermore, the amount of crestal bone resorption may be minimised, since there is no micro-gap or micro-movement between the implant and its abutment. This becomes even more critical for long-term aesthetic results in the anterior region. In order to demonstrate the successful use of one-piece implants, this article describes the restoration of mandibular incisors with one-piece MDIs.

_Case reports

Case I

A 67-year-old female patient presented with occasional throbbing pain in the mandibular anterior region. The patient's medical history was non-contributory. Clinical and radiographic evaluation revealed two separate peri-apical lesions on teeth #23, 25 and 26 (Figs. 1 & 2). The patient reported that tooth #24 had been extracted 15 years ago. The incisors were deemed non-restorable and treatment planned for extraction. Owing to the size and duration of the peri-apical lesions, delayed placement of implants was planned. The teeth were carefully luxated with a periosteal elevator and atraumatically extracted, preserving the thin facial bone. A wire-embedded provisional restoration was fabricated and bonded to the adjacent canines with flowable resin (Figs. 3 & 4). After ten weeks of healing, the provisional restoration was removed. The distance measured

between the two mandibular canines was 15 mm (Fig. 5).

A crestal incision was made and a limited soft-tissue flap was reflected to expose the alveolar crest of bone. In this fashion, the patient experiences reduced post-operative swelling and discomfort. With a 1.6 mm twist drill and copious irrigation, osteotomies were performed at a speed of 1,500 rpm. The angulation of the twist drill was carefully monitored throughout the osteotomies. Following completion of the prepared implant sites, visual and tactile inspection of the internal bony walls was performed to ensure the absence of any fenestration or dehiscence at the cervical area. Two 2.5 mm-diameter implants (MS implant, Osstem) were then placed in the ideal 3-D position and torqued to 25 Ncm with a manual torque wrench. The superior margin of the transmucosal portion was positioned 2 mm apical to the soft-tissue margin (Figs. 6 & 7). Immediately following implant placement, provisional restorations were fabricated at chairside using prefabricated temporary abutments and acrylic resin.

The provisional restorations were snapped into position using the friction-fit temporary abutments, eliminating the use of cement (Figs. 8 & 9). This could remove the risk of cement being forced into the gap between the implant fixture and soft tissue. The provisional restorations had no centric or eccentric occlusal contacts. The patient was instructed to avoid any function of the implant for eight weeks.

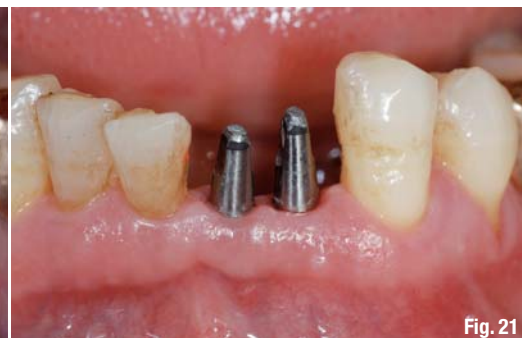
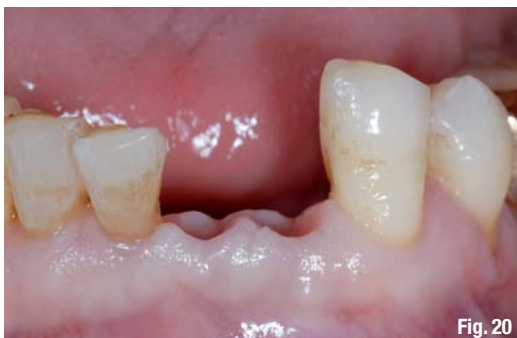
Fig. 17_Pre-op X-ray.

Fig. 18_Resin-bonded provisional restoration after extraction of teeth #23 and 24.

Fig. 19_Eleven weeks post-extraction.

Fig. 20_Papilla preservation with ovate pontics.

Fig. 21_Eight weeks post-implant placement.

Fig. 22 Modified impression caps.
Fig. 23 Indexing jig.

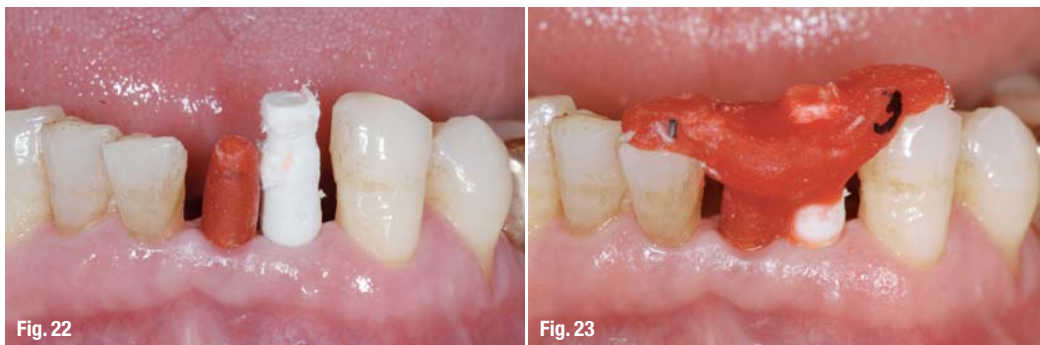
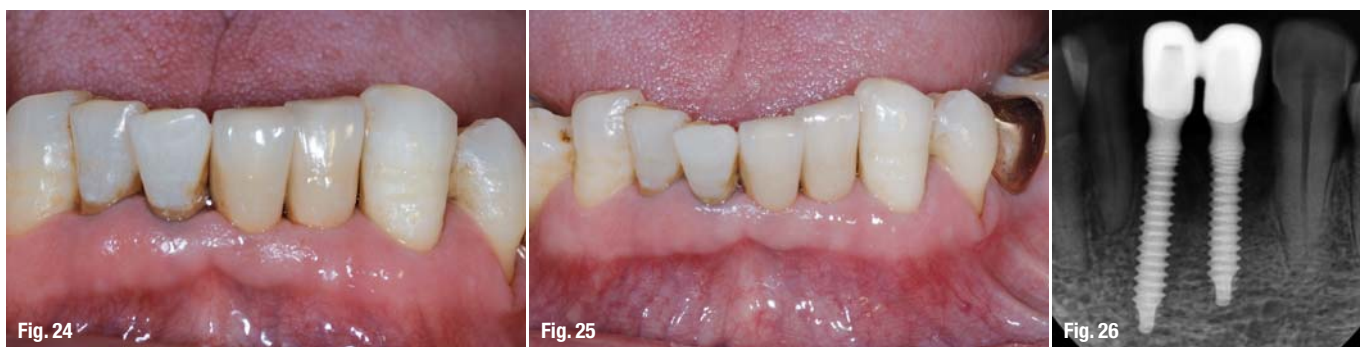
Fig. 24 Final prosthesis.
Fig. 25 Eleven-month follow-up.
Fig. 26 Peri-apical X-ray.



After a healing phase of two months, a final impression was produced using friction-fit impression caps (Figs. 10 & 11). Definitive restorations were then fabricated on the working cast and adjusted to have slight occlusal contacts

altered cast was made, and a definitive prosthesis was fabricated. The clinical and radiographic evaluation at 11 months demonstrated a good aesthetic result with no significant peri-implant bone loss (Fig. 24).


in centric occlusion and excursive movements (Figs. 12–14). The clinical re-evaluation demonstrated a minimal gingival change around the prosthesis, and a stable horizontal bone level was observed radiographically at the 13-month follow-up (Figs. 15 & 16).

Case II

A 58-year-old male patient presented with severe mobility and peri-apical lesions on teeth #23 and 24 (Fig. 17). A provisional restoration was fabricated and bonded to the adjacent natural teeth immediately following extraction (Fig. 18). The provisional restoration was left undisturbed for 11 weeks and the interdental papillae were preserved with ovate pontics (Figs. 19 & 20). The interdental distance measured between teeth #22 and 25 was 8 mm, and two 2.5 mm-diameter implants were placed in position. The superior margin of the transmucosal portion was positioned sub-gingivally, and the height of the abutments was reduced to ensure adequate incisal clearance (Fig. 21). Owing to the limited interdental space, the impression caps were modified (Fig. 22). An indexing jig was used to avoid any undue stress applied to implant fixtures during the impression procedure (Fig. 23). An

Conclusion

Based on the clinical cases presented in this article, the utilisation of one-piece MDIs appears to be a good treatment option for replacing missing mandibular incisors. Considering the simplicity, ease of implant placement and immediate provisionalisation, this treatment offers a new option for patient care.

about the author		cosmetic dentistry
	Dr Chonghwa Kim specialises in prosthodontics and implantology. He works in a private practice in downtown Seoul, Korea. He graduated from the University of Michigan School of Dentistry in 1997 and completed	
	prosthodontic training at the University of Minnesota. Dr Kim is Co-director of the Global Academy of Osseointegration and serves as a Director of international relations for the Korean Academy of Esthetic Dentistry. He can be contacted at kimchonghwa@hotmail.com .	



Reproducción autorizada por el Instituto Nacional de Bellas Artes y Literatura, 2011

Federation Dental International Annual World Dental Congress

NEW HORIZONS IN ORAL HEALTH CARE
14 - 17 SEPT. 2011



www.fdi2011.org
info@fdi2011.org

“The philosophy of dental treatment is very important”

An interview with Dr José Roberto Moura, IFED President



Dr José Roberto Moura

_Dr José Roberto Moura graduated from the University of Taubaté (Brazil) in 1983 with a specialty degree in Restorative Dentistry. He later completed his master's degree in Prosthodontics at the same university. Dr Moura served as President of the Brazilian Society of Esthetic Dentistry (BSED) from 1999 to 2000 and from 2002 to 2003. He is currently President of the International Federation of Esthetic Dentistry (IFED).

_cosmetic dentistry: *Dr Moura, you have been actively involved in aesthetic dentistry since your first BSED presidency in 1999. Would you please tell us how you became involved in dentistry?*

Dr Moura: Actually, I have been involved in aesthetic dentistry for much longer. In 1990, I started to work with adhesive dentistry using some materials and techniques that I had brought to Brazil from the USA. In 1994, my friend Dr Marcelo Fonseca started the BSED and invited me to join its board of directors, as we were already working in that area even though it was something new in Brazil at that time.

_Cosmetic dentistry is guided by patient desires, contemporary fashion and trends. However, the majority of cosmetic dental treatments are invasive in nature and not always in line with oral health and ethical standards. What is your take on this?

I disagree with that statement. I think that aesthetic dentistry is also based on, for example, direct composite restorations, which are very conservative and able to improve smiles while preserving sound dental structure. Even bonded ceramic restorations have become more conservative over the years with the improvement of these materials, which are becoming more resistant even at small thicknesses. Besides that, there are very conservative aesthetic techniques such as bleaching, cosmetic contouring and micro-abrasion. The philosophy of dental treatment is very important in this matter and this, in turn, is directly influenced by the way dentists are trained and taught.

_In your opinion, what are the most important considerations for dentists interested in introducing cosmetic dentistry into their general practice? What are the largest obstacles?

Cosmetic dentistry is the use of dental materials that not only restore the function of the tooth, but also its appearance. These materials, mainly composites and ceramics, are already largely in use in many practices. Besides, in many countries, aesthetic dentistry is one of the main reasons that patients come to dental offices nowadays. The bottom line is that every dentist doing cosmetic dentistry in his or her practice needs to go about this very seriously, taking high quality hands-on courses, especially those that value conservative treatments and patient health.

_You are currently serving as IFED President. Would you please briefly highlight the main goals and activities of IFED, as well as what you wish to achieve during your presidency?

The main goal of IFED is to bring aesthetic dentistry academies from all over the world together to interact with one another in seeking to promote the exchange of experience and knowledge. IFED has one General Assembly that takes place in Chicago during the Midwinter Meeting, where new ideas are presented to IFED by the representatives of the academies. We also have a World Meeting every two years, which is hosted by one of the member academies. The next one will be held in Brazil from 2 to 5 November 2011 in the beautiful city of Rio de Janeiro.

_What are IFED's current challenges in expanding its membership and activities in the Asia-Pacific region?

We need active members that can really help us contact representatives of aesthetic dentistry groups all over Asia who are willing to join us in our task. We have had great help from people like Dr Peter Tay (Singapore), Dr Seok-Hoon Ko (Korea), Dr Akira Senda (Japan) and Dr Sushil Koirala (Nepal), and I personally hope we can expand the IFED representation in Asia.

How can a national academy become part of IFED?

In order to apply as candidate, they need to fill out a form, which can be requested from our secretary through our website. The applications will be reviewed by a members committee and discussed during the annual Executive Council meeting in Chicago. If the criteria are met, they will be voted in at the General Assembly as associate members. Following three years of activity, they are voted to become active members and also part of our great world family.

Next year's IFED meeting will be held in your home country Brazil. How are preparations coming along and what will the major attractions be?

The BSED is working very hard in order to promote a great meeting with presentations by the great masters from all over the world, and also a good social programme that promotes interaction amongst participants. We will be proud to have Dr Adriana McGregor (USA), Prof Bart van Meer-



IFED

International Federation of Esthetic Dentistry

beek (Belgium), Dr Christian Coachman (Brazil), Dr Dinos Kountouras (Greece) and Dr Tidu Mankoo (UK) as speakers, amongst others. Additionally, the beautiful and charming city of Rio de Janeiro will certainly be a wonderful host city.

Information technology has changed the way dentists are educating themselves. Internet-based webinars and study clubs have become standard practice for dentists worldwide. How is IFED using this technology to educate professionals and the public globally?

We intend implementing an e-learning section on our website with articles and videos as soon as possible. We are also seeking to establish online journals. There are also many other ideas that the Executive Committee is currently discussing, but I must say, this is not an easy task, but one that I am personally committed to.

AD

implants

international magazine of oral implantology



One issue free of charge!



Subscribe now!

You can also subscribe via
www.oemus.com/abo

I hereby agree to receive a free trial subscription of **implants international magazine of oral implantology** (4 issues per year). I would like to subscribe to **implants** for € 44 including shipping and VAT for German customers, € 46 including shipping and VAT for customers outside of Germany, unless a written cancellation is sent within 14 days of the receipt of the trial subscription. The subscription will be renewed automatically every year until a written cancellation is sent to OEMUS MEDIA AG, Holbeinstr. 29, 04229 Leipzig, Germany, six weeks prior to the renewal date.

Reply via Fax +49 341 48474-290 to OEMUS MEDIA AG or per E-mail to grasse@oemus-media.de

Last Name, First Name

Company

Street

ZIP/City/Country

E-mail

Signature

Notice of revocation: I am able to revoke the subscription within 14 days after my order by sending a written cancellation to OEMUS MEDIA AG, Holbeinstr. 29, 04229 Leipzig, Germany.

Signature

OE 1/11

“Foreign markets are very important to us”

An interview with Olaf Sauerbier, CEO of VOCO GmbH

_VOCO, based in Cuxhaven on the northern coast of Germany, is an established international provider of high-quality dental materials. In addition to products for restorative dentistry, it offers a wide range of materials and preparations for the fields of prosthetics and prophylaxis. **cosmetic dentistry** spoke with Olaf Sauerbier, CEO and chief of Marketing and Sales, about new products and aesthetic trends in restorative dentistry.

Olaf Sauerbier (left) in talks with DT Group Editor Daniel Zimmermann.



_cosmetic dentistry: *The Association of Dental Dealers in Europe (ADDE) has recently predicted growth rates above three per cent for most European dental markets. Do you see any signs of recovery in your company?*

Olaf Sauerbier: To be honest with you, the recession never really caught us. We usually tend to perform slightly better than the overall market and expect to be no different for this business year. The year 2010 started off better than last year ended, and we saw some significant growth in most of our business segments in the first and second quarters.

Although we have invested significantly in our German businesses by extending our sales team

by 15 new employees, foreign markets are very important to us. At the moment, we are expanding our existing businesses worldwide, especially in North America. It will be a while before we are able to take full advantage of the enormous potential this market has to offer.

_Did the products you introduced two years ago at IDS Cologne meet your expectations?

The most important product we introduced at IDS in terms of sales was definitely the non-run, non-drip NDT syringe. This new delivery form helped us to increase sales of most of our highly flowable materials like Grandio Flow, Grandio Seal and Ionoseal. Our gingiva-shaded restoration system Amaris Gingiva has also shown good performance. We have to admit that the market for such a product is still small but, on the other hand, we see the demand for aesthetic restorations of exposed necks of teeth increasing owing to demographic changes and people ageing. Those who have highly aesthetic requirements will find it hard to pass this product by.

Another bestseller has been the one-component, light-curing, nano-reinforced, self-etch bond Futurabond M that we launched in SingleDose and in a three-bottle value pack. Not to forget the Rebuilda Post System, an award-winning complete system for placing 15 posts in post-endodontic treatment, that sold successfully in Germany and abroad within a short amount of time.

_Some segments in dentistry, dental implants in particular, have shown decreasing sales. What is the situation in the market segments you are involved in?

The recession might have had devastating effects on companies offering upscale materials and equipment but the situation in restorative and preventative dentistry looks far more promising. In the segments in which we are actively involved, such as prosthetics, prophylaxis or dental cements, we have been able to achieve growth rates between 10 and 20 per cent.

Filling materials did not perform very well owing to increased market competition. There are plenty of new and innovative filling materials on the market right now and we have to invest a great deal in order to stay ahead with new developments and products.

What current trends have you observed in the industry?

All manufacturers are striving for a product that offers almost ideal properties for a filling material and exhibits the same physical properties as natural tooth substance. All our competitors are moving towards this ideal but I see us far ahead. We have been working with nanotechnology since the early 2000s and based on the results of this launched our first nanohybrid composite Grandio in 2003. This product is still in high demand in Germany and many other markets.

But we did not stop there. With GrandioSO, we are now able to present another nanohybrid composite to the dental community that has outperformed our original expectations. In terms of its physical properties, it is probably the most tooth-like material on the market.

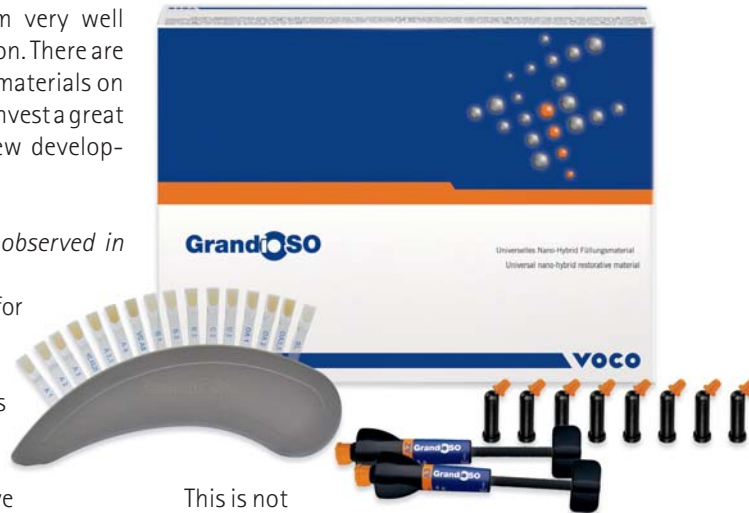When and where will it be available?

It is already available in Germany and other selected European markets. Like its predecessor, GrandioSO is universally applicable but a little more translucent, so it can be used for restorations in the maxillary anterior region.

We will still offer Grandio to our customers worldwide. In the end, it is the dentists who decide which product they prefer.

Do aesthetics play a more prominent role in the development of a composite like VOCO's GrandioSO?

The primary goal is function. There is a place for aesthetics too, but it must not compromise functionality or the stability of the filling. There are different points of view in dentistry regarding this matter right now but for us the primary goal cannot be highly opaque teeth that might be currently en vogue amongst Hollywood stars. In the US, for example, we found that dentists were using the white opaque shade of our flowable composite Grandio Flow for anterior restorations, as this is the typical shade of highly bleached teeth in the US. Normally, we recommend it only be used to whiten dark spots or in cases in which dentists absolutely need an opaque layer.



This is not the direction we wish to take. Teeth have a natural translucency and we want to keep it that way. I believe that with our current portfolio we offer dentists viable solutions to achieving long-lasting and natural aesthetic restorations.

Some European companies develop their products especially for the North American market. Do you do the same?

We sell exactly the same products in North America as we sell in Europe. Usually, most products are launched there six months after they have been placed on the European markets. The only difference is the type of shade. In Germany, for example, the majority of dentists use Shade A3.5, which does not play any significant role in markets like the US, where Shade A2 is more common.



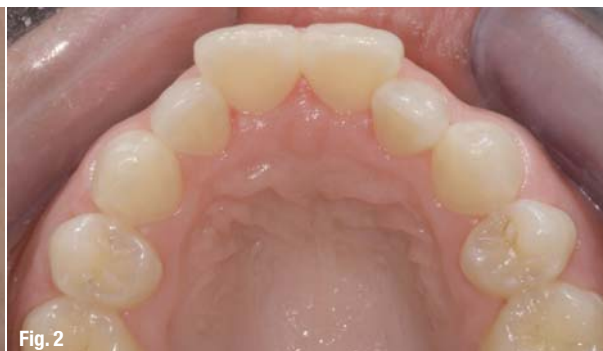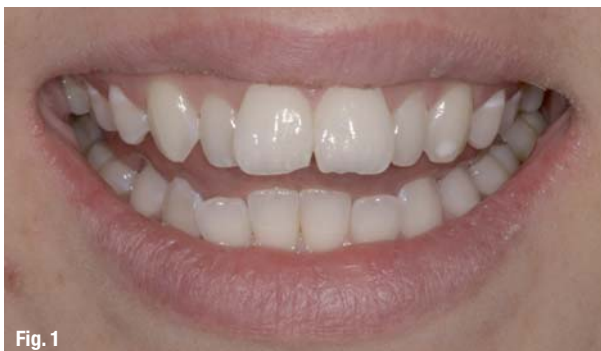Will GrandioSO be the main focus of your presentation at IDS this year and are you planning to introduce more products there?

GrandioSO will indeed be the main focus of our IDS presentation, but there are other products that we plan to launch at IDS 2011.

Aerial view of the VOCO headquarters in Cuxhaven, Germany.

The Inman Aligner—Alignment, bleaching, bonding: A progressive approach to smile design (Part II)

Author_Dr Tif Qureshi, UK



The following article is Part II in a series discussing the use of the Inman Aligner as a tool for MICD.¹ The first article (published in *cosmetic dentistry* 2/10) demonstrated that standalone treatments offer patients an alternative to fixed braces, which are unsightly and have long treatment times, and to expensive clear aligner treatments in suitable cases.

This article will demonstrate that patients who desire a more traditional smile makeover can achieve beautiful results in a more progressive manner that

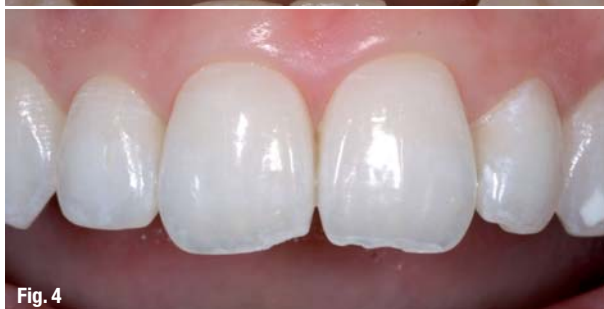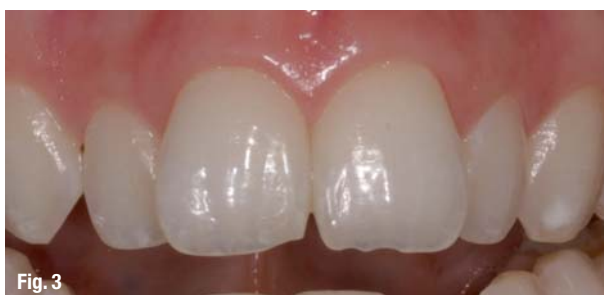allows them to make their choices along the way. This often results in virtually no removal of tooth structure and a treatment result with the responsibility of decision-making shared between dentist and patient.

Moreover, the subject matter of this article could potentially start one of the most controversial debates in cosmetic dentistry for years. We are not only discussing a radically different approach to smile makeovers, but critically a sharply different approach to the traditional methods of planning smile design.

What would you choose?

Patients entering cosmetic practices are often assessed at the initial consultation. They have digital photographs taken and perhaps study models are made. Normally, dental imaging software is used to show patients what can be achieved. These ingenious programmes can help patients realise what is possible. Naturally, care must always be taken when promising treatment results that are viewed digitally.

While computer imaging can be a very powerful tool to help the patient see the potential in his/her smile, I believe it also can make a patient focus on a certain prescribed goal that may not be the only way of satisfying his/her wishes. Dentists using imaging would ideally create a set of five to ten different out-



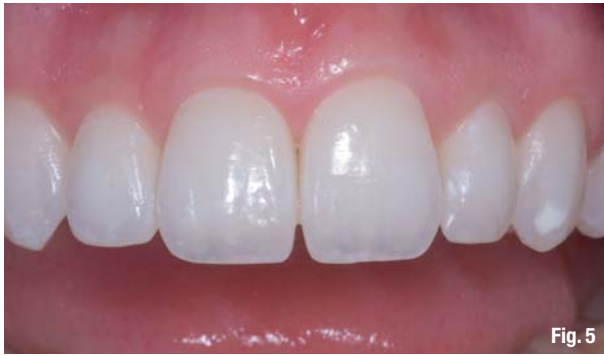

Fig. 5

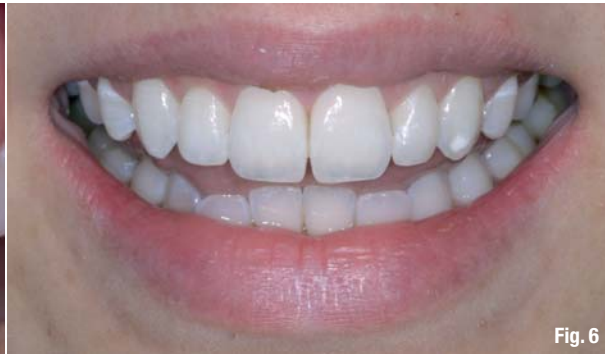

Fig. 6

comes of varying degrees of improvement to allow the patient to make a more informed decision. While ideal, it is not certain that dentists actually present different levels of treatment to their patients digitally. Even if they were able to see various images of their teeth, it can still be difficult for a patient to really see and feel the suggested changes in their mouth. One can question the ethics of allowing patients to commit to a potentially irreversible procedure based on 2-D photographs.

Three-dimensional wax-ups can also be very useful at this stage. If a patient is keen on the image, going to an additive wax-up can sometimes allow for a direct preview try-in using a silicone stent taken from set-up. Temporary material of variable shades can be tried in directly, without any bonding to allow the patient to see the proposed outline, form and overall aesthetics.

Despite this, veneers are often used to treat alignment issues and it is very difficult for patients to appreciate the alignment of their own teeth with wax-up or imaging. **By approaching these cases with a different protocol in mind, a dramatically less invasive treatment plan becomes evident.**

The first step is to look at the patient's tooth alignment. Misaligned teeth often cause issues in gum heights, line angles, light reflections, shades and tooth length. Correcting the misalignment first can create a completely different perception of the apparent problems. Next, the teeth should be bleached. This can be done either immediately after the teeth have been aligned or preferably simultaneously. After alignment and bleaching, edge bonding (we term this the ABB concept) should be offered to improve the incisal edge outline.

This combination of treatments also works well because the Inman Aligner is a removable appliance and only needs to be worn 16 to 18 hours a day. This means simultaneous bleaching is very possible and straightforward. A recent study from Sweden indicates a cost-benefit advantage of treating patients with removable appliances in general dental clinics,

rather than with fixed appliances at specialist orthodontists.² The conclusion of this study is significant, since a popular choice amongst aesthetic dentists in the UK is removable orthodontics.

The cases outlined below highlight patients who, either at the start of treatment or for years, had originally wanted veneers and had a specific result in mind that only veneers could have offered quickly. They were all concerned about the degree of preparation required, so undertook alignment first. Then, part of the way through, started bleaching and very quickly changed their minds about what they wanted once they saw their own teeth improve.

_Case I (Figs. 1–8)

Laura was concerned about her very prominent central incisors. She wanted to have them straightened and had considered veneers. She had ruled out conventional orthodontics and invisible braces be-

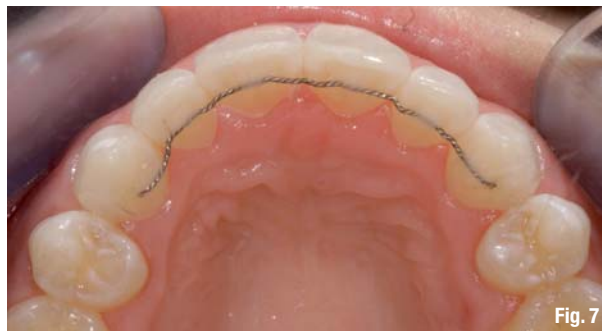
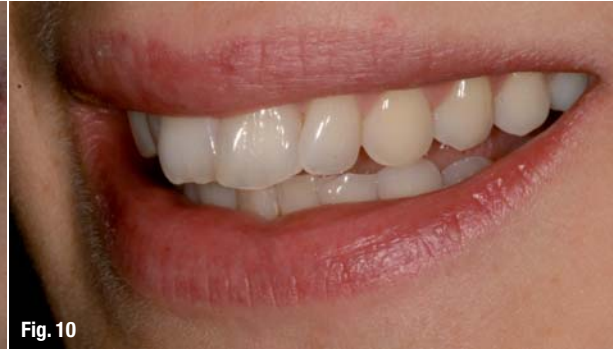
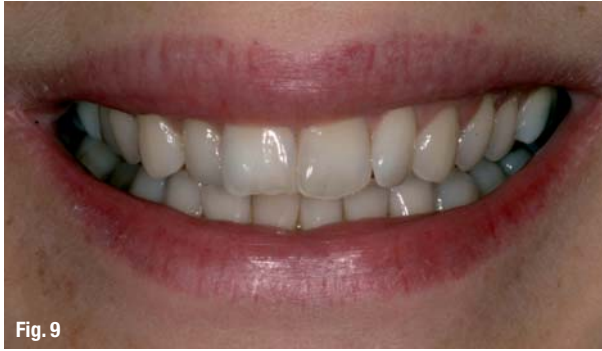Fig. 7



Fig. 8



cause she wanted a quick treatment and did not want anything stuck to her teeth, which is the reason that she had refrained from orthodontic treatment. Several years ago, she may well have had veneers placed.

On viewing her teeth before the occlusal photograph, it was quite clear that this would have involved massive preparation of the upper central teeth. Preparation would have been well into dentine and may have even involved elective endodontics. Her lateral teeth would have needed little preparation, but the emergence profiles would have been poor, creating unrealistic aesthetics and a possible periodontal risk later on. Instead, the alignment was completed with an Inman Aligner in ten weeks. Her treatment sequence is detailed below.

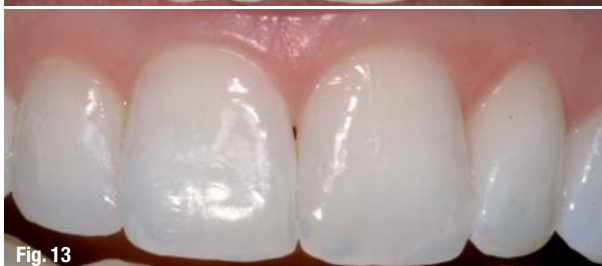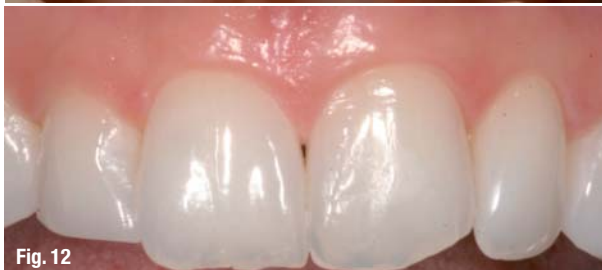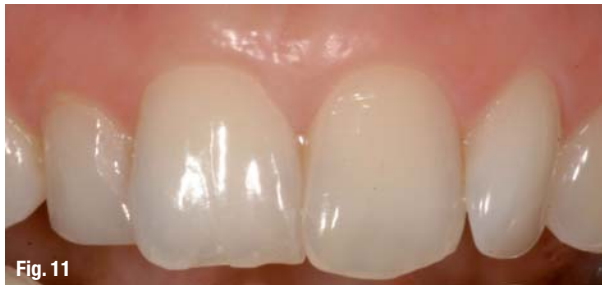BACD-style digital photographs were taken and the amount of crowding was calculated using an

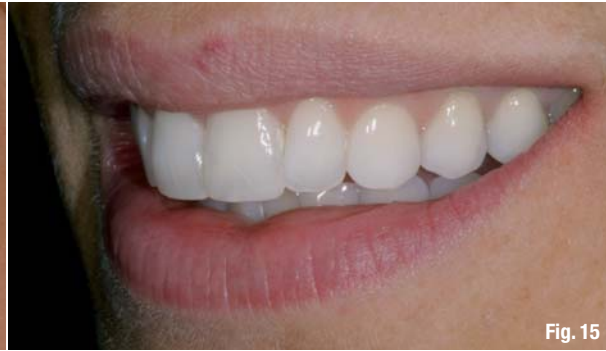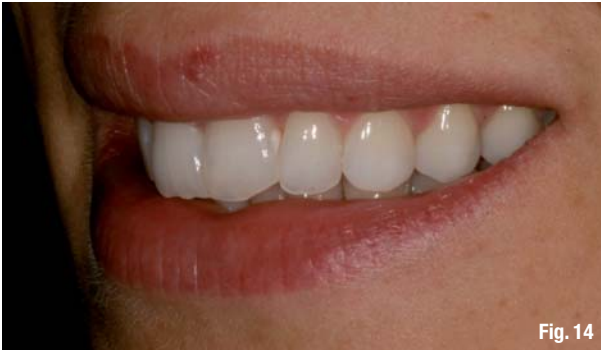electronic crowding calculator, which can also be done by arch evaluation of the patient's study models. We measured the ideal curve and subtracted this measurement from the total mesio-distal widths of the teeth being moved.³ The results showed that there was only 1.6 mm crowding. This seemed less than one would have expected; the reason for this was that because the laterals were being pushed out, the arch was being expanded, thus creating space.

It was clear from the photographs that despite the obvious crowding, there was some less obvious irregular tooth wear. It was important to indicate this to the patient, as this would become more evident once the misalignment had been corrected. The patient was quoted for three incisal composite tips. She opted for an Inman Aligner with an incorporated expander. These expanders are a very handy way of creating extra space either to treat cases that are more complex or to use instead of performing interproximal reduction (IPR).

In this case, **no IPR was performed**. We planned to get nearly all space by using the midline expander. The patient was instructed to turn the midline screw once a week after one week of wear. Each turn is 1/4 of a revolution and equates to 0.25 mm. At week six, bleaching was started with soft rubber sealed trays. After nine weeks, the patient had expanded 1.8 mm and her teeth were in alignment. (As a rule, less than 2.5 mm expansion with an incorporated expander is easily tolerated.)

Looking at her post-alignment result, the golden proportion, gingival heights and axial-inclinations had improved dramatically, all without a handpiece being picked up and in the space of nine weeks. What was very clear to the patient at this point was that she only needed some simple bonding to improve the incisal edge outlines. Without the use of an anaesthetic, the edge outlines were prepared with very slight roughening of the edge, bonding of hybrid composite on the load bearing edge and a micro-fill on the facial surface. The edges were then polished.





The patient was thrilled with the result we achieved using an Inman Aligner and some simple bonding. She described that when she had once considered having veneers, she had hoped for a similar result. There are still minor imperfections, but, in my opinion, these contribute to her natural beauty.

There is a stark contrast between the treatment selected and the potential treatment approaches in this case. Where once a patient, who refused orthodontics, would have consented and received highly aggressive tooth preparations to achieve correct alignment with veneers, now a removable aligner and some simple bonding were able to achieve a similar and arguably better result in less than three months with not a micrometer of tooth reduction needed.

Case II (Figs. 9–17)

This young lady had been attending my practice for some time and was aware of porcelain veneers, having seen our previously advertised cases. We had spoken about the aesthetic benefits of veneers years before. However, on reviewing her case, it was clear that we could improve her alignment dramatically with an Aligner in a short period.

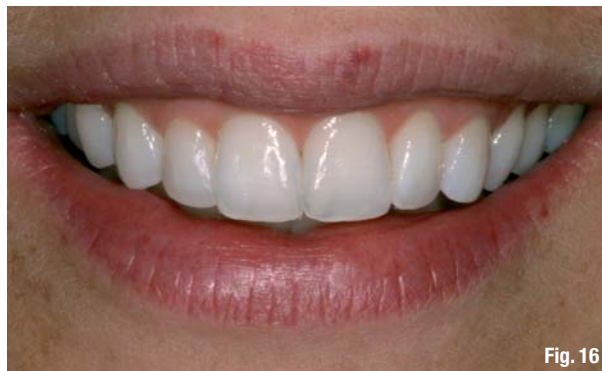We took an occlusal image of her anterior teeth and outlined the amount of tooth structure that would have to be removed to produce veneers that would look aesthetic. It was immediately apparent to the patient that alignment of her teeth would offer a possibly better treatment outcome. Her case was suitable for an Inman Aligner and as only 2.5 mm crowding was present, this meant it could be treated quickly and simply.

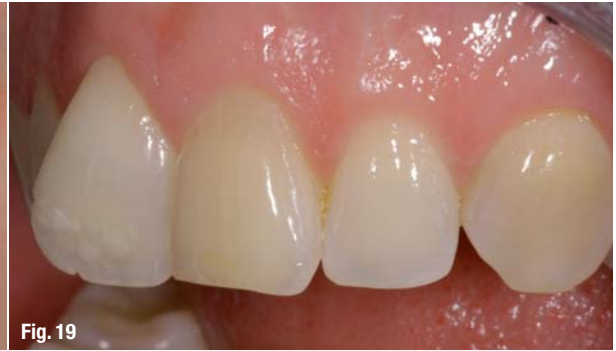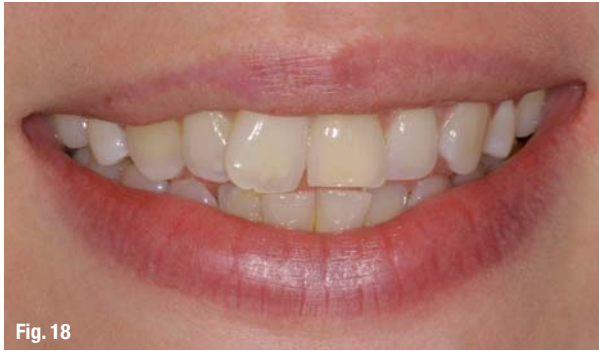Her Inman Aligner was fitted and IPR performed progressively over three visits. At week eight, upper and lower bleaching trays were constructed even though her alignment was not yet complete. Home whitening was begun with clear and concise instructions. We used rubber trays with a deep seal cut into the model to create a tight dam effect. Over two weeks, her teeth whitened nicely and at week ten, she returned for a review.

Interestingly, the patient's perception of her smile had changed dramatically. Owing to the improved line angles, whiter teeth and balanced gum heights, her eyes were now only drawn to the irregular outline caused by chipping and differential wear.

The patient then enquired about fixing the edges. We offered to bond the incisal edge with virtually no preparation. A hybrid composite (Tetric Flow, Ivoclar Vivadent) was placed palatally and incisally with a micro-fill on the facial surface. This was done in B0 and B1 shades to match the bleaching. The patient was delighted with the result and a wire retainer was bonded immediately.

Despite some clear deviations from her ideal simulated smile, the patient explained that she felt her smile after alignment was better than she had





imagined her veneers would have been. Had veneers been placed, we could perhaps have corrected the golden proportion more fully, balanced the zeniths, improved the canine outlines, widened the buccal corridors, etc. However, that was clearly not what the patient desired. Should she later decide that she does need further improvements, we can proceed with already straightened teeth. The ABB smile design is progressive and not sudden or rushed. In this manner, the patient is given the opportunity for decision-making in his/her treatment and the responsibility in choice is shared.

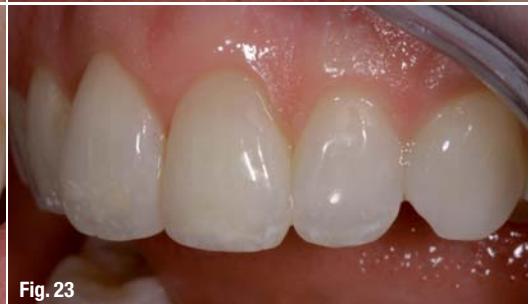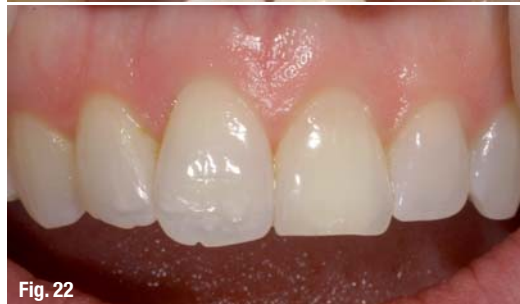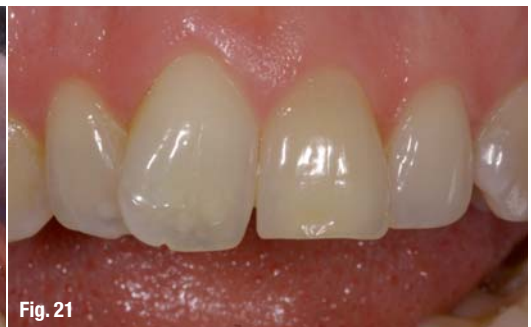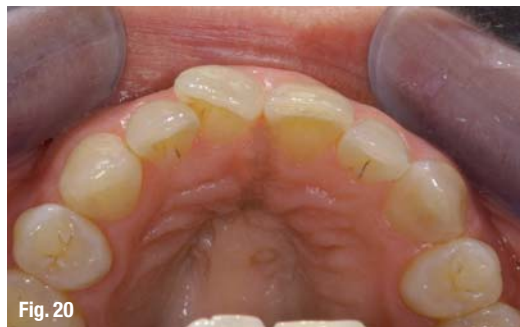_Case III (Figs. 18–26)

This patient presented with what she described as a "wonky smile". She had previously looked into the possibility of having porcelain veneers placed so understood some of the aims of smile design. However, on studying her teeth, it became clear that there was potential to pre-align first. Her upper right central was mesially rotated by approximately 30° and her laterals were slightly in-standing and mesially inclined. Furthermore, she had fairly stained teeth, with the canines two shades darker than the centrals.

On examining the occlusal view, the patient became aware of the extent of aggressive tooth preparation that would be required to place a veneer. She understood that her teeth needed to be aligned first before we decided on the next step in design.

An Inman Aligner was used over the period of eleven weeks to de-rotate the front tooth and to tip out the laterals. At week eight, bleaching was begun using 35- to 45-minute a day H₂O₂ gels. Simultaneous whitening is a very attractive part of aligner treatment, as it helps with patient motivation. After alignment, the case was re-examined. Once her teeth had been straightened, it became evident to the patient that her problem concerned *edge shape*, which had actually worsened with alignment owing to differential wear. In fact, the left central was 2.5 mm shorter than the right. It was very clear to the patient that only these incisal edges needed building in order to achieve the smile she desired.

For placement of the incisal edges at week twelve, no local anaesthetic was administered. Other than slight roughening of the worn incisal edges of the upper left 1 and 2, no other preparations were needed. A tetric hybrid composite (Tetric Flow, Ivoclar Viva-



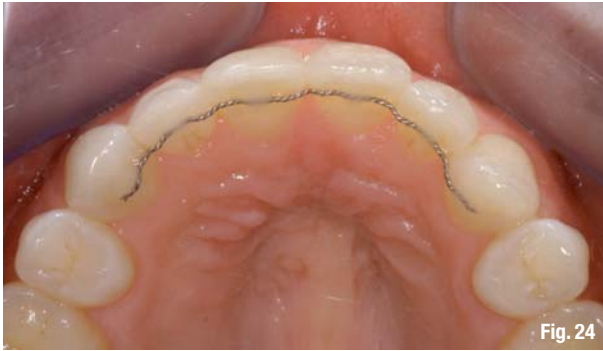

Fig. 24

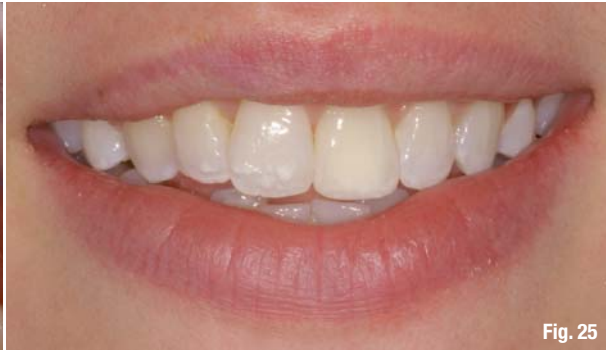

Fig. 25

dent) was built up free-hand on the incisal edge and palatal surface to match the outline of the other central. A small amount of white opaquer was dotted in to match the facial surface and was simply filled with a nano-hybrid composite (Venus Diamond, Heraeus) for high polish. The composite was polished vertically using rubber sticks (PoGo, DENTSPLY DeTrey) to try to blend in with surface anatomy to mask the join. The process was repeated on the lateral.

The patient was held in retention using her aligner and an impression was taken for a wire retainer to be fitted two weeks later. It was especially nice to retain the natural aesthetic characterisation of this patient. Ceramic work, as beautiful as it can be, would certainly have changed her appearance more—some may say for the better, but that was not what the patient actually wanted. She wanted her own teeth to have correct length and look straighter and whiter.

Shared responsibility of treatment

The ABB concept can truly be described as minimally invasive. At the same time, it actively involves the patient in the treatment, giving him/her a feeling of being in control and taking responsibility for his/her treatment. This has been proven to be of great significance when measuring patient satisfaction of treatment results.⁴

There are many anecdotal stories about patients who had technically beautiful veneers placed but found that these simply did not meet their desires. The problem is that even with no-preparation veneers, an irreversible procedure has been undertaken and this has been done mainly based upon the treating dentist's opinion, with the patient having very little input.

In my experience, every patient that I have treated according to the ABB concept has accepted the result happily, even though technically it might not be perfect from a smile design point of view. Nowadays, with rising levels of litigation, one would have to question the wisdom of selecting a treatment path that could result in conflict over one in which the patient participates in key decisions and sees his/her own teeth improve.

I believe this approach firmly sits alongside MICD core principles, which recommend a more minimally invasive and patient-led approach.

Conclusion

I understand the controversy in challenging the traditional approach to smile design, but the new mantra of **progressive smile design** is vital when we are looking to give our patients what they actually want. Previously, pre-whitening was always a way of giving our patients an alternative view of their

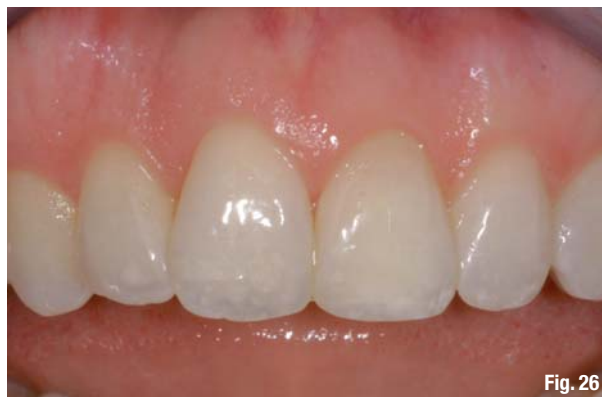

Fig. 26

teeth. Now, and more significantly with alignment techniques, patients can make their own decisions and massively reduce the risks by breaking down the process of a smile makeover into stages and re-assessing at each point.

With ABB, it is possible to align, whiten and bond a case in less than twelve weeks, which previously might have required eight to ten veneers, four times the cost and significant tooth preparation. Thus, a dramatic contrast in pathways has been created. If a patient is happy after alignment, whitening and minimal bonding, then this has to be viewed as a success. This UK technique is now a significant new treatment discipline in itself and cosmetic dentistry will be better for it. After all, what would you choose to have?_

Editorial note: A complete list of references is available from the publisher.

_contact **cosmetic**
dentistry

Dr Tif Qureshi

Straight talks Seminars
40–44 Clipstone Street,
Ground Floor East
London, W1W 5DW
UK

info@straight-talks.com
www.straight-talks.com

CLEARFIL SA CEMENT— Easy to remove, hard to forget!

Author _ Dr Jürgen Garlichs, Germany

In past years, adhesive technology has progressed substantially, especially in the area of direct, aesthetic composite restorations. The basis for enamel adhesion through acid etching was laid by Dr Michael Buonocore in the 1950s. Since then, the procedure has established itself as a safe and permanent method for adhesion in dentistry. For a long time, dentine adhesion was not able to provide even nearly as good results as enamel adhesion. Only in the 1990s were products developed that enabled reliable dentine adhesion.

Furthermore, most all-ceramic systems require an adhesive bond with the hard tooth substance to stabilise the ceramic framework.

CLEARFIL SA CEMENT

CLEARFIL SA CEMENT is a self-adhesive, dual-curing composite cement for the cementation of indirect restorations, such as crowns and bridges; inlays and onlays made of metal, ceramic and composite; as well as root-canal posts. The material is applied directly from the

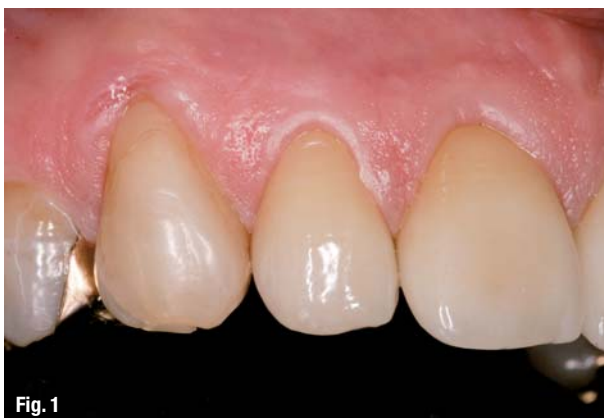

Fig. 1

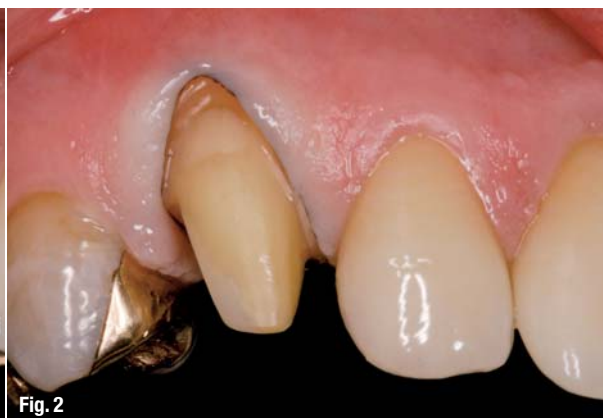

Fig. 2

Fig. 1 _Initial situation. Tooth #13 with approximal caries, apical osteitis and poor cervical restoration. Prosthetic provision planned after endodontic treatment.

Fig. 2 _Prepared situation before insertion. Adhesive build-up fillings were placed in the cervical and disto-incisal areas. A retraction cord was used in order to ease cementation and drying.

Owing to the great results with direct adhesive techniques, they were also implemented for the adhesion of indirect prosthetic restorations. The aim was to combine the simple and quick handling properties of conventional cements with the good adhesion of modern composite provisions. This first led to the further development of classic composite cements and finally to the development of self-adhesive composite cements that do not require extensive pre-treatment of tooth structures.

The reasons for focusing on self-adhesive cements include numerous clinical trials, which prove that the bond and stability of metal-free crowns on prepared teeth are significantly higher with adhesive composite cements than with conventional cements, such as zinc phosphate, glass ionomer or polycarboxylate ce-

Automix delivery syringe without prior etching or bonding to the hard tooth substance. Furthermore, CLEARFIL SA CEMENT releases fluoride ions into the surrounding tooth substance. Compared with other fixing cements, CLEARFIL SA CEMENT provides an excellent bonding strength to enamel (23.2 MPa) and dentine (18.1 MPa),¹ as well as mechanical stability, in addition to its easy handling properties. Owing to its self-adhesive ability, the dentine tubules are sealed and hypersensitivities thus prevented.

CLEARFIL SA CEMENT mainly contains Bis-GMA, TEGDMA, hydrophobic dimethacrylate and MDP. Its self-adhesive ability is achieved reliably and effectively through the unique adhesive monomer MDP as tried and tested in CLEARFIL bonding cements and PANA VIA (both

Kuraray). Owing to the affinity of CLEARFIL SA CEMENT to and good wettability of the tooth surface, the MDP penetrates into the tooth structure effectively and ensures even adhesion. Multifunctional monomers and the dual-curing catalyst system provide a high cross-linking rate and good polymerisation characteristics. The mixed, uncured cement has a mildly acidic pH value. After application, the pH value rises until it is neutral in its polymerised state. CLEARFIL SA CEMENT contains 66 wt% (45 vol%) of filler material in and below the micro-metre range with an average size of 2.5 μm , and therefore has exceptional mechanical properties in combination with a thin layer of only 19 μm .

Clinical case reports have proven the excellent material properties of CLEARFIL SA CEMENT. In an investigation, Dr Cornelis Kleverlaan at the Academic Centre for Dentistry Amsterdam recorded a flexural strength of 81 MPa for CLEARFIL SA CEMENT. A trial by Yamamoto *et al.* at the University of Osaka demonstrated that

metal posts and glass-fibre posts. CLEARFIL SA CEMENT is available in Universal (A2) and White colour shades.

Advantages of CLEARFIL SA CEMENT

The most significant clinical advantage is good adhesion through the MDP monomer and the resulting secure mechanical and chemical bond to enamel and dentine. CLEARFIL SA CeMENT is a universally applicable material and, owing to the thin layer it creates, allows for an adhesion cement layer of only 19 μm and thus high dimensional stability. The low water resorption in combination with excellent margin qualities supports long-term stability.

CLEARFIL SA CEMENT was developed on the basis of PANAVIA, a gold standard adhesive composite cement, whose properties have already been proven over a long period of time. The handling parameters were the main focus during the development of CLEARFIL SA CEMENT. The resulting advantages are undoubtedly its simple

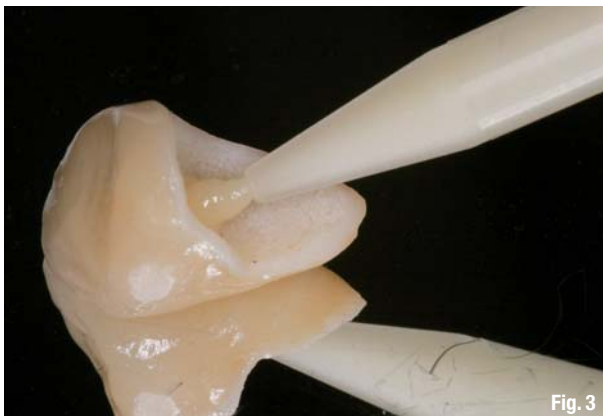

Fig. 3

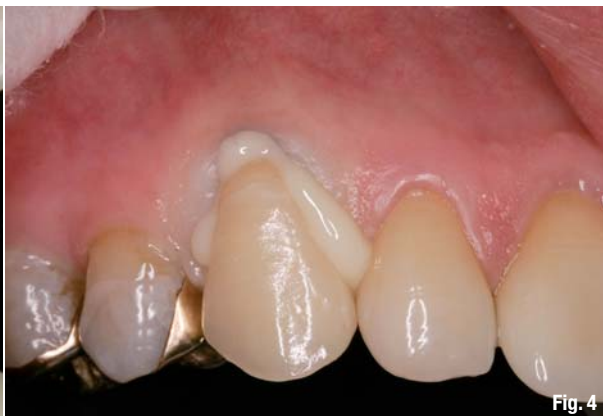

Fig. 4

CLEARFIL SA CEMENT has a low linear expansion rate (0.26%) and low water absorption (27.7 $\mu\text{g}/\text{mm}^3$).² A survey on the quality of the margins by Sadr *et al.* at Tokyo Medical and Dental University found perfect margins on all samples even after 3,500 thermal cycles.³ (For complete trial results, please refer to the detailed scientific product information of the manufacturer.)

Application range

CLEARFIL SA CEMENT is suitable for a wide range of indications involving indirect restorations and a wide range of materials, such as the cementation of crowns, bridges, inlays, onlays made of ceramic (zirconia, alumina, silica-based ceramic, etc.), hybrid ceramics, composite resin and metal, as well as metal cores, resin cores,

handling properties, the quick implementation of the treatment steps, the Automix application and flexible working times.

CLEARFIL SA CEMENT can be applied exactly portioned into the prepared restoration or onto the prepared tooth, directly after fitting the mixing tip. According to an internal trial, the relative moisture of the hard tooth substance is of secondary importance. CLEARFIL SA CEMENT provides very good bonding values on both dry, moist and wet enamel and dentine. Thanks to the dual polymerisation mechanism, the curing time can be controlled. After a short initial polymerisation of two to five seconds with the curing lamp, excess material can be easily removed.

After light-curing the margin for 20 seconds, the restoration will be set tight and saliva-proof

Fig. 3 Bubble-free application of CLEARFIL SA CEMENT (Universal) directly from the Automix syringe into the silane-treated, lithium-disilicate glass-ceramic crown. The hard tooth structure requires no conditioning.

Fig. 4 Ceramic crown directly after insertion. Excess CLEARFIL SA CEMENT can be easily squeezed out and remains at the crown margin without flowing away.

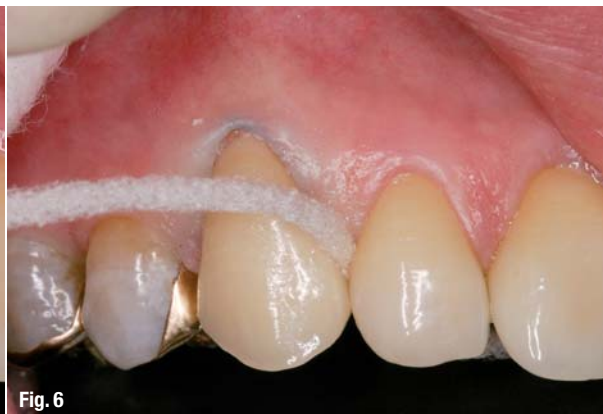
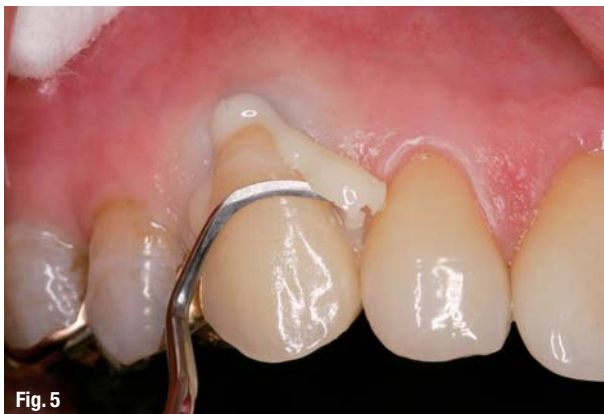
Fig. 5 After two to five seconds of light-curing, the excess material becomes gel-like and can be easily removed in one piece without leaving any residue.

Fig. 6 The approximal spaces are carefully cleaned with SuperFloss. The final light polymerisation phase takes 20 seconds.

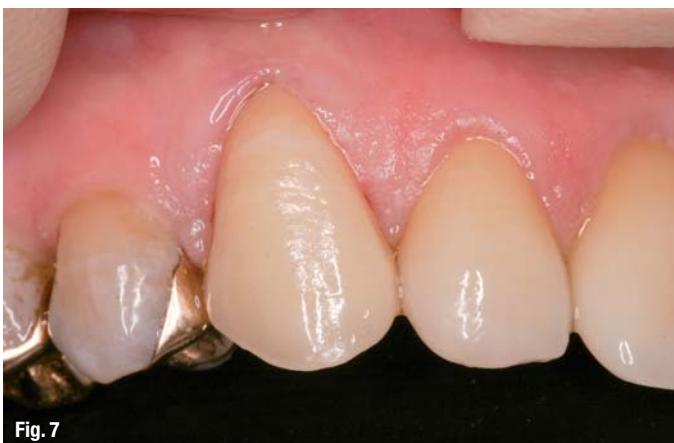in situ. Cement not reached by the light will polymerise within five minutes. Owing to the thinness of the CLEARFIL SA CEMENT layer, the cement will not alter the natural colour of the ceramic restoration. In general, the Universal (A2) colour shade is used. White, which shows a better contrast with the gingiva when removing excess material, is used to shield against dark dentine colours or under metal restorations.

Clinical case

A 65-year-old patient presented with pain in tooth #13. After examination and X-ray analysis, profound approximal caries and apical osseitis were diagnosed. Furthermore, the existing cervical filling showed an insufficient marginal seal (Fig. 1). The neighbouring teeth #12, 11 and 22 had already been treated with ceramic crowns.

Tooth #13 first received endodontic treatment in several sessions. After all signs of inflammation had ceased, the root canal was permanently filled and a provisional crown placed in order to ensure a non-irritated state of the root-canal filling before placing the permanent crown.

Fig. 7 Situation directly after insertion of restoration and removal of retraction cord.

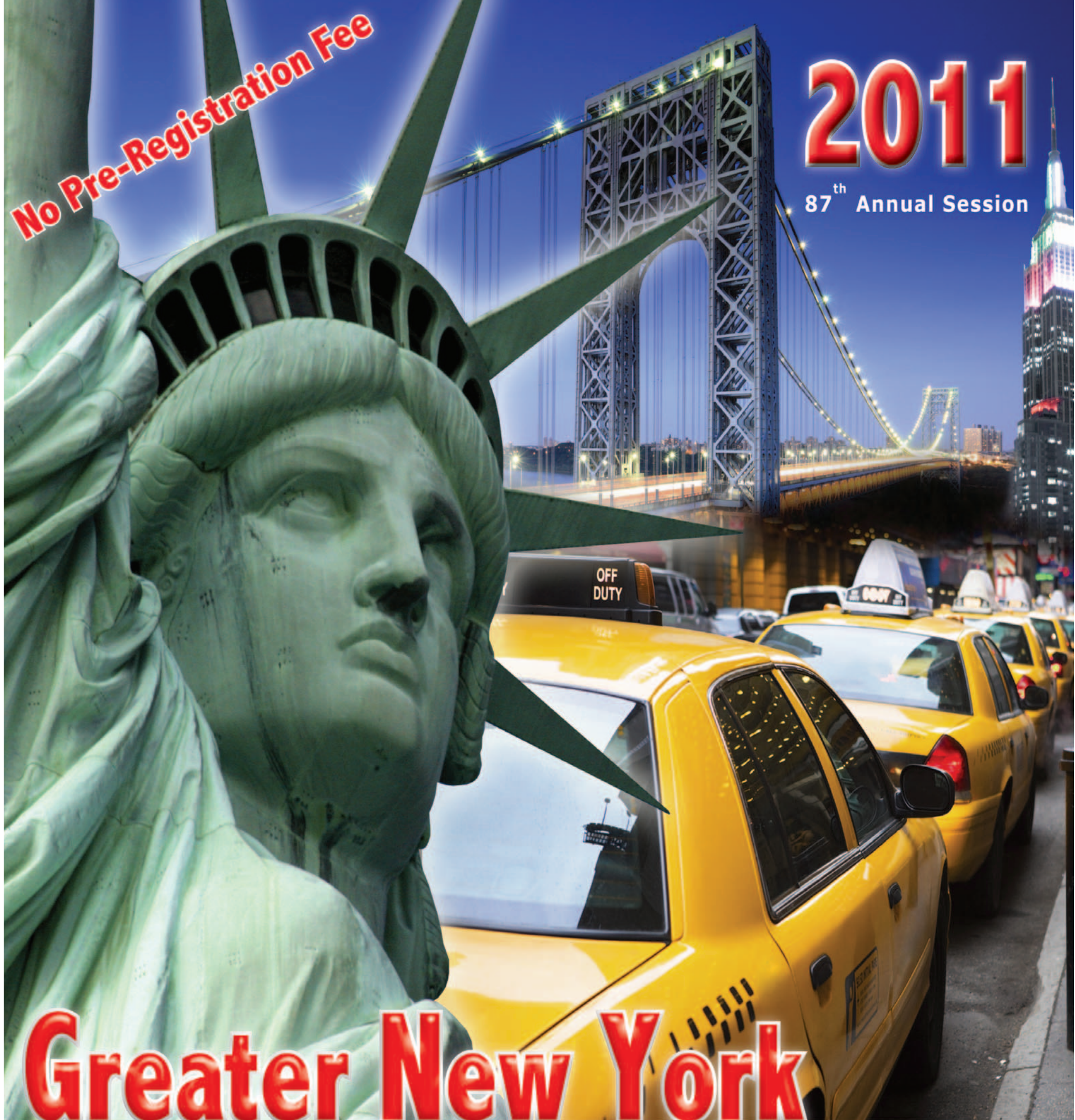


Prior to definitive stump preparation, the provisional distal and cervical crown parts received adhesive build-up fillings. For the restoration, we used the universal composites CLEARFIL MAJESTY Esthetic and CLEARFIL MAJESTY Flow. The self-etching, two-step adhesive CLEARFIL SE BOND was used for the adhesive pre-treatment of the dentine. The preparation was completed and the colour of the crown defined using a VITA shade guide.

The impression was taken as a one-step, putty-wash impression. Tooth #13 received a temporary crown until the ceramic crown was inserted. The temporary crown on tooth #13 was removed and the core thoroughly cleaned directly before the crown was inserted. A retraction cord was used in order to ease the insertion of the crown, as well as for contamination control purposes.

The gingiva appeared to be free of any irritation, the resin core was free of any clefts and the preparation margin was exactly and clearly defined (Fig. 2). An IPS e.max Press (Ivoclar Vivadent) crown was provided by the laboratory ready to use (Fig. 3). Try-in showed that the fit was good so that the crown could be inserted permanently. The crown was cleaned and treated according to manufacturer's instruction. The stump was cleaned with water and any excess water removed (Fig. 2).

After fitting the mixing tip, CLEARFIL SA CEMENT in Universal (A2) was directly applied into the crown with the Automix syringe (Fig. 3). CLEARFIL SA CEMENT is supplied bubble free in the container. Ideally, the mixing tip of the Automix syringe should remain in the cement during application in order to avoid incorporating any air bubbles. After application of the cement into the restoration, the dentist has one minute of working time in which to insert the restoration. When cementing inlays, onlays or



No Pre-Registration Fee

2011

87th Annual Session

**Greater New York
Dental Meeting™**

Scientific Meeting:
Friday, November 25 -
Wednesday, November 30



Exhibits:
Sunday, November 27 -
Wednesday, November 30

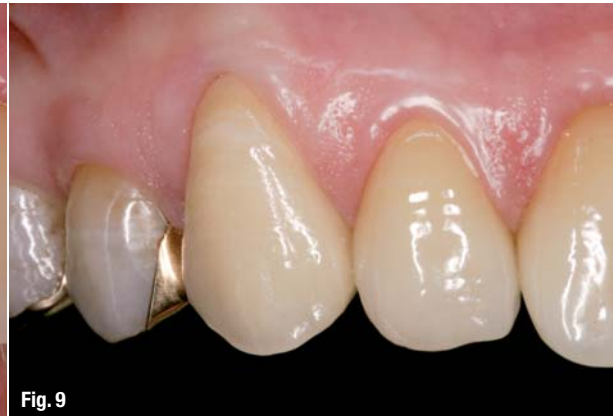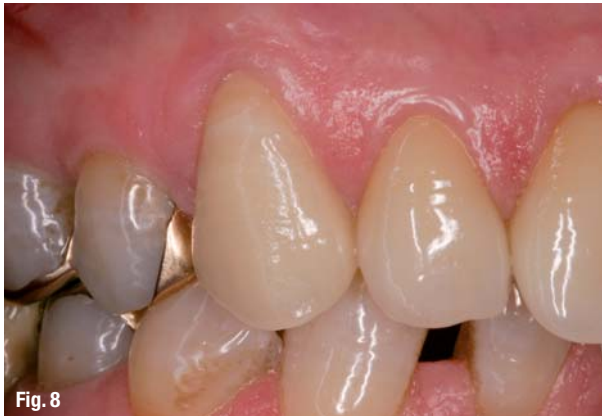The Largest Dental Meeting/Exhibition/Congress in the United States

root-canal posts, CLEARFIL SA CEMENT can also be applied directly into the cavity. Owing to the higher temperature in the oral cavity, the available working time is thus reduced to approximately 40 seconds.

The thixotropic properties of CLEARFIL SA CEMENT enable easy insertion and positioning into the final position, as the material flows under pressure (Fig. 4). Nevertheless, excess material will remain at the crown margin without flowing

_Summary

In the case described, IPS e.max Press, a lithium-disilicate glass-ceramic restoration, was inserted with the self-adhesive composite cement CLEARFIL SA CEMENT. This product is distinguished by its efficient Automix application and its dual polymerisation mechanism. The application of the material and the insertion of the restoration are made easier thanks to the thixotropic effect.



Figs. 8 & 9 One week after insertion of the ceramic crown on tooth #13 the gingiva appears to be free of irritation. The marginal fit is tight and the transition cannot be seen with the naked eye. The natural colour of the ceramic is not influenced by CLEARFIL SA CEMENT.

away and can be coagulated slightly by applying a polymerisation lamp for two to five seconds, depending on the lamp's power, so that it can be easily removed with an instrument, usually in one piece (Fig. 5). It is important that while removing the excess material, the crown be held fast in its final position.

For ceramic and composite crowns, light polymerisation occurs for 20 seconds from both sides after removal of excess material. As CLEARFIL SA CEMENT is dual-curing, the final chemical polymerisation of the areas that cannot be reached by light is achieved after five minutes, meaning that CLEARFIL SA CEMENT can also be used under metal restorations.

Cleaning of the approximal spaces with SuperFloss (Oral-B) and the removal of the retraction cord are carried out after complete light- and chemical curing (Fig. 6). CLEARFIL SA CEMENT ensures a tight marginal fit and does not influence the colour shade of the ceramic or composite restoration.

Figure 7 shows the completed restoration *in situ* directly after insertion and removal of the retraction cord. Figures 8 and 9 show the non-irritated state at one week after insertion of the prosthetic provision for tooth #13. The marginal fit is tight and the transition cannot be seen with the naked eye.

CLEARFIL SA CEMENT provides secure mechanical and chemical bonding to tooth structures and restorations. It can be used in many application areas ranging from metal, ceramic and composite restorations to root-canal posts. The thin layer of CLEARFIL SA CEMENT and low solubility ensure long-term prosthetic success.

_References

1. Iwamoto N, Uctasli S, Ikeda M, Nakajima M, Tagami J. Shear Bond Strength of New Self Adhesive Cement to Enamel and Dentin. International Symposium for Adhesive Dentistry 2008 in Kanazawa. Abstract #P-24.
2. Yamamoto H, Nakamura T, Wakabayashi K, Okada A, Kinuta S, Yatani H. Mechanical Properties of New Self-adhesive Resin Based Cement. International Symposium for Adhesive Dentistry 2008 in Kanazawa. Abstract #P-28.
3. Sadr A, Shimada Y, Tagami J. Micro leakage of Class-V Inlays using an Experimental Self-Adhesive Resin Cement. IADR Meeting in Toronto, 2008. Abstract #0404.

_contact

cosmetic
dentistry

Kuraray Europe GmbH

BU Medical Products
Hoechst Industrial Park/F 821
65926 Frankfurt/Main
Germany

dental@kuraray.eu
www.kuraray-dental.eu

The 30th Moscow International Dental Forum

Moscow 2011

The 30th Moscow International Dental Forum



Dental-Expo
international dental fair

September 26-29

Crocus Expo exhibition grounds

more than
450
exhibitors

more than
25000
attendees

more than
35
countries

www.dental-expo.com

DENTALEXPO[®]



Aesthetic restoration created with composite

Author_ Dr Anna Salat Vendrell, Spain

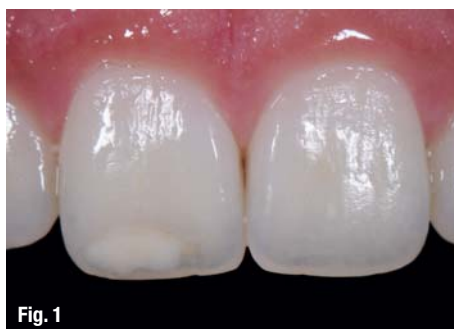

Fig. 1

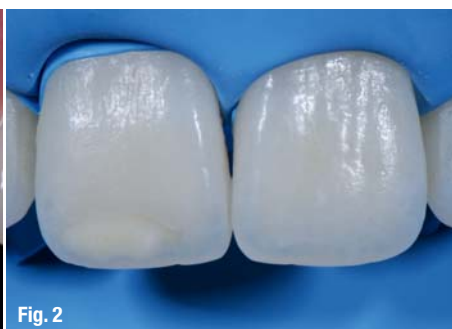

Fig. 2

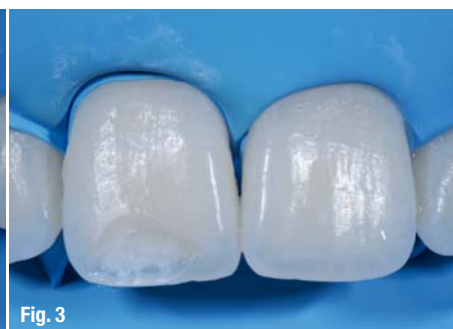

Fig. 3

Fig. 1_Pre-op situation.

Fig.2_Absolute isolation of the operating field with a rubber dam is the ideal form of moisture control.

Fig. 3_Preparation of a small circular chamfer.

The new generation of resin composite materials in combination with modern layering techniques allows today's practitioners to treat their patients with minimally invasive, highly aesthetic direct restorations. Owing to their enhanced properties, these materials produce results that are hardly distinguishable from natural dentition, especially with regard to colour, which is particularly desirable in anterior teeth.

The new composite IPS Empress Direct (Ivoclar Vivadent) enables us to create restorations that are almost invisible to the human eye. The appropriate increment technique together with correct handling of the materials and high-gloss polishing produces predictable, aesthetic results directly in the mouth. Owing to its nano-hybrid structure, the material can also be used to restore posterior teeth.

IPS Empress Direct materials are available in various levels of opacity, translucency and brightness. By combining the different materials, tooth-like light scattering can be achieved. The working

steps of the technique used to place IPS Empress Direct are described in this article.

Clinical case: Step-by-step restorative procedure

A young patient presented with a defective resin composite filling in tooth #11. The margin was no longer tight and the interface between the tooth structure and the restoration exhibited staining. What is more, the chroma, opalescence and shade of the filling did not correspond to that of the natural dentition (Fig. 1).

According to the treatment plan, the filling would be removed, the cavity prepared along minimally invasive principles and the tooth restored with a direct resin composite. In order to achieve impeccable integration of the restoration in the oral environment and an aesthetic smile line with a uniform colour, the composite would have to be placed using the increment technique. As the cavity had walls on all sides, there was no need to create a wax-up or a silicone template to restore

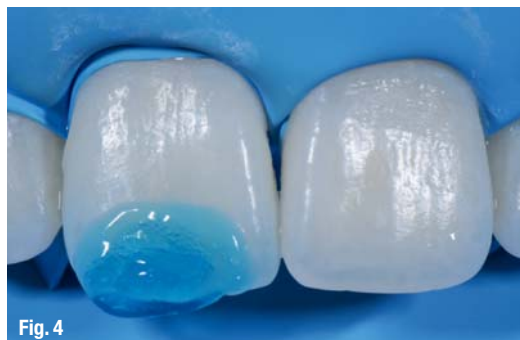

Fig. 4

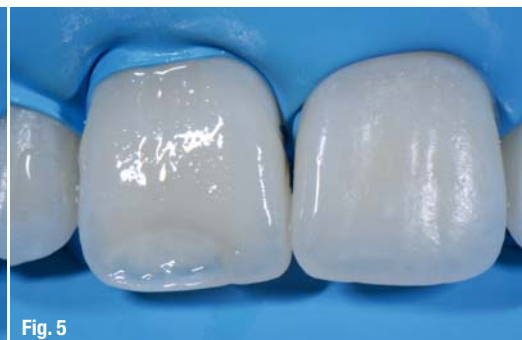

Fig. 5

Fig. 4_Etching with 37% phosphoric acid.

Fig. 5_Application of the adhesive.

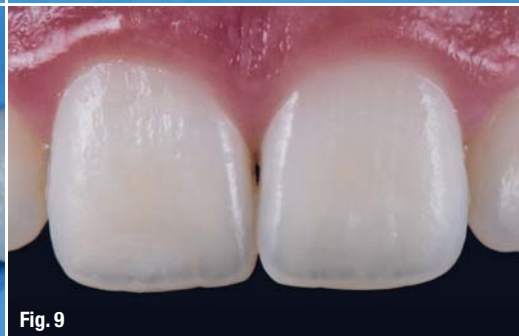
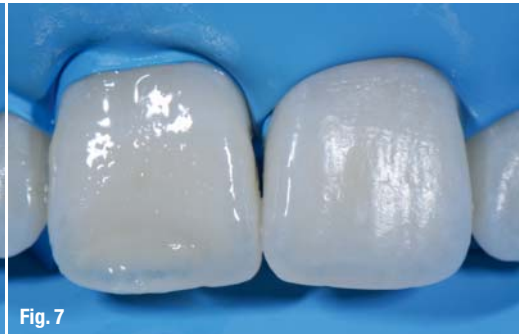
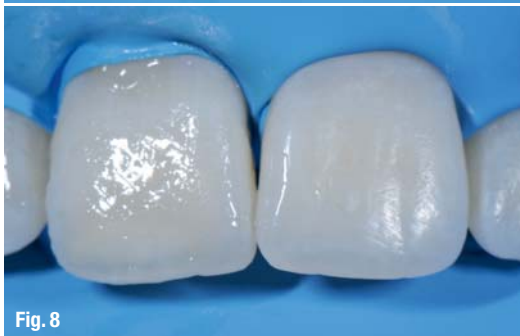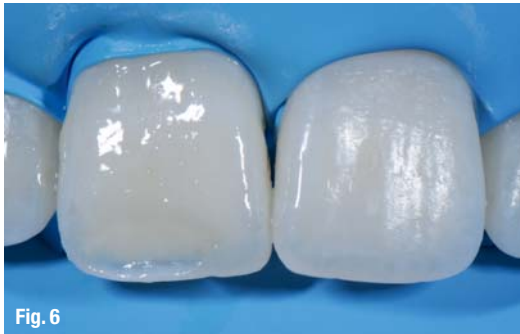Fig. 6 Application of the dentine material in the appropriate shade, that is, the appropriate translucency/opacity.

Fig. 7 Application of the opalescent material in the enamel part of the tooth.

Fig. 8 Application of the enamel material on the entire facial part of the restoration.

Fig. 9 Restoration one week after it was placed.

the tooth shape. A layering scheme was established before the treatment was begun.

During the dental examination, the general preoperative situation, the natural colour of the patient's teeth and individual characteristics were photographically documented. The layering scheme was prepared on the basis of the photographs. The different materials that would be used for the restoration were established in the process. In order to reproduce the special characteristics of the patient's tooth anatomy, the appropriate dentine and enamel shades were selected along with an opalescent material and a white-opaque material (from the IPS Empress Direct range).

At a second appointment, the operating field was isolated with a rubber dam, since absolute moisture control is indispensable in the placement of resin composites (Fig. 2). The outer margins of the old filling were traced with a pencil. This was done to highlight the transition between the filling and the tooth structure in the removal of the old filling. A small chamfer was prepared on the vestibular side, as this is indicated for this type of restoration (Fig. 3). Next, the enamel and dentine were etched with 37% phosphoric acid (Total Etch) and a three-component adhesive (Syntac) was applied (Figs. 4 & 5).

In order to obtain the desired tooth shade, the dentine part of the restoration was built up first with dentine material (IPS Empress Direct Dentin A2; Fig. 6). A translucent and opalescent material (Trans Opal from the IPS Empress Direct range) was used to build up the enamel part (Fig. 7). Thin white-

opaque strips (IPS Empress Direct Bleach XL) were applied over the dentine segment to enhance the brightness. Finally, an appropriately shaded enamel material (IPS Empress Direct Enamel A2) was placed over the entire facial surface of the restoration to cover all the previously placed materials (Fig. 8). The creation of surface texture as well as finishing and polishing are important working steps in imparting a restoration with a true-to-nature appearance. As a result, they have to be given due attention. In the present case, the surface texture was created with diamond burs at low speed. This allowed the procedure to be precisely controlled. A three-step silicone polishing system (Astropol) was used to finish and polish the restoration. Finally, the restoration was polished to a high gloss finish using aluminium oxide, diamond pastes (Shiny System, Micerium), brushes and felt wheels.

It is worthwhile recalling the patient for a third appointment to ensure that the restoration blends into the natural environment when the tooth is moist and to establish whether any shape or colour adjustments need to be made (Fig. 9).

_contact

**cosmetic
dentistry**



Dr Anna Salat Vendrell
C/ Frederic Corominas nº 48
Torrelles de Llobregat
08629 Barcelona
Spain
annasalat@hotmail.com

Class II fillings in everyday clinical work

Author _ Dr Sylvain Mareschi, France

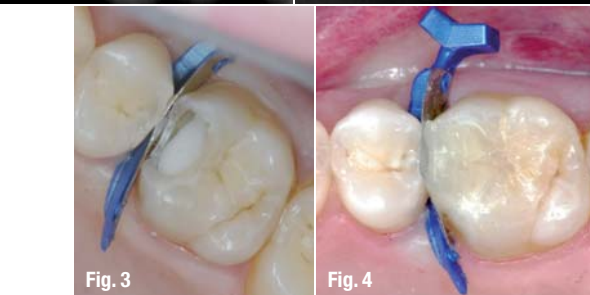
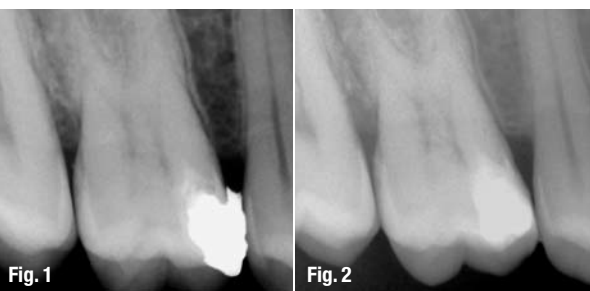
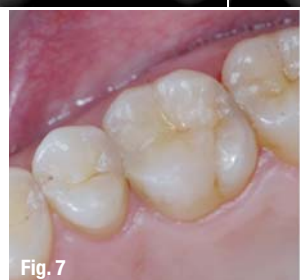
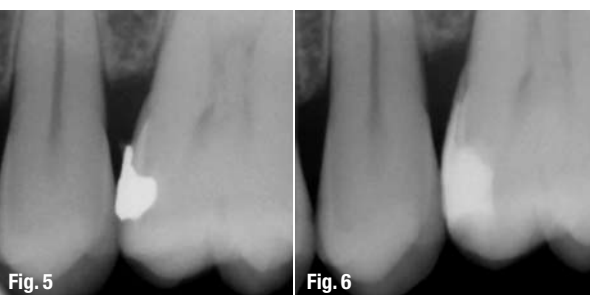Fig. 1 _ Previous amalgam filling.
Fig. 2 _ Composite filling.
Fig. 3 _ FenderMate matrix in place.
Fig. 4 _ Filling before initial polish.

Fig. 5 _ Previous amalgam restoration.
Fig. 6 _ Class II composite restoration.
Fig. 7 _ Completed restoration.



_Making proximal cavity fillings requires a rigorous clinical procedure that must be easily reproducible. The aim is to obtain a dental morphology that reconstructs a tight contact point and avoids future food impaction. Another very important goal is respecting the anatomy and physiology of the patients' interdental papillae, as well as guaranteeing the balance and integrity of the proximal space.

_Compression of the papillae

It is much more difficult to obtain a good contact point with composite compared to amalgam because of the way composite material needs to be light-cured. If the proximal matrix does not have a good adaptation to the tooth, then too much compression on the composite filling material will result in cervical overhang. This in turn will compress the interdental papillae and may cause periodontal damage to the patient's tooth (Figs. 1 & 2).

_The matrix

It is easy to understand the importance of the role of the matrix both in forming the filling proximally and channelling the filling material to the correct position. Directa's FenderMate matrix perfectly

fulfils the clinical needs of completing Class II cavities (Figs. 3 & 4). The concept of a steel plate and plastic interdental wedge in one piece was initially introduced by Directa in the concept of FenderWedge, a device for protecting the adjacent tooth during preparation, and replicated under the name FenderMate as a matrix system. The aim is to facilitate the insertion of a wedge and an anatomically adapted matrix at the same time.

The matrix can be removed in two stages. The interdental wedge, which separates from the steel matrix, can be taken out first and the steel matrix can then be removed next. The matrices are available in two sizes—narrow and regular—and for right and left application. They are colour-coded—green and blue—for ease of identification. FenderMate may be applied either buccally or lingually.


_The contact point

The interdental wedge with a flexible wing keeps the lower part of the matrix in contact with the cervical walls of the cavity. This causes a slight separation of the teeth so that when the filling is made, it is slightly larger than usual in the proximal direction. Once the matrix has been removed, the patient's teeth will return to their natural position, assuring tight contact between the proximal spaces with the adjacent tooth.

The matrix's convex shape positions the interdental contact point in the highest third of the tooth and creates a papillary play compatible with the physiology and the natural interdental space for cleaning. The curved shape of the combined matrix and interdental wedge forms the matrix around the buccal and lingual limits of the cavity box, and the pre-shaped contact former creates a natural contact point on the patient's tooth (Figs. 5–7).

Editorial note: This article was first published in DENTOSCOPE 58/10, 2009.

_contact	cosmetic dentistry
<p>Directa AB Box 723 194 27 Upplands Väsby Sweden</p> <p>info@directadental.com www.directadental.com</p>	



WWW.SINODENT.COM.CN

SINO-DENTAL 2011

June 9-12, 2011

China National Convention Centre Beijing

Joint Organizers

International Health Exchange and Cooperation Centre,
Ministry of Health, P. R. China
Chinese Stomatological Association
Beijing University School of Stomatology

Supporter

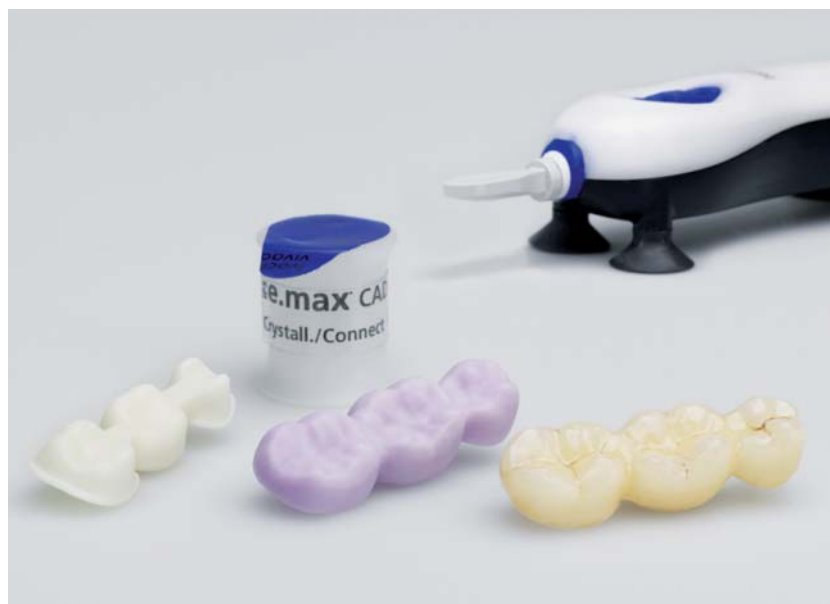Ministry of Health, P.R. China

Contact: Ms.Sunny Ms. Carol
Tel: (86)10-88393922/3923/3929/3917
E-Mail: info@sinodent.com.cn

www.sinodent.com.cn

Biggest Dental Show in China

Lithium disilicate meets zirconium oxide



The IPS e.max CAD-on technique. Front: IPS e.max CAD superstructure, IPS e.max ZirCAD framework and the completed IPS e.max CAD-on bridge restoration. Centre: IPS e.max CAD Crystall/Connect fusion glass-ceramic. Back: Ivomix vibrator unit.

The IPS e.max CAD-on technique allows dental laboratories to utilise lithium-disilicate glass-ceramics in the fabrication of high-strength, zirconium-based bridges.

What makes the new CAD/CAM-based processing technique IPS e.max CAD-on so special is that it involves a combination of lithium disilicate and zirconium oxide. The lithium-disilicate glass-ceramic IPS e.max CAD offers high strength and aesthetics. It has already been used successfully for the fabrication of single-tooth restorations such as monolithic crowns.

IPS e.max ZirCAD zirconium oxide is used to create high-strength frameworks, primarily for bridge restorations. By means of the IPS e.max CAD-on technique, three- to four-unit posterior bridges that consist of aesthetic, high-strength lithium-disilicate superstructures on a zirconium-oxide framework can be produced.

The production procedure

The CAD-on technique involves the fabrication of two components: a zirconium-oxide

framework made of IPS e.max ZirCAD and a lithium-disilicate superstructure made of IPS e.max CAD. Both parts are designed using the new and intuitive inLab V3.80 software from Sirona and milled with the Sirona inLab MC-XL unit.

The IPS e.max ZirCAD framework is then subjected to a quick sintering process in the Programat S1. Subsequently, a homogeneous all-ceramic bond between the two individually milled parts is established by means of an innovative fusion glass-ceramic that has been developed especially for the purpose. The fusion process occurs simultaneously with the crystallisation of IPS e.max CAD.

Treatment goals are reached more quickly and efficiently

IPS e.max CAD-on takes the fabrication of tooth- or implant-borne posterior bridges to the next level with regard to efficiency and productivity. This new technique enables dental laboratories to create zirconium-based IPS e.max CAD restorations within a day and with little manual effort. The results leave nothing to be desired in terms of strength, economy and aesthetics.

The IPS e.max CAD-on technique can be used as an alternative to the layering or press-on technique. From this autumn, IPS e.max CAD blocks and accessories for the IPS e.max CAD-on technique will be available worldwide.

_contact	cosmetic dentistry
<p>Ivoclar Vivadent AG Bendererstrasse 2 9494 Schaan Principality of Liechtenstein</p> <p>info@ivoclarvivadent.com www.ivoclarvivadent.com</p>	

Dentech China 2011

www.dentech.com.cn

The 15th China Int'l Exhibition & Symposium on Dental Equipment, Technology & Products

The 5th Asian Dental Lab Outsourcing Exhibition

October 26~29, 2011

The Expo Theme Pavilion, Shanghai, China



Approved by: Ministry of Science and Technology of the People's Republic of China

Sponsored by: China Association for Science and Technology / Chinese Stomatological Association / Shanghai Stomatological Association

Organized by: China International Conference Center for Science & Technology / Ninth People's Hospital, School of Medicine, Shanghai Jiao Tong University

Co-organized by: College of Stomatology, Shanghai Jiao Tong University / School of Stomatology, Tong Ji University /

Shanghai Stomatological Disease Center / Shanghai ShowStar Exhibition Service Co., Ltd.

If you are interested in participating or visiting the Exhibition, please fill the form below and fax or post to: Shanghai ShowStar Exhibition Service Co., Ltd.

Room 22C/D, Jiali Mansion, No. 1228, Yan'an Road (W), Shanghai 200052, China

Tel: 86-21-6294 6966 / 6294 6967 / 6294 6968. Fax: 86-21-6280 0908. E-mail: mail@showstar.net

I am interested in DenTech China 2011, please send me more information on

EXHIBITING

VISITING

Name _____ Company _____

Address _____

Telephone _____ Fax _____

Zip _____ E-mail _____



International Events

2011

IADR General Session & Exhibition

San Diego, CA, USA
16–19 March 2011
www.iadr.org

International Dental Show

Cologne, Germany
22–26 March 2011
www.ids-cologne.de

ACE Tampa 2011 Conference on Social Media & Marketing for Dentistry

Tampa, FL, USA
1 & 2 April 2011
www.acesthetics.com

CAD/CAM & Computerized Dentistry International Conference

Dubai, UAE
12 & 13 May 2011
www.cappmea.com

AACD Boston 2011

Boston, MA, USA
18–21 May 2011
www.aacd.com

EAED Spring Meeting

Istanbul, Turkey
2–4 June 2011
www.eaed.org

IACA 2011

San Diego, CA, USA
28–30 July 2011
www.theiaca.com

AAED Annual Meeting

San Juan, Puerto Rico
2–5 August 2011
www.estheticacademy.org

FDI Annual World Dental Congress

Mexico City, Mexico
14–17 September 2011
www.fdiworldental.org

IFED World Congress

Rio de Janeiro, Brazil
21–24 September 2011
www.ifed.org

Dental–Facial Cosmetic International Conference

Dubai, UAE
27 & 28 October 2011
www.cappmea.com



submission guidelines:

Please note that all the textual components of your submission must be combined into one MS Word document. Please do not submit multiple files for each of these items:

- _ the complete article;
- _ all the image (tables, charts, photographs, etc.) captions;
- _ the complete list of sources consulted; and
- _ the author or contact information (biographical sketch, mailing address, e-mail address, etc.).

In addition, images must not be embedded into the MS Word document. All images must be submitted separately, and details about such submission follow below under image requirements.

Text length

Article lengths can vary greatly—from 1,500 to 5,500 words—depending on the subject matter. Our approach is that if you need more or less words to do the topic justice, then please make the article as long or as short as necessary.

We can run an unusually long article in multiple parts, but this usually entails a topic for which each part can stand alone because it contains so much information.

In short, we do not want to limit you in terms of article length, so please use the word count above as a general guideline and if you have specific questions, please do not hesitate to contact us.

Text formatting

We also ask that you forego any special formatting beyond the use of italics and boldface. If you would like to emphasise certain words within the text, please only use italics (do not use underlining or a larger font size). Boldface is reserved for article headers. Please do not use underlining.

Please use single spacing and make sure that the text is left justified. Please do not centre text on the page. Do not indent paragraphs, rather place a blank line between paragraphs. Please do not add tab stops.

Should you require a special layout, please let the word processing programme you are using help you do this formatting automatically. Similarly, should you need to make a list, or add footnotes or endnotes, please let the word processing programme do it for you automatically. There are menus in every programme that will enable you to do so. The fact is that no matter how carefully done, errors can creep in when you try to number footnotes yourself.

Any formatting contrary to stated above will require us to remove such formatting before layout, which is very time-consuming. Please consider this when formatting your document.

Image requirements

Please number images consecutively throughout the article by using a new number for each image. If it is imperative that certain images are grouped together, then use lowercase letters to designate these in a group (for example, 2a, 2b, 2c).

Please place image references in your article wherever they are appropriate, whether in the middle or at the end of a sentence. If you do not directly refer to the image, place the reference at the end of the sentence to which it relates enclosed within brackets and before the period.

In addition, please note:

- _ We require images in TIF or JPEG format.
- _ These images must be no smaller than 6x6 cm in size at 300 DPI.
- _ These image files must be no smaller than 80 KB in size (or they will print the size of a postage stamp!).

Larger image files are always better, and those approximately the size of 1 MB are best. Thus, do not size large image files down to meet our requirements but send us the largest files available. (The larger the starting image is in terms of bytes, the more leeway the designer has for resizing the image in order to fill up more space should there be room available.)

Also, please remember that images must not be embedded into the body of the article submitted. Images must be submitted separately to the textual submission.

You may submit images via e-mail, via our FTP server or post a CD containing your images directly to us (please contact us for the mailing address, as this will depend upon the country from which you will be mailing).

Please also send us a head shot of yourself that is in accordance with the requirements stated above so that it can be printed with your article.

Abstracts

An abstract of your article is not required.

Author or contact information

The author's contact information and a head shot of the author are included at the end of every article. Please note the exact information you would like to appear in this section and format it according to the requirements stated above. A short biographical sketch may precede the contact information if you provide us with the necessary information (60 words or less).

Questions?

Claudia Salwiczek (Managing Editor)
c.salwiczek@oemus-media.de

cosmetic dentistry _ beauty & science

Publisher

Torsten R. Oemus
oemus@oemus-media.de

CEO

Ingolf Döbbecke
doebbecke@oemus-media.de

Members of the Board

Jürgen Isbaner
isbaner@oemus-media.de

Lutz V. Hiller
hiller@oemus-media.de

Editor-in-Chief

Dr Sushil Koirala
skoirala@wlink.com.np

Co-Editor-in-Chief

Dr So-Ran Kwon
smileksr@hotmail.com

Managing Editor

Claudia Salwiczek
c.salwiczek@oemus-media.de

Executive Producer

Gernot Meyer
meyer@oemus-media.de

Designer

Franziska Dachsel
f.dachsel@oemus-media.de

Copy Editors

Sabrina Raaff
Hans Motschmann

Published by

Oemus Media AG
Holbeinstraße 29
04229 Leipzig, Germany
Tel.: +49-341/4 84 74-0
Fax: +49-341/4 84 74-2 90
kontakt@oemus-media.de
www.oemus.com

Printed by

Messedruck Leipzig GmbH
An der Hebemärchte 6
04316 Leipzig, Germany

Advisory Board

Dr Michael Miller, USA
Dr Seok-Hoon Ko, Korea

Editorial Board

Dr Anthony Au, Australia
Dr Bao Baicheng, China
Dr Helena Lee, Singapore
Dr Hisashi Hisamitsu, Japan
Dr Jiraporn Charudilaka, Thailand
Dr Mostaque H. Sattar, Bangladesh
Dr Ratnadeep Patil, India
Dr Sim Tang Eng, Malaysia
Dr Suhit Raj Adhikari, Nepal
Dr Takashi Nakamura, Japan
Dr Vijayaratnam Vijayakumaran, Sri Lanka



Claudia Salwiczek, Managing Editor

cosmetic
dentistry _ beauty & science
is the official publication of:

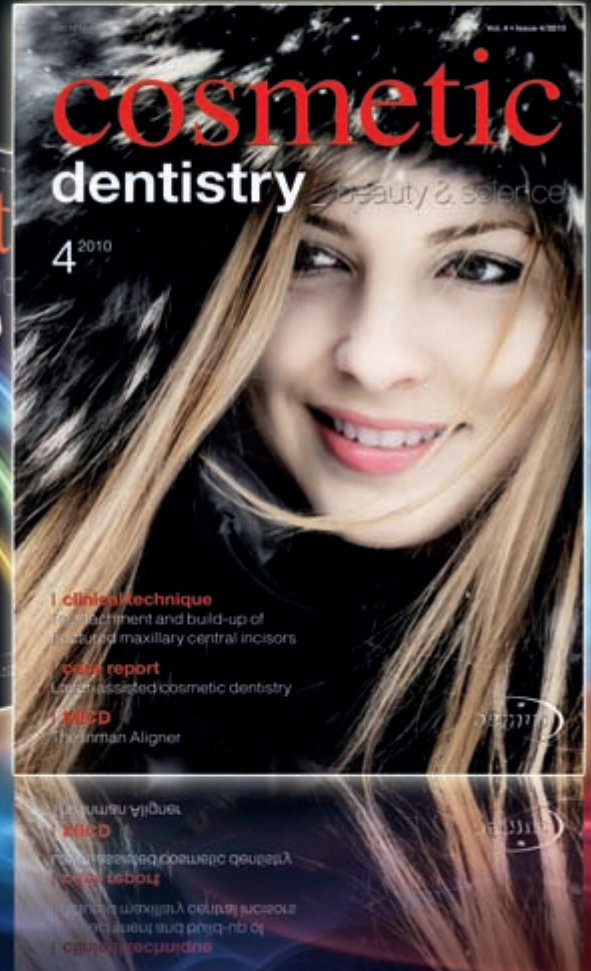
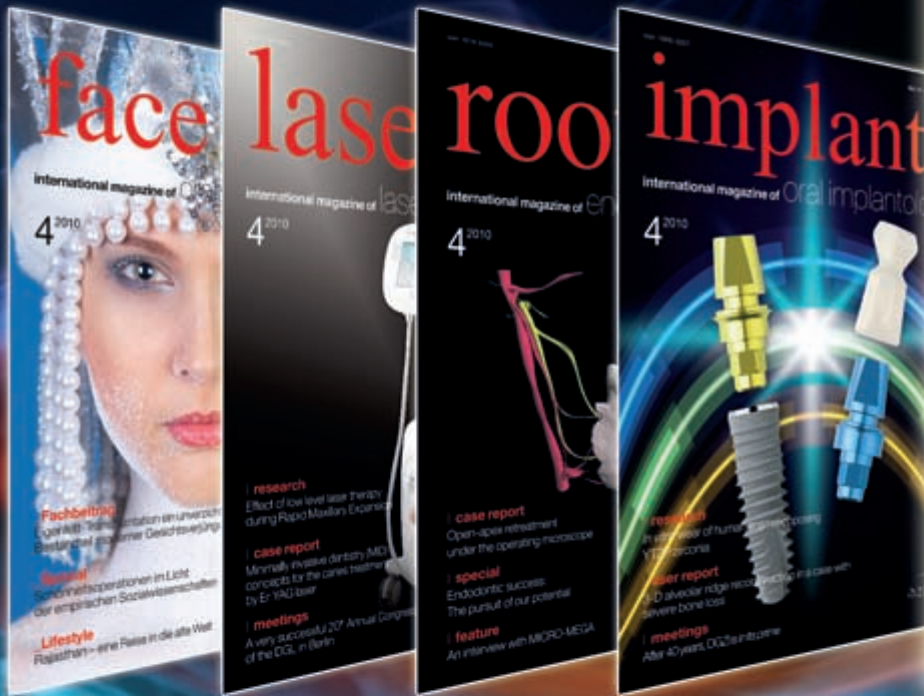
Copyright Regulations

cosmetic dentistry beauty & science is published by Oemus Media AG and will appear in 2011 with one issue every quarter. The magazine and all articles and illustrations therein are protected by copyright. Any utilisation without the prior consent of editor and publisher is inadmissible and liable to prosecution. This applies in particular to duplicate copies, translations, microfilms, and storage and processing in electronic systems.

Reproductions, including extracts, may only be made with the permission of the publisher. Given no statement to the contrary, any submissions to the editorial department are understood to be in agreement with a full or partial publishing of said submission. The editorial department reserves the right to check all submitted articles for formal errors and factual authority, and to make amendments if necessary. No responsibility shall be taken for unsolicited books and manuscripts. Articles bearing symbols other than that of the editorial department, or which are distinguished by the name of the author, represent the opinion of the afore-mentioned, and do not have to comply with the views of Oemus Media AG. Responsibility for such articles shall be borne by the author. Responsibility for advertisements and other specially labeled items shall not be borne by the editorial department. Likewise, no responsibility shall be assumed for information published about associations, companies and commercial markets. All cases of consequential liability arising from inaccurate or faulty representation are excluded. General terms and conditions apply, legal venue is Leipzig, Germany.

cosmetic dentistry _ beauty & science



You can also subscribe via
www.oemus.com/abo

 **Subscribe now!**

I would like to subscribe to **cosmetic dentistry** for € 44 including shipping and VAT for German customers, € 46 including shipping and VAT for customers outside Germany, unless a written cancellation is sent within 14 days of the receipt of the trial subscription. The subscription will be renewed automatically every year until a written cancellation is sent to OEMUS MEDIA AG, Holbeinstr. 29, 04229 Leipzig, Germany, six weeks prior to the renewal date.

▶ **Reply** via Fax +49 341 48474-290
or via E-mail to grasse@oemus-media.de

Last Name, First Name	
Company	
Street	
ZIP/City/County	
E-mail	Signature

Notice of revocation: I am able to revoke the subscription within 14 days after my order by sending a written cancellation to OEMUS MEDIA AG, Holbeinstr. 29, 04229 Leipzig, Germany.

Signature





BEAUTY – COMPOSE IT!

Highly aesthetic restorative

- Two simple steps
- Layers like in nature
- Brilliant results



Please visit us at
Cologne
22.-26.03.2011
Stand R8/S9 + P10, Hall 10.2

A M A R I S



Now also available
in gingiva shades