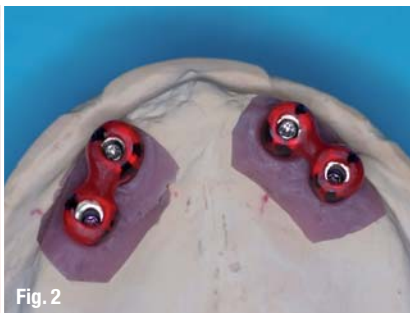
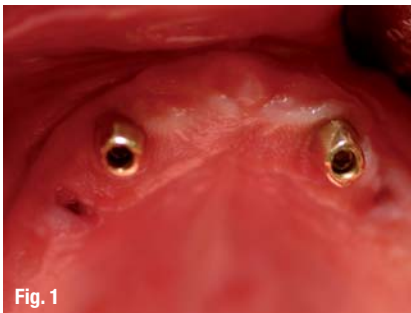
Implant-prosthetic troubleshooting

When dental technicians and dentists break into a sweat!

Authors _Dr Georg Bach & Christian Müller, Germany



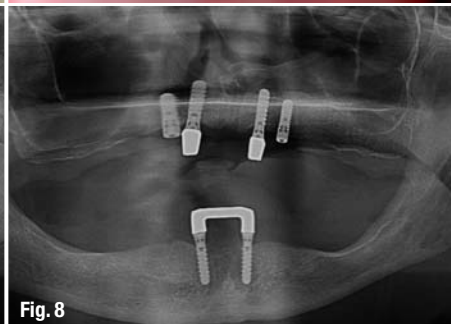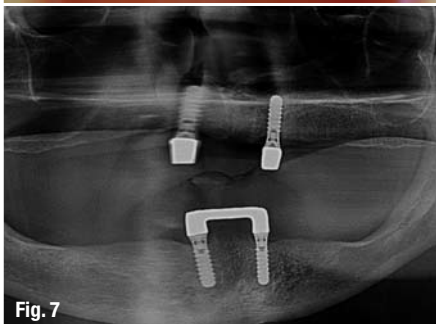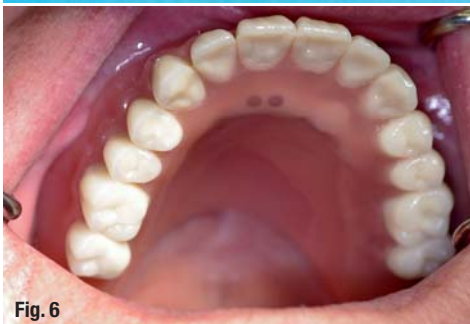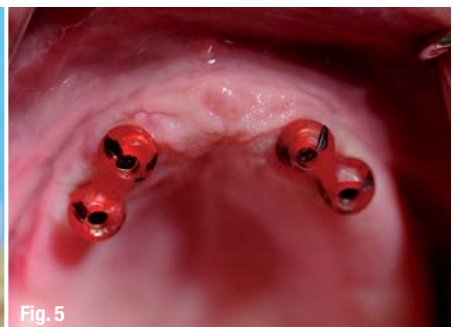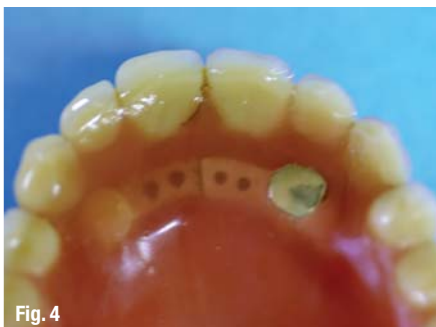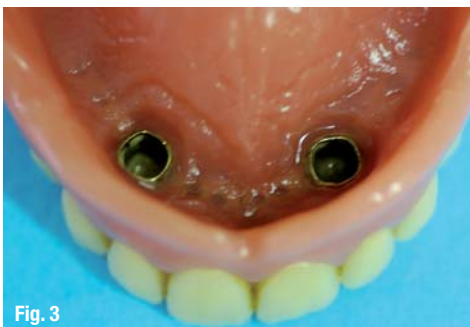Unidentified jaw misalignment
Figs. 1–4 The former prosthesis (with two maxillary implants); note the discrepancy between the translucent templates and the axis of the plastic front teeth.

_Implant-prosthetic troubleshooting usually starts at an advanced stage of the implant-prosthetic treatment, i.e. when implants have already been inserted, and the next step is the insertion of prostheses on the artificial abutment teeth. This point in time is extremely un-

favourable for several reasons, one being that—owing to the already completed surgical phase—there is no opportunity for intervention and modification of the implant placement, and the other reason being that the patient feels he or she is on the verge of a successfully completed treatment and does not realise that difficulties may now arise, which in extreme cases could result in failure of the entire treatment. This development usually ends in mutual accusations and forensic disputes.

_"Incorruptible"—The dental master model

In a worst-case scenario, it will not become apparent that the inserted implants cannot be



treated dentally, or only with extreme difficulty, owing to unfavourable placement in the jawbone until the dental master model has been created by the dental technician after casting or after the check-bite at the very latest.

"Plaster is incorruptible!". This conclusion, attributed to Freiburg dental surgeon Prof Eschler, was deliberately kept trivial; however, it is simply and utterly true. The dental master model shows the realities concerning placement of the implant, its axis, also with regard to abutment teeth, and the transition to the gingiva.

Exemplary patient cases

Our report will demonstrate, based on a few exemplary patient cases, the solution possibilities, but also the limits of implant-prosthetic troubleshooting—especially in terms of achieving a sustainable result for patient, dentist and dental technician.

Unidentified jaw misalignment (Figs. 1–8)

The problem

Two years ago, a male patient (in his mid-70s) had received two implants in the maxilla, followed by treatment with telescopes and a partial prosthesis. The patient stated that "the work did not agree with him right from the start".

Aside from functional problems, he disliked the fact that the maxillary front teeth were not visible even when he opened his mouth half-way.

Just by looking at the maxillary prosthesis it was easy to notice the metal portions of the prosthesis, which were placed extremely palatally, showing through. An examination of the oral cavity revealed a considerable discrepancy between the implant placement and the axis of the plastic front teeth!

Our solution

A wax-up marked the beginning of the actual treatment. It was modified until the patient was satisfied with the placement of his teeth and his subsequent appearance. Based on the results of this treatment planning, we were able to determine which position and alignment would be required for two additional implants (distally of the existing ones).

This in turn resulted in the creation of a drilling template, which was used during the insertion of the two additional artificial abutment teeth. After osseointegration of these two implants in regions #14 and 24, the new partial prosthesis (now supported by four implants (two existing and two new ones) was produced and integrated step by step.

Aside from cases like the one mentioned above, which are usually the result of design errors and/or design flaws, there is additional, yet different implant-prosthetic troubleshooting—covering primarily implant fractures or failure of individual implants within an extensive supra-structure. This considerably smaller part of implant-prosthetic problem areas, as compared with the group of design errors mentioned above,

Figs. 5 & 6 After interdisciplinary planning between dental technician and dentist, two additional distally located implants were inserted; the four artificial abutment teeth each received a telescopic crown. We used individual insertion keys to facilitate incorporation of the telescopes.

Fig. 7 Initial X-ray image (panoramic tomography) with two implants (treated with telescopes) in the maxilla.

Fig. 8 Condition after the increase of abutment teeth in the maxilla, each inserted distally of the previous implants.

Loss of implant due to peri-implantitis

Fig. 9 The mesial abutment tooth of a bridge entirely supported by implants in the left maxilla was lost. After healing of the soft tissue, a further implant was inserted in a position as close as possible to the former implant position. The illustration shows the dental master model with the customised abutment.

Fig. 10 The former bridge structure was used as a customised "spoon" for the newly added implant so that a customised abutment could be created for the additional implant to be mounted distally (note the loss of vertical distance) for use in the existing restoration.

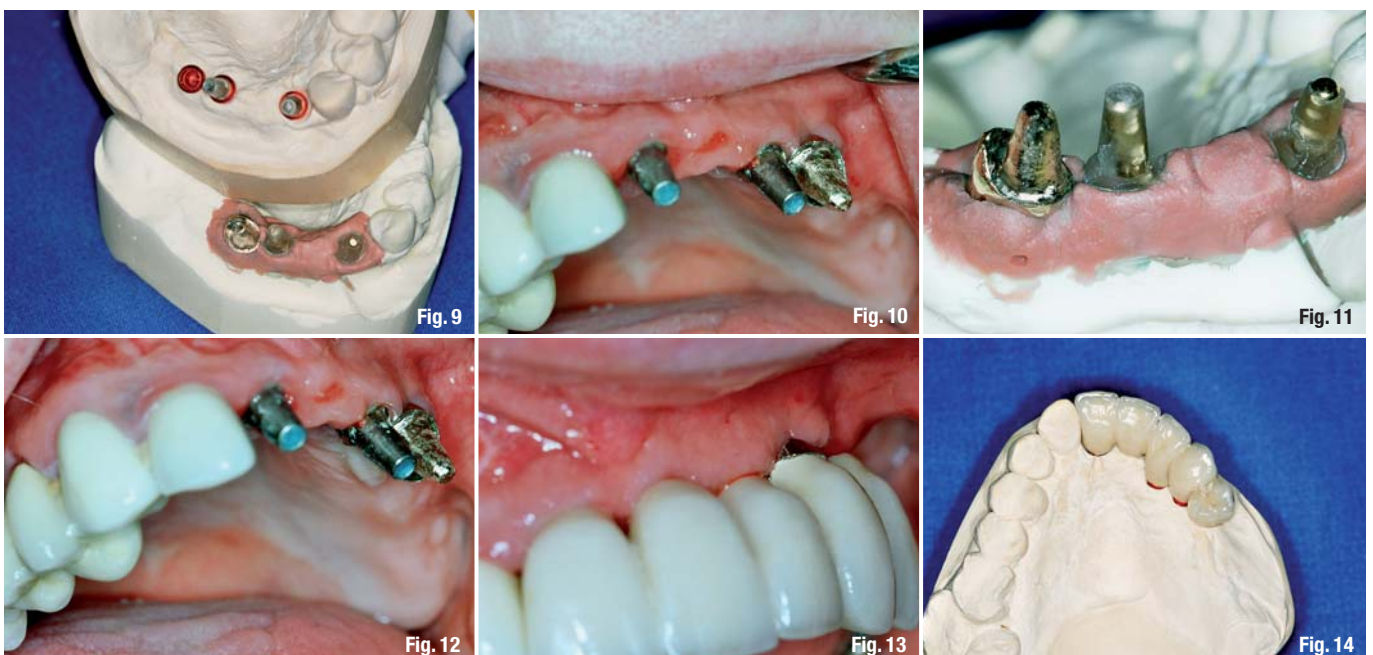

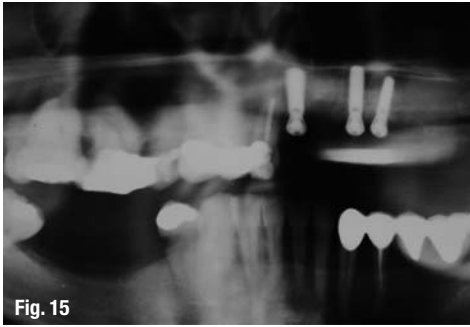


Fig. 15

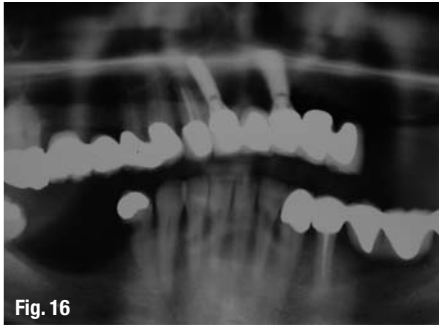


Fig. 16

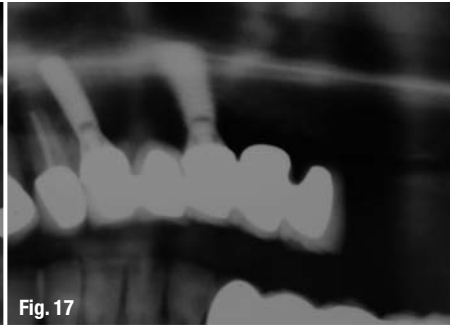

Fig. 17

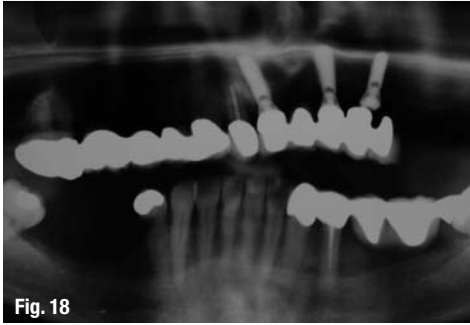


Fig. 18

Fig. 11_Customised abutment tooth as a terminal abutment.

Fig. 12_Patient's oral condition.

Figs. 13 & 14_We were able to preserve the bridge in the left maxilla.

Fig. 15_Three implants had originally been inserted to treat anodontia in the second quadrant.

Figs. 16 & 17_The distal implant was lost; the detailed view shows the non-functional crown #25.

Fig. 18_Condition after re-implantation distally of the implant localization.

Implant fracture

Fig. 19_The distal (diameter-reduced) implant of a bridge supported entirely by fractured implants.

Fig. 20_An additional implant was inserted distally after removal of the fragment that had remained in the bone. After integration of the implant, a new bridge supported entirely by implants was created, while incorporating the former implant.

will be covered and evaluated in this article. The purpose of this is to demonstrate solutions so that the patients affected receive a modified solution in order to preserve the existing and very expensive work.

_Loss of implant due to peri-implantitis
(Figs. 9–18)

A bridge structure in the second quadrant had been in place without any problems in a 50-year-old female patient for 10 years. Therefore, she only came to recall and follow-up examinations sporadically. The problem-free period ended abruptly when swelling and bite pain occurred in the left half of the maxilla. A panoramic tomography revealed radiological indications of a profound osseous defect around the mesial implant, which had to be removed on the same day. The issue then was the entire supra-structure. The patient insisted that this structure be preserved owing to the financial cost of having a new structure created after re-implantation.

Our solution

A new implant was inserted after the soft tissue and bone had healed in the area where the lost implant had previously been in place. The bridge structure that had been temporarily affixed on the remaining implant was used as guidance for incorporation of a replacement implant and then removed for the actual implant procedure.

After osseointegration of the artificial abutment tooth, we inserted a plastic abutment and made a casting of the integrated bridge structure with polyether casting material. This customised abutment was transformed into metal and the bridge structure finally cemented in place after a trial insertion.

_Implant fracture (Figs. 19 & 20)

Diameter-reduced implants can often be implanted even in a reduced osseous bed and aid in the avoidance of augmentations. However, when introduced into the market, diameter-reduced implants were frequently used for other indications as well; some authors even recommended using them as standard implants. Stress phenomena caused a considerable number of implant fractures, resulting in markedly restricted indications for diameter-reduced implants.

The case presented here reflects the typical progress of this early phase. A purely implant-supported (two abutments) extension bridge was incorporated into the fourth quadrant. A diameter-reduced implant was used in spite of an orovestibular bone dimension that would have been sufficient for supporting a standard implant. The result was that the distal implant fractured after eight years.

Our solution

In one surgical session, we removed both the implant fragment remaining in the bone by way of an osteotomy and placed a further distal im-

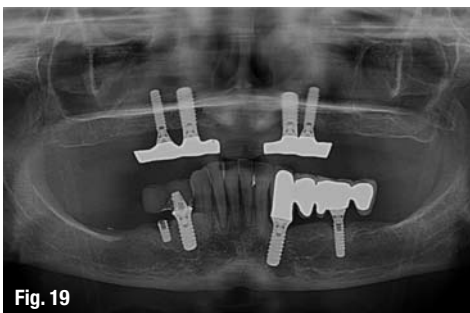

Fig. 19

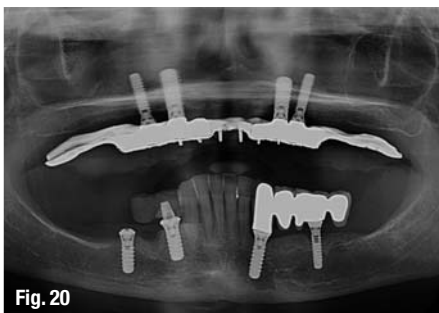

Fig. 20

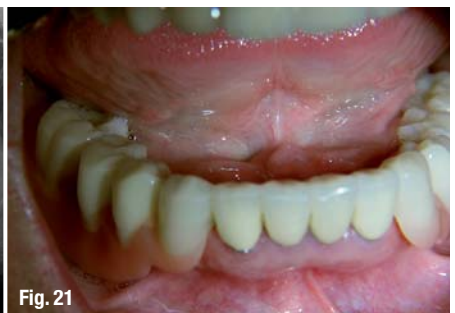

Fig. 21

ADVANCED TISSUE-MANAGEMENT

The easy way to aesthetics.

PARASORB Sombrero®

RESODONT®

PARASORB® HD Cone

GENTA-COLL® HD Cone



RESODONT®

- ▶ naturally cross-linked, with no chemical additives
- ▶ quick and easy to cut to size and apply, both sides can be used
- ▶ rapid integration in the surrounding tissue
- ▶ highest degree of product safety and excellent biocompatibility

PARASORB Sombrero®

- ▶ to cover and simultaneously fill the alveolus (socket preservation)
- ▶ offers a defined regeneration matrix
- ▶ formation of a stable bony implant bed after a relatively short time
- ▶ improved long-term aesthetic and functional results particularly in the anterior region

PARASORB® HD Cone GENTA-COLL® HD Cone

- ▶ rapid and safe haemostasis
- ▶ reduction of alveolar ridge atrophy
- ▶ optionally comes with antibiotic protection for high-risk patients (e.g. diabetics, smokers, immune-suppressed patients)

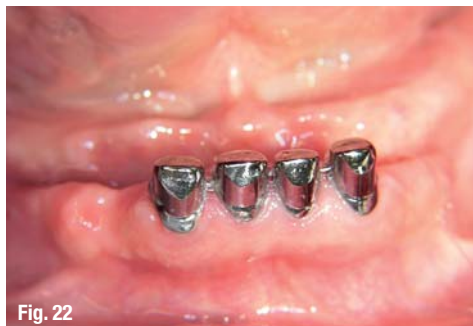

Fig. 22

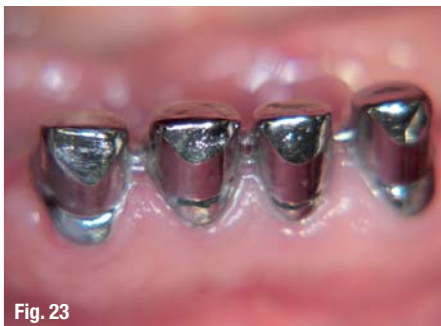

Fig. 23

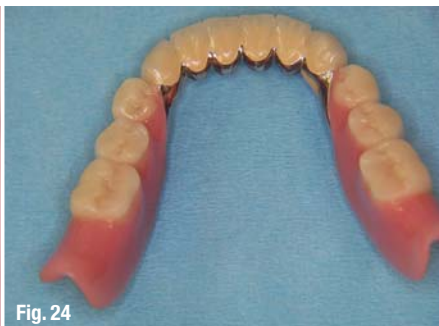

Fig. 24

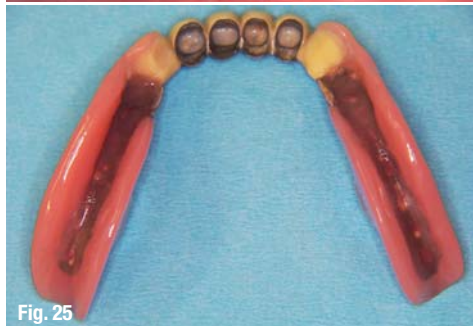

Fig. 25

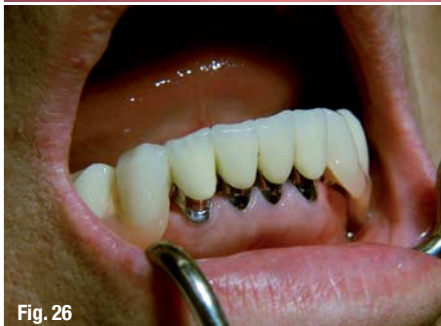

Fig. 26

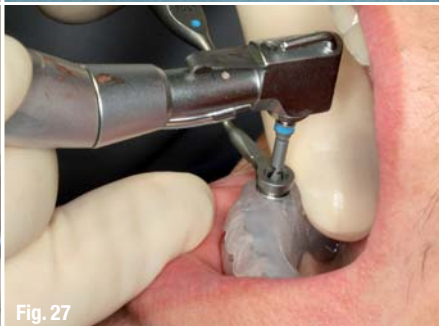

Fig. 27

The unsuccessful conventional solution

Figs. 21–25 Owing to the loss of prospective abutment teeth #43 and 33 during the prosthetic treatment phase, the remaining front teeth #42, 41, 31 and 32 received telescopic crowns.

Fig. 26 The partial prosthesis showed insufficient mounting.

Figs. 27–29 With the aid of 3-D imaging and planning, four implants were inserted in regions #46, 43, 33 and 36—without any augmentative treatment.

Fig. 30 After osseointegration of the artificial abutment teeth, two side-tooth bridges entirely supported by implants and four individual crowns were integrated with the remaining mandibular teeth.

plant. After its osseointegration, we incorporated a completely new bridge using the existing mesial implant.

The results achieved here can help us learn from design errors and select a different approach for future cases, so that we can also treat patients who have had failure of a comprehensive prosthetic restoration. Our last case will illustrate this situation.

The unsuccessful conventional treatment versus the successful, well-planned implantological procedure (Figs. 21–34)

Finally, we would like to present an unusual case: an unsuccessful conventional treatment that was replaced with implantological treatment carried out in close collaboration between the dentist and dental technician. The patient had experienced considerable complications during prosthetic treatment (the goal being a telescopic partial prosthesis supported by teeth

#43 and 33, while preserving the front teeth #42 to 32, which had been caries-free and without fillings until then, and replacement of teeth #47 to 44 and 34 to 37). First, tooth #33 fractured and had to be extracted, in spite of the fact that preparation and casting had already been done. Treatment was replanned after this event, and teeth #42, 41, 31 and 32 were also prepared (the goal being telescopic crowns). Shortly before implementation, tooth #43 also had to be extracted. The patient was unable to give the exact reasons for this. This left her with four teeth—#42, 41, 31 and 32—which all had telescopic crowns.

Anchoring of the partial prosthesis was poor; the patient was able to loosen it with minimal tongue-applied pressure. The pronounced tendency of the prosthesis saddles to cave in also resulted in complications in the form of multiple recurrent pressure sores. The patient was referred to us at this point. The reason for this according to her dentist was that implants, which the patient had inquired about, could be inserted

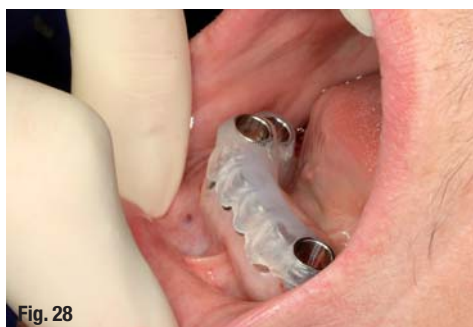

Fig. 28

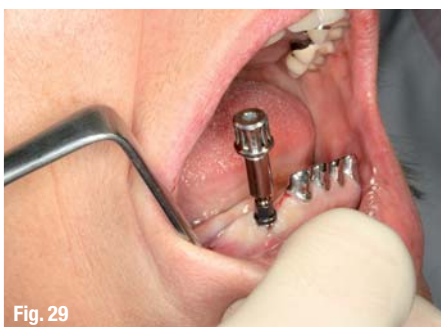

Fig. 29

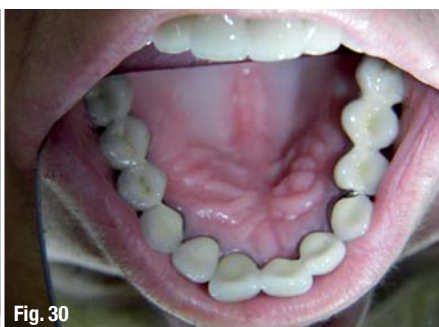

Fig. 30

neither in the extended front-tooth area nor in the side-tooth area owing to the narrow and atrophied alveolar ridge.

Our solution

It was true that the alveolar ridge on both sides, starting with the cuspid region and extending to the area where the molars had been previously, was fairly pointed, and the course of the osseous limbus alveolaris displayed a pro-

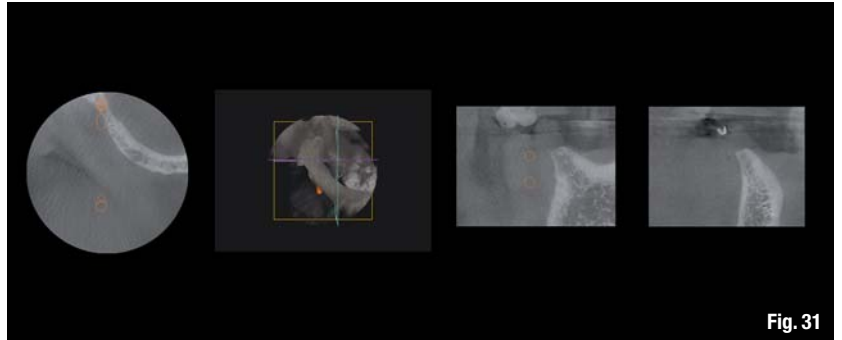


Fig. 31

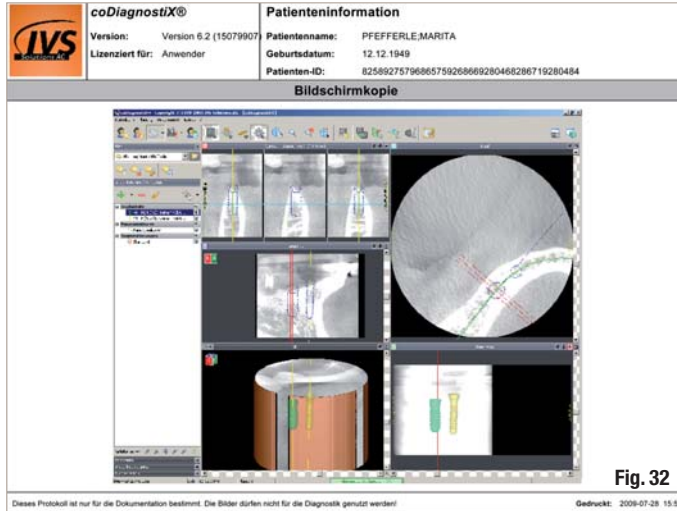


Fig. 32

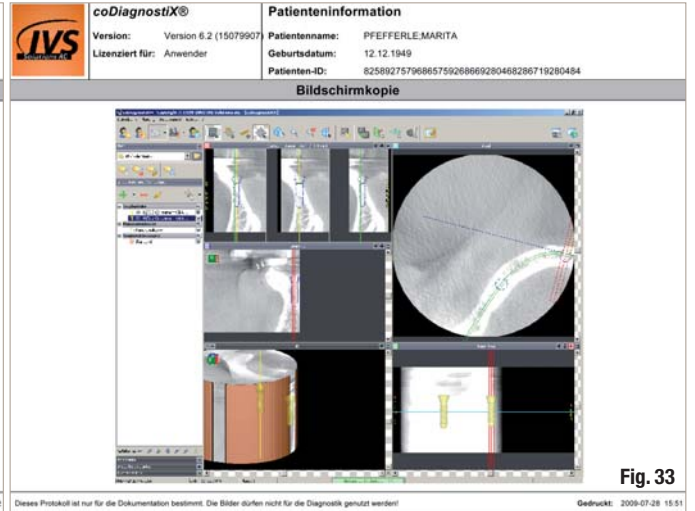


Fig. 33

nounced sagging distally of the previous pre-molar zone.

The patient thus showed considerable osseous deficits in both the oro-vestibular and horizontal dimension. In order to assess the basic possibilities of oral implants, we decided to perform 3-D imaging, which proved extremely helpful in this complex patient case. After illustration of the osseous situation, there were indications that implantation would be possible without carrying out augmentation procedures. We then prepared a virtual implant plan, the results of which led us to prepare a drilling template.

The remaining front teeth proved very helpful as a place for securely anchoring the template. By opting for a shortened row of teeth with one implant each in the region of the former six-year molars and an additional artificial abutment in each of the former cuspid areas, we were able to keep the dimensions of the template relatively small.

The insertion of four implants in the regions of teeth #46, 43, 33 and 36 and their osseointegration were followed by treatment with the supra-structures, which consisted of two bridges in regions #46 to 43 and 33 to 36, entirely supported by implants, and four individual crowns on the

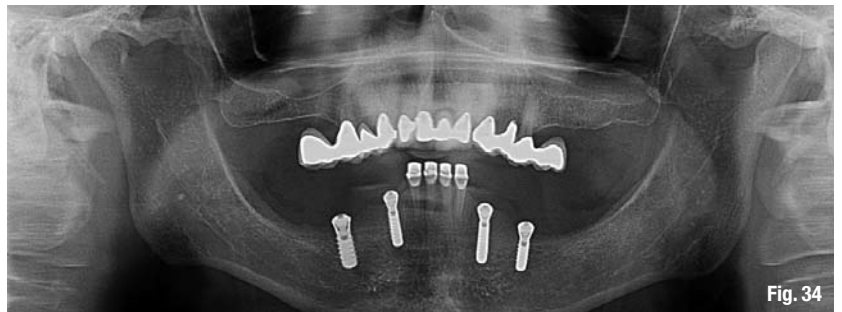

Fig. 34

front teeth. The restorations were temporarily affixed for six months and then cemented in place.

_contact	implants
<p>Dr Georg Bach Oral surgery specialist Rathausgasse 36 79098 Freiburg/Breisgau, Germany doc.bach@t-online.de</p> <p>ZTM Christian Müller Master dental technician Dental Technik Müller Carl-Kistner-Straße 21 79115 Freiburg/Breisgau, Germany CHMUE10@aol.com</p>	

Figs. 31–33_Three-dimensional diagnosis and planning (see dental pins) of the third and fourth quadrant. **Fig. 34**_Orthopantomogram after incorporation of four implants, three of which were diameter-reduced Roxolid (Straumann) implants.