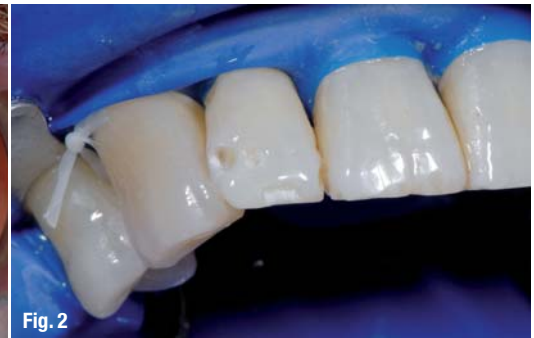
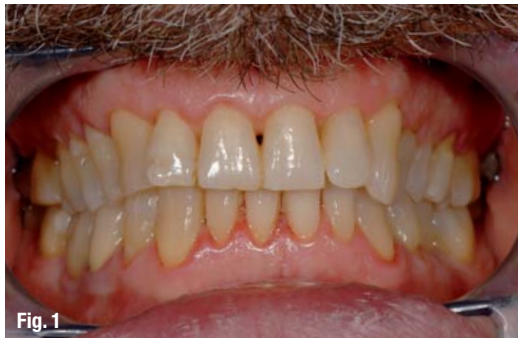
Enamel alterations

Author_Dr Prof Giuseppe Iaria, Italy

Fig. 1 A 56-year-old male patient presented with a tooth that showed enamel alterations.

Figs. 2 The use of the dam is suggested.



A healthy 56-year-old male patient presented with enamel alteration of tooth #7. The oral examination showed a healthy periodontium and temporomandibular joint, and the teeth were in a Class I occlusion (Figs. 1–4). The radiographic examination showed no other radicular lesions. The soft-tissue status indicated good periodontal health. For the hard-tissue test, percussion was normal, and there was no mobility or tenderness to touch or air spray. The tooth tested vital with the electric pulp tester and cold testing.

Fig. 3 The use of the DELight Er:YAG laser.

Fig. 4 The craters left by the laser are visible.

Fig. 5 The use of the bur to remove the unsubstained enamel.

Fig. 6 Acid etching.

Fig. 7 After acid etching.

Figs. 8–11 Result.

The objective was to restore tooth #7 using an Er:YAG laser in the following sequence:

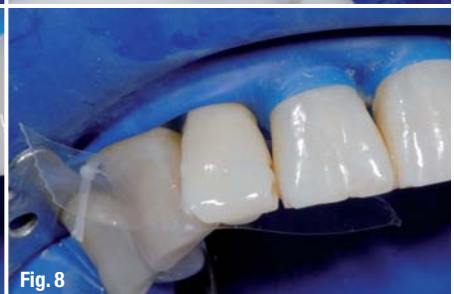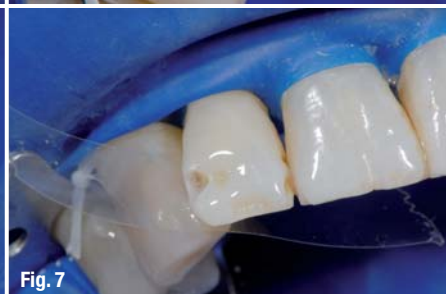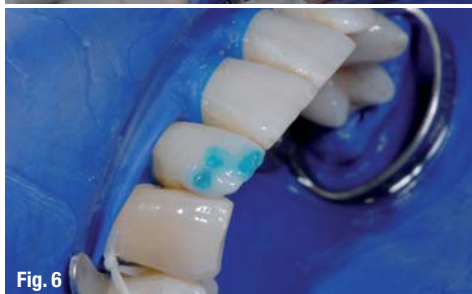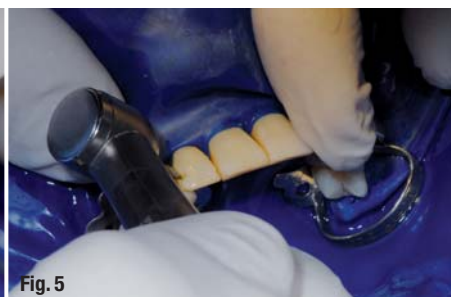
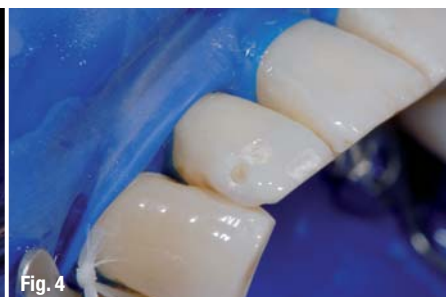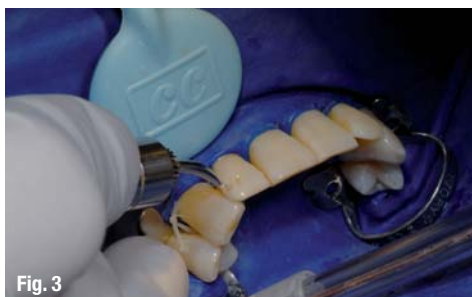
- Prepare the cavities of the tooth.
- Decontaminate bacteria in the treated surfaces.
- Prepare the margins using a bur to obtain an adequate surface with a maximum area of adhesion.

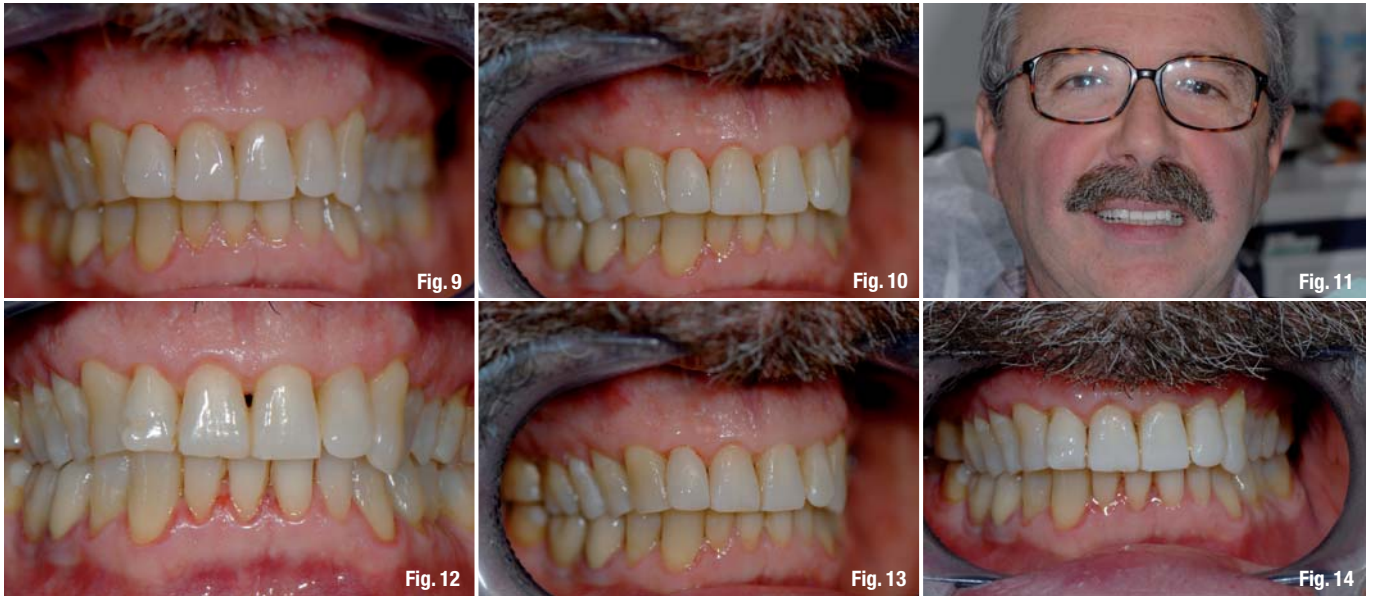d. Restore the cavities with a hybrid composite resin.

The Er:YAG laser wavelength is readily absorbed by hard tissue; therefore, it is possible to conserve healthy tooth structure more easily than using a conventional high-speed handpiece. In addition, the relative lack of tactile stimulation offered by laser treatment compared with a conventional high-speed handpiece often allows the procedure to be performed without the need for an anaesthetic.

Precautions

Adequate water spray must be maintained as the procedure is performed. Good visibility and low power are necessary for careful preparation in order to avoid both thermal damage and excessive removal of tooth structure.





Treatment alternatives

The treatment alternatives would have been conventional dental drills to roughen the dental surfaces. Such burs could have caused a greater loss of hard tissue, microfractures of the tooth enamel and tenderness.

_Laser operating parameters

An Er:YAG laser (DELIGHT, HOYA ConBio) with a wavelength of 2,940nm was used with its fibre delivery system and a 600µ quartz tip. It operates in a free-running pulse mode with a pulse duration of 300ms. The laser was used at 5W (200mJ, 25Hz) with an 80° quartz tip and water mist in non-contact mode for enamel ablation and at 3.2W (160mJ, 20Hz) with an 80° quartz tip and water mist in non-contact mode for dentine ablation. Prior to commencing the procedure, the patient was familiarised with the procedural steps. Subsequently, all laser safety precautions were performed. These included, but were not limited to, the administering of laser safety glasses to the patient and operators, displaying laser hazard signage, and inspecting the mechanical components of the laser.

Once safety systems were in place, the laser was test-fired to ensure proper beam function and water spray delivery. As the target tissue was addressed, high-volume suction was used continuously. The laser pulse rate was set to 25Hz and the laser energy was set to 200mJ, which produced a power of 5W. Enamel ablation was achieved using an 80° quartz tip with water mist in non-contact mode.

After this had been done, the laser pulse rate was set to 20Hz and the laser energy was set to 160mJ, which produced a power of 3.2W. Dentine ablation was achieved using an 80° quartz tip with water mist in

non-contact mode. Thereafter, Clearfil SE Bond (Kuraray America, Inc.) was applied to enamel and dentine surfaces and a nano-composite Adonis (Sweden & Martina S.p.A.) was used as the restorative material. Finishing of the restoration was performed with coarse diamond burs, 12-blade finishing burs, and finishing discs (Figs. 5–15).

_Post-operative instructions

The patient was told that he could resume normal activities owing to the lack of numbness because of no anaesthetic having been administered.

_Follow-up care

The objectives originally set were achieved. The entire procedure was performed with success without the use of dental anaesthetic. In addition, satisfactory aesthetic results were obtained (Fig. 16). The long-term results are in keeping with the objectives of the original treatment plan. The tooth maintained healthy vitality tests.

Fig. 8 The result immediately post-treatment.

Fig. 9 Front view of the restored enamel.

Fig. 10 Angled view of the teeth post-treatment.

Fig. 11 The patient showing his restored smile.

Fig. 12 Enamel alteration of tooth #7 before treatment.

Fig. 13 The restored tooth #7 post-treatment.

Fig. 14 One year post-treatment.

_contact	laser
<p>Dr Prof. Giuseppe Iaria University of Genoa Italy President IAHT– Int Ac of High Tech President ALDI–ALD Italian study Club Dental Laser Educator ALD</p> <p>Office: 19, Via S. Eustacchio–25128 Brescia, Italy Tel.: +39 030 391239 Fax: +39 030 3392399 iariagiuseppe@virgilio.it</p>	