

Diode-laser-assisted combination therapy of a lip haemangioma

Author_Dr Georg Bach, Germany

Fig. 1 Equipment needed for creating an ice-block: toothpick, rubber bands, fibre holder and cut-off bottom portion of a single-serving yoghurt container.




Fig. 2 To prevent the fibre-holding channel from icing up, its end is sealed with sticky wax, which can also be used for placement on the bottom of the plastic container.

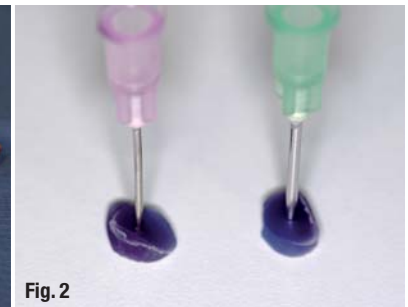


Fig. 3 To affix the fibre holder securely, it is stabilised with rubber bands and a toothpick, which serves as a holding strip.

Congenital vascular haemangiomas are relatively rare in dental practice. They occur in babies and toddlers and show a typical three-phase course: the initial phase is often marked by massive growth ("proliferation phase"), and the subsequent remission phase is then followed by an obligatory regression ("regression phase"). The typical three-phase clinical course usually enables a unique differentiation from a malformation, which—contrary to congenital haemangiomas—is often encoun-

tered in dental practice and affects primarily the lip area. A multitude of possible treatment options is mentioned for treatment of a vascular malformation of the lip.

Surgical treatment

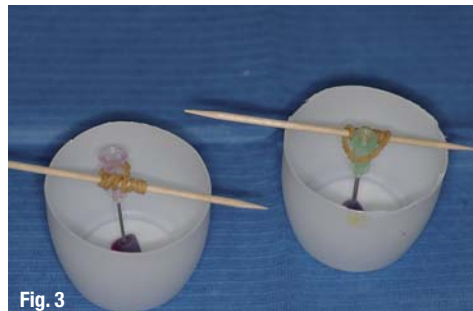Owing to intra-surgical complication rates (haemorrhaging), which are the exception to the rule today, surgery is only carried out in special clinics, especially if functional disruptions are expected because of a rapidly growing haematoma and non-surgical treatments do not promise success.

Modified surgical procedure according to Prof H. Deppe:
_tapping of the haemangioma;

Fig. 4 The container is filled with water.




Fig. 5 An ice-block with a fibre holder is moulded in the freezer.



- _ aspiration of the blood;
- _ injection of polyether impression material;
- _ hardening of the material; then
- _ surgical removal of the haemangioma into which the impression material has been injected with considerably reduced intra-surgical haemorrhaging.

Cryotherapy

This treatment is usually successful in haemangiomas with a thickness of up to 5 mm, with very few side-effects. However, cryotherapy for the lip is the subject of controversial discussion because of the risk of scar formation.

_ Laser-assisted treatment

Nd:YAG and diode lasers are primarily used here; isolated cases of treatment with yellow-light and argon lasers are also described in the literature. Medication (corticosteroids, in some cases also cytostatics) often used in the treatment of other haemangiomas is not relevant in the case of lip haemangiomas.

This report describes a combination treatment consisting of pre-surgical cooling and intra-surgical diode-laser use with simultaneous cooling with an ice-block into which the fibre is directed.

Goal

Diode lasers are the most common dental lasers in German dental clinics and dental clinics worldwide. These lasers are used primarily and very successfully for combating biofilm in the treatment of peri-implantitis, marginal periodontitis and endodontics.

Diode-laser light with a wavelength of 810 nm is absorbed extremely well by dark surfaces and thus also by blood. Use of a diode laser for the treatment of haemangiomas in an ideal situation, that is, with controlled thermal coagulation, would thus be conceivable. Reports on treatment with other laser wavelengths (Nd:YAG, CO₂, Argon and yellow-light lasers), which have been used for treating haemangiomas for years, often mention tissue necrotisation and post-surgical complications after laser treatment. These consequences are undesirable for tissue in aesthetically relevant areas, which most certainly include the lips, and are viewed critically by patients.

The central idea of the treatment of lip haemangiomas with diode-laser-assisted therapy is to combine the excellent absorption of diode-laser light with a wavelength of 810 nm and simultaneous cooling with an ice-block in order to keep the side-effects described to a minimum or, ideally, to prevent them.

_ Making a combination ice/fibre-holding block

The ice-block should be an ideal size and shape. Based on our experience, this can easily be achieved by using the cut-off bottom portion of a single-

AD

WFLD
The art of the light
2012 April 26 - 28 **2012**
Barcelona

XII Congreso de la S.E.L.O.
Sociedad Española de Láser Odontostomatológico

Science & Fun

Venue
Hotel Hesperia Tower

Key dates:
Abstract submission deadline;
December 15, 2011
Early registration fees deadline;
January 20, 2012

www.wfldbcn2012.com

Congress Technical Secretariat
TILESA KENES SPAIN
c/ Provença, 385 6-C
08025 Barcelona
Tel: +34 932 182 061
wfl2012@kenes.com

SELO Technical Secretariat
Mdv-Organización y Protocolo
c/ Bruc, 28 2n.
08010 Barcelona
Tel: +34 607 499 365
mdv@emedeuve.com

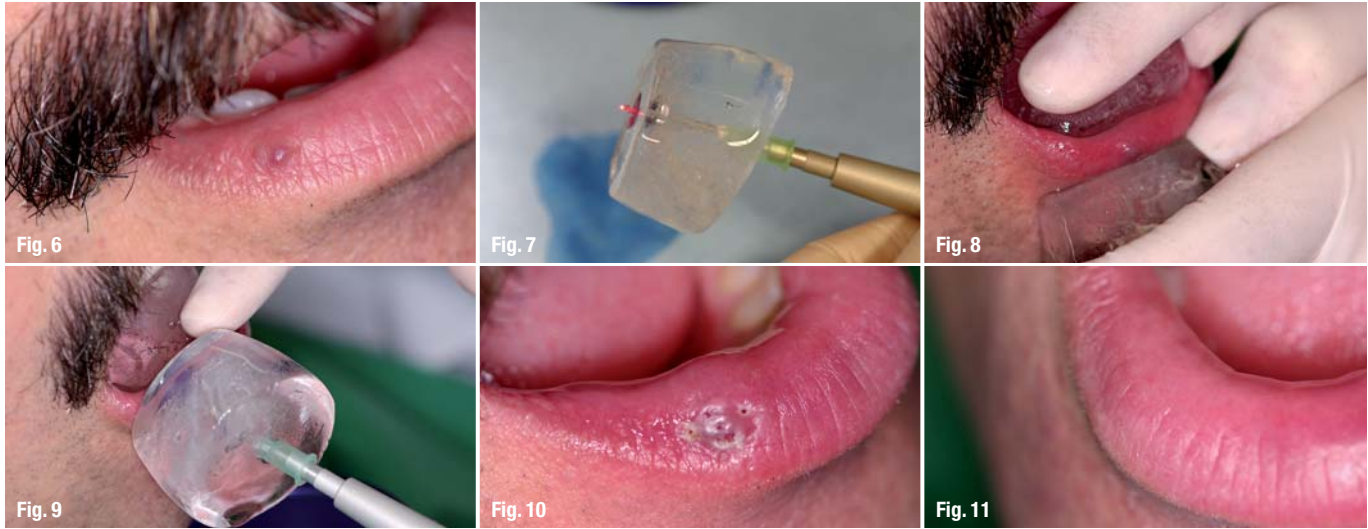


Fig. 6_ Hemangioma on right half of lower lip.
Fig. 7_ The fibre can be pushed through the fibre channel in the ice-block to the lip haemangioma that requires treatment.
Fig. 8_ Pre-surgical cooling around the haemangioma using an ice-block without a fibre holder.
Fig. 9_ Ice-block application; laser application.
Fig. 10_ Note the circular "injections", which demonstrate the expansion of the haemangioma.
Fig. 11_ Condition four weeks post-treatment.

serving drinkable yoghurt container as a mould for the ice-block. In order to direct the fibre through this ice-block, a disposable fibre holder (diameter must fit the fibre to be inserted) must be placed with the aid of a toothpick and rubber bands in such a way that it is centred and in contact with the bottom of the container. The container is then filled with water and placed in a freezer to freeze the block. A second (and possibly third) ice-block without a fibre holder should be created for the pre-surgical "cooling phase", which should occur approximately ten minutes prior to the laser treatment. The block's bulbous form conforms ideally to the shape of the lips.

Clinical application

Prior to the laser-assisted treatment, small amounts of local anaesthetic (approximately 8 x 0.1 ml) are injected around the haemangioma. The number of areas in which anaesthetic is injected can be reduced slightly in the case of smaller haemangiomas (this treatment is not suitable for very large lip haemangiomas).

Immediately after the local anaesthetic, the ice-block without fibre is used to cool the area for ten minutes (if possible, covering the entire haemangioma). The ice-block is then exchanged, the ice-block with the integrated fibre holder is placed onto the haemangioma, fitting it as closely as possible, and the laser fibre is then pushed through. Fibres with a diameter of 400 µm have proven to be suitable for this application; they are a good compromise between the achievable surface effect and minimum tissue trauma.

In the subsequent application of the laser, the fibre penetrates the lip surface and is inserted into the haemangioma up to a maximum of 5 mm. Ideally, the final position of the fibre will be in the centre of the haemangioma surface. After a ten-second appli-

cation of the laser, the fibre is removed and the position of the ice-block adjusted a little; then the same procedure is followed on a different, untreated area of the haemangioma. Treatment is completed when all areas of the haemangioma have been treated.

It is recommended that a second ice-block with fibre holder be available as a back-up to ensure that the haemangioma is constantly and perfectly covered. During treatment, the patient is covered with absorbent sheets to catch the melting water from the ice-block running from the lip to the ventral area.

Laser parameters

A diode laser that uses high pulse or digital pulse technology (elexxion) and emits laser light with a wavelength of 810 nm was used for combination treatment of a lip haemangioma. Pulse performance is 30 W at a frequency of 20,000 Hz with a pulse duration of 16 µs.

Conclusion

The combination treatment presented here, which entails simultaneous cooling during the use of a laser for treatment of a lip haemangioma, is a high-quality alternative to established procedures.

Its application is fairly simple and the advantage is that there are only minimal post-surgical complaints (minimal pain or swelling, very little scarring). Laser-assisted treatment of a lip haemangioma using a diode laser has distinct advantages compared with lasers with other wavelengths for treatment of medium-sized and small haemangiomas. The application of diode lasers is limited in the case of extensive haemangiomas.

The prevalence of diode lasers in dental and oral and maxillofacial surgical clinics supports the availability of this treatment.

_contact	laser
<p>Dr Georg Bach Oral surgery specialist Rathausgasse 36 79098 Freiburg/Breisgau, Germany doc.bach@t-online.de</p>	