

# laser

international magazine of laser dentistry

2<sup>2011</sup>



## | overview

The antibacterial effects of lasers in endodontics

## | interview

New double-wavelength-laser — successful launch at IDS

## | meetings

XI Congress of SELO

0277113

Clean and fully intact  
dental tubules after  
laser treatment.

# The universe at your fingertips.



## LightWalker®

**Introducing the highest technology dental laser system**

**Supreme clinical results in:**

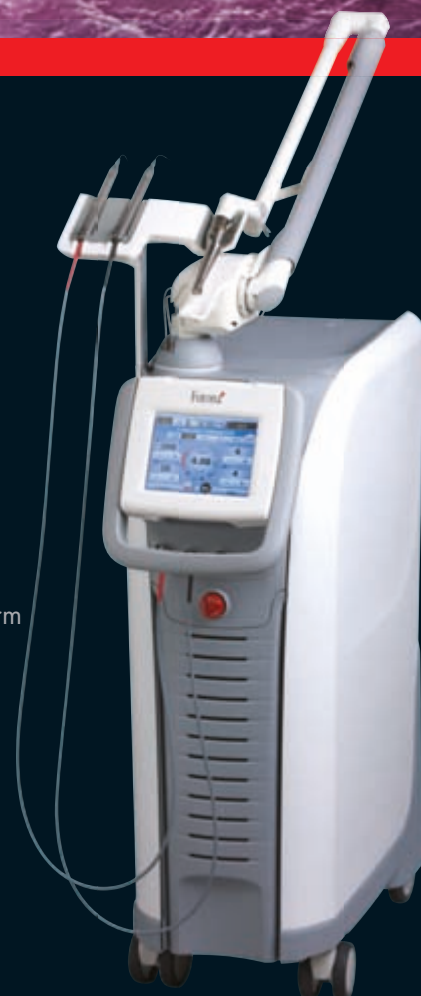- TwinLight™ Perio Treatments (TPT)
- TwinLight™ Endo Treatments (TET)
- No-sutures soft tissue surgery
- Gentle TouchWhite™ bleaching
- Patient-friendly conservative dentistry

**Unmatched simplicity of use:**

- Pre-sets for over 40 applications
- Intuitive user navigation
- Balanced and weightless OPTOflex arm
- Nd:YAG handpiece detection system
- Er:YAG scanner ready

Journey into a new dental experience with speed, precision and great results.  
Visit [www.lightwalkerlaser.com](http://www.lightwalkerlaser.com) today!

**Fotona**  
choose perfection



[www.fotona.com](http://www.fotona.com)

88897/9.0



# IDS approves use of laser in dentistry



Prof Dr Norbert Gutknecht  
WFLD President  
Editor-in-Chief

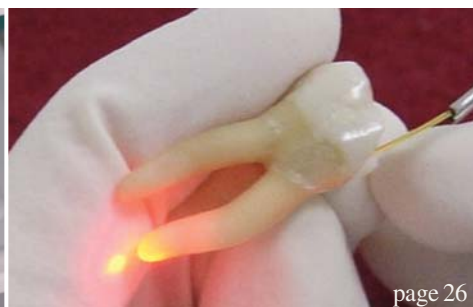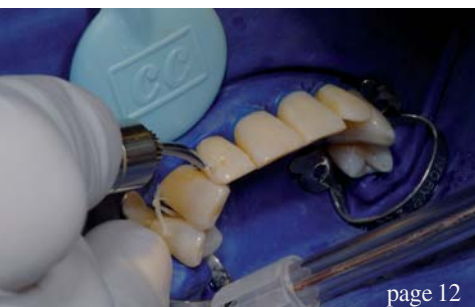
\_The IDS—International Dental Show—in Cologne showed once again the further dissemination and awareness of laser therapy in dentistry. A significant higher number of distributors showed their laser devices to the dental world with new innovations and treatment concepts. Seeing this I am even more sure that laser therapy will play an improving role in the wide field of modern dental therapy.

The upcoming European Division Congress of the WFLD in Rome promises to be an outstanding congress, especially with the location Rome as a special attraction. If you have not made your decision to participate in this congress it is more than high time now and I am sure you will not regret it!

Hope to see you in Rome!

A handwritten signature in black ink, appearing to read 'Gutknecht'.

Prof Dr Norbert Gutknecht  
Editor-in-Chief



## | editorial

- 03 IDS approves use of **laser in dentistry**  
| Prof Dr Norbert Gutknecht

## | case report

- 06 Laser-assisted **immediate implantation** at infected site  
| Drs Avi Reyhanian *et al.*
- 12 **Enamel** alterations  
| Dr Giuseppe Iaria
- 14 Utilising **laser** technology  
| Dr Patrick J. Broome
- 18 Treatment of **gingival hyperpigmentation** for aesthetic purposes using the diode laser  
| Drs M. L. V. Prabhuj *et al.*

## | clinical technique

- 20 **Diode-laser-assisted combination therapy** of a lip haemangioma  
| Dr Georg Bach
- 23 Periodontitis therapy with **3,000 % more power**  
| Dr Darius Moghtader

## | overview

- 26 The antibacterial effects of **lasers in endodontics**  
| Dr Selma Christina Cury Camargo

## | industry report

- 32 TwinLight™ laser-assisted **endodontics**  
| Dr Kresimir Simunovic
- 36 TouchWhite™ Er:YAG laser-assisted **Tooth Whitening**  
| Jugoslav Jovanovic

## | special

- 40 **Infection control**  
| Dr Frank Yung

## | laser

- 42 **New double-wavelength-laser—** successful launch at IDS  
| An interview with Frederico Pignatelli
- 44 **The Joint Fellowship Course** of Tehran and Aachen Universities  
| Reza Fekrazad *et al.*

## | meetings


- 45 **International events 2011 & 2012**
- 46 **XI Congress of SELO**  
| Paloma Montero *et al.*
- 48 **Biggest IDS ever**

## | news

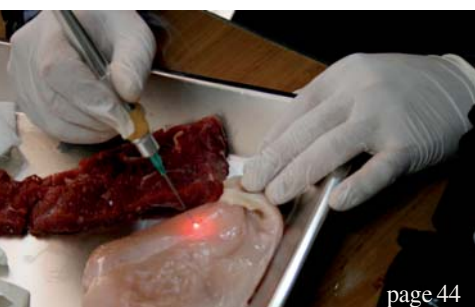- 49 **Manufacturer News**

## | about the publisher

- 50 | Imprint



Cover image courtesy of A.R.C. Laser GmbH,  
[www.arclaser.de](http://www.arclaser.de)





*Express  
your mastery*

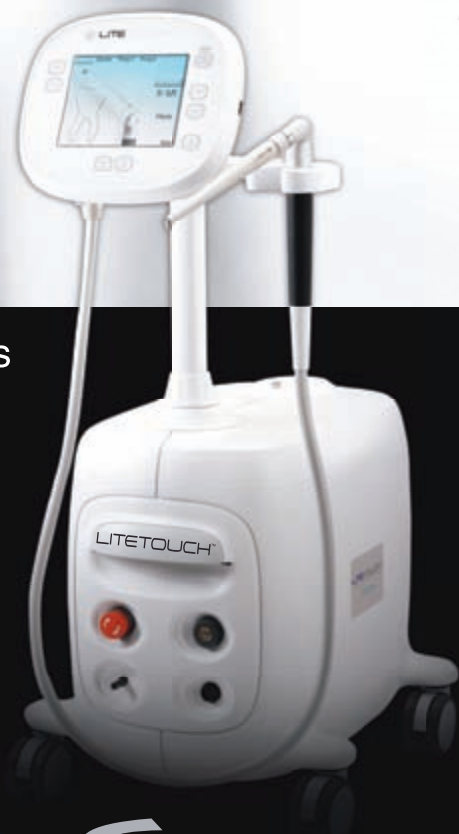Join the fast growing success of Syneron Dental Lasers

Presenting

**LITETOUCH™**

The unique fiber-free Er:YAG laser

Dentist's **1<sup>st</sup>** Choice  
for hard and soft tissue procedures



III WFLD-ED European Congress - Sapienza University of Rome - Italy, June 9-11 2011, Booth 13

W W W . S Y N E R O N D E N T A L . C O M

**Syneron™**  
DENTAL LASERS

# Laser-assisted immediate implantation at infected site

**Authors** Drs Avi Reyhanian, Natan Fuhrman, Israel & Costas Ioannou, Cyprus

## Abstract

Osseointegration of dental implants has become a routinely recommended procedure in the clinical practice of dentistry.<sup>1-4</sup> Over the years, patients have begun to demand a shortened treatment time and that treatment be done in one visit, to the extent possible. This clinical case study will discuss and demonstrate the correct use of the Er:YAG laser (2,940 nm) in immediate placement of implants (in one visit) at the infected site: extraction, degranulation, decontamination, placing the implant, and treating the bone defect (guided-bone regeneration—GBR).

This technique using the Er:YAG laser presents several advantages compared with conventional treatment methods, and there are minimal post-operative complications coupled with a high success rate.

## *Introduction of the clinical case*

A 21-year-old soldier presented to the clinic with the chief complaint of mobility of tooth #11. There was no medical history. He had undergone trauma to the tooth a year before, which had been untreated. Clinical examination revealed mobility grade 3+ at tooth #11 with fistula and a change of

**Fig. 1** Mobility and fistula of tooth #11.

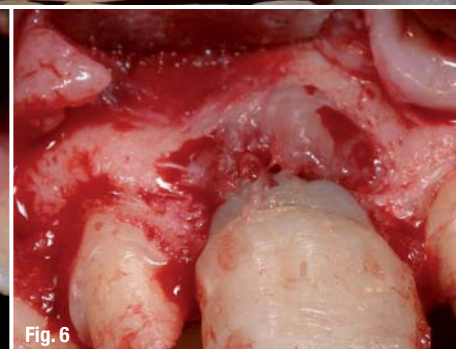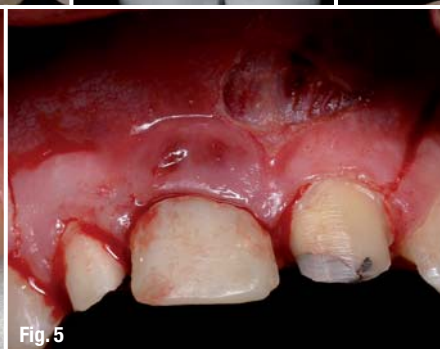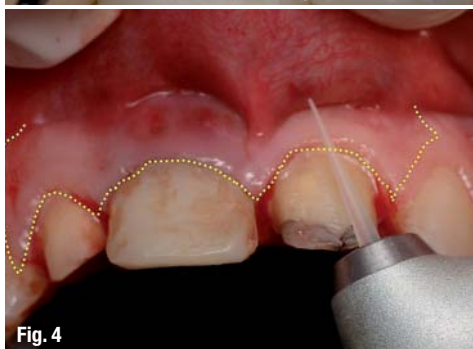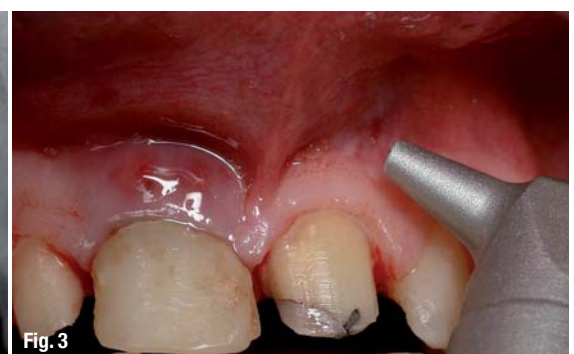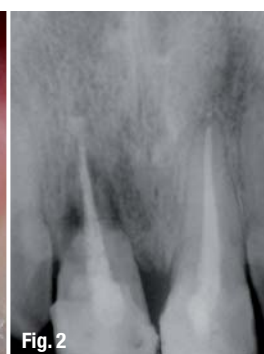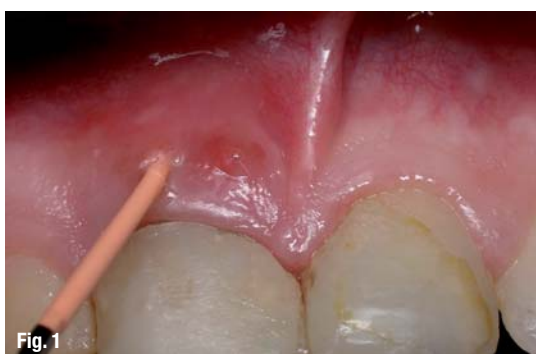
**Fig. 2** X-ray image of teeth #11 and 21.

**Fig. 3** The CO<sub>2</sub> laser used for the frenectomy.

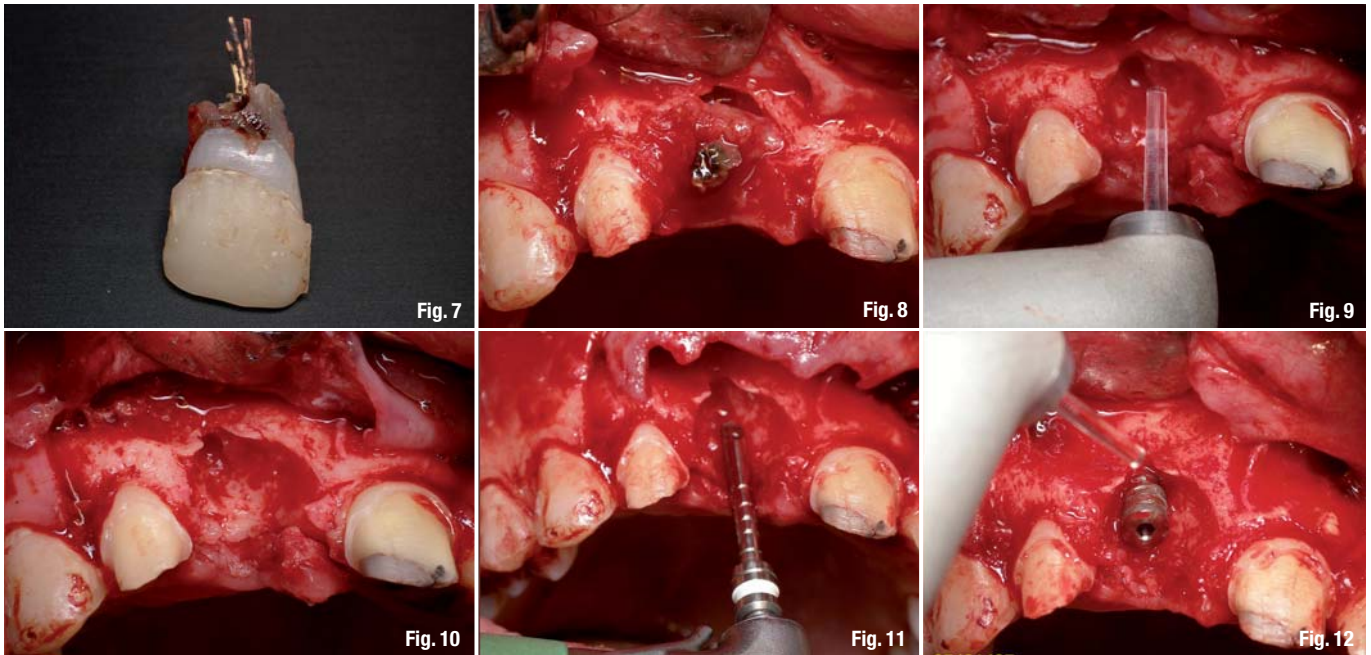
**Fig. 4** The Er:YAG laser used for incision.

**Fig. 5** The intrasulcular and vertical incisions and the frenectomy.

**Fig. 6** Lifting the flap.







colour of tooth #21. A periodontal probe indicated a depth pocket of 9mm and bleeding on probing. Radiographs revealed horizontal and vertical bone loss due to trauma around teeth #11 and 21 with root canal (Figs. 1 & 2).

Implant indications for laser treatment:

- \_frenectomy using the CO<sub>2</sub> laser;
- \_incision using the Er:YAG laser;
- \_lifting a flap.

Simultaneous (combined) approach:

- \_extraction;
- \_ablation of granulation tissue using the Er:YAG laser;
- \_insertion of immediate implant using the Er:YAG laser—lasing just the cortical bone;
- \_GBR using the Er:YAG laser;
- \_primary closure.

Treatment alternatives:

- \_Using conventional treatment
  - scalpel
  - surgical bur
  - high-speed rotary instruments
  - GBR
  - sutures
- \_Multiple post-operative appointments: staged approach
- \_Placement of the fixture after healing.

#### Diagnosis and treatment plan

Severe periodontitis with massive bone loss around tooth #11 was diagnosed. The treatment plan entailed lifting a flap, extraction of the tooth

and immediate placement of a submerged implant, using a CO<sub>2</sub> laser for the frenectomy, then using an Er:YAG laser for incision, ablation of granulation tissue, bone remodelling and shaping decortication for GBR. Uncovering of the submerged implant with an Er:YAG laser was to be done a year later.

#### Rational for treatment

The pulsed Er:YAG laser can cut and ablate tissue with excellent surgical precision without excessive heat or thermal injury. Healing time is shortened when compared with a scalpel or hand instruments. Using a CO<sub>2</sub> laser for a frenectomy results in no bleeding, no pain post-operatively, and a reduced healing time compared with conventional methods.

#### Indications/contra-indications and alternative treatment

There were no contra-indications for use of the laser on this patient. Care must be taken to set proper parameters and use a proper technique, so that both hard and soft tissues are not ablated when only one of the tissues is being targeted. Maximum water spray cooling must be used with the Er:YAG laser to avoid thermal damage.

#### Clinical technique, laser wavelength and laser operating parameters

The lasers selected for the frenectomy were a CO<sub>2</sub> laser (Aqualite, Lumenis Dental; 10,600 nm, 6W, SP, non-contact), a free-running, pulsed Er:YAG laser (LiteTouch, Syneron Medical Ltd; 2,940 nm, repetition rate of 17–10 Hz, 400–700 mJ). The tips

**Fig. 7\_** The extracted tooth.

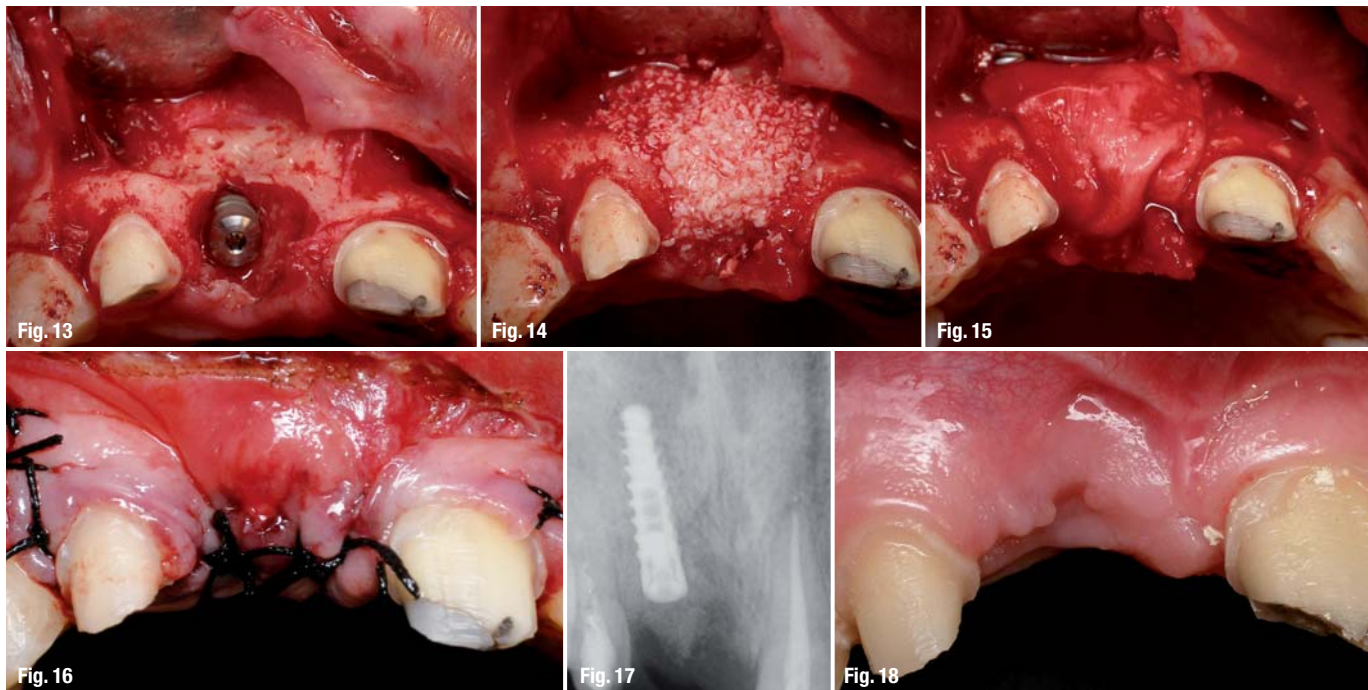
**Fig. 8\_** The bone defect.

**Fig. 9\_** The Er:YAG laser ablates the granulation tissue.

**Fig. 10\_** The bone defect after ablation and marking the location of the implant with the Er:YAG laser.

**Fig. 11\_** The pilot hole.

**Fig. 12\_** Decortication with the Er:YAG laser.



**Fig. 13\_**Immediately after decortication.

**Fig. 14\_**Xenograft using Bio-Oss for GBR.

**Fig. 15\_**Resorbable membrane.

**Fig. 16\_**Primary closure.

**Fig. 17\_**X-ray image immediately post-op.

**Fig. 18\_**Three months post-op.

used were 200 $\mu$  and 1,300 $\mu$  sapphire tips. The laser selected for uncovering the submerged implant was an Er:YAG laser (LiteTouch) with a 200 $\mu$  sapphire tip and a power setting of 300mJ/25 Hz.

#### *Treatment sequence*

Verbal consent was obtained from the patient and his parents after explaining the advantages of laser treatment compared with conventional surgical techniques.

Local anaesthetic was first given to the patient. The frenectomy was then performed with the CO<sub>2</sub> laser set in non-contact mode and to 6WSP (Fig. 3).<sup>5-7</sup>

Er:YAG lasers can be used to make an incision for flap lifting, such as crestal, intrasulcular or vertical release incisions, and produce a wet incision (some bleeding) as opposed to the dry incision (no bleeding) produced by the CO<sub>2</sub> laser.<sup>8-11</sup>

The Er:YAG laser with a 200 $\mu$  sapphire tip and set in contact mode was used to perform intrasulcular incision and two vertical incisions (Figs. 4 & 5). A full-thickness flap was lifted (Fig. 6) and tooth #11 was extracted (Fig. 7).

Vaporisation of granulation tissue (if any exists) after lifting a flap can be done efficiently with the Er:YAG laser, with a lower risk of overheating the bone than with the current diode or CO<sub>2</sub> lasers.<sup>11,17,14</sup> There is no need for any hand instruments. Results from both controlled clinical and basic studies have pointed to the high potential of the Er:YAG laser. Its

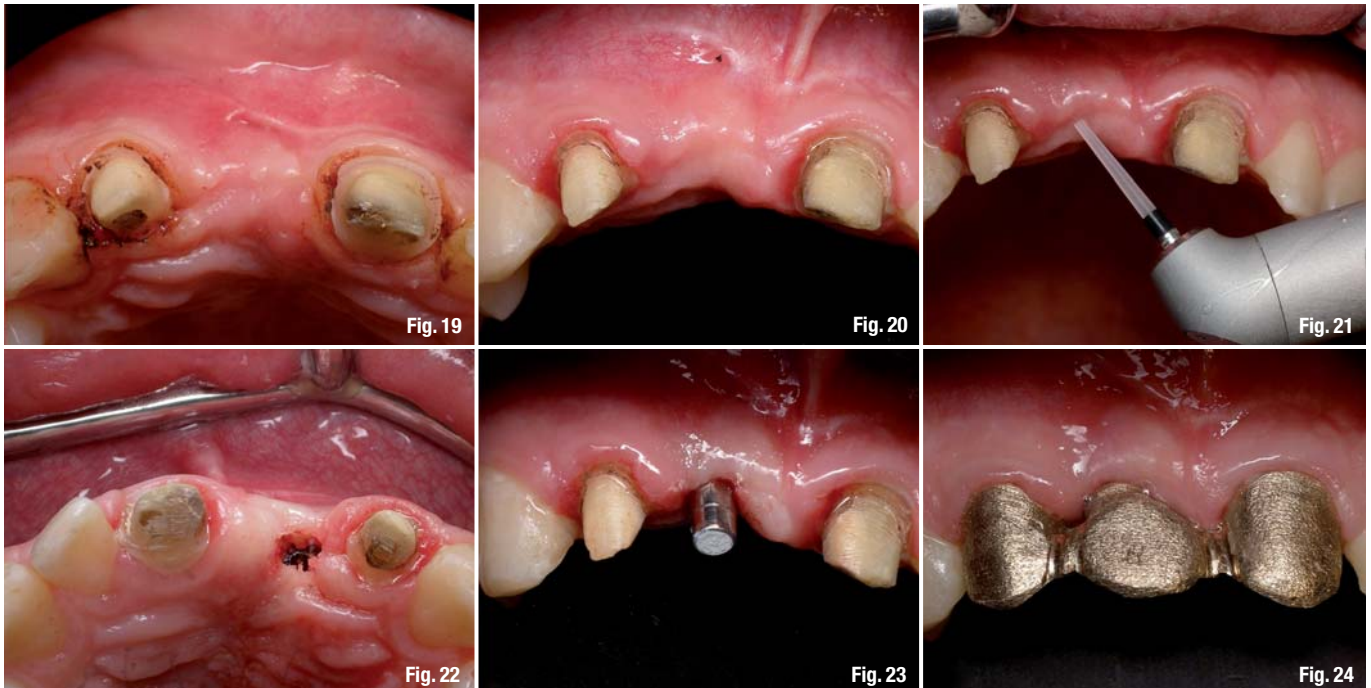excellent ability to ablate soft tissue effectively without producing major thermal side-effects to adjacent tissue has been demonstrated in numerous studies.<sup>12-15</sup>

Granulation tissue was ablated with the Er:YAG laser with a 1,300 $\mu$  tip in non-contact mode and with a power setting of 600mJ/12 pps (Figs. 8 & 9). Detoxification of the infected site was done by laser directly on the bone, using a low-energy setting. In this way, the target tissue was disinfected without injuring the bone. The laser is bactericidal.<sup>15,16</sup> The necrotic bone was ablated using the Er:YAG laser with a 1,300 $\mu$  sapphire tip in non-contact mode and with a power setting of 350mJ/20 pps.<sup>8,10,17,18</sup>

The placement site for the implant was marked with the Er:YAG laser (Fig. 10), and the entire length of the implant was prepared using rotary instruments (Fig. 11). The laser does not replace the pilot drill; it is used to create a pilot hole for the drill. The preparation for the entire length of the implant should not be lased with the laser.

An implant with a length of 13 mm and diameter of 3.75mm (MIS Implants Technologies Ltd) was placed manually (Fig. 12). The bone defect required GBR. Decortication was performed with the Er:YAG laser with a 1,300 $\mu$  sapphire tip in non-contact mode and with a power setting of 400mJ/12 pps (Figs. 12 & 13). The bone defect around the implant was filled with Bio-Oss bone substitute (Geistlich Biomaterials) and covered with Bio-Gide (Geistlich Biomaterials), an absorbent, bilayer membrane





(Figs. 14 & 15). Sutures were applied and primary closure was achieved (Fig. 16). An X-ray was taken to confirm the placement of the implants (Fig. 17).

### **Biological rationale for immediate implantation**

- \_ Simplified procedure that reduces the surgical stages;
- \_ conservation of bone volume surrounding natural tooth;
- \_ combination of post-extraction healing phase with osseointegration;
- \_ maximum stimulation of natural healing processes;
- \_ shortened healing phase and rehabilitation time;
- \_ positive psychological effect on the patient.

### **Post-operative assessment**

The patient was prescribed Clindamycin (150 mg x 50 tabs) to avoid infection. He was also given Motrin (800 mg x 15 tabs) for pain. Instructions were given to rinse with a 0.2% chlorhexidine mouthwash, starting the next day for two weeks (three times a day). The patient returned for his first follow-up the next day with a moderate swelling and pain. The flap was closed. At ten days, the patient returned for the stitches to be removed and there were no signs of swelling haematoma or pain. After one month, the soft tissue had healed. A three-month evaluation of the area showed complete healing and no complications (Fig. 18). The soft tissue had healed over the bone and there were no bony projections observed under the soft tissue. The prognosis was excellent.

### **Complications**

The patient had no complications related to laser treatment either during or after laser therapy. There was no soft or hard tissue damage.

### **Follow-up and long-term results**

The patient was assessed once a week in the first month, at six weeks, three months and six months after the start of the treatment. At the fifth-month supportive periodontal therapy appointment, the patient had excellent healing and had improved tissue colour, contour and consistency (Fig. 19).

A year post-treatment the submerged implant was uncovered with the Er:YAG laser with an 800µ sapphire tip in non-contact mode and with a power setting of 400 mJ/25 pps (Figs. 20–23). Five months after this, the rehabilitation was completed: three crowns on teeth #12, 11 (eight implants) and 21 (Figs. 24 & 25).

This case was followed-up for three years and two months (Figs. 26 & 27). An X-ray image shows a small absorption of bone around the neck of the implant.

### **Conclusion**

We conclude that using the 2,940 nm wavelength laser for these procedures offers many advantages compared with conventional methods, such as the reduction of patient discomfort, enhancement of the surgical site and reduced treatment time.<sup>21</sup> This

**Fig. 19** Five months post-op, showing complete closure.

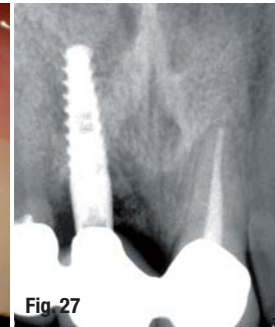
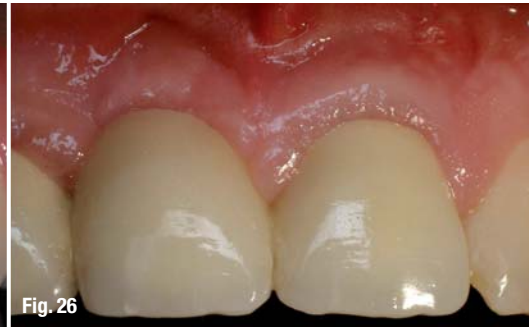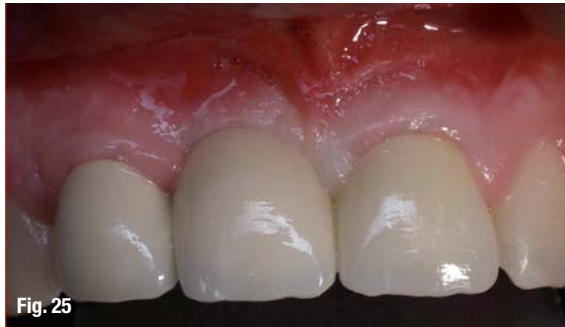**Fig. 20** A year post-op.

**Fig. 21** Using the Er:YAG laser to uncover the submerged implant.

**Fig. 22** The uncovered implant.

**Fig. 23** The abutment.

**Fig. 24** The alloy part of the rehabilitation – porcelain-fused-to-gold crowns.



**Fig. 25** \_Final result a year and five months post-op.

**Fig. 26** \_Three years and two months post-op.

**Fig. 27** \_X-ray image three years and two months post-op.

wavelength can be employed for the purpose of the decontamination of infected sites and it has been shown to be effective and safe.<sup>12,19,20</sup> In addition, post-operative effects such as pain and swelling are less pronounced. This laser has become an invaluable tool for many procedures by simplifying treatment and offering patients faster, less stressful oral therapy with enhanced outcomes.

This case demonstrates that the Er:YAG laser is a very valuable tool that shows promise and safety as an effective new technical modality for implant therapy. However, further clinical and basic investigations are required to establish the clinical effectiveness and safety of the Er:YAG laser in implant site preparation.

## References

1. Adell R, Lekholm U, Rockler B, Brånemark PI, "A 15-Year Study of Osseointegrated Implants in the Treatment of the Edentulous Jaw". *Int J Oral Surg*. 1981 Dec;10(6):387–416.
2. Albrektsson T, "A Multicenter report on Osseointegrated Oral Implants". *J Prosthet Dent*. 1988 Jul;60(1):75–84.
3. Buser D, Mericske-Stern R, Dula K, Lang Nova Pulse, "Clinical Experience with One-Stage, Non-Submerged Dental Implants". *Adv Dent Res*. 1999 Jun;13:153–61.
4. Olsson M, Friberg B, Nilson H, Kultje C, "Mkl – a Modified Self-Tapping Branemark Implant: 3-Year Results of a Controlled Prospective Pilot Study". *Int J Oral Maxillofac Implants*. 1995 Mar-Apr;10(2):243.
5. Shetty K, Trajtenberg C, Patel C, Streckfus C. "Maxillary frenectomy using a carbon dioxide laser in a pediatric patient: a case report". *Gen Dent*. 2008 Jan-Feb;56(1):60–3.
6. Haytac MC, Ozcelik O. "Evaluation of patient perceptions after frenectomy operations: a comparison of carbon dioxide laser and scalpel techniques". *J Periodontol*. 2006 Nov;77(11):1815–9.
7. Fiorotti RC, Bertolini MM, Nicola JH, Nicola EM. "Early lingual frenectomy assisted by CO<sub>2</sub> laser helps prevention and treatment of functional alterations caused by ankyloglossia". *Int J Orofacial Myology*. 2004 Nov;30:64–71.
8. Ishikawa I, Aoki A, Takasaki AA, "Potential Applications of Er:YAG Laser in Periodontics" *J Perio Res*. 2004 Aug;39(4): 275–85.
9. Watanabe H, Ishikawa I, Suzuki M, Hasegawa K, "Clinical Assessments of the Erbium:YAG Laser for Soft Tissue Surgery and Scaling", *J Clin Laser Med Surg*. 1996 Apr, 14(2):67–75.
10. Ishikawa I, Sasaki KM, Aoki A., Watanabe H, "Effects of Er:YAG Laser on Periodontal Therapy", *J Int Acad Periodontol*. 2003 Jan;5(1): 23–8.
11. Sasaki KM, Aoki A., Ichinose S, Yoshino T, Yamada S, Ishikawa L, "Scanning Electron Microscopy and Fourier Transformed Infrared Spectroscopy Analysis of Bone Removal Using Er:YAG and CO<sub>2</sub> Lasers", *J Perio*, 2002 Jun; 73(6):643–52.
12. Sasaki KM, Aoki A., Ichinose S, Yoshino T, Yamada S, Ishikawa L, "Scanning Electron Microscopy and Fourier Transformed Infrared Spectroscopy Analysis of Bone Removal Using Er:YAG and CO<sub>2</sub> Lasers", *J Perio*, 2002 Jun; 73(6):643–52.
13. Kreisler M, Al Haj H, d'Hoedt B. "Temperature Changes at the Implant-Bone Interface During Simulated Surface Decontamination with an Er:YAG Laser". *Int J Prosthodont*. 2002 Nov-Dec;15(6):582–7.
14. Schwarz F, Rothamel D, Becker J, "Influence of an Er:YAG Laser on the Surface Structure of Titanium Implants", *Schweiz Monatsschr Zahnmed*. 2003;113(6):660–71.
15. Schwarz F, Bieling K, Sculean A, Herten M, Becker J, "Treatment of Periimplantitis with Laser or Ultrasound. A Review of the Literature". *Schweiz Monatsschr Zahnmed*. 2004; 114(12): 1228–35.
16. Kreisler M, Kohnen W, Marinello C, Gotz H, Duschner H, Jansen B, d'Hoedt B. "Bactericidal Effect of the Er:YAG Laser on Dental Implant Surfaces: An In Vitro Study", *J Periodontol*. 2002 Nov;73(11):1292–8.
17. Kreisler M, Kohnen W, Christoffers AB, Gotz H, Jansen B, Duschner H, d'Hoedt B. "In Vitro Evaluation of the Biocompatibility of Contaminated Implant Surfaces Treated with an Er:YAG Laser and an Air Powder System". *Clin Oral Implants Res*. 2005 Feb;16(1):36–43.

*Editorial note: The whole list of references is available from the publisher.*

## \_contact

laser

### Avi Reyhanian, DDS

Shaar Haemek Street, Netanya 42292, Israel

### Natan Fuhrman, DDS

Institute of Advanced Dental Education, Haifa, Israel

### Costas Ioannou, DDS

35 Ifigenias str 2007, Nicosia, Cyprus





***Lay the Foundations to your  
successful Future now!***

*Next master course starts: Aachen 26.09.11, Dubai 17.10.11*



## ***Master of Science (M.Sc.) in Lasers in Dentistry***

*Would you also like to be part of the International Dentists' Elite?*

- *The first accredited M.Sc. programme in dentistry in Germany*
- *Career-accompanying postgraduate programme of two years at the University of Excellence RWTH Aachen*
- *Internationally accepted and accredited by the German Government, the European Union, the Washington Accord and the Bologna Process*
- *Science-based and practice-orientated on highest national and international level*
- *Bronze Award of the European Union for „Life-Long Learning programmes“*



Aachen Dental Laser Center

**More information:**

AALZ GmbH · Pauwelsstrasse 19 · 52074 Aachen · Germany  
Tel. +49 - 2 41 - 9 63 26 70 · Fax +49 - 2 41 - 9 63 26 71  
[www.aalz.de](http://www.aalz.de) · [info@aalz.de](mailto:info@aalz.de)

In cooperation with the University  
of Excellence RWTH Aachen

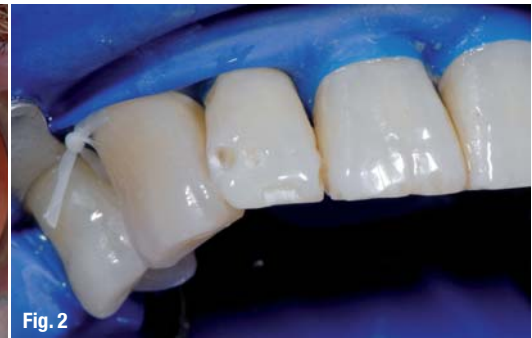
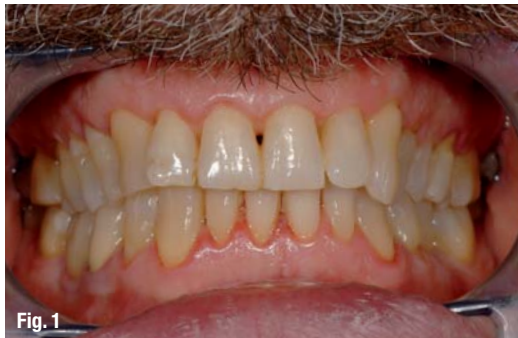
# Enamel alterations

Author\_Dr Prof Giuseppe Iaria, Italy

**Fig. 1**\_A 56-year-old male patient presented with a tooth that showed enamel alterations.

**Figs. 2**\_The use of the dam is suggested.



A healthy 56-year-old male patient presented with enamel alteration of tooth #7. The oral examination showed a healthy periodontium and temporomandibular joint, and the teeth were in a Class I occlusion (Figs. 1–4). The radiographic examination showed no other radicular lesions. The soft-tissue status indicated good periodontal health. For the hard-tissue test, percussion was normal, and there was no mobility or tenderness to touch or air spray. The tooth tested vital with the electric pulp tester and cold testing.

**Fig. 3**\_The use of the DELight Er:YAG laser.

**Fig. 4**\_The craters left by the laser are visible.

**Fig. 5**\_The use of the bur to remove the unsubstained enamel.

**Fig. 6**\_Acid etching.

**Fig. 7**\_After acid etching.

**Figs. 8–11**\_Result.

The objective was to restore tooth #7 using an Er:YAG laser in the following sequence:

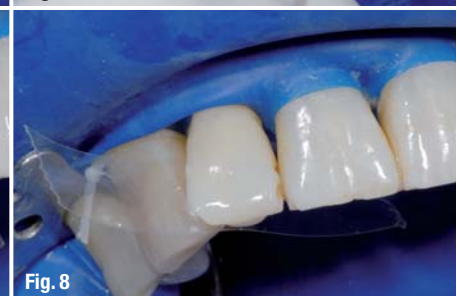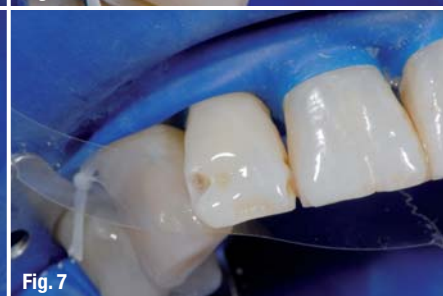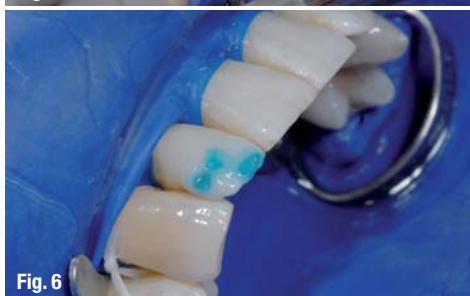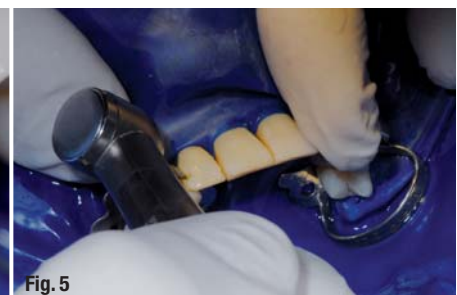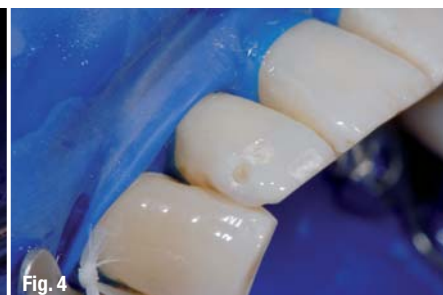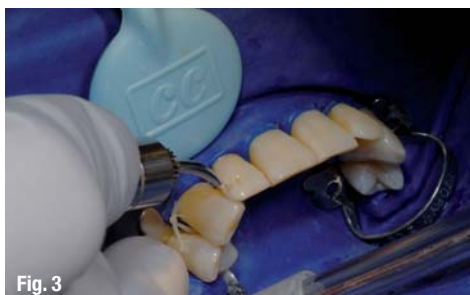- Prepare the cavities of the tooth.
- Decontaminate bacteria in the treated surfaces.
- Prepare the margins using a bur to obtain an adequate surface with a maximum area of adhesion.

d. Restore the cavities with a hybrid composite resin.

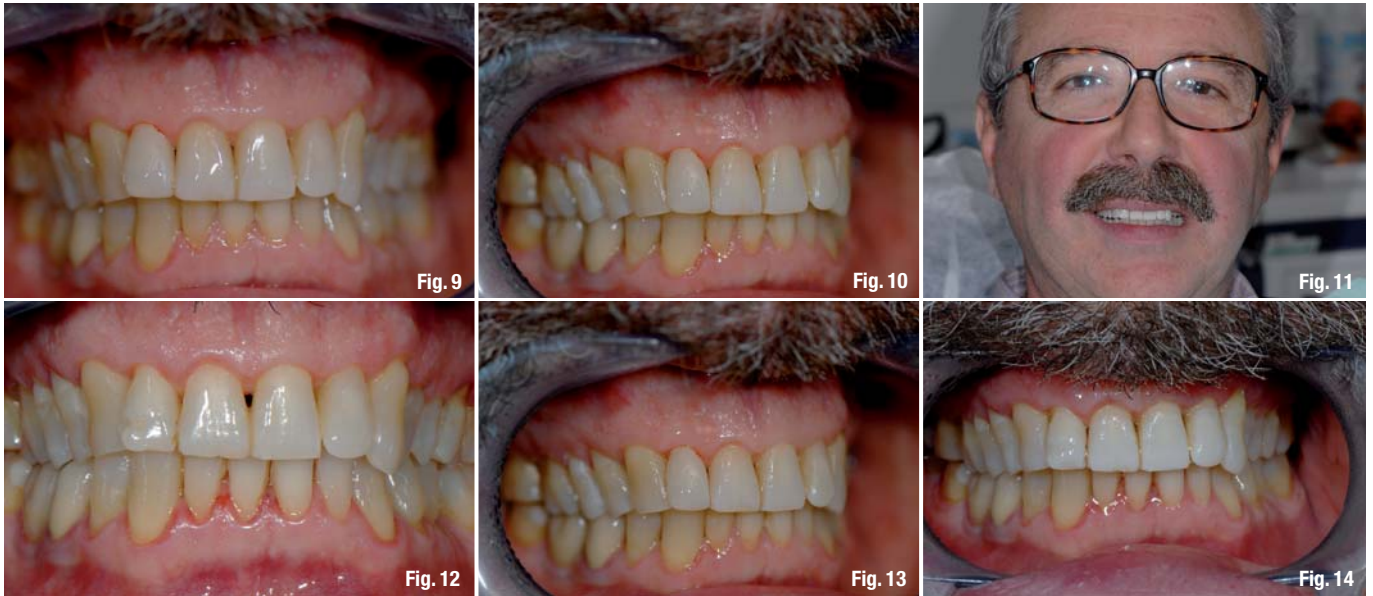The Er:YAG laser wavelength is readily absorbed by hard tissue; therefore, it is possible to conserve healthy tooth structure more easily than using a conventional high-speed handpiece. In addition, the relative lack of tactile stimulation offered by laser treatment compared with a conventional high-speed handpiece often allows the procedure to be performed without the need for an anaesthetic.

## Precautions

Adequate water spray must be maintained as the procedure is performed. Good visibility and low power are necessary for careful preparation in order to avoid both thermal damage and excessive removal of tooth structure.







### Treatment alternatives

The treatment alternatives would have been conventional dental drills to roughen the dental surfaces. Such burs could have caused a greater loss of hard tissue, microfractures of the tooth enamel and tenderness.

### Laser operating parameters

An Er:YAG laser (DELIGHT, HOYA ConBio) with a wavelength of 2,940nm was used with its fibre delivery system and a 600µ quartz tip. It operates in a free-running pulse mode with a pulse duration of 300ms. The laser was used at 5W (200mJ, 25Hz) with an 80° quartz tip and water mist in non-contact mode for enamel ablation and at 3.2W (160mJ, 20Hz) with an 80° quartz tip and water mist in non-contact mode for dentine ablation. Prior to commencing the procedure, the patient was familiarised with the procedural steps. Subsequently, all laser safety precautions were performed. These included, but were not limited to, the administering of laser safety glasses to the patient and operators, displaying laser hazard signage, and inspecting the mechanical components of the laser.

Once safety systems were in place, the laser was test-fired to ensure proper beam function and water spray delivery. As the target tissue was addressed, high-volume suction was used continuously. The laser pulse rate was set to 25Hz and the laser energy was set to 200mJ, which produced a power of 5W. Enamel ablation was achieved using an 80° quartz tip with water mist in non-contact mode.

After this had been done, the laser pulse rate was set to 20Hz and the laser energy was set to 160mJ, which produced a power of 3.2W. Dentine ablation was achieved using an 80° quartz tip with water mist in

non-contact mode. Thereafter, Clearfil SE Bond (Kuraray America, Inc.) was applied to enamel and dentine surfaces and a nano-composite Adonis (Sweden & Martina S.p.A.) was used as the restorative material. Finishing of the restoration was performed with coarse diamond burs, 12-blade finishing burs, and finishing discs (Figs. 5–15).

### Post-operative instructions

The patient was told that he could resume normal activities owing to the lack of numbness because of no anaesthetic having been administered.

### Follow-up care

The objectives originally set were achieved. The entire procedure was performed with success without the use of dental anaesthetic. In addition, satisfactory aesthetic results were obtained (Fig. 16). The long-term results are in keeping with the objectives of the original treatment plan. The tooth maintained healthy vitality tests.

**Fig. 8** The result immediately post-treatment.

**Fig. 9** Front view of the restored enamel.

**Fig. 10** Angled view of the teeth post-treatment.

**Fig. 11** The patient showing his restored smile.

**Fig. 12** Enamel alteration of tooth #7 before treatment.

**Fig. 13** The restored tooth #7 post-treatment.

**Fig. 14** One year post-treatment.

### contact

### laser

#### Dr Prof. Giuseppe Iaria

University of Genoa Italy  
President IAHT– Int Ac of High Tech  
President ALDI–ALD Italian study Club  
Dental Laser Educator ALD

#### Office:

19, Via S. Eustacchio–25128 Brescia, Italy  
Tel.: +39 030 391239  
Fax: +39 030 3392399  
iariagiuseppe@virgilio.it

# Utilising **laser** technology

## Obtaining better clinical results and creating better patient experiences

**Author\_**Dr Patrick J. Broome, USA



Fig. 1

**\_If your patients are like** the majority of our patients, they are always in a rush and seeking the quickest way to accomplish the dentistry they need or desire. We live in a world of instant gratification and everyone is seeking convenience, speed, cost savings and a better end result. It is rare to find a product or device that makes our clinical success easier and more predictable and saves time.

Laser-assisted dentistry offers the clinician all of the above. Today, we are performing old procedures in new ways and obtaining equal or better results in a minimally invasive manner. Who would have thought that procedures such as gingival recontouring, frenectomies and restorative dentistry could even be attempted without local anaesthesia? Today, in the hands of a trained and competent dentist, these procedures are becoming routine and an increasing number of patients are hearing of the positive experiences of their friends who have undergone laser dentistry.

Few dentists will pass up any technology that can differentiate their practice from all the rest and that offers undeniable benefits to their patients. Clinical dental lasers are just that type of technology. I encourage everyone to ask questions and take the time to deliberate the investment, but be open-minded enough to recognise the enormous benefits for your patients and your dental office.

### **Fig. 1 \_Pre-op situation.**

A 25-year-old patient desired elimination of a “gummy smile” and bulbous areas of her teeth in an effort to obtain a more mature appearance. Orthodontic correction had been completed one year prior to consultation. The patient desired “rock star” white teeth (value) and a new smile to harmonise with her facial features and skin tone. She specifically requested porcelain veneers.



**5<sup>TH</sup>** INTERNATIONAL CONGRESS IN  
IMPLANTOLOGY & ESTHETIC DENTISTRY

# THE **CUTTING EDGE** OF CLINICAL DENTISTRY

## LECTURES

SWITZERLAND

PASCAL MAGNE

MICHEL MAGNE

DIDIER DIETSCHI

UELI GRUNDER

MARKUS HURZELER

USA

SASCHA JOVANOVIC

GREECE

PANOS BAZOS

### CHAIRMEN:

PANOS BAZOS, GREECE

STAVROS PELEKANOS, GREECE

**SEPTEMBER 23-24 2011 ATHENS, GREECE**

ATHENAEUM INTERCONTINENTAL HOTEL & CONVENTIONAL CENTER  
103 - 105, SYNGROU AVENUE, ATHENS

Conference Fee (lectures only):

183 EUR until June 30, 2011

240 EUR until Sept 5, 2011

300 EUR from Sept 6, 2011 until upon registration

ORGANIZED BY



MEDIA PARTNERS



SPONSORS



More information & registration:

Tel: +30 210 222 2637 +30 210 213 2084 [omnipress@omnipress.gr](mailto:omnipress@omnipress.gr) web: [www.omnicongresses.gr](http://www.omnicongresses.gr) [www.omnipress.gr](http://www.omnipress.gr)



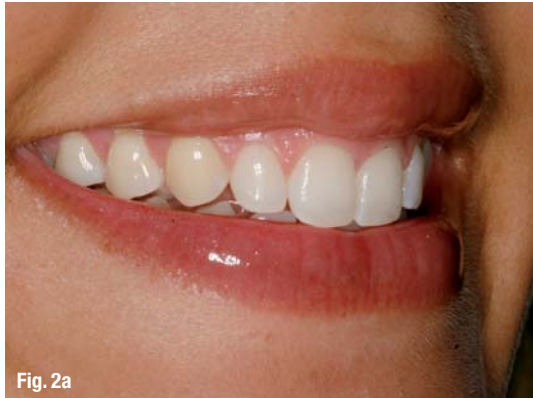

Fig. 2a

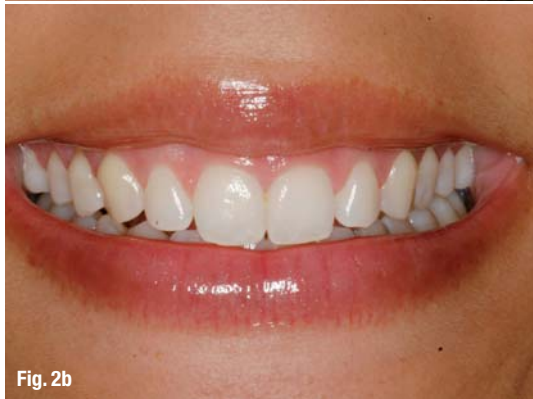

Fig. 2b

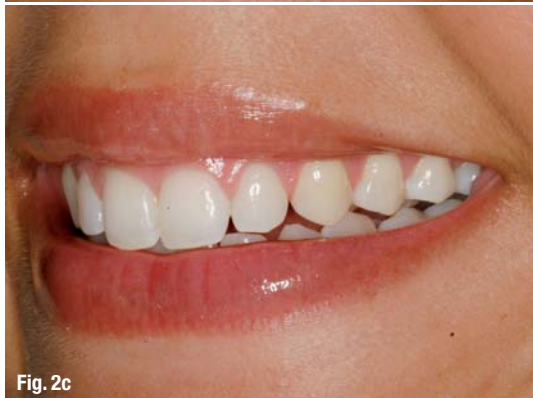

Fig. 2c

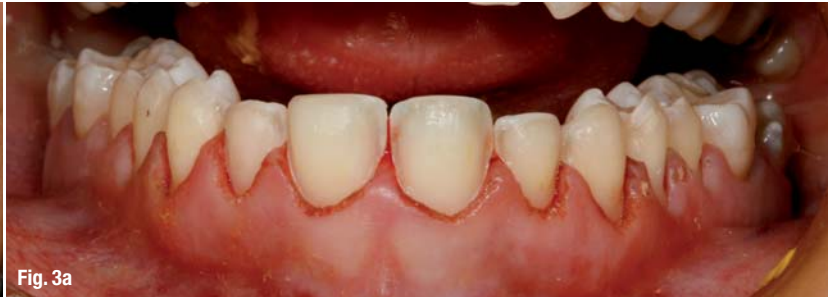

Fig. 3a

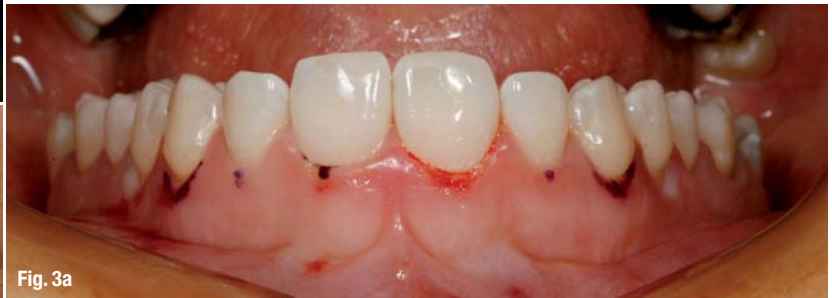

Fig. 3a

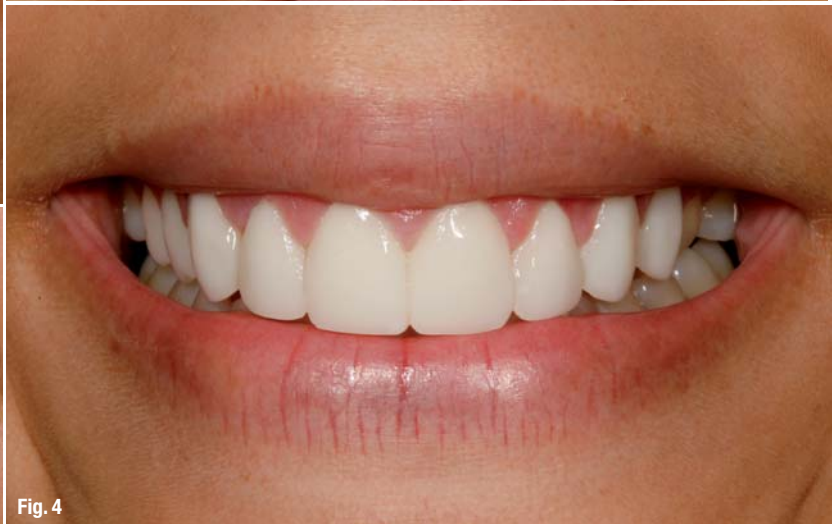

Fig. 4

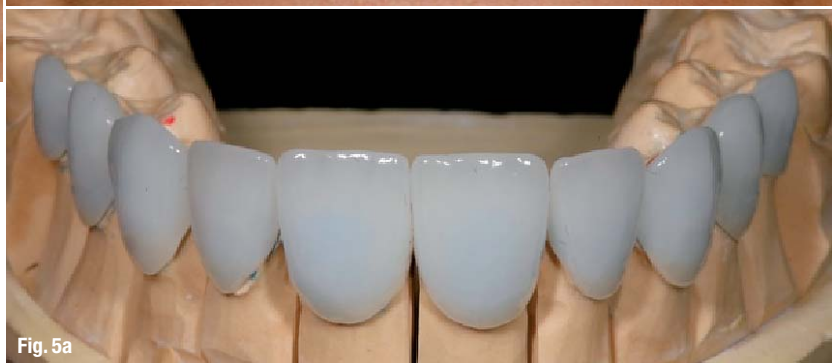

Fig. 5a

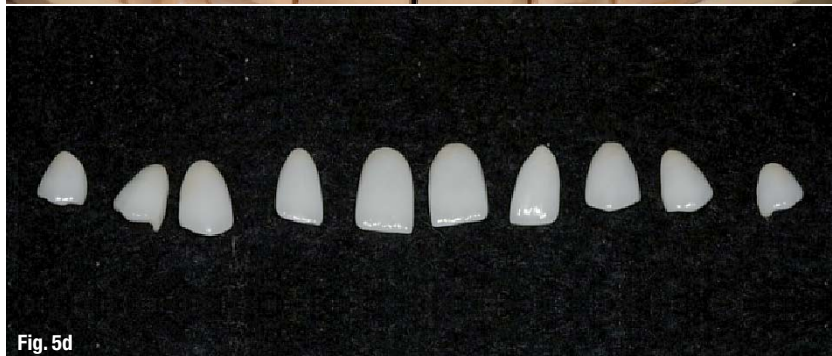

Fig. 5d

**Figs. 2a–2c** 1:2 view of pre-op natural smile.

The patient has a beautiful natural smile. The options presented to the patient were: 1) whitening; 2) gingival recontouring and enameloplasty to recontour existing bulbous cervical areas that were of concern to the patient; and 3) porcelain veneers with gingival recontouring and osseous crown lengthening in areas in which biological width would have to be violated in order to obtain correct gingival zenith heights determined during smile design.

**Figs. 3a & b** Gingival zeniths are marked and raised with the Waterlase MD Er,Cr:YSGG laser system. Osseous correction is accomplished over teeth #7 to 10 utilising a closed technique to modify the bone architecture between the line angles and not encroaching into the interproximal area.

**Fig. 4** Temporary restorations are placed and gingival tissue is evaluated for the desired aesthetic outcome.

Once the patient is satisfied with the corrections, the fabrication of the final porcelain restorations proceeds.

**Figs. 5a & b** Porcelain restorations prior to try-in and evaluation.

The following is a case I would like to share that illustrates the typical patient seeking cosmetic care in our office. By utilising laser technology, we were able to accomplish a complex treatment in a short period, while obtaining excellent tissue health and a nice cosmetic result that yielded an advocate for our office and for laser technology.

At our first consultation, the patient elected just whitening. One year later, she returned and elected to proceed with the porcelain veneers and laser gingival recontouring and crown lengthening as needed to design the smile she desired.

This case illustrates that our conservative approach to treatment can be achieved by utilising minimally invasive tools such as the Waterlase MD. There are many ways to accomplish any given dental task and no one uses the same bur for every preparation or the same hand instrument for every task. With that in mind, consider the Waterlase MD another tool that

can be utilised and added to your clinical "tool-box". When presented with daily tasks such as crown lengthening and gingival recontouring, remember that there may be many ways to accomplish the same task and today they involve minimally invasive techniques that eliminate scalpel and/ or other mechanical methods. A positive patient experience is a powerful tool that you can utilise to expand your practice. It is an exciting time in dentistry and every visit is an opportunity to show our patients the reason that they should be excited as well!\_

\_contact

laser

**Dr Patrick J. Broome**

2809 Coltsgate Rd Ste 200

Charlotte, NC 28211

USA

pjbroome@hotmail.com

**Figs. 6a-d**\_ Final bonded restorations and final tissue contours four weeks after initial preparation. Note tissue contour stability and health.

**Figs. 7**\_ The patient is satisfied that her aesthetic goals were accomplished and pleasantly surprised that a complete solution was possible in such a short period (three weeks).

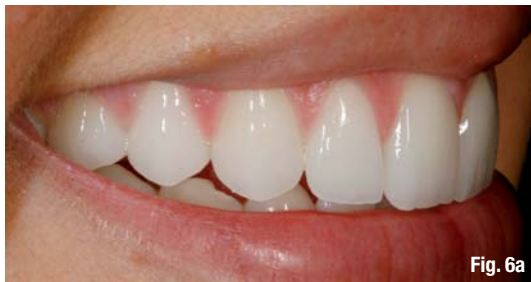

Fig. 6a

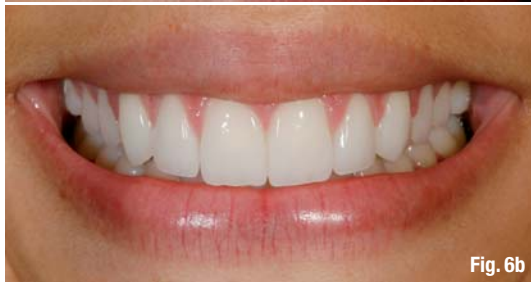

Fig. 6b

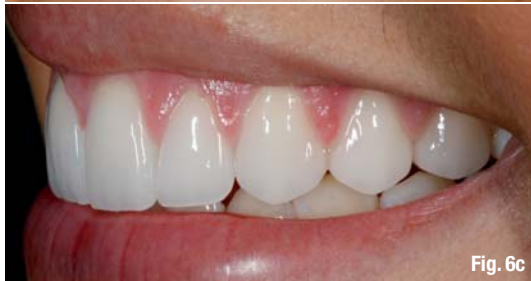

Fig. 6c

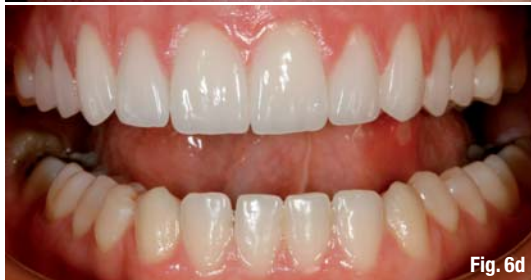

Fig. 6d




Fig. 7



# Treatment of gingival hyperpigmentation for aesthetic purposes using the diode laser

**Author\_ Drs M.L.V. Prabhuji, S.S. Madhupreetha & V. Archana, India**

**\_The colour of the gingiva** is various among different individuals and it is thought to be associated with cutaneous pigmentation. It depends on the vascular supply of the gingiva, epithelial thickness, degree of keratinisation of the epithelium and the presence of pigmented cells.

Oral pigmentation is the discolouration of the mucosa or gingiva. It can be either due to physiological or pathological conditions. Melanin, a brown pigment, is the most common pigment associated with the etiology of oral pigmentation.

Gingiva is the most common site of pigmentation in the oral cavity. This hyperpigmentation is seen as a genetic variation in some populations independent of their age and sex. Hence it is termed as physiological or racial gingival pigmentation. Melanosis of the gingiva is frequently present in dark skinned ethnic groups as well as in different medical conditions. Although pigmentation of the gingiva is completely a benign condition, it is an esthetic problem in many individuals.

Gingival depigmentation is a periodontal surgical procedure in which the gingival hyperpigmentation is eliminated or reduced by different techniques.

## **\_Gingival depigmentation techniques**

Various depigmentation techniques have been employed with similar results. Selection of a technique should be based on clinical experience and individual preferences.

The various methods include gingivectomy, gingivectomy with free gingival autografting, electrosurgery, cryosurgery, radiosurgery, chemical agents such as 90% phenol and 95% alcohol, abrasion with diamond bur, Nd:YAG laser, semiconductor diode laser and CO<sub>2</sub> laser.

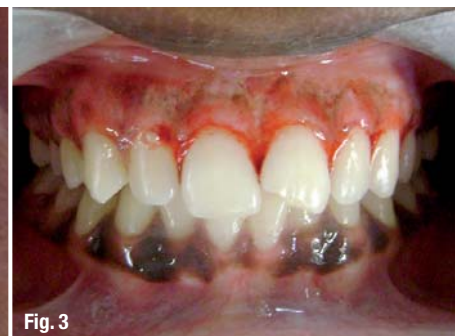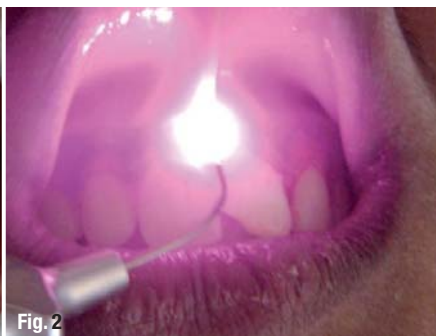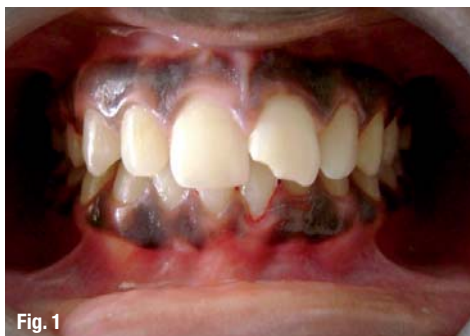One of the most common techniques for depigmentation is the surgical removal of undesirable pigmentation using scalpels. In this procedure, gingival epithelium is removed surgically along with a layer of underlying connective tissue. The denuded connective tissue then heals by secondary intention.

Laser ablation of gingival depigmentation has been recognized as one of the effective techniques. Different lasers have been used for gingival depigmentation including carbon dioxide (10.600 nm), diode (810 nm), Neodymium:Yttrium Aluminium garnet (1.064 nm) and Erbium: YAG (2.940 nm) lasers.

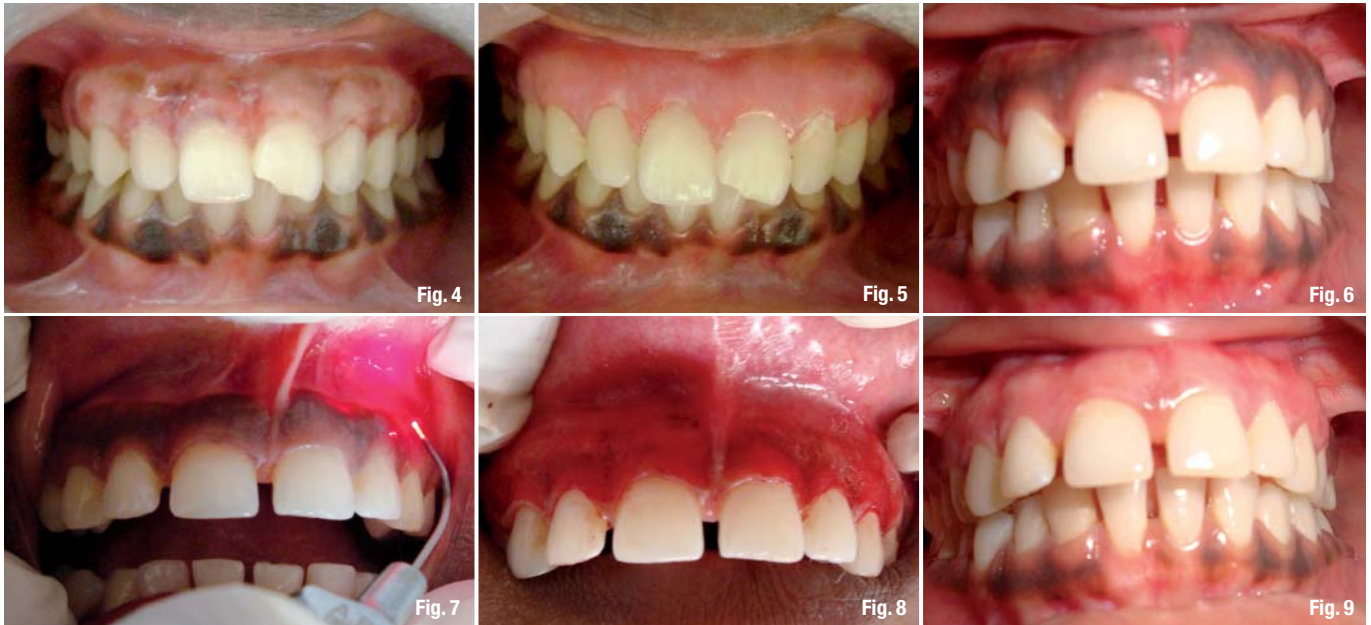**Fig. 1** \_Pre-op situation.

**Fig. 2** \_Use of the FOX diode laser to treat gingival pigmentation.

**Fig. 3** \_Immediate post-op situation.







The diode laser has been introduced in dentistry few years back. The diode laser is a solid-state semiconductor laser that typically uses a combination of Gallium (Ga), Arsenide (Ar), and other elements, such as Aluminium (Al) and Indium (In), to change electrical energy into light energy. It also can be delivered through a flexible quartz fiber optic handpiece and has a wavelength of 819 nm. This energy level is absorbed by pigmentation in the soft tissues and makes the diode laser an excellent hemostatic agent. It is used for soft tissue removal in a contact mode. The power output for dental use is generally around 2 to 10 watts. It can be either pulsed or continuous mode.

The present case series describes simple and effective depigmentation techniques using A.R.C. Fox™ (semiconductor diode laser), which have produced good results with patient satisfaction.

### Case report 1

A 22 year old female patient visited the department of Periodontics, Krishnadevaraya College of Dental sciences, Bangalore with the chief complaint of "blackish gum". The medical history was non-contributory. Intra-oral examination revealed generalized blackish pigmentation of the gingiva, however it was healthy and completely free of any inflammation. Considering the patient's concern, a laser depigmentation procedure was planned.

#### *Procedure*

Diode Laser (A.R.C. Fox™) with wavelength of 810 nm was selected for the procedure. No topical or local anaesthesia was given to the patient. Melanin pigmented gingiva were ablated by diode laser vapor-

ization with a flexible, hollow-fiber delivery system with a non-contact, air cooling handpiece, under standard protective measures. The procedure was performed on all pigmented areas. Remnants of the ablated tissue were removed using sterile gauze dampened with saline. This procedure was repeated until the desired depth of tissue removal was achieved. Analgesics and chlorhexidine 0.2% mouthwash were prescribed.

### Case report 2

A 24 year old female patient visited the department of Periodontics, Krishnadevaraya College of Dental sciences, Bangalore with the chief complaint of "blackish gum". The medical history was non-contributory. Intra-oral examination revealed generalized blackish pigmentation of the gingiva, however it was healthy and completely free of any inflammation. Considering the patient's concern, a laser depigmentation procedure was planned.

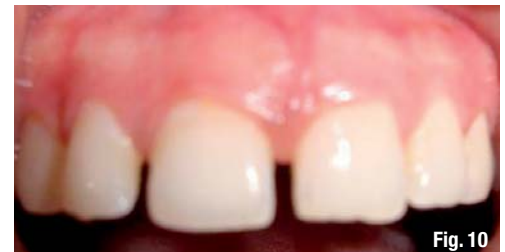#### *Procedure*

The depigmentation was performed identically to the first case. Analgesics and chlorhexidine 0.2% mouthwash were prescribed.

### Results

No post-operative pain, haemorrhage, infection or scarring occurred in first and subsequent visits. Healing was uneventful. Patient's acceptance of the procedure was good and results were excellent as perceived by the patient.

**Fig. 4** \_One week post-op.  
**Fig. 5** \_Three months post-op.  
**Fig. 6** \_Pre-op situation.  
**Fig. 7** \_Use of the FOX diode laser to treat gingival pigmentation.  
**Fig. 8** \_Immediate post-op situation.  
**Fig. 9** \_One week post-op.



**Fig. 10** \_Three months post-op.

**\_contact** **laser**

**Department of Periodontics**  
Krishnadevaraya College of Dental Sciences  
Hunasamaranahalli,  
Via Yelahanka  
Bangalore, 562157  
India

prabhujimlv@gmail.com

# Diode-laser-assisted combination therapy of a lip haemangioma

Author\_Dr Georg Bach, Germany

**Fig. 1** Equipment needed for creating an ice-block: toothpick, rubber bands, fibre holder and cut-off bottom portion of a single-serving yoghurt container.



Fig. 1

**Fig. 2** To prevent the fibre-holding channel from icing up, its end is sealed with sticky wax, which can also be used for placement on the bottom of the plastic container.

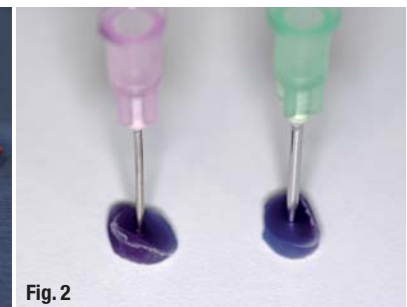


Fig. 2

As a general rule, haemangioma—also referred to as a “blood sponge”—is a broader term for many different vascular abnormalities. The treatment of haemangiomas, especially in dental practice, requires a clear distinction between congenital vascular tumours and vascular malformations.

tered in dental practice and affects primarily the lip area. A multitude of possible treatment options is mentioned for treatment of a vascular malformation of the lip.

## *Surgical treatment*

Owing to intra-surgical complication rates (haemorrhaging), which are the exception to the rule today, surgery is only carried out in special clinics, especially if functional disruptions are expected because of a rapidly growing haematoma and non-surgical treatments do not promise success.

Modified surgical procedure according to Prof H. Deppe:

\_tapping of the haemangioma;

**Fig. 3** To affix the fibre holder securely, it is stabilised with rubber bands and a toothpick, which serves as a holding strip.

**Fig. 4** The container is filled with water.

**Fig. 5** An ice-block with a fibre holder is moulded in the freezer.

Congenital vascular haemangiomas are relatively rare in dental practice. They occur in babies and toddlers and show a typical three-phase course: the initial phase is often marked by massive growth (“proliferation phase”), and the subsequent remission phase is then followed by an obligatory regression (“regression phase”). The typical three-phase clinical course usually enables a unique differentiation from a malformation, which—contrary to congenital haemangiomas—is often encoun-

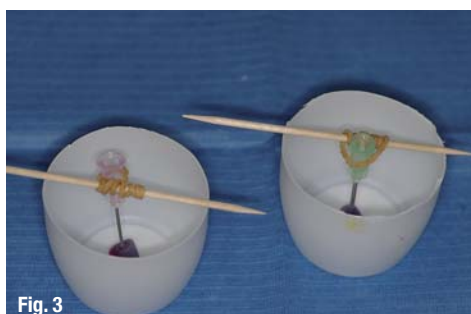

Fig. 3



Fig. 4



Fig. 5

\_aspiration of the blood;  
 \_injection of polyether impression material;  
 \_hardening of the material; then  
 \_surgical removal of the haemangioma into which  
 the impression material has been injected with con-  
 siderably reduced intra-surgical haemorrhaging.

### Cryotherapy

This treatment is usually successful in haeman-  
giomas with a thickness of up to 5 mm, with very few  
side-effects. However, cryotherapy for the lip is the  
subject of controversial discussion because of the  
risk of scar formation.

### \_Laser-assisted treatment

Nd:YAG and diode lasers are primarily used here;  
isolated cases of treatment with yellow-light and  
argon lasers are also described in the literature. Med-  
ication (corticosteroids, in some cases also cytostat-  
ics) often used in the treatment of other haeman-  
giomas is not relevant in the case of lip haeman-  
giomas.

This report describes a combination treatment  
consisting of pre-surgical cooling and intra-surgical  
diode-laser use with simultaneous cooling with an  
ice-block into which the fibre is directed.

### Goal

Diode lasers are the most common dental lasers in  
German dental clinics and dental clinics worldwide.  
These lasers are used primarily and very successfully  
for combating biofilm in the treatment of peri-im-  
plantitis, marginal periodontitis and endodontics.

Diode-laser light with a wavelength of 810 nm is  
absorbed extremely well by dark surfaces and thus  
also by blood. Use of a diode laser for the treatment  
of haemangiomas in an ideal situation, that is, with  
controlled thermal coagulation, would thus be con-  
ceivable. Reports on treatment with other laser  
wavelengths (Nd:YAG, CO<sub>2</sub>, Argon and yellow-light  
lasers), which have been used for treating haeman-  
giomas for years, often mention tissue necrotisation  
and post-surgical complications after laser treat-  
ment. These consequences are undesirable for tissue  
in aesthetically relevant areas, which most certainly  
include the lips, and are viewed critically by patients.

The central idea of the treatment of lip haeman-  
giomas with diode-laser-assisted therapy is to com-  
bine the excellent absorption of diode-laser light  
with a wavelength of 810 nm and simultaneous cool-  
ing with an ice-block in order to keep the side-effects  
described to a minimum or, ideally, to prevent them.

### \_Making a combination ice/fibre-hold- ing block

The ice-block should be an ideal size and shape.  
Based on our experience, this can easily be achieved  
by using the cut-off bottom portion of a single-

AD



**WFLD**  
The art of the light  
**2012** April 26 - 28 **2012**  
**Barcelona**



**XII Congreso de la S.E.L.O.**  
*Sociedad Española de Láser  
Odontoestomatológico*



Venue  
**Hotel Hesperia Tower**

*Science & Fun*

**Key dates:**  
**Abstract submission deadline;**  
**December 15, 2011**  
**Early registration fees deadline;**  
**January 20, 2012**

**www.wfldbcn2012.com**



<b>Congress Technical Secretariat</b> TILES A KENES SPAIN c/ Provença, 385 6-C 08025 Barcelona Tel: +34 932 182 061 wfl2012@kenes.com	<b>SELO Technical Secretariat</b> Mdv-Organización y Protocolo c/ Bruc, 28 2n. 08010 Barcelona Tel: +34 607 499 365 mdv@emedeuve.com
--	---





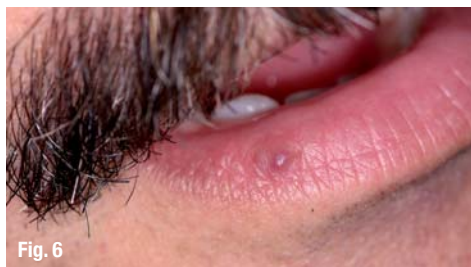

Fig. 6




Fig. 7

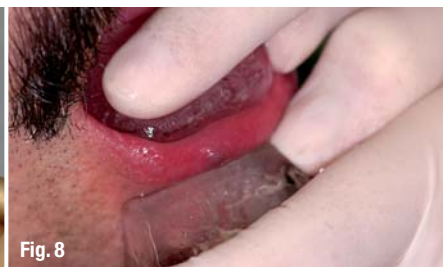

Fig. 8

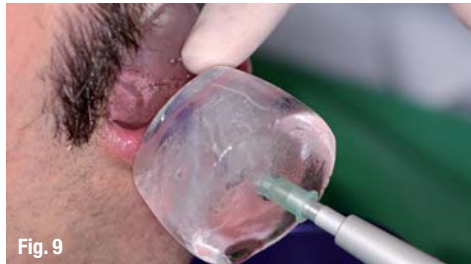

Fig. 9

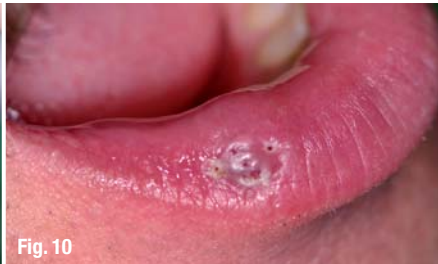

Fig. 10

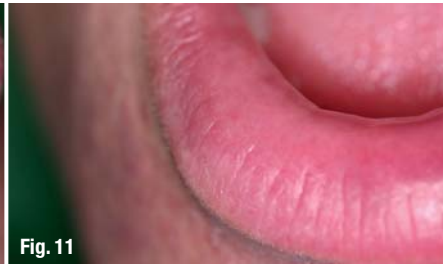

Fig. 11

**Fig. 6\_** Hemangioma on right half of lower lip.

**Fig. 7\_** The fibre can be pushed through the fibre channel in the ice-block to the lip haemangioma that requires treatment.

**Fig. 8\_** Pre-surgical cooling around the haemangioma using an ice-block without a fibre holder.

**Fig. 9\_** Ice-block application; laser application.

**Fig. 10\_** Note the circular "injections", which demonstrate the expansion of the haemangioma.

**Fig. 11\_** Condition four weeks post-treatment.

serving drinkable yoghurt container as a mould for the ice-block. In order to direct the fibre through this ice-block, a disposable fibre holder (diameter must fit the fibre to be inserted) must be placed with the aid of a toothpick and rubber bands in such a way that it is centred and in contact with the bottom of the container. The container is then filled with water and placed in a freezer to freeze the block. A second (and possibly third) ice-block without a fibre holder should be created for the pre-surgical "cooling phase", which should occur approximately ten minutes prior to the laser treatment. The block's bulbous form conforms ideally to the shape of the lips.

## Clinical application

Prior to the laser-assisted treatment, small amounts of local anaesthetic (approximately 8 x 0.1 ml) are injected around the haemangioma. The number of areas in which anaesthetic is injected can be reduced slightly in the case of smaller haemangiomas (this treatment is not suitable for very large lip haemangiomas).

Immediately after the local anaesthetic, the ice-block without fibre is used to cool the area for ten minutes (if possible, covering the entire haemangioma). The ice-block is then exchanged, the ice-block with the integrated fibre holder is placed onto the haemangioma, fitting it as closely as possible, and the laser fibre is then pushed through. Fibres with a diameter of 400 µm have proven to be suitable for this application; they are a good compromise between the achievable surface effect and minimum tissue trauma.

In the subsequent application of the laser, the fibre penetrates the lip surface and is inserted into the haemangioma up to a maximum of 5 mm. Ideally, the final position of the fibre will be in the centre of the haemangioma surface. After a ten-second appli-

cation of the laser, the fibre is removed and the position of the ice-block adjusted a little; then the same procedure is followed on a different, untreated area of the haemangioma. Treatment is completed when all areas of the haemangioma have been treated.

It is recommended that a second ice-block with fibre holder be available as a back-up to ensure that the haemangioma is constantly and perfectly covered. During treatment, the patient is covered with absorbent sheets to catch the melting water from the ice-block running from the lip to the ventral area.

## Laser parameters

A diode laser that uses high pulse or digital pulse technology (elexxion) and emits laser light with a wavelength of 810 nm was used for combination treatment of a lip haemangioma. Pulse performance is 30 W at a frequency of 20,000 Hz with a pulse duration of 16 µs.

## Conclusion

The combination treatment presented here, which entails simultaneous cooling during the use of a laser for treatment of a lip haemangioma, is a high-quality alternative to established procedures.

Its application is fairly simple and the advantage is that there are only minimal post-surgical complaints (minimal pain or swelling, very little scarring). Laser-assisted treatment of a lip haemangioma using a diode laser has distinct advantages compared with lasers with other wavelengths for treatment of medium-sized and small haemangiomas. The application of diode lasers is limited in the case of extensive haemangiomas.

The prevalence of diode lasers in dental and oral and maxillofacial surgical clinics supports the availability of this treatment.

## contact

## laser

### Dr Georg Bach

Oral surgery specialist  
Rathausgasse 36  
79098 Freiburg/Breisgau,  
Germany

doc.bach@t-online.de

# Periodontitis therapy with 3,000% more power

**Author** \_Dr Darius Moghtader, Germany

*\_Sometimes by asking questions that nobody has ever asked before you break new ground. In my case, this was: how can I help periodontitis patients even more effectively? And the simple answer is: with the "3,000% more power" therapy.*

*What's that?*

*Is that dangerous?*

*How is that supposed to work?*

*Why do we need this?*

*What's that supposed to mean?*

No one had asked me these questions when I presented the concept developed in our office in 2007 as a pilot project at IDS. Nevertheless, I shall answer these previously unasked questions here.

## **\_The idea**

I came upon the idea of a different way to treat periodontitis while researching literature on the topic of lasers. The 2003 Yukna Report<sup>1</sup> described the LANAP method. This Laser-Assisted New Attachment Procedure promised regeneration instead of repair, combined with a spectacular design. Dr Yukna of New Orleans, Louisiana, had three female patients, each of whom agreed to undergo the study on two single-rooted teeth with plaque. One tooth in each patient was treated using the LANAP method and the other with the Nd:YAG laser in accordance with a standard protocol.

And here's the kicker (this would happen only in the US): after monthly recalls, both teeth were removed from the bone block in all three patients!

The histological results showed regenerated bone and new periodontal ligament in two of the three LANAP teeth. The control group had only one long functional epithelium. Neither the root surface nor the pulp showed histological changes.

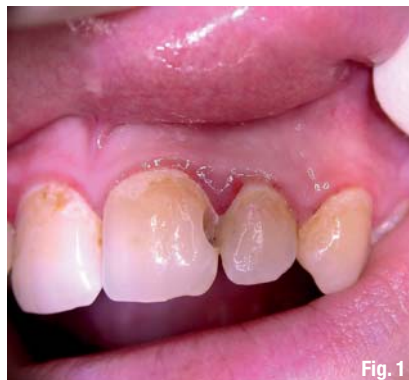

Fig. 1

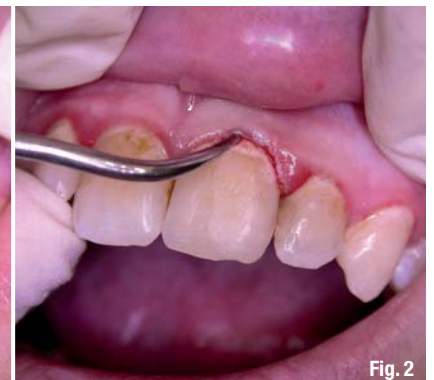

Fig. 2

So far so good—anyone who knows me knows that, as a general dentist, I am a fan of the diode laser. The only Nd:YAG laser that can handle the LANAP procedure and is patented for the job is the Millennium Laser from the undisputed master inventor and laser pioneer Dr Robert H. Gregg.

**Fig. 1** \_Initial scenario.

**Fig. 2** \_Opening the socket.

## **\_The method**

I analysed which factors were different from a standard laser protocol and tried to adapt the diode-laser procedure accordingly. Thanks to the support of ellexion, I was able to develop a protocol for the claros at 30W and 20,000Hz.

*What clinical indication of successful treatment can we expect based on the Yukna Report?*

**Fig. 3** \_Elap-p, the first time around.

**Fig. 4** \_Plaque and toxin removal.

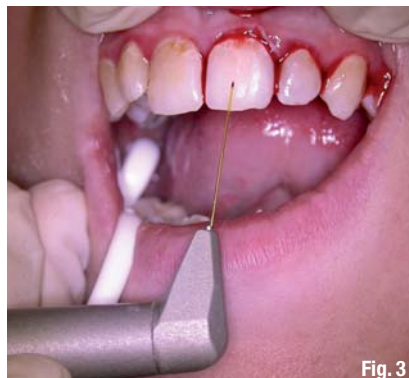

Fig. 3

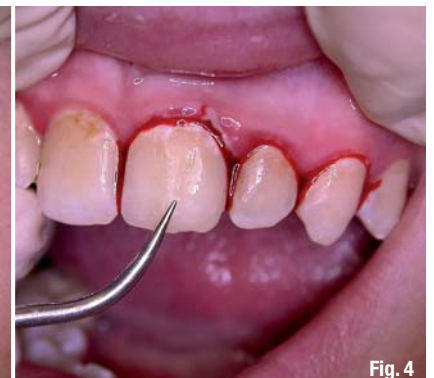
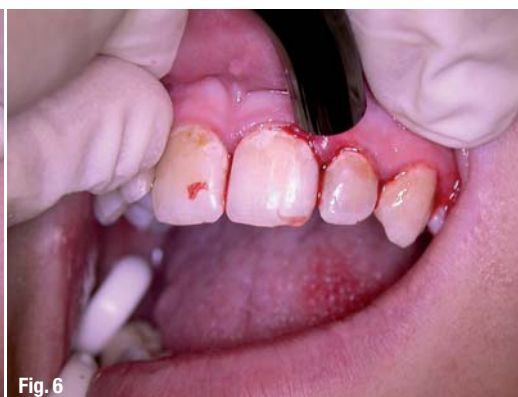
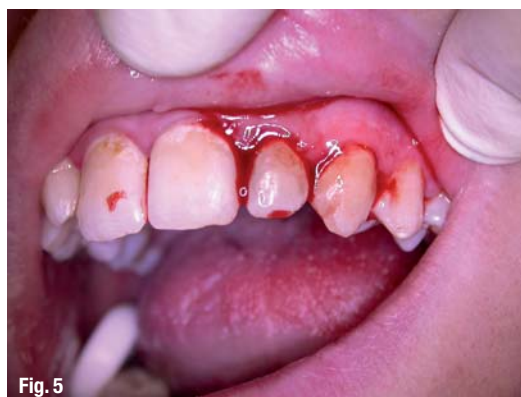Fig. 4

**Fig. 5** \_Elap-p, the second time around.

**Fig. 6** \_Soft laser treatment.



Such an indication is bleeding from the treated socket. As a laser user, I am sure you know that treated sockets can become very dry after normal laser treatment. Many manufacturers even use this as a selling point, and the patient is satisfied as well—after all, there is no more bleeding. The problem is, no blood means no regeneration, no healing, no new bone. Every dentist is familiar with the problems caused by dry sockets. Schulte addressed this concept in the filling of cysts with autologous blood.

### The questions

#### *How do we achieve this?*

We achieve this with extremely short impulses at very high wattage levels.

#### *Is this safe for the patient?*

In order to answer this question, we asked Dr I. Krejci of the University of Geneva to conduct a pilot study in 2007. The results of the study can be summarised as follows. At the recommended tested settings, a temperature reduction of up to 20% occurred compared with treatment with a 1.11 W continuous wave. There were no significant electron microscopical changes to the root. At these settings, no carbonisation of the root surfaces took place. Of course, further studies are necessary and desirable to corroborate these results.

#### *Why do we need this?*

The goal is greater regeneration instead of repair.

#### *How does this work?*

This works using elap-p, a procedure developed in the dentist's office for the dentist's office.

#### *What is elap-p?*

Simply put, elap-p means the following: 3,000% more power with up to 20% less heat generation with no carbonisation or coagulation.

Every dentist has experienced first-hand the scenario below.

### Case study

#### *Initial scenario*

The patient comes into the office on Friday evening with sharp shooting pains and was not able to sleep the night before. Pain medication works only for a short period. Redness and bleeding clearly indicate an acute periodontal cause.

#### *Opening the socket*

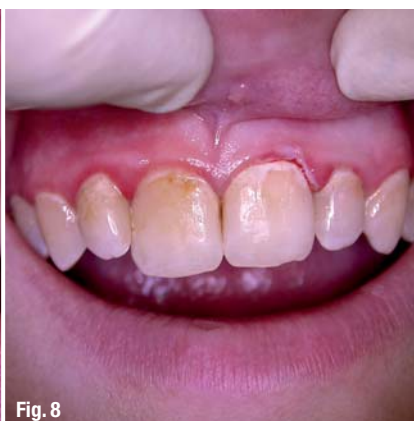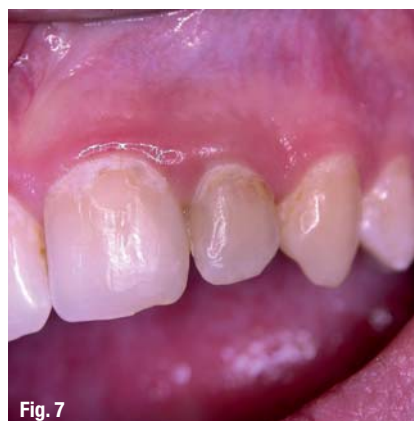After local anaesthesia, a traditional cleaning, including plaque removal, is first performed, either with an Er:YAG laser or, as shown here, through an ultrasonic periodontal probe. Of course, manual instruments can also be used if preferred. This allows the laser fibre easy access to the site of the inflammation.

#### *Elap-p, the first time around*

Laser decontamination is performed using the 810 nm, 30 W, 5,000 Hz diode laser at a pulse duration of 10  $\mu$ s. The average measured output from the 400  $\mu$ m fibre tip is 1.2 W. Using the periodontal handpiece, the surface of each tooth is treated in a grid pattern for 5 seconds, i.e. about 20 seconds per tooth. Forced intentional bleeding occurs with no coagulation or carbonisation.

**Fig. 7** \_Follow-up after 48 hours.

**Fig. 8** \_Comparison between treated side and untreated side.





*Plaque and toxin removal*

The Er:YAG laser, ultrasonic periodontal probe or manual instruments are once again used to remove bacterial debris, toxins (antigens) and plaque.

*Elap-p, the second time around*

Laser decontamination is repeated using the 810nm, 30W, 5,000Hz diode laser at a pulse duration of 10µs with an average output from the 400µm fibre tip of 1.2W. Using the periodontal handpiece, the surface of each tooth is treated in a grid pattern for 5 seconds, i.e. about 20 seconds per tooth. With a knock-on effect (repeated laser decontamination) on bacteria and intentional forced bleeding with no carbonisation or coagulation, the unique effect of the 30W pulse on the tissue shows an excellent healing prognosis and minimal damage to the gingival tissue, as the blood contains everything necessary for tissue regeneration or repair.

*Wound closure*

The socket is closed through bidigital pressing of the gingiva.

*Soft laser treatment*

Soft laser treatment is then performed at 75 MW, 8,000Hz and 9µs for two minutes to alleviate pain and accelerate wound healing.

*Follow-up after 48 hours*

The patient comes in on Monday at 8:30 a.m. and reports immediate pain relief directly after treatment. She was able to enjoy the weekend without pain medication or antibiotics and was able to eat anything she wanted later in the evening following treatment.

**\_Comparison between treated side and untreated side**

For mobility grades higher than 1, simple acid-etch composite splinting is required. Premature contact leading to non-physiological stress must generally be removed. Naturally, after successful acute treatment, systematic periodontal treatment is to be performed.

Wishing you successful tooth maintenance! \_

**\_contact** **laser**

**Dr Darius Moghtader**

In den Weingärten 47  
55276 Oppenheim,  
Germany

[www.oppenheim-zahnarzt.de](http://www.oppenheim-zahnarzt.de)  
[www.laser-zahn-arzt.de](http://www.laser-zahn-arzt.de)

AD

LaserHF®

# Laser meets Radio Frequency



## LaserHF®

**Worldwide first combined Laser plus HF unit**

- Pre-adjusted programs for all dental soft tissue treatments, with individual programming
- Easy handling by dual operating concept: touch-screen and automatic starting system
- Modern radio frequency surgery (2.2 MHz) allows easy, fast and precise cutting
- Diode laser (975 nm) for periodontology, endodontology and implant exposure
- Therapeutic laser (650 nm) for Low Level Laser Therapy (LLLT) and antimicrobial Photodynamic Therapy (aPDT)
- Good value of money

[www.hagerwerken.de](http://www.hagerwerken.de)

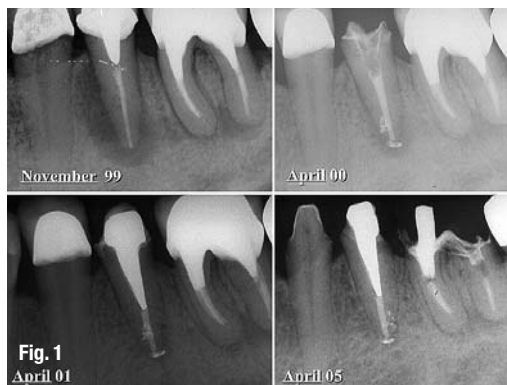
Tel. +49 (203) 99269-26 · Fax +49 (203) 299283

**HÄGER  
WERKEN**

# The antibacterial effects of lasers in endodontics

Author\_Dr Selma Cristina Cury Camargo, Brazil

**Fig. 1** Success in endodontic treatment: apical radiolucency repair.



## Endodontic infection

The success of endodontic treatment reaches values between 85 to 97 per cent.<sup>1</sup> Adequate treatment protocols, knowledge and infection control are the basic components to achieve such values (Fig. 1).<sup>2</sup> It is well known that apical periodontitis is caused by the communication of root-canal microorganisms and their by-products with the surrounding periodontal structures. Exposure of dental pulp directly to the oral cavity or via accessory canals, open dentinal tubules or periodontal pockets, are the most probable routes of the endodontic infection.<sup>2,3</sup>

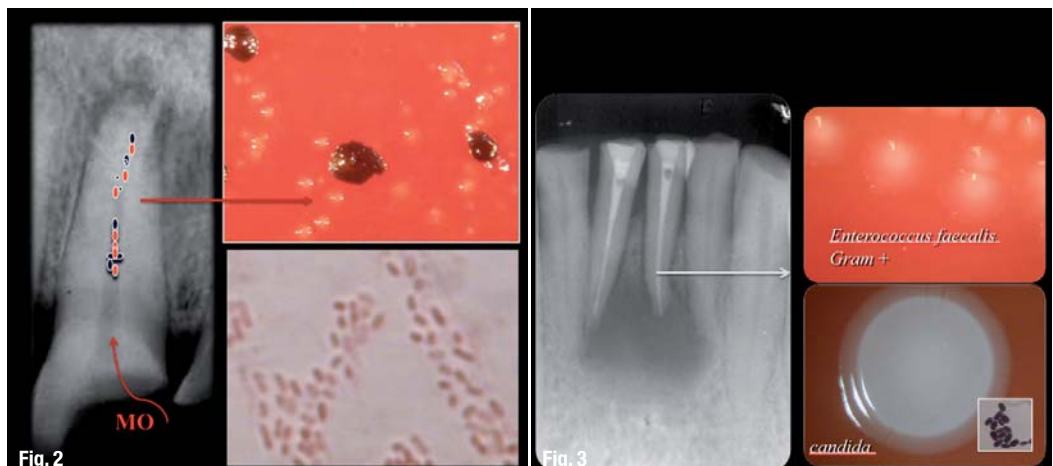
Clinically, apical periodontitis is not evident as long as the necrotic tissue is not infected with microorganisms.<sup>4-6</sup> There are up to 40 isolated species of bacteria present in the root canal. Cocci, rods, filaments, spirochetes, anaerobic and facultative anaerobic are frequently identified in primary infection, fungus can also be isolated.<sup>2,7</sup> Endodontic microbiota can be found suspended in the main root canal, adhered to the canal walls and deep in the dentinal tubules at a depth of up to 300 µm (Fig. 2). The absence of cementum dramatically increases bacteria penetration into dentinal tubules.<sup>8-11</sup>

It has been shown that bacteria can also be found outside the root-canal system, located at the apical cementum and as an external biofilm on the apex.<sup>12-15</sup> Following conventional endodontic treatment, 15 to 20 per cent of non-vital teeth with apical periodontitis fail.<sup>16-18</sup> The presence of bacteria after the decontamination phase or the inability to seal root canals after treatment are reasons for failure.<sup>2</sup> The remaining contamination in endodontically treated teeth is able to maintain the infectious disease process in the periapical tissue.

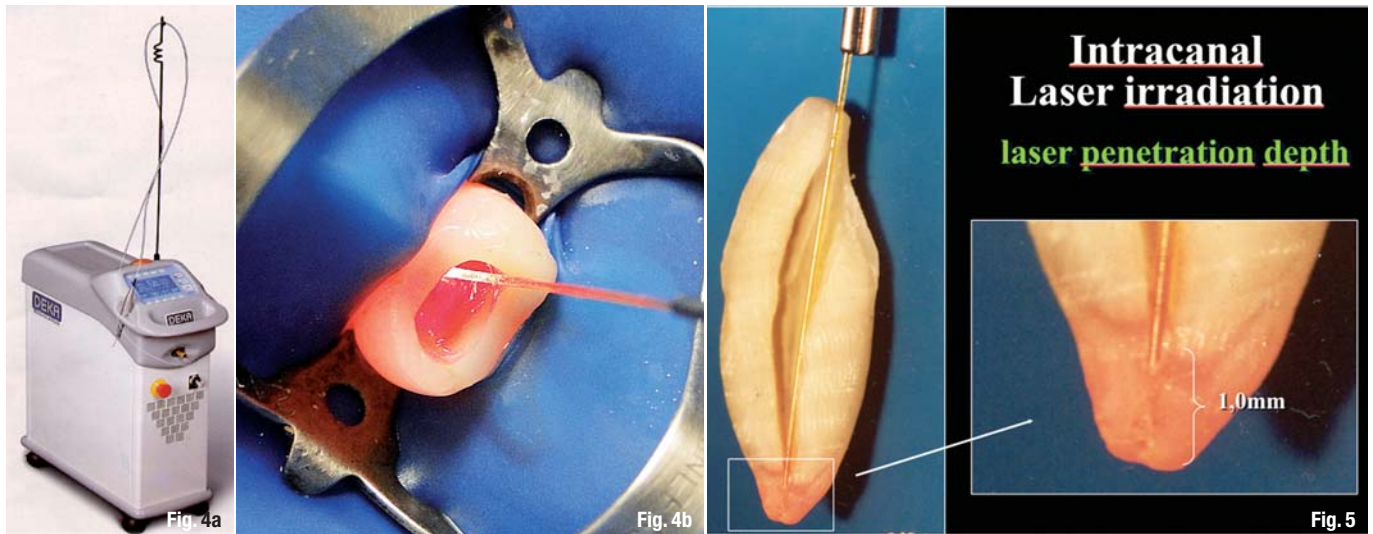
Retreatments are the first choice in failed root canals. The microbiota found in persistent infections

**Fig. 2** Primary infection. Black pigmented strains (a) and G-rods (b).

**Fig. 3** Persistent infection.







differs from that in primary infection (Fig. 3). Facultative anaerobic gram positive (G+) and negative (G-) microorganisms and fungus are easily found.<sup>19-21</sup> Special attention is given to *E. faecalis*, a resistant facultative anaerobic G+ cocci, identified in a much higher incidence in failed root canals.<sup>22-25</sup> The importance of bacterial control plays a significant role in endodontic success. Adequate and effective disinfection of the root-canal system is necessary. Based on that, all efforts must be done in order to achieve this result.

### Endodontic therapy

The bacterial flora of the root canal must be actively eliminated by a combination of debridement and antimicrobial chemical treatment. Mechanical instrumentation eliminates more than 90 per cent of the microbial amount.<sup>26</sup> An important point of note is the adequate shaping of the root canal. Evaluating the antibacterial efficacy of mechanical preparation itself, Dalton *et al.*<sup>27</sup> concluded that instrumentation to an apical size of #25 resulted in 20 per cent of canals free of cultivable bacteria, when a #35 size was made, 60 per cent showed negative results.

Irrigating solution has been associated with mechanical instrumentation to facilitate an instrument's cutting efficiency, remove debris and the smear layer, dissolve organic matter, clean inaccessible areas and act against microorganisms. Sodium hypochlorite is the most common irrigant used in endodontics.<sup>28</sup> It has an excellent cleansing ability, dissolves necrotic tissue, has a potential antibacterial effect and, depending on the concentration, is well tolerated by biological tissues. When added to mechanical instrumentation, it reduces the number of infected canals by 40 to 50 per cent.

Other irrigating solutions are also used during endodontic preparation. EDTA, a chelating agent used

primarily to remove the smear layer and facilitate the removal of debris from the canal has no antibacterial effect.<sup>29</sup> Chlorhexidine gluconate has a strong antibacterial activity to an extensive number of bacteria species, even the resistant *E. faecalis*, but it does not breakdown proteins and necrotic tissue as sodium hypochlorite does.<sup>30</sup>

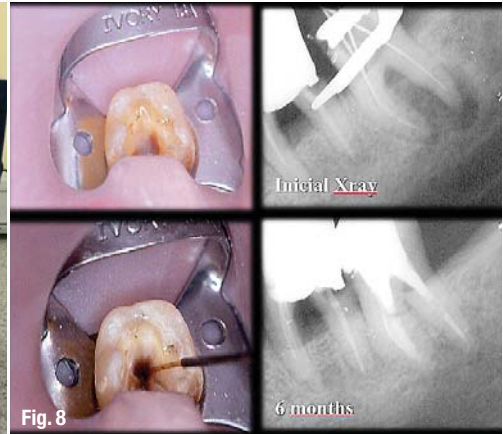
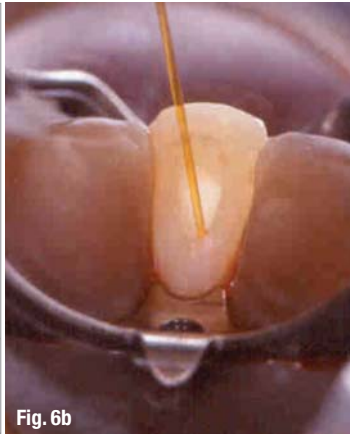
Because the association of mechanical instrumentation and irrigating solutions are not able to totally eliminate bacteria from the canal system—a status that is required for root-canal filling—additional substances and medicaments have been tested in order to suppress the gap that occurs in standard endodontic protocols. The principal goal of dressing the root canal between appointments is to ensure safe antibacterial action with a long-lasting effect.<sup>31</sup> A great number of medicaments have been used as dressing material, such as formocresol, camphorated parachlorophenol, eugenol, iodine-potassium iodide, antibiotics, calcium hydroxide and chlorhexidine.

Calcium hydroxide has been used in endodontic therapy since 1920.<sup>31</sup> With a high pH at saturation over pH 11, it induces mineralisation, reduces bacteria and dissolves tissue. For extended antibacterial effectiveness, the pH must be kept high in the canal and in the dentine as well. This ability depends on the diffusion through dentine tubules.<sup>32</sup>

Although most microorganisms are destroyed at pH 9.5, a few can survive over pH 11 or higher, such as *E. faecalis* and candida.<sup>21</sup> Because of the resistance of some microorganisms to conventional treatment protocols—and the direct relation between the presence of viable bacteria in the canal system and the reduced percentage of treatment success—additional effort has to be made to control canal system infection.

**Fig. 4a & b** Nd:YAG laser intra canal irradiation.

**Fig. 5** Nd:YAG laser irradiation, deep penetration.



**Fig. 6a & b**\_Diode 980 nm intra-canal irradiation.

**Fig. 7**\_Er:YAG laser.

**Fig. 8**\_Endodontic laser therapeutic plan.

## Lasers in endodontics

Lasers were introduced in endodontics as a complementary step to increase antibacterial efforts in conventional treatments. The antibacterial action of Nd:YAG, diodes, Er:YAG and photo activated disinfection (PAD) have been explored by a number of investigators. In the following section, each laser is evaluated with the aim of selecting an adequate protocol that will result in a high probability of success in teeth with apical periodontitis.

### Nd:YAG laser

The Nd:YAG laser was one of the first lasers tested in endodontics. It is a solid-state laser. The active medium is usually YAG-yttrium aluminum garnet (Y<sub>2</sub>Al<sub>5</sub>O<sub>12</sub>) where some Y<sup>3+</sup> are substituted for Nd<sup>3+</sup>. It is a four-level energy system operating in a continuous or pulsed mode. It emits a 1,064 nm infrared wavelength. Thus, this laser needs a guide light for clinical application. Flexible fibers with a diameter between 200 nm and 400 μm are used as delivery systems. It can be used intra canal, in contact mode (Fig. 4).

The typical morphology of root-canal walls treated with the Nd:YAG laser show melted dentine with a globular and glassy appearance, and few areas are covered by a smear layer. Some areas show dentinal tubules sealed by fusion of the dentine and deposits of mineral components.<sup>33,34</sup> This morphologic modification reduces dentine permeability significantly.<sup>35,36</sup> However, because the emission of the laser beam from the optical fiber is directed along the root canal, not laterally, not all root-canal walls are irradiated, which gives more effective action at the apical areas of the root.<sup>37</sup> Undesirable morphologic changes, such as carbonisation and cracks, are seen only if high parameters of energy are used.

One of the major problems for intra-canal laser irradiation is the increase of temperature at the external surface of the root. When laser light reaches a tis-

sue, a thermal effect occurs. The heat is directly associated to energy used, time and irradiation mode. An increase in temperature levels over 10° Celsius per one minute can cause damage to periodontal tissues, such as necrosis and ankylosis.

Lan (1999)<sup>38</sup> evaluated *in vitro*, the temperature increase on the external surface of the root after irradiation with a Nd:YAG laser under the following parameters of energy: 50 mJ, 80 mJ and 100 mJ at 10, 20 and 30 pulses per second. The increase of temperature was less than 10 degrees. The same results were obtained from Bachman *et al.* (2000)<sup>39</sup>, Kimura *et al.* (1999)<sup>40</sup> and Gutknecht *et al.* (2008).<sup>41</sup> In contrast to the external surface, intra-canal temperature rises dramatically at the apical area, promoting an effective action against bacteria contamination. For the Nd:YAG laser, 1.5 W and 15 Hz, are safe parameters of energy for temperature and morphological changes.<sup>33,41</sup>

The primary use of the Nd:YAG laser in endodontics is focused on elimination of microorganisms in the root-canal system. Rooney *et al.* (1994)<sup>42</sup> evaluated the antibacterial effect of Nd:YAG lasers *in vitro*. Bacterial reduction was obtained considering energy parameters. Researchers developed different *in vitro* models simulating the organisms expected in non-vital, contaminated teeth. Nd:YAG irradiation was effective for *B. stearothermophilus*,<sup>43,44</sup> *S. faecalis*, *E. coli*,<sup>45</sup> *S. mutans*,<sup>46</sup> *S. sanguis*, *P. intermedia*<sup>47</sup> and a specific microorganism resistant to conventional endodontic treatment, *E. faecalis*.<sup>48-50</sup> Nd:YAG has an antibacterial effect in dentine at a depth of 1,000 μm (Fig. 5).<sup>50</sup>

Histological models were also developed in order to evaluate periapical tissue response after intra-canal Nd:YAG laser irradiation. Suda *et al.* (1996)<sup>51</sup> proved in dog models that Nd:YAG irradiation that 100 mJ/30pps (pulses per second) during 30 seconds was safe to surrounding root tissues. Maresca *et al.* (1996),<sup>52</sup> using human teeth indicated for apical surgery, confirmed Suda *et al.*<sup>51</sup> and Ianamoto *et al.* (1998)<sup>53</sup> results. Koba *et al.* (1999)<sup>54</sup> analysed histopathological inflamma-



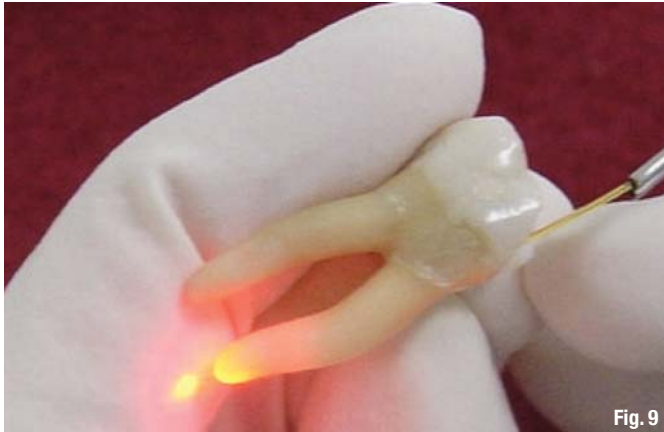

Fig. 9

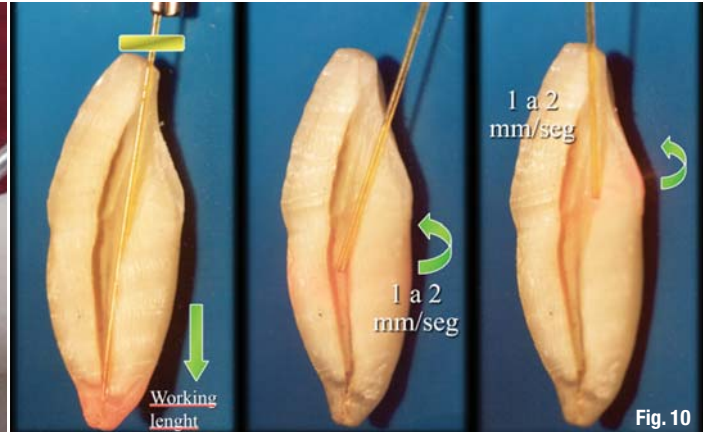


Fig. 10

tory response after Nd:YAG irradiation in dogs using 1 watt and 2 watts. Results showed significant inflammatory reduction in 4 and 8 weeks compared to the non-irradiated group.

Clinical reports published in the literature confirm the benefits of intra-canal Nd:YAG irradiation. In 1993, Eduardo *et al.*<sup>55</sup> published a successfully clinical case that associated conventional endodontic treatment with Nd:YAG irradiation for retreatment, apical periodontitis, acute abscess and perforation. Clinical and radiographic follow-up showed complete healing after 6 months.

Similar results were shown by Camargo *et al.* (1998).<sup>56</sup> Gutknecht *et al.* (1996)<sup>57</sup> reported a significant improvement in healing of laser-treated infected canals, when compared to non-irradiated cases.

Camargo *et al.* (2002)<sup>58</sup> compared *in vivo* the antibacterial effects of conventional endodontic treatment and conventional protocol associated to the Nd:YAG laser. Teeth with apical radiolucency, no symptoms and necrotic pulps were selected and divided into two groups: conventional treatment and laser irradiated. Microbiological samples were taken before canal instrumentation, after canal preparation and/or laser irradiation and one week after treatment. Results showed a significant antibacterial effect in the laser group compared to the standard protocol. When no other bactericidal agent was used, it is assumed that the Nd:YAG laser played a specific role in bacterial reduction for endodontic treatment in patients.

## \_Diodes

The diode laser is a solid-state semiconductor laser that uses a combination of gallium, arsenide, aluminium and/or indium as the active medium. The available wavelength for dental use ranges between 800 and 1,064 nm that emits in continuous and gated pulsed mode using an optical fibre as the delivery system (Fig. 6). Diode lasers have gained increasing

importance in dentistry due to their compactness and affordable cost. A combination of smear layer removal, bacterial reduction and less apical leakage brings importance to this system and makes it viable for endodontic treatment. The principal laser action is photo-thermal.

The thermal effect on tissue depends on the irradiation mode and settings. Wang *et al.* (2005)<sup>59</sup> irradiated root canals *in vitro* and demonstrated a maximum temperature increase of 8.1° Celsius using 5 watt for seven seconds. Similar results were obtained by da Costa Ribeiro.<sup>60</sup> Gutknecht *et al.* (2005)<sup>61</sup> evaluated intra-canal diode irradiation with an output set of 1.5 watts observed a temperature increase in the external surface of the root of 7 degrees Celsius with 980 nm of diode irradiation at a power setting of 2.5 watts at a continuous and chopped mode and demonstrated that the temperature increase never exceeded 47 degrees Celsius, which is considered safe for periodontal structures.<sup>41</sup>

Clean intra-canal dentine surfaces with closed dentinal tubules, indicating melting and recrystallisation, were morphological changes observed at the apical portion of the root after intra-canal diode irradiation.<sup>62</sup> In general, near infrared wavelengths, such as 1,064 nm and 980 nm, promote fusion and recrystallisation on the dentine surface, closing dentinal tubules.

The apparent consensus is that diode laser irradiation has a potential antibacterial effect. In most cases, the effect is directly related to the amount of energy delivered. In a comparative study designed by Gutknecht *et al.* (1997),<sup>63</sup> an 810 nm diode was able to reduce bacteria contamination up to 88.38 per cent with a distal output of 0.6 watts in CW mode. A 980 nm diode laser has an efficient antibacterial effect in root canals contaminated with *E. faecalis* at an average between 77 to 97 percent. Energy outputs of 1.7 watts, 2.3 watts and 2.8 watts were tested. Efficiency was directly related to the amount of energy and dentine thickness.<sup>64</sup>

**Fig. 9** \_Intra-canal laser irradiation, molars.

**Fig. 10** \_Intra-canal laser irradiation, technique.

## Er:YAG laser

Er:YAG lasers are solid-state lasers whose lasing medium is erbium-doped yttrium aluminium garnet (Er:Y<sub>3</sub>Al<sub>5</sub>O<sub>12</sub>). Er:YAG lasers typically emit light with a wavelength of 2,940nm, which is infrared light. Unlike Nd:YAG lasers, the output of an Er:YAG laser is strongly absorbed by water because of atomic resonances. The Er:YAG wavelength is well absorbed by hard dental tissue. This laser was approved for dental procedures in 1997. Smear layer removal, canal preparation and apicoectomy are the indications for endodontics (Fig. 7).

The morphology of dentinal surface irradiated with an Er:YAG laser is characterised by clean areas showing opened dentinal tubules free of smear layer in a globular surface. The effects on bacterial reduction by Er:YAG was observed by Moritz *et al.* (1999).<sup>65</sup> Stabholz *et al.* (2003)<sup>37</sup> described a new endodontic tip that can be used with an Er:YAG laser system. The tip allows lateral emission of the radiation rather than direct emission through a single opening at the far end. It emits through a spiral tip located along the length of the tip. In order to examine the efficacy of the spiral tip in removing smear layer, Stabholz *et al.* (2003)<sup>66</sup> showed cleaned intra-canal dentine walls free of smear layer and debris under SEM evaluation.

## Photo-activated disinfection

Another method of disinfection in endodontics is also available. PAD is based on the principle that photo-activatable substances that bind to the target cells and are activated by light of suitable wavelength. Free radicals are formed, producing a toxic effect to bacteria. Toluidine blue and methylene blue are examples of photo-activatable substances. Tolonium chloride is able to kill most of the existing bacteria. *In vitro* studies, PAD has an effective action against photosensitive bacteria such as *E. faecalis*, *F. nucleatum*, *P. intermedia*, *P. micros* and *Actinomyces comitans*.<sup>67,68</sup> On the other hand Souza *et al.* (2010),<sup>69</sup> evaluating PAD antibacterial effects as a supplement to instrumentation/irrigation in infected canals with *E. faecalis*, did not prove significant effect regards to intra-canal disinfection. Further adjustments in the PAD protocols and comparative research models may be required to before clinical usage recommendations.

## Discussion and conclusion

There are good reasons to focus the treatment of non-vital contaminated teeth upon the destruction of bacteria in the root canal. The chances for a favourable outcome of the treatment are significantly higher if the canal is free from bacteria when it is obturated. If, on the other hand, bacteria persist at

the time of root filling, there is a higher risk of failure treatment. Therefore, the prime objective of treatment is to achieve the complete elimination of all bacteria from the root-canal system.<sup>2,31</sup>

Today, the potential antibacterial effect of laser irradiation associated with the bio-stimulation action and accelerated healing process is well known. Research has supported the improvement of endodontic protocol. An endodontic laser therapeutic plan brings benefits to conventional treatment, such as minimal apical leakage, effective action against resistant microorganisms and on external apical biofilm, and an increase in periapical tissue repair. Based on that, laser procedures have been incorporated into conventional therapeutic concepts to improve endodontic therapy (Fig. 8).

Clinical studies have shown the benefits of an endo-laser protocol in apical periodontitis treatment. For endodontic treatment, laser protocol is a combination of standard treatment strategies associating cleaning and shaping the root canal with a minimal adequate shape up to #35, irrigating solutions with antibacterial properties and intra-canal laser irradiation using controlled parameters of energy. Ideal sealing of the root canal and adequate coronal restoration are needed for an optimal result.

In practice, little additional time is required for laser treatment. Irradiation technique is simple once flexible optical fibres of 200µm in diameter are used. The fibre can easily reach the apical third of the root canal, even in curved molars (Fig. 9). The released laser energy has an effect in dentine layers and beyond the apex in the periapical region. The laser's effect is applicable in inaccessible areas, such as external biofilm adhered at the root apex.

Irradiation technique must follow basic principles. A humid root canal is required and rotary movements from the coronal portion to the apex should be carried out, as well as scanning the root canal walls in contact mode (Fig. 10). The power settings and irradiation mode depend on one's choice of a specific wavelength.

Nd:YAG, diodes in different wavelength emissions, Er:YAG, Er:CrYSGG and low-power lasers can be used for different procedures with acceptable results. Laser technology in dentistry is a reality. The development of specific delivery systems and the evolution of lasers combined with a better understanding of laser-tissue interaction increase the opportunities and indications in the endodontic field.

*Editorial note: A complete list of references is available from the publisher.*

### contact

### laser

#### Dr Selma Camargo

University of Cidade de São Paulo, Brazil  
Rua Pinto Gonçalves,  
85/54 Perdizes  
São Paulo, SP 05005-010,  
Brazil

selmacris@me.com



# Sofia Dental Meeting

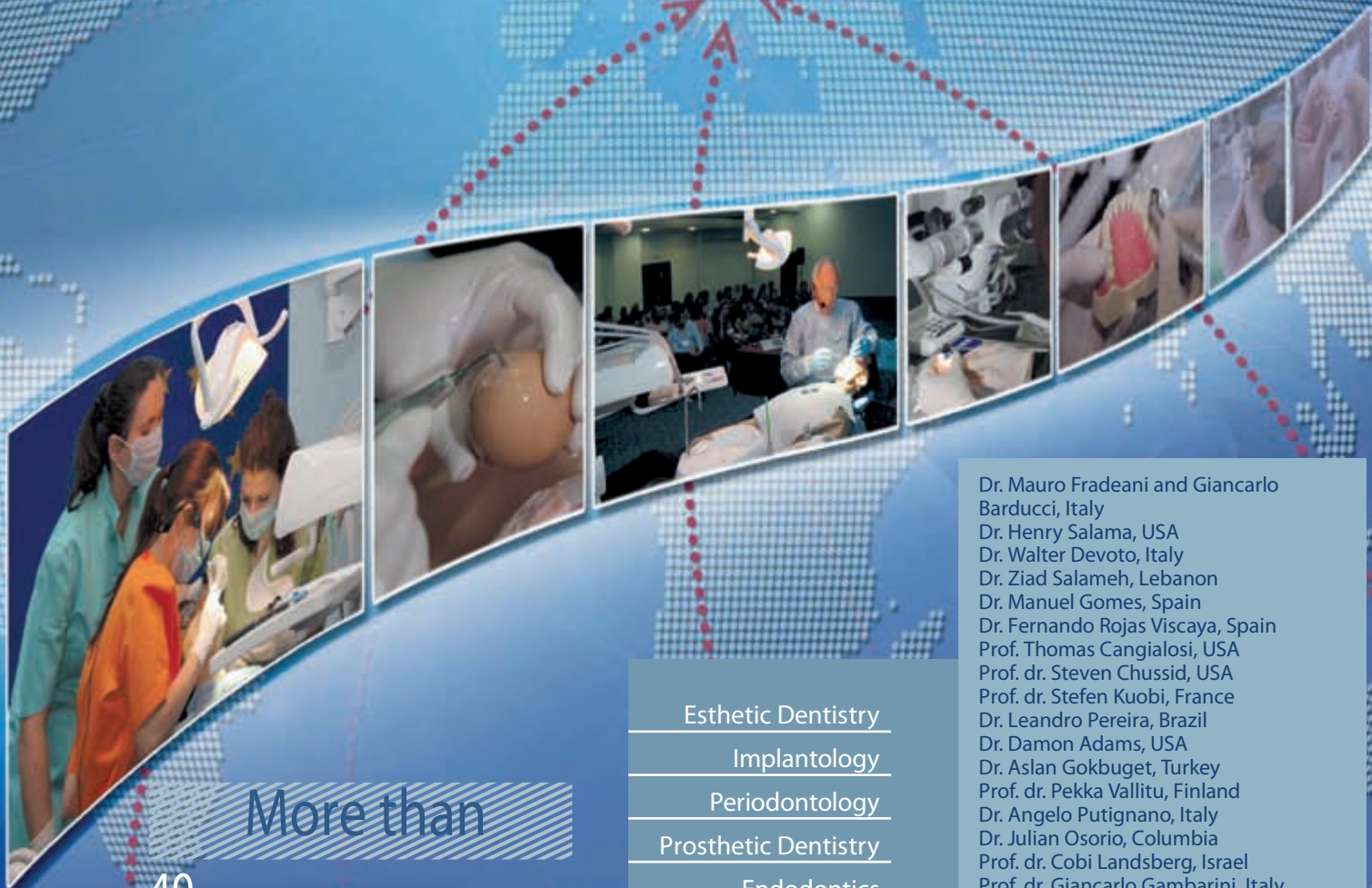September 29-th - October 2-nd 2011

Sofia, Bulgaria,

Dedeman Princess Hotel



Sofia  
Dental  
Meeting



More than

40 Lectures

30 Workshops

10 Live clinical demonstrations

50 Leading worldwide famous speakers

Esthetic Dentistry

Implantology

Periodontology

Prosthetic Dentistry

Endodontics

Orthodontics

Pediatric Dentistry

Occlusodontics

Dr. Mauro Fradeani and Giancarlo Barducci, Italy  
Dr. Henry Salama, USA  
Dr. Walter Devoto, Italy  
Dr. Ziad Salameh, Lebanon  
Dr. Manuel Gomes, Spain  
Dr. Fernando Rojas Viscaya, Spain  
Prof. Thomas Cangialosi, USA  
Prof. dr. Steven Chussid, USA  
Prof. dr. Stefen Kuobi, France  
Dr. Leandro Pereira, Brazil  
Dr. Damon Adams, USA  
Dr. Aslan Gokbuget, Turkey  
Prof. dr. Pekka Vallitu, Finland  
Dr. Angelo Putignano, Italy  
Dr. Julian Osorio, Columbia  
Prof. dr. Cobi Landsberg, Israel  
Prof. dr. Marcel Le Gall, France  
Dr. Gil Tirlet, France  
Dr. Jamison Spencer, USA  
Dr. Dinos Kountouras, Greece  
Dr. Peter Van der Schoor, the Netherlands  
Dr. Angelo Troedhan, Austria  
and a lot of Bulgarian lecturers

## Online registration:

Before 10 Sept. 2011 – 150 €

After 10 Sept. 2011, Onsite – 220 €

(the tax includes congress fee, Gala Cocktail)

For more information: [sofiadentalmeeting@gmail.com](mailto:sofiadentalmeeting@gmail.com)

Krum Popov Str. 62, Sofia 1421, Bulgaria,

tel. + 359 2 8657031; + 359 888 258 210

[www.sofiadentalmeeting.com](http://www.sofiadentalmeeting.com)

# TwinLight™ laser-assisted endodontics

Author\_Dr Kresimir Simunovic, Switzerland

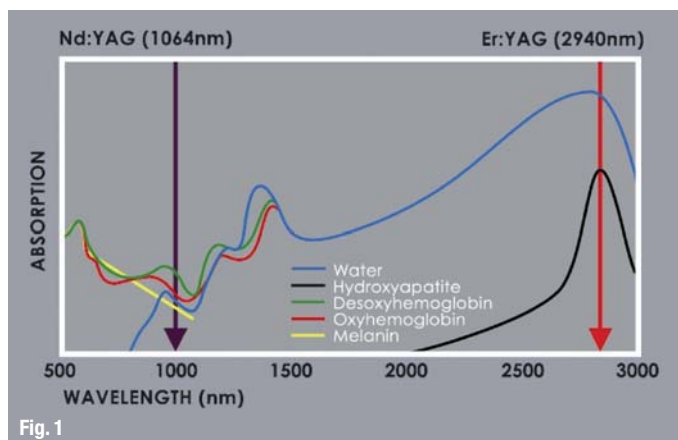


Fig. 1

**Fig. 1** Absorption coefficient in human tissues, as a function of laser wavelength. The absorption coefficient is at a minimum with the Nd:YAG laser wavelength (1,064 nm), and at the maximum with the Er:YAG laser wavelength (2,940 nm).

**Fig. 2** Removal of the debris and smear layer from the root canal walls using the Er:YAG laser. The treatment is accompanied by collateral irrigation with saline solution.

**Fig. 3** Deep decontamination with the Nd:YAG laser (3–5 times per session).

**Classical root treatment** involves cleaning the root canal using mechanical means and rinsing with antibacterial solutions and solvents. However, there are two major disadvantages of standard chemo-mechanical preparations.<sup>1</sup> First, the bactericidal effect of the rinsing solutions is limited to the root canal. Because of the narrow diameter of the dentinal tubules and the high surface tension of the liquid solutions, they are able to penetrate only a small distance down the tubules. The penetration depth of chemical disinfectants reaches only 100µm into the dentinal tubules<sup>2</sup>, while the bacteria can penetrate over 1,000µm from the canal lumen<sup>3</sup>, and remain protected in the deeper layers of dentin. The second important disadvantage is that the mechanical

preparation of side canals and other branches, as well as the complete removal of the smear layer, are impossible using classical means.

Over the past twenty years many types of laser sources have been studied and used as a means to improve upon the classical dental treatments.<sup>1,4</sup> No single "universal" laser source has been found that could be effectively and safely used for every dental procedure. Instead, as studies have demonstrated, each of the laser-assisted procedures should be performed with a laser that produces laser pulses at a wavelength that is known to be most effective for that particular procedure. In addition, many treatments would benefit immensely if they were performed with a succession or simultaneously using a multiplicity of laser sources. Of course, having a large number of laser sources in a practice would be impractical and very expensive. For this reason, the TwinLight™ treatment concept has been developed by Fotona d.d., based on the scientific understanding and clinical experience that for most laser-assisted treatments there exists an optimal combination of two basic complementary crystal laser sources, namely the Nd:YAG and the Er:YAG laser sources. The Nd:YAG laser wavelength (1,064 nm) is the most versatile and most deeply penetrating laser wavelength, while the Er:YAG laser wavelength (2,940 nm) is the wavelength with the highest absorption in human tissues (Fig. 1).

The use of the TwinLight™ laser-treatment concept in the field of endodontics was recently introduced by Dr Norbert Gutknecht.<sup>5</sup>

## The Nd:YAG laser wavelength in endodontics

For addressing the problem of deeply lying bacteria, lasers with a deep penetration into dentin, and preferably with a high peak-pulse power, are now being routinely used for disinfecting root canal systems.<sup>6-15</sup> As a result of their capability to spread and



Fig. 2

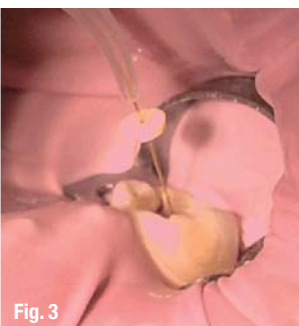

Fig. 3



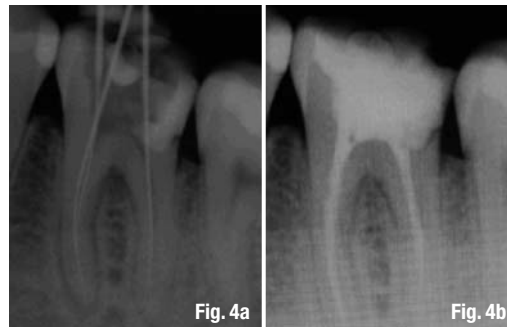
penetrate deeply into the dentinal walls, lasers have been demonstrated to be physically more efficient than traditional chemical irrigants in the decontamination of the dentinal walls.<sup>13</sup> The pulsed Nd:YAG laser has become the gold standard for this procedure.<sup>1, 6-9</sup> Of all dental laser wavelengths, the Nd:YAG laser wavelength has the deepest penetration in dentin, and the bactericidal effect of this laser has been demonstrated up to a depth of 1,000  $\mu\text{m}$ .<sup>7-9</sup> The pulsed Nd:YAG (1,064 nm) laser results in a bacterial reduction of 85% at 1,000  $\mu\text{m}$ , while the continuous-wave diode lasers show a much lower disinfection effects (63% at 750  $\mu\text{m}$  for the 810 nm diode<sup>14</sup>, and 33% at 500  $\mu\text{m}$  for the 980 nm diode.<sup>15</sup> Recent studies have shown that the higher effectiveness of the Nd:YAG laser in comparison to diode lasers can be attributed not only to the penetrating wavelength but also to the Nd:YAG laser's high peak-pulse power capability, which results in disinfecting temperature pulsing in the bacteria's immediate micro environment.<sup>16</sup>

### The Er:YAG laser wavelength in endodontics

In recent years, a laser solution has been proposed and developed that also addresses the second disadvantage of classically performed root canal treatments.<sup>7-23</sup> For the effective debridement and cleaning of the complex root canal system, the extremely high absorption of the pulsed Er:YAG laser wavelength (2,940 nm) in water and chemical irrigants is utilized to create a "cleansing" photo-acoustic effect within the root canal system.<sup>5,21-24</sup> Here, the erbium laser tip is placed into the tooth canal filled with either a saline solution or chemical irrigant. As the Er:YAG laser pulses are emitted from the fiber tip, they are immediately fully absorbed by the irrigant, creating shock waves within the irrigant that mechanically clean and debride the root canal system, even in otherwise difficult-to-reach side canals and branches. Since the action is purely mechanical, there is minimal thermal effect on the dentin. Canal walls treated photo-acoustically with the Er:YAG laser show a complete removal of the smear layer with open dentinal tubules and intact collagen structure.<sup>23</sup>

### TwinLight™ Endodontic Treatments

The latest TwinLight™ Endodontic Treatment (TET), as proposed by Dr Norbert Gutknecht of the University of Aachen<sup>5</sup>, is based on the Fotona TwinLight™ complementary laser-wavelength treatment concept. The TET procedure successfully addresses the two disadvantages of classical root canal treatments since it combines both of the complementary "gold standard" wavelengths: the deeply penetrating Nd:YAG laser wavelength for the deep thermal disinfection of the dentin, and the highly absorbed Er:YAG



**Fig. 4** Initial finding (10.12.2008) and follow-up (4.3.2009) after a TwinLight™ laser assisted endodontic treatment.

laser wavelength for the non-thermal, photo-acoustic cleaning and debridement of the complex root canal system.

In our practice, we use a dental laser system that incorporates both laser wavelengths, Nd:YAG and Er:YAG, in one device (the Fidelis AT, manufactured by Fotona d.d.). The TET procedure consists of the following three laser treatment steps.

In the first laser treatment step, the hard-tissue ablative capability of the Er:YAG laser is utilized to obtain free access to the pulp chamber. Compared to the classical procedure, this step allows a selective, pressure free and less painful opening of the irritated tissue. The bacterial load is not pushed into deeper root areas, and the danger of spreading of the bacterial wave throughout the body system is significantly reduced.

In the second laser treatment step, the root canal system is cleaned and debrided via the Er:YAG laser-induced photo-acoustics (Fig. 2). A saline solution and Preciso or Xpulse side-firing tips are used for this procedure (20–65 mJ, 15–25 Hz). Alternatively, the PIPS procedure<sup>23</sup> can be performed using EDTA @ 15–17% solution and special radial, end stripped PIPS fiber tips (20 mJ, 10–50 Hz).

In the third laser-treatment step, the root canal is rinsed and dried, and then deeply decontaminated using the Nd:YAG laser (200  $\mu\text{m}$  fiber, 1.5 W, 15 Hz) as is shown in Figure 3.

### Conclusion

A combination of laser treatments using two "gold standard" dental laser wavelengths can dramatically improve the prognosis of root-filled teeth. The integration of the Nd:YAG and Er:YAG laser wavelengths into a combined TwinLight™ procedure represents an endodontic therapy that successfully addresses both factors that complicate achieving sterility in the tooth: the anatomical root configuration and the characteristics of deeply resident bacterial flora. The TwinLight™ laser-assisted endodontic treatment starts with vibration-free removal of the hard tissue,

to be continued by the selective removal of the smear layer and debris throughout the root-canal system, and finally followed by deep decontamination of the dentin tubules. The TwinLight™ approach represents a progressive decontamination from the first to the last step of the laser-assisted therapy. It reduces the risk of bacteria spreading into the perioperative area and the body system, which is particularly important for immuno-compromised patients. It also produces a clean three-dimensional root canal wall anatomy with open and decontaminated dentin tubules, which allows for a precise three-dimensional root filling. And lastly, the laser treatment may have a biomodulation effect on the immuno response as well as a biostimulation effect on the fibroblasts. A typical case is shown in Figure 4.

Besides root canal therapy, there are other excellent indications for the TwinLight™ treatment concept. In my practice we also apply the TwinLight™ concept (using the latest Er:YAG fiber tips, Preciso, and Xpulse) with laser-assisted implant setting in surgery, and to pin root canal management in temporaries or before cementation in prosthetic dentistry. Similarly, recent studies further suggest that the use of a combination of Nd:YAG and Er:YAG lasers in periodontal therapy, such as WPT (Wavelength-optimized Periodontal Therapy), can be associated with cementum-mediated new connective tissue attachment and apparent periodontal regeneration of diseased root surfaces.<sup>25-26</sup>

In conclusion, the combination of the two TwinLight™ complimentary laser wavelengths comes very close to being a truly "universal" dental laser system.

## References

- Moritz A et al, Oral Laser Application, Quintessence Verlag Berlin; 2006: 241–313.
- Berruti E et al, Penetration ability of different irrigants into dentinal tubules, J. Endod 2007; 23 (12): 725–7.
- Kouchi Y et al, Location of Streptococcus mutans in the dentinal tubules of open infected root canal system, J. Dent Res 1980; 59(12): 2038–2046.
- Gutknecht N et al, Proceedings of the 1st International Workshop of Evidence Based Dentistry on Lasers in Dentistry, Quintessence Publishing; 2007: 101–113.
- Gutknecht N, A new treatment concept in endodontics—the laser supported crown-down technique, 12<sup>th</sup> Congress of World Federation for Laser Dentistry (WFLD) in Dubai; Conference Booklet; 2011: 22.
- Gutknecht N, Behrens V.G., The Nd-YAG laser as an aid to root canal obturation. Milan, Monduzzi Editore, 79<sup>th</sup> Annual World Dental Congress of FDI, 1991, p. I/275–I/280.
- Gutknecht N, Kaiser F, Hassan A, Lampert F. Long-term clinical evaluation of endodontically treated teeth by Nd:YAG lasers. J Clin Laser Med Surg 1996;14:7–11.
- Gutknecht N, Moritz A, Conrads G, Sievert T, Lampert F. Bactericidal effect of the Nd:YAG laser in in-vitro root canals. J Clin Laser Med Surg 1996;14:77–80.
- Klinke T et al, Antibacterial effects of Nd:YAG laser irradiation within root canal dentin. J Clin Laser Med Surg, 1997; 15:29–31.
- Gutknecht N, Gogswaardt D van, Conrads G, Apel C, Schubert C, Lampert F. Diode laser radiation and its bactericidal effect in root canal wall dentin. J Clin Las Med Surg 2000;18:57–60.
- Moritz A, Gutknecht N, Schoop U, Goharkay K, Doertbudak O, Sperr W. Irradiation of infected root canals with a diode laser in vivo: results of microbiological examinations. Lasers Surg Med 1997;21:221–226.
- Gouw-Soares S, Gutknecht N, Conrads G, Lampert F, Matson E, Eduardo CP. The bactericidal effect of Ho:YAG laser irradiation within contaminated root dentinal samples. J Clin Las Med Surg 2000;18:81–87.
- Schoop U et al, Bactericidal effect of different laser systems in the deep layers of dentin. Lasers Surg Med. 2004;35(2): 111–6.
- Klinke T et al, Antibacterial effects of Nd:YAG laser irradiation within root canal dentin. J Clin Laser Med Surg, 1997; 15: 29–31.
- Gutknecht N et al, Bactericidal effect of a 980-nm diode laser in the root canal wall of bovine teeth. J Clin Laser Med Surg, 2004; 22:9–13.
- Pirnat S et al. Thermal tolerance of E. faecalis to pulsed heating in the millisecond range. Lasers med. sci., [in press] 2010.
- Gutknecht N, Franzen R, Lampert F. Finite Element Study on Thermal Effects in Root Canals During Laser Treatment with a Surface-absorbed Laser. Lasers Med Sci, 17:137–144, 2002.
- Franzen R, Esteves-Oliveira M, Meister J, Wallerang, Vanweersch L, Lampert F, Gutknecht N. Decontamination of deep dentin by means of erbium, chromium:yttrium-scandium-gallium-garnet laser irradiation. Lasers Med Sci, 2009, vol. 24 (1) pp. 75–80, DOI 10.1007/s10103-007-0522-2.
- Aranha AC, Domingues FB, Franco VO, Gutknecht N, Eduardo de CP. Effects of Er:YAG and Nd:YAG lasers on dentin permeability in root surfaces: a preliminary in vitro study. Photomed Laser Surg. 2005 Oct;23(5):504–8. PMID: 16262582.
- Minas N, Meister J, Franzen R, Gutknecht N, Lampert F. In vitro investigation of intra-canal dentine-laser beam interaction aspects: I. Evaluation of ablation capability (ablation rate and efficiency). Lasers Med Sci, 2009, DOI 10.1007/s10103-009-0701-4.

*Editorial note: The whole list of references is available from the publisher.*

## \_contact

## laser

### Dr. Kresimir Simunovic

Seefeldstr. 128, 8008 Zurich, Switzerland  
Tel.: +41 44 3834070

ksimunovic@smile.ch  
www.simident.ch



# ISTANBUL WELCOMES DENTAL PROFESSIONALS

[www.dentalistanbul.com](http://www.dentalistanbul.com)



*di*<sup>®</sup>

**DENTAL ISTANBUL'11**

CONGRESS | EXHIBITION | COURSES

OCTOBER 22-23, 2011

SUPPORTED BY

**dti** Dental  
Tribune  
International

ORGANIZED BY

**vvg**  
vestiver  
publishinggroup

# TouchWhite™ Er:YAG laser-assisted Tooth Whitening

**Author** \_Jugoslav Jovanovic, Republic of Srpska

**\_Cosmetic dentistry has become** a very important part of dental practice. Studies show that at least one-third of the population is not satisfied with the color and form of their natural teeth.<sup>1-3</sup> It has been estimated that among patients who present themselves for cosmetic treatments, up to 15% suffer from psychiatric conditions termed Body Dysmorphic Disorder (BDD), also known as dysmorphophobia, which literally means "fear of ugliness".<sup>4,5</sup> BDD has an estimated prevalence of 1% to 2% in the general population and is characterized by a preoccupation with a slight or imagined defect of some aspect of physical appearance. With the increasing demand for esthetic dental care, it is clear that tooth bleaching can present a minimally invasive cosmetic approach.

Vital tooth bleaching is an increasingly popular treatment in dentistry. In order to enhance or to accelerate the whitening process, heat activation of the bleaching agent by light, heat, or laser has been introduced. Some manufacturers of laser- or light-based bleaching systems claim that there is improved light absorption, reduced tooth heating, and even photochemical activation of the bleaching gel following the addition of an activator, absorber or colorant.<sup>6,7</sup>

In a systematic review, Buchalla and Attin concluded that there was no real evidence of photochemical bleaching, and that power bleaching was a result of photothermal activation.<sup>8</sup> Additionally, they have also warned that activation of bleaching agents by light or laser may have an adverse effect on pulpal tissue due to an increase of intrapulpal temperature exceeding the critical value of 5.6 °C. This is due to the fact that in a typical laser- or light-activated bleaching, the light is not fully absorbed

in the relatively thin layer of the gel that is deposited on the tooth surface. As a result, the laser energy is transmitted into the dental tissue. This can lead to an undesired heating of the whole tooth and of the dental pulp, possibly leading to pain and irreversible damage.

## **\_TouchWhite™ Er:YAG laser-assisted bleaching**

The review by Buchalla and Attin<sup>6</sup> was performed before the introduction of the TouchWhite™ method for Er:YAG laser-assisted tooth whitening.<sup>9</sup> The TouchWhite™ method makes use of the fact that the Er:YAG laser wavelength has a water absorption peak in the vicinity of 3 µm. Since water is the major component of the aqueous bleaching gels, this eliminates the need for any additional absorbing particles in the bleaching gels. More importantly, taking into account thermal burden considerations, the TouchWhite™ procedure represents the most effective and least invasive laser-assisted tooth whitening method possible. Due to its high absorption in bleaching gels, the Er:YAG laser beam is fully absorbed in the gel and does not penetrate to the hard tissue or the pulp. All of the laser energy is thus effectively used for the heating of the gel. There is no direct heating of the dental tissue and the pulp, as is the case with other laser-assisted whitening methods.

Figure 1 shows the side view thermal image of a tooth during Er:YAG or diode laser (810 nm) illumination of the bleaching gel.<sup>10</sup> Since the Er:YAG wavelength is fully absorbed in the gel, there is no direct heating of the underlying tooth. On the other hand, the diode wavelength is relatively weakly absorbed in the gel, and the transmitted light directly

heats up the whole tooth. For this reason, the Er:YAG laser power is utilized more effectively, and the gel can be heated to higher temperatures without compromising the safety of the tooth or of the pulp. As a consequence, the TouchWhite™ procedure can be performed with a minimal undesirable thermal burden on the tooth, and the tooth whitening speed can be safely increased by 5–10 times.<sup>10</sup>

The TouchWhite™ method was first proposed and studied by the Laser and Health Academy in partnership with Fotona. Later, the Aachen Dental Laser Center (AALZ) in Germany performed a detailed *in vitro* study of the temperature elevation in the pulp chamber under different Er:YAG laser-whitening scenarios, followed by a clinical study of Er:YAG laser-assisted whitening.<sup>10–12</sup> Both studies confirmed the TouchWhite™ method to be safe and very effective in shortening the activation times of the bleaching gels.

An introductory clinical study of the TouchWhite™ procedure was also made by Dr Jugoslav Jovanovic of the Kozarac Dental clinic in the Republic of Srpska, BH. This study tested an Er:YAG laser-assisted whitening method in which the bleaching gel was illuminated in three sequences of 20 seconds, with 10 seconds of waiting time between the illumination sequences (according to the studies made by Fotona and AALZ, this illumination mode can shorten the bleaching time from 10 minutes down to 1.5–2 minutes). A Fotona Fidelis Plus Er:YAG laser with an R093 collimated bleaching handpiece was used in the study. The laser settings were as follows: laser power 0.55 W, repetition rate 10 Hz and pulse duration VLP. Five patients with 16 intrinsically stained teeth (12 vital and 4 non-vital) were treated with the Fotona teeth whitening gel (35% H<sub>2</sub>O<sub>2</sub>). One to three treatment sessions were made depending on the intensity of discoloration. The results of this introductory study confirmed that the Er:YAG laser applied in the three sequence mode can be safely and effectively used for teeth whitening of vital and non-vital tooth discoloration. None of the patients felt any heating of their teeth or pain during the treatment. Only one patient developed a temporary hypersensitivity after the bleaching, however, this sensitivity was attributed to the gel activity itself. The results of this study have already been presented at the 5<sup>th</sup> SOLA Congress in Vienna in 2009.<sup>13</sup> Since then, the TouchWhite™ tooth bleaching procedure has been performed on more than 40 patients. In comparison with diode and Nd:YAG bleaching, the Er:YAG laser-assisted whitening method proved to be more comfortable for patients while achieving the same or better whitening efficacy at shorter treat-

ment times. As an example, Fig. 2 shows before and after photos for one of the cases.

### The Er:YAG laser-assisted bleaching procedure


An appointment for Er:YAG laser bleaching is typically scheduled to last approximately 45 minutes. Before the start of the initial preparation, photographs are taken and general health status is established regarding possible indications or contraindications such as: leaking restoration, periodontal problems, caries, neck sensitivity, enamel fractures and cracks, insufficient oral hygiene, expectations of the patient, endodontic problems or TMJ disorders.

The steps of the procedure are performed in the following order:

- A) *Placement of cheek and lips retractor*  
(OptraGate, Ivoclar Vivadent; Schaan, Liechtenstein)
- B) *Teeth preparation*  
Extrinsic stains, plaque, debris are removed with pumice in order to obtain optimal results. Any organic material remaining on the tooth surface would interact with the bleaching agent, thus reducing effectiveness. Conventional polishing pastes should not be used because they may contain oils that inhibit the bleaching reaction.
- C) *Photographs of teeth before procedure*  
Once the pre-treatment photos are completed the procedure may begin.
- D) *Insertion of bite blocks*  
Bite blocks or a combination bite block and saliva aspirator is placed.
- E) *Gingival protection*

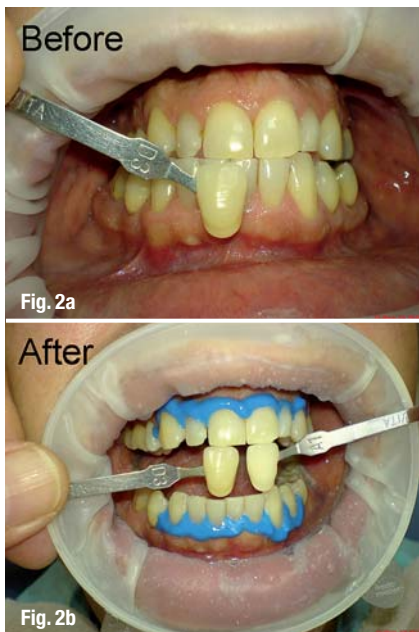Soft tissues should be protected from the hydrogen peroxide gel and laser light. Also, the hypersensitive dental neck should be protected from the

**Fig.1** Side view thermal images of a tooth under Er:YAG laser (a), and diode laser (b) illumination.



**Fig. 1**





**Fig. 2a & b** \_Photos before and after Er:YAG laser assisted whitening procedure.

bleaching gel in order to avoid undesirable pain during the procedure. The teeth and gums are dried with compressed air and a gingiva protector (that comes with the Fotona bleaching kit) is placed on the exposed cervical root surface (1–1.5 mm) and cervical gingival tissues (4–5 mm).

#### *F) Application of the bleaching gel*

The Fotona Bleaching kit contains gingival protection flowable resin material, bleaching gel and after-bleaching care material, packed in a syringe. The complete bleaching kit should be

stored in a refrigerator (temp. 3–8 °C). Before the application, the kit is taken out of the refrigerator, the gel is mixed in the amount needed for the procedure, and the mixed gel is left to rest for 4–8 min at room temperature. The gel is then applied to the teeth with a spatula in a predetermined sequence 11–21–13–23–24–14–15–25–12–22 for the upper teeth and 33–43–34–44–35–45–32–42–31–41 for the lower teeth.

#### *G) Protection of the patient, assistant and dentist with protective goggles*

Although the Er:YAG laser beam is less dangerous for the eyes in comparison to other laser wavelengths that are transmitted through to the retina (KTP, diode or Nd:YAG), protection goggles are mandatory.

#### *H) Irradiation with the Er:YAG laser*

Every tooth is irradiated for 20 sec in the same sequence as the gel application. The parameter settings are as follows: Fotona Er:YAG laser, frequency 10 Hz; power 0.55 W; pulse duration VLP, handpiece R093.

The handpiece is moved in a sweeping manner across the gel surface. If undesirable pain or sensitivity occurs on any tooth (rarely) go to the next tooth. Pay attention not to irradiate two neighboring teeth at the same time. The whole procedure is repeated three times so that every tooth is irradiated for 3 x 20 seconds.

#### *I) Removal of the bleaching gel and color check*

When the three-cycle illumination of all teeth has been completed, the gel is removed with an aspirator and the tooth surface is thoroughly rinsed

with a water spray. The color is checked with a shade guide and shown to the patient.

#### *J) Re-checking the gingival protection and repeating the procedure*

The procedure can be repeated up to 3 times in one appointment if necessary.

#### *K) After-treatment photographs*

At the end of the treatment, the teeth are cleaned of the gel, and the gingival protection is removed. The achieved color is checked, compared with the shade guide (VITA B1–C4) and included in the image to serve as a reference point.

Teeth are gently dried. Patients are instructed not to eat or drink colored food for 72 hours (coffee, tea, red wine). Smoking should also be avoided. An appointment is made for a control session after 14 days. If there is need for a second treatment, the interval is 14 days. \_

#### **\_References**

- Goldstein RE, Survey of patient attitudes toward current esthetic procedures, J. Prosthet Dent 1984;52:775–780.
- Truin GJ, Burgersdijk RC, Kalsbeek H, van't Hof MA, Cosmetic dentistry, Ned Tijdschr Tandheelkd 1989;96:378–381.
- Willemsen WL, Burgersdijk RC, Truin GJ, Mulder J. Cosmetic dental treatment in an adult Dutch population. Community Dent Health 1994;11:378–381.
- Sarver DB, Wadden TA, Pertschuk MJ, Witaker LA. Body image dissatisfaction and body dysmorphic disorder in 100 cosmetic surgery patients. Plast Reconstr Surg 1998;101:1644–1649.
- Crerand CE, Franklin ME, Sarver DB. Body dysmorphic disorder and cosmetic surgery. Plast Reconstr Surg 2006;118:167–180.
- Baik JW, Rueggeberg FA, Liewehr FR. Effect of light-enhanced bleaching on in vitro surface and intrapulpal temperature rise. J Esthet Restor Dent 2001;13:370–378.
- Verheyen P, Walsh LJ, Wernisch J, Schoop U, Moritz A. Laser assisted bleaching in: Moritz A, Beer F, Goharkay K, Schoop U, Strassl M, Verheyen P, et al (eds). Oral Laser Application. Quintessence: Berlin, 2006:407–448
- Buchalla W, Attin T, External bleaching therapy with activation by heat, light or laser—a systematic review. Dent Mater 2007;23:586–596.
- TouchWhite™ is a registered trade mark of Fotona d.d. (www.fotona.com).

*Editorial note: The whole list of references is available from the publisher.*

\_contact

laser

**Jugoslav Jovanovic, DDS**  
Kozarac General Dentistry Clinic  
Republic of Srpska, BH

# THE BUSINESS OF DENTISTRY



## INTERNATIONAL DENTAL EXHIBITION AND MEETING APRIL 20 - 22, 2012

**Your Top Choice for Continual Education**

Earn academic  
accreditation points for  
your accrual in your country's  
continual education programme

IDEM Singapore 2012 Scientific Conference provides the expertise and insight you need to expand your skill set, optimize patient care, and enhance practice revenue. Hear from world-class speakers on a diverse range of topics, such as implantology, aesthetics, endodontics, periodontics and orthodontics. Don't miss out on the limited attendance hands-on workshops by world-renowned experts in their field.

### Featured Speakers:



#### Dennis Tarnow

*Clinical Professor of  
Periodontology and Director of  
Implant Education, Columbia  
School of Dental Medicine,  
New York*



#### Michel Magne

*Associate Professor of  
Clinical Dentistry and  
Director of Dental Technology,  
University of Southern California,  
Los Angeles*



#### Pascal Magne

*Associate Professor,  
Chair of Aesthetic  
Dentistry, University  
of Southern California,  
Los Angeles*



#### Robert Boyd

*Professor & Chairman  
of Orthodontics,  
School of Dentistry,  
University of California  
San Francisco*

Endorsed By



Supported By



Held In



In Co-operation With



Co-organiser



International  
Koelnmesse Pte Ltd  
Ms. Ziqi Zielinski  
Tel: +65 6500 6721  
z.zielinski@koelnmesse.com.sg

 **koelnmesse**  
we energize your business

# Infection control

Author\_Dr Frank Yung, Canada

More than 20 years ago, a dental patient named Kimberly Bergalis was diagnosed with Aids. The source of her HIV infection was her dentist. Even though the exact path of transmission is still not known, this first proven transmission of HIV from dentist to patient—and the subsequent intense coverage by the media—set off tremendous confusion and panic amongst dental patients. It was her unfortunate death in 1991 that changed the dental profession almost overnight, prompting all sorts of new regulations and guidelines, including the sterilisation of dental instruments. The document *Guidelines for Infection Control in Dental Health-care Settings* was published by the US Centers for Disease Control and Prevention (CDC) on 19 December 2003, providing some of the current and available scientific rationale for infection-control practices, for which recommendations were made.<sup>1</sup> These suggestions were followed closely by various governing dental health organisations, including the

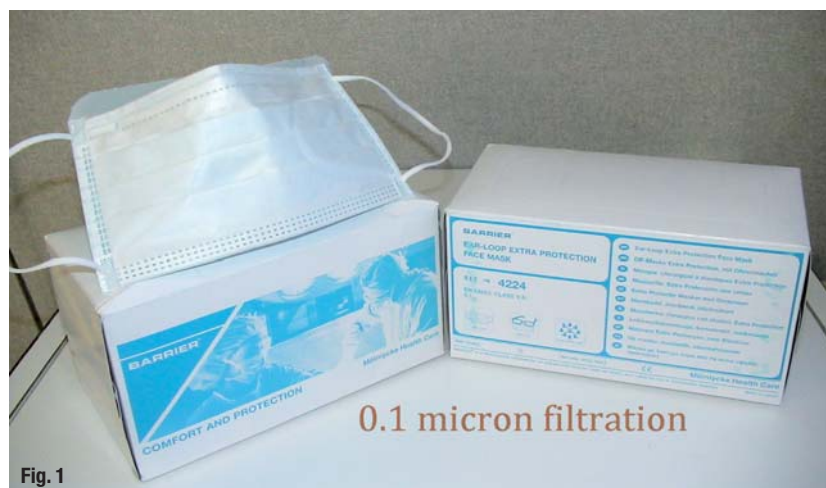US Occupational Safety and Health Administration (OSHA) and Health Canada.

In dentistry, we see patients from different walks of life every day and they bring all kinds of pathogens to our dental offices. It is our responsibility to arrest the path of these pathogens and attempt to prevent them from infecting others and spreading beyond our practices. Following the CDC recommended infection-control guidelines and procedures can help stop and prevent transmission of infectious organisms through blood, oral and respiratory secretions and contaminated equipment during the course of dental treatment. One factor to consider in assessing the risk of contamination is the type of bodily substances to which dental health-care personnel (DHCP) are exposed. It is generally understood that human blood has a high infectious potential.<sup>2</sup> In addition to bacteria and fungi, human saliva has been found to be capable of harbouring many kinds of infectious viruses.<sup>3,4</sup> Without the benefits of a quick and reliable reference, DHCP have to assume that everyone is a potential carrier. This is the fundamental reason that dental practices should have a universal infection prevention protocol.

Amongst many other related issues, the CDC guidelines explain the manner in which to wear surgical gloves properly and implement a glove protocol. These recommendations will help properly prevent contamination from our patients' oral tissues and fluids. Regarding surgical masks, laser ablation of human tissue or dental restorations can cause thermal destruction and can create smoke by-products containing dead and live cellular material (including blood fragments), viruses, and possible toxic gases and vapours. One concern is that aerosolised infectious material in the laser plume, such as the herpes simplex virus and human papillomavirus may come into contact with the nasal mucosa of the laser operator and nearby DHCP. Although no evidence exists that HIV or the hepatitis B virus (HBV) has been transmitted via aerosolisation and inhalation, there are scientific studies that confirm the risk of this possible route of contamination.<sup>5,6</sup> The risk to DHCP from exposure to laser plumes and smoke is real, and, along with other measures such as strong high-volume suction, the use of a high-filtration mask is strongly recommended (Fig. 1).

**Fig. 1** An example of a high-filtration protective mask, which is recommended for use with dental lasers.

**Fig. 2** An example of the submission of indicators to a testing service for assessment of office sterilisation equipment's effectiveness.



**Fig. 2**

UBC STERILIZER MONITORING SERVICE  
Oral Microbiology Laboratory Room 324  
Faculty of Dentistry  
The University of British Columbia  
2199 Westbrook Mall  
Vancouver, B.C.  
V6T 1Z3  
(604) 822-2765

STERILIZER MONITORING SERVICE  
Oral Microbiology Laboratory Room 324  
Faculty of Dentistry  
The University of British Columbia  
2199 Westbrook Mall  
Vancouver, B.C.  
V6T 1Z3  
(604) 822-2765

Fill in  
Sterilizer #: \_\_\_\_\_ Date: \_\_\_\_\_  
Sterilizer Type: ☐ Chemclave ☐ Steam ☐ Dry Heat  
Dr. Frank Yung  
Name: \_\_\_\_\_  
Address: \_\_\_\_\_  
City: \_\_\_\_\_ Province: \_\_\_\_\_ Postal Code: \_\_\_\_\_  
Area Code: \_\_\_\_\_ Phone Number: \_\_\_\_\_

Any changes?

BACTERIAL SPORE TEST  
Bacillus anthracis spores  
Geobacillus stearothermophilus  
TEST STRIP  
PEEL

TEST STRIP

EXPIRY DATE: Jan 31, 2012

BACTERIAL SPORE TEST  
Bacillus anthracis spores  
Geobacillus stearothermophilus  
CONTROL STRIP  
PEEL

CONTROL STRIP  
DO NOT REMOVE



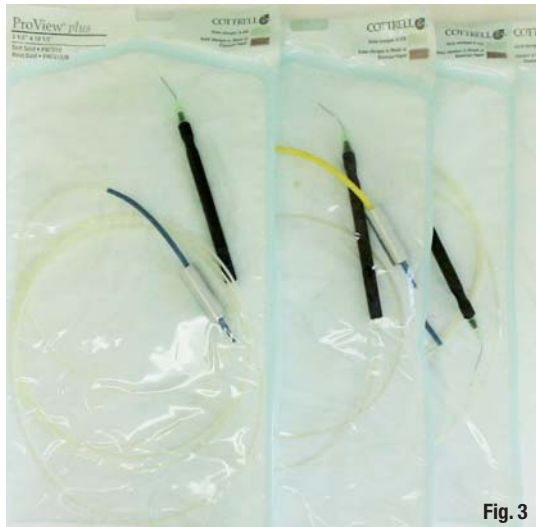

Fig. 3

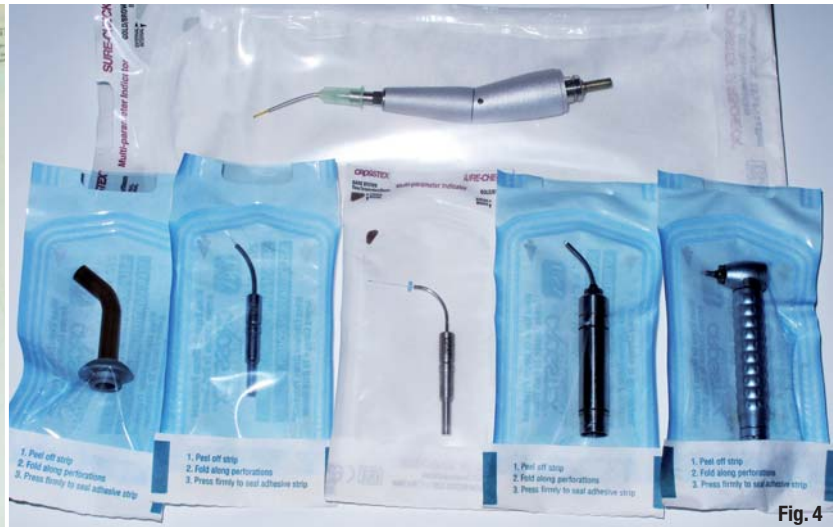

Fig. 4

Sterilisation is a multistep procedure that must be performed carefully and correctly by the DHCP to help ensure that all instruments are uniformly sterilised and safe for patient use. Cleaning, which is the first basic step in all decontamination and sterilisation processes, involves the physical removal of debris and reduces the number of micro-organisms on an instrument or device. If visible debris or organic matter is not removed, it can interfere with the disinfection or sterilisation process. Proper monitoring of sterilisation procedures should include a combination of process indicators and biological indicators, and should be assessed at least once a week (Fig. 2). Patient-care items are generally divided into three groups, depending on their intended use and the potential risk of disease transmission. Critical items are those that penetrate soft tissue, touch bone or contact the bloodstream. They pose the highest risk of transmitting infection and should be heat sterilised between patient uses. Examples of critical items are surgical instruments, periodontal scalers, surgical dental burs, optical fibres (Fig. 3) and contact tips (Fig. 4). Therefore, it is extremely important to examine, cleave, polish and sterilise optical fibres and contact tips after each use. Alternatively, sterile, single-use, disposable devices can be used. Semi-critical items are those that come into contact with only mucous membranes and do not penetrate soft tissues. As such, they have a lower risk of transmission. Examples of semi-critical instruments are dental mouth mirrors, amalgam condensers and impression trays. Most of the equipment in this category is heat tolerant, and should therefore be heat sterilised between patient uses. For heat-sensitive instruments, high-level disinfection is appropriate. Non-critical items are instruments and devices that come into contact only with intact (unbroken) skin, which serves as an effective barrier to micro-organisms. These items carry such a low risk of transmitting infections that they usually only require cleaning and low-level dis-

infection. Examples of instruments in this category include X-ray head/cones, blood pressure cuffs, low-level laser emission devices and laser safety glasses. For low-level laser therapy, the use of a transparent barrier similar to disposable sleeves for curing lights is acceptable. For safety glasses, the use of a low-level disinfectant is suitable as long as it has a label claim approved by OSHA for removing HIV and HBV. The disposal of used instruments and excised biological tissues should be managed separately. A cleaved optical fibre, broken contact tips, or disposable fibres should be disposed of properly in a sharps container. Harvested biological waste should be placed in a container labelled with a biohazard symbol. In order to protect the individuals handling and transporting biopsy specimens, each specimen must be placed in a sturdy, leak-proof container with a secure lid to prevent leakage during transport. By following these guidelines, the spread of pathogens amongst dental patients, DHCP and their families can be prevented, and the passing of Kimberly Bergalis will not have been in vain.

**Fig. 3** An example of sterilised optical fibres and handpieces.

**Fig. 4** An example of sterilised rigid glass tips and handpieces.

#### Disclosure

*Dr Yung has no commercial or financial interest regarding this article.*

*This article was first published in the Journal of Laser Dentistry, 18/2 (2010): 68–70.*

*Editorial note: A list of references is available from the publisher.*

\_contact

laser

**Dr Frank Y. W. Yung**  
Toronto, Ontario, Canada

frankyung@rogers.com  
www.drfrankyung.com

# New double-wavelength-laser— successful launch at IDS

An interview with Federico Pignatelli, Chairman and CEO Biolase Technology Inc.



*Mr Pignatelli, Biolase is predominantly known to dentists as a manufacturer of dental lasers, but also develops lasers for other medical sectors. Which corporate tradition and which competences underline this high specialization in the medical laser technology?*

**Federico Pignatelli:** Biolase is redefining surgery in dentistry and medicine. We have more than 140 issued patents and 143 patents pending in the field of dental and medical lasers of which approximately 70% are focused on our core Er,Cr:YSGG laser technology, which combines our patented laser energy at 2,780 nm with water to precisely cut hard tissue, soft tissue and bone. In addition to dentistry, our YSGG technology has broad applications in ophthalmology, dermatology, orthopedics, and ENT. In 2011 you will see us begin expansion into these new markets starting with our YSGG laser and methodologies for treating presbyopia, a condition that affects more than 2.5 billion people worldwide. Our innovative R & D team combined with a senior management staff with many years of medical laser experience are the keys to us expanding into the medical laser sectors.

*You have four different dental lasers in your range of products. Can you please explain, in short, for which indications which laser is suited best?*

The iLase 940 nm diode laser is a very convenient and affordable way to get started in laser dentistry. Completely wireless and handheld, it is perfect for troughing around crown preps to eliminate packing retraction cord, gingivectomies, treating periodontal pockets in a soft-tissue management program plus root canal decontamination. With 5 watts of power in pulse mode, it is capable of most soft tissue procedures.

The EzLase, Total Diode Solution performs all diode soft-tissue, hygiene procedures, endo and perio indications plus full-mouth teeth whitening and LLLT for biostimulation and pain relief. The EzLase features higher power and more pulse modes than the iLase for even greater control and patient comfort. Full-mouth teeth whitening takes less than 20 minutes. The EzLase is the only dental laser in the US with FDA clearance for temporary pain relief for TMD and other facial pain indications. We have developed a new deep tissue handpiece specifically for biostimulation and our doctors are seeing amazing results.

The WaterLase MD Turbo was a major breakthrough in all-tissue laser technology when it was introduced a few years ago. This laser is an ideal entry level all-tissue laser for pediatric and restorative dentistry including cavity preps of all classes. It is also FDA cleared for periodontal indications including subgingival calculus removal and new attachment procedures. For endodontic indications, it is clinically proven to disinfect root canals three times more effectively than using NaOCl when using our patented EndoLase™ radial firing tips.

The new dual wavelength WaterLase iPlus has advanced laser technology to its ultimate. The combination of the 2,780 nm and 940 nm wavelengths in a single unit provides maximum versatility for performing all dental laser indications. With 600 mJ per pulse and pulse repetition rates from 5 to 100 Hz, this laser can cut hard-tissue as fast as a high-speed drill—or any other dental laser—without the pain or

creation of micro-fractures in healthy tooth structures the drill can cause. It also reduces the—risk of cross-contamination from dental burs that has been shown in recent studies. The intuitive, indications-based graphic interface makes operating the iPlus as quick and easy to learn as using a smart phone.

*With the Er,Cr:YSGG laser with a wavelength of 2,780nm, Biolase has developed the Erbium laser further and owns the patent for this wavelength. What advantages does the Er,Cr:YSGG laser offer compared to a Er:YAG laser?*

BIOLASE is one of the research pioneers in dental lasers. In our experiments with many kinds of lasers for over 20 years, we have found the Er,Cr:YSGG laser wavelength of 2,780nm to be the most efficient for cutting not only hard-tissue, but also soft-tissue and bone as well. And that's one feature of our company that also distinguishes us from everyone else. Rather than taking a readily available commercial laser, such as Er:YAG, and then asking doctors to use it, we took the opposite approach. We first learned which laser would be most applicable for dental procedures, regardless of commercial availability, and then worked to bring it to market. The result is a biological and therapeutic treatment that provides minimum trauma and superior healing. Our YSGG technology is also more efficient than the Er:YAG which allows us to generate high power and high hertz rates in a small package using a standard power outlet.

You may have also noticed that our diode wavelength of 940nm is different than the more traditional diode wavelengths of 810nm and 980nm. The reason we chose 940nm is very similar to our choice of Er,Cr:YSGG. From a laser physics standpoint, we considered it because it is on an absorption peak for hemoglobin and oxyhemoglobin with higher absorption in water than the 810nm. This provides an excellent balance of cutting and coagulation of all types of oral tissues. We then gave our clinical advisors unmarked multi-wavelength units to evaluate. Clinically, they all selected the 940nm over other the common diode wavelengths.

*At the Midwinter Meeting in Chicago at the end of February, the presentation of the new Er,Cr:YSGG laser Waterlase iPlus was extremely successful. Which product features were received best?*

Doctors were most impressed that the iPlus cuts hard-tissue as fast as a high-speed drill. Many of

them, including experienced laser dentists, couldn't believe it even after they tried it.

They also loved our new system interface. Rather than requiring the doctor to enter values for power, air and water spray, and pulses per second, the Waterlase iPlus simply asks doctors to select what indication they want to perform. The iPlus takes care of all the technical details of setting up the laser parameters and recommends the optimum tip and handpiece combination.

Doctors have been waiting for a powerful, yet simple laser to use. Now they finally have it with the Waterlase iPlus.

*Are the reactions of the IDS visitors similar?*

The reaction to the cutting speed and intuitive indications-based user interface of the iPlus at the IDS was similar to the Chicago Midwinter, but the international doctors and distributors really liked the new more flexible fiber delivery system with higher illumination and larger diameter tips and the ability to order an iPlus in custom colors, especially the red and the black versions.

*Did you experience at the IDS that dentists and dental assistants have the need for more information regarding dental lasers?*

Yes. Recent market research supports your observation that dentists and dental assistants need more information on all aspects of dental lasers. At Biolase we are working very hard to educate dentists and their staffs

on the wide range of indications that can be performed by diode and all-tissue lasers, how they can be integrated into the practice to generate a return on their investment, the amount of clinical training and support that is available to help them master laser dentistry and finally how much easier our new lasers are to learn and operate compared to lasers in the past.

*What sales channels do you use for your products?*

Internationally, we sell through a large network of distributors. We are currently selling in about 50 countries and in addition to Biolase-Europe in Floss, Germany, we are opening up company offices in China, India and South America to better support our dealers in these fast growing markets.

*Mr Pignatelli, thank you very much!*

**“Doctors have  
been waiting for  
a powerful, yet  
simple laser  
to use.”**



# The Joint Fellowship Course of Tehran and Aachen Universities

## An academic and scientific joint program

**Authors\_**Reza Fekrazad, Katayoun AM Kalhori



When Plan of Development and Advancement of Laser in Dentistry (PDALD) was accepted by the Ministry of Health and Medical Education in Iran, the education department of Laser national committee of the Ministry of Health authored an educational curriculum in two units for laser in Dentistry, which has to be taught in 34 hours. It has been scheduled and confirmed that all undergraduate and post-graduate students ought to pass these two units.

To teach the course, some well-trained and fully experienced professors were needed.

Twenty top professors were chosen among applications from all universities of the country. The University of Tehran as the oldest and largest university of the country was selected for handling the program. On the other hand the University of Aachen was elected among top Universities of the world which are active teaching laser in the world as the partner.

After some negotiations authorities of both Universities signed an agreement to run the program of training 20 professors in 18 months in three phases.

Phase one was concentrated on basics. Iranian professors managed this phase. Participants were supposed to pass the course with good grades. They had to learn how to work with different types of laser in the market practically even on real patients'.

E-learning education was also practiced to help them more. They also were asked to have review article on a key subjects which was found very helpful.

In the second phase, a team of international professors from the University of Aachen held class in the second 6-months course in the University of Tehran. It was the advanced course, which started in December 2009 and is going to be in Jul 2010. Course participants have to pass a final exam at the end. They would be awarded a certificate after the exam.

For the last phase, they are asked to have a study case for their thesis. Finally, they ought to present the project and defend it during the 3 phases students have been in touch with their professors on-line and have received up-dated information and have raised any probable questions.

The course is still going on, besides its academic values the program PDALD has already taken a giant step in the knowledge of laser in Iran and has added to the value of two well reputable Universities of Tehran and Aachen. We are proud to say that the program has been handled in a very friendly and scientific atmosphere.

We hope in the near future the level of these relationships goes higher in education and research fields.

\_contact

laser

**Reza Fekrazad DDS, Ms**  
Periodontologist-Head of  
Fellowship Course

dr\_rfekrazad@yahoo.com

**Katayoun AM Kalhori**  
Oral and Maxillofacial  
Pathologist-Educational  
Manager of Co

dr\_kalhori@yahoo.com

# International events

## 2011

### **FDI Annual World Dental Congress**

Mexico City, Mexico  
14–17 September 2011  
[www.fdiworldental.org](http://www.fdiworldental.org)

### **Annual Congress of DGZI**

Cologne, Germany  
30 September–1 October 2011  
[www.dgzi.de](http://www.dgzi.de)

### **20<sup>th</sup> Annual Scientific Congress of the EAO**

Athens, Greece  
12–15 October 2011  
[www.eao-congress.com](http://www.eao-congress.com)

### **Annual Congress of DGL**

Düsseldorf, Germany  
28–29 October 2011  
[www.startup-laser.de](http://www.startup-laser.de)

### **Greater New York Dental Meeting**

New York, NY, USA  
25–30 November 2011  
[www.gnydm.org](http://www.gnydm.org)

## 2012

### **LaserOptics Berlin**

Berlin, Germany  
19–21 March 2012  
[www.laser-optics-berlin.de](http://www.laser-optics-berlin.de)

### **IDEM International Dental Exhibition**

Singapore  
20–22 April 2012  
[www.idem-singapore.com](http://www.idem-singapore.com)

### **13<sup>th</sup> WFLD World Congress**

Barcelona, Spain  
26–28 April 2012  
[www.wfld-barcelona2012.com](http://www.wfld-barcelona2012.com)

### **90<sup>th</sup> General Session & Exhibition of the IADR**

Rio de Janeiro, Brazil  
20–23 June 2012  
[www.iadr.org](http://www.iadr.org)





# XI Congress of SELO

**Authors**\_Paloma Montero, Isabel Sáez de la Fuente, Josep Arnabat, Spain



On 11–12 February, the XI National Congress of the Spanish Society of Laser in Odontostomatology (SELO) was held in Seville, with the title: “Excellence in operating lasers”.

cluding dentists, hygienists and students. There were many commercial companies who displayed the latest laser technologies to the assistants.

The President of the Congress, Doctor Isabel Sáez de la Fuente, with Doctor Daniel Torres Lagares, coordinator of the area of Oral Surgery of the University of Seville and Vice-President of the Congress, and the rest of the organising committee (Patricia Bargiela, Paloma Montero, Betina Pérez, Eloy Cano, Carlos Valdivieso, Rocío Velázquez and Ignacio Arregui) organized a scientific program of a high level that was of interest to all participants of the Congress. It achieved accreditation from the Agency of Medical Care s side of Andalucía, meaning that the training given at this event is considered as credits for continuous training in the national system. The Congress was held in the hotel Silken AlAndalus Palace and attended by 200 assistants, in-

During the inauguration, carried out by the Honorable Rector of the University of Seville, the importance of technology in the improvement of the daily practice was emphasized. Institutions with scientific boards should approve the incorporation of this in the dental office. This message was emphasized by members of the inaugural table: the Rector of the University of Seville (Joaquín Luque), the Director Manager of the Andalusian Service of Health (José Luis Gutiérrez Pérez), accompanied by Silvestre Ripoll (Member of the Scientific Commission of the School of Dentists of Seville), Josep Arnabat (President of SELO), the teacher Cosme Gay Escoda (President of the Scientific Committee of the Congress) and Isabel Sáez de la Fuente (President of the Congress).

Moving onto the scientific program, the pre-congress course took place on Friday morning attended







by the doctors Francisco Enrile and José Miguel Romero (Huelva), Pedro Buitrago (Valencia), Ignacio Arregui (León) and Ignacio Sanz (Madrid).

The rest of the scientific program was concerned with current matters: treatment of periimplantitis and periodontal treatments (Georgios Romanos, Francesco Martelli, Vanessa Ruiz, Antón Sculean, Gerd Volland and Jan Tuner), aesthetic dentistry and adhesion (Martín Jorgens, Henrik Holm, María Pérez and Carlo Fornaini), oral surgery (Rolando Crippa, Antonio Bowen, Antonio España, Gonzalo López and Patricia Bargiela Pérez). To sum up, the scientific program, was attended by speakers of great national and international prestige.

Simultaneously, the V meeting SELO for hygienists and assistants was celebrated, to which came near to 50 of these professionals interested in the study of the physique bases of laser, its utilization in areas of odontology (periodontics, endodontics, oral surgery, aesthetic, etc) and its integration in he daily office. The

speakers Cristina Vaquero, Daniel Abad, Marcela Bisheimer, Sofia Raja, Luis Suárez, Rocío Velázquez and Ángela Rodríguez talked about these topics throughout the morning.

The social program was very successful among the assistants. The speaker's dinner took place in the restaurant Casa Robles in the Placentines street, and the dinner gala in the Exhibition Casino. The dinner was livened up with a jazz group, and later a flamenco dance performance, which was to the liking of all the assistants.

Without a doubt, the organisers of the Congress agreed that of having a city like Seville as a venue, was key to the success of this Congress, preparing the sphere for the next big event related to laser dentistry that will be celebrated in our. The 13<sup>th</sup> World Congress of the World Federation Laser Dentistry will take place in Barcelona the last week of April 2012, organized by Doctor Antonio España, where we look forward to seeing you soon again.



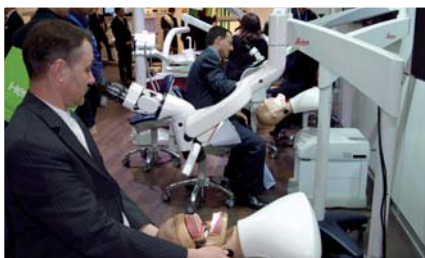# Biggest IDS ever

The upbeat mood at IDS 2011 was especially due to the large number of visitors. Accordingly, the trade fair's halls were very busy and the exhibitors' stands were extremely well visited. Exhibitors confirmed that representatives of all important professions—ranging from dental practices and dental labs to the dental trade, plus the higher education sector—visited their stands. Exhibitors were particularly pleased with the large number of international visitors to the trade fair. This year there was a strong increase in visitors not only from Latin America and South America, Australia, the United States and Canada, but also from Italy, France, the Netherlands, Spain, the United Kingdom, Switzerland, Russia, Ukraine, Turkey, Israel, China and India. IDS was also a huge financial success for many exhibitors. Countless orders were placed, both domestically and internationally, and so numerous companies were able to boast a long list of orders. Of equal if not greater importance to many exhibitors were the opportunities to establish and maintain contacts, generate customer loyalty, win new customers and open up new foreign markets. All of these goals were also reached at the 34<sup>th</sup> International Dental Show. Last but not least, the exhibitors expressed great satisfaction with the visitors' high decision-making authority. This finding is confirmed by the initial results of an independent visitor survey, as 85 per cent of all trade visitors are involved in purchasing decisions at their company. "We've succeeded in making the International Dental Show even more attractive, both domestically and internationally. The

strong increase in international participants especially shows that IDS is the world's leading dental trade show," says Dr Martin Rickert, Chairman of the Association of German Dental Manufacturers (VDDI). "What's more, participants were able to forge high-quality business contacts, both between industry and trade professionals as well as between the industry, dentists and dental technicians. Thus the trade fair once again signalled better times ahead and generated momentum that will help the dental sector stay on course for a successful business year."

## Enormous interest in innovation

The specialist trade and users were especially interested in the innovative new products and technologies on display. According to Dr Martin Rickert (VDDI), the trade fair demonstrated that digital processes and technologies are becoming increasingly popular since they facilitate even more efficient and higher quality treatments. Hence a major focus of IDS 2011 was on products and systems that offer users and patients improvements in preventative care, diagnostics and dental treatment. These include expanded ultrasound systems that enable painless professional preventative care, digital intraoral scanners, improved root canal treatment methods, new dental filling materials, aesthetic dental crowns and bridges that look especially natural, and improved digital X-ray diagnostics that are especially useful in the area of implantology.



# Manufacturer News

Hager & Werken

## A plaster for implantology

Implantology offers some very interesting application fields for Hager & Werken's Reso-Pac plaster which remains soft: First of all the adhesive cellulose-based periodontal dressing is a great help in implant healing by covering the wound and its sutures, consequently protecting the intra-oral wound area from the oral milieu with its germ settlements. Reso-Pac is hydrophilic and, therefore, offers an ideal adhesion to the oral cavity tissue. Upon modeling it, Reso-Pac turns into a smooth paste-like surface which is pleasant to the

patient. The applied periodontal dressing remains soft and dissolves completely after approximately 30 hours without leaving any residues, making a later removal by the dentist unnecessary. Furthermore, Reso-Pac can be used as a medicament carrier for periimplantitis treatment. Reso-Pac is available in useful 2g single doses as well as in an economical 25g tube. Further information can be found at:

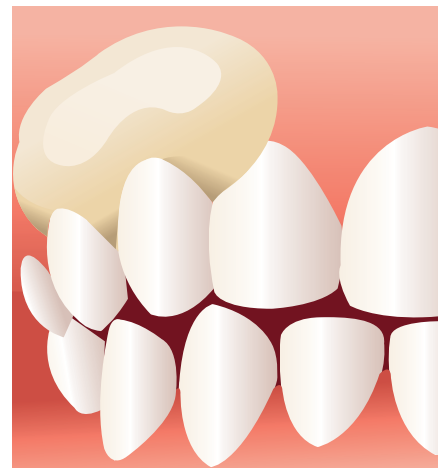
**Hager & Werken GmbH & Co. KG**

PF 100654

47006 Duisburg, Germany

[info@hagerwerken.de](mailto:info@hagerwerken.de)

[www.hagerwerken.de](http://www.hagerwerken.de)



Henry Schein

## Number 1 for social responsibility

Henry Schein, the largest distributor of health care products and services to office-based dental, medical and veterinary practitioners, has been ranked number one in the "Wholesalers: Health Care" industry in *Fortune* Magazine's 2011 list of "World's Most Admired Companies" in the categories of Social Responsibility and Global Competitiveness. The mission of Henry Schein Cares, the Company's global corporate social responsibility program, is to enhance access to care for under-



served populations globally through the support of not-for-profit organizations, institutions, and communities dedicated to increasing the delivery of health education and care. Henry Schein establishes strategic public-private partnerships to carry out this mission with a special emphasis on three areas of focus: wellness, prevention, and treatment; emergency preparedness and relief; and capacity building. "Henry Schein is honored to be included together with some of the most respected companies in the world in *Fortune's* 'World's Most Admired Companies' list," said Stanley M. Bergman, Chairman and Chief Executive Officer of Henry Schein, Inc. "Since our Company's beginning nearly eight

decades ago, Henry Schein has retained a deep commitment to social responsibility. This commitment to giving back to society has endured and, in fact, has steadily grown, as Henry Schein has rapidly expanded our business around the world. Being recognized by our peers and other business leaders for our accomplishments in social responsibility as well as for our global competitiveness, is a source of great pride for us."

**Henry Schein Dental  
Deutschland GmbH**

Monzastraße 2a  
63225 Langen, Germany

[info@henryschein.de](mailto:info@henryschein.de)

[www.henryschein-dental.de](http://www.henryschein-dental.de)

Syneron Dental Lasers

## Cross-Continental Clinical Research Collaboration

Syneron Dental Lasers continues to advance laser dentistry education and clinical research across the globe, this time connecting between the Faculty of Medicine at Plovdiv Medical University in Bulgaria, and the Department of Dentistry at the Cheng Hsin General Hospital in Taipei, Taiwan. The two academic institutions were introduced to one another via Syneron Dental Lasers, as Plovdiv University already has strong cooperation with the company and has already begun conducting extensive clinical research

in laser dentistry, with the LiteTouch™ dental laser. This brand new cooperation means that Assistant Professor Dr. Georgi Tomov, PhD., from the Department of Operative Dentistry and Endodontics at Plovdiv University will assume the role of a supervisory researcher at an interdepartmental project with the goal to facilitate cooperation between the two universities in the field of higher dental laser education and science, as well as promote the cooperation of research in laser-assisted dental treatment. Working with Professor Tzi Kang Peng, PhD., Professor and Chair of the Dept. of Dentistry at Cheng Hsin General Hospital in Taipei, the study in the area of Erbium:YAG Laser in Clinical Dentistry will compare Laser Assisted Periimplantitis Treatment with the Erbium:YAG LiteTouch™ dental laser vs. traditional

surgical treatments, from the perspective of periodontal clinical attachment level gain.

Syneron Dental Lasers is the Gold Sponsor of the WFLD-European Congress, which will convene in Rome on June 9–11. The company will host a multidisciplinary Laser Dentistry Education & Technology Industry Think Tank session at the culmination of the conference.

**Syneron Dental Lasers**

POB 223  
Yokneam 20692, Israel

[dental@syneron.com](mailto:dental@syneron.com)

[www.synerondental.com](http://www.synerondental.com)



# laser

international magazine of laser dentistry



## Publisher

Torsten R. Oemus  
[oemus@oemus-media.de](mailto:oemus@oemus-media.de)

## CEO

Ingolf Döbbecke  
[doebbecke@oemus-media.de](mailto:doebbecke@oemus-media.de)

## Members of the Board

Jürgen Isbaner  
[isbaner@oemus-media.de](mailto:isbaner@oemus-media.de)

Lutz V. Hiller  
[hiller@oemus-media.de](mailto:hiller@oemus-media.de)

## Chief Editorial Manager

Norbert Gutknecht  
[ngutknecht@ukaachen.de](mailto:ngutknecht@ukaachen.de)

## Co-Editors-in-Chief

Samir Nammour  
Jean Paul Rocca

## Managing Editors

Georg Bach  
Leon Vanweersch

## Division Editors

Matthias Frenzen  
*European Division*

George Romanos  
*North America Division*

Carlos de Paula Eduardo  
*South America Division*

Toni Zeinoun  
*Middle East & Africa Division*

Loh Hong Sai  
*Asia & Pacific Division*

## Senior Editors

Aldo Brugneira Junior  
Yoshimitsu Abiko  
Lynn Powell  
John Featherstone  
Adam Stabholz  
Jan Tuner  
Anton Sculean

## Editorial Board

Marcia Martins Marques, Leonardo Silberman, Emina Ibrahim, Igor Cernavin, Daniel Heysselaer, Roeland de Moor, Julia Kamenova, T. Dostalova, Christliebe Pasini, Peter Steen Hansen, Aisha Sultan, Ahmed A Hassan, Marita Luomanen, Patrick Maher, Marie France Bertrand, Frederic Gaultier, Antonis Kallis, Dimitris Strakas, Kenneth Luk, Mukul Jain, Reza Fekrazad, Sharonit Sahar-Helft, Lajos Gaspar, Paolo Vescovi, Marina Vitale, Carlo Fornaini, Kenji Yoshida, Hideaki Suda, Ki-Suk Kim, Liang Ling Seow, Shaymant Singh Makhan, Enrique Trevino, Ahmed Kabir, Blanca de Grande, José Correia de Campos, Carmen Todea, Saleh Ghabban, Stephen Hsu, Antoni Espana Tost, Josep Arnabat, Ahmed Abdullah, Boris Gaspirc, Peter Fahlstedt, Claes Larsson, Michel Vock, Hsin-Cheng Liu, Sajee Sattayut, Ferda Tasar, Sevil Gurgan, Cem Sener, Christopher Mercer, Valentin Preve, Ali Obeidi, Anna-Maria Yannikou, Suchetan Pradhan, Ryan Seto, Joyce Fong, Ingmar Ingenegeren, Peter Kleemann, Iris Brader, Masoud Mojahedi, Gerd Voland, Gabriele Schindler, Ralf Borchers, Stefan Grümer, Joachim Schiffer, Detlef Klotz, Herbert Deppe, Friedrich Lampert, Jörg Meister, Rene Franzen, Andreas Braun, Sabine Sennhenn-Kirchner, Siegfried Jänicke, Olaf Oberhofer, Thorsten Kleinert, Umberto Romeo, Roly Kornblit, Thierry Selli

## Executive Producer

Gernot Meyer  
[meyer@oemus-media.de](mailto:meyer@oemus-media.de)

## Designer

Sarah Fuhrmann  
[s.fuhrmann@oemus-media.de](mailto:s.fuhrmann@oemus-media.de)

## Customer Service

Marius Mezger  
[m.mezger@oemus-media.de](mailto:m.mezger@oemus-media.de)

## Published by

Oemus Media AG  
Holbeinstrasse 29  
04229 Leipzig, Germany  
Tel.: +49 341 48474-0  
Fax: +49 341 48474-290  
[kontakt@oemus-media.de](mailto:kontakt@oemus-media.de)  
[www.oemus.com](http://www.oemus.com)

## Printed by

Messedruck Leipzig GmbH  
An der Hebemärchte 6  
04316 Leipzig, Germany

## laser

international magazine of laser dentistry  
is published in cooperation with the World Federation for Laser Dentistry (WFLD).

## WFLD President

Prof Dr Norbert Gutknecht  
University of Aachen Medical Faculty  
Clinic of Conservative Dentistry  
Pauwelsstr. 30  
52074 Aachen, Germany  
Tel.: +49 241 808964  
Fax: +49 241 803389644  
[ngutknecht@ukaachen.de](mailto:ngutknecht@ukaachen.de)  
[www.wfld-org.info](http://www.wfld-org.info)

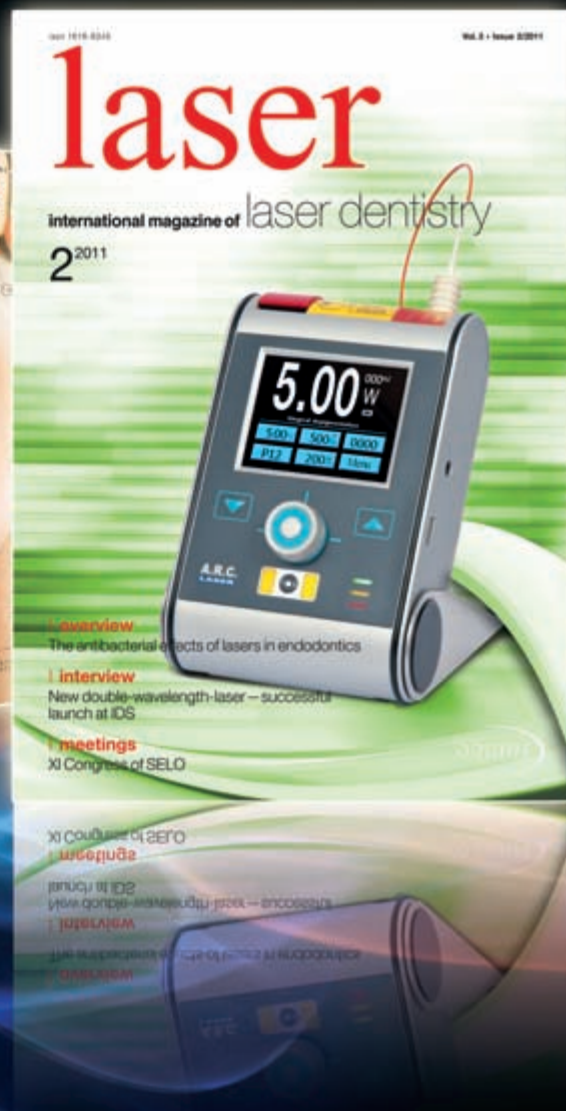## Copyright Regulations

The **laser** international magazine of laser dentistry is published by Oemus Media AG and will appear in 2011 with one issue every quarter. The magazine and all articles and illustrations therein are protected by copyright. Any utilization without the prior consent of editor and publisher is inadmissible and liable to prosecution. This applies in particular to duplicate copies, translations, microfilms, and storage and processing in electronic systems.

Reproductions, including extracts, may only be made with the permission of the publisher. Given no statement to the contrary, any submissions to the editorial department are understood to be in agreement with a full or partial publishing of said submission. The editorial department reserves the right to check all submitted articles for formal errors and factual authority, and to make amendments if necessary. No responsibility shall be taken for unsolicited books and manuscripts. Articles bearing symbols other than that of the editorial department, or which are distinguished by the name of the author, represent the opinion of the afore-mentioned, and do not have to comply with the views of Oemus Media AG. Responsibility for such articles shall be borne by the author. Responsibility for advertisements and other specially labeled items shall not be borne by the editorial department. Likewise, no responsibility shall be assumed for information published about associations, companies and commercial markets. All cases of consequential liability arising from inaccurate or faulty representation are excluded. General terms and conditions apply, legal venue is Leipzig, Germany.

# laser

international magazine of laser dentistry



You can also subscribe via  
[www.oemus.com/abo](http://www.oemus.com/abo)



Subscribe now!

6 / 4, , + 3/ 24 2 1 3/ laser international magazine of  
laser dentistry 224 2 0 1 8 1 / 1 € . , 4 . ( 2 ) 00 . ( . / 1 1- . 423/- 12 € . , 4 . ( 2 ) 00 . ( . / 1 423/- 12 / 432 / 1- . 84. , 22 61 33 . . „ 3/. 22 . 36 3 ) . 82 / 3 ) 1 03 / 3 ) 31 , 24 2 1 03 / . ) 24 2 1 03 / . 6 „ 1 . 6 43/- 3 „ 8 18 8 1 4. 3, 61 33 . . „ 3/. 22 . 33 / , . 231 09 ( 1- . 8 2 7 6 +2 01 / 1 3/ 3 ) 1 . 6 , 3

Last Name, First Name

Company

Street

ZIP/City/County

E-mail

Signature

Notice of revocation: I am able to revoke the subscription within 14 days after my order by sending a written cancellation to OEMUS MEDIA AG, Holbeinstr. 29, 04229 Leipzig, Germany.

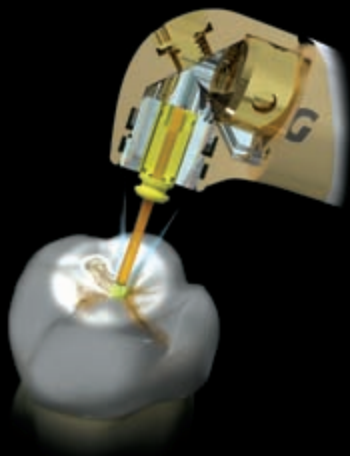
Signature

0,8 7 3/ 3/ / 1 - , 3/ ( 1 22 / - 42 -

# The Dual Wavelength *waterlase*\**iPlus*<sup>™</sup>

Advancing Laser Technology to Its Ultimate

## *i*NCOMPARABLE ACCESS & FIELD OF VISION



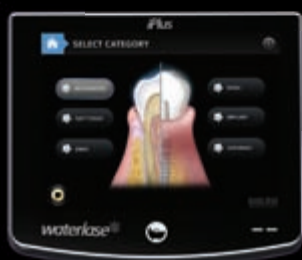- ⊕ No Pain, Therefore No Shot Necessary
- ⊕ No Micro-fractures or Thermal Damage
- ⊕ No Cross Contamination as with Burr
- ⊕ Best Ergonomic & Smallest Design

## *i*NCREDIBLE POWER



- ⊕ Cutting Speed that Surpasses the High Speed Handpiece and Any Other Dental Laser on the Market
- ⊕ Cuts Faster and More Efficiently than Lasers with More Power Watts
- ⊕ Combines 0.5-10 Watts Power with 100 Hz & Short Pulse for 600 mJ of Laser Energy
- ⊕ Patented Laser Technology

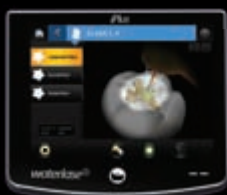## *i*NTUITIVE GRAPHICAL USER INTERFACE



- ⊕ Step 1: Application

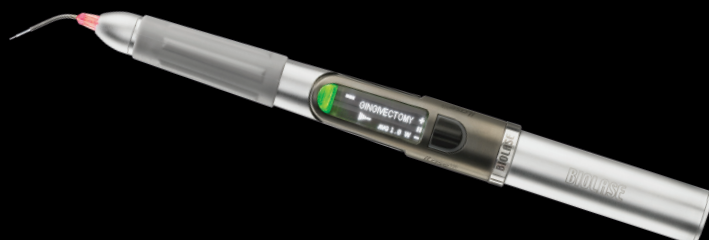

- ⊕ Step 2: Procedure



- ⊕ Step 3: No Shot/No Drill

## *i*LASE 940nm DIODE LASER



- ⊕ 5 Watts of Power with ComfortPulse
- ⊕ Handheld & Ergonomic
- ⊕ Battery Operated with Finger Switch Activation
- ⊕ Proprietary Multi-diameter/Length Bendable Tips
- ⊕ Single Use for NO Cross Contamination