

# Key principles that enhance success when restoring endodontically treated teeth

**Authors\_** Dr Nadim Z. Baba & Dr Charles J. Goodacre, USA

**\_Restoring endodontically treated teeth** and retaining them throughout life remains a challenge. Several factors play a key role in the long-term survival of endodontically treated teeth and associated restorations. The purpose of this article is to identify the key principles that affect tooth and restoration survival.

## **\_Principle #I**

*Most endodontically treated posterior teeth should be restored with crowns to enhance their longevity.*

Clinicians have observed a difference between endodontically treated teeth and vital teeth. Endodontically treated teeth fracture more often than vital teeth: they tend to break during extraction and pulpless molars without crowns can fracture.<sup>1,2</sup>

Multiple studies have shown that endodontically treated teeth benefit from the placement of crowns. One study determined that endodontically treated teeth without crowns were lost at six times the rate of those with crowns.<sup>3</sup> Another study demonstrated that endodontically treated teeth without crowns were lost after an average time of 50 months, whereas endodontically treated teeth with crowns were lost after an average time of 87 months.<sup>4</sup> Fixed partial dentures have increased clinical failure when supported by endodontically treated abutment teeth compared with vital abutment teeth.<sup>1,5-8</sup> However, while crowns significantly improved the success of endodontically treated posterior teeth it has not been shown that they improve the success of anterior teeth.<sup>9</sup> Therefore, intact or minimally restored endodontically treated anterior teeth do not need complete coverage by a crown. They only need a crown when they are weakened by large and/or multiple coronal restorations or when they require significant colour/form changes that cannot be managed by a more conservative treatment.<sup>10</sup>

In contrast with the above studies, a group of researchers<sup>11</sup> found similar success rates when they evaluated endodontically treated premolars restored with a post and direct composite resin restorations both with and without complete coverage. Similarly, a retrospective cohort study<sup>12</sup> indicated that endodontically treated molars that are intact, except for the access opening, could be restored successfully using composite resin restorations.

After considering the available data, we recognise the potential benefits of using composite resin to restore posterior teeth that are intact except for a conservative access opening. However, more clinical data is needed that identifies the long-term success of these teeth when occlusal wear and heavy forces or para-functional habits are present. For this reason, we recommend that endodontically treated teeth that have been previously restored receive crowns that encompass the cusps because of the occlusal forces that will be applied to cusps that have been weakened by previous tooth structure removal. Conversely, it may be possible to avoid crowns on some previously restored posterior teeth with only conservative access openings and little to no wear visible that would indicate the presence of detrimental occlusal forces. Another example of a tooth that may not need a crown is a mandibular first premolar, which typically has a small, poorly developed lingual cusp and a lack of occlusal interdigitation that might spread the cusps apart and induce fracture.<sup>13</sup>

## **\_Principle #II**

*Posts do not reinforce endodontically treated teeth. Their only purpose is to retain the core.*

Historically, the use of posts was based on the concept that they reinforce teeth. Virtually every laboratory study has shown that either posts do not reinforce teeth or they decrease the fracture strength

resistance of the tooth when a force is applied via a mechanical testing machine.<sup>14-24</sup> Additionally, studies have compared the fracture resistance of endodontically treated extracted teeth without posts or crowns with the fracture resistance of teeth restored with posts, cores and crowns. Maxillary incisors, without posts, resisted higher failure loads than the other groups with posts and crowns,<sup>16</sup> and mandibular incisors with intact natural crowns exhibited greater resistance to transverse loads than teeth with posts and cores.<sup>17</sup> These studies show no evidence that posts have a strengthening reinforcement effect (Fig. 1).

Clinical studies have also failed to provide definitive support for the concept that posts strengthen endodontically treated teeth.<sup>2, 10, 25, 26</sup> When the radiographs of 200 consecutively treated patients were examined several years after endodontic treatment, it was determined that teeth with posts had significantly more apical periodontitis.<sup>2</sup> An analysis of data from multiple clinical studies noted that 3% of teeth with posts fractured and found no evidence that posts enhanced the survival of teeth.<sup>26</sup> Posts have had little enhancing effect on the clinical success of fixed partial denture abutments, but they have improved the clinical success of removable partial denture abutments compared with endodontically treated abutments where no posts were used.<sup>10</sup>

Since clinical and laboratory data indicate that teeth are not strengthened by posts, their purpose is the retention of a core that will provide adequate retention and support for the definitive crown or prosthesis. Unfortunately, this primary purpose has not been completely recognised. A survey demonstrated that 24% of general dental practitioners felt that posts strengthen the teeth.<sup>27</sup> Another survey found that 62% of dentists over the age of 50 believed that posts reinforce the teeth (39% of part-time faculty, 41% of full-time faculty and 56% of non-faculty practitioners), whereas only 41% of dentists under the age of 41 did not believe this.<sup>28</sup> An additional survey found that 29% of general dental practition-

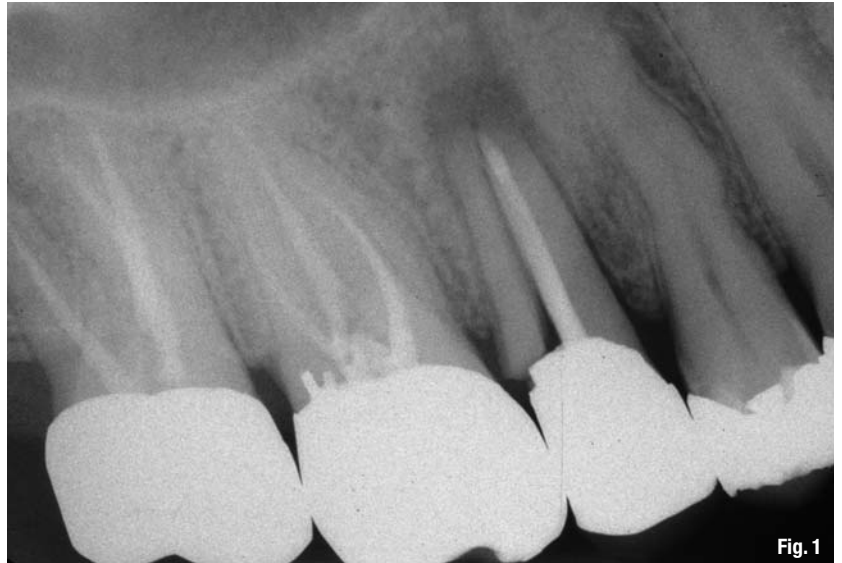

Fig. 1

ers felt that posts reinforced the teeth, and 17% of board-certified prosthodontists in Sweden believed this too.<sup>2</sup>

**Fig. 1** A radiograph of a fractured maxillary second premolar with a metallic prefabricated post.

Since posts do not reinforce a tooth, they should only be used when the core cannot be retained by some other means.

### Principle #III

*The radiographic minimal length of gutta-percha should be 5mm to ensure an adequate apical seal.*

After the preparation of an endodontically treated tooth to receive a post, the remaining gutta-percha at the apex is a barrier against the passage of bacteria to the peri-apical area. Several studies<sup>29-31</sup> have found that there is greater leakage when only 2 to 3 mm of gutta-percha is present, but that the preservation of 4 to 5 mm of gutta-percha ensures an adequate seal.<sup>21, 31, 33-35</sup> Although multiple studies have indicated that 4 mm produces an adequate seal, stopping precisely at 4 mm is difficult and radiographic variations in angulation could lead to retention of less

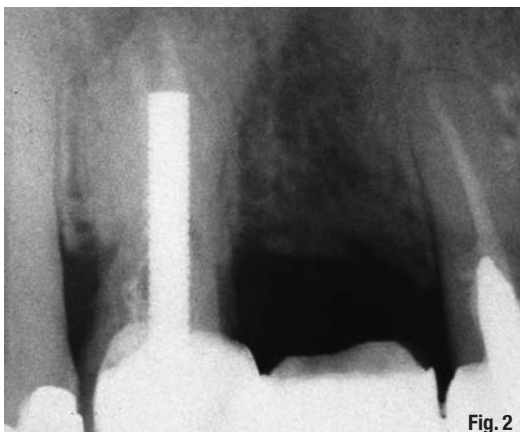


Fig. 2

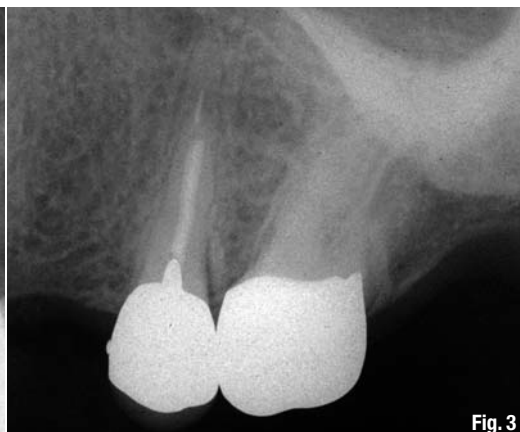
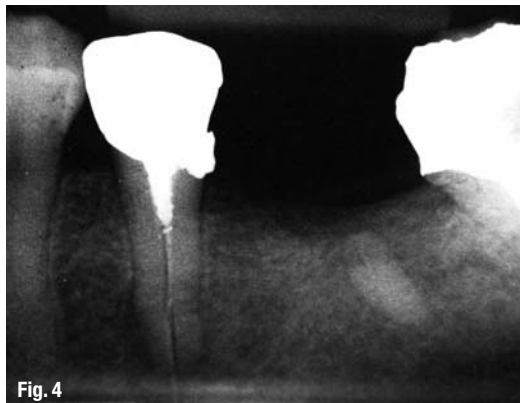
Fig. 3

**Fig. 2** A radiograph of an excessively long parallel-walled post in a maxillary first premolar with a less than ideal amount of gutta-percha remaining at the apex.

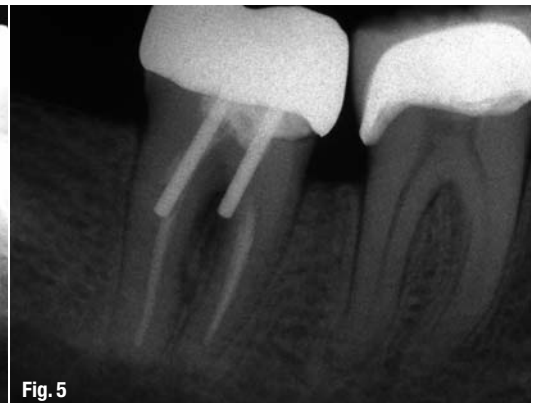**Fig. 3** A very short post in the root of a maxillary second premolar.

**Fig. 4** A threaded post in a mandibular second premolar that caused a root fracture.



**Fig. 4**

**Fig. 5** Perforation of the roots of a mandibular second molar, the result of post space preparation with instruments not held parallel to the root canals.



**Fig. 5**

than 4mm. Therefore, 5mm appears to be a safer minimal radiographic length than 4mm (Fig. 2).

The best method of preserving the apical seal during preparation of a post space is use of the working length determined during endodontic treatment. The same reference point on the tooth used during endodontic therapy should be used during the post preparation. Additionally, a canal preparation instrument with an appropriate diameter should be used in conjunction with a rubber stopper placed around the instrument at the proper location to help ensure that an adequate amount of gutta-percha is retained apically.

Three methods have been advocated for removal of gutta-percha during preparation of a post space without disturbing the apical seal: chemical, thermal and mechanical.<sup>29,32,36-39</sup> It has been determined that both hot hand instruments and rotary instruments can be safely used to remove condensed gutta-percha adequately when 5mm is retained apically.<sup>29,32,3-39</sup>

The immediate removal of gutta-percha after endodontic treatment has also been studied for its effect on the apical seal. Several studies have determined that the removal of gutta-percha immediately after root-canal treatment has no detrimental effect on the apical seal.<sup>30,31,33,36,40</sup>

#### **\_Principle #IV**

*The optimal post length for all teeth, except molars, is determined by retaining 5mm of apical gutta-percha and extending the post to the gutta-percha. For molars, only the primary root should be used and it should not extend more than 7mm into that root. Short posts should be avoided.*

The appropriate length for a post should be based on minimising the potential for damage to the tooth, optimising post retention and maintaining an appropriate apical seal for the root-canal filling. Several length guidelines have been proposed.<sup>41-45</sup> A review of

scientific data provides the basis for differentiating between these varied guidelines.

While short posts have never been advocated, studies have shown that they are frequently observed on radiographs (Fig. 3). It was found that only 34% of 327 posts were as long as the inciso-cervical length of the crown.<sup>46</sup> An evaluation of 200 endodontically treated teeth, determined that only 14% of posts were two-thirds or more of the root length.<sup>47</sup> Another radiographic study of 217 posts determined that only 5% of the posts were two-thirds to three-fourths of the root length.<sup>48</sup> Root fractures caused by high stresses occur more frequently when short posts are used,<sup>23,49-52</sup> whereas increasing the length of a post increases the root fracture resistance.<sup>21</sup>

It was determined that posts that are three-fourths of the root length offered the greatest rigidity and produced the least root deflection.<sup>21</sup> However, use of this apparently optimal post length is difficult with many teeth. When a tooth has an average or below average root length and the post occupies two-thirds or more of the root length, it is not possible to retain 5mm of gutta-percha at the apex.<sup>54</sup> Therefore, optimal post length is determined by retaining 5mm of apical gutta-percha and extending the post to that depth.

The use of this post length guideline is appropriate for all teeth, except molars. A study of 150 extracted maxillary and mandibular molars determined that molar post spaces should not be prepared more than 7mm apical to the orifice of the root canal in the primary roots (the distal root of mandibular molars and the palatal root of maxillary molars) because of the increased likelihood of root perforation.<sup>55</sup> Secondary roots (facial roots of maxillary molars and mesial roots of mandibular molars) cannot even accommodate posts that are 7mm long without excess root thinning and the potential for perforation or root fracture after restoration. Therefore, molar posts should not extend more than 7mm into the primary roots and secondary roots should be avoided whenever possible.

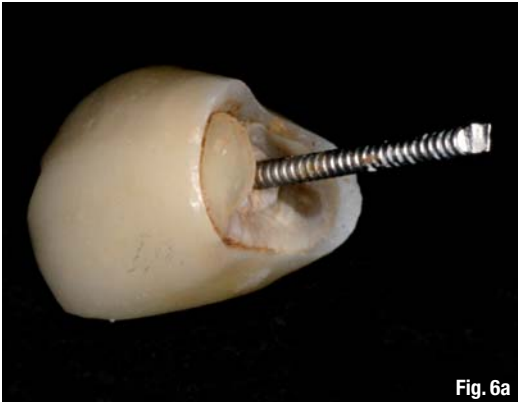

Fig. 6a

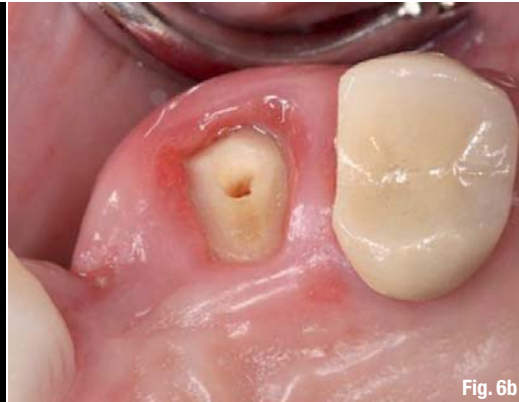

Fig. 6b

**Figs. 6a & b** Post and crown loosened from maxillary canine a few months after placement. Both the core/prefabricated post and the crown came off (a). Clinical photograph shows the absence of cervical tooth structure (ferrule) for retention of the crown (b).

**\_Principle #V**

*Large diameter posts increase the possibility of root thinning, root perforation and root fracture. It is recommended that posts not exceed one-third of the root diameter.*

Increasing the diameter of a post weakens the remaining root. It has been determined that stresses increase in a root as the post diameter increases;<sup>56</sup> larger post diameters decrease the resistance to tooth fracture.<sup>53</sup> With large diameter posts (1.5 mm or more), it was determined<sup>57</sup> that there was a six-fold increase in the potential for root fracture for every mm of increased post diameter.

Studies have shown that root fracture is the second most common cause of post and core failure.<sup>58-62</sup> Multiple factors have been associated with the potential for root fracture, including large diameter posts,<sup>23, 50, 56</sup> short posts,<sup>23, 49-52</sup> and threaded posts (Fig. 4).<sup>44, 49, 50, 57, 63-65</sup> It is recommended that the post diameter not exceed one-third of the root diameter<sup>55</sup>

and that the post diameter be proportionally related to average root dimensions.

To ensure that posts do not exceed one-third of the root diameter, the post diameter should be between 0.6 and 1.2 mm, depending on the tooth.<sup>66-68</sup> Only post preparation instruments that match the desired diameter of the post space should be used. When using a particular brand of post, make sure that the matching drill belongs to the same type of post (Tables I & II).

A good understanding of dental anatomy, the configuration of the roots and their variations, and use of an appropriate instrument angulation help in avoiding root thinning and perforation. Instruments should be angled so that they follow the canal (Fig. 5).

When posts are needed in premolars, they are best placed in the palatal root of the maxillary premolar and the straightest root of any mandibular premolar with multiple roots. Root taper, curvature and depressions should be reviewed prior to post preparation.

**Table I** Suggested maximum diameter based on root dimensions and pulp morphology for maxillary teeth.

Maxillary teeth	Central incisor	Lateral incisor	Canine	First premolar	Second premolar	First molar	Second molar
Number of canals*	100 %: 1 canal			83 %: 2 canals 12 %: 1 canal 2 %: 3 canals	48 %: 1 canal 43 %: 2 canals 0.6 %: 3 canals	<b>mesiobuccal root</b> 59.2 %: 2 or more canals 40.8 %: 1 canal  <b>distobuccal root</b> 98.3 %: 1 canal 1.7 %: 2 or more canals  <b>palatal root</b> 99.9 %: 1 canal 1 %: 2 or more canals	<b>mesiobuccal root</b> 51.5 %: 1 canal 47 %: 2 or more canals  <b>distobuccal root</b> 99.7 %: 1 canal 0.3 %: 2 or more canals  <b>palatal root</b> 99.9 %: 1 canal 0.1 %: 2 or more canals
Number of roots*	1 root			75 %: 2 roots 23 %: 1 root 2 %: 3 roots	90.7 %: 1 root 9 %: 2 roots 0.3 %: 3 roots	95.9 %: 3 roots 3.9 %: 2 roots	88.6 %: 3 roots 7.8 %: 2 roots 2.8 %: 1 root 0.4 %: 4 roots
Suggested post diameter in mm**	1-1.7	0.8	1-1.5	0.8-1 in the palatal root		1 in the palatal root	

Table I

Manibular teeth	Central incisor	Lateral incisor	Canine	First premolar	Second premolar	First molar	Second molar
Number of canals*	75 %: 1 canal 25 %: 2 canals 6 %: >2 canals	72 %: 1 canal 28 %: 2 canals 2 %: >2 canals	89.4 %: 1 canal 10.6 %: canal	74 %: 1 canal 25 %: 2 canals 1 %: 3 canals	93 %: 1 canal 7 %: 2 canals <0.05 %: 3 canals	<b>2 rooted teeth</b> <b>mesial root</b> 95.7 %: 2 or more canals 4.3 %: 1 canal  <b>distal root</b> 68.4 %: 1 canal 31.6 %: 2 or more canals  <b>3 rooted teeth</b> <b>mesial root</b> 100 %: 2 or more canals  <b>distobuccal root</b> 97.6 %: 1 canal 2.4 %: 2 or more canals  <b>distolingual root</b> 100 %: 1 canal	<b>mesial root</b> 86 %: 2 or more canals 14 %: 1 canal  <b>distal root</b> 85.1 %: 1 canal 14.9 %: 2 or more canals
Number of roots*	100 %: 1 root		94.8 %: 1 root 5.2 %: 2 roots	95 %: 1 root 5 %: 2 roots	98.5 %: 1 root 1 %: 2 roots 0.5 %: 3 roots	80.9 %: 2 roots 12.8 %: 3 roots 0.04 %: 4 roots	84.1 %: 2 roots 1.5 %: 3 roots 2.5 %: 1 root
Suggested post diameter in mm**	0.5–0.8	0.5–1	1–1.5	0.8–1		1 in the distal root	

Table II

**Table II** \_Suggested maximum diameter based on root dimensions and pulp morphology for mandibular teeth.

\*Adapted from data present in Dental Anatomy & Interactive 3-D Atlas and provided by Dr Blaine Cleghorn, Dalhousie University, Canada, November 2007.

\*\*Adapted from data published by Shillingburg, 1982 and Tilk, 1979.

When posts are needed in molars, they should be placed in roots that have the greatest dentine thickness. These roots are known as the primary roots and they are the palatal roots of maxillary molars and the distal roots of mandibular molars. However, it is important to remember that extension of a post more than 7 mm apical to the root-canal orifice in primary canals increases the risk of perforation.<sup>55</sup> The mesial roots of mandibular molars and the facial roots of maxillary molars should be avoided if at all possible. Attention should also be given to avoiding instrument pressure on the root surface towards the furcation, as this surface is thinned more easily than the outer surface owing to root curvature.

With all teeth, the apical 5 mm of the roots should be avoided because most root curvatures occur within 5 mm of the root apex<sup>69</sup> and entrance into this area increases the risk of excessive root thinning or perforation.

### \_Principle #VI

*A cervical ferrule should engage 2 mm of tooth structure to prevent root fracture.*

Ferrules can be established by the core engaging tooth structure (core ferrule)<sup>70–73</sup> or by the crown overlying/encompassing sound tooth structure apical to the core (crown ferrule).<sup>74–79</sup> The data indicates that crown ferrules are more effective than core ferrules<sup>71–73,80</sup> and crown ferrules increase the tooth's re-

sistance to fracture.<sup>74,75,80</sup> In spite of the data supporting the benefit of crown ferrules, not all practitioners recognise their value. A survey published by Morgano *et al.*<sup>80</sup> evaluated the percentage of respondents who felt a ferrule increased a tooth's resistance to fracture: 56% of general dentists, 67% of prosthodontists and 73% of board-certified prosthodontists felt that core ferrules increased a tooth's fracture resistance.

Different lengths and forms of the ferrule have been studied.<sup>74,76,77,81</sup> The length and form are essential to the success of the "ferrule effect". When possible, encompassing 2 mm of intact tooth structure around the entire circumference of a core creates an optimally effective crown ferrule. Ferrule effectiveness is enhanced by grasping larger amounts of tooth structure. The amount of tooth structure engaged by the overlying crown appears to be more important than the length of the post in increasing a tooth's resistance to fracture (Fig. 6).

If insufficient cervical tooth structure remains to develop a ferrule, surgical crown lengthening or orthodontic extrusion should be considered to expose more tooth structure. In some situations, it may be prudent to extract a tooth and replace it with an implant and crown when one or more of the following conditions is present: a ferrule cannot be developed; crown lengthening would create an unacceptable aesthetic environment or produce a furcation defect; or a short root is present that would not permit appropriate post length to be developed.

## \_Principle #VII

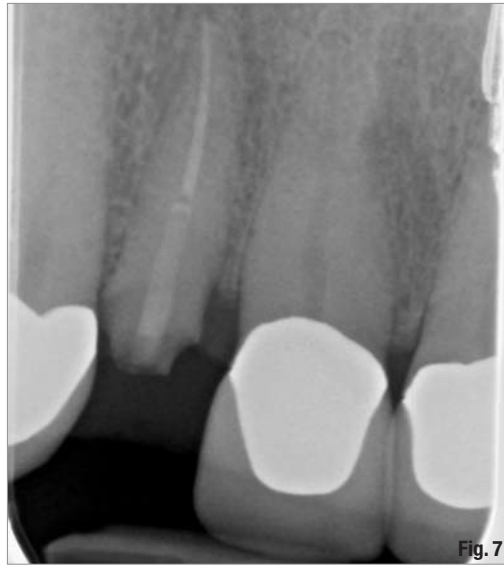*Until more long-term data is available, fibre-reinforced resin posts should be used with caution.*

For many years, the standard method of restoring endodontically treated teeth has been either a custom cast post and core or a prefabricated metal post with a restorative material core.<sup>41, 82, 83</sup> A nationwide survey of dentists in 1994 reported that 40% of general practitioners used prefabricated posts, and the most popular post was the parallel-sided serrated metal post.<sup>28</sup> The usage of prefabricated posts has undoubtedly increased even more substantially since the 1994 survey. The high demand for aesthetic restorations and all-ceramic crowns led to the development of a variety of non-metallic prefabricated post systems as alternatives to metal posts.<sup>84-87</sup> In addition to the aesthetic advantages of non-metallic posts, laboratory studies have shown that the resin-based alternative posts have favourable physical and mechanical properties and there is less root fracture with fibre-reinforced resin posts than with metal posts.<sup>88-92</sup> However, clinical studies of fibre-reinforced posts have produced a wide range of reported failure percentages, ranging from 0% after a mean of 2.3 years to 11.4% after 2 years.<sup>9, 58-61, 63, 93-96</sup> Post loosening and root fracture have been the most commonly reported complications (Fig. 7).<sup>58-62, 93, 97, 98</sup> Because the core depends on the retentive capacity of the post, the prognosis of the final restoration is highly dependent on the retention of the post.<sup>99</sup> Given the wide range of reported failure percentages, it appears that additional long-term clinical data is needed to determine the efficacy of fibre-reinforced posts.

## \_Conclusion

Based on this review of available research, the following clinical recommendations are made:

1. Crowns are not needed for intact or minimally restored anterior teeth except when substantial colour or form changes cannot be accomplished by more conservative means.
2. Crowns should be placed on most endodontically treated posterior teeth to enhance their long-term survival. There is some data that indicates posterior teeth that are intact, except for the access opening, can be satisfactorily restored with composite resin rather than a crown. However, the long-term success of this more conservative treatment in the presence of heavy occlusal forces is not known.
3. Posts weaken teeth and they should only be used when the core cannot be adequately retained by some other means.
4. An adequate apical seal is retained by preserving 5 mm of gutta-percha.



**Fig. 7** A radiograph of a fractured maxillary lateral incisor with a glass fibre post.

5. Short posts should be avoided, as they increase the potential for root fracture. For all teeth except molars, optimal post length is determined by retaining 5 mm of apical gutta-percha and extending the post to that depth. For molars, posts should only be placed in the primary roots (palatal roots or maxillary molars and distal roots of mandibular molars) and they should not be extended more than 7 mm apical to the orifice of the root canal owing to the possibility of root thinning or perforation.
6. The diameter of posts should not exceed one-third of the root diameter to minimise root thinning and the potential for root fracture. Post preparation instrument diameter should be matched to root diameters.
7. When crowns are placed on endodontically treated teeth, they should encompass 2 mm of tooth structure apical to the core whenever possible, since crown ferrules increase the resistance of teeth to fracture.
8. Until more long-term clinical data becomes available, fibre-reinforced resin posts should be used with caution owing to the wide range of reported failure rates in clinical studies.

*Editorial note: A complete list of references is available from the publisher.*

## \_contact

roots



### Dr Nadim Z. Baba

Loma Linda University, School of Dentistry  
Department of Restorative Dentistry  
11092 Anderson Street  
Loma Linda, CA 92350  
USA

nbaba@llu.edu