

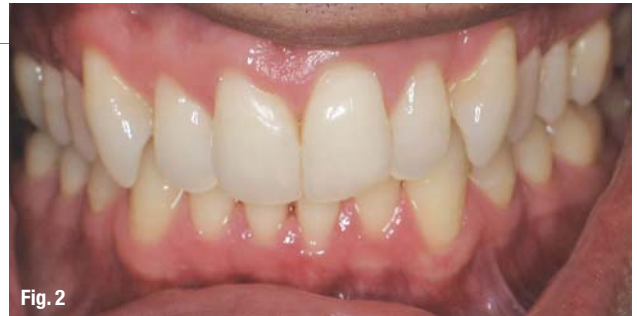# A banker's bond: When less is more

Author\_ Dr Sarah Kong, USA

Fig. 1\_Full face pre-op.



Fig. 2\_Pre-op close-up, retracted.

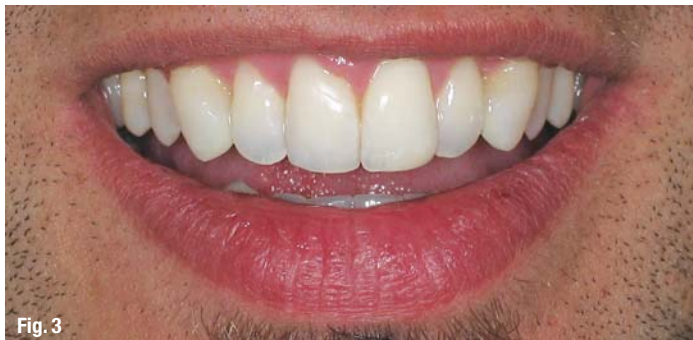

This banking executive was an existing patient who wished to improve his smile. His first treatment arose from a desire to reduce the prominence and pointedness of his upper canines (Figs. 1 & 2). We recommended he try orthodontics and whitening first, and then possibly some cosmetic treatment thereafter, depending on the desired result.

The patient was adamant about not having orthodontics, so we did a mock-up on his canines to see if he liked the way it would look if we bonded his teeth sans orthodontic treatment. He loved the look and was immediately motivated to have his teeth whitened and bonded.

His teeth were deep bleached and the mesial surfaces of the canines were bonded to diminish the pointedness of his canines. He loved the more natural and harmonious look created

Fig. 3\_Pre-op close-up, after canines were bonded.



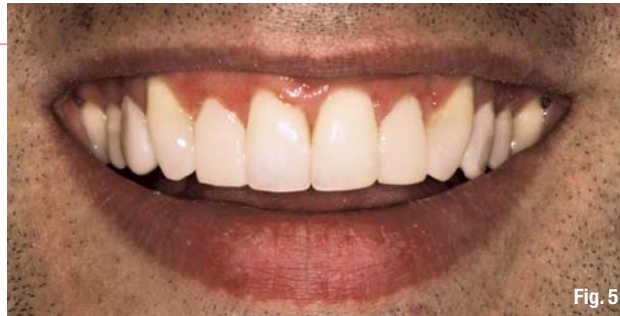by the bonding (Fig. 3). That was about three years ago.

More recently, he came in for his routine prophylaxis appointment and wished to improve his smile a little more. This time, he wanted to see whether we could better align his teeth, again without the aid of orthodontics. He enquired whether porcelain veneers for all his teeth would be a feasible option.

Closer clinical examination revealed several cosmetic issues, including but not limited to:

1. palatally inclined lateral incisors;
2. prominent and mesially rotated canines;
3. tooth #9 was slightly more retroclined than tooth #8;
4. an uneven gumline due mainly to a large cervical divot on tooth #8 with associated gingival overgrowth;
5. anterior crowding; and
6. retruded premolars that caused the smile to end at the canines in a narrow arch form (Fig. 3).

We discussed all these issues with the patient and then, as before, created a mock-up of teeth #7 to 10 to show the patient what he would look like with four resin veneers (Figs. 4 & 5).



**Fig. 4** Full-face with mock-up of teeth #7 and 10.

**Fig. 5** Mock-up, close-up of veneers on teeth #7 to 10.

The patient did not understand the need for the gumlift on tooth #8, so we added bonding to the gumline to give the illusion of a more uniform gumline that the patient could see and understand. At this stage, we pointed out that his premolars appeared to fall away from his smile and become lost in the buccal corridor. The premolars on one side were mocked up as resin veneers so he could see the difference the built up teeth would make in comparison to the other side.

Multiple images of the various mock-up options were taken and e-mailed to the patient, along with multiple treatment plan options. After careful consideration, the patient opted for the resin veneers on teeth #7 to 10, as well as the gumlift.

It was because of the mock-up and photographs that the patient realised the value of the gumlift in creating a more attractive smile. He wanted to consider the resin veneers for the premolars and possibly have them done in the future.

### The procedure

The patient presented for the bonding appointment with his teeth already whitened. We began by placing topical anaesthetic before anaesthetising teeth #7 to 10 with The Wand

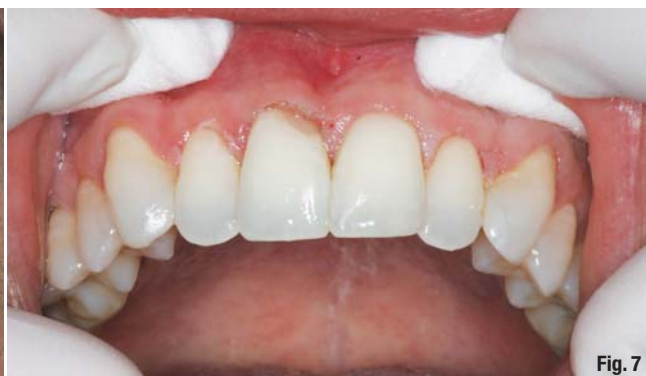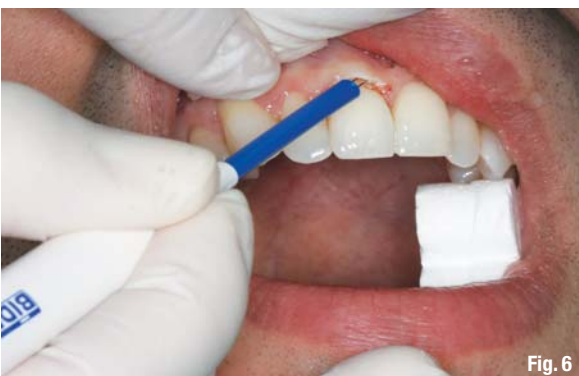(Milestone Scientific). Subsequent injections of lidocaine were placed around the gumline of teeth #7 to 10 before electrosurgery of the gums.

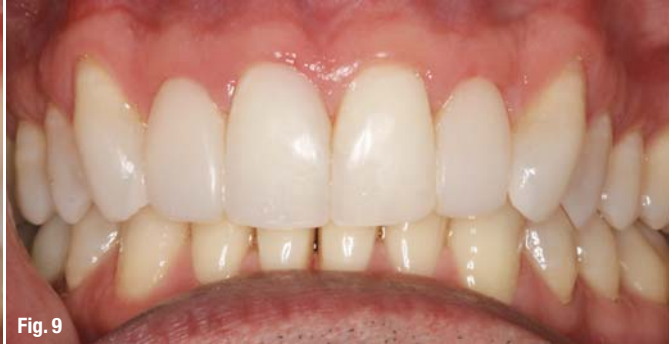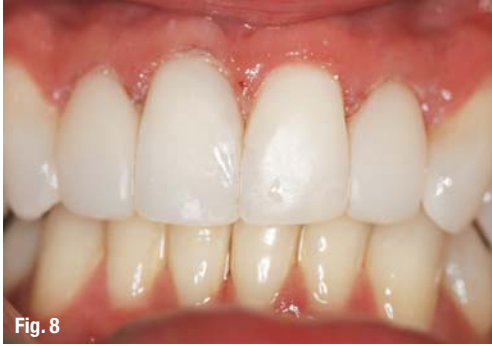Using Bident (Synergetics), a bipolar electrosurgery unit, the gingiva around tooth #8 was contoured to ideal proportions (Figs. 6 & 7). Once the gingiva had been removed, it was discovered that the underlying bone had grown into the cervical divot of tooth #8, right on top of the enamel. It was then decided that crown lengthening was indicated, so a small, round diamond bur was used to contour the bone to match the ideal gumline. We proceeded to contour the gingiva on the mesials of teeth #7 and 10 and to create symmetry of tooth #9 with tooth #8 (Fig. 8). The Bident unit allowed for gentle, clean coagulation in a wet field. There was no grounding needed, and because the unit is meant to be used with water, there was no tissue charring or shrinkage. A more effective, more precise and safer result was achieved, with essentially no post-operative bleeding—a perfect scenario for bonding teeth immediately with no fear of a contaminated field.

The teeth were now ready to be bonded. They were carefully cleaned with pumice to remove any surface debris and stains. Metal strips were placed interproximally to isolate each tooth. Thereafter, they were micro-etched

**Fig. 6** Bident on tooth #8.

**Fig. 7** Gumline after Bident and CCL.





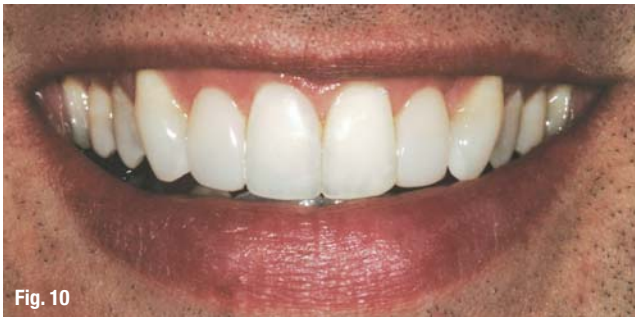**Fig. 8**\_Immediate post-op photograph of resin veneers and gumlift on teeth #7 to 10.

**Fig. 9**\_Close-up two weeks post-op, retracted.

with aluminium oxide to allow for better mechanical retention. Before the application of a bonding agent (OptiBond Solo Plus Unidose, Kerr), 37 % phosphoric etch was placed and rinsed.

Tooth #8 was bonded first using various layers of composite, starting with a micro-hybrid

When he returned for his two-week follow-up visit, the gums were ideally contoured, the resin veneers looked wonderful, and the patient said they felt wonderful too (Fig. 10). No polishing was required, so another high shine polish was done to make them sparkle. Post-operative photographs were taken and the patient was very pleased with the results (Fig. 11).



**Fig. 10**

**Fig. 11**

**Fig. 10**\_Close-up two weeks post-op.

**Fig. 11**\_Happy patient.

(Premise, Kerr/Sybron) and ending with a micro-filled composite (Renamel, COSMEDENT). This tooth was contoured and polished with a series of polishing discs (SHOFU) before proceeding so that the next tooth (#9) could be matched to this tooth without being bonded to it.

Teeth # 7, 9 and 10 were bonded in a similar fashion with various shades to create a more natural, graded appearance. As before, each tooth was polished before bonding the next one. Final contouring and polishing were achieved, and a high shine was gained with a Twist-2-It and polishing paste. In about two hours, the patient had a new smile! Even the post-operative gumline looked amazing immediately, with no bleeding (Fig. 9).


Gentle Gel, an *Aloe vera* and herbal gel, was placed along the gumline and given to the patient to apply at home to help soothe the gums and facilitate quicker healing. The patient was amazed with and loved his new smile immediately.

He also mentioned that he had no immediate post-operative pain, and his gums looked and felt better in just a couple days after the bonding appointment. Overall, the patient was ecstatic about the dramatic improvement, especially the contouring of the gumline, which contributed immensely to the final cosmetic result. He also loved that his beautiful smile

was achieved in a single bonding appointment with a minimally invasive approach—less is more. Now he is already thinking about and looking forward to his next dental venture—resin veneers for his premolars.

\_about the author

cosmetic dentistry



**Dr Sarah Kong** graduated from the Baylor College of Dentistry, where she was later Professor of Restorative Dentistry. She specialises in preventive and restorative dentistry, transitionals, anaesthesia and periodontal

care. Dr Kong is an active member of numerous professional organisations, including the American Dental Association, Academy of General Dentistry, American Academy of Cosmetic Dentistry, Texas Dental Association and Dallas County Dental Society. She can be contacted at [drkong@dallasdentalspa.com](mailto:drkong@dallasdentalspa.com).

# Dental Tribune for iPad – Your weekly news selection

Our editors select the best articles and videos from around the world for you every week. Create your personal edition in your preferred language.

[ipad.dental-tribune.com](http://ipad.dental-tribune.com)

