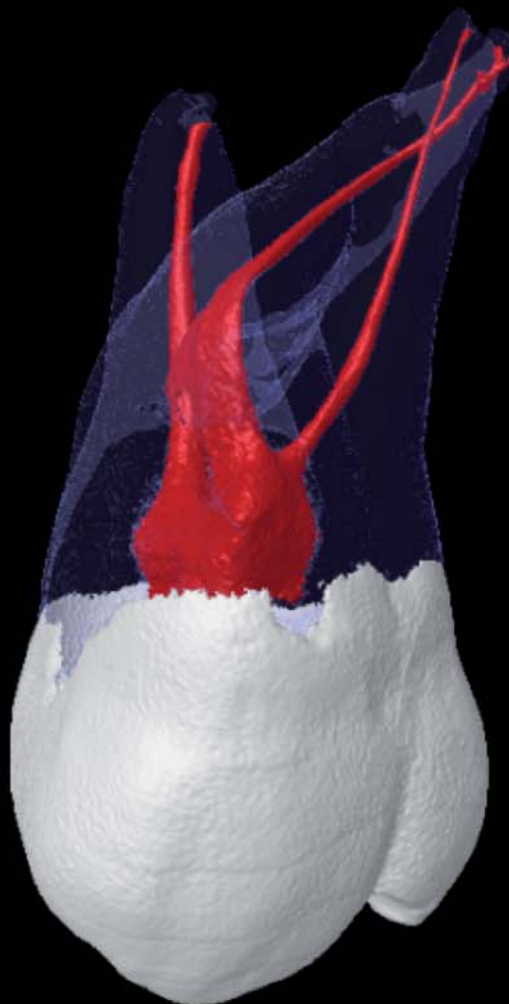

roots

international magazine of endodontology

3²⁰¹¹



| **case report**

White lines or white lies?

| **opinion**

Is rotary NiTi the new paradigm?

| **practice management**

Connectivity in the dental world



Touch Precision



High-tech apex locator for precise length determination

Sets new standards with respect to user-friendliness and design

- Unique 3-D style colour touch screen
- Smart user interface
- Foldable, pocket-sized design

VDW GmbH
P.O. Box 830954 • 81709 Munich • Germany
Tel. +49 89 62734-0 • Fax +49 89 62734-304
www.vdw-dental.com • info@vdw-dental.com



RAYPEX® 6

Apex locator



Endo Easy Efficient®

Dear Reader,



Dr Rafaël Michiels

Endodontics is changing—for better or for worse, that depends on your point of view. Recently, the introduction of new endodontic files aroused the endodontic community. We have seen the arrival of the Self-Adjusting File (SAF), with its revolutionary design and atypical shaping approach. Other recent developments are the WaveOne and Reciproc files, which use a reciprocating movement instead of a continuous rotating movement.

While these innovations offer some advantages to the existing files, we should remain wary. In the last couple of years, a number of innovations have been hyped for a while and then disappeared.

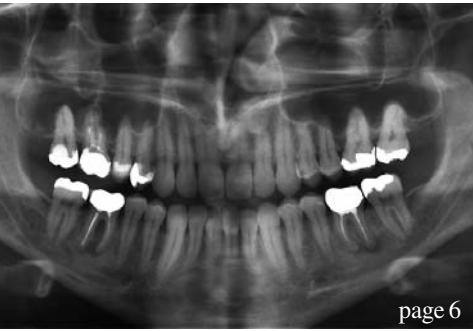If we take a good look at them, then it is my opinion that this is mainly because there is not much new about them. The WaveOne and Reciproc files, for example, are simply automated versions of the "old" balanced force technique propagated by Dr Roane in 1985. "Obturation in three dimensions", the slogan employed by many current obturation devices, has been possible since Dr Schilder's classic article in 1967. Many more examples can be given this way.

There are many other classic articles that describe materials, techniques, anatomy, etc. If you are an optimist, you could say that the recent inventions make it easier and more predictable to achieve the goal of a root-canal treatment according to the fundamental principles. If you are a realist, then you recognise that the problem lies herein: there is a general lack of knowledge of the basic literature in endodontics. If you are not armed with this knowledge, then you are vulnerable to marketing and aggressive sales representatives. We ourselves have the responsibility of stopping this loss of critical thought. We have to keep ourselves up to date by attending congresses, following independent courses and reading the literature. If we manage to do this and if we succeed in teaching our students and colleagues to do the same, then I am sure we can change endodontics for the better with many new materials, techniques and devices to come.

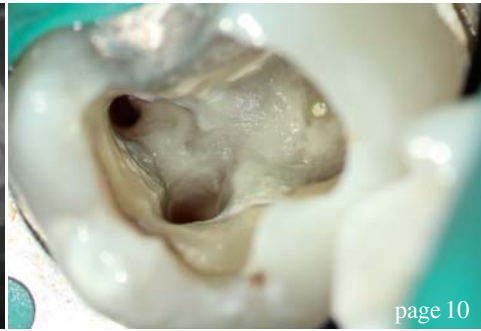I am honoured to contribute to this edition of **roots** and hope you will enjoy this issue and can use it to improve your endodontic treatment.

Yours faithfully,

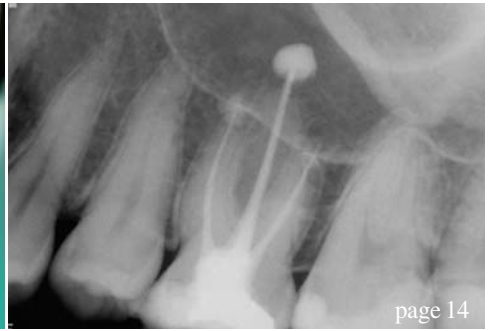Dr Rafaël Michiels
Hasselt, Belgium



page 6



page 10



page 14

| editorial

- 03 **Dear Reader**
| Dr Rafaël Michiels, Guest Editor

| case report

- 06 **Efficient and ergonomic apical resection using the Kaiserswerth algorithm**
| Prof Marcel Wainwright
- 10 **White lines or white lies?**
| Dr Rafaël Michiels
- 14 **A race to the apex—Crown-down in 1!**
| Dr Philippe Sleiman
- 16 **Do we treat patients based on radiolucency? —A case report**
| Dr Sander Loos
- 18 **Are endodontists invited to the treatment planning party?**
| Dr Daniel Flynn

| opinion

- 24 **Is rotary NiTi the new paradigm?**
| Dr Barry L. Musikant

| research

- 28 **CBCT study of root-canal morphology of mandibular first molars in a Spanish population**
| Dr Óliver Valencia de Pablo *et al.*

| feature

- 34 **An interview with Dr Reena Gajjar, My Dental Hub**
- 38 **An interview with Dr Ladislav Grad & Dr Matjaz Lukac, Fotona d.d.**

| practice management

- 40 **Connectivity in the dental world**
| Shane Hebel
- 44 **Six steps to a chartless practice**
| Dr Lorne Lavine

| industry news

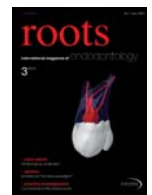
- 47 | Acteon/VDW

| meetings

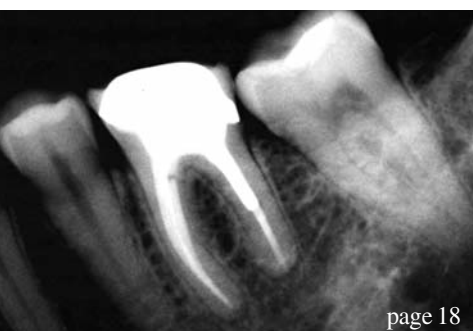- 48 **International Events**

| about the publisher

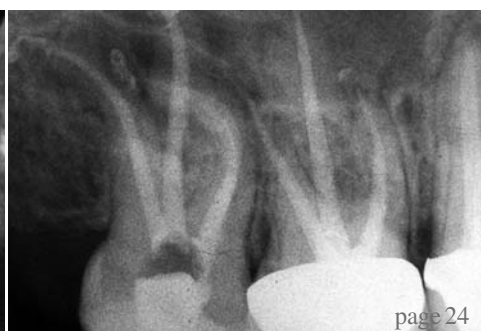- 49 | submission guidelines
- 50 | imprint



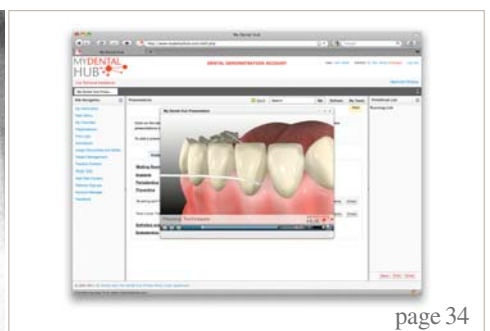Cover image courtesy of Prof Marco Versiani and Prof Manoel D. Sousa Neto, Ribeirão Preto Dental School, University of São Paulo.



page 18



page 24



page 34



Cordless
with an extra-small head

120 Years W&H.
Help us support SOS Children's Villages!



An extra-small head. No cord. And full power. The Entran cordless handpiece provides complete freedom of movement and, thanks to its extra-small head, also gives optimum access to the treatment site. The torque-controlled automatic direction change and the five torque levels set new safety standards in cordless endodontics.

People have Priority! W&H supports the humanitarian organization SOS Children's Villages. Get involved! Further information at wh.com

entran

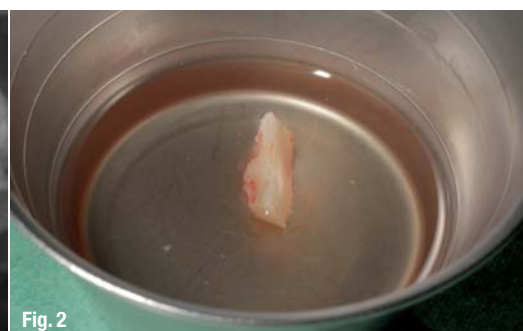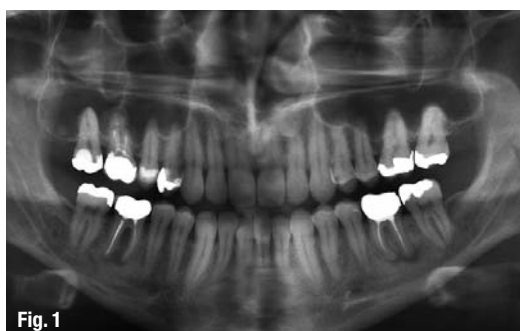Endodontics. Cordless!

Efficient and ergonomic apical resection using the Kaiserswerth algorithm

Author_ Prof Marcel Wainwright, Germany

Fig. 1_OPG showing active infection at sites 16, 36 and 46.

Fig. 2_Bone block, stored in Ringer's solution.



Thanks to minimally invasive techniques, such as ultrasonic surgery and the availability of reliable restorative materials, the surgical revision and rehabilitation of endodontically treated teeth have a significantly better prognosis than only ten years ago. Apical resection is a challenging surgical procedure—not least because of the limited accessibility of the surgical field. Instrumentation of an apical resection case therefore requires a surgical technique that is as simple as it is safe and ergonomic.

Case I

A 34-year-old male patient presented at our clinic for the first time. The orthopantomogram (OPG) yielded an accidental finding of apical translucencies at teeth #14, 36 and 46, which had been insufficiently treated endodontically. Clinically, these translucencies were asymptomatic and diagnosed as instances of chronic apical periodontitis or apical osteitis (Fig. 1).

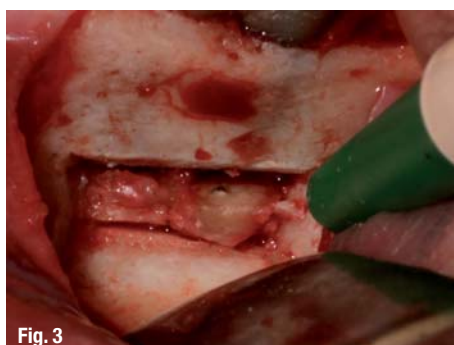
Fig. 3_Surgical site after removing a bone block and performing apical resections on tooth #36.

Fig. 4_The MAP System.

Fig. 5_Autoclavable box with syringe, mixing cup and tips.

This report presents two clinical cases in illustrating a system for applying retrograde endodontic filling materials that has proven a consistently viable option in our clinical practice.

Together with the patient, we planned for an apical resection of tooth #36 in conjunction with a retrograde root-canal filling with subsequent removal of the non-salvageable teeth #16 and 46.

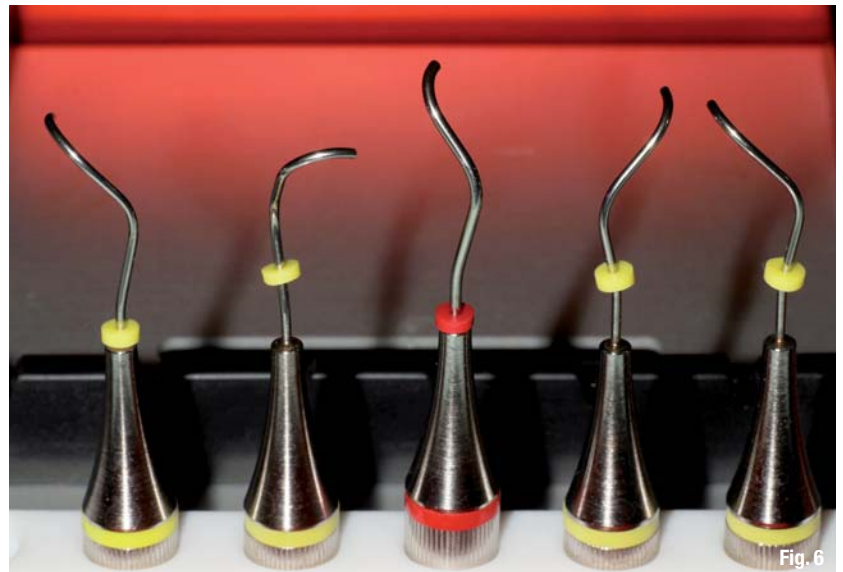


Following extensive consultation and patient education, surgery was performed under local infiltration anaesthesia. With our protocol, block anaesthesia is unnecessary in 98 % of all surgical interventions in the mandible, and dispensing with it minimises the risk of iatrogenic nerve damage.

An incision was performed in the marginal gingiva, with a mesiodistal relief incision, followed by preparation of a full flap for adequate access to the surgical site. Using the Piezotome 2 (Acteon), a buccal bone window of adequate depth was prepared to gain access to the apical region at tooth #36 in order to perform the apical resection. It is helpful for the preparation to provide for undercuts in order to facilitate subsequent removal of the bone block. As no rotary instruments were used and because ultrasonic surgical instruments have a vaso-constrictor effect, the surgical field remained impressively free of bleeding and afforded a clear view of the site. The bone block was stored in Ringer's solution to facilitate subsequent repositioning (Fig. 2). The root apices were then exposed and ultrasonically removed (Fig. 3).

After apical resection, our protocol called for thorough removal of all soft tissue using instruments, followed by complete decontamination of the cyst lumen using a diode laser. Care had to be taken to ensure that the laser tip did not make direct contact with the bone. Retrograde preparation of the root canals was also performed ultrasonically, which only takes a few seconds when using the Piezotome 2.

Following chlorhexidine-digluconate and sodium-hypochlorite rinses, the retro-prepared root canals



were dried with paper points. In our clinic, we have had excellent success with the MAP (Micro-Apical Placement) retro system (PDSA), which has been on the market for many years (Fig. 4). The system comes in a sterilisable metal container (Fig. 5). The triple-angled endo tips (Fig. 6) greatly simplify the uptake and application of the material, with the syringe facilitating "injection" (retrograde obturation) of the root canal to a depth of several millimetres. This well-targeted application of the restorative material keeps the surgical field open (Fig. 7).

On application of ProRoot MTA (DENTSPLY Maillefer), the material was allowed to set, the cross-section surface of the resected area was smoothed and polished, the resection lumen was filled with a

- Fig. 6** Endo tips with different angulations.
- Fig. 7** Applying MTA using the MAP System.
- Fig. 8** The bone block is repositioned and secured with bone cement (VitalOs).
- Fig. 9** Post-op OPG detail following apical resection of tooth #36.
- Fig. 10** Base-line status of tooth #14 following apical resection *alio loco* and reinfection.
- Fig. 11** Surgical site 14 following the semilunar incision.
- Fig. 12** Retrograde ultrasonic preparation (Piezotome 2).

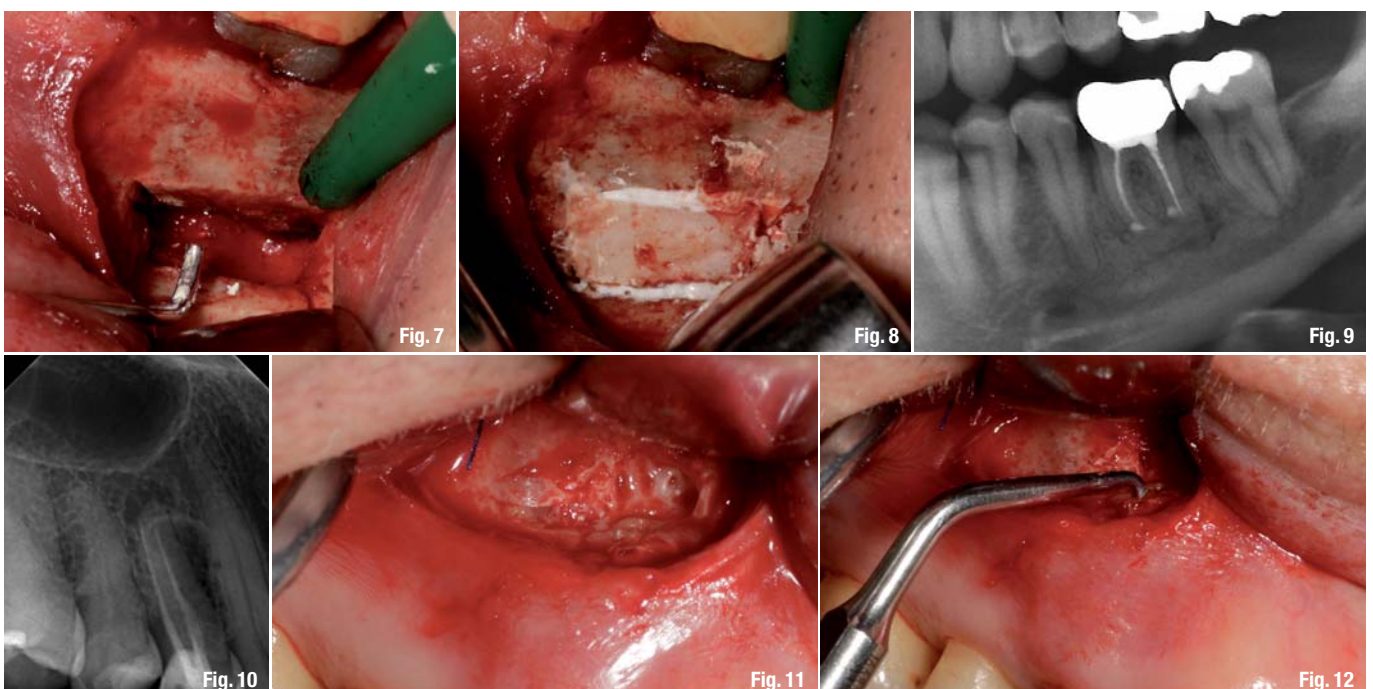




Fig. 13 _Mixed ProRoot MTA prior to application.

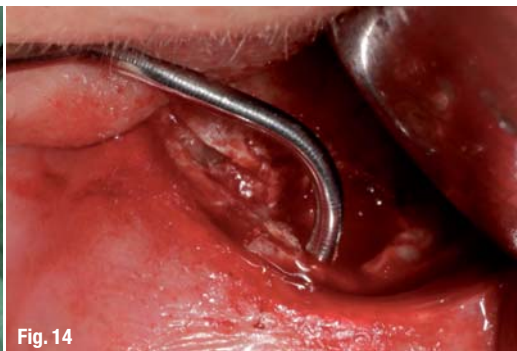

Fig. 14

Fig. 14 _Applying the MTA using the MAP System.

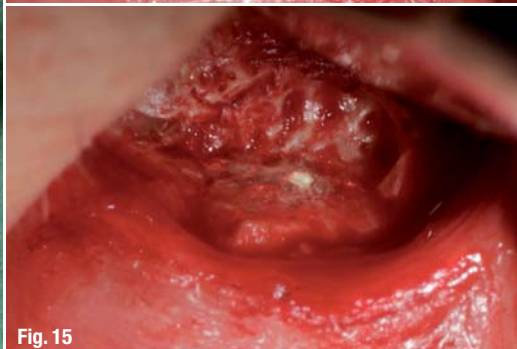

Fig. 15

Fig. 15 _Resected and retro-filled tooth #14.

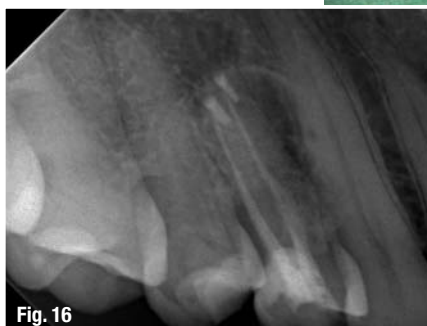

Fig. 16

Fig. 16 _Revision treatment outcome for tooth #14.

quick-hardening bone cement (VitalOs, PDSA), and the bone block was returned to its place (Fig. 8). The post-operative radiograph shows the site following apical resection and retro-grade root filling (Fig. 9).

radiograph (Fig. 16) shows an efficient retrograde filling of both root canals following revision of tooth #14. Owing to a projection artefact, the restorative appeared beside the canals, when it was in fact clinically located exactly within.

The patient was prescribed Amoxicillin 750 mg and Ibuprofen 600 mg post-operatively, as well as Arnica C30 to prevent swelling. Post-operative healing was uncomplicated and the sutures could be removed after eight days. Swelling was minimal, and the patient reported virtually no post-operative pain.

Case II

A 65-year-old female patient presented with an apical resection on tooth #14 that had been performed *alio loco* five years before. The patient was looking for help because the site had become infected again. She reported pain at tooth #14 on occlusal contact and percussion. A local digital radiograph clearly showed the area of apical resection, the two root-canal fillings, and a cystic peri-apical radiolucency (Fig. 10). Since this was a surgical re-entry case, the same incision technique was used as chosen by the primary treatment provider, i.e. a crescent-shaped incision as described by Pichler (Fig. 11). The procedure was otherwise the same as in Case I. Following retrograde ultrasonic preparation (Fig. 12), ProRoot MTA was mixed to a working consistency and applied using the MAP System (Figs. 13 & 14). This clean and efficient application mode and controlled handling shortened the surgical procedure and reduced post-operative complaints (Fig. 15). The post-operative

Conclusion

Apical resection is a routine procedure in our clinic. Thanks to the use of ultrasonic surgery, the surgical laser and the MAP System, this procedure is reliable, predictable and simple, and we have preserved the natural teeth of many patients. Being an oral implantologist myself, I do not perceive anything contradictory in looking at these treatment methods; rather, apical resection is a complementary treatment mode and an attempt to preserve teeth over the longer term that would otherwise be considered lost.

Editorial note: A complete list of references is available from the author.

<u>_contact</u>	roots
<p>Prof Marcel Wainwright Dental Specialists and White Lounge Kaiserswerth Kaiserswerther Markt 25–27 40489 Düsseldorf Germany</p> <p>www.dentalspecialists.de</p>	



Simplicity is the real innovation



wave.one™

- Only one sterile NiTi instrument per root canal in most cases
- Decreases the global shaping time by up to 40%
- Reciprocating technology respecting the root canal anatomy
- Single use as new standard of care

White lines or white lies?

Author_ Dr Rafaël Michiels, Belgium

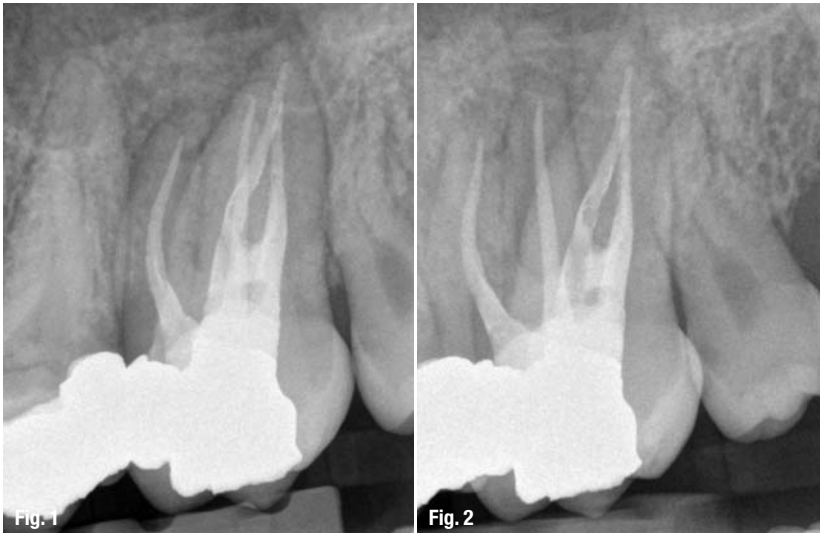


Fig. 1 _Parallel diagnostic radiograph.
Fig. 2 _Eccentric diagnostic radiograph.

With the recent development of new file systems—WaveOne from DENTSPLY Maillefer and RECI-PROC from VDW—endodontists have been having controversial discussions about their usefulness. This is partly due to the aggressive marketing of these products. Great emphasis is laid on simplifying the endodontic procedure. The thought behind this is that creating a simpler shaping protocol will allow the dentist to produce standardised shapes more easily and thus enhance the cleaning of these canals. However, endodontics is not, nor will it be, a simple procedure. There is no such thing as a perfectly round canal. In 1925, Hess already demonstrated that we should not speak of root canals, but rather of root-canal systems.¹

Many other studies have confirmed Hess's findings. Only a few months ago, a micro-CT study guide titled *The Root Canal Anatomy Project* became available online, offering high-resolution images of root-

canal systems, which clearly demonstrate the complexity of those systems.

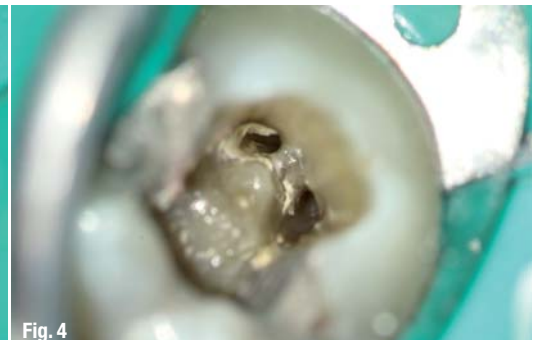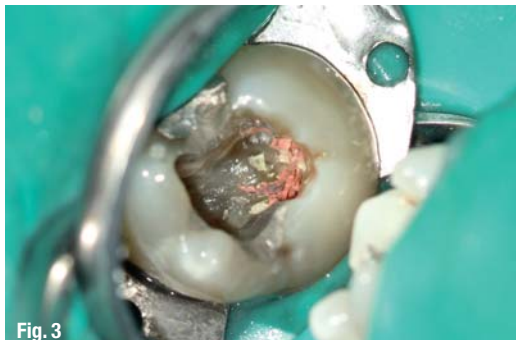If we take another approach to these new file systems, we have to ask ourselves: Do they deliver something new? And the answer is: No, they do not. They re-introduce the concept of reciprocating motion according to the balanced force technique by Roane.² This reciprocating motion does lead to less separation of files, which is an advantage of the current rotary systems.³⁻⁵ When looking at the final size that the Primary WaveOne file creates, we notice that it is similar to that achieved with a ProTaper F2 file (DENTSPLY Maillefer). Therefore, one WaveOne file creates the same shape as four ProTaper files (S1, S2, F1 & F2), which leads to a quicker preparation of the root canal.

The shortened preparation time allows more time for cleaning, but it would be delusional to think that this would happen in reality. As we live in an era in which time is money, quicker preparation will most likely result in less cleaning, thus increasing the number of suboptimal root-canal treatments (RCT). The new file systems also propagate the 'single-use' concept, which eliminates the possibility of cross-contamination or contamination with prions. Although the risk of contamination is very low when using sterilised instruments, it is true that with the pre-sterilised WaveOne files, the risk is zero.

Overall, the new reciprocating file systems have some advantages compared to older rotary files, but the practitioner should be aware that they only shape canals. They do not clean them!

This leads me to the title of this article...

Fig. 3 _Opening cavity.
Fig. 4 _Calcified pulpal tissue in the middle of the palatal canal.



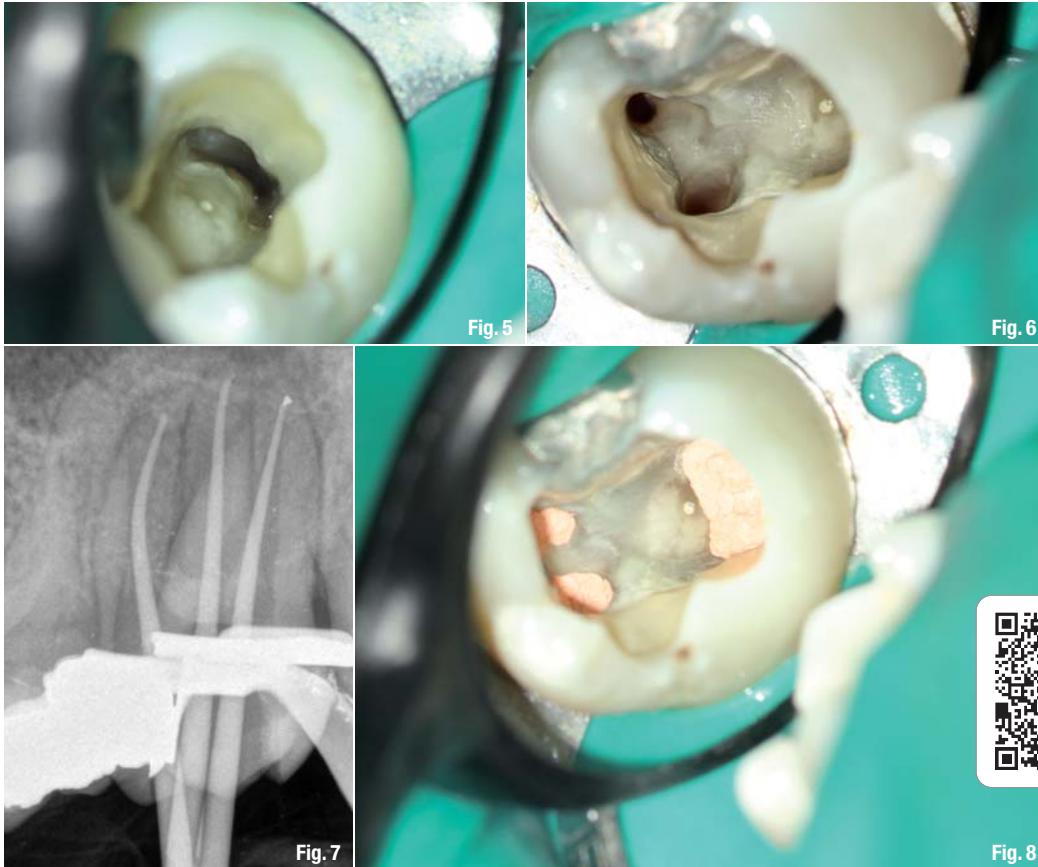


Fig. 5_ The cleaned palatal canal.
Fig. 6_ The cleaned buccal canals.

Fig. 7_ Gutta-percha cone-fitting.
Fig. 8_ The pulp chamber after obturation with gutta-percha.

White lines or white lies?

Most dental manufacturers bring gutta-percha cones and obturators on the market that correspond to the final finishing size of the conforming file system. The promoted obturation techniques are the single-cone technique and carrier-based obturation, both of which have shown to be more prone to leakage than warm vertical condensation.^{6,7}

This is without considering the studies that used the flawed dye-penetration test for micro-leakage. However, the discussion remains whether these techniques are better, worse or equal to warm vertical condensation, and it is not likely that it soon will be over.

Regardless of all this, the clinician is now presented with an 'all-inclusive' system for creating nice white lines on a radiograph and this in a quick and easy way, creating the illusion of perfectly executed RCT. Cleaning has become the bottleneck for treatment time and it is tempting to reduce the total cleaning time, which results in suboptimal RCT. This does not mean that all recent developments are for the worse. To the contrary, dentists should be prudent in their use. The only way to achieve this is to educate dentists properly about the basic fundamental principles in endodontics.

Case report

The following case report is used as an example of nice white lines on a radiograph. A 35-year-old male patient was referred to our practice. Tooth #15 had been treated by the referring dentist, who had found four canals, of which two were palatal canals, which is very rare. The referring dentist applied a standard cleaning protocol with sodium hypochlorite. At first sight, the treatment looked adequate (Figs. 1 & 2). However, the patient kept complaining about the tooth being sensitive when he was eating and he complained of spontaneous pain from time to time. The patient's medical history was non-contributory.

Clinical tests were performed (Table I) and together with the history and the radiographic findings we decided to retreat the tooth. The pulpal diagnosis was a previously treated tooth and the apical diagnosis was symptomatic apical periodontitis.

Table I_ Clinical tests.

	26	27	28
electric pulp test	positive	NA	positive
thermal test	positive	NA	positive
percussion	negative	positive	negative
palpation	negative	positive	negative
periodontal probing	normal	normal	deep pockets

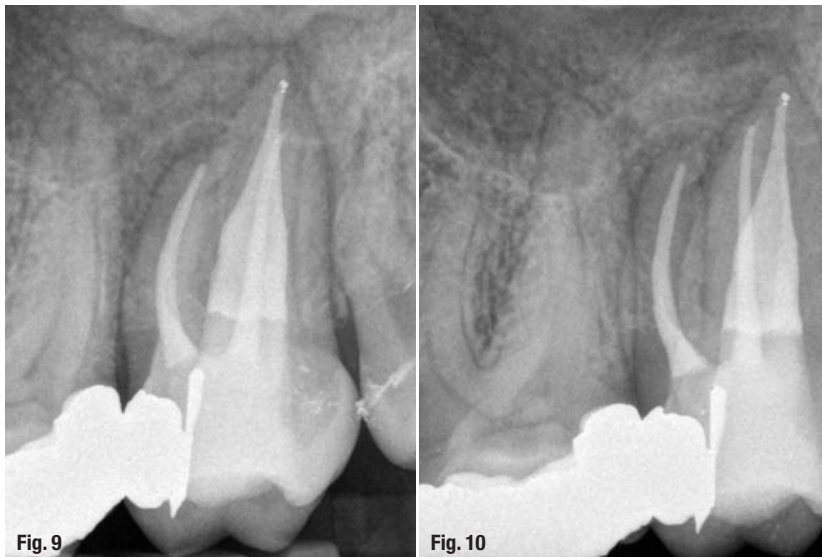

Fig. 9_Post-op radiograph (parallel).

Fig. 10_Post-op radiograph (eccentric).

_Treatment

Initially, the tooth was isolated with a rubber dam and an opening cavity was created through the amalgam restoration (Fig. 3). The canals were located and the opening cavity finished. Using a ProFile 25.06 rotary file (DENTSPLY Maillefer) at 300 rpm, the gutta-percha was removed. No chloroform was

necessary, as it appeared that the canals had been filled using a single-cone technique. As mentioned above, this technique might not be an ideal obturation technique. However, a more striking problem became apparent. The two palatal canals were separated by a piece of calcified pulp tissue (Fig. 4). These pieces of tissue harvest an incredible amount of bacteria and if they are not removed, they can easily lead

to persistent infection. It is not always easy to distinguish the calcified tissue from (tertiary) dentine and if the dentist does not use magnification, it is practically impossible.

The calcified tissue was removed using ultrasound with ProUltra tips (DENTSPLY Maillefer). After the removal of the calcified tissue, there was only one very wide palatal canal left. Both buccal canals were also cleared from the gutta-percha and I searched for a second mesiobuccal canal but was not able to find one. From then onwards, complete cleaning and shaping were performed (see Table II for shaping sequence).

Cleaning was performed with 5% sodium hypochlorite and a final rinse with 10% citric acid for

about three minutes. Both fluids were ultrasonically activated at the end of the treatment, three times for 20 seconds. Passive ultrasonic irrigation was performed with the Irrisafe tip (Satelec), as it provides better results than manual dynamic or sonic activation, according to the literature. Figures 5 and 6 show the canals after they had been dried with paper points.

A control radiograph (Fig. 7) was taken, fitting gutta-percha cones in the canals. It appeared that a small piece of amalgam had fallen into the palatal canal and was stuck apically. I tried to remove it but was unable to do so. I eventually decided to leave it in place, since the effect on the final prognosis is negligible. The canals were obturated with gutta-percha and TopSeal (DENTSPLY Maillefer) using warm vertical condensation (Figs. 8–10). The difference from the original situation was very clear. The canals were now properly cleaned, shaped and obturated.

_Conclusion


White lines on a radiograph are a 2-D representation of obturated canals. These lines do not give away anything about the cleaning, shaping and obturating techniques applied. Hence, they do not tell us anything about the biology of the treated root-canal system. Endodontic files are just instruments that facilitate proper cleaning of the root-canal system. Emphasis should be placed on respecting this root-canal system and the fundamental principles of cleaning, shaping and obturating, rather than creating beautiful white lines in an easy and fast way.

Editorial note: A complete list of references is available from the publisher. A video of the case is available on www.dental-tribune.com/articles/content/id/6165 or simply scan the QR code with your smartphone.

palatal	mesiobuccal	distobuccal
Flexile 15	K-file 10	K-file 10
Flexile 20	Flexile 15	Flexile 15
Flexile 25	Flexile 20	Flexile 20
Flexile 30	ProTaper S1	ProTaper S1
ProFile 35.06	ProTaper S2	ProTaper S2
Flexile 35	ProTaper F1	ProTaper F1
	ProTaper F2	ProTaper F2
	ProFile 35.06	ProFile 35.06
	Flexile 35	Flexile 35

Table II_Shaping sequence.

_about the author
roots



Dr Rafaël Michiels graduated from the Department of Dentistry at Ghent University, Belgium, in 2006. In 2009, he completed the three-year postgraduate programme in Endodontics at the University of Ghent. He works in two private practices limited to Endodontics in Belgium. He can be contacted at rafael.michiels@gmail.com and via his website www.ontzenuwen.be.

implants

international magazine of oral implantology



You can also subscribe via
www.oemus.com/abo

 **Subscribe now!**

One issue free of charge!

I hereby agree to receive a free trial subscription of **implants international magazine of oral implantology** (4 issues per year).

I would like to subscribe to **implants** for € 44 including shipping and VAT for German customers, € 46 including shipping and VAT for customers outside of Germany, unless a written cancellation is sent within 14 days of the receipt of the trial subscription. The subscription will be renewed automatically every year until a written cancellation is sent to OEMUS MEDIA AG, Holbeinstr. 29, 04229 Leipzig, Germany, six weeks prior to the renewal date.

Last Name, First Name

Company

Street

ZIP/City/County

E-mail

Signature

Notice of revocation: I am able to revoke the subscription within 14 days after my order by sending a written cancellation to OEMUS MEDIA AG, Holbeinstr. 29, 04229 Leipzig, Germany.

Signature

Holbeinstr. 29, 04229 Leipzig, Germany, Tel.: +49 341 48474-0, Fax: +49 341 48474-290, E-Mail: grasse@oemus-media.de

OEMUS MEDIA AG



A race to the apex— Crown-down in 1!

Author_ Dr Philippe Sleiman, Lebanon

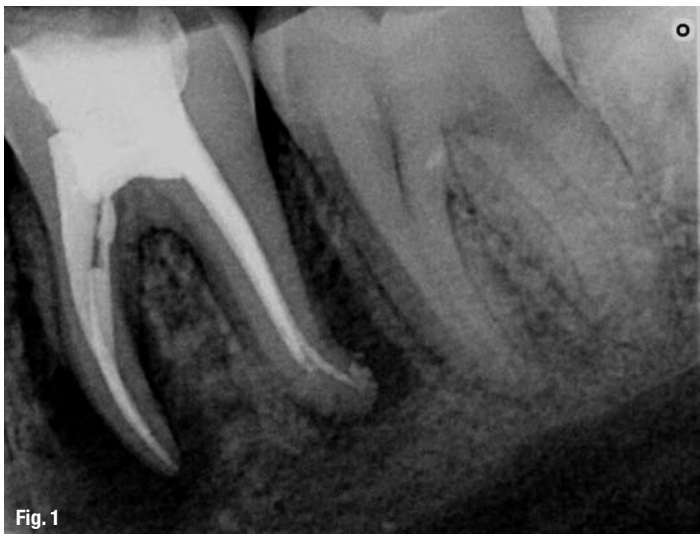

Fig. 1_Immediate post-op of the lower molar, showing the radiolucency around the mesial and distal roots.

Fig. 2_Post-op after eight months, showing very nice healing around both roots.

Fig. 3_Pre-op X-ray, showing the extrusion of the material into the maxillary sinus.

Fig. 4_After removal of the Thermanfil and the paste that was attached to it from inside the palatal root.

_Is it really a race? It seems to me that dentists are very eager to get to the apex as fast as possible these days. For whatever reason, it makes us feel more comfortable when we are able to put a file at the end of a root canal. Its signals mission accomplished for us.

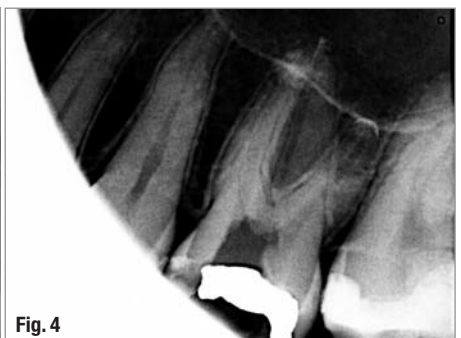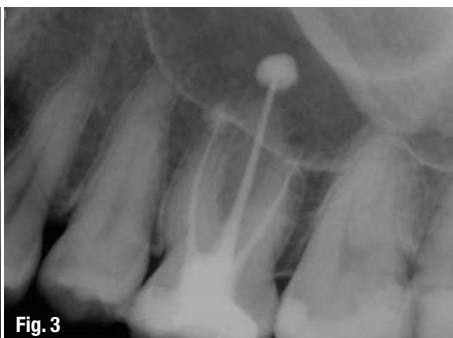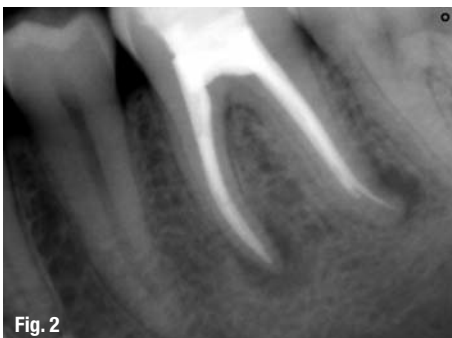Different manufacturers are advertising their techniques, which use practically the same or a slightly modified NiTi alloy in a multistep technique with reciprocating motion. The quality of the dentine, the direction in which the debris is pushed or evacuated and the internal stress on the file itself are some areas of concern regarding these techniques.

One of the characteristics of the R-phase of the Twisted File (TF; SybronEndo) is that it gives the file flexibility and a higher stress tolerance compared with other alloys, which allows for a faster and safer root-canal enlargement. Arrival at the apex can be achieved with one file, if the practitioner is in favour of this technique. Crown-down can be achieved with a single file too, depending on the initial canal anatomy.

_Technique

NiTi files are designed to enlarge and not to open the canal. Thus, checking the canal patency prior to any file enlargement in the environment of a proper irrigating solution is necessary. We can face two different clinical situations related mostly to anatomic considerations:

1. In the upper centrals, laterals and premolars, for example, and even in the distal canal in molars, where we can identify the root-canal space on the preoperative X-ray, no pre-flaring or pre-enlargement is needed. TF 25/08 can easily perform crown-down safely and quickly.
2. In a different clinical situation, such as the lower molars and the mesial canals of the upper molars, it is preferable to check the patency of the canals, as they can be pretty tricky—especially the lower mesial canals, as they present two curves in the centre of the root canal. More importantly, the first



of the two curves will not appear on the X-ray and may become a perfect trap for NiTi files. In such cases, after checking the patency, TF 25/.06 is a perfect file for crown-down. The 25/.06 may get you to the apex in a few seconds or, if you have not reached the apex after the first four strokes, you may need to clean the file, irrigate the canal and try again. The .06 taper is a very good choice for treating curved canals because a larger taper inside a curve may result in taper lock and lead to file separation.

Achieving crown-down in such a fast and high-tech way may tempt us to neglect the irrigation protocol. Here, the use of ultrasonic activation can be of great help to disinfect the canal space and remove the smear layer when this is done with proper irrigating solutions.

Reaching the apex with the crown-down technique may not be the ultimate technique for proper root-canal enlargement, especially with respect to the apical enlargement of the last 3 mm of the canal. According to a variety of studies, the crown-down technique cannot be the sole instrumentation technique, and the last 3 mm of the root-canal space should be addressed in a different way. This subject is a controversy amongst practitioners and amongst schools owing to differences in the philosophy of root-canal enlargement.

I personally support the idea of apical enlargement and find the TF 40/.04 to be the best file to do the job, as it offers the flexibility and safety necessary for reaching the apex after the canal has been enlarged with a 25/.08 or .06 file. In such a case, the total number of files used for the crown-down and apical enlargement will amount to two NiTi files.

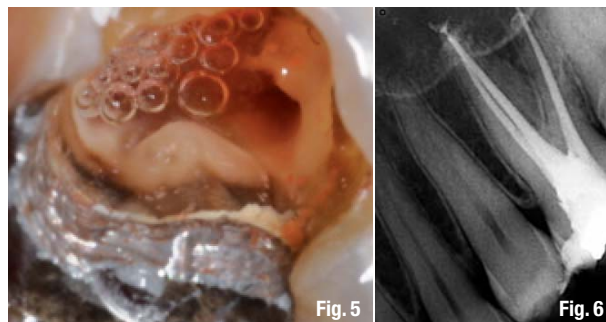
Clinical cases

The patient was referred to the office to check a possible crack in the mesial and distal root (Fig. 1). Depth probing did not reveal a pinpoint pocket. After I had done a bite test and carefully checked the access cavity and the entries of the canals for potential cracks, I decided to treat the root canal and check the post-operative situation, since the patient was desperate to save her tooth.

Upon establishing a direct/straight-line access to the coronal part of the canal, a TF 25/.06 was used for crown-down, which was followed by copious irrigation activated with an ultrasonic file for 15 seconds for each solution used. Apical enlargement was then done with a TF 40/.04, followed by a 15-second activation of sodium hypochlorite in order to eradicate the organic part of the apical biofilm that had been mechanically disrupted with the apical file.

The sodium hypochlorite was carefully removed from the root-canal space using distilled water and ultrasonic activation. Sealing the canal was achieved with Resilon (RealSeal, SybronEndo) in a modified vertical compaction technique. At the eight-month follow-up, nice healing was observed (Fig. 2).

The second case was a bit more complicated (Fig. 3). The patient was referred after she had received a root-canal treatment but was still suffering from pain and pressure in her sinuses. The pre-operative X-ray clearly showed that obturation material inside the palatal root had passed into the sinus cavity. Upon opening the access cavity, I was surprised to see that Thermafil carrier-based obturators (DENTSPLY) had been used, which explained the extrusion of the material into the maxillary sinus. A retreatment was scheduled after the options had been discussed with the patient. Three Thermafil obturators were successfully removed with a TF 25/.06 (Fig. 4). The patient felt immediate relief, as air was escaping the sinus from the palatal canal (Fig. 5).



No sodium hypochlorite was used to irrigate the canal. Chlorhexidine solution was activated slowly with an ultrasonic file and apical enlargement was done with the TF 40/.04, followed by an immediate obturation of the root-canal space with Resilon using a modified vertical obturation technique (Fig. 6). The patient was impressed with the speed of the treatment and expressed her gratitude for saving her molar.

Proper cleaning and shaping of the whole root-canal space have been recognised as a challenge, particularly in curved and narrow canals. NiTi instruments can only prepare a certain percentage of the root-canal space. Irrigation and sealing are the other important steps in the microbial control phase for successful endodontic treatment. A deficiency in mechanical preparation or in the sealing of the root canal could offer the remaining micro-organisms an opportunity to re-colonise the filled canal space, resulting in failure of the endodontic treatment.

I would like to thank Yulia Vorobyeva, interpreter and translator, for her help with this article.

Fig. 5 Air bubbles coming out of the sinus via the palatal canal.
Fig. 6 Sealing of the root canal in the same session.

_contact roots

Dr Philippe Sleiman
Dubai Sky Clinic
Burjuman Business Tower,
Level 21
Trade Center Street,
Bur Dubai
Dubai, UAE

phil2sleiman@hotmail.com

Do we treat patients based on radiolucency? —A case report

Author_ Dr Sander Loos, Netherlands

_Just after Christmas, on 26 December 2010, a 76-year-old male patient, who was in great pain, consulted the emergency dentist. The patient indicated that he felt a throbbing pain in his lower left jaw. The pain was unbearable and had kept him awake all night. The dentist took radiographs of teeth #36 and 37 and an orthopantomogram (OPG; Figs. 1 & 2).

Although the radiograph did not show the full anatomy of tooth #37 and its surrounding structures, the dentist diagnosed apical periodontitis (AP) and advised an endodontic retreatment or extraction and an implant. To make the patient comfortable for the time being, he prescribed 500 mg Amoxicillin and Ibuprofen.

After another sleepless night, the patient consulted a different emergency dentist on 27 December. The analgesics did not give him pain relief and he was starting to become desperate. The second dentist confirmed the original diagnosis and referred the patient to an oral surgeon because an endodontist was not available at short notice. He requested apical surgery on tooth #37.

The following day, the oral surgeon took another OPG and concluded that surgery was not the best treatment option in this case because the apex was located too close to the *nervus alveolaris inferior* and access to the apices of tooth #37 was difficult. He also confirmed the diagnosis of an AP and suggested extraction or endodontic retreatment.

On 5 January 2011, the patient visited my office for the first time. The pain had diminished but not disappeared. Intra-oral examination showed a well-restored dentition with a cantilever bridge on teeth #35 to 37, with #36 and 37 functioning as abutments. Tooth #37 showed an occlusal filling in the crown. Palpation of the buccal fold was not painful and there was no mobility of teeth #36 and 37. The pockets of #36 were within normal limits. However, periodontal probing distal of #37 provoked strong pain and extreme bleeding. The distal pocket measured approximately 6 mm.

As the previously taken radiographs were not available and the OPT was considered unsuitable for proper diagnosis, a peri-apical radiograph (Fig. 3) was taken. The radiograph showed that tooth #37 had previously been treated endodontically. The mesial canals were filled with silver cones rather too short of the apex. There also appeared to be some gutta-percha and a large metal post in the distal

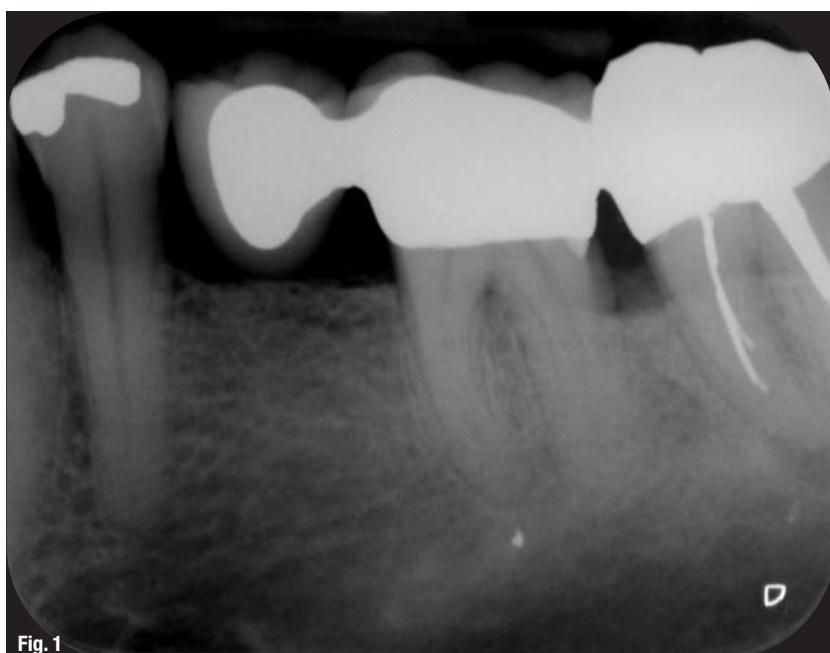
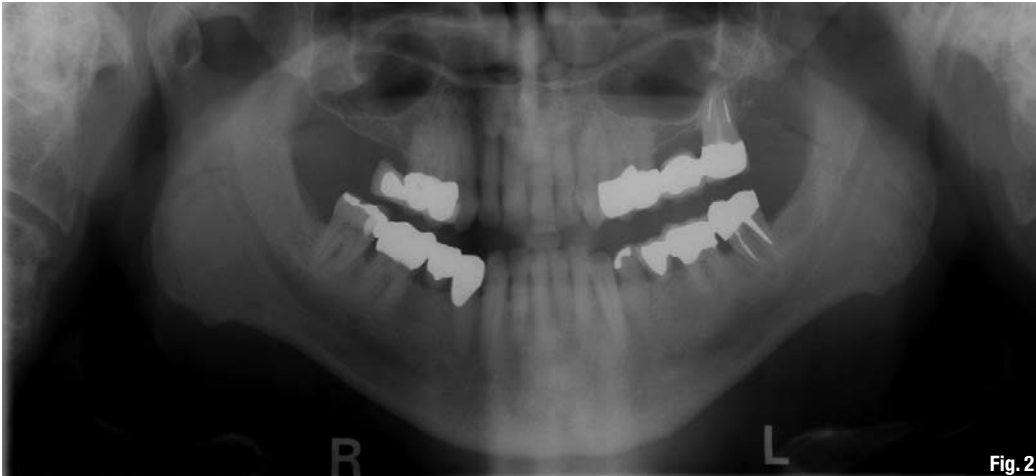


Fig. 1



“The radiographic picture is **only one means of diagnosis** ... the picture **may show a lot of rarefaction**, but to use it as the **sole means of diagnosis** is unwise.”

—Thomas Philip Hinman, 1921—

canal. Additionally, radiolucency was noticeable around the apex of the mesial root. According to the patient, he had received endodontic treatment about 15 years ago owing to pain following bridge cementation. The tooth had been without symptoms since then.

Considering the history and my clinical and radiographic findings, my differential diagnosis was:

1. painful AP owing to reinfection or leakage;
2. painful marginal periodontitis distal of tooth #37 owing to poor oral hygiene;
3. vertical root fracture (VRF) of the distal root of tooth #37.

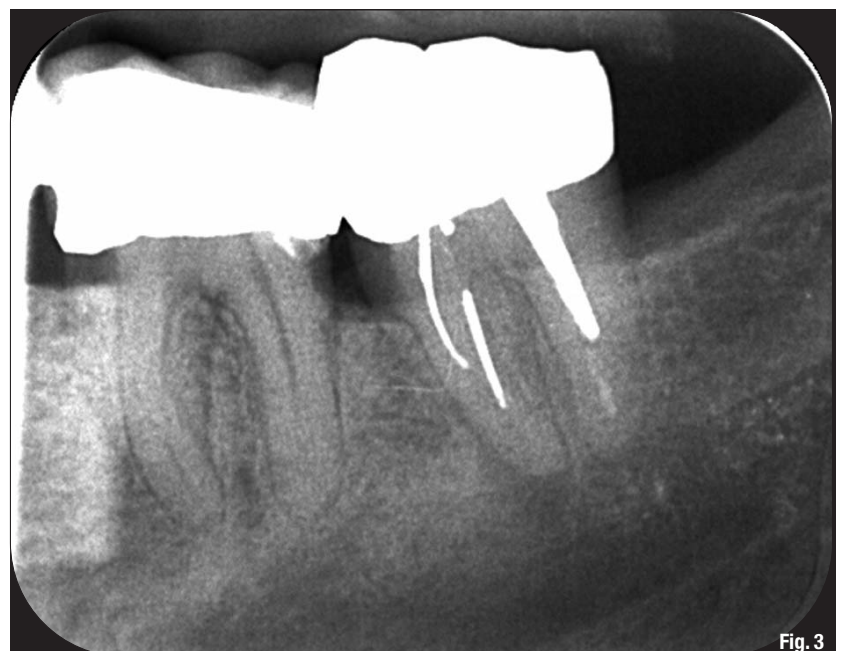As diagnosis 1 and 3 would have required rather invasive therapies (retreatment or extraction), we opted to rule out the local marginal periodontitis first. Under local anaesthesia, the distal pocket was thoroughly cleaned and the patient was instructed to use dental floss distal of tooth #37 on a daily basis.

On 31 January, three weeks after initial treatment, the patient returned for evaluation and appeared free of complaints. There was no bleeding on probing and pain could not be provoked.

It should be noted that by selecting this strategy, neither an AP nor a VRF was definitively excluded as a cause of pain. It should be taken into account that owing to the patient being on antibiotics, the

symptoms of the AP may have temporarily disappeared and returned at a later stage. Nevertheless, at that point we treated the patient based on history, a radiograph and patient complaints rather than merely on the basis of the radiolucency evident on the radiograph.

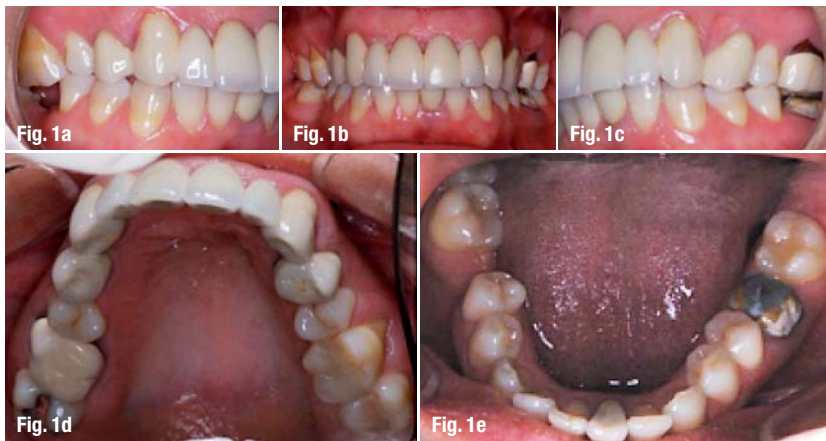In May 2011, the patient returned to our office once again. He was free of complaints, pockets were within normal limits and there was no bleeding on probing.



_contact	roots
	
<p>Dr Sander Loos Heuvelweg 21 3761 XL Soest Netherlands s.loos@acta.nl</p>	

Are endodontists invited to the treatment planning party?

Author_ Dr Daniel Flynn, UK



Figs. 1a–e_ Good oral hygiene. Gingival recession of 4 mm on the buccal aspect of UR6 and the UL6. BPE scores of 1 in all quadrants.

_This is an exciting time to be an endodontist in practice. The availability of advanced technologies aids in the provision of excellent treatment and has transformed the perception of endodontics to that of a dynamic, cutting edge specialty. It is now possible to predictably treat an increasing range of complex cases. Despite this, it is concerning that endodontists only play a limited role in treatment planning in practice.

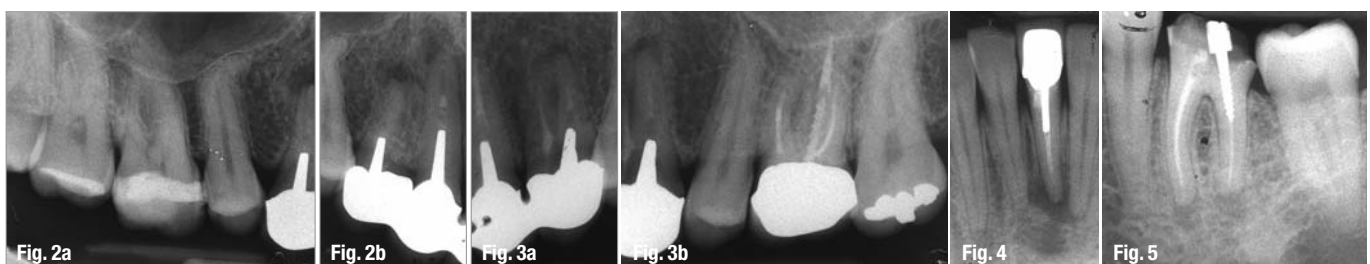
I have five to ten referrers who regularly send patients for opinions prior to treatment planning. This means, a majority of referrers do not wish to or just do not consider the availability of our specialist skill and knowledge. If a patient presents after the treatment plan has been agreed on, consent signed and a financial plan put in place, it becomes much more difficult to change direction. We need to ensure that we do not become technicians working to the prescription of referring dentists, but instead are actively involved at the crucial initial decision-making stage.

Endodontic treatment planning most often focuses on restoring individual teeth with less attention paid to the role of these teeth in the mouth as a whole. Dentistry has become more specialised over the last decade. This has resulted in a reduced incorporation of all the dental disciplines into treatment planning of patients. Predicting the long-term serviceability of a tooth in the context of a restorative treatment plan is complex. The pendulum has swung over the years from only extracting unrestorable teeth to replacing restorable teeth with dental implants. We need to be knowledgeable about dental implants and gain experience in complex treatment planning. It is encouraging to see that postgraduate courses are increasingly including implant training and complex restorative treatment planning in endodontic programmes. Once these knowledge and clinical skills are present, the endodontist is in the best possible situation to be least biased in decision-making regarding tooth restorability.

The quest to obtain an evidence-based approach for decision-making in dentistry is prominent at the moment. There is no accepted standardisation tool for assessing the overall status of teeth. In practice, decisions are therefore made based on available evidence, previous clinical experiences, intuition and accounts of successful treatments by colleagues or even dental representatives. Social psychologists tell us that human beings are "cognitive misers", that is, we accept that we have limited ability to process all the available information and thus try to devise strategies to deal with complex planning issues.

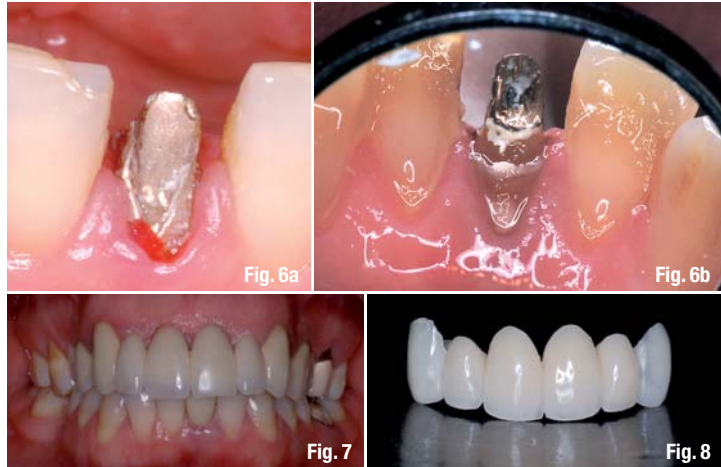This is evident when we do treatment planning sessions with general dentists. These sessions are invaluable as a type of focus group so we can under-

Figs. 2 & 3_ Peri-apical radiographs.
Fig. 4_ Technically inadequate RCT and a peri-apical radiolucency.
Fig. 5_ Peri-apical radiolucencies associated with the mesial and distal roots.



stand the needs and wants of local practitioners. These findings, it should be noted, are from a small self-selected group and may not reflect what occurs in practice in a wider context:

1. Many dentists make treatment decisions based on radiographs alone without dismantling teeth and assessing restorability.
2. There is a general perception that root-canal retreatment (RCT) has a 50/50 chance of "not working" and that apicectomies are unlikely to be successful in the long term.
3. Implant treatment has success rates close to 100% and carries a low risk of complications in the long term.



Figs. 6a & b Adequate amount of tooth structure lingually and a little ferrule present buccally.
Fig. 7 Completion and temporisation of LL1 and LL6.
Fig. 8 Temporary bridge.

Heuristics are a simple, rule of thumb strategy for solving problems. Its attractiveness lies in the fact that in a busy practice one does not need to go through a complex decision-making process for each possible alternative. An example I often hear is, "If a failed tooth has been root-canal treated and restored with a post, we need to extract the tooth." Once established it is easy to reaffirm existing views, but it is extremely difficult to change them.

whereas a large number of recent implant studies have ignored biological and technical complications.⁴ As endodontists, implant technology is to be embraced. In fact, the advent of implants has made the endodontist's job a lot easier. It is our duty though to stop the pendulum from swinging too far. We need to disseminate the knowledge and prevent perfectly restorable teeth from being artificially replaced.

It is also striking to note the language used when general practitioners talk about treatment alternatives. Root-canal treatment (especially retreatment) is associated with uncertainty and the possibility of failure, whereas implant treatment is associated with success and predictability.

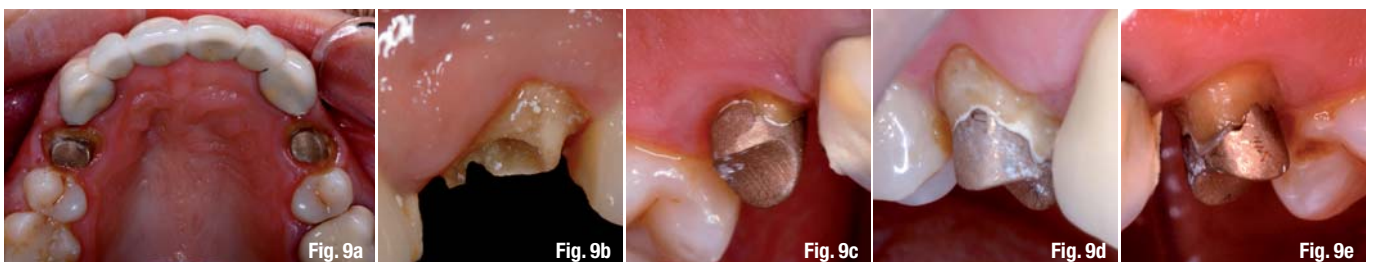
Hard tissues	
Teeth present:	76543 / 34567 87 54321/1234567
Good margins on the PFM crown LL1 and the PFM double-abutted bridge UR4, UR3 to UL3, UL4. Crown de-cemented from LL6.	
Table 1	

These perceptions exist despite excellent studies demonstrating RCT and endodontic microsurgery to be incredibly successful. Systematic reviews show that RCT has a success rate greater than 80% over four to six years,¹ while outcome studies show that endodontic microsurgery has a greater than 91% success rate after five to seven years.² With good case selection, success rates greater than 80% are easily achievable for RCT, as some of the studies included in the systematic review were completed in the past when implants were not an available treatment option and therefore heroic endodontics were attempted in order to save teeth.

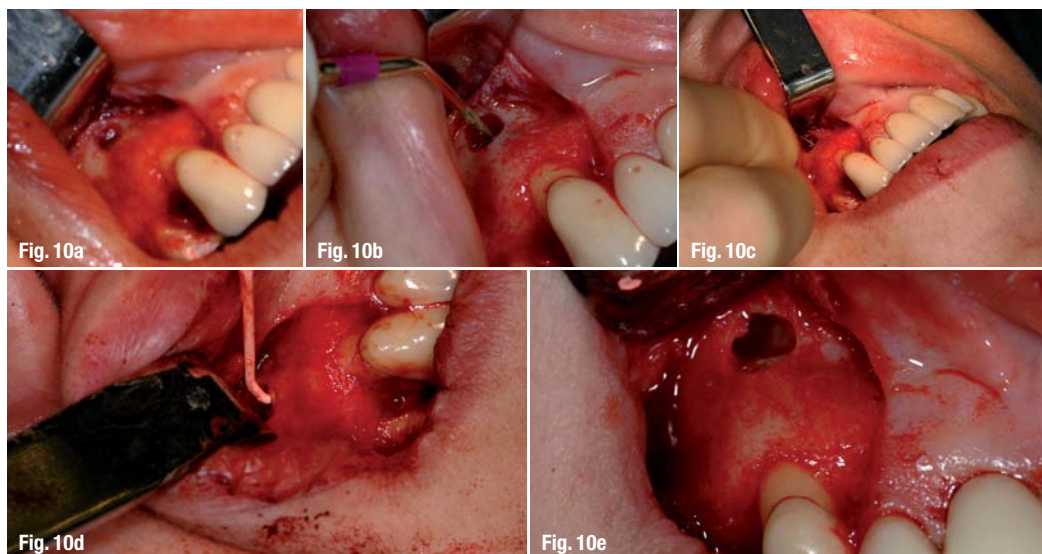
According to Aronson,⁵ once a decision has been made, most people are motivated to justify their actions and beliefs. We seek to justify our actions and tend to focus on the positive aspects of chosen treatment whilst ignoring any disadvantages. Likewise, we downgrade the positives of the treatment option we did not take. This phenomenon—dissonance—occurs for most people following a difficult decision especially, if the decision involved a great deal of time or money. Meanwhile, the theory of irrevocability suggests that once a final decision has been made, we tend to be more certain that it was the right decision than before, when more uncertainty was involved.

Traditional endodontic outcome studies have used stringent criteria³ when evaluating the treatment,

Figs. 9a–e RCT was completed and newly cast post and cores and temporary crowns were placed.



Figs. 10a–e Endodontic micro-surgery (a), resection (b & c), retro-preparation (d & e), obturation with gutta-percha and MTA.



_Case report

I use the following case presentation to promote the possibilities of endodontics in treatment planning. This 36-year-old female patient presented for consultation after she had already seen a restorative dentist for treatment planning. She was highly edu-

bridges. The current bridge was nine years old. The patient suffered recurrent infections from her UL3/4 region and UR4 tooth. She had taken multiple courses of antibiotics over that period and now wished to determine and resolve the source of the problem. She had a hectic work schedule, but was prepared to take set days off in order to have as much treatment as possible done in a sitting. She was happy with the shape and colour of her existing bridgework and did not wish to appear noticeably different following treatment, as she was involved in work on television. A removable option was not possible at any stage, even as a temporary measure. Cost was not a primary concern, although she desired value for money.

Occlusal examination

- Class I molar and incisal relationship.
- RCP and ICP appeared coincident.
- Protrusion was guided by the incisors.
- Right side and left side excursions were in group function. **Table II**

Diagnoses

cated, demanding and costs were not a limiting factor. In my experience, only a small number of patients chose to get a second opinion. Most accept the first treatment plan proposed.

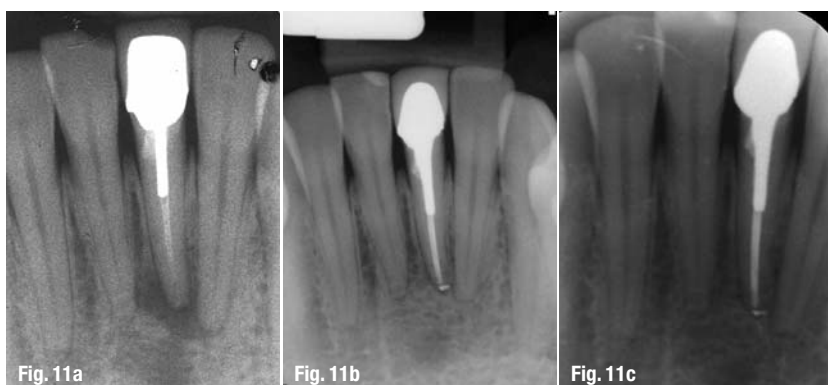
The patient visited the dentist on a regular basis and her medical history was non-contributory. The extra-oral examination revealed a medium to low smile line but no other relevant findings. Besides soft tissues, the intra-oral examination revealed nothing relevant to the treatment. The patient had good oral hygiene. We found gingival recession of 4 mm on the buccal aspect of UR6 and the UL6. Her basic periodontal examination (BPE) scores were 1 in all quadrants (Figs. 1a–e; Tables I & II).

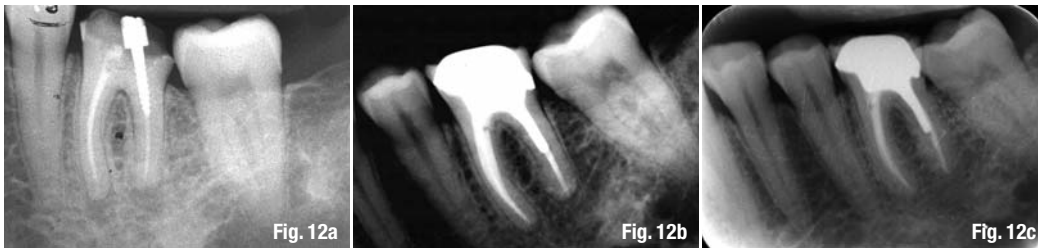
Figs. 11a–c LL1 complete healing: Pre-op (a), 1-year follow-up (b), 3-year follow-up (c).

The patient was asymptomatic on presentation. A traumatic accident at the age of nine resulted in the eventual loss of UR2, UR1, UL1 and UL2. Over 25 years, the upper incisors had been replaced with three

Her radiographic examination showed that UR4, UR3, UL4 and UL3 were the abutments for the double-abutted bridge spanning from UL4 to UR4. Marginal discrepancies were not visible (Figs. 2 & 3). The teeth were restored with post restorations and had technically inadequate RCTs. UL3 and UL6 had no evidence of apical periodontitis. There were peri-apical radiolucencies associated with the UR4, UR3 and UL4.

LL1 was restored with a post/core and a crown. There was a technically inadequate RCT and a peri-





Figs. 12a–c_LL6 complete healing: Pre-op (a), 1-year follow-up (b), 3-year follow-up (c).

apical radiolucency approximately 5 mm in diameter (Fig. 4). LL6 had been restored with a screw post (Dentatus) and had a technically inadequate RCT. There were peri-apical radiolucencies associated with the mesial and distal roots (Fig. 5).

Treatment plan

The patient's chief concerns were to be infection free, have an identical aesthetic appearance and for the plan to be cost effective. The original treatment plan was extraction of LL6, LL1, UR3, UR4, UL3 and UL4 and replacement with immediately loaded implants at a cost of around £30,000.

In order to determine other possible options, we had to dismantle the teeth and assess the restorability. In this process, communication is vital, as the patient needs to understand the uncertainties involved. It is extremely difficult to give an accurate estimate of treatment costs before initiating this course of action and dismantling teeth will often commit the patient to an expensive reconstruction no matter what the findings.

In order to understand the decisions general practitioners make regarding when to extract or restore a tooth, I completed a small survey to assess treatment decisions for each tooth in this case. Ideally, the decision to restore or extract a tooth should be based on:

1. the quality, quantity and position of remaining dentine;
2. the functional and aesthetic demands that will be placed on the tooth;
3. the quantity and quality of surrounding alveolar bone;
4. a cost-benefit analysis of each treatment option;
5. systemic factors;
6. potential to cause harm or adverse effects; and
7. patient preferences.

In this case, 40% of dentists wished to extract LL6 and replace it with an implant, while 80% wished to extract LL1 based on the information provided above. The reasons cited for extraction included:

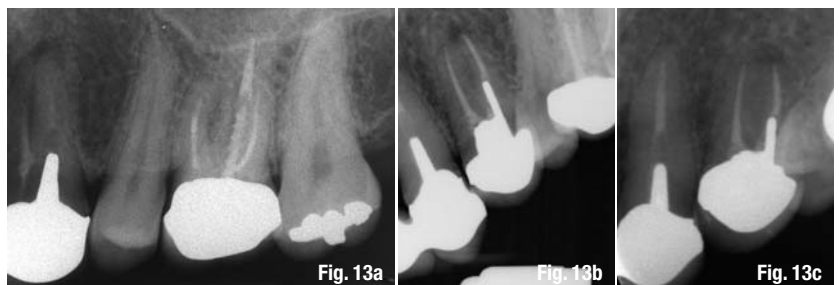
1. A good treatment had already been completed and failed.

2. There was a radiolucency present and a previous root-canal filling.
3. The size of the radiolucency was greater than 5 mm.
4. A post was present and would be difficult to remove.
5. The tooth could be cracked or unrestorable.
6. Restoration would not result in a "predictable" long-term result.

It is important that we address the misconceptions that RCT is unpredictable if there is a radiolucency associated with the tooth and that there is a critical level where the size of the radiolucency has a definite effect on the prognosis of treatment. It would be an interesting research project to reproduce this survey on a much larger scale to ascertain practitioners' treatment decisions.

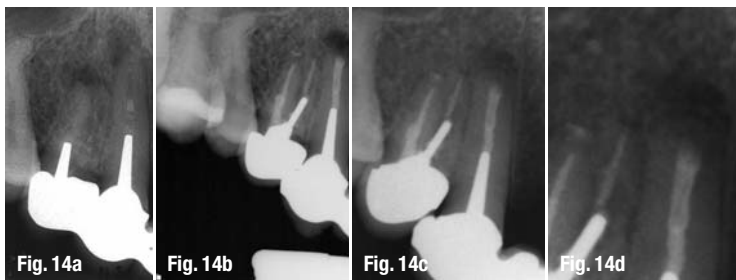
_LL6 and LL1

The teeth were dismantled and LL6 was found to be restorable. However, the LL1 proved a more difficult decision. There was an adequate amount of tooth structure lingually; however, there was a little ferrule present buccally (Figs. 6a & b). I placed great



Figs. 13a–c_UL4 healing: Pre-op (a), 1-year follow-up (b), 3-year follow-up (c).

Special tests	Table III						
Tooth no.	LL6	LL2	LL1	UR4	UR3	UL3	UL6
TTP	N	N	N	N	N	N	N
Soft-tissue tenderness	N	N	N	N	N	N	N
Sinus	N	N	N	N	N	N	N
Mobility	I	I	II	I	I	I	I
Periodontal probing	<3 mm	<3 mm	<3 mm	<3 mm	<3 mm	<3 mm	<3 mm
Sensitivity tests	N	P	N	N	N	N	N



Figs. 14a–d UR3/4 complete healing: Pre-op (a), 1-year follow-up (b), 3-year follow-up (c) and close-up of healing UR3/4 (d).

importance on the fact the restoration had worked in the past with this amount of tooth structure and removal of the post was achieved reasonably atraumatically. The tooth had failed biologically rather than mechanically.

Had this tooth failed mechanically, the treatment of choice would have been a dental implant followed by a resin-bonded bridge. Technically, implant placement would be very difficult in this case, as the interdental space was 5.5mm. There is a requirement of at least 1.5mm of bone between the implant and adjacent teeth, leaving only 3 mm for the implant diameter. Not all implant systems have implants this small and technically the treatment would need to be executed ideally.

Surgical endodontics was also a treatment option for LL1. The advantages of a cheaper, quicker solution need to be balanced with long-term biological considerations. Technically, it may be difficult to complete a retro-preparation to the level of the post, as the roots on these teeth are generally lingually inclined. Also, were I to do this case today, I would get a CBCT scan to ensure that no lingual canal had been missed before considering a surgical option, which can be present in up to 40% of cases.

Following completion and temporisation of LL1 and LL6, it was time to move to the upper anteriors (Fig. 7). Aesthetics are critical and was the patient's primary concern. She was adamant that the teeth look the same as her existing bridgework. We elected to construct a laboratory temporary bridge (Fig. 8) prior to dismantling UR4 and UL4, in case some of the

porcelain fractured when sectioning through the base metal substructure.

The bridge was sectioned and the underlying posts and cores were removed with ultrasonic vibration. The teeth were judged to be restorable. Root-canal treatment was completed and newly cast post and cores and temporary crowns were placed (Figs. 9a–e).

The pathology associated with UR3 was treated by surgical endodontics (Figs. 10a–e). This conservative approach allowed us to maintain the existing bridge and aesthetics, which, along with dealing with the infection, was the most critical factor for the patient. As the canine was the patient's longest tooth that had a peri-apical lesion around the root for a period, removing the apical 3mm was unlikely to reduce the ability of the tooth to support the bridge significantly. It also allowed us to make a more favourable bridge design, as double-abutted bridges were no longer desirable. However, that design had worked in this case. Our approach also reduced the cost of treatment significantly. The initial quote for implant treatment was £15,000 to £30,000. The cost of this treatment plan was just over £5,000. The patient had one surgical procedure and recent studies suggest that there is a lower chance of complications following endodontic treatment than following implant treatment.⁶ The bridge must be monitored over time, as sectioning the UL4 and UR4 could result in disruption of the cement layer. The patient, however, had excellent oral hygiene and a low risk of caries.

At the 3-year follow-up, the patient was symptom free and delighted that her objectives had been achieved to date (Figs. 11–14). Of course, it's early days yet and in the fullness of time it may be proved that a more aggressive treatment plan would have been a more appropriate choice. The beauty of a conservative treatment plan is that all the other options are still available in the long term.

Conclusion

I like to use this case to demonstrate that endodontists should not be forgotten in the treatment planning process. Rather than quoting success rates of studies, it may be more effective to engage practitioners with examples for them to plan, demonstrate the endodontic possibilities with long-term follow-ups and let the results speak for themselves. Fear of failure is a powerful emotion. It is a significant challenge for us to spread the message to ensure that the true value of predictable endodontics can be appreciated and that perfectly saveable teeth are not removed.

Editorial note: A complete list of references is available from the author.

_about the author



Dr Daniel Flynn qualified from the Dublin Dental School and Hospital, Trinity College (Ireland), in 2002. Dr Flynn recently joined the EndoCare team headed by Dr Michael Sultan. He has lectured in both the UK and Ireland and provides hands-on courses for general practitioners. He also teaches Endodontics at the Eastman Dental Institute for Oral Health Care Sciences. For more information please contact EndoCare at reception@endocare.co.uk or visit www.endocare.co.uk.

roots

Win a free trip to New York City with Dental Tribune!



The Global Dental Tribune Awards to celebrate excellence in dentistry. They will recognise outstanding individuals and teams that have made a unique and substantial contribution to improving dental care, whether in clinical practice, health policy, dental education, dental research or the dental industry.

Applications will be judged by a jury of renowned opinion leaders from all parts of the world. The winners will receive a free economy flight to New York City to join us at the Award Ceremony, which will be held at the Greater New York Dental Meeting on November 28, 2011.

All Dental Tribune readers are cordially invited to submit their applications online without registration fees by October 21, 2011.

For preregistrations and your online application please go to:

awards.dental-tribune.com



Is rotary NiTi the new paradigm?

Author_ Dr Barry L. Musikant, USA

Fig. 1 Photograph of a K-file. Note the high number of flutes that are more horizontal in orientation, therefore contributing to poor design under function.



Fig. 1

Does rotary NiTi deserve the title of a new paradigm? In order to be determined to be a "paradigm" it must represent a fundamentally new model. In the case of endodontics, this new model of instrumentation differentiates itself from the old model by being employed in a crown-down fashion rather than the traditional step-back used with K-files.

Furthermore, the crown-down technique is used with rotary NiTi to minimise the engagement along length, making rotary NiTi somewhat less vulnerable to breakage, but at the same time requiring an increased amount of time for recapitulation. The introduction of a new model constituting a paradigm shift not only implies superiority of the new model, but clearly defines the old system as inferior, out of date and lacking the fundamental intelligence that is incorporated into the new model.

What is most peculiar about this "paradigm shift" is its dependence on the old model. Rotary NiTi cannot be used unless the glide path is first created using the K-files.¹ Realising that the new model is dependent upon the old model leads to some possible insights. The shortcomings of the old model are still present and the new model at best does not resolve the old model's shortcomings. Moreover, rotary NiTi is

not without its own shortcomings. K-files, for all their limitations in apical negotiation, distorted shaping, impaction of debris and loss of length, rarely break during usage. Rotary NiTi, on the other hand, has made the dentist constantly aware of its vulnerability to torsional stress and cyclic fatigue, stresses that routinely occur when shaping with rotary NiTi.

Those supporting the benefits of this new model state that crown-down has the advantage of pushing less debris peri-apically, making endodontics more predictable. There is little in the endodontic literature that supports this viewpoint and its supposed benefits.

An automated rotating crown-down approach to shaping canals that is still dependent upon the poorly designed K-file is really a dual system of canal shaping with each portion of the system compensating for the weaknesses of the other. The K-files engage the canal walls excessively, producing a poor tactile perception of what the tip of the instrument is encountering. This limitation can lead to ledging, blockages and apical transportation. For this reason, their use is limited as much as possible before employing rotary NiTi.

Those using rotary NiTi must use the K-files to create a clear pathway from the canal orifice to its apex because the tip of rotary NiTi instruments is vulnerable to breakage if its tip locks and binds apically.

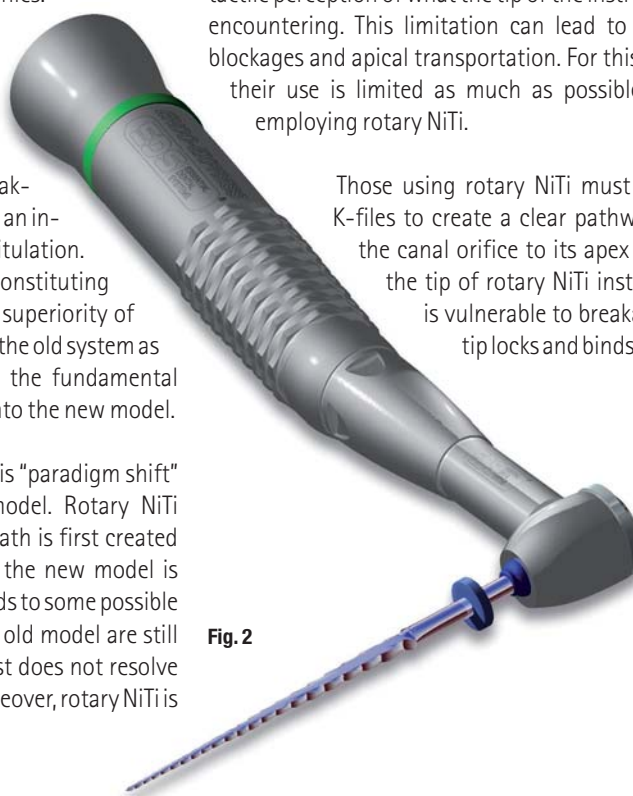


Fig. 2

Fig. 2 Illustration of a relieved reamer used in a reciprocating handpiece.



Fig. 3

with half the number of flutes and twice as vertically oriented, will efficiently shave the dentine using the same watch-winding stroke.

Fig. 3 Photograph showing the vertical flutes and flat of a relieved reamer.

It is only when the canal pathway is completely clear along its entire length that the rotary NiTi instruments can be used without fear of torsional stress. Even then, a clear pathway does not eliminate all the stresses that rotary NiTi will bear.

Rotation around a curve creates cyclic fatigue, shortening the life of the NiTi instruments, with cyclic fatigue accelerated, the greater and the more abrupt the curve being negotiated.² Compensation for this vulnerability comes in two forms. The poorly designed K-files (Fig. 1) may be used to shape the canals further before switching to rotary NiTi or the NiTi instruments may be used to shape more conservative preparations, not based on the biological needs of the canal, but the metallurgical limitations of the NiTi instrument.

Perhaps the best way to illustrate the sleight of hand in the marketing of rotary NiTi is to consider a simple alternative: the use of relieved reamers rather than K-files, instruments that work so well that they can be used from start to finish. Whereas K-files engage when a watch-winding motion is used and only remove dentine on the pull stroke, the reamers,

These instruments engage less along length, are significantly more flexible and shave rather than cut more efficiently. As long as patency is maintained, these instruments will remain centred when being negotiated apically and have the ability to work all the walls upon withdrawal of the instrument.³ For the most part, these instruments do all the shaping. It is not a dual system because there is no need for another system to compensate for any weaknesses. The strengths that relieved reamers (Fig. 2) bring to shaping canals, whether used in a manual watch-winding motion or in a 30° reciprocating handpiece, are constant throughout the entire procedure (Fig. 3).

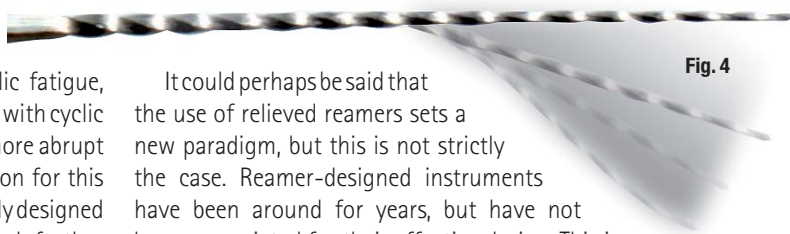


Fig. 4

It could perhaps be said that the use of relieved reamers sets a new paradigm, but this is not strictly the case. Reamer-designed instruments have been around for years, but have not been appreciated for their effective design. This is understandable because they have rarely been taught in the dental schools.

Fig. 4 Photograph illustrating a relieved reamer lacking the snap-back qualities of its NiTi counterparts.

Somewhere along the way, K-files became the instrument of choice in institutions of higher learning and so became ossified over the years without proper justification. It was really the advent of rotary NiTi that eventually highlighted the shortcomings of K-files. That a system as expensive and vulnerable as rotary NiTi is dependent upon initial instruments of such poor design makes one realise that the edifice of endodontics based on K-files is unsupported. To be dependent upon a poor design makes no sense.

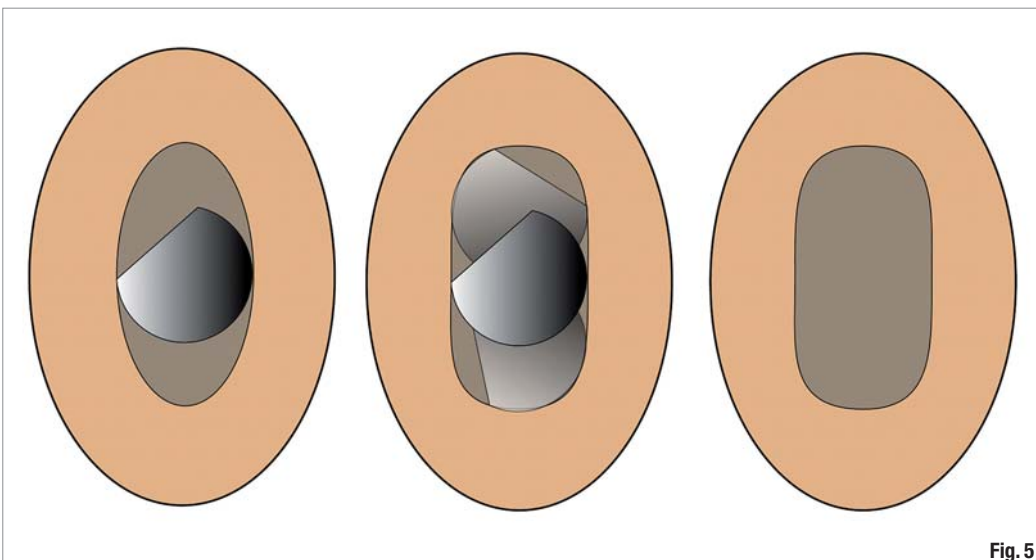


Fig. 5

Fig. 5 Illustration showing an asymmetrical instrument's ability to distinguish and clean an oval-shaped canal.

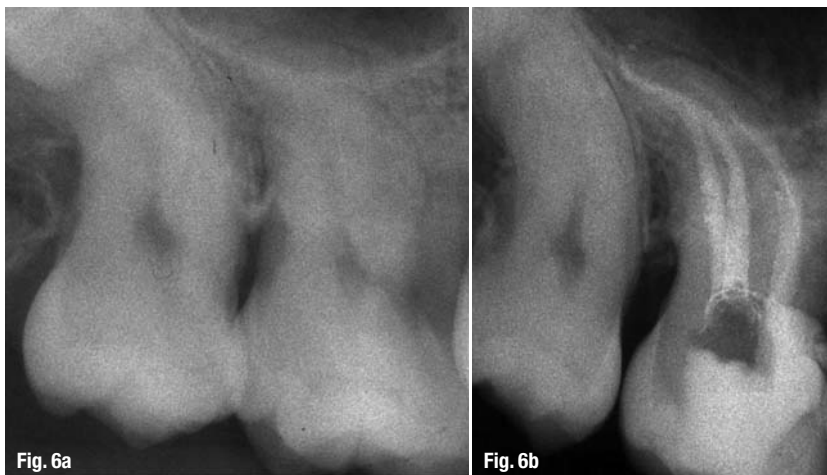


Fig. 6a

Fig. 6b

Figs. 6–8 Radiographs illustrating the clinically excellent results obtained using relieved reamers in a reciprocating handpiece.

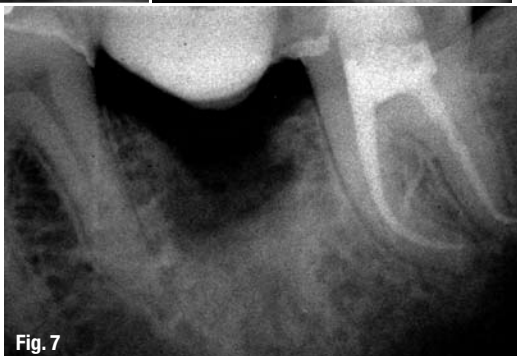

Fig. 7

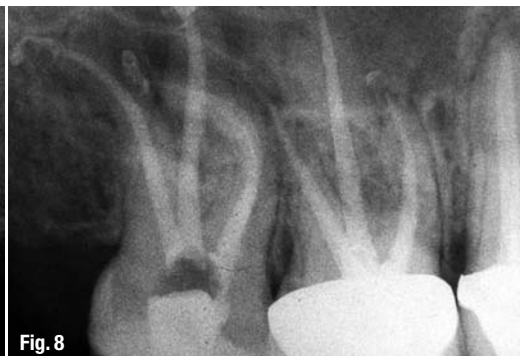

Fig. 8

If we simply brush away the use of K-files, the subsequent use of rotary NiTi and all the marketing that has gone along with its establishment as the new paradigm, we are left with simple, inexpensive yet highly effective tools that allow endodontics to be performed with none of the procedural stress associated with K-files. Relieved reamers provide the dentist with the following advantages:

- virtually invulnerable to breakage;
- can be used six to seven times before replacement;
- will not break even if inadvertently used many more times;
- can be negotiated apically with far less resistance than K-files;
- more flexible, less engaging and more effective at removing dentine from the canal walls than K-files;
- do not snap back to the straight position like rotary NiTi (Fig. 4);
- record curvatures;
- are confined to a tight arc of motion;
- stay centred when negotiating apically;
- can be used against any and all walls when being removed from the canals;
- can differentiate between a tight canal and a solid wall (Fig. 5);
- can differentiate between a round and oval canal;
- can shape even a highly curved canal to a minimum of 35 without canal distortion;

- have a cutting tip that pierces rather than impacts dentinal tissue and debris;⁴
- can be used both manually and in a 30° reciprocating handpiece;
- on average cost 90% less than rotary NiTi on a per-use basis.

What any dentist might want to ask himself is whether he is listening to the sizzle or tasting the steak. The significant number of dentists who, while being lured by the sizzle, are desperately waiting to experience the steak, only to be disappointed by the shortcomings inherent in any rotary NiTi system, is amazing.

For anyone who has made a major investment in rotary NiTi, it may be difficult to accept that there is a simpler, more effective and far safer means of shaping canals that costs a fraction of what rotary NiTi costs.

These alternative systems do not have to be called a paradigm shift. Rather, the paradigm shift must happen in our minds, allowing the ability to judge systems based on their performance rather than the promise of that performance.

For examples of cases that highlight the clinically excellent results using the alternative method discussed in this article, see Figures 6 to 8.

Knowing that nothing beats the old adage that the proof is in the pudding, I make my long-standing offer to anyone who wishes to experience the superior effectiveness of relieved reamers to K-files, K-flex files and rotary NiTi to take the free one-on-one two-hour workshop I give in our New York endodontics practice.

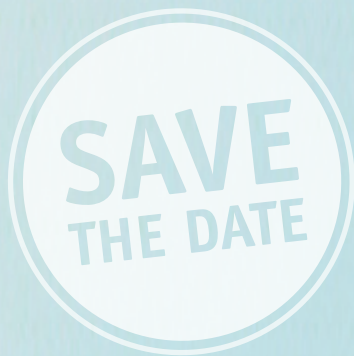If you are interested, call +1 212 582 8161 and ask for Evelyn to schedule the workshop, which is generally held on a Tuesday or Thursday from 7 to 9:30 pm. The address is 119 W. 57th St.—a safe part of town for out-of-towners who may have any trepidations.

Editorial note: A complete list of references is available from the publisher.

_contact	roots
<p>Dr Barry Lee Musikant Essential Dental Systems, Inc. 89 Leuning Street S. Hackensack, NJ 07606 USA</p> <p>info@edsdental.com</p>	

1ST ANNUAL DGET MEETING

German Society of Endodontology
and Dental Traumatology (DGET)



10th ANNUAL DGEndo Meeting

German Society of Endodontology (DGEndo)

3–5 November 2011

Bonn, Germany // KAMEHA Grand Hotel Bonn

Speakers

Dr. Arnaldo Castellucci
Prof. Markus Haapasalo
Prof. Syngcuk Kim
Prof. Thomas Kvist
Dr. Roy Nesari
Prof. Manoel Sousa-Neto
Prof. Junji Tagami
Prof. Marco Versani
Prof. Roland Weiger



FURTHER DATES

Spring Academy 2012 // 2 & 3 March 2012 // Heidelberg, Germany
SUPPORTED BY DR. JOHANNES MENTE & KLAUS LAUTERBACH

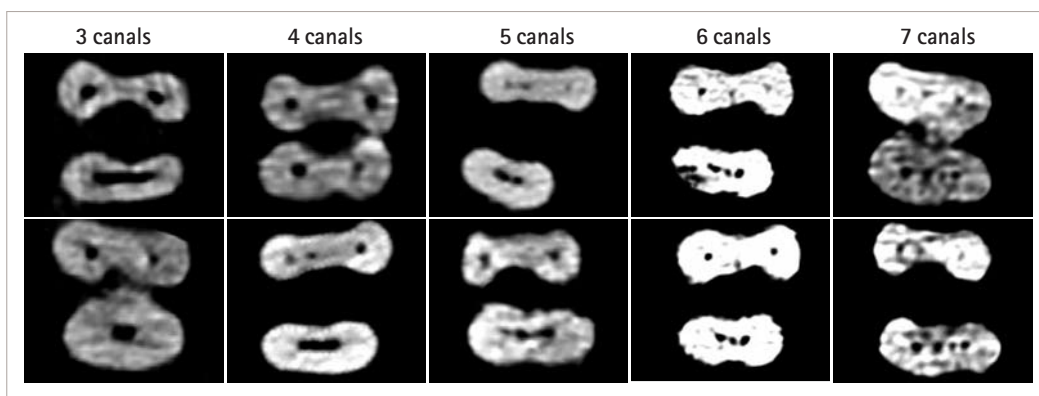
2nd Annual DGET Meeting // 1–3 November 2012 // Leipzig, Germany



CBCT study of root-canal morphology of mandibular first molars in a Spanish population

Authors Drs Óliver Valencia de Pablo, Jose María Abadal, Roberto Estévez, Federico Moreno-Sancho, Teresa Pérez-Zaballos & Manuel Péix Sánchez, Spain

Fig. 1 Slices depending on the number of canals in the MFMs found using CBCT.



The objective of root-canal treatment is the rigorous mechanical and chemical cleaning of the entire pulp cavity, its 3-D obturation with an inert material and the achievement of an appropriate hermetic coronal seal to prevent micro-organism intrusion.¹ Micro-organisms are the most important aetiological factor for pulp and peri-apical pathology. Pulp tissue not completely removed from the root-canal system is the main reason for failure of endodontic treatment in molars. The cause of failure is the infection of the remaining tissue, which is either already or subsequently infected by micro-organisms.² This problem seems to be aggravated by the presence of root canals unnoticed by the clinician, coinciding with anatomical variations or additional canals.³ In fact, the lack of knowledge about root-canal anatomy has been identified as one of the most common reasons for endodontic failure.⁴

The mandibular first molar (MFM) is the most frequently endodontically treated tooth.^{5,6} Furthermore, it is the tooth with the greatest rate of endodontic failure.^{7,8} The relative simplicity and uniformity of the external surfaces of its roots quite often mask the internal complexity.⁹ Generally, the MFM is described as having three canals, two in the mesial and another in the distal root.¹⁰ Recent studies demonstrate the possible presence of three canals in any of the roots.¹¹⁻¹⁴

Various methods have been employed to study the internal anatomy. The best-known and most frequently used method in the literature is achieving transparency of the roots. In recent years, 3-D imaging technology has been introduced and cone-beam computed tomography (CBCT) in particular is starting to prove very valuable in dento-maxillofacial imaging. CBCT is a useful tool in implant dentistry, for identifying anatomic structures and for the evaluation of periodontal lesions,¹⁵⁻¹⁸ as well as many other applications.

With regard to endodontics, Cotton *et al.* described a number of cases in which CBCT was the definitive diagnostic tool used.¹⁹ In these cases, CBCT showed an MFM with an extra root that had not been diagnosed or treated initially. However, only a few studies have used this modern diagnostic technique to analyse canal configuration. Various researchers have used CBCT to evaluate maxillary molars.²⁰⁻²³ CBCT has also been used to determine the number and the morphology of the roots of mandibular molars in patients.²⁴⁻²⁷

The following is the first *in vitro* study to use CBCT technology to determine the configuration and morphology of the canal system of the permanent MFM.

Materials and method

In collaboration with various Spanish National Health Service centres, 53 permanent MFMs were collected. The age and gender of the patients were not known. Before extraction, the dentist confirmed that the teeth to be extracted were MFMs, relying on their position within the lower arch. Afterwards, this was corroborated through the coronal anatomical analysis of the samples. After extraction, all samples were cleaned and stored in 10% formaldehyde. All samples were submerged in 4% NaClO to dissolve any remaining organic tissue. Manual curettes and ultrasonic scalers were used to dissolve any calculus that remained on the root surfaces.

In order to locate and secure the samples within the bite holder of the CBCT device, they were embedded in Plasticine. The scanning was carried out by an expert radiologist, who had experience using CBCT. The device used for the purposes of this survey was the i-CAT (Imaging Sciences International) with a voxel size of 0.2 mm and a grey scale of 14 bits.

Owing to the characteristics of the CBCT, the position of the samples during scanning did not matter. The entire volume was registered, not only the volume that falls within a determined area as would be the case using conventional techniques. Therefore, we were able to study the results in any of the spatial planes. All the samples were positioned starting with the mesial root followed by the distal.

Once the 3-D images of every sample had been processed, the data was analysed with i-CAT Vision software (Imaging Sciences International), which offers various views of the data. We used the multi-

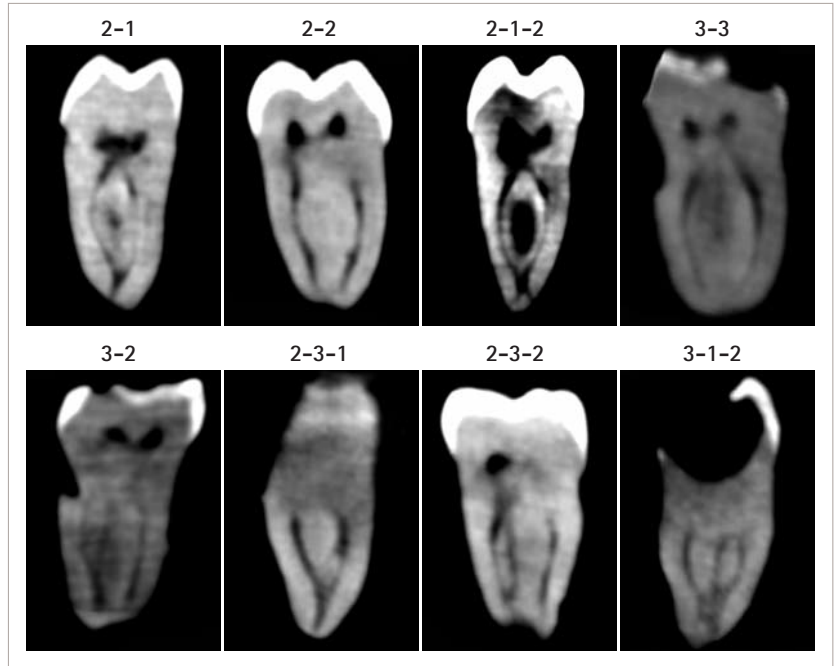
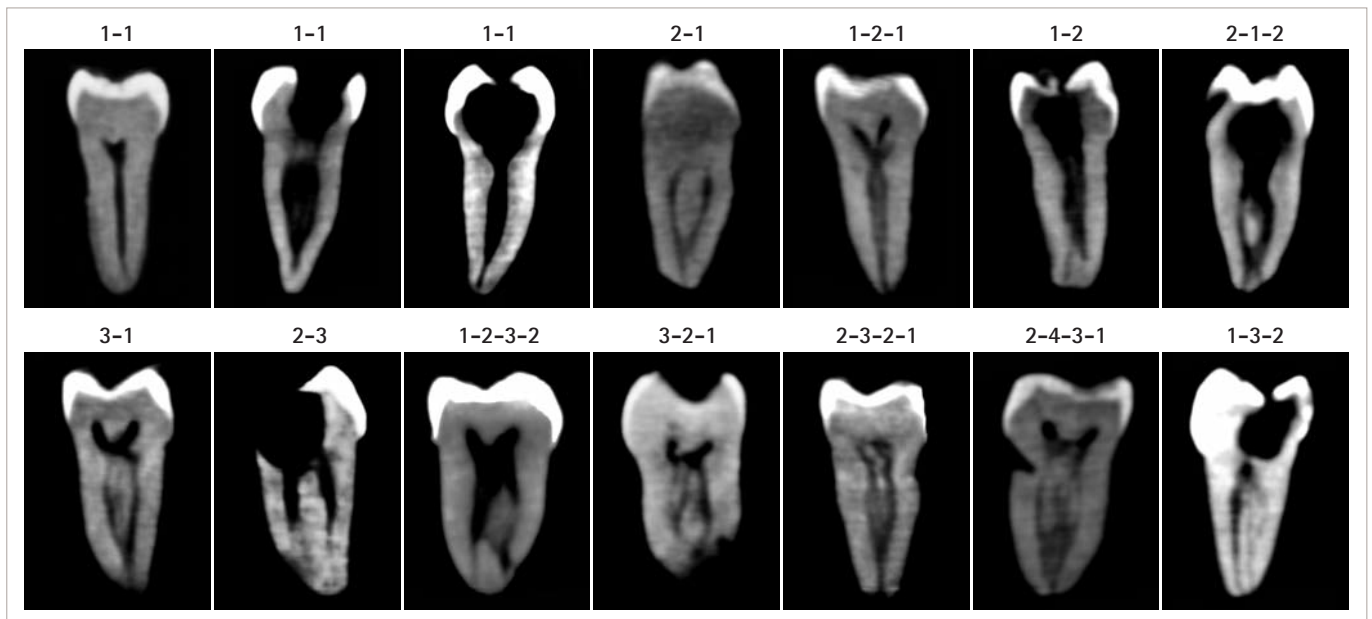


Fig. 2 Examples of different canal configurations found in the mesial root using CBCT.

planar reconstruction screen, as it allowed us to analyse the images in slices for the three different spatial axes. In addition, the screen showed a simultaneous interaction amongst the axes, allowing the operator to rotate the inclination of the sample in a way that allowed the observation of the curvature of each root through independent axial slices.

The canal configurations observed in the samples were grouped based on Vertucci's classification.²⁸ (Since 1984, different configurations to the ones described by Vertucci have been proposed.) Table I shows a schematic representation of the different types of canal systems that are present in the roots of the permanent MFMs as given in the literature.²⁹

Fig. 3 Examples of different canal configurations found in the distal root using CBCT.



Vertucci 1984


























Vertucci 1984																
Type 1 1-1	Type 2 2-1	Type 3 1-2-1	Type 4 2-2	Type 5 1-2	Type 6 2-1-2	Type 7 1-2-1-2	Type 8 3-3									
																
Kartal & Cimilli 1997	Gulavibala <i>et al.</i> 2001					Sert <i>et al.</i> 2004	Peiris <i>et al.</i> 2007	Al-Qudah & Awawdeh 2009								
Type 2a 2-1	Type 2b 2-1	Type 9 3-1	Type 10 2-1-2-1	Type 11 4-2	Type 12 3-2	Type 13 2-3	Type 14 4-4	Type 15 5-4	Type 16 1-3	Type 17 1-2-3-2	Type 18 1-2-3	Type 19 3-1-2	Type 20 2-3-1	Type 21 2-3-2	Type 22 3-2-1	Type 23 3-2-3
																

Table I Configuration possibilities of mandibular MFM roots according to the literature.

_Results

The results of the total number of canals found, the canal configurations in the mesial root and the canal configurations in the distal roots are shown in Tables II, III and IV. Figure 1 shows examples of the slices from the molars, illustrating the number of canals. Figure 2 shows examples of the different configurations found in the mesial root, while Figure 3 shows examples for the distal root.

_Discussion

A literature review found that the number of canals in the MFM varies and that there are differences between the findings of *in vitro* and *in vivo* studies in this regard. We suggest that modifications of the access cavity and clinical effort to locate the canals may be a possible explanation for these differences.²⁹ The calcification of the coronal portion of the canal often does not permit adequate access to the root and canal morphology, but this does not mean that it has disappeared.

The calcification always follows a corono-apical direction. Therefore, the most complicated part for a clinician is to identify the entrance to the canal. However, once this has been achieved, instrumentation is usually simple. Thanks to CBCT, it is possible to

observe axial slices of roots of any given height, allowing us to count the number of canals independently of the coronal access.

Initially, we know that both the mesial and the distal root have just one canal and the dentine apposition inside them develops a canal system.³⁰ On some occasions, we were able to find up to four different divisions at a given height. Clinically, it is extremely difficult not only to detect their existence, but also to access them with either manual or rotary instruments. In fact, when four canals were observed within a root, the divisions between them were so tiny that they disappeared after the instrumentation of the main canals, resulting in a simpler "prepared" anatomy. The above-mentioned facts may explain the lower number of canals found in the literature compared with the results obtained in our investigation.²⁹

We obtained similar results to Forner Navarro *et al.* for the number of canals in the mesial root of the MFM using CT.¹¹ In two different *in vitro* studies, they found the frequency of three canals within the mesial root to be 14.8% and 12%. We obtained a rate of 17% in our study, which made us question the validity of other methodologies. Further analysis of the 3-D technique is necessary. In our opinion, the main advantage of the technique is that it does not alter the structure of the samples in any way.

Table II Number of canals in MFMs.

Number of canals	3	4	5	6	7
Number of molars	22	14	15	1	1
Incidence in %	41.5	29.4	28.3	1.9	1.9

A recent publication confirmed the afore-mentioned data.³¹ In the study, 48 access cavities were prepared *in vitro* and modified in the mesial root of MFMs. The pulp chamber was explored with a microscope and ultrasonic tips. The operator observed the presence of a middle mesial canal in nine roots (18.7%). This confirms that the proper elimination of calcification and coronal interferences allows access to a greater number of canals in the mesial root of the MFMs.

The literature shows that Types II and IV of Verucci's classification of the canal system configuration are the most frequent in the mesial root.²⁹ In our study, 39.6% of the mesial roots—compared with 35% in the literature—showed two canals that were linked in the apical third, a close correlation. In our study, the Type IV configuration—two independent canals—was less frequent (39.6%) compared with the literature (52.3%). The presence of three independent canals was only seen in one case, but other complex configurations, such as 3-2, 2-3-1, 2-3-2 and 3-1-2, were found, raising the number of mesial roots with three canals to nine.

The configuration of the canal system of the distal root offered more variety. The frequency of a

single canal (47.2% in our data compared with 62.7% in the literature) was lower, increasing the number of cases involving more complex configurations. This is probably due to a higher rate of calcification in the canals in our samples. Most of our samples were extracted owing to large decay lesions, defective and not repairable restorations or coronal fractures, with a considerable number showing clear signs of prolonged chronic bruxism. All these factors enhance the apposition of dentine on the inside of canals, creating subdivisions of the main canal. We found three configurations not yet described in the literature:

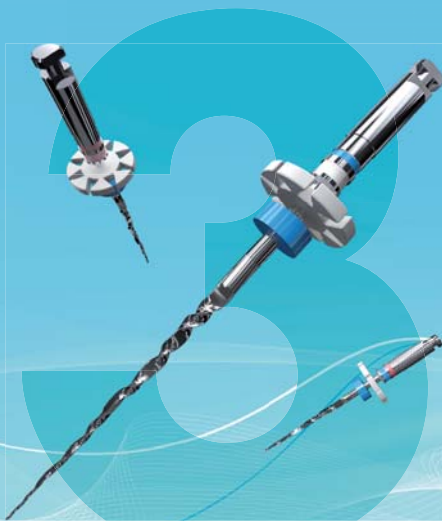- 1-3-2: Initially, we observed a single canal, which rapidly diverged into three. Towards the middle third of the root, two canals joined to finish with two different canals in the apical third.
- 2-3-2-1: One of the roots showed two canals that later divided into three. Towards the middle third, two of them joined together and all of them finished in the same common foramen.
- 2-4-3-1: In another distal root, we found the most complex of all configurations in either a distal or a mesial root. Two canals divided into four, fusing afterwards into three and finally joined together to finish at the same foramen.

AD

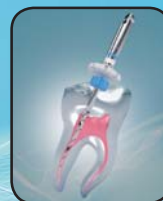iRaCe

Quick, Effective and Safe

Only 3 instruments for most cases
Single-length technique

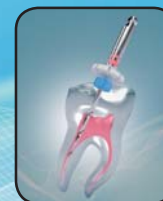

R1 - 15/.06



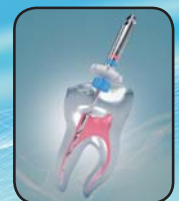up to WL

R2 - 25/.04



up to WL

R3 - 30/.04



up to WL

www.iRaCe.ch



	2-1	2-2	2-1-2	3-3	3-2	2-3-1	2-3-2	3-1-2
Number of mesial roots	22	21	2	1	3	3	1	1
Incidence in %	39.6	39.6	3.8	1.9	5.7	5.7	1.9	1.9

Table III _Mesial root-canal system configuration.

Another difference between our results compared with the literature regarding the distal root was the low frequency of the Type II configuration (5.7% compared with 14.5%), which is in contrast with our findings for configuration Type III. The explanation seems to be simple: the results of *in vitro* studies were consistently similar to our results, while the results of *in vivo* studies were not. The problem is that when a canal divides into two towards the middle third, the only way to fill it is by instrumenting the canal to enlarge the coronal portion, allowing direct access to each of the canals. The consequence is that clinically all Type III canals (1-2-1) become Type II canals (2-1) after root-canal treatment has been completed.

Given the amount of information provided without altering the samples, CBCT technology is a great aid for the *in vitro* evaluation of the root-canal anatomy of the permanent MFM. Michetti *et al.* compared CBCT slices with histological sections to determine the appearance of the second mesiobuccal canal in maxillary molars. They found no significant differences.³² Neelakantan *et al.* compared CBCT to four different methods for the study of the morphology of the root-canal system. Their results of CBCT were similar to those obtained using a clearing technique, which is considered the gold standard for this kind of study.³³

The radiation a patient has to endure depends directly on the volume to be scanned, which makes *in vivo* analysis using CBCT a clinical possibility.¹⁹ In fact, the literature review has shown, that CBCT is a very valuable and useful tool in obtaining a satisfactory treatment outcome.^{34,35}

Table IV _Distal root-canal system configuration.

	1-1	2-1	1-2-1	1-2	2-1-2	3-1	2-3	1-2-3-2	3-2-1	2-3-2-1	1-3-2	2-4-3-1
Number of mesial roots	25	3	10	2	1	4	1	1	2	2	1	1
Incidence in %	47.2	5.7	18.9	3.8	1.9	7.5	1.9	1.9	3.8	3.8	1.9	1.9

_Conclusion

It has been shown that CBCT is a useful and valid tool for *in vitro* evaluation of the morphology of the root-canal system of the permanent MFM. The most frequent configurations for the mesial root were 2-1 and 2-2, but a high percentage of roots (17%) had three canals. Half of the distal roots had only one canal, but the other half had diverse configurations, with 1-2-1 the most frequent configuration. The CBCT results obtained in this study also demonstrated more complex configurations, such as 1-3-2, 2-3-2-1 and 2-4-3-1, which have not been previously described in the literature.

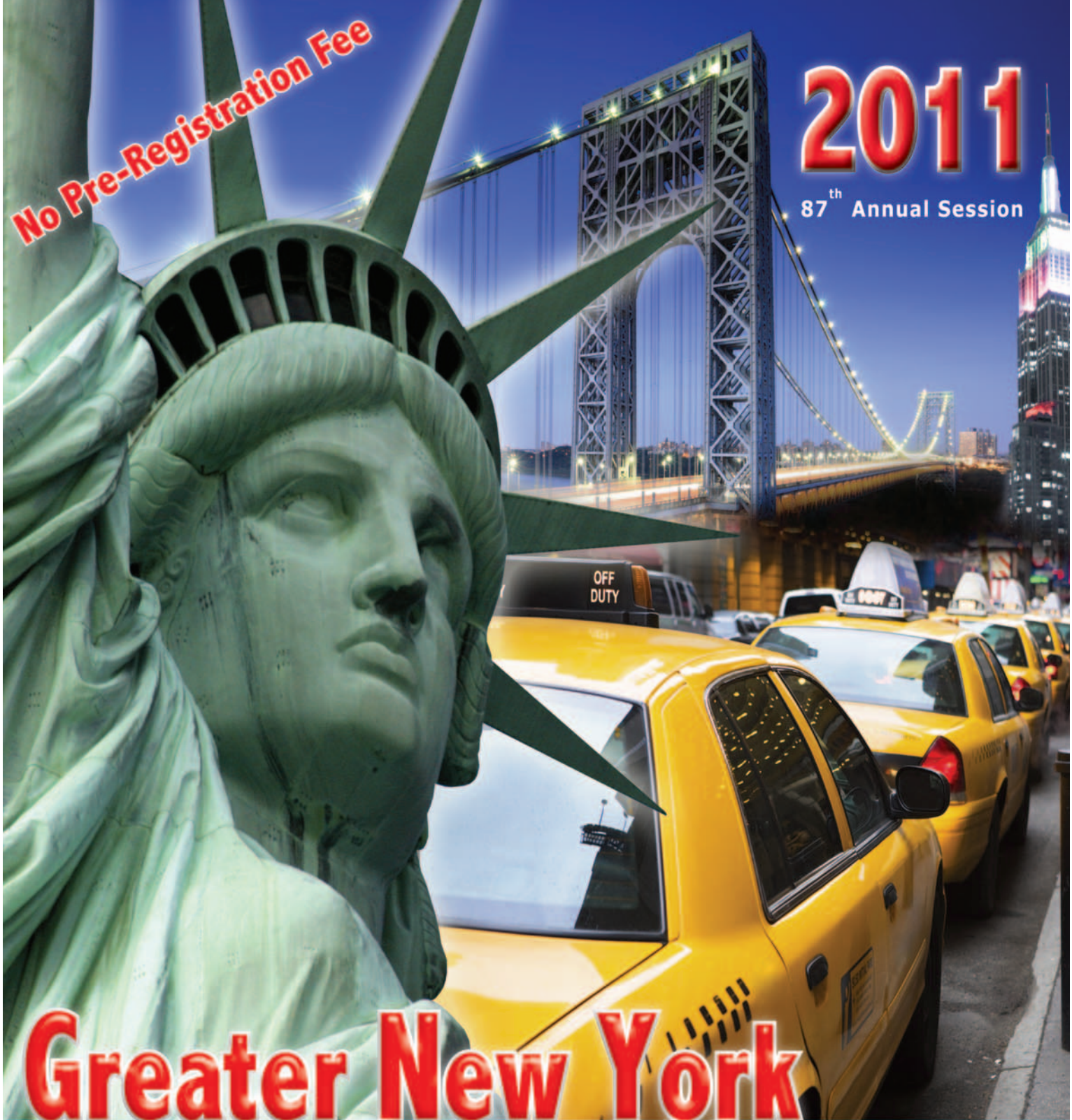
Editorial note: A complete list of references is available from the publisher.

_contact	roots
 <p>Dr Óliver Valencia de Pablo Department of Endodontics, Universidad Europea de Madrid Avenida de Bruselas nº 64 28028 Madrid Spain</p> <p>oliver.valencia@uem.es</p>	

No Pre-Registration Fee

2011

87th Annual Session



Greater New York Dental Meeting™

Scientific Meeting:
Friday, November 25 -
Wednesday, November 30



Exhibits:
Sunday, November 27 -
Wednesday, November 30

The Largest Dental Meeting/Exhibition/Congress in the United States

“Patient education needs to be part of the daily activities of a practice”

An interview with Dr Reena Gajjar, Canada



Dr Reena Gajjar

_My Dental Hub is premier web-based dental patient education software. Accessible via your computer or mobile device, including the iPad, it provides patients with informative material on major areas in dentistry, including 3-D animations. Patients are then empowered to make educated decisions about the proposed treatment. **roots** spoke to Dr Reena Gajjar about the idea behind and the benefits of the software.

_roots: *How did the idea for My Dental Hub evolve?*

Dr Gajjar: My Dental Hub (formerly Click & Print) started back in 1996, when I joined my husband's prosthodontic practice. Having a background in computer graphics, I developed educational printable materials using images and simple explanations for our practice. These were used exclusively during patient consultations.

It soon became apparent that the treatment plan acceptance rate was increasing dramatically with these materials.

My husband, Dr Ken Hebel, began employing these materials and experienced the same response. Patients asking about treatment options were presented with the printable materials to review and take home. We both found that in addition to enhanced case acceptance, this material was a referral driver.

This digital educational tool, facilitation of patient comprehension and acceptance of proposed treatment manifested in a software program, was originally called Click & Print, which contained printable forms and a few animations that demonstrated dental procedures. Click & Print was sold on a disk for several years. Four years ago, we started to notice a shift in the way that companies were doing business—becoming cloud based—and we made the investment to convert our disk-based product to a web-based product. The development took over a year, but the investment proved to be a smart decision, since we emerged as My Dental Hub—the first cloud-based patient education and practice-marketing solution.

As a cloud-based company, we have the ability to constantly upgrade and update our product offering, and customise our solutions to the needs of our clients. As the dental industry starts moving towards cloud-based solutions, we are well positioned to offer solutions to meet the needs of the individual dental practice, as well as the collaborative needs of dental organisations.

_How do/did you obtain the information used in the software? Do you collaborate with universities and/or companies?

Most of the software content was written and developed by Dr Hebel and me. We collaborated with dental colleagues for some of the clinical content; however, all the 3-D animations are designed and created in-house. The users of our program play an important role in the development of our content, since we develop content based on what our clients need.

Clients submit requests for content they would like to see, and based on popularity and demand, we develop the content. So, in fact, it is actually our users that have guided the direction of the content in the software. This is one of the tremendous advantages of being a web-based company. As we develop new content, we upload it to the program, and it is immediately available to our users. No need to wait for next year's disk upgrade!

Convincing patients to invest in dental treatment, e.g. an implant treatment, is a challenging task. How will My Dental Hub help?

We believe that there are three primary components to case acceptance. Patients will invest in dental treatment if they understand the problem and understand the treatment that is being offered, but more importantly, patients must understand the value of the treatment and how that treatment will improve the quality of their life (whether it is related to improving function or aesthetics). The content in My Dental Hub has been specifically developed to address these components of patient education in a language that patients will understand. The 3-D animations are used to visually explain the procedure and the benefits of the treatment, and the printable (e-mailable) documents serve as reinforcement of the animations and as a resource for patients to review at home.

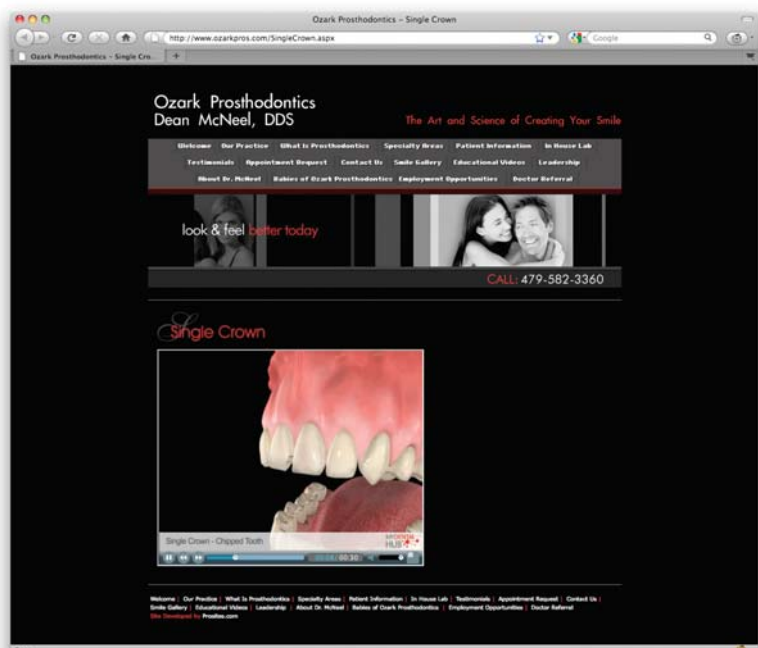
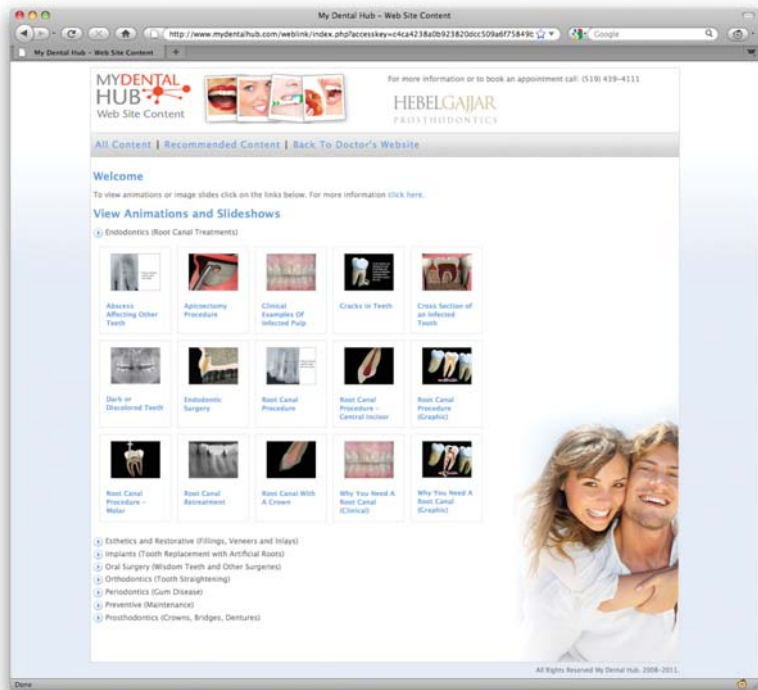
What are some of the additional features the software offers?

One of the key features of the software is the ability to e-mail the animations and documents to patients. This allows the dental practice to extend their consultation from their office into the patient's home, where patients can share and discuss the recommended treatment with those involved in the decision-making process.

My Dental Hub has several modules within the program. We offer animations, image documents, narrated slide shows, customisable text documents, a document creator, a patient and photo management section allowing the practice to upload and store patient images, as well as a presentation-creation module. Our newest module, *Easy Consult*, has been extremely popular and is currently our most-used module. *Easy Consult* allows the busy

practice to do a consultation in three simple steps and then e-mail the entire consultation to their patients. It automates the consultation process. It's very simple and highly effective!

Users can link their practice website to the Website Content template, which is personalised with the doctor's logo and contact information.



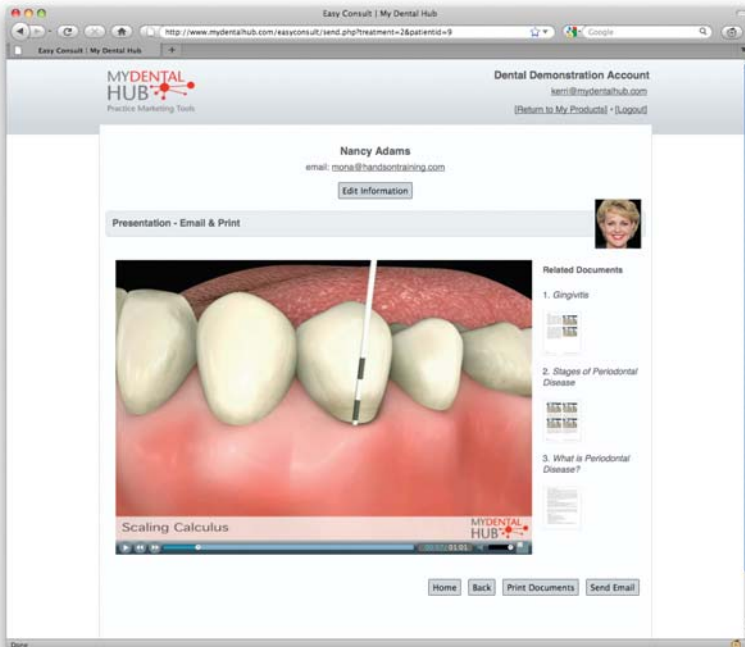
My Dental Hub also offers mobile applications (apps), available on iPad, iPhone and Android tablets, containing all our animations and slide shows. The iPad app is extremely popular in dental practices as an easy way to explain treatment to patients. It provides an exceptional presentation on oral-hygiene instruction, which invariably is a significant driver in any dental practice.

Users can also embed any of the narrated animations or slideshows directly in their practice website to maintain branding and consistency.

Easy Consult allows the busy practice to do a consultation in three simple steps and then e-mail the entire consultation to their patients.

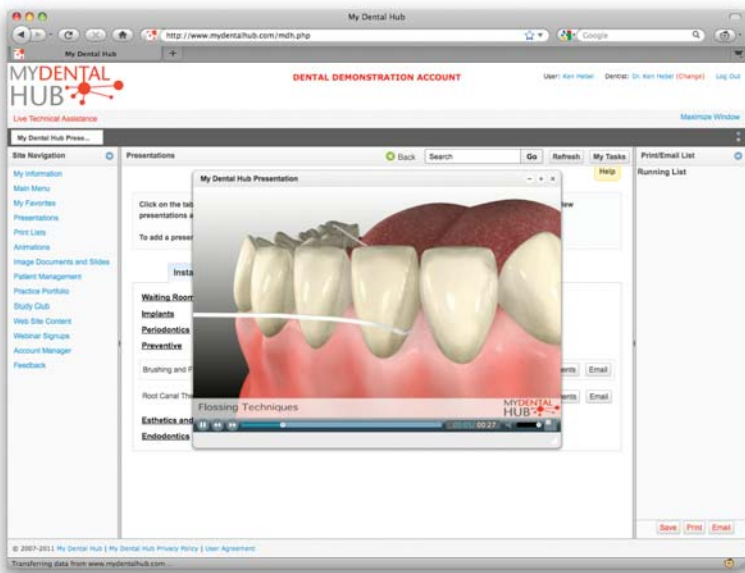
In addition, we offer a product called *Web Site Content* that allows users to place any of our animations and slideshows on their websites or linked to their website. High-quality animations on a website allow patients to obtain information about the procedures offered by the practice and

facility. External marketing includes websites, advertising, mailings, etc. that are done virally through e-mail or regular mail. Many dentists are not trained in marketing and find it inherently difficult to embrace marketing to grow their business. Many do not know how, many just don't think they need to.



Many dentists do not take the time to educate their patients or understand the value of patient education. Many feel that patients will accept treatment on the sole basis that the dentist told them they need it. That may have been the way it was, but we now live in an information-based society, and if patients do not receive adequate information from their dentist, they will seek it elsewhere. (Hopefully, that won't be the competitor down the street!)

We did a survey of our My Dental Hub clients to determine how effective patient education was in their practices. Our end users told us that they had experienced an increased case acceptance of **53%**! This number indicates the importance of educating patients, and the impact it has is apparent in any business, including the business of dentistry.



The process of patient education needs to be woven into the daily activities within a practice. This requires enhanced staff training and implementation. Many dentists do not invest the time to integrate the process into their practice procedures. Acceptance of a practice philosophy mandates that training for implementation is as important as training in the procedure.

Can My Dental Hub also be a helpful tool for cutting through language barriers or communicating with disabled patients?

Absolutely! A picture is worth a thousand words. Visual images and especially animations tell a story, even if the words cannot be understood. Many of our dentists use our iPad app for that reason. Even with the narration turned off, patients use the iPad to browse the animations and learn about the different dental procedures offered by the practice. Most of us are visual learners. In situations in which there may be a communication barrier, we find that our client base uses the animations as a component of informed consent.

Is the software available in different languages?

The software is currently only available in English; however, we are working on translating the software into Spanish and French. We have

Instant presentations make even the most complex case presentations easy, with supporting documents ready to be printed or e-mailed.

offer a powerful branding and marketing tool for a practice.

In your opinion, what are the most common mistakes dentists make in patient education/marketing their dental practice?

There are two types of marketing that dental practices should do—internal and external marketing. Internal marketing includes posters, brochures, discussions, etc. delivered within the

many international practices that have requested translations and our goal is to offer the program in multiple languages, thus catering to an international clientele.

How much does the software cost? Are updates available free of charge?

My Dental Hub is a suite of products and is subscription based. All updates are included in the subscription fee. The full package includes animations, slideshows, documents, patient and photo management, presentations, and *Easy Consult*. The software comes with an unlimited licence, which means that within a practice, there can be an unlimited number of computers and users. The subscription also includes unlimited training, unlimited support, all updates and upgrades, all new content, an unlimited number of e-mails, unlimited storage of patient data, photos and documents and daily backup. We offer special pricing for American Academy of Periodontology members (we were chosen as their exclusive patient-education provider), and other organisations. Pricing can be found on our website. We also offer a "lite" version of the software that provides access to all of our animations and narrated slideshows on both computers and mobile devices.

Web Site Content allows the practice to link their website to the entire library of narrated animations and slideshows so patients can browse through all the content and/or they can embed specific content directly into their website. We also offer a free ten-day trial that can be requested on our website.

In your opinion, how will digital tools change the dental practice and the way in which doctors communicate with their patients?

The entire world is digital—not "becoming" digital. Dentists must embrace this new means of doing business simply because it is now a component of everything, from paying a bill in a restaurant to travel, shopping and doing something as basic as reading.

In terms of communication, digital tools enable a dental practice to communicate quickly, easily and effectively with patients or referrals. No more printing, no more mailing, diminished expense and waste.

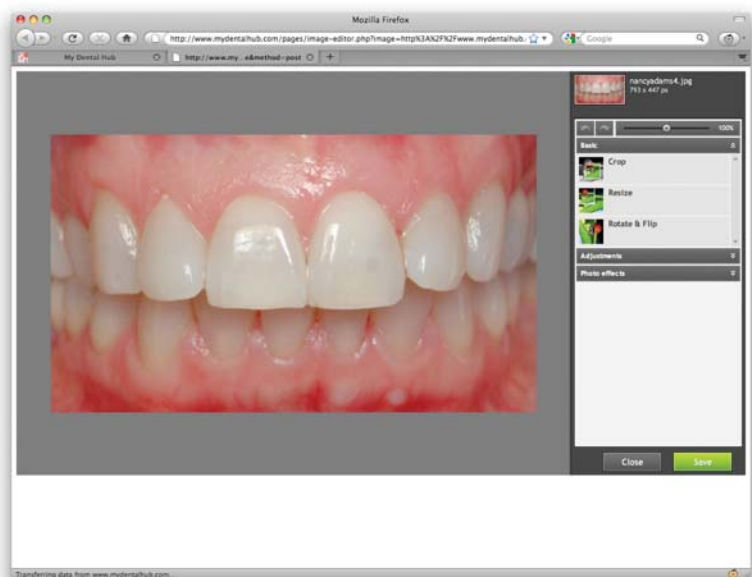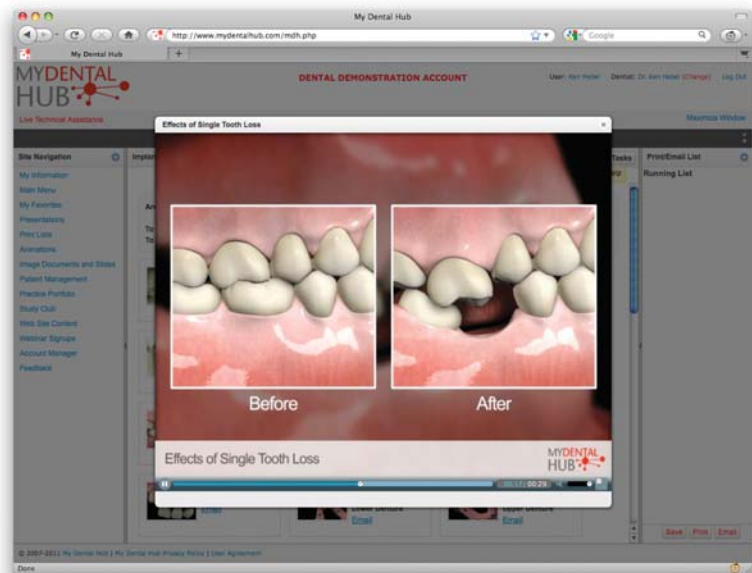
Society is changing. People are more aware of their environment and doing their part to go "green". With simple tools, a dental practice can deliver high-quality education directly and exemplify "environmental friendliness" as well. Ten years ago, if you had told people you could e-mail

animations to patients to show them a dental procedure, no one would have believed it possible. Today, this is the way of the world and the way business is being done.

I believe that with the incorporation of digital tools into a dental practice, "elegant simplicity and seamless connectivity" with patients and

Hundreds of videos with narration can be accessed easily.

Industry leading, stunning animations explain dental procedures in a clear, concise manner.



colleagues will become the standard. Those who embrace today's technology will be tomorrow's industry leaders.

A simple photo management module organises patient photos and offers easy to use editing tools.

We all live in a connected world. My Dental Hub is about being at the epicentre of that connection in the dental world.

For more information please call +1 877 789 4448 or visit www.mydentalhub.com.

“The Scanner mode is going to revolutionise dentistry”

An interview with Dr Ladislav Grad & Dr Matjaz Lukac, Fotona d.d.



Dr Ladislav Grad & Dr Matjaz Lukac

_The new LightWalker hard- and soft-tissue dental laser system from Fotona was introduced at IDS 2011. The system offers a wide range of dental applications and, according to the manufacturer, will revolutionise dentistry in the coming years. **roots** had the opportunity to speak to Drs Ladislav Grad and Matjaz Lukac about the benefits of the system for general dentists, as well as specialists.

_roots: *Dr Grad, Dr Lukac, congratulations on the launch of LightWalker! Would you please tell us about its applications and how dentists can benefit from using it?*

Dr Grad: LightWalker has two laser sources, offering a wide range of dental applications. The laser can be used in all different dental specialties—endodontics, periodontics, conservative dentistry, tooth whitening, etc.—but there is more. Fotona is a manufacturer of medical lasers and well known in the field of surgical and dermatological lasers. Owing to our background, we were able to include additional indications. You see, in some countries, dentists can perform aesthetic treatments, such as facial hair removal or removal of vascular lesions.

Our system is also perfect for surgical procedures. For example, treating leukoplakia was a very invasive procedure traditionally. With our laser, the lesions can be vaporised with almost no bleeding or trauma, which is a big advantage for patients and doctors. We know of some clinics, where one laser is shared by different departments: three days a week, it is used in the dental department; two days a week, the aesthetic doctors and dermatologists use it for their patients.

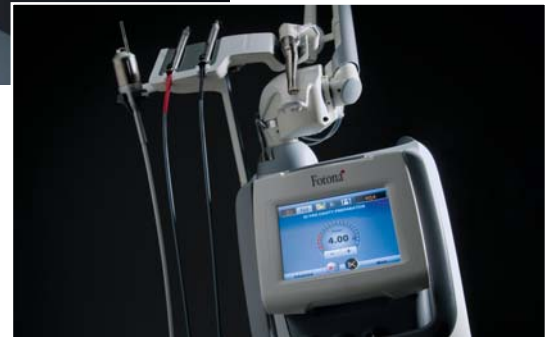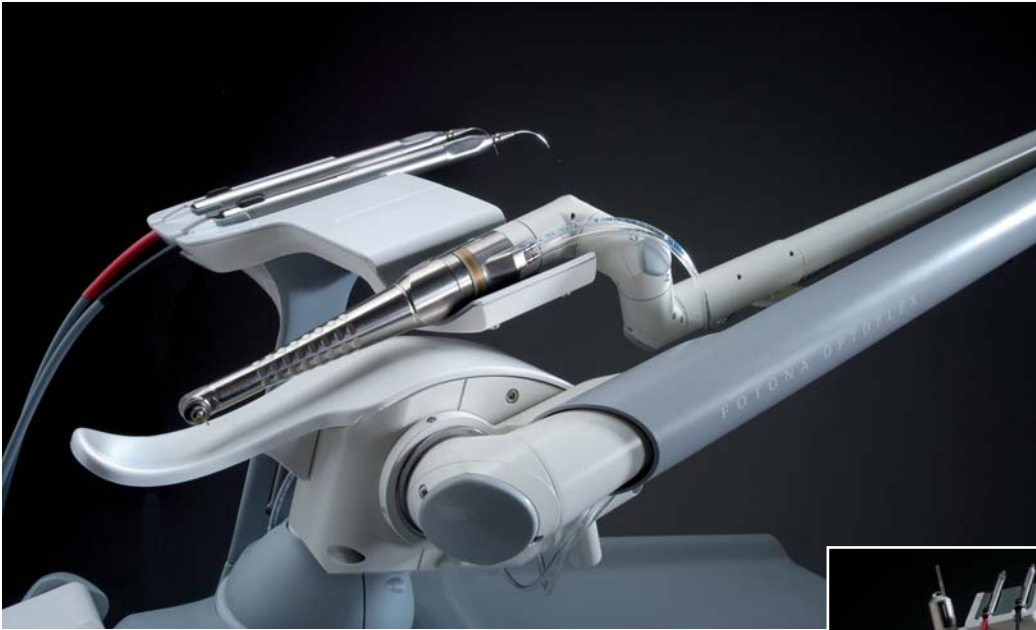_What was the impetus for developing the new laser?

Dr Lukac: We have been in dental lasers since the early '90s, and wanted to pool all of our experience—in terms of use and technology—into a new system without having to make any compromises. Amongst the most exciting applications of LightWalker is the photon-induced root-canal therapy that makes treating even posterior teeth a simple procedure for every general dentist. There is also a combined laser wavelength procedure, the TwinLight, for periodontal disease treatment. With TwinLight, hard-tissue calculus and soft-tissue epithelial lining can be removed. General dentists can now treat perio patients' disease comprehensively, without scalpels or sutures, right in their own practice. Amongst the aesthetic treatments, our patented TouchWhite tooth-whitening method should be mentioned. It is extremely gentle, yet shortens the whitening time by a factor of five.

Our patented quantum square pulse (QSP) technology allows the laser to ablate more efficiently and with greater precision because the laser beam is not affected by hard-tissue debris. We created this technology especially for this laser. By being able to ablate more efficiently, the edges of individual craters are virtually straight, creating a perfect cut and resulting in higher levels of precision and maximum tooth preservation in hard-tissue treatments.

_Where are your biggest markets at the moment and which markets are you approaching?

Dr Grad: Currently, the biggest market for our lasers is Europe. However, with LightWalker we plan on becoming a global market leader.



What additional features are you offering with the laser?

Dr Lukac: There is one feature, the scanner mode, which we think is going to revolutionise dentistry. LightWalker is the first dental laser system in the world that can accommodate laser scanning technology. The scanner-ready Er:YAG laser will be able to provide consistent and even ablation in hard and soft tissue. The speed and consistency of ablation performed with a scanner is virtually impossible to achieve with any other tool. It is the "weightlessness" of the laser light that makes this possible. Our goal now is to guide dentists in using the scanning ability of the laser.

We also believe that one of the first fields that is going to be revolutionised will be implantology. Now, it is finally possible to drill larger diameter holes with laser. Currently, mechanical drills are used, which cause thermal damage and a smear layer, which can lead to problems later on, such as infections. We are currently conducting clinical research on this and we don't have FDA clearance yet, but that's where we are going.

What effect do you foresee lasers are going to have on dentistry?

Dr Lukac: The big selling point for this unit is its wide range of applications. This is what is drawing customers. As I said, this technology evolves so that it is easy to use. It is a tool that can be used for a variety of indications. I am predicting that soon there will be no more laser-specific dental meetings because the laser is becoming part of the regular dental practice, thus laser will become part of general meetings. Soon, lasers will be just another dependable tool that dentists use without hesitation.

How can dentists learn about how to use this laser effectively? Are you offering courses?

Dr Grad: Yes. Laser dentistry is currently not part of the dental curriculum taught at most universities.

There are, however, many possibilities for postgraduate dental education. We have reference doctors in different states who offer local training courses. We collaborate a great deal with Aachen University in Germany, which is the leading educational and research institution for lasers in dentistry. There are specific dates reserved on which practitioners can attend a training seminar at the university. It is very important for users to establish a safe and confident handling of this technology and education is the way to go about establishing that. There is no turning back. Without laser technology, there is no modern dentistry.

For information on Fotona laser workshops please go to www.fotona.com/en/dentistry/workshops/.

_contact

roots

Fotona d.d.

Stegen 7
1000 Ljubljana
Slovenia

info@fotona.com
www.fotona.com

Connectivity in the dental world

Author_ Shane Hebel, Canada

_We live in a time in which things are changing exponentially and the way that we go about doing business is drastically evolving. The Internet has become a major player in businesses that never thought that it could apply to them. Instead of battling the Internet with a long stick and keeping it out of the dental industry, it has always been our philosophy to leverage it in new and innovative ways that can be used to the advantage of health-care professionals worldwide.

After a lot of research and brainstorming, we discovered that the real reason that people are online and using products is because of a little thing called connectivity. Many people are online because it allows them to connect and engage with other people who have similar ideas, views or interests. We knew that our mission of serving as a communications and learning hub was lacking, as we were not serving every aspect of our clients' needs in this area of dentistry. This led to a few feverish weeks of programming, writing and networking to bring you the latest suite in the 'Hub'.

_Introducing My Dental Buddies!

MyDentalBuddies is a network of dental bloggers, community members and dentists, who can collaborate to provide information to the dental community at large. This free initiative is a social network that allows users to connect and engage with fellow dentists around the world! This is a HUGE opportunity to learn in a collaborative and innovative way to increase your efficiency and effectiveness in your own personal practice.

In one day, more than 100 million people signed onto Facebook. Twitter generated more than 300 million tweets. Approximately 3 million people 'checked in' to their current location and 35,000 hours of video was uploaded to YouTube. The Internet is an extremely busy place for all of that to happen in a single day!

You may ask why that is relevant to you. Fantastic, you say, more teenagers are uploading pictures of the party they went to last night. You may be thinking that this massive amount of sharing has no more value than the latest episode of *Jersey Shore*. However, this is where you may benefit from a change in perspective! Although social media started as just that, a place to socialise, it has expanded into a massive enterprise that has since evolved into a realm with numerous applications for anyone in the world.

Let us take a few minutes to really dig into what social media is and why it can benefit YOU. Who cares about how it can benefit Lady Gaga or President Obama. I want to know how it can benefit ME in my life and why it is such a big deal.

Unfortunately, this time around our good friend Wikipedia let us down. Wikipedia defines 'social media' as "the use of web-based and mobile technologies to turn communication into interactive dialogue". Okay, so that tells us the specifics of what social media does. It allows people to connect online. Well, that's cool. E-mail did that. Why is social media so special?

Let us bring it down a peg and see if we can gain some further insight. "If you make customers unhappy in the physical world, they might each tell six friends. If you make customers unhappy on the Internet, they can each tell 6,000 friends," Jeff Bezos, CEO of amazon.com, said. WOAHH, now that provides a lot of insight! Social media allows people to interact with thousands and thousands of people that they would not have access to otherwise. *And they can tell them whatever they want. Uncensored. Fantastic!*

So, social media allows people to say whatever they want online without being censored. Social media is a +1 for free speech. However, we still have not answered the question: *what does that mean for*

you? Well, let us go down one step further with some specific examples. If your customers are telling 6,000 people that they are at the dentist and they are lovin' it—that's really good. If they are telling 6,000 people that your office is terrible—that's not so good for you. Being part of the social network and getting involved in communication areas that your patients are in will give you an unprecedented look into your 'online reputation' and give you a chance to really see what your patients are saying.

So now we're spying!?! Fantastic, just what you want to do in the health-care industry. The news industry recently tried that and the resulting News Corp and James Murdoch phone-hacking scandal has resulted in worldwide embarrassment for both the media industry and the governments in which those companies operated. However, there are more aspects of social media that are very beneficial to you, and not in a creepy kind of way. When people think of social media, their minds immediately jump to huge websites like Facebook and Twitter. While these websites embody the values of social media, they're not the end-all and be-all of the social media landscape.

Social media is about *connecting and collaborating* online. Take a look at LinkedIn, tumblr, YouTube and the many other social media websites out there today. These are social media tools. These are social networks. These are YOUR networks. They are places where you can come to connect with fellow people, to collaborate and to LEARN. That is the most important part of all of this! Social media provides an extremely effective medium for active learning, participation and collaboration.

Social media is one major player on the Internet, but it is not the only way that the Internet is changing the dental industry. The Internet has a vast array of resources that are making our world faster paced, more dynamic and more thought-provoking. It is also changing the way that we compete and how we do business. The health-care industry has long been a profession in which competition is not considered a large factor. Many individuals stayed with a health-care professional for their entire lives and that was the end of it. Once again, the Internet has played a part in upsetting the status quo and changing the way that people view healthcare. Websites like WebMD.com and the online directories of health-care professionals in different areas have opened up the possibility of competition where one did not exist before. Dentists and other health-care professionals are starting to have to change the way that they do things in order to compete in this new marketplace.

One of the most important things that dentists do in their practice is selling. Now, this is not the way

things have been done in the past. Many dentists still operate under the belief that patients come to them for health care, not to be sold to. However, let's look at some of a dentist's vocabulary in sales terms and see what happens:

diagnosis: which product will work best for the patient

case options: pitching

case acceptance: making the sale

treatment: delivery of product

Are you still as convinced that sales do not exist in the dental industry? The Internet is responsible for a huge number of changes in the dental industry and as a result health-care professionals are constantly having to be innovative in order to survive in a more competitive and dynamic workplace.

I stumbled across this cool article recently that talks about innovation in the workplace, a fascinating read and very applicable to the dental industry! This is one area where dentists are currently lacking. It is so easy to fall into a set routine and not think about new or different ways to do things. I mean, why bother? Your practice is making money. Why do you need to be innovative?

Emily Ford, *The Sunday Times*, recently wrote an article on that very topic. Innovation is a huge new part of the dynamic connected world. People are constantly collaborating to come up with more and more innovative solutions to problems and it is important to keep up with this changing environment. Ford suggested a few tips for innovating at work, which have been given a dental twist to make them especially applicable to your practice.

Make innovation a priority

Always look for new ways you can do things, new products you can use and new ways of interacting with your staff and patients. Not only will it make your days new and exciting, it will benefit your practice in the long run too!

Take risks and embrace failure

If you buy a new instrument and it does not work, what did you lose? A little bit of time and money? What would have happened if it worked? You may have saved a ton of time, made the quality of treatment increase and made a patient's ordeal less painful. Do you think that it is worth it? I definitely do! By embracing failure, you can learn new things quickly, learn what works and what does not in your practice, and ultimately help your practice to succeed with the increased knowledge that you will have.

Eyes on the future

Think of it this way: when you know where you're going, you can figure out the fastest and easiest way to get there. By planning ahead, you can spend time thinking of innovative and new ways of doing things that will make your future endeavours that much easier. By knowing where you're going, you can constantly be on the lookout for things that will help you get there, making the whole process faster and more efficient.

Foster creativity at all levels

Encourage your staff to do the same as you! Ask them to be constantly thinking about ways they could change the way that they do things. Would something else work better than what they're currently doing? Could they use a new tool to make their job easier? No one will know the answers to these questions better than them, so have them start thinking about it! Your staff are a huge resource in coming up with creative and innovative ideas in your practice.

Break the rules

Ask a ton of questions! Why do you do something a certain way? Has anyone ever tried doing it another way? We get so entrenched in our beliefs, habits and routines that over time we stop thinking about why we do things and just do them. Bring that back! Question the things you do everyday—ask yourself why you do them and whether there's a better way. Chances are that you'll find a few things that will make your practice a more productive and efficient place!

Collaborate across boundaries

Everyone has insights to share. Your receptionist or assistant may notice things that you do not. Get

them involved in the process! Chances are that they have some great ideas of things that you could be doing in your practice that you are not. Using your staff effectively is one of the best things that you could do and by involving them in this process you are giving them ownership of the success of the practice and motivating them to make it better!


Innovating does not have to be a one-man show either. The Internet is connecting us in ways that we could not have even dreamed of in the past and it is important to be involved in every way that you can. Although the Internet provides both a valuable resource and fierce competition for your time and your professional career, it is not the only tool for collaboration and shared learning that is out there today.

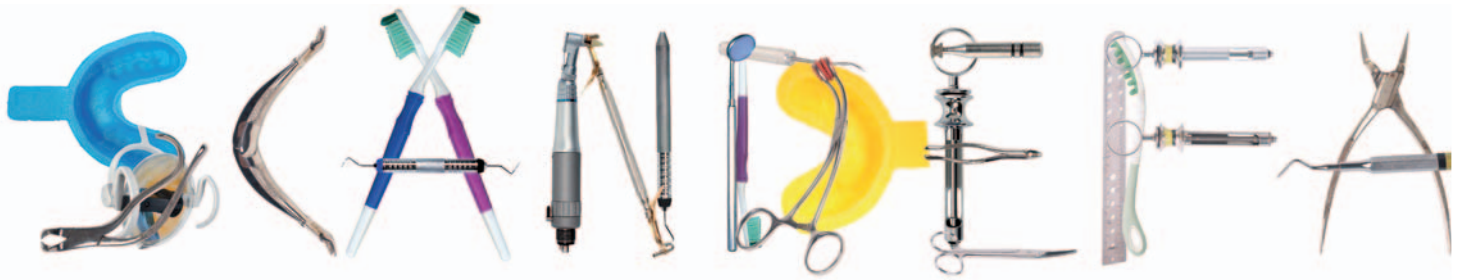Here is a new and interesting thought: why don't you ask your employees for their ideas? Your employees may have a ton of cool and innovative ideas for ways that you could make your practice more efficient and effective. However, they are probably not telling you these ideas! Why not? Well, for starters, you never asked! Many people won't share their opinions about some things (especially business) because they are scared that they will seem like they do not know what they are talking about. No one likes that feeling!! If your employees know that their ideas are welcome you will probably find them flooding in!

What does this all boil down to? It comes down to *connectivity* and *collaboration*. That's it. Those two simple words are what the future of the dental industry (and every other industry) is going to come down to. The ability to collaborate with other like-minded individuals, share ideas, innovate and ultimately create a better working system are what the Internet, social media and connective sites are all about.

This is what we are about at My Dental Buddies. My Dental Buddies is a connective website for you, for dentists, staff and other health-care professionals in the dental industry. We recognise the importance of collaborating socially and innovating together and want to bring that to you. It is a portal, a blank slate that the users of the site can fill with whatever content they feel is important to them. That is the beauty of the uncensored Internet; whatever is most important to the largest number of people is what gets talked about. We strive to leverage the Internet to make your dental practice the best that it can be. Please help us to do the same!_

Editorial note: A complete list of sources is available from the publisher.

_about the author		roots
	<p>Shane Hebel is currently a student studying Finance and Accounting at the Schulich School of Business. He is a sales and marketing executive for My Dental Hub. He is involved in a number of organisations that promote collaboration, connectivity and education, including Impact Entrepreneurship Group, Standard International and, of course, My Dental Buddies.</p>	
<p>shane@mydentalhub.com www.about.me/shane.hebel www.linkedin.com/in/shanehebel www.twitter.com/shane_hebel</p>		



APRIL 26- 28, 2012 • BELLA CENTER • COPENHAGEN • DENMARK

Welcome to the 45th Scandinavian Dental Fair
The leading annual dental fair in Scandinavia

SCANDEFA 2012



The 45th SCANDEFA invites you to exquisitely meet the Scandinavian dental market and sales partners from all over the world in springtime in wonderful Copenhagen

SCANDEFA 2012

Is organized by Bella Center and is being held in conjunction with the Annual Scientific Meeting, organized by the Danish Dental Association (www.tandlaegeforeningen.dk).

175 exhibitors and 11.422 visitors participated at SCANDEFA 2011 on 14,220 m² of exhibition space.

Exhibit at Scandefa

Book online at www.scandefa.dk
Sales and Project Manager, Christian Olrik
col@bellacenter.dk, T +45 32 47 21 25

Travel information

Bella Center is located just a 10 minute taxi drive from Copenhagen Airport. A regional train runs from the airport to Orestad Station, only 15 minutes drive.

Check in at Bella Center's newly built hotel

Bella Sky Comwell is Scandinavia's largest design hotel. The hotel is an integral part of Bella Center and has direct access to Scandefa. Book your stay on www.bellasky.dk

Six steps to a chartless practice

Author_ Dr Lorne Lavine, USA

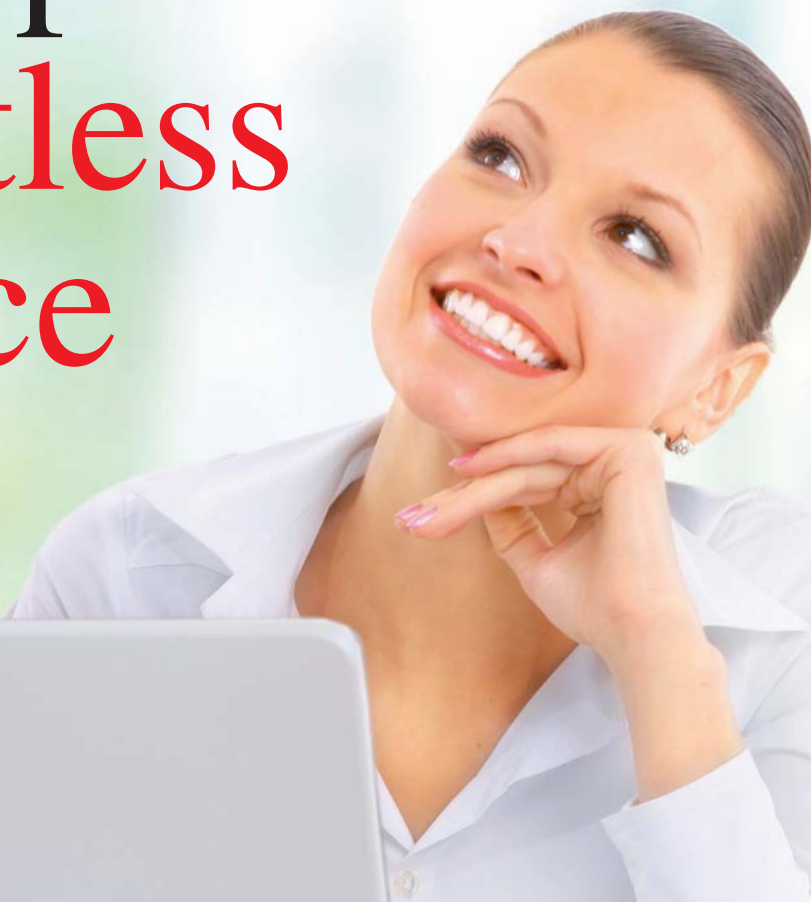

Photo: EDHAR

_There is no doubt that the modern dental practice has changed rapidly over the past fifteen years. Dentists have come to realise that with new technology, they can create a practice that is more efficient, costs less to run, and allows for decentralisation of the front office. Records that were primarily paper- and film-based are being replaced by digital radiography, electronic records, and there is a move towards a paperless, or at the very least, chartless practice. Most offices realise that there will always be paper in a dental practice. Whether it is walkout statements, insurance forms or printed copies of images, paper will forever be part of the dental practice. That being said, there are a number of practices that have truly eliminated their paper charts. While the process is easier for a start-up practice, with proper planning, existing practices can achieve this goal as well.

Many dentists are probably aware that the Federal Government is mandating that all patient records be paperless by the end of the year 2014. The challenge for most practices is evalu-

ating their current and future purchases to ensure that all the systems will integrate properly together. While many dentists are visually oriented and thus tend to focus on the criteria that they can actually see and touch, some of the most important decisions are related to more abstract standards. I have therefore developed a six-point checklist that I feel is mandatory for any dentist adding new technologies to his or her practice, and I recommend that each step be completed in order.

_I Practice management software

It all starts with the administrative software that is running the practice. To develop a chartless practice, this software must be capable of some very basic functions. For practices that wish to eliminate paper, dentists need to consider every paper component of the dental chart and try to find a digital alternative. For example, entering charting, treatment plans, handling insurance estimation and processing through e-claims, ongoing patient retention and recall

activation, scheduling, and dozens of other functions that are used on a daily basis. Many older programs do not have these features and if practices wish to move forward, dentists will have to consider more modern practice software.

It is important to understand that as much as we would all prefer that our practice management software programs could handle all of these functions, most fall short of this. Fortunately, there are a number of third-party programs that can provide functionality where the practice management programs cannot, such as programs that allow digitisation of forms that require patient signatures and programs that can reduce the process of entering progress notes to a few clicks of a mouse.

_II Image management software

This is probably the most challenging decision for any practice. Most practice management programs offer an image management module. Eaglesoft has Advanced Imaging, Dentrix has Dexis, Kodak has Kodak Dental Imaging, and so on. These modules are closely integrated with the practice management software and tend to work best with digital systems sold by the company.

For example, having an integrated image module makes it very easy to attach images to e-claims with a few clicks of a mouse. However, there are also many third-party image programs that will bridge very easily to the practice management software and offer more flexibility and choices, although with slightly less integration. There is no perfect system. The choice really is between paying a premium for greater integration or paying less for greater flexibility. Some of the better known third-party image programs include Apteryx XRayVision, XDR and Tigerview.

_III Operatory design

The days of a single intra-oral camera and a TV in the upper corner are being replaced by more modern systems. The majority of practices place at least two monitors in the operatories, one for the patient to view images or for patient education or entertainment, and one for the dentist and staff to use for charting and treatment planning and any sensitive information concerning the Health Insurance Portability and Accountability Act, such as the daily schedule or other information that dentists would prefer that the

patient not see. Microsoft Windows has built-in abilities to allow dentists to control exactly what appears on each screen.

There are numerous ergonomic issues that must be addressed when placing monitors, keyboards and mice. For example, a keyboard placed in a position that requires the dentist to twist his or her back around will cause problems, as will a monitor that is improperly positioned. Another important decision for the practice will involve deciding whether the dentist prefers patients to see the monitor when they are completely reclined in the chair. If this is the case, then the options are a bit more limited for monitor placement. There are some very high-tech monitor systems that not only allow the patient to see the screen, but also create a more relaxing environment for patients considering long procedures.

_IV Computer hardware

After the software has been chosen and the operatories designed, it's time to add the computers. Most practices will require a dedicated server in order to protect their data and with the necessary power to run the network. The server is the lifeblood of any network and it is important to design a server that has redundancy built-in for the rare times that a hard drive might crash and can easily be restored. The workstations must be configured to handle the higher graphical needs of the practice, especially if the practice is considering digital imaging.



Photo: Konstantin Chagin



Photo: Minerva Studio

The computers placed in the operatories are often different from the front desk computers in many ways. They will have dual display capabilities, better video cards to handle digital imaging, smaller cases to fit inside the cabinets, and wireless keyboards and mice. An often-overlooked consideration is that the smaller the computer, the more heat it generates. Heat is the number one enemy of computers, and since many dentists will place their computers inside a cabinet at the 12 o'clock position, having proper ventilation is critical.

_V Digital systems

The choice of image software will dictate which systems are compatible. Digital radiography is the hot technology at this time owing to many factors. Dentists with digital radiography report greater efficiency by having the ability to capture and view images more rapidly, better diagnostics, cost savings by the elimination of film and chemicals, and higher case acceptance through patient co-diagnosis of their dental

needs. All systems have pros and cons, and dentists will have to evaluate each system based on a set of standards that are important to that practice. For some dentists, it might be image quality. For others, it may be the cost of the systems, the warranty of the sensor, the company's reputation, or the compatibility of the sensors with their existing image management software. Keep in mind that intra-oral cameras are still an excellent addition to any practice, since they allow patients to see the things that typically only a practitioner could see.

_VI Data protection


With a chartless practice, protecting data is crucial to preventing data loss due to malware or user errors. Every practice, at a minimum, should be using antivirus software to protect against the multitude of known viruses and worms, a firewall to protect against hackers, who try to infiltrate the network, and have an easy-to-verify backup protocol in place to be able to recover from any disaster. The different backup protocols are as varied as the number of practices, but it is crucial that the backup is taken offsite daily and can be restored rapidly. The modern term is *practice continuity*. It is not only the data that is being backed up that is important, but also critically, the speed with which the system can be restored and the practice can be up and running following a disaster such as a server crash, fire or flood.

For practices that wish to be chartless or paperless, it is crucial to evaluate all the systems that need to be replaced with a digital counterpart, and to adopt a systematic approach to adding these new systems to the practice. Most practices would be well advised to replace one system at a time, and become comfortable with this new system before adding new technologies to the practice. The typical practice will take 9 to 18 months to transition from a paper-based practice to a chartless one.

_contact	roots
	<p>Dr Lorne Lavine 2501 W. Burbank Blvd., #303 Burbank, CA 91505 USA</p> <p>drlavine@thedigitaldentist.com www.thedigitaldentist.com</p>

Endo the confident way

The current trend in surgical endodontics is using a minimally and non-invasive protocol to treat the entire root canal, using an operating microscope and high-tech micro-instruments.



Satelec presents the Endo-Success Apical Surgery kit of five ultrasonic instruments, developed to perform the exclusive 3-6-9 protocol for micro-apical surgery.

The active part of the instruments has a new diamond coating that enhances their efficacy, allowing for more precise and controlled retro-endodontic

treatment and conserving more bone and dental tissues. The root canal is preserved and the infection eradicated at its origin.

The first instrument to be used in following the protocol is the AS 3D universal tip with a 3 mm working length. Next is the AS 6D, which reaches 6 mm. The AS 9D is then used up to the coronal third (9 mm) in certain cases. Finally, the ASLD (left oriented) and ASRD (right oriented) tips are used to treat premolars to a working length of 3 mm.



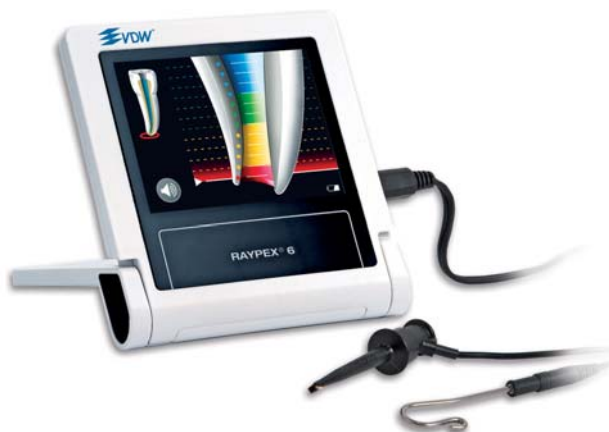_contact	roots
<p>Satelec-Acteon Equipment 17 Avenue Gustave Eiffel 33708 Mérignac France</p> <p>satelec@acteongroup.com www.acteongroup.com</p>	

RAYPEX 6

State-of-the-art technology

For the precise location of the apical constriction, electronic means have been proven to be superior to using radiographs. RAYPEX devices ensure precise measurement and feature a unique zoom-in function, which significantly aids endodontic treatment. The latest model, RAYPEX 6, redefines user-friendliness and design standards.

Its design, operation and user-friendliness were developed to a high standard, resulting in a stylish and handy casing, which can be folded flat when not in use. The high-resolution touch-screen with a self-explanatory user-interface is comparable with a smartphone, and the menu guidance was designed to ensure precise and fast navigation through the functions.



For precise length determination, RAYPEX 6 uses the latest multi-frequency technology. The 3-D graphic display constantly indicates the position of the tip of the file, while the automatic zoom-in function in the region of the apical constriction enhances safety in the critical section just before reaching the working length. Acoustic signals allow for a "blind" localisation of the apex.

RAYPEX 6 is ready for use—simply plug-in and start. Any personalisation of display colour and tones, for instance, can be done quickly.

RAYPEX 6 means precise length determination and touch-screen convenience.

_contact	roots
<p>VDW GmbH Bayerwaldstr. 15 81737 Munich Germany</p> <p>info@vdw-dental.com www.vdw-dental.com</p>	

International Events

2011

Czech Endodontic Society Annual Congress

1 October 2011
Prague, Czech Republic
www.e-s-e.eu

DGET Annual Meeting

3–5 November 2011
Bonn, Germany
www.dget.de

AAE Fall Conference

3–5 November 2011
New Orleans, LA, USA
www.aae.org

Pan Dental Society Conference

11 & 12 November 2011
Liverpool, UK
www.pandental.co.uk

Greater New York Dental Meeting

25–30 November 2011
New York, NY, USA
www.gnydm.org

BAET International Dental Traumatology Symposium

16 December 2011
Brussels, Belgium
www.baet.org



2012

Second Pan Arab Endodontic Conference

11–14 January 2012
Dubai, UAE
www.paec2012.com

Swiss Society for Endodontology International Conference

20 & 21 January 2012
Lausanne, Switzerland
www.endodontology.ch

DGET Spring Academy

2 & 3 March 2012
Heidelberg, Germany
www.dget.de

Skand Endo

23–25 August 2012
Oslo, Norway
nina.gerner@c2i.net

DGET Annual Meeting

1–3 November 2012
Leipzig, Germany
www.dget.de

submission guidelines:

Please note that all the textual components of your submission must be combined into one MS Word document. Please do not submit multiple files for each of these items:

- _ the complete article;
- _ all the image (tables, charts, photographs, etc.) captions;
- _ the complete list of sources consulted; and
- _ the author or contact information (biographical sketch, mailing address, e-mail address, etc.).

In addition, images must not be embedded into the MS Word document. All images must be submitted separately, and details about such submission follow below under image requirements.

Text length

Article lengths can vary greatly—from 1,500 to 5,500 words—depending on the subject matter. Our approach is that if you need more or less words to do the topic justice, then please make the article as long or as short as necessary.

We can run an unusually long article in multiple parts, but this usually entails a topic for which each part can stand alone because it contains so much information.

In short, we do not want to limit you in terms of article length, so please use the word count above as a general guideline and if you have specific questions, please do not hesitate to contact us.

Text formatting

We also ask that you forego any special formatting beyond the use of italics and boldface. If you would like to emphasise certain words within the text, please only use italics (do not use underlining or a larger font size). Boldface is reserved for article headers. Please do not use underlining.

Please use single spacing and make sure that the text is left justified. Please do not centre text on the page. Do not indent paragraphs, rather place a blank line between paragraphs. Please do not add tab stops.

Should you require a special layout, please let the word processing programme you are using help you do this formatting automatically. Similarly, should you need to make a list, or add footnotes or endnotes, please let the word processing programme do it for you automatically. There are menus in every programme that will enable you to do so. The fact is that no matter how carefully done, errors can creep in when you try to number footnotes yourself.

Any formatting contrary to stated above will require us to remove such formatting before layout, which is very time-consuming. Please consider this when formatting your document.

Image requirements

Please number images consecutively throughout the article by using a new number for each image. If it is imperative that certain images are grouped together, then use lowercase letters to designate these in a group (for example, 2a, 2b, 2c).

Please place image references in your article wherever they are appropriate, whether in the middle or at the end of a sentence. If you do not directly refer to the image, place the reference at the end of the sentence to which it relates enclosed within brackets and before the period.

In addition, please note:

- _ We require images in TIF or JPEG format.
- _ These images must be no smaller than 6x6 cm in size at 300 DPI.
- _ These image files must be no smaller than 80 KB in size (or they will print the size of a postage stamp!).

Larger image files are always better, and those approximately the size of 1 MB are best. Thus, do not size large image files down to meet our requirements but send us the largest files available. (The larger the starting image is in terms of bytes, the more leeway the designer has for resizing the image in order to fill up more space should there be room available.)

Also, please remember that images must not be embedded into the body of the article submitted. Images must be submitted separately to the textual submission.

You may submit images via e-mail, via our FTP server or post a CD containing your images directly to us (please contact us for the mailing address, as this will depend upon the country from which you will be mailing).

Please also send us a head shot of yourself that is in accordance with the requirements stated above so that it can be printed with your article.

Abstracts

An abstract of your article is not required.

Author or contact information

The author's contact information and a head shot of the author are included at the end of every article. Please note the exact information you would like to appear in this section and format it according to the requirements stated above. A short biographical sketch may precede the contact information if you provide us with the necessary information (60 words or less).

Questions?

Claudia Salwiczek (Managing Editor)
c.salwiczek@oemus-media.de

roots

international magazine of endodontology

Publisher

Torsten R. Oemus
oemus@oemus-media.de

CEO

Ingolf Döbbecke
doebbecke@oemus-media.de

Members of the Board

Jürgen Isbaner
isbaner@oemus-media.de

Lutz V. Hiller

hiller@oemus-media.de

Managing Editor

Claudia Salwiczek
c.salwiczek@oemus-media.de

Executive Producer

Gernot Meyer
meyer@oemus-media.de

Designer

Josephine Ritter
j.ritter@oemus-media.de

Copy Editors

Sabrina Raaff
Hans Motschmann

Published by

Oemus Media AG
Holbeinstraße 29
04229 Leipzig, Germany
Tel.: +49 341 48474-0
Fax: +49 341 48474-290
kontakt@oemus-media.de
www.oemus.com

Printed by

Messedruck Leipzig GmbH
An der Hebemärchte 6
04316 Leipzig, Germany

Editorial Board

Fernando Goldberg, Argentina
Markus Haapasalo, Canada
Ken Serota, Canada
Clemens Bargholz, Germany
Michael Baumann, Germany
Benjamin Briseno, Germany
Asgeir Sigurdsson, Iceland
Adam Stabholz, Israel
Heike Steffen, Germany
Gary Cheung, Hong Kong
Unni Endal, Norway
Roman Borczyk, Poland
Bartosz Cerkaski, Poland
Esteban Brau, Spain
José Pumarola, Spain
Kishor Gulabivala, United Kingdom
William P. Saunders, United Kingdom
Fred Barnett, USA
L. Stephan Buchanan, USA
Jo Dovgan, USA
Vladimir Gorokhovskiy, USA
James Gutmann, USA
Ben Johnson, USA
Kenneth Koch, USA
Sergio Kuttler, USA
John Nusstein, USA
Ove Peters, USA
Jorge Vera, Mexico



Claudia Salwiczek, Managing Editor



Copyright Regulations

_roots international magazine of endodontology is published by Oemus Media AG and will appear in 2011 with one issue every quarter. The magazine and all articles and illustrations therein are protected by copyright. Any utilisation without the prior consent of editor and publisher is inadmissible and liable to prosecution. This applies in particular to duplicate copies, translations, microfilms, and storage and processing in electronic systems.

Reproductions, including extracts, may only be made with the permission of the publisher. Given no statement to the contrary, any submissions to the editorial department are understood to be in agreement with a full or partial publishing of said submission. The editorial department reserves the right to check all submitted articles for formal errors and factual authority, and to make amendments if necessary. No responsibility shall be taken for unsolicited books and manuscripts. Articles bearing symbols other than that of the editorial department, or which are distinguished by the name of the author, represent the opinion of the afore-mentioned, and do not have to comply with the views of Oemus Media AG. Responsibility for such articles shall be borne by the author. Responsibility for advertisements and other specially labeled items shall not be borne by the editorial department. Likewise, no responsibility shall be assumed for information published about associations, companies and commercial markets. All cases of consequential liability arising from inaccurate or faulty representation are excluded. General terms and conditions apply, legal venue is Leipzig, Germany.

roots

international magazine of endodontology



You can also subscribe via
www.oemus.com/abo

 **Subscribe now!**

I would like to subscribe to **roots** for € 44 including shipping and VAT for German customers, € 46 including shipping and VAT for customers outside Germany, unless a written cancellation is sent within 14 days of the receipt of the trial subscription. The subscription will be renewed automatically every year until a written cancellation is sent to OEMUS MEDIA AG, Holbeinstr. 29, 04229 Leipzig, Germany, six weeks prior to the renewal date.

► **Reply** via Fax to +49 341 48474-290 to OEMUS MEDIA AG or via E-mail to grasse@oemus-media.de

Last Name, First Name

Company

Street

ZIP/City/Country

E-mail

Signature

Notice of revocation: I am able to revoke the subscription within 14 days after my order by sending a written cancellation to OEMUS MEDIA AG, Holbeinstr. 29, 04229 Leipzig, Germany.

Signature

MAP SYSTEM

Micro-Apical Placement System



NiTi Memory Shape Nadel

- Niti memory shape needles – flexible, bendable needle
 - can be shaped to any required curvature – perfectly follows the canal anatomy
 - the needle takes its initial straight shape during autoclave sterilization
- The MAP (Micro-Apical Placement) System, provides a unique and efficient method for placing root-canal repair materials:
 - either by orthograde obturation for the treatment of perforations, root-end fillings and pulp-cappings using curved, straight or «memory shape» NiTi needles
 - or by retrograde obturation after apical resection thanks to the specially designed, triple-angled needles (left and right angled) and/or hooked needles