

Single-tooth implants in the aesthetic zone— Challenge and opportunity

Author_ Dr Ata Anil, Turkey

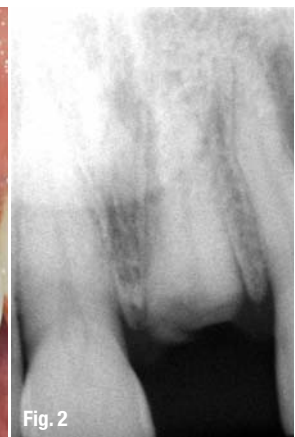
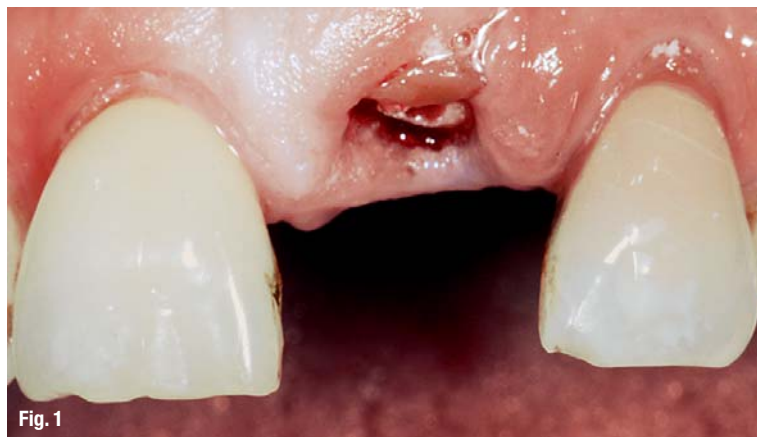
Fig. 1_Initial clinical situation with fractured tooth 21.

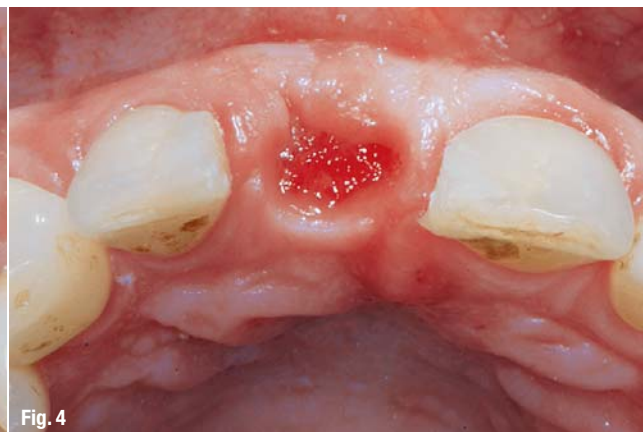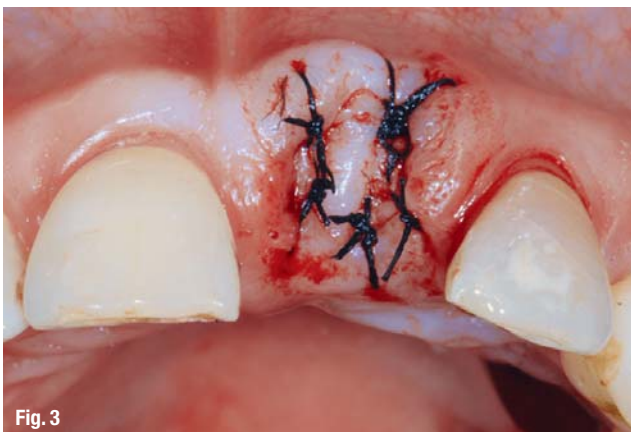Fig. 2_ Corresponding X-ray with conservable root remains.

_Single-tooth implants in the anterior region permit not only functional reconstruction at the highest level, but also reconstruction for aesthetic reasons. However, when providing cosmetically attractive treatment, a large number of parameters need to be taken into account, and experience and knowledge of physiological processes are essential. The following article will describe the implant-supported reconstruction of an anterior tooth lost as the result of an accident.

After extraction of the fractured root, we performed a reconstruction of the soft tissue to act as a basis for a harmonious reconstruction of red-white aesthetics. This was performed at the same time as implant placement via bone augmentation and connective tissue transplant. The surgical measures applied allowed optimisation of the hard and soft tissue and, using a gingiva former, the shape of the gingiva could be adapted to the neighbouring teeth. Delivery of a ceramic

Fig. 3_ After atraumatic extraction the alveolar cavity is closed with a free gingival graft.

Fig. 4_ The ovate pontic pre-forms the soft tissue.



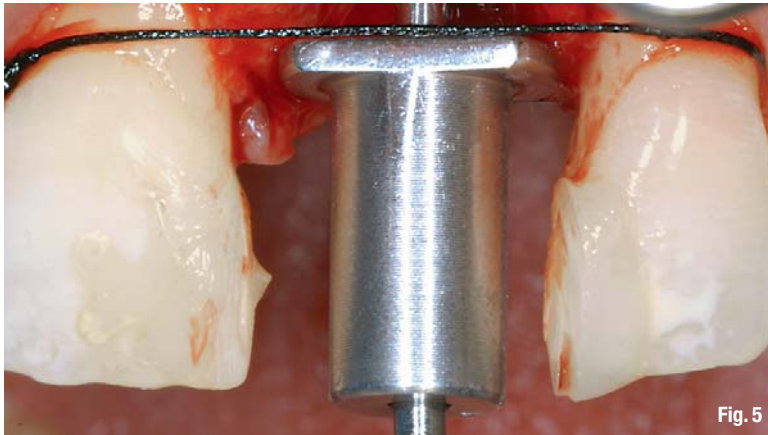


Fig. 5

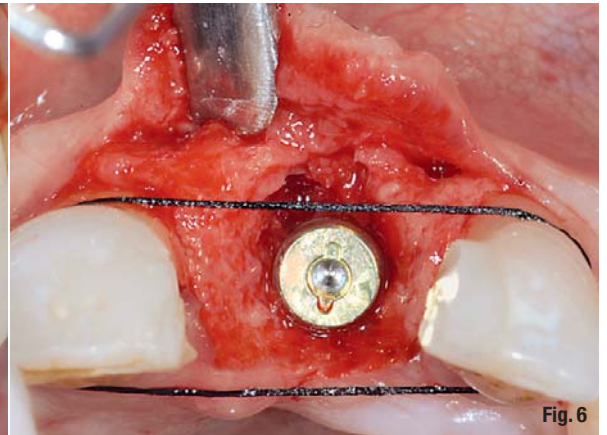


Fig. 6

crown completed the attractive final cosmetic result.

In the case of completely or partially toothless arches, implant-aided and -supported rehabilitation is a successful method of treatment in which single-tooth implants are largely used to restore function and aesthetics. Anatomically correct positioning of the implant can, however, only be realised, if the necessary bone level and soft tissue profile are considered in the planning and treatment. Tooth shape and colour are equally important for providing an aesthetically harmonious appearance. The anterior region of the maxilla is not referred to as the aesthetic zone without reason. After all, it is the most striking region of the stomatognathic system and affects facial appearance.

This is why special rules apply to implant-supported single-tooth restoration in this region with regard to the choice of abutment: titanium abutments may show through translucent ceramics, lead to dark colour effects or have a negative impact on the optical effect of the papillae. In the course of time, the edge of the abutment may even become visible owing to changes in gingival profile. A number of established surgical

procedures can be employed to improve conditions for a natural appearance of the restoration, but the healing of the soft tissue plays a major role in ensuring long-term success of these measures. Ideally, primary wound healing remains the objective. Any loss of bone after tooth loss is to be compensated for with suitable augmentation techniques.

_ Case report

A 50-year-old female patient with a non-contributory medical history presented to our dental practice with complaints about tooth 21, which had been fractured in a traffic accident (Fig. 1). The X-ray showed no apical lucency in the area of the destroyed tooth (Fig. 2). Clinical examination showed a sufficient volume of attached gingiva and that the frenulum was in a physiological position. However, the vestibular soft tissue was ruptured in the area of the fractured tooth. It seemed as if the bone underneath the rupture had also been involved.

Although most of the mesial and distal papillae were in their correct position and still connected to the root cement of the neighbouring teeth, the distal papillae had receded by approxi-

Fig. 5 Determining the ideal position for the implant with an Iglhaut locator and surgical suture materials.

Fig. 6 After insertion of the XIVES plus implant, a 1 to 2 mm wide gap remains.

Fig. 7 An absorbable membrane and a connective tissue graft are placed over the implant and the filled defect.

Fig. 8 The flap is repositioned and sutured.

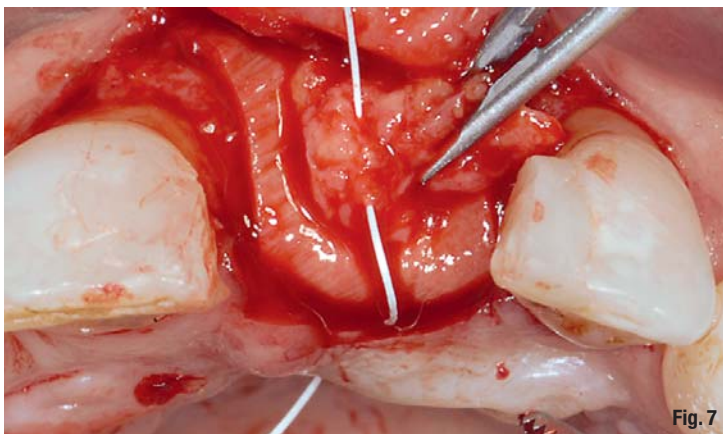


Fig. 7

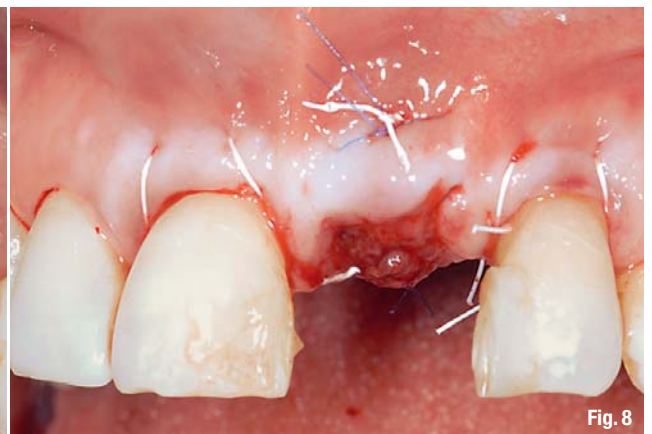


Fig. 8

Fig. 9_The X-ray after six months demonstrates good bone regeneration.

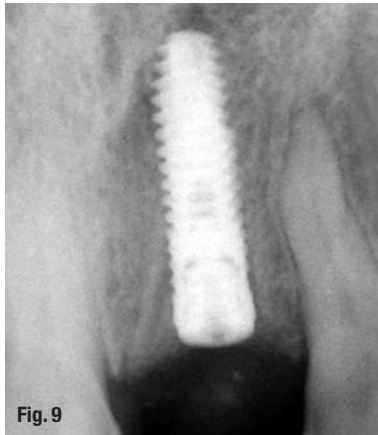
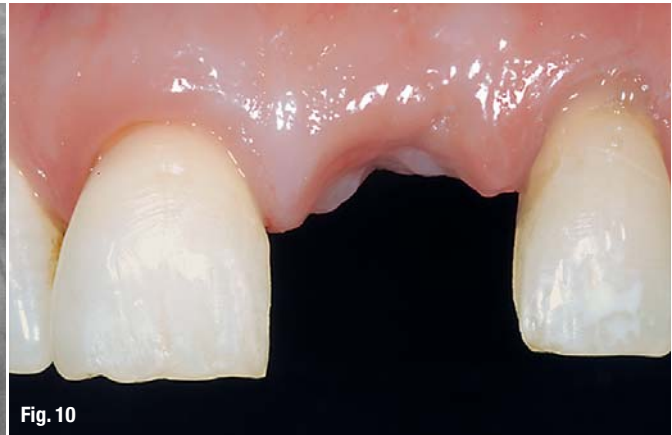

Fig. 10_The clinical situation after removing interim treatment.



mately 1 to 1.5 mm. As the length of the remaining root was insufficient for a combined endodontic–prosthetic restoration and the crown margin was to be positioned sub-gingivally to provide an optimal aesthetic result, we decided to extract the remaining part of the root and to replace it with a XiVE S plus implant (DENTSPLY Friadent).

The periodontal fibres in the root area were loosened with a scalpel. The periodontal gap was extended with a periosteal elevator and the sub-crestal fibres separated. This was the most atraumatic course of tooth extraction. Then, the extraction alveolar was carefully debrided to remove any remaining granulation tissue completely. To avoid damaging the labial bone lamella, no force was exerted in bucco-palatal direction during root extraction. The soft tissue remained undamaged by avoiding a vertical incision.

Using palatal mucosa as a free gingival graft, we ensured primary healing in the region of the extraction alveolar. This was previously measured with a periodontal probe, the corresponding trimmed graft placed over the alveolar cavity and stabilised with sutures (Fig. 3). To support the

mesial and distal papillae and to condition the tissue, a temporary crown was constructed from composite material and fixed to the neighbouring teeth as an ovate pontic (Fig. 4). Implant placement was carried out six weeks later. Immediate implant placement after tooth extraction is usual, but in this case controlled bone regeneration was also required, which made implant placement directly after extraction of the remaining root part inadvisable.

A para-crestal incision some 2 to 3 mm palatal to the alveolar ridge was carried out under local anaesthetic, and a mucoperiosteal flap was prepared using a periosteal elevator. The flap reached buccally to the muco-gingival junction. This way, the alveolar ridge could be exposed. The bone was cleared of connective tissue. The implant position was determined using a locator. In order to avoid perforation of the labial bone safely, the implant was not to be inserted directly into the alveolar socket but shifted slightly in a palatal direction.

To permit insertion of the implant within the aesthetic window, we determined the ideal bucco-palatal alignment using surgical suture materials fixed to the neighbouring teeth (Fig. 5).

Fig. 11_Uncovery of the implant with a scalpel.

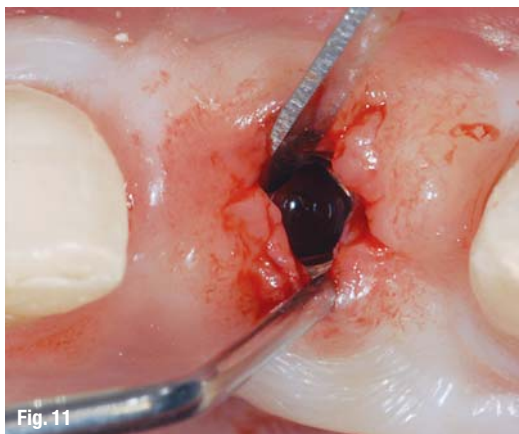


Fig. 12_The TempBase Abutment is reinserted and fitted with a TempBase Cap as temporary treatment.

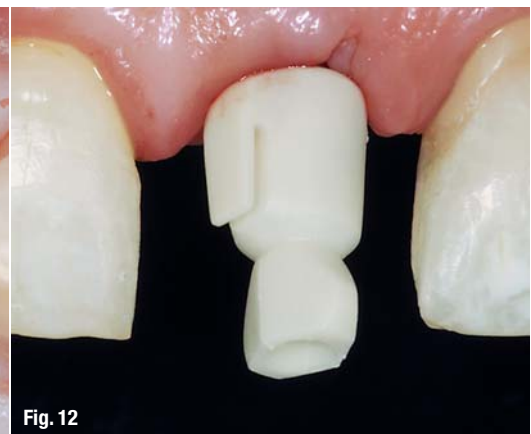

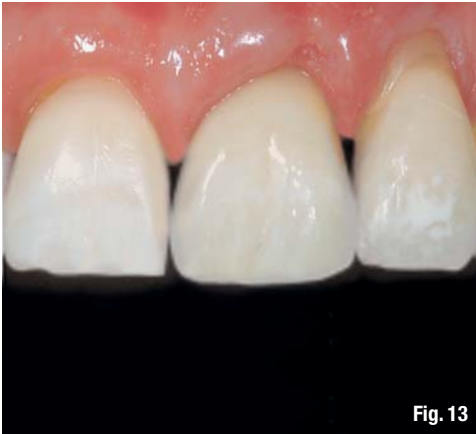


Fig. 13

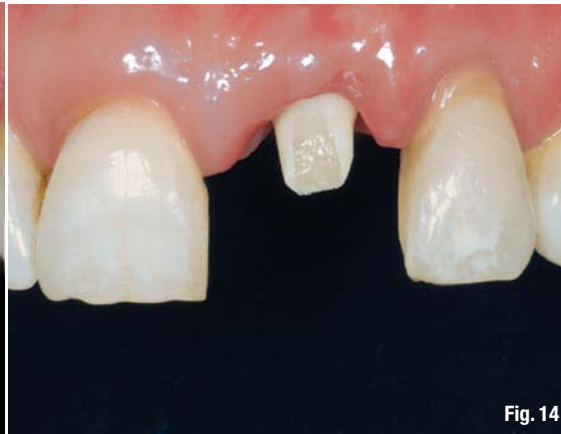

Fig. 14

Fig. 13_ The temporary crown, fabricated chairside and modified on the basis of the TempBase Cap, is pressed into position on the surrounding soft tissues.

Fig. 14_ Fitting of the laboratory-customised CERCON abutment.

This allows for adequate dimensioning of the crown on the one hand, and provides sufficient labial tissue volume on the other.

The implant site was prepared for a XiVE S plus (3.8 mm in diameter, 15 mm in length) implant. By involving the palatal cortical bone and bone-specific preparation afforded by XiVE and the condensing thread of the implant, we achieved a torque of 50 Ncm during insertion. After placing the XiVE implant in its final position, an approximately 2 mm wide gap remained to the *Lamina vestibularis* (Fig. 6). We mixed the drill cuttings collected with a bone trap, which is standard procedure, with a xenogeneic bone grafting material and filled the defect.

As a means of protection, we covered it with a correspondingly trimmed absorbable membrane. This was covered with a gingival graft from the palatal mucosa, and the flap was repositioned and sutured (absorbable sutures 4.0; Figs. 7 & 8). As during the first intervention, Amoxicillin (Augmentin 1,000 mg) was given as antibiotic cover and chlorhexidine mouthwash solution and naproxen sodium (Apranax 275 mg) to be taken as required. Healing progressed without problems.

Six months later and following successful osseointegration, uncover was done using a scalpel (Figs. 9–11). The TempBase (DENTSPLY Friadent), which was used as placement head and replaced with a cover screw after insertion, was re-inserted and temporarily restored with an appropriate chairside-modified TempBase Cap (Fig. 12). The transition between the plastic cap and the previously prepared temporary crown was filled with composite material.

During placement of the temporary crown, pressure was exerted on the underlying soft tissue and the papillae until the region became ischemic (Fig. 13). This condition needs to be reversible, and it is essential to check that the tissue regains its red colouring after a few minutes. In our experience, this method achieves proliferation of the papillae coronally. After four weeks, the temporary crown was removed and replaced with a transfer coping and the impression was made using a type I polyvinylsiloxane.

The resulting ceramic crown manufactured in the laboratory was bonded to the matching CERCON abutment (DENTSPLY Friadent) using a light-cure adhesive after try-in (Fig. 14). After

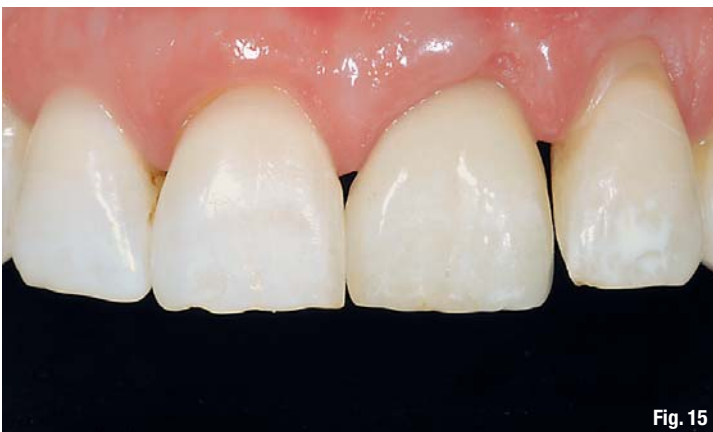

Fig. 15

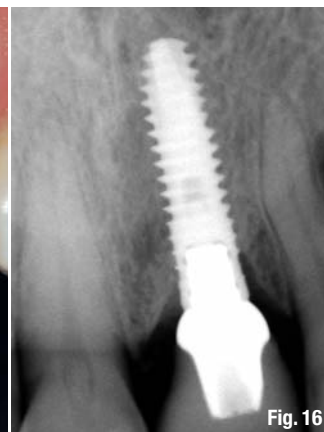


Fig. 16

Fig. 15_ Final ceramic crown *in situ* adapts harmoniously to the overall picture.

Fig. 16_ X-ray follow-up after three years demonstrates largely stable bone conditions.

three years, conditions remained stable with a pleasing aesthetic appearance (Figs. 15 & 16).

Discussion

Implants for single-tooth replacement are an important and established treatment concept. For this case, an implant was placed soon after extraction of the traumatised tooth because this appeared to be the most appropriate protocol, also with regard to the good condition of the remaining teeth. A number of investigations have found ridge atrophy during the first year of tooth loss. As a rule, atrophy commences after the third week and the *Crista alveolaris* decreases by 30 to 50 % within a year.

To protect the bone against increasing degeneration through physiological load, the implant should ideally be placed directly after tooth extraction (immediate implant placement) or after four to six weeks at the latest (delayed immediate implant placement), once soft tissue healing is complete. If the gingiva and bone are not involved, the implant can be placed immediately.

In cases in which the tooth has been lost for endodontic reasons (owing to periodontal disease or following trauma with bone and gingiva loss), augmentative procedures are usually also required. To ensure secure healing of the membranes and soft tissue grafts used for augmentation, the surgical area should be covered completely to allow primary healing. Ideally, the soft tissue is given four to six weeks to regenerate before placing the implant. Primary wound healing can be ensured by placing a free gingival graft over the extraction wound.

To provide long-term success of the implant, the endosseous part of the implant must be covered completely by bone. Here, the vestibular regions of the implants play a major role. After bone reconstruction, it is also important to cover the entire region with soft tissue. The combination of bone reconstruction and grafting with autogenous bone, which can be collected using a bone trap for example, has proven a highly practicable method for augmentation. By covering with an absorbable collagen membrane, the soft tissue is isolated from the regenerative region. In this case, as the vestibular soft tissue was of insufficient volume despite the free gingival graft, a palatal connective tissue graft was placed in addition to the augmented region. The thickness of the soft tissue affects the degree of recession. As a thick gingiva is better nourished, a connective tissue graft is often used in aesthetic regions.

In the case of single-tooth restorations, the localisation of the implant is the most important factor for achieving aesthetically pleasing reconstruction. Templates should be used for positioning. If this is not possible, the manual methods in use for years can be employed. The length of the papillae, measured with a periodontal probe, bone thickness and the vestibular lamellae are very important for long-term stable treatment. In our case, we used the Iglhaut locator because the implant was not placed directly into the alveolar socket but into a more palatal-oriented position.

We know from the literature that soft tissue is a mirror of the bone. Using a palatal connective tissue graft, a thin gingival biotype can be converted into a thick biotype. In our case, we employed an envelope technique for transplantation of the sufficiently dimensioned palatal-source mucosa graft. If the soft tissue is thick enough, it is possible to shape gingiva and papillae with temporary crowns. In addition, if there is sufficient distance to the bone, the papillae can even be extended. Pressure is exerted on the papillae to profile them in the direction of the crown. Sufficient connective tissue thickness prevents the showing through of titanium, but a darker discolouration is definitely avoided by using zirconium dioxide abutments.

Summary

Additional bone and soft tissue constructions are usually necessary to provide a long-term appealing reconstruction with single implants in the aesthetic zone, and localisation of the implant must be planned accurately. The implant should be placed as soon as possible after tooth loss. Zirconium dioxide is a proven material for abutments.

Editorial note: This article was first published in IDENTITY 2/11. A complete list of references is available from the author.

Contact

cosmetic
dentistry



Dr Ata Anil

Ardent Dental Clinic
Teşvikiye Cad. 49/10
34365 Nişantaşı
Istanbul
Turkey

ataanil@ar-dent.com
www.ar-dent.com

IPS e.max[®]

**“THAT’S ALL
I NEED!”**

Galip Gürel, Dentist, Turkey.

Many different indications and many different materials to choose from – this scenario is a thing of the past. The IPS e.max system allows you to solve all your all-ceramic cases, from thin veneers to 12-unit bridges. Dental professionals all over the world are delighted.

all ceramic
all you need



www.ivoclarvivadent.com

Ivoclar Vivadent AG

Bendererstr. 2 | FL-9494 Schaan | Principality of Liechtenstein | Tel.: +423 / 235 35 35 | Fax: +423 / 235 33 60

ivoclar
vivadent[®]
passion vision innovation