

Flapless implant surgery and its effect on peri-implant soft tissue

A prospective longitudinal clinical study

Authors _ Dr Kai Höckl, Prof Peter Stoll, Dr Georg Bach, Prof Wolfgang Bähr & Verena Stoll, Germany

Abstract

Background and aim

Minimally invasive implant insertion may offer the reduction of peri-implant inflammation, pocket depth and crestal bone loss, as well as minimisation of post-surgical complications. The goal of the present study was to clinically investigate the soft-tissue response and to compare the outcome obtained with flapless, placed implants of three different manufacturers.

Materials and methods

In this clinical study, 346 implants inserted in 115 patients between January 2001 and February 2009 were examined. A total of 337 two-piece titanium (235 Straumann and 102 Thommen) and nine one-piece zirconium-dioxide implants (Z-Systems) were used. The patient sample included seven smokers, two patients with diabetes mellitus, seven patients

with bleeding disorders and one patient undergoing intravenous bisphosphonate therapy. Regular clinical examination of stability and peri-implant soft-tissue status was performed one, two, three, four and 16 weeks after implant insertion.

All implants were loaded for at least 12 months with either fixed or removable prosthetic restorations. Attachment level, bleeding on probing (BOP), secretion, plaque and keratinised gingiva were documented.

Results

After loading, one of the 347 implants was lost. The survival rate of the Straumann implants ($n = 235$) was 99.6%, that of the Thommen implants ($n = 102$) was 100% and that of the Z-Systems implants ($n = 9$) was 100%. Thus, the general survival rate was 99.9% after a mean follow-up period of three years and eight months.

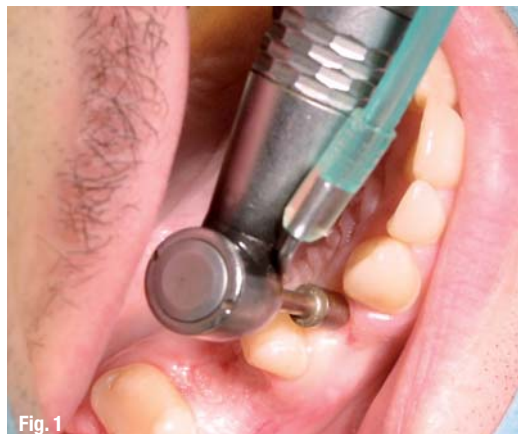

Fig. 1 _ Tissue punch to expose the alveolar crest.

Fig. 2 _ Start of the drill sequence with the rose drill.

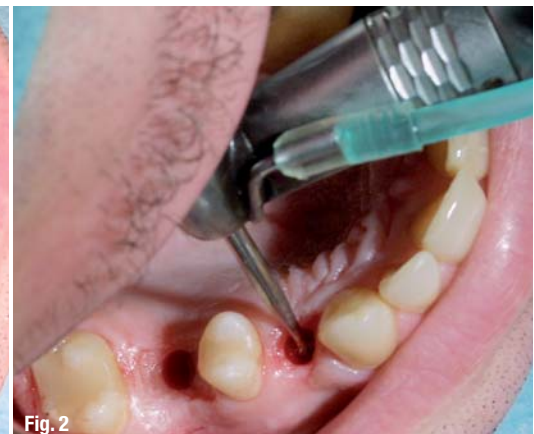

Fig. 2

CHEAPLY IMPLANTS
BETTER IMPLANTS
AS IHDE DENTAL



SAY IT TO ALL!

www.banal-implants.de

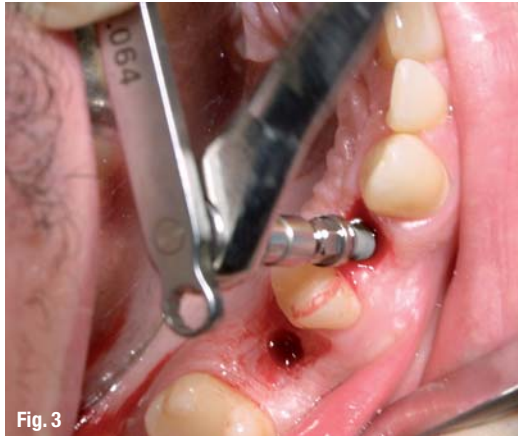

Fig. 3

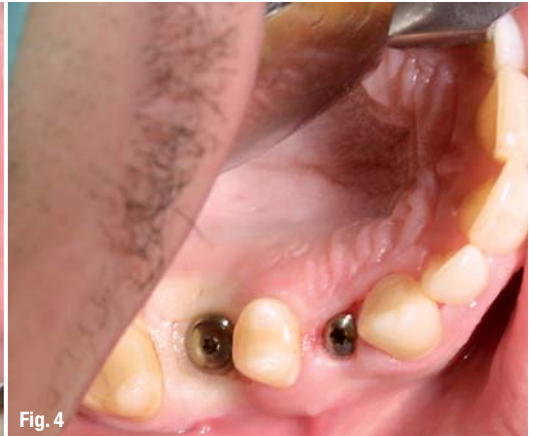

Fig. 4

Fig. 3_Flapless implant insertion.

Fig. 4_Immediately after implant insertion.

A positive bleeding score (BOP) was found at 106 of the 346 implant sites (30.63%). A significant difference was documented between Straumann implants, where bleeding occurred only in 14.9%, and Thommen implants, where a positive bleeding score was found in 38.2%.

No differences between the three implant types were found in terms of probing depth (PD). The mean PD was 2.4 mm irrespective of the implant design. Bleeding score was significantly higher for those implants without keratinised mucosa. Of the Straumann implants, 161 were surrounded by a band of keratinised tissue, as were 74 Thommen implants. Only 38 Straumann (26.4%) and 22 Thommen (30.6%) implants showed positive BOP. Eight of the nine Z-Systems implants were placed in keratinised mucosa and none of them showed any signs of inflammation.

Conclusions and clinical implications

The results presented in this article demonstrate that healthy peri-implant soft tissue can be obtained following minimally invasive surgery and transgingivally placed implants. Flapless implant insertion shows a success rate comparable to conventional implant surgery. The results of this study prove that flapless implant surgery is a predictable procedure. In addition, our findings lead to the conclusion that a band of keratinised gingival tissue around implants minimises soft-tissue bleeding.

Introduction

In conventional implant surgery, more or less extensive flaps are created to expose the surgical field. Since the beginnings of implantology, the technique has been gradually modified and refined to the one- or two-stage procedures most frequently used today. Despite these modifications, the surgical process has remained remarkably constant. After exposure of the jaw bone by preparing a mucoperiosteal flap, the implant is inserted into a cavity cre-

ated by careful bone drilling. Thereafter, the covering soft tissue is sutured to its previous place (Adell *et al.* 1985).

Initial bone loss seems to be caused by interrupted blood supply that follows removal of the periosteum (Ramfjord & Costich 1968; Wood *et al.* 1972; Kleinheinz *et al.* 2005). Flapless procedures utilise only a small soft-tissue punch to expose the alveolar crest (Fig. 1). The size of the surgical field corresponds therefore to the implant diameter.

The term "minimally invasive" or "flapless" implant surgery describes an alternative procedure to conventional incision and flap preparation (Figs. 2–4; Sclar 2007). In addition, this atraumatic approach allows good preservation of the anatomically important gingival and periodontal structures (Al-Ansari & Morris 1998; Zetz & Qureshy 2000; Kan *et al.* 2000). Flapless surgery is becoming increasingly popular and patient acceptance of this procedure is very high. The limited surgical trauma minimises: (a) intra-operative bleeding; (b) surgical time; (c) risk of infection; and (d) post-surgical complaints such as swelling and pain related to the surgical trauma. In many cases, second-stage surgery, i.e. measures to expose the implant shoulder, can be avoided (Stoll 2008). Flapless surgery may help to avoid significant bone loss. The tissue punch used has a diameter similar to that of the inserted implant. Animal studies have demonstrated the importance of the punch diameter. A punch diameter that is minimally smaller than the implant diameter had a positive effect on healing (Lee *et al.* 2009).

It is well known that conventional surgical procedures using titanium screw implants result in very successful long-term survival rates of 94 to 99% (Adell *et al.* 1985; Behneke *et al.* 2000; Cochran *et al.* 2002; Roos-Jansaker *et al.* 2006). This longitudinal study aimed to determine whether flapless, i.e. transgingival, minimally invasive, implant placement can lead to a success rate comparable to con-

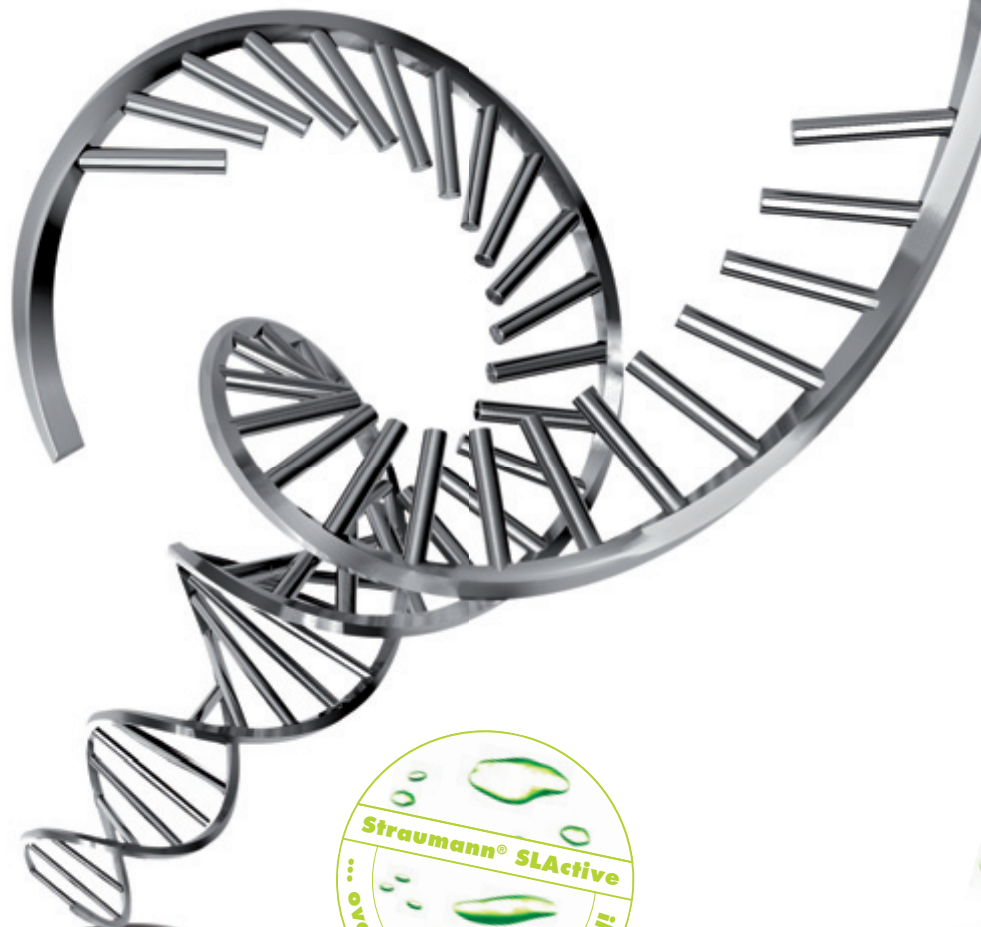


ROXOLID®

THE NEW "DNA" OF IMPLANT MATERIALS

ROXOLID® – Exclusively designed to meet the needs of dental implantologists.

Roxolid® offers ■ Confidence when placing small diameter implants ■ Flexibility of having more treatment options ■ Designed to increase patients' acceptance of implant treatment



Please contact us at **+41 (0)61 965 11 11**. More information on www.straumann.com

COMMITTED TO
SIMPLY DOING MORE
FOR DENTAL PROFESSIONALS

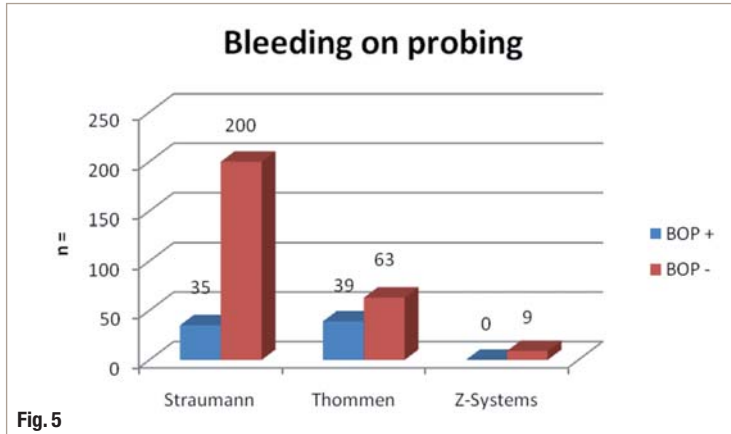


Fig. 5 Bleeding on probing.

ventional insertion. The clinical performance of dental implants with different design (two types of titanium two-piece implants with different machined collar height and zirconium-oxide one-piece implants) and from different manufacturers was compared. Soft tissue health was evaluated in particular. The relationship of keratinised mucosa and the health status of peri-implant soft tissue was analysed.

_Materials and methods

In this study, 347 implants inserted between January 2001 and February 2009 were evaluated. All were placed by one surgeon using the flapless surgical protocol. The patients were recruited from the six months resp. one-year recall programme.

For the purposes of the clinical longitudinal study, 115 (67 female and 48 male) patients with a mean age of 63 (18 to 85) were followed up. They received a total of 347 implants: 236 Straumann, 102 Thommen and nine Z-Systems. The patient sample included seven smokers, two patients with diabetes (receiving oral antidiabetics), seven patients with hemorrhagic diathesis (receiving oral anti-coagulants) and one patient with intravenous bisphosphonate therapy. Patients were excluded

Fig. 6 Probing depth PD distribution.

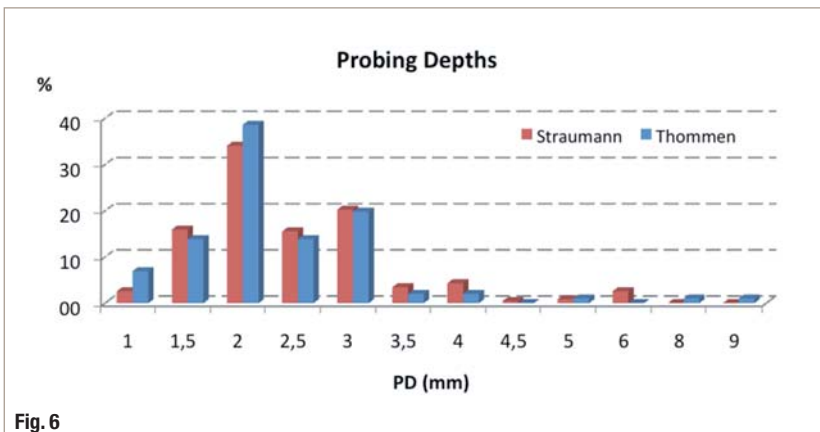


Fig. 6

from the study if they showed severe general medical contra-indications. Patients elected received one shot of standard prophylactic antibiotics (penicillin 1 Mio IU or clindamycin 600 mg p.o.) one hour before surgery. The implant bed was prepared according to the recommendations and instrumentation of each manufacturer.

Straumann (Standard and Standard+) and Thommen Medical (ELEMENT and CONTACT) titanium two-piece implants, and Z-Systems zirconium-dioxide one-piece implants (Z-Look3) were used. The implants used had a platform diameter of 3.5 to 6.5 mm (Straumann: 3.5 mm, 4.8 mm and 6.5 mm; Thommen: 3.5 mm, 4 mm, 4.5 mm and 5 mm; Z-Systems: 5 mm and 6 mm). The soft-tissue punches used in this study showed a diameter of 4 or 5 mm.

Post-operative clinical examination of stability and peri-implant soft tissue was performed one, two, three, four and 16 weeks after implant insertion. Radiological examination was done before and immediately after implant surgery, after osseointegration and one year after prosthetic loading. All implants were loaded for at least 12 months with either fixed or removable prosthetic restorations.

Mouth hygiene was assessed visually and classified into four categories: very good (no plaque, no tartar), good (little plaque, little tartar), medium (some plaque, some tartar) and poor (excessive plaque, excessive tartar). The presence or absence of keratinised gingiva was also recorded.

The gingival depth resp. thickness around the implant neck was measured with a calibrated probe. The measurement was done with slight pressure exerted from the gingival margin until resistance was encountered. For implants, as opposed to natural teeth, an increased pocket depth of up to 4 mm is acceptable without further measurements (Behneke *et al.* 1997). This is due to the parallel orientation of the connective tissue fibres. Bleeding on probing and pathological secretion were recorded. Selected results were tested by means of the Wilcoxon U test (NPAR1WAY procedure, SAS Ver. 9.1.3.) for non-normally distributed data. Significance was assumed if $p < 0.05$ ($\alpha = 5\%$). The number of tests was limited to minimise the probability of false-positive results.

_Results

The 3.75 (0.25–9.7) year follow-up period of all implants showed only one failed (explanted) implant (Straumann). This was due to peri-implant in-



4TH INTERNATIONAL

CAMLOG CONGRESS

MAY 3RD – 5TH, 2012

LUCERNE, SWITZERLAND



FEEL THE PULSE OF SCIENCE IN THE HEART OF SWITZERLAND

- "State of the art" in implant dentistry
- Internationally renowned scientific committee, well-known speakers
- First-class workshops
- Lucerne – world-famous congress venue
- Groovy party – "Let's rock the Alps!"
- Attractive partner programs in Lucerne and surroundings
- Excellent price-performance ratio

SCIENTIFIC COMMITTEE

Prof Jürgen Becker, Prof Fernando Guerra, Prof Frank Schwarz,
Prof Thomas Taylor, Prof Hendrik Terheyden,
Prof Georg Watzek, Prof Axel Zöllner



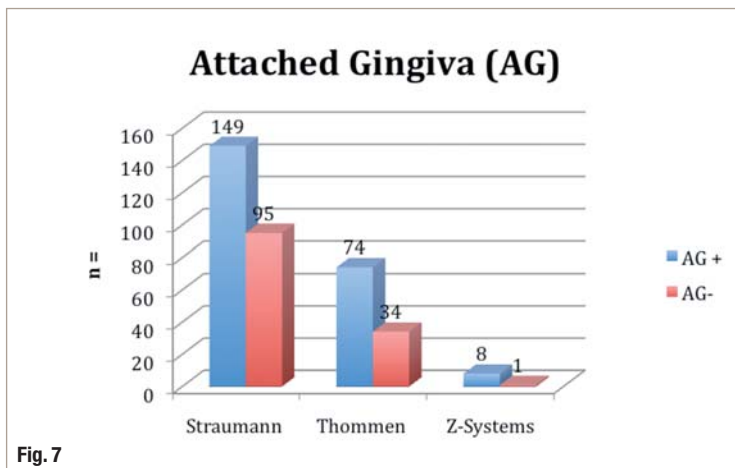


Fig. 7

Fig. 7_ Attached gingiva. fection and reduced stability. The resulting overall survival rate was 99.7%. Of the 236 Straumann implants, 235 were clinically controlled with a mean follow-up period of 5.4 (0.75–8) years. The corresponding survival rate for Straumann implants was therefore 99.6%. The mean follow-up period for the 102 Thommen implants was two (0.25–9.7) years. No Thommen implant had failed when this article was written. In this subgroup, one case of bisphosphonate-related osteonecrosis of the jaw (ONJ) was discovered, surprisingly, at the final follow-up. The two implants were retained following local and antibiotic treatment, i.e. were deemed survivors. None of the Z-Systems implants failed during the mean follow-up period of two (0.8–3.8) years.

Sulcus bleeding on careful probing was observed in 19% of the implants ($n = 67$). With regard to the different manufacturers, BOP was observed in 14.9% of the Straumann implants ($n = 35$) and in 38.2% of the Thommen implants ($n = 32$). The difference was statistically significant (Fisher's ex-

Fig. 8_ Bleeding on probing for implants with AG.

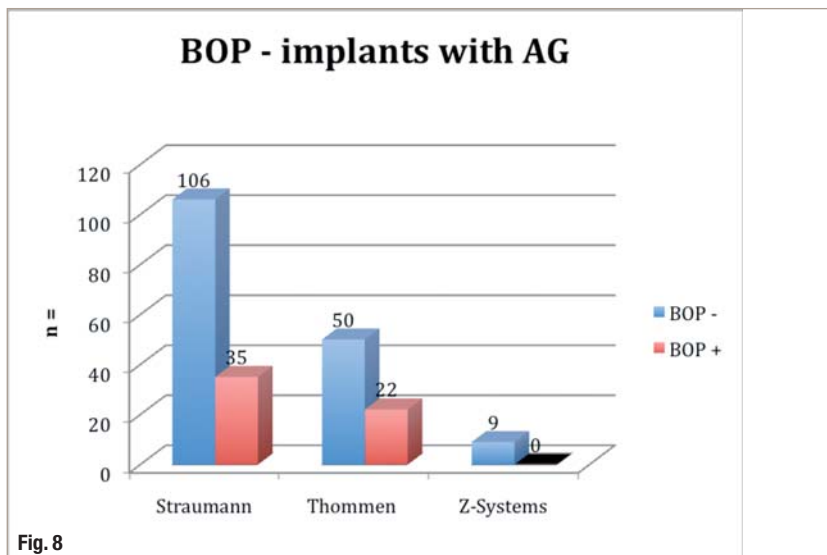


Fig. 8

act test, $p < 0.05$). None of the nine Z-Systems implants showed BOP (Fig. 5). The evaluation revealed 89% of implants ($n = 308$) with a PD of between 1 and 3 mm. A PD of 4 to 6 mm was found in 10% of implants ($n = 34$). (The PD value distribution for Straumann and Thommen implants is shown in Fig. 6.) Only one female patient with a PD of 8 mm and 9 mm was documented (ONJ). No differences were found in PD between the three implant types. The mean PD of all 346 implants was 2.4 mm irrespective of the implant design.

Of all implants, 70% ($n = 244$) were surrounded by keratinised, attached gingiva (AG). This was the case for 68.5% of the Straumann implants ($n = 161$), 72.5% of the Thommen implants ($n = 74$) and 89% of the Z-Systems implants ($n = 8$; Fig. 7).

Based on the results observed, an attempt was made to establish a correlation between:

1. AG and BOP; and
2. AG and PD.

Attached gingiva and bleeding on probing

The influence of soft tissue on peri-implant health is not conclusively elucidated. Of the 346 implants studied, 244 were surrounded by AG and only 27.9% ($n = 68$) of these exhibited BOP. Of the 236 Straumann implants, 161 were surrounded by AG and 26.4% ($n = 38$) of these were BOP positive. Of the 102 Thommen implants, 74 were surrounded by AG and 30.6% ($n = 22$) of these were deemed BOP positive. Of the nine Z-Systems implants, eight were surrounded by AG and all of them were BOP negative (Fig. 8). The difference in the number of patients with AG and positive BOP between Straumann and Thommen implants was statistically significant ($p < 0.05$; 26.4 compared with 30.3%). Also the converse relationship, i.e. the correlation between the absence of AG and positive BOP, was also evaluated. This was found in 67.9% of the Straumann implants ($n = 38$), compared with 64.7% of the Thommen implants ($n = 22$). The difference was statistically significant ($p < 0.05$).

Attached gingiva and probing depth

The mean PD for the 244 implants surrounded by AG was 2.4 (± 0.9) mm. The 102 implants without AG had an identical PD of 2.4 (± 0.7) mm. A statistically non-significant trend was seen in the Thommen implants. The 74 Thommen implants surrounded by AG showed a PD of 2.2 (± 1.1) mm, whereas the 34 implants without AG showed a mean PD of 2.8 (± 1.4) mm. The eight Z-Systems implants surrounded by AG had a mean PD of 1.5 mm. The single implant without AG had a PD of 2 mm (Fig. 9).

ADVANCED TISSUE-MANAGEMENT

The easy way to aesthetics.

PARASORB Sombrero®

RESODONT®

PARASORB® HD Cone

GENTA-COLL® HD Cone



RESODONT®

- ▶ naturally cross-linked, with no chemical additives
- ▶ quick and easy to cut to size and apply, both sides can be used
- ▶ rapid integration in the surrounding tissue
- ▶ highest degree of product safety and excellent biocompatibility

PARASORB Sombrero®

- ▶ to cover and simultaneously fill the alveolus (socket preservation)
- ▶ offers a defined regeneration matrix
- ▶ formation of a stable bony implant bed after a relatively short time
- ▶ improved long-term aesthetic and functional results particularly in the anterior region

PARASORB® HD Cone GENTA-COLL® HD Cone

- ▶ rapid and safe haemostasis
- ▶ reduction of alveolar ridge atrophy
- ▶ optionally comes with antibiotic protection for high-risk patients (e.g. diabetics, smokers, immune-suppressed patients)

_Discussion

The study aimed to assess the long-term clinical outcome of minimally invasive, flapless surgery with a particular focus on the peri-implant soft tissue. This longitudinal study investigated whether, with respect to soft tissue, it is possible to obtain results comparable to or even better than the standard, more invasive, flap surgery. To date, there is only a limited number of such studies. Three different implant designs were compared. Ample evidence is available documenting the long-term implant survival rate of >90% after five years with classical, trapezoidal flap surgery (Behneke *et al.* 2000; Mericske-Stern *et al.* 2001; Romeo *et al.* 2002).

Surprisingly, there is limited information on the long-term outcome of the flapless surgical protocol. Until now, published papers have reported the outcome only up to 18 months (Brodala, 2009). In a multicentre clinical study, Becker *et al.* (2009) evaluated 57 patients. They demonstrated that the results are similar to those obtained with the conventional flap protocol. After five years, 37 of these patients were followed up and the survival rate remained as high as 98.7%. This is comparable to the result obtained in the present study, with a slightly longer than average follow-up time of three to four (maximum of 9.7) years and 99.6% of surviving and fully functional implants at the time of the last follow-up.

The predictability of transgingival healing following flap preparation has been extensively investigated. Numerous studies concluded that there is no difference between implants that healed in submerged or open fashion (Ericsson *et al.* 1997; Buser *et al.* 1990, 1999; Abrahamsson *et al.* 1999; Weber *et al.* 2000). For flapless surgery, despite a modification of the surgical approach, osseointegration can be achieved in a predictable way (Campelo & Camara 2002; Sclar 2007; De Bruyn *et al.* 2009; Jeong *et al.*

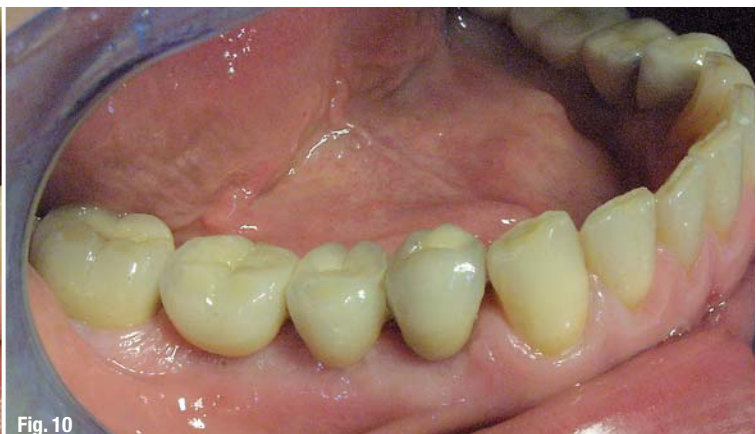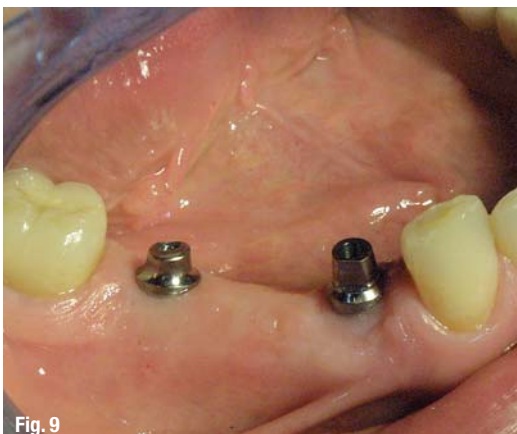2007, 2010; Rousseau 2010). Concerns of a higher failure rate, caused by the inevitable contamination of the sterile implant surface by oral bacterial flora, were not confirmed. The results of an animal study proved that contamination of the soft tissue before surgery has no negative impact on implant osseointegration (Ivanoff *et al.* 1986). Adherence to aseptic conditions during surgery nevertheless remains an important implantation success factor (Adell *et al.* 1985; Sennerby & Lekholm 1993).

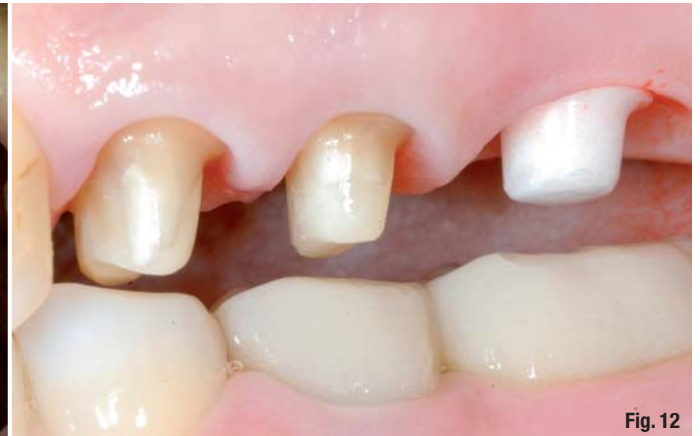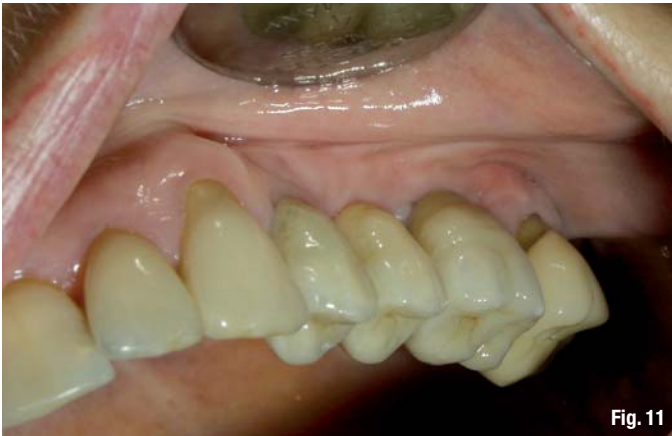Recently, in a controlled retrospective study Rousseau (2010) was able to demonstrate that in the correct indication range the success of minimally invasive transgingival implantation is the same as that of the classical protocol: minimally invasive, 98.3%; conventional, 98.5%. Nevertheless investigations of the peri-implant soft tissue following minimally invasive surgery are rare: 24, 44 and 241 patients have been followed up over a period of four to 12 months (Oh *et al.* 2006; Lee *et al.* 2009; Jeong *et al.* 2010, respectively).

The influence of keratinised peri-implant AG on the occurrence of peri-implant inflammation is still a controversial issue (Marquez 2004). In this study, a relationship between AG and implant survival was not established. We analysed the PD and BOP clinical parameters, which can be measured in a practice setting with reasonable technical equipment. This comparison should allow the assessment of peri-implant tissue health. An animal study demonstrated that missing AG resulted in significantly increased recession and slightly higher attachment loss (Warrer *et al.* 1995). This result implied that the absence of AG around implants increases plaque-induced tissue damage. The implication was validated in a clinical study (Bouri *et al.* 2008) of 2008 implants, which remained in situ for at least 12 months. The presence of at least 2 mm of AG was accompanied by minimal alveolar bone loss and improvement of indices that describe peri-implant tissue health. The same study demonstrated that in the

Fig. 9 Correlation of AG with PD.

Fig. 10 Peri-implant soft tissue before insertion of fixed prosthetic restoration (Straumann).





control group the implants with less than 2 mm of AG had significantly increased BOP frequency. In addition, radiographic examination showed a higher average bone loss when AG was not sufficient. These results however have to be viewed with caution: Meijer *et al.* (1992) stated that the resolution of conventional X-ray is limited and minimal changes in the marginal bone will often not be recognised. This was confirmed in an animal experiment (Caulier *et al.* 1997). Current 3-D imaging techniques such as CT or DVT (digital volume tomography) offer an improved picture of the peri-implant bone quality (Mengel *et al.* 2006). However, legal considerations prohibit a more frequent X-ray follow-up.

In a study of 26 patients, Krekeler *et al.* (1983) found that the presence of AG improved gingiva's sensitivity to inflammation caused by mechanical irritation. It seems therefore likely that AG is advantageous for the health of the peri-implant tissue but it is not a prerequisite condition. According to the authors, plaque control is the most important factor for the absence of peri-implant inflammation. A further study provided contradictory results. This clinical study found a correlation between AG and the incidence of mucositis (Roo-Jansaker *et al.* 2006). The authors reasoned that implants without keratinised tissue have a tendency to gingiva recession and therefore less peri-implant pockets will be found. This was confirmed by Chung *et al.* (2006) in a retrospective multicentre study of 69 patients with 339 implants. In this study, the appearance of plaque and peri-implant lesions was significantly increased around implants with AG. Unfortunately, this was not confirmed in further clinical studies. It was shown that neither the presence or the width of keratinised mucosa, nor the mucosal border mobility had an influence on plaque control or on the inflammatory status of the peri-implant tissue (Block *et al.* 1990; Strub *et al.* 1991; Wennström *et al.* 1994; Hanisch *et al.* 1997; Cairo *et al.* 2008). According to Wennström *et al.* (1994), there was no negative ef-

fect of keratinised tissue on bleeding behaviour or plaque control, although 61% of the implants showed no peri-implant AG.

The latter findings are in line with the results presented in this article. Of the 346 implants, 244 were surrounded by keratinised tissue. Our findings confirmed that less BOP is found in the presence of AG. This is independent of the implant type used (zirconium-oxide or titanium) and design (one or two piece). We therefore conclude that in the presence of keratinised alveolar mucosa, susceptibility to peri-implant inflammation is reduced. This was also the conclusion of a recent multicentre study (Eccelente *et al.* 2010), but the finding must be treated with caution. Recently, it was also demonstrated histologically that peri-implant inflammation can be found even in the absence of clinical signs (Nahas *et al.* 2010). In a human study, the authors investigated 12 samples obtained at implant uncovering (second-stage surgery). The presence of chronic, inflamed peri-implant infiltrates was shown in the absence of clinical symptoms.

In this study, only 26.2% of Straumann and 31.9% of Thommen implants displayed BOP (the difference was not significant). Only one of the eight Z-Systems implants was BOP positive. No conclusion is possible based on this small number of implants. It seems likely nevertheless that the soft-tissue integration of zirconium-oxide implants is as good, if not better, as suggested by Blaschke and Volz (2006).

It is known that AG has a positive impact on peri-implant health (Krekeler *et al.* 1983; Warrer *et al.* 1995; Bouri *et al.* 2008; Adibrad *et al.* 2009). In a meta-analysis of the role of local risk factors in implantology, no relationship was found between the presence of keratinised mucosa and implant survival (Martin *et al.* 2009). Our results demonstrate that the presence of keratinised gingiva around implants may lead to less peri-implant inflammation and has no immediate effect on implant survival.

Fig. 11 Peri-implant soft tissue with restoration inserted.

Fig. 12 Peri-implant soft tissue with restoration inserted (Thommen Element).

Furthermore, the clinically measurable PD was analysed, thus allowing conclusions concerning the inflammatory status of the peri-implant tissue (Shou *et al.* 2002). The PD measurement is one of the most important parameters for clinical characterisation of the implant condition (Behneke *et al.* 2002). It is of central importance also because of the similarity of the tissues surrounding teeth and implants. The value measured is related to marginal bone loss (Quiryren & Listgarten 1990). For natural dentition, a PD of 1 to 3 mm is considered to be physiological, though around implants the healthy or pathological values vary. A PD of 1.5 to 3.5 mm was found to be optimal by Behneke *et al.* (1997). The values found in our study are significantly different. Although the mean PD was not influenced by the presence of AG in the case of Straumann implants, i.e. PD remained constant at 2.4 mm, for Thommen implants a significant difference was found. It needs to be emphasised that the polished collar height of the Straumann implants used was 1.8 mm (Standard+) and 2.8 mm (Standard), whereas for Thommen implants this was 1.5 mm (CONTACT) and 1 mm (ELEMENT). One can only speculate that the polished collar of 1.8 mm and 2.8 mm together with keratinised AG may lead to a reduced PD and also slightly higher BOP. On the other hand, shorter polished collars are preferred prosthetically because in the long-term they lead to an aesthetically more favourable outcome. The analysis presented has also shown that in the presence of keratinised gingiva, minimally invasive transgingival implantation led to stable implant integration with respect to soft tissue.

The PD values measured in this study (overall mean of 2.4 mm) are comparable to published results. A PD of 2.2 mm that remained constant over four years was reported (Becker *et al.* 2009). This value seems reasonable when considering the anatomical parodontal structures. Similar to natural teeth, biological width is formed around implants too. This begins at the implant–abutment interface and ends, as with natural teeth, at the limbus alveo-

laris (Buser *et al.* 1989, 1992; Ericsson *et al.* 1996; Cochran *et al.* 1997; Hermann *et al.* 1997; Abrahamsson *et al.* 1997; Kohal *et al.* 1999; Hermann *et al.* 2000). It is known from animal studies that the dimensions of biological width are similar around implants and natural teeth (Buser *et al.* 1989, 1992; Cochran *et al.* 1997; Ericsson *et al.* 1995). The height of the implant–mucosal complex is 3 to 4.8 mm and the dimensions of its components seem to vary more around implants than around teeth (Berglundh *et al.* 1991; Hermann *et al.* 2000). Our results confirm these findings; the most frequent PD values were 2 and 3 mm. This corresponds well with the published biological width (Berglundh *et al.* 1991; Weber *et al.* 1996). The consequence of frequent abutment replacement was a more apically attached connective tissue and increased incidence of marginal bone loss (Abrahamsson *et al.* 1997, 2003). Transgingival healing with immediate restoration of the implants helps to reduce the frequency of abutment changes; it may hence lead to more stable bone levels.

As mentioned above, one female patient had a PD of 8 and 9 mm with pus secretion. This occurred in the presence of a symptomatic bisphosphonate-related ONJ at already osseointegrated and restored implants. The patient had been taking Zolendrate for three years as an adjuvant therapy for mammary carcinoma. She did not report this and it was only revealed by inquiry of her oncologist. The infection resolved after systemic antibiotics and careful local treatment. To date, the implants are in situ and symptom free.

Following minimally invasive insertion of titanium implants, in most cases healthy peri-implant tissue was found in this study. BOP was seen for only 14.9% of Straumann implants, compared with 38.2% of Thommen implants. This difference may be explained by the higher polished collar of Straumann (2.8 mm and 1.8 mm) in comparison with Thommen implants (1.5 mm and 1 mm). In the same way as PD, this finding can be related to the height of the mucosal implant complex. Histological investigation (not feasible within the scope of this study) would be needed to confirm this assumption.

The influence of the micro-gap (50–100 µm for most commercial implant systems) between the implant and its abutment (or secondary prosthetic parts) is controversial. The micro-gap can be populated by bacteria and thereby affect both the peri-implant bone loss and the peri-implant soft tissue (Scarano *et al.* 2005). Clinical studies that compared one- and two-piece implants have found significantly more inflamed sites around two-piece than around one-piece implant systems (Broggini *et al.* 2003). Such a trend was also confirmed in this study.

Fig. 13 Peri-implant soft tissue before prosthetic restoration (Z-Look3).

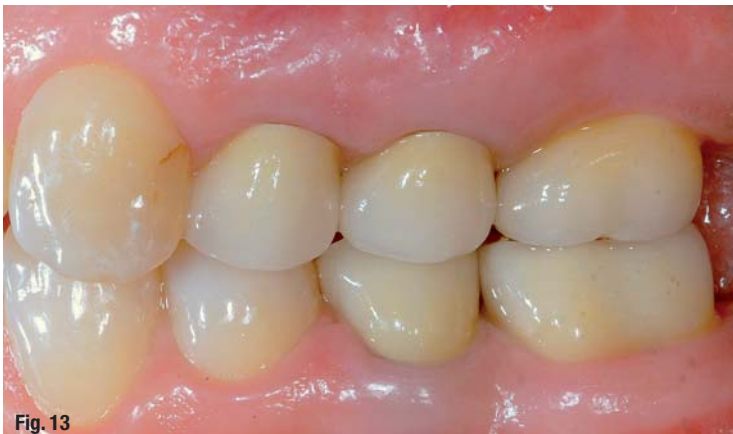

Fig. 13

The presence of BOP is considered to be a readily available parameter that reflects peri-implant health (Heitz-Mayfield 2008). Its clinical importance is not always equivocal and should be assessed cautiously in relation to additional parameters. The presence of BOP is generally considered to be a symptom of inflammation; nevertheless, the complete opposite was also found. Lang *et al.* (1990) in their thorough study demonstrated that the absence of BOP is only clinically meaningful if found in several consecutive measurements, i.e. negative prediction value of 98%. The presence of BOP had no clinical relevance (positive prediction value of 6%). The negative prediction value appears to be true in implantology too (Lang *et al.* 1994; Becker & Gansky 2007). To confirm a peri-implant inflammation, measurement of matrix metalloproteinase activity (MMP-8/collagenase-2) would be necessary. Ma *et al.* (2000) and Xu *et al.* (2008) have shown that this enzyme activity allows distinction between diseased and healthy tissues.

_ Conclusion

In addition to peri-implant soft-tissue preservation, minimally invasive implantation offers important advantages. This is particularly true for elderly, medically compromised patients, who typically present with limited bone availability and/or poor bone quality in addition to congenital or anti-coagulant-induced bleeding diathesis, as well as general medical contra-indications that make larger augmentative intervention quite challenging. In these patients, excellent results can be obtained using a minimally invasive, transgingival approach and patient chewing comfort can be improved dramatically. As only the soft tissue the size of the implant diameter will be excised, the implant acts as a tamponade that may effectively diminish bleeding from the bone and soft tissue.

In early stages, the flapless technique was recommended to inexperienced surgeons. It soon became clear that this type of surgery is technically very sensitive. Achieving success requires a much higher level of clinical experience than originally thought. Van de Velde *et al.* (2008) found no relationship between surgical experience and precision using synthetic models. This finding has to be viewed with criticism because a successful minimally invasive surgery depends to a large extent on the correct assessment of the anatomical situation and this skill can be only obtained through long-term clinical experience. False assessment of the anatomic conditions may lead to bone perforation or false implant position. These severe complications can only be avoided through long-term implantological practice.

Dental implantology has changed with the introduction of combined X-ray and DVT machines and easy access to CT. Prospective planning and the feasibility of 3-D implant site evaluation have led to increased popularity of minimally invasive implantology (Sclar 2007). Promising results were reported by recent studies that tested the transfer accuracy of planning with drilling templates manufactured using various methods (Van Assche *et al.* 2010; Danza & Carinci 2010; Lomzynski & Mierzwinska-Nastalska 2010; Neugebauer *et al.* 2010). The number of patients treated using minimally invasive methods will undoubtedly increase in future. Thanks to exact planning before surgery and data transfer to suitable templates, patients will have access to high quality solutions with minimal surgical intervention. In the hands of inexperienced dentists, who would blindly rely on planning with templates, planning error when doing computer-assisted implantology may lead to disastrous results (Van Assche *et al.* 2010; Stoll 2010).

Flapless implant insertion in this study demonstrated a success rate comparable to conventional implant surgery. Our results are congruent with the recently published recommendations of the ITI Consensus Conference in September 2010 (Weber *et al.* 2010). The presented results demonstrated that flapless implant surgery is a predictable procedure. It has the advantages of preserving mucosal health around dental implants. The statistically higher rate of bleeding around Thommen implants is possibly associated with the shorter polished collar. The low positive prediction value of BOP must not be forgotten. Overall good peri-implant soft-tissue health conditions were found around all three implant types (Figs. 10–15). This study has confirmed that a band of keratinised gingival tissue around implants is not absolutely necessary but can minimise soft-tissue inflammation.

Editorial note: A list of references is available from the publisher.

_contact

implants

Dr Kai Höckl

c/o KOSMedics Private Hospital for Aesthetic Surgery and Laser Medicine, Prof Stoll & Partner

Wilhelmstr. 3
79098 Freiburg/Breisgau
Germany

kai.hoeckl@web.de