

Smile enhancement with laser technology— Predictable and esthetic

A case report

Author_Dr Hugh Flax, USA



Fig. 1 _ Visualizing the entire oral-facial composition helps to diagnose less harmonious features of the smile.

_Introduction

With the esthetic zone being absolutely critical to a patient's external appearance and inner emotions, orchestrating a bioesthetic result is mandatory. Too often, this is complicated when esthetic desires infringe on the health of the periodontal complex. This is often true when biologic width violations have occurred iatrogenically. Many factors may contribute to these failures, the two main culprits being intracrevicular margin location and overcontoured restorations. Not only is plaque accumulation problematic, but the

supracrestal fibers also become interrupted, causing the tissues to become further inflamed and esthetically unmanageable. Kois' landmark study defined the total dentogingival complex (DGC) as clinically predictable at 3.0 mm on the direct facial aspect, and at 3.0–5.0 mm interproximally when measured from the free gingival margin to the osseous crest. It is critical anteriorly that the gingival margin mimics the osseous scallop while maintaining the DGC.¹ Further complicating these complex situations is the degree of inflammation in the soft tissue, affecting the clinical development of health and esthetic symmetry.

Dental lasers have evolved considerably as an adjunctive and alternative treatment to safely, conservatively, and reliably decrease bacterial levels and improve the hard and soft tissue contours. Often the patient is frustrated with his or her previous poor cosmetic results.

However, to improve the periodontal framework in order to create an ideal result, they must be referred to yet another doctor. Even more challenging is the extended healing time created by reflective mucoperiosteal surgery. This not only affects the

chronology of final restorative care, but also delays the patient's ultimate satisfaction and happiness for a minimum of two to three months. Fortunately, dental lasers have evolved considerably as an adjunctive and alternative treatment to safely, conservatively, and reliably decrease bacterial levels and improve the hard and soft tissue contours. Studies of Er:YSGG lasers by Rizioiu and others have shown that thermal coagulative results, as

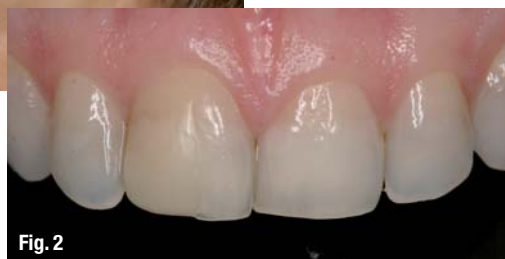
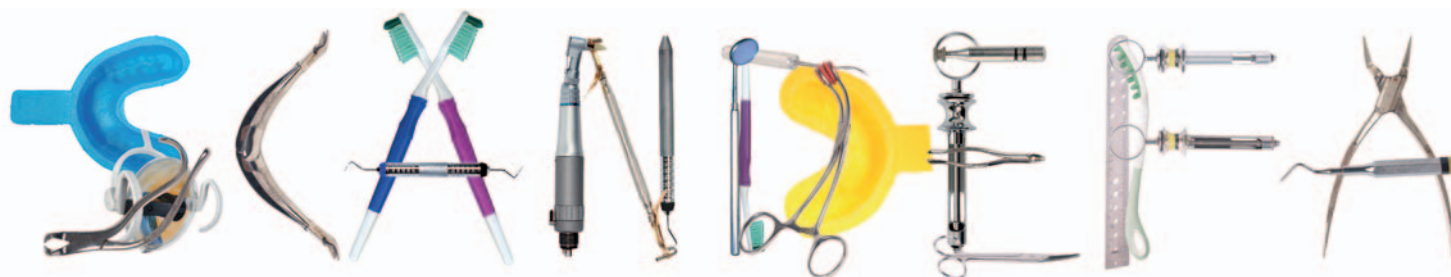

Fig. 2 _ Close-up photography is essential to planning peri-restorative care.



APRIL 26- 28, 2012 • BELLA CENTER • COPENHAGEN • DENMARK

Welcome to the 45th Scandinavian Dental Fair
The leading annual dental fair in Scandinavia

SCANDEFA 2012



The 45th SCANDEFA invites you to exquisitely meet the Scandinavian dental market and sales partners from all over the world in springtime in wonderful Copenhagen

SCANDEFA 2012

Is organized by Bella Center and is being held in conjunction with the Annual Scientific Meeting, organized by the Danish Dental Association (www.tandlaegeforeningen.dk).

175 exhibitors and 11.422 visitors participated at SCANDEFA 2011 on 14,220 m² of exhibition space.

Exhibit at Scandefa

Book online at www.scandefa.dk
Sales and Project Manager, Christian Olrik
col@bellacenter.dk, T +45 32 47 21 25

Travel information

Bella Center is located just a 10 minute taxi drive from Copenhagen Airport. A regional train runs from the airport to Orestad Station, only 15 minutes drive.

Check in at Bella Center's newly built hotel

Bella Sky Comwell is Scandinavia's largest design hotel. The hotel is an integral part of Bella Center and has direct access to Scandefa. Book your stay on www.bellasky.dk

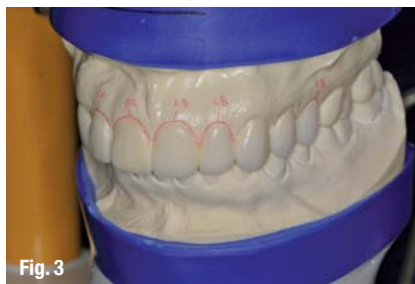

Fig. 3

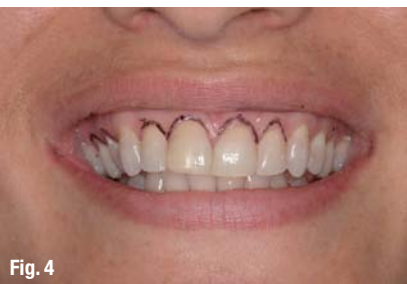

Fig. 4

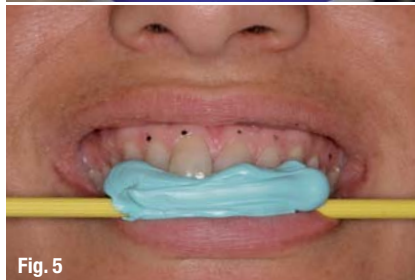

Fig. 5

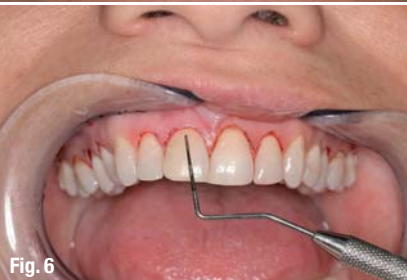

Fig. 6

Fig. 3 A mounted diagnostic wax-up is a critical roadmap to planning a realistic result.

Fig. 4 Outlining the desired gingival margins, prior to anesthesia, communicates a blueprint to the patient and restorative team.

Fig. 5 A stick-bite helps to verify that incisal and gingival planes will be parallel.

Fig. 6 The tissues are treated in a very nontraumatic manner with the Waterlase.

Fig. 7 To modify the bone, a very tight up-and-down movement is performed, using the black mark as a reference following the gingival scallop.

Fig. 8 A curette helps clean and smooth the sulcus of any debris.

well as bony ablation characteristics are similar to a dental bur.² From a patient-friendly standpoint, less need for suturing and shorter healing times improves case acceptance for doing ideal dentistry. In selected cases, such as the one presented in this article, minimally invasive laser procedures, with precise restorative planning and technique, can satisfy esthetic and functional parameters. Furthermore, patients can enjoy optimal results more comfortably and efficiently.

A conservative strategy was devised that would allow us to correct the problems and causes in a "multi-tasking" manner.

_Case Presentation

A 38-year-old female patient presented for correction of what she termed her "tilted smile" (Fig. 1). Given that she was starting a new sales career, she also wanted to make her teeth brighter and her smile much broader.

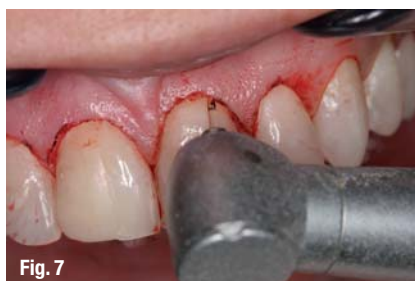

Fig. 7

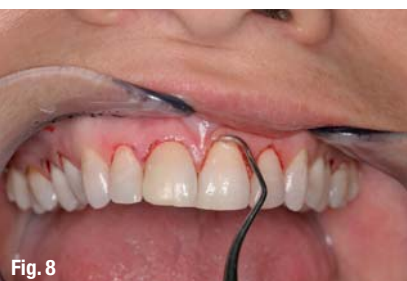

Fig. 8

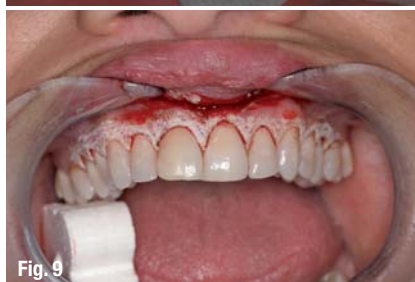

Fig. 9

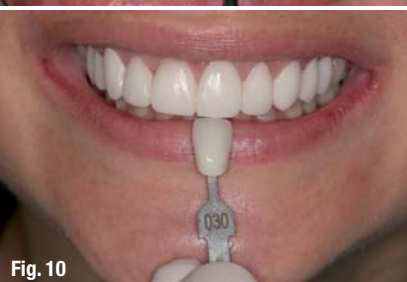

Fig. 10

The patient shared her frustration about previous dental consultations that had focused solely on orthodontic or surgical solutions without considering a more practical approach that would fit her busy life. Her smile analysis established a collapse of the bicuspids in the buccal corridor. Furthermore, the axial inclinations, irregular gingival margins, and incisal edges created a downward tilt to the patient's right due to tooth positioning. Close-up imaging showed healthy gingival tissues as well as a weakened right central incisor from a large composite (Fig. 2).

_Findings

A full clinical examination with radiographs and mounted models revealed the following:

- Biomechanically, the majority of her teeth remained strong despite previous dental care.
- Periodontally, soft and hard tissues were healthy.
- Occlusally, load testing was normal (after muscle relaxation) and there was obvious CR-CO anterior-vertical slide due to a premature contact at tooth #30.
- Esthetically, the width-to-length ratio of the upper centrals was 1:2, far from the ideal range of 0.75:1.0. Tooth shade was a VITA A2.

_Treatment plan

Given the patient's previous history and her desire for minimally invasive dental care, a conservative strategy was devised that would allow us to correct the problems and causes in a "multi-tasking" manner:

- muscle and bite therapy with a Tanner appliance, followed by careful equilibration aided by the T-scan (Tekscan System; South Boston, MA)
- three-dimensional wax-up on a Stratos articulator (Ivoclar Vivadent; Amherst, NY) (Fig. 3)
- home bleaching of the lower teeth with Opalescence 15% (Ultradent; South Jordan, UT)
- "closed flap" periodontal modification with the Waterlase ErCr:YSGG (Biolase Technology; San Clemente, CA) while the first three items were being accomplished (the combination of these four steps was a tremendous time saver and also allowed us to carefully monitor progress on a weekly basis)
- definitive restorative care with porcelain veneers and a crown on tooth #8.

No tissue necrosis or significant bleeding occurred as a result of using the laser's relatively lower settings.

_Treatment

At the initial closed periodontal lift, the ErCr:YSGG laser was used in three modes (gingival sculpting, osseous recontouring, and bio-stimulation). Prior to anesthesia, the desired framework was planned and outlined using a fine marker (Fig. 4). Furthermore, a

stick-bite was used, not only to establish an ideal incisal plane, but also to properly align the gingival margins (Fig. 5).

With the settings at 2.0 Watts (W), 20 pulses per second, 20% air, and 20% water, a G-6 tip (600 μ in diameter) was used to shape the labial gingival region. No tissue necrosis or significant bleeding occurred as a result of using the laser's relatively lower settings. All areas were "sounded" using a periodontal probe (Fig. 6). At the facial margins, osseous sculpting required great precision in order to maintain a 3-mm DGC. A specially tapered T4 tip (400 μ in diameter) was used at a 25% higher wattage of 2.5W. Prior to usage, the tip was measured and marked to 3 mm in order to maintain controlled adjustments within the gingival sulcus during perio probing movement of the tip (Fig. 7). The resection was smoothed with a 7/8 curette (Fig. 8). Using low-level laser therapy at a setting of 0.25 W, a decrease in the release of inflammatory histamine and increased fibroblasts for junctional epithelial growth was achieved by "frothing" the outer epithelium and injection sites (Fig. 9). The patient was placed on a vigorous home-care regimen (Oxygel, Oxyfresh; Coeur d'Alene, ID) and closely monitored for a month while occlusal therapy and bleaching procedures were performed.

Four weeks after surgery, the tissues had healed and restorative care could be initiated. The patient's teeth were prepared for veneers and a crown with mild soft tissue reshaping, to fine-tune our previous treatment. After taking impressions and bite registrations, prototype provisionals (Luxatemp Plus, Zenith DMG; Englewood, NJ) were fabricated using the "shrink-wrap" technique. The patient was sent home with the same home-care regimen as mentioned previously, and instructed to "test-drive" her new smile for esthetics and function. She returned in a week to perfect the prototype's occlusion, color, and morphology. Photographs and models were sent to the laboratory, providing a final blueprint for the porcelain restorations (Fig. 10).

Four weeks later, the provisionals and cement were carefully removed from the teeth. All restorations were tried in individually and as a group to verify fit and esthetics. After the patient's enthusiastic approval, the porcelain was bonded using the two-by-two technique and isolation. Margins were smoothed and polished and occlusion balanced with the T-scan. A protective night-time appliance was created to add longevity to the rehabilitation. Our very satisfied patient said that we had exceeded her expectations.



Fig. 9 A "laser bandage" is placed along the treated area to improve the healing time and decrease the patient's discomfort. Note the immediate improvement of the geometric progression of gingival embrasures.

Fig. 10 Detailed information helps the laboratory to translate clinical results to the porcelain restorations.

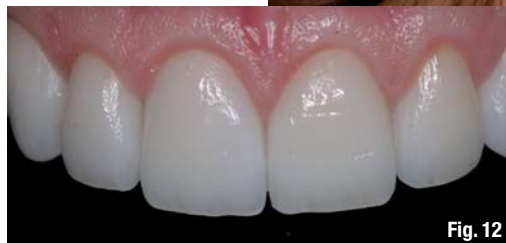

Fig. 11 The great improvement in esthetics boosted the patient's self-confidence and pride in her dental care.

Fig. 12 Ideal proportions and emergence profiles will create long-term healthy tissues and bioesthetics.

Conclusions

The use of a hard/soft tissue laser is a wonderful adjunctive tool for cosmetic and restorative dentistry. The case discussed here demonstrates that this type of laser technology gives dentists the ability to make significant soft and hard tissue changes while being minimally invasive. These changes not only improve the final esthetic outcome of the case but also provide the physiologic functional parameters required for successful dentistry.

Acknowledgments

The author thanks his office team and laboratory technician, Mr. Wayne Payne (Payne Dental Lab, San Clemente, CA), for continually enhancing the lives of many patients like the one presented here. He also is thankful to his family, who allow him to contribute to the education of other dentists and their teams.

Contact

Hugh Flax DDS
1100 Lake Hearn Dr. NE
Suite 440
Atlanta, Georgia 30342
Tel.: +1-404-255-9080
Fax: +1-404-255-2936
smile@flaxdental.com
www.flaxdental.com

laser

Editorial note: A list of references is available from the publisher.

Editor's Note: This article was reprinted with permission of Journal of Cosmetic Dentistry®, 2011 American Academy of Cosmetic Dentistry, All Rights Reserved. 608.222.8583; www.aacd.com