

Papillon-Lefèvre syndrome

New laser-assisted treatment method

Authors _ Dr Maziar Mir, Dr Surena Vahabi, Dr Shahrzad Jalali, Dr Bahram Kazemi, Dr Susanne F. de Haar, Dr Gholam Hossein Ramezani, Prof Dr Friedrich Lampert and Prof Dr Norbert Gutknecht

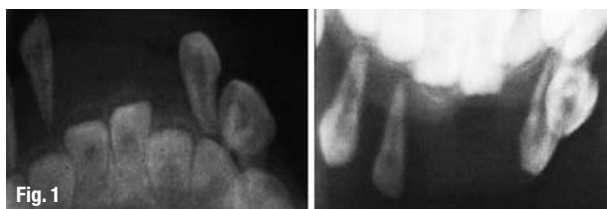


Fig. 1

Fig. 1 _ Maxillary and mandibular occlusal view radiographs taken on April 1998: Bone loss around the primary teeth shows a very poor diagnosis for saving the teeth. Therefore, all primary teeth were extracted.

_Introduction

Papillon-Lefèvre syndrome (PLS) is a rare autosomal recessive disorder. Its reported incidence is one to four per million and both the sexes are equally affected.¹ PLS is characterised by palmo-plantar hyperkeratosis, periodontopathy and premature loss of deciduous, as well as permanent dentition.² Plaque and calculus deposits may be present, along with significant halitosis.³ It manifests between one to five years of age and the patient becomes edentulous in the early teens. Another component of PLS is asymptomatic ectopic calcification in the choroids plexus and tentorium,² hearing loss, follicular hyperkeratosis and nail abnormalities.⁴ About 20% of these patients also show an increased susceptibility to infection, probably due to dysfunction of lymphocytes and leukocytes.² PLS is diagnosed mainly clinically.⁵ It needs to be differentiated from other conditions that show similar oral and cutaneous clinical features, such as acrodynia, hypophosphatasia, histiocytosis X, leukaemia, cyclic neutropenia and Takahara syndrome, which are also associated with periodontitis and premature loss of teeth.⁶ The risk of developing periodontal disease decreases with age because of the immune response to antigenic challenge.³ PLS patients usually have very complex subgingival flora, which includes the presence of *Actinobacillus actinomycetemcomitans*, capnophilic bacteria and *Capnocytophaga*

*spp.*⁵ In a PCR study, *Bacteroides*, in particular, *Bacteroides forsythus*, were associated with different types of periodontitis.⁷ It was mentioned by Kabashima *et al.*⁸ that IL-8, IL-1 alpha and IL-1 beta cytokines may be responsible for modulating the process of rapidly progressive periodontitis in a patient with PLS.⁸

PLS is caused by mutations in the gene that encodes cathepsin C (CTSC),⁹ as well as the related condition Haim-Munk syndrome and some cases of prepubertal periodontitis.¹⁰ This gene encodes a lysosomal cysteine protease or dipeptidyl aminopeptidase I (DPPI) necessary for the activation of serine proteinases in polymorphonuclear leukocytes (PMNs). It has also been suggested that DPPI is involved in a wide variety of immune responses, such as the activation of phagocytes and T lymphocytes. If the protein is truncated, it may not be transported to the organelle and may be not able to activate protein kinases. In addition, it will not be able to activate phagocytes and T lymphocytes, thereby leading to disease phenotype. Therefore, any typical mutation may result in either truncation or alteration in the conformation of CTSC-encoded enzyme DPPI.⁴ This gene is located on chromosome 11. Codon seven of this chromosome shows the exact mutation. This mutation has been registered as Hm040133 and directly affects one of the amino-acid residues at the active site of the enzyme.⁹ Up to now, 50 different mutations have been described in PLS patients.¹¹ The most common class of point mutation is a transition involving substitution of a G-C (guanine-cytosine) pair with an A-T (adenine-thymine) pair or vice versa. Variations at the site harbouring such changes have recently been termed "single nucleotide polymorphisms".⁶ In patients with PLS, loss-of-function mutations in CTSC do not affect lym-

phokine-activated killer cell function. Natural killer (NK) cells from affected patients contain inactive granzyme B, indicating that CTSC is required for granzyme B activation in unstimulated human NK cells.¹² However, according to the existing data, CTSC gene mutations are only responsible for 70 to 80% of PLS cases.¹³ De Haar *et al.* demonstrated that PLS patients lack the activity of the PMN-derived serine proteinases elastase, cathepsin G and proteinase 3. They found that the PMNs of PLS patients released lower levels of IL-37. Furthermore, because of their deficiency in serine proteases, the PMNs of PLS patients were incapable of neutralising the leukotoxin produced by this pathogen, which resulted in increased cell damage.¹⁴

The goal of periodontal therapy is to eliminate bacteria in the pockets, to remove hard- and soft-tissue deposits, to remove the granulation tissue and pocket epithelium in the periodontal lesions, to do root planing and, later, to enhance the attachment gain.¹⁵ The conventional mechanical treatment of periodontitis in a patient with PLS has a poor prognosis. Almost no treatment that saved the permanent dentition in PLS patients has been described so far. The most optimistic papers have described an extraction of all the deciduous teeth six months before eruption of permanent molars # 16 and 17 followed by a period of edentulism. The edentulous period may explain there being no recurrent attachment loss in the permanent teeth up to age 17.¹⁶ After this age, treatment shifts to the use of dental implants and complete dentures as the best solutions to this problem.¹⁸ Also, regular bacteriological tests may help to prevent or control the risk of infection.³ Several studies have demonstrated that additional irradiation with low-level and diode lasers is better than scaling and root planing alone.^{19–22}

Relatively recently, Cobb concluded some clinical evidence from the literature that demonstrates that certain laser wavelengths could be helpful for the decontamination of periodontal sockets.²³ Qadri *et al.* demonstrated that additional treatment with low-level laser reduced gingival inflammation after non-surgical treatment. Plaque index, gingival index and probing depth declined more on the side given such treatment. Another marker of inflammation, gingival crevicular fluid volume, has been also reported to be greater on the treated side.¹⁹ Ishikawa and Sculean published a review article in 2007 that demonstrated the successful results of diode laser assistance in de-epithelialising and sulcus decontamination therapies.²⁴

In this study, additional to complete clinical, radiological, pathological and genetic diagnosis, a laser-assisted periodontal therapy was performed on a PLS

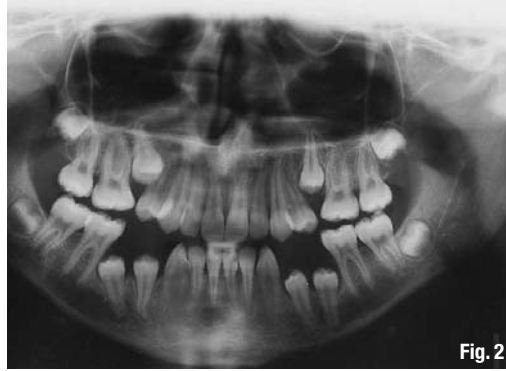

Fig. 2 Panoramic view taken on December 2008: The bone-level and soft-tissue lines are all normal. There is no pathological finding reportable.

patient. Following the accurate evaluations of the studies noted earlier, a 980 nm diode laser was selected to treat this particular patient, who lived in a village with no access to well-equipped laser clinics. Diode lasers are semiconductors that use solid-state elements to change electrical energy into light energy, and are smaller and more easily transported to areas far from medical centres. These lasers with wavelengths of 810 to 980 nm approximate the absorption coefficient of soft-tissue pigmentation. Therefore, light energy from diode lasers is well absorbed by the soft tissue and poorly absorbed by teeth and bone.²⁵

Review of a case with a new laser-assisted treatment plan

A three-and-a-half-year-old female patient was referred to the clinic with ten missing and six mobile primary teeth in April 1998. Physical examination revealed palmar and plantar hyperkeratosis. No other physical, mental or laboratory disorders were found. Dental examinations showed severe generalised gingival loss of attachment in both dental arches. There was a root exposure all around the existing teeth. Periodontitis as a manifestation of systemic disease is concluded as diagnosis.

Radiographic findings

Severe bone loss was evident in occlusal view radiographs (Fig. 1). The permanent teeth were found healthy inside the bone.

Microbiological and histopathological findings

The early antibiogram detection showed cephalixin as the antibiotic of choice for the disease. The result of the cultures revealed the predominant presence of *Bacteroides*. Hypercementosis and inflammatory reactive hyperplasia (fibrosis) were observed in the slides of the teeth involved and surrounding tissues, respectively.

Genetic analysis

By use of polymerase chain reaction (PCR), we amplified the seven exons of cathepsin C using the

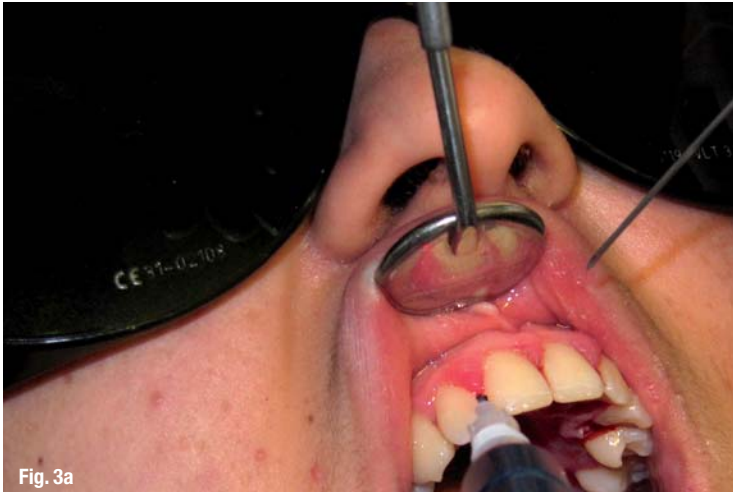


Fig. 3a

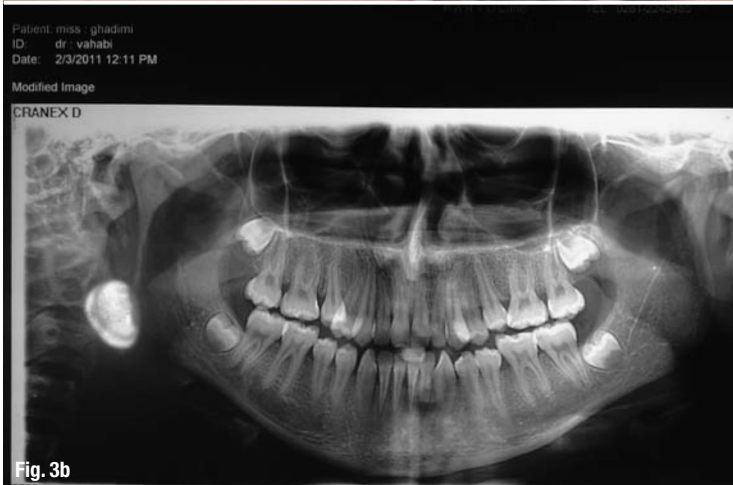

Fig. 3b

Fig. 3a & b Final clinical and radiograph condition of patient is shown as was registered in February 2011. This is the first time that a 12-year follow-up of a case of PLS has reported success in complete teeth eruption without any tooth mobility until the age of 16.

primers described in other studies. After the PCR process, we confirmed the presence of the PCR product by 2% agarose gel electrophoresis. The PCR products were purified using columns and the concentration of the DNA was determined spectrophotometrically. For the sequence reaction, we used the same primers as for the PCR reaction and the reaction was carried out using the BigDye Terminator mix (Applied Biosciences). The data was automatically collected and analysed by the software of the Sequencer. The sequences were compared with the published cathepsin C sequence. A nucleotide 1212 A>G mutation in the cathepsin C gene was found, which was predicted to result in an amino acid 405 His>Arg mutation. The mutation was confirmed by the use of restriction enzyme analysis performed on exon seven. The nucleotide mutation has not been reported previously.

Treatment

The patient was treated with a daily chlorhexidine mouth rinse. To eliminate the source of infection, all the primary teeth were extracted in June 1998. An early anti-biogram test has reported cephalixin to be recommended after extraction of the teeth. This selective antibiotic therapy elimi-

nated the need for antibiotic therapy before eruption of the permanent teeth, which was recommended by some earlier studies.

Follow-ups and laser-assisted therapy

The infection was successfully controlled. The patient was re-evaluated clinically and para-clinically and no future antibiotic therapy was needed. The permanent incisors and first molars erupted under good oral hygiene care. A recall on November 2003 showed no significant finding on the panoramic X-ray either.

In July 2007, gingivitis and the start of new contamination were reported. Therefore, laser treatment using a diode laser (970+/-10 nm wavelength, K-laser, Eltech S.R.L.) was selected in addition to routine hand instrumentation and curettage. This laser irradiated a beam with a diameter of 300 µm and 2.5 to 3 W output power around free gingival margins and inside the pockets after removing the necrotised parts of tissue. The full mouth procedure took approximately 15 minutes and the entire operation was documented using a professional video camera. The exact output power was 2 W during treatment and a reputation rate of 20 was selected.

The patient was re-evaluated after 1.5 years due to the relocation of her parents and difficult access to them. Although no treatment was done in this time, gingival tissue colour was normal in December 2008, and there were no evidences of deep periodontal pockets or loss of attachments, except slight inflammation around the gingival margins. No significant pathological finding was reported from the panoramic radiograph either (Fig. 2). Orthodontic treatment was proposed by a related department, but as the orthodontic wire and brackets are a source of plaque accumulation, diode laser therapy is done at the same time as each orthodontic visit to maintain the good condition of teeth until the age of 18. On February 2011, all teeth were still healthy and the patient was still undergoing periodical laser therapy additional to scaling and root planing. The final radiograph and clinical condition are presented in Figure 3.

_Discussion

The aetiology of the periodontal component is not entirely clear. The gene abnormality that causes PLS is found on chromosome 11q14, which involves mutations of cathepsin C.²⁶ This mutation was shown as in this case. The enzyme cathepsin C is active in skin, gingival tissue and immunologically active cells;²⁷ it is possible that the absence of functional cathepsin C affects the immune response to microbial infection. Thus, periodontal pathogens

are enabled, secondary to the impaired local immune response. Periodontal treatment included extraction of all the deciduous teeth and mechanical therapy with the concomitant use of systemic antibiotics.

In case reports, both mechanical debridement alone and mechanical therapy plus a single antibiotic have failed to eradicate *A. actinomycetem-comitans* and improve the periodontal condition in PLS.^{16,28} In this case, microbiological studies showed *Bacteroides* as the predominant bacterial species and cephalexin as the antibiotic of choice which has been resulted.

Numerous studies have demonstrated that the period of edentulism following the extraction of all deciduous teeth prevented involvement in later erupting permanent teeth. In these studies, extraction was followed by other treatment, such as mechanical therapy, systemic antibiotics and surgical treatment.^{16, 29–33} So, early diagnosis to extract the deciduous teeth before eruption of permanent teeth is very important, which was done in this case. Success in retaining the permanent teeth seems to depend on the timing of these therapies. If any teeth erupt after the period (edentulism) into a mouth that is free of periodontal disease, patients have a good chance of remaining periodontally healthy, even if oral hygiene and maintenance are not optimal, as happened in this case.

Several lasers have been used to decontaminate periodontal pockets.¹⁹ Some authors have reported proliferation of gingival fibroblasts after using low-level laser and have shown that the stimulated fibroblasts are better organised in parallel bundles.¹⁹ Low-level laser therapy may play an important role in periodontal wound-healing and regeneration by enhancing the production of the growth factors.³⁴ Application of the diode laser can reduce bacteria²⁰ in gingival crevices, which may reduce bacteraemia following ultrasonic scaling.²² Thermal and photo-disruptive laser effects result in the elimination of periodonto-pathogenic bacteria, regardless of laser wavelength.^{21, 35} Some studies have demonstrated that instrumentation of soft periodontal tissues with a diode laser (980 nm) leads to complete epithelial removal as compared with conventional treatment methods with hand instruments.¹⁵

Periodontitis in PLS is a multifactorial process believed to have genetic, bacterial and immunological aetiologies, making it difficult to diagnose and treat. Early diagnosis and administering appropriate systemic antibiotic therapy in patients with PLS might preserve all permanent teeth that otherwise would exfoliate spontaneously or be extracted. We con-

clude that microbiological tests may be a powerful tool to select the proper antibiotic for the successful treatment of a PLS patient. Decontamination of sockets after de-epithelialisation of gingival soft tissue in inflamed margins with a diode laser is a successful aid to the previous hand instrumentation and medicament therapies. This fact has been clinically proven by a ten-year follow-up of a case that has a healthy periodontal condition. Similar cases reported in the literature mostly resulted in loosened permanent teeth. This success, while partly due to the correct antibiotic selection, is mostly the result of sufficient laser therapy. More studies are needed to establish this finding. As PLS is a very rare syndrome, no randomised clinical trial could be done. Therefore, collaboration between several medical universities could be the key to conducting a long-term cohort study entailing laser treatment.

_References

1. W.A.D. Griffiths, M.R. Judge and I.M. Leigh, "Disorders of Keratinisation", in R.H. Champion, J.L. Burton, D.A. Burns and S.M. Breathnach (eds.), Textbook of Dermatology, 6th edn. (Oxford: Blackwell Scientific Publications, 1998), 1569–71.
2. R. Bergman and R. Friedman-Burnham, Papillon–Lefèvre syndrome: A study of the long-term clinical course of recurrent pyogenic infections and the effects of etretinate treatment, British Journal of Dermatology, 119/6 (1998): 731–6.
3. H.U. Toygar, C. Kircelli, E. Firat, et al., Combined therapy in a patient with Papillon–Lefèvre syndrome: A 13-year follow-up, Journal of Periodontology, 78/9 (2007): 1819–24.
4. A.A. Wani, N. Devkar, M.S. Patole, et al., Description of two new cathepsin C gene mutations in patients with Papillon–Lefèvre syndrome, Journal of Periodontology, 77/2 (2006): 233–7.

Editorial note: The whole list of references is available from the publisher.

_contact	laser
<p>Dr Maziar Mir</p> <p>British Lasik and Cosmetic Surgery Center, Dubai, UAE</p> <p>Department of Preventive and Conservative Dentistry University Hospital Aachen and Aachen Dental Laser Center RWTH Aachen University Pauwelsstr. 19 52074 Aachen Germany</p> <p>mmir@ukaachen.de</p>	