

Laser in daily practice use

The key to therapeutic and economic success

Authors _ Prof Dr Frank Liebaug & Dr Ning Wu, Germany

_Laser dentistry went through a rapid development within the last years. Today, the use of laser devices enhances the whole dental treatment range valuably and supports conventional as well as conservative therapies. So the practitioner achieves more safety and a better clinical result can be obtained for the patient in a gentle way. In the following, the authors show different alternatives based on clinical case studies.

Especially for the colleagues with their own practice it is important to study the possibilities, but also the limitations of modern laser dentistry and to get an idea about the possible introduction in their practice.

_Practical indication for lasers in dentistry

Today, application fields of laser devices in oral therapy are to be found in diagnostics, caries and hard tissue removal, periodontology, antimicrobial, photodynamic therapy of mucosa diseases, en-

doodontics, implantology and preparation of suprastructures, periimplantitis therapy (Fig. 2), high-quality prosthetics, laser-supported pediatric dentistry, prophylaxis, bleaching and—last but not least—in esthetic dentistry.

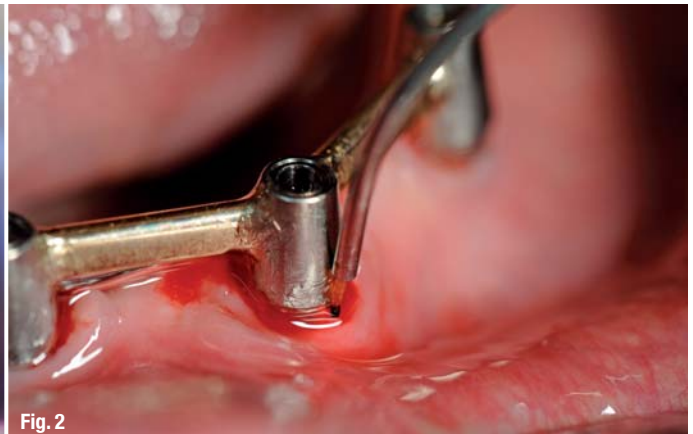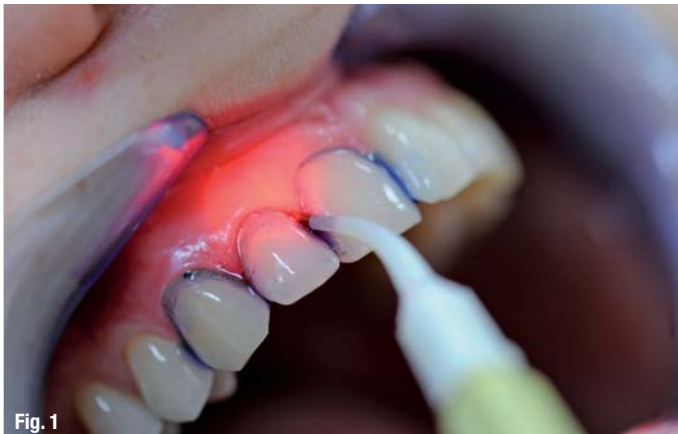_Wavelengths determine indication of use

However, there is not just one device for all applications and indications, in fact the indication is determined by the respective wavelength of the laser. Caries and hard tissue removal are treated with the Er:YAG device. As these devices are high-end developments, they are connected with high investment costs for the dental practice. If appropriately used by the dentist and integrated into the daily treatment concept, the use of such devices is reasonable midterm, therapeutically as well as economically.

Within the last years, various dental laser systems have gained importance in the therapy of pe-

Fig. 1 _Antimicrobial, photodynamic therapy in marginal periodontitis.

Fig. 2 _Laser for periimplantitis therapy, 17 years post implantation and dental bar provision.



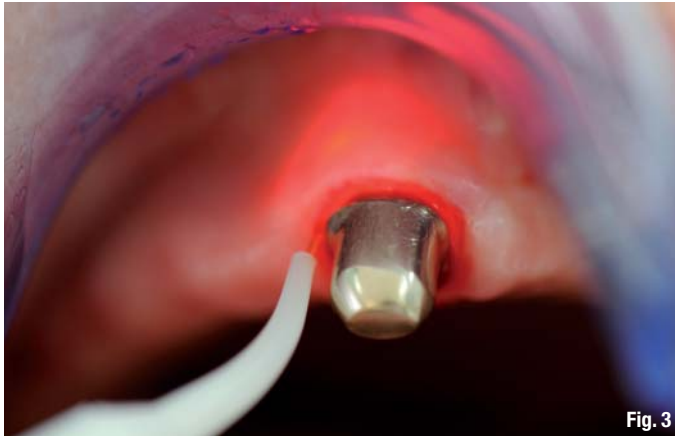

Fig. 3

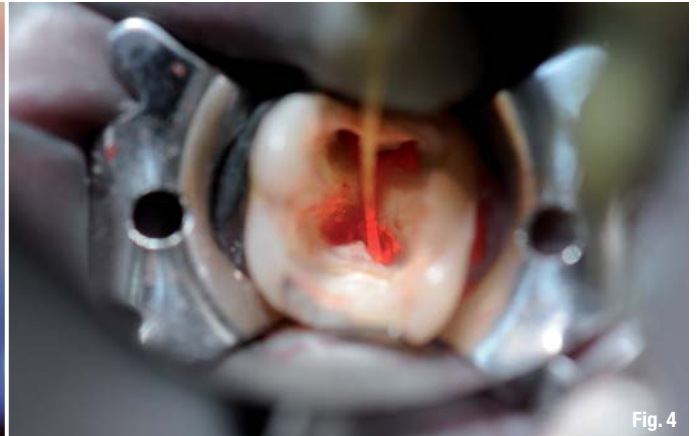


Fig. 4

riodontitis. In principle, the use of laser can only be seen as completion of the conventional, systematic therapy even though the field of non-surgical periodontal therapies could have been expanded by laser application meanwhile.

Before using laser devices, the patient must be prepared in terms of a completed initial therapy. Due to the latest developments in the field of laser technology, it seems to be conceivable that even the removal of concretions can be done by means of a laser.

Usage of laser creates a bactericidal environment and supports healing

Primarily, however, the dentist takes advantage of the bactericidal effect of a certain wavelength. Numerous studies and publications in various fields of dentistry have proved that laser shows an excellent antibacterial effect in the infrared area and that it is able to deactivate bacterial toxins. This effect starts developing at an output power clearly underneath the limit for a thermal damage of soft and hard tissue. Thin and flexible light conductor

Fig. 3 _ Pocket decontamination at telescopic tooth with a laser.

Fig. 4 _ Laser decontamination of root canals at a molar under Rubberdam.

AD

cosmetic dentistry

_ beauty & science

One issue free of charge!

You can also subscribe via www.oemus.com/abo

 **Subscribe now!**

I hereby agree to receive a free trial subscription of **cosmetic dentistry** (4 issues per year). I would like to subscribe to **cosmetic dentistry** for € 44 including shipping and VAT for German customers, € 46 including shipping and VAT for customers outside of Germany, unless a written cancellation is sent within 14 days of the receipt of the trial subscription. The subscription will be renewed automatically every year until a written cancellation is sent to OEMUS MEDIA AG, Holbeinstr. 29, 04229 Leipzig, Germany, six weeks prior to the renewal date.

Reply via Fax +49 341 48474-290 to OEMUS MEDIA AG or per E-mail to grasse@oemus-media.de

Last Name, First Name

Company

Street

ZIP/City/Country

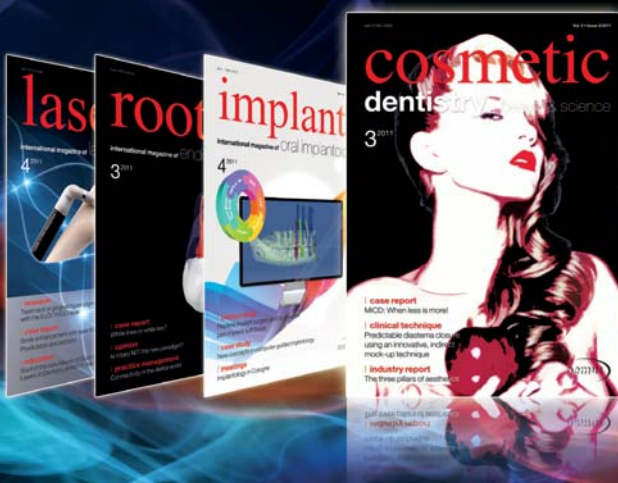E-mail

Signature

Notice of revocation: I am able to revoke the subscription within 14 days after my order by sending a written cancellation to OEMUS MEDIA AG, Holbeinstr. 29, 04229 Leipzig, Germany.

Signature

laser 4/11



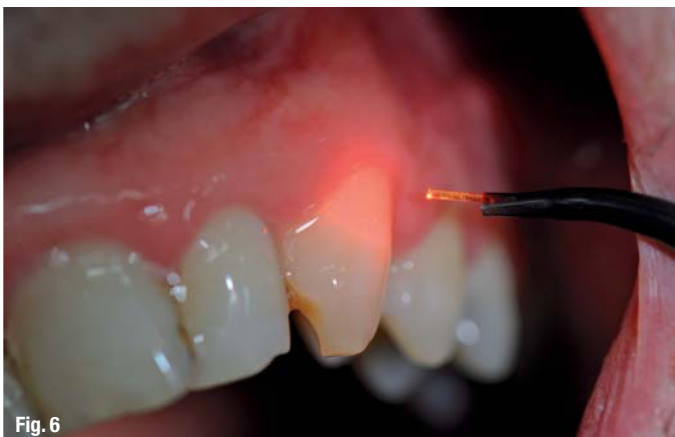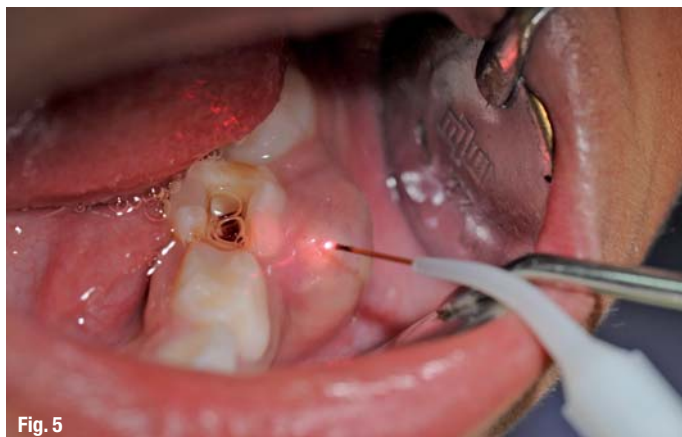


Fig. 5 Laser incision at acute, submucous abscess in primary dentition.

Fig. 6 Laser application for desensitization of hypersensitive tooth surfaces.

systems bring the laser radiation to nearly any desired place and can be well used even in the bifurcation area of molars. So it seems to be obvious to profit from these advantages in connection with a systematic periodontal therapy. If the output power is increased, also pocket epitheliums in terms of a closed curettage can be removed with an Nd:YAG or diode laser. Therefore, pocket decontamination with the laser is very effective, even in case of an acute local periodontitis.

Advantages of laser-supported periodontal therapy

Most dentists as well as patients will quickly realize the advantages especially in the fields of periodontology and laser-supported endodontics. For the field of laser-supported* periodontal therapy this means:

- no bleeding after treatment, even in patients suffering from a bloodclotting disorder or taking anticoagulants*
- significantly less anesthesia demand
- agreeable and easier treatment
- better healing process without complications
- considerably less postoperative pain
- drinking and eating possible after subsiding of anesthesia
- less postoperative hypersensitivities of tooth necks by sealing of dentin tubuli
- germ reduction in periodontal pockets (Fig. 3).

Advantages of laser-supported endodontic treatment

The success rate in endodontic therapy can be significantly increased by a consequent use of the laser device, too, thus avoiding surgical interventions to the point of necessary tooth extraction in case of clinical failures (Fig. 4). A major advantage is the 99% germ reduction* in the root canal immediately after exposure to laser light resulting in:

- possibly no medicamentous insert
- time saving, often whole treatment in just one appointment
- sealing of the apical dentin tubuli
- avoiding of apicectomy.

Clinical examples

The following case studies show just a small selection of treatment possibilities, without claim to be complete, to encourage interested colleagues to integrate innovative methods into the daily practice in the interest of their patients. It is not to be underestimated that especially children and anxious, sensitive patients are very open to this treatment method. One example should be the incision of an acute submucous abscess in the primary dentition (Fig. 5). But also the relatively many patients with herpes labialis or sore stomatitis aphthosa respond positively to the oral laser therapy. Hypersensitive tooth surfaces can be treated effectively with the non-contact procedure (Fig. 6).

The newcomer might have difficulties to find the appropriate device on the current dental market. Aside from devices with just one laser of a certain wavelength, the combination unit LaserHF, which we use in our practice, has been available for more than a year now. Apart from a diode laser with a wavelength of 975 nm, this device includes a low-level-laser with 660 nm and an additional high frequency surgery unit for cutting and coagulation.

_contact	laser
<p>Prof Dr med Frank Liebaug Professor Hangzhou Normal University, China Guestprofessor Shandong University, China Praxis für Laserzahnheilkunde und Implantologie Arzbergstraße 30 98587 Steinbach-Hallenberg Tel.: +49 36847 31788</p>	