

# roots

international magazine of endodontology

4<sup>2011</sup>

| **case report**

Minimally invasive crown lengthening

| **practice management**

The passive income practice

| **meetings**

Ten years of DGEndo and the launch of DGET

0277113



Simplicity is the real innovation



wave.one™

- Only one sterile NiTi instrument per root canal in most cases
- Decreases the global shaping time by up to 40%
- Reciprocating technology respecting the root canal anatomy
- Single use as new standard of care

# Dear Reader,

**The single most important development** that was a giant leap for endodontics is micro-computed tomography, which gives us a 3-D view. Without this technology, the basis for many endodontic procedures was just empirical, like enlarging the root canal three sizes beyond the first file that binds during hand instrumentation, or arbitrarily deciding the final apical size with tapered rotary use.

Prof Marco Versiani's root-canal anatomy project on micro-CT study guide has demystified many old concepts. Now we know that all root canals are curved, apical diameters are not as small as perceived, and root canals do not have large tapers.

Regenerative endodontics, though in the infant stage, can hold significant implications for the management of necrotic immature teeth. These treatment protocols can result in radiographic and clinical evidence of healing and subsequent root development. Tyler Lovelace *et al.* have demonstrated that the evoked-bleeding step in regenerative procedures triggers a significant accumulation of undifferentiated stem cells in the canal space, leading to the regeneration of pulpal tissues. Future developments may see wider application of these tissue-engineering principles, revolutionising the field of endodontics.

The use of lasers in endodontics may be common procedure soon with a number of applications in access preparation, root-canal shaping, and decontamination of the root-canal system. The improved technology has introduced endodontic fibres and tips of a calibre and flexibility that permit insertion up to 1 mm from the apex. Laterally emitting conical fibre tips were found to be safe under defined conditions for intra-canal irradiation without harmful thermal effects on the periodontal apparatus.

The EndoVac irrigation system (SybronEndo) is one of the best things that has happened to endodontics in recent years. While sodium hypochlorite significantly eliminates the biofilm associated with endodontic infections, it can cause catastrophic tissue damage when extruded. With EndoVac, fortunately, it can now be safely delivered to full working length. Research shows that EndoVac usage can result in a significant reduction of post-operative pain levels in comparison with conventional needle irrigation.

Micro-CT studies show that the apical thirds are not cleaned with tapered systems of small tip size. In addition, they showed that instruments with a flat widened tip determine apical diameter better than round tapered instruments. The coming years are bound to see an increased acceptance of LightSpeed LSX instruments (SybronEndo) to obtain biologically optimal preparations.

At a time when dental professionals have a choice between root-canal treatment and implant placement after extraction, it is heart-warming to see that recent developments in endodontics, if incorporated into the surgery, can maintain the tooth in a functional state for many years.

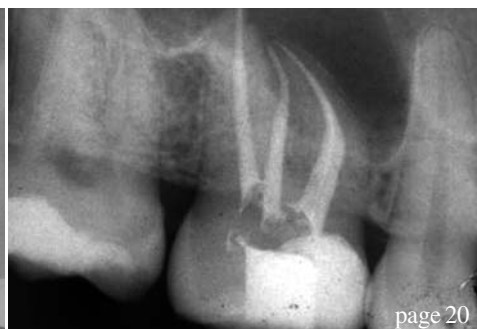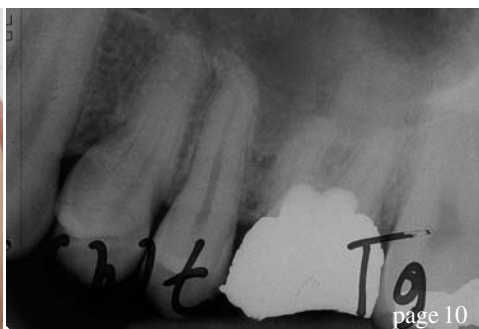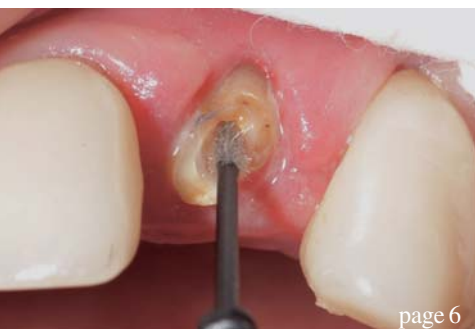Yours faithfully,



Prof Beena Rani Goel  
President of the International Academy for Rotary Endodontics



Prof Beena Rani Goel



| editorial

- 03 Dear Reader  
| Prof Beena Rani Goel, Guest Editor

| case report

- 06 Minimally invasive crown lengthening as an alternative to implant treatment  
| Prof Marcel Wainwright

| research

- 10 Vital amputation of permanent teeth  
| Dr Robert Teeuwen

| practice management

- 18 The passive income practice  
| Dr Phillip Palmer

| opinion

- 20 Critical thinking:  
The missing link in endodontic education  
| Dr Barry Lee Musikant
- 24 Rubber dam hazards?  
| Dr Kenneth S. Serota

| news

- 26 Dental X-rays can predict fractures

| feature

- 28 An interview with Dr Emanuele Ambu

| industry news

- 32 FKG Dentaire introduces *iRaCe* and *Scout-RaCe*  
| FKG


| meetings

- 34 Dental symposium at home? AMED goes virtual  
| Dr Terrell F. Pannkuk
- 36 Ten years of DGEndo and the launch of DGET  
| Oscar von Stetten

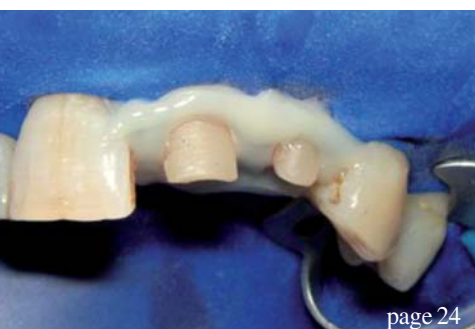| International Events

| about the publisher

- 41 | submission guidelines
- 42 | imprint



Cover image courtesy of Produits Dentaires SA.

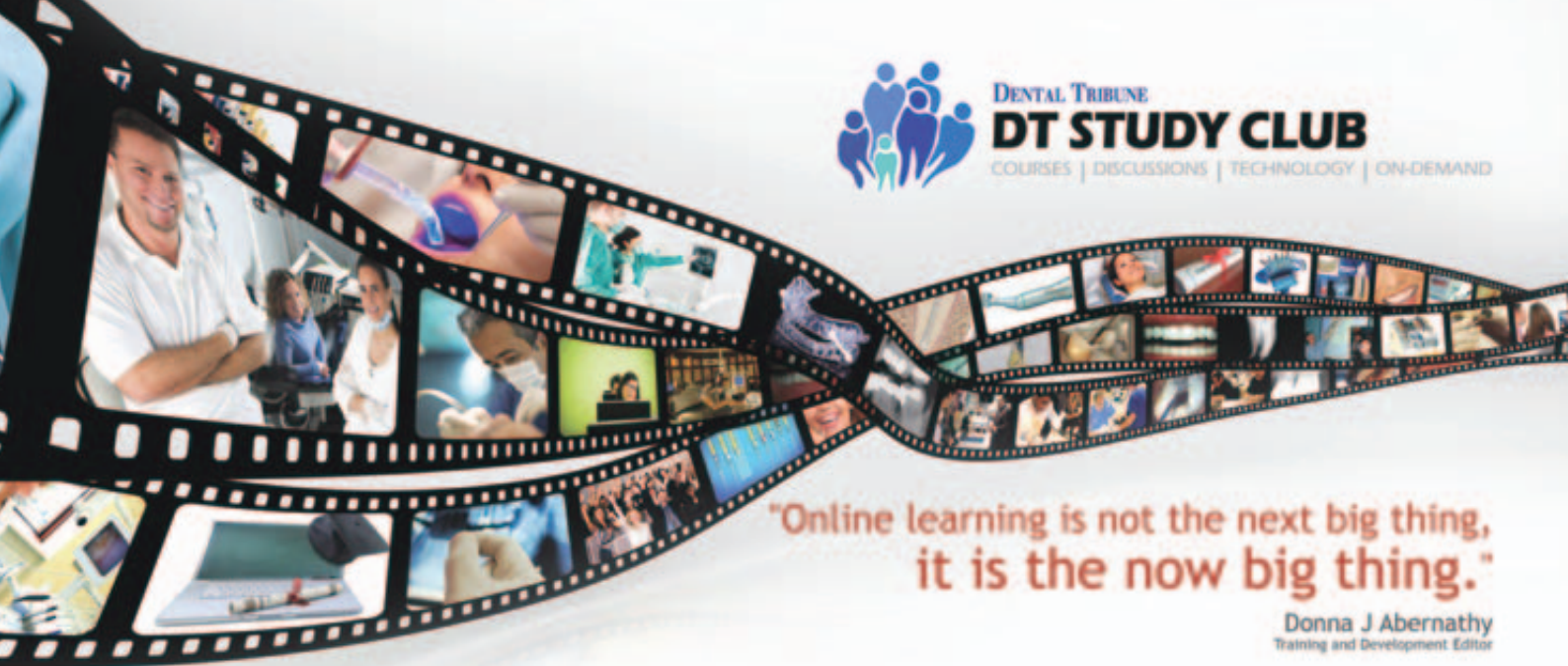



DENTAL TRIBUNE

**DT STUDY CLUB**

COURSES | DISCUSSIONS | TECHNOLOGY | ON-DEMAND



**"Online learning is not the next big thing,  
it is the now big thing."**

Donna J Abernathy  
Training and Development Editor

## DTSC - COURSES, COMMUNITY, TECHNOLOGY, ON-DEMAND

The DT Study Club makes all of this possible from the comfort of your own computer and without travel expenses. In other words, welcome to the community!

The purpose of this study club is to provide practitioners like yourself an opportunity to learn and network with like-minded colleagues in a friendly, non-threatening environment. We encourage you to take advantage of Dental Tribune's global outreach to access a variety of fresh perspectives and cultures, enhancing your educational mix.

### 24/7 LIVE AND INTERACTIVE ONLINE COURSES

Fulfill your yearly CE requirements with our growing list of archived ADA CERP approved courses.



### DISCUSSION FORUMS

focused on helping today's practitioners to stay up to date. Networking possibilities that go beyond borders to create a truly Global Dental Village



### VIDEO REVIEWS OF PRODUCTS

Our opinion leaders unveil new products, services, and give you their first impressions of the industry's hottest topics.



### PEER REVIEWED CASE STUDIES

Upload, comment, participate. We encourage you to share your cases for review with like-minded practitioners.



REGISTER FOR FREE ON [WWW.DTSTUDYCLUB.COM](http://WWW.DTSTUDYCLUB.COM)

CONTESTS WITH CHANCES TO WIN FREE TUITION FOR ADA/CERP C.E. ACCREDITED WEBINARS

SPONSORSHIP AND SPEAKING INQUIRIES:  
JULIA WEHKAMP, [J.WEHKAMP@DTSTUDYCLUB.COM](mailto:J.WEHKAMP@DTSTUDYCLUB.COM), (416) 907-9836.

**ADACERP**  
Continuing Education Recognition Program



PRACTICE MANAGEMENT



GENERAL DENTISTRY



COSMETICS



ENDODONTICS



IMPLANTOLOGY



PERIODONTICS



ORTHODONTICS



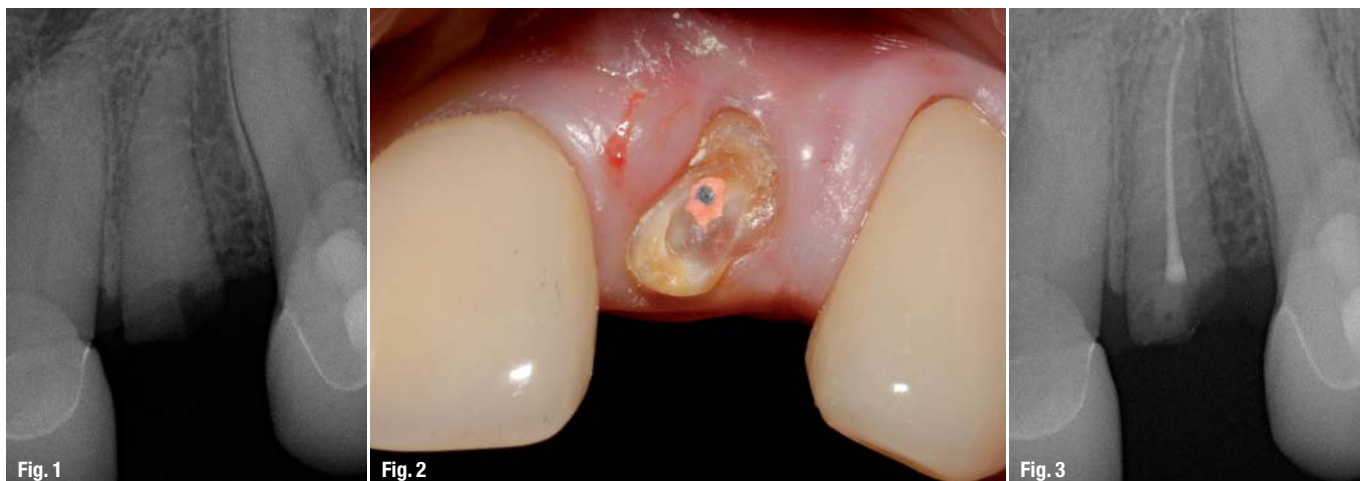DENTAL HYGIENE

[WWW.DTSTUDYCLUB.COM](http://WWW.DTSTUDYCLUB.COM)



# Minimally invasive crown lengthening as an alternative to implant treatment

Author\_ Prof Marcel Wainwright, Germany



**Fig. 1** Single-tooth radiograph showing the fractured tooth #22.

**Fig. 2** Thermoplastic root filling in tooth #22.

**Fig. 3** Radiograph of the orthograde root filling, found to be *lege artis*.

**\_Crown fractures frequently force** the treatment provider to make a clear-cut treatment choice between tooth preservation and dental implant treatment. Speakers at implantological congresses tend to present impressive implant/prosthetic solutions for anterior fracture cases, to the point where the audience could be tempted to believe that this was the only appropriate treatment alternative. The following case report documents a tooth preservation option that is simple to perform, minimally invasive and successful.

## **\_Case report**

A 66-year-old male patient presented at our office with a fractured upper left lateral incisor (tooth #22). The clinical crown of this tooth had fractured in the marginal region, with the pulp of the tooth slightly exposed in one location; the pulp tissue vitality test showed a weak positive result. The patient was completely free of pain symptoms. There was no root mobility. Available treatment options were discussed with the patient based on a single-tooth radiograph (Fig. 1). The neighbouring teeth #21 and 23 had been

restored with all-ceramic crowns two years previously. However, a three-unit fixed prosthetic denture was rejected by the patient, as was surgical treatment with immediate implant placement following extraction.

Conservative tooth preservation was therefore the treatment of choice for patient and treatment provider alike. The patient was informed that tooth preservation could only be successful if the required orthograde root-canal instrumentation was possible, the tooth was symptom free and biological width could be restored prior to the fabrication of a crown restoration. If these requirements turned out not to be met, an implant/prosthetic solution would have to be resorted to as an alternative.

## *Treatment sequence*

Following extensive patient education and pre-therapeutic discourse, the patient received local anaesthesia, and tooth #22 was instrumented. This was initially difficult, as the root canal turned out to be slightly obturated. Following instrumentation

to ISO 20, the tooth was prepared for a root filling. Instrumentation to more than ISO 20 did not appear advisable, as the reduced diameter of tooth #22 already constituted an increased fracture hazard during preparation of the endodontic post or in the presence of lateral forces. At the same visit, an ortho-grade endodontic filling was placed using a thermo-plastic restorative technique (Thermafil; DENTSPLY DeTrey) and Sealapex (SybronEndo; Fig. 2). The control radiograph showed that the root-canal filling had been placed *lege artis* (Fig. 3).

Surgical crown lengthening was planned for four weeks later. Like all surgical interventions at our clinic, this crown lengthening was performed using ultrasonic surgical instruments (Acteon). In this protocol, the surgeon employs a surgical kit containing multiple calibrated diamond instruments (Fig. 4). A minimal circumferential incision was performed under local anaesthesia, completely dispensing with extensive flap elevation procedures or relieving incisions. The marginal bone was prepared approximately 2 mm farther apically to provide sufficient biological width for a subsequent crown (Berglundh 1992). The use of ultrasonic surgical instruments allows the surgeon to proceed quickly while protecting the tissue, as these instruments help reduce the risk of iatrogenic damage to the root dentine, a risk that is elevated when using conventional rotary instruments (Fig. 5). The site was sutured closed using a synthetic monofilament thread (Trofilene 8-0, Stoma; Fig. 6). Microsurgical suturing is indispensable in the anterior region. If it is neglected, this will result in tissue recession and impaired aesthetics.

The sutures were removed one week later. Wound healing was uneventful, and the patient was completely free of pain and other symptoms throughout the entire treatment. After an additional week, a post-and-core build-up was performed using the Fibrapost and Sealacore system (Produits Dentaires; Fig. 7). The root canal was prepared with reamers, which are available in four different diameters (Fig. 8). The option to use the depth stop to pre-calibrate the reamer to the desired length was helpful, not least



Fig. 4

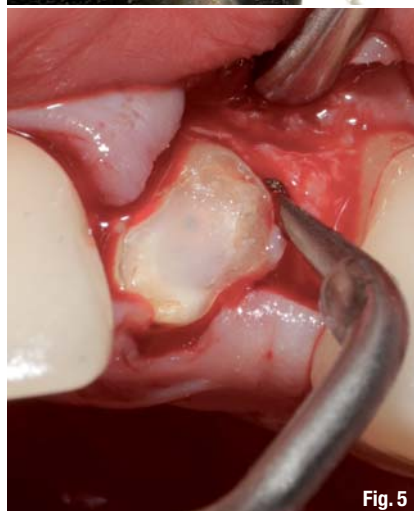

Fig. 5

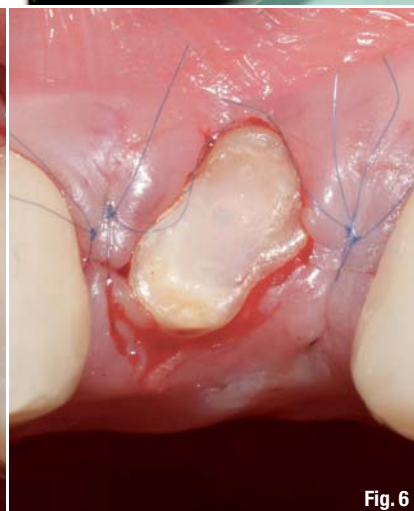


Fig. 6

as a precaution against excessive preparation depths (Figs. 9 & 10).

The root canal was prepared under copious irrigation and conditioned with a self-etching bonding system (Sealacore; Fig. 11). The UDMA-based resin cement (Sealacore) was introduced into the root canal with a syringe and application tip (Fig. 12). The Fibrapost is a fibreglass-reinforced resin endodontic post (Fig. 13) with retentive grooves. Our clinic uses metal-free endodontic post systems exclusively, as their biomechanical properties are clearly superior to those

Fig. 4\_Crown lengthening kit (Acteon).

Fig. 5\_Ultrasonic crown lengthening of tooth #22 using minimally invasive incisions.

Fig. 6\_Microsurgical 8-0 suture.

Fig. 7\_Fibrapost and Sealacore system.

Fig. 8\_Endodontic reamers.

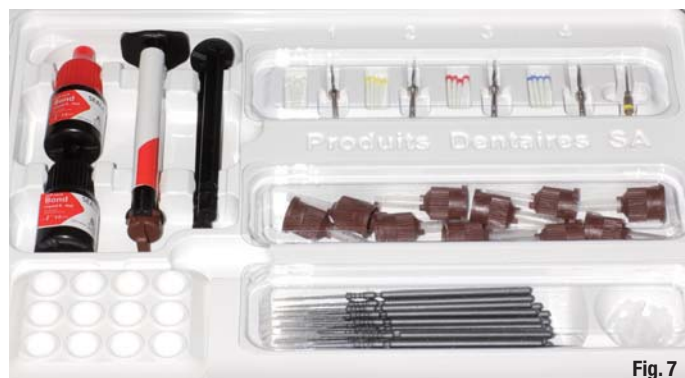


Fig. 7

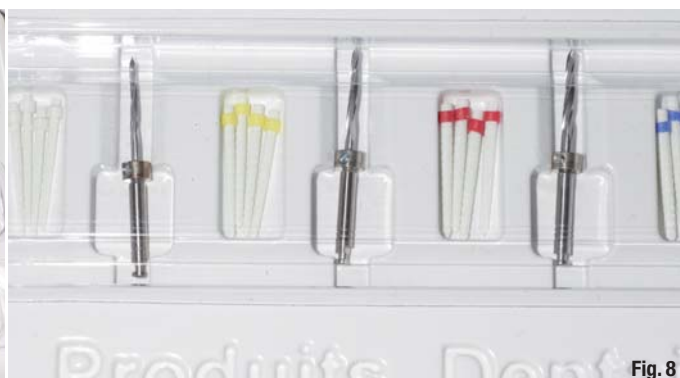

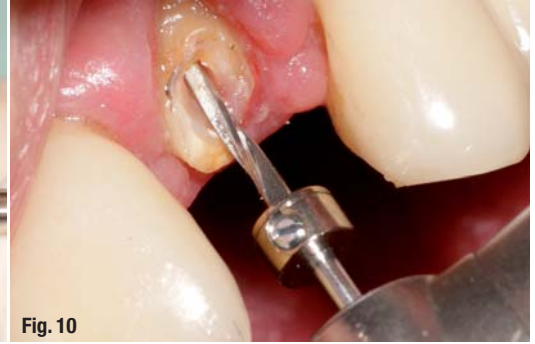Fig. 8

**Fig. 9**\_Defining preparation depth using the adjustable stop.



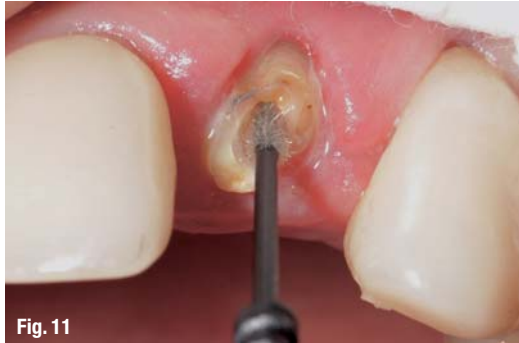**Fig. 9**

**Fig. 10**\_Endodontic preparation using a reamer.

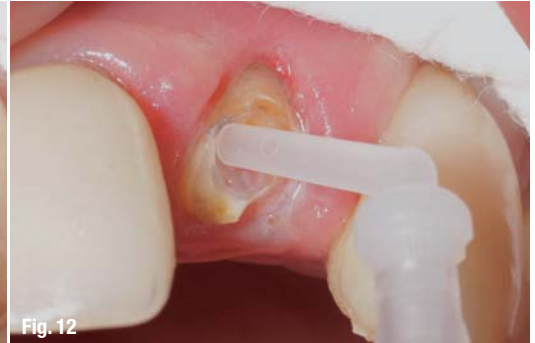

**Fig. 10**

**Fig. 11**\_Conditioning the lumen of the root canal for accepting the endodontic post.



**Fig. 11**



**Fig. 12**

**Fig. 12**\_Applying the resin cement.

of metal posts. One important aspect is the absorption of the vertical lateral masticatory forces, which is better for the resin posts than for the metal posts because the former have material characteristics resembling those of natural dentine. In addition, the optical properties of the system (translucency, transparency) facilitate highly aesthetic anterior solutions while eliminating the risk of corrosive discolouration.

native to implant/prosthetic treatment, provided that the tooth is free of pain, that the preconditions for endodontic treatment are met, and that the root is stable. Today's post-and-core systems are expected to be metal free and to offer easy handling and aesthetic long-term results. Our experience with the Fibrapost and Sealacore system has been positive throughout; they have produced excellent results and suit our procedures well.

Following core shaping and preparation (Fig. 14), a polyether impression was taken for an all-ceramic crown (e.max, Ivoclar Vivadent). The definitive crown was delivered a week after tooth preparation and cemented with a dual-curing self-adhesive cement (RelyX Unicem, 3M ESPE; Fig. 15).

**Fig. 13**\_Fibrapost with retention groups.

**Fig. 14**\_Core placement and preparation.

**Fig. 15**\_All-ceramic crown *in situ*. Note the healthy and complete papillae and periodontal tissues.

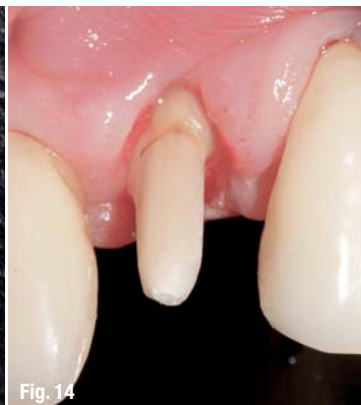**\_Summary**

When the clinical crown of a tooth is lost due to fracture, surgical crown lengthening and tooth restoration based on a post and core is a viable alter-

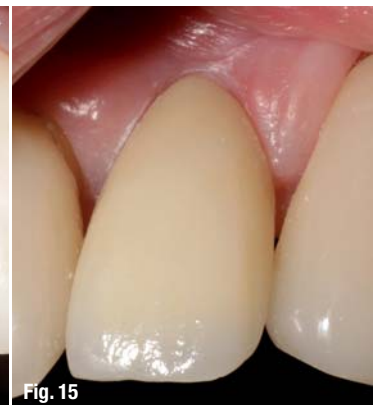_contact	roots
<p><b>Prof Marcel Wainwright</b>                  Dental Specialists and White Lounge Kaiserswerth                  Kaiserswerther Markt 25–27                  40489 Düsseldorf                  Germany</p> <p><a href="http://www.dentalspecialists.de">www.dentalspecialists.de</a></p>	



**Fig. 13**



**Fig. 14**



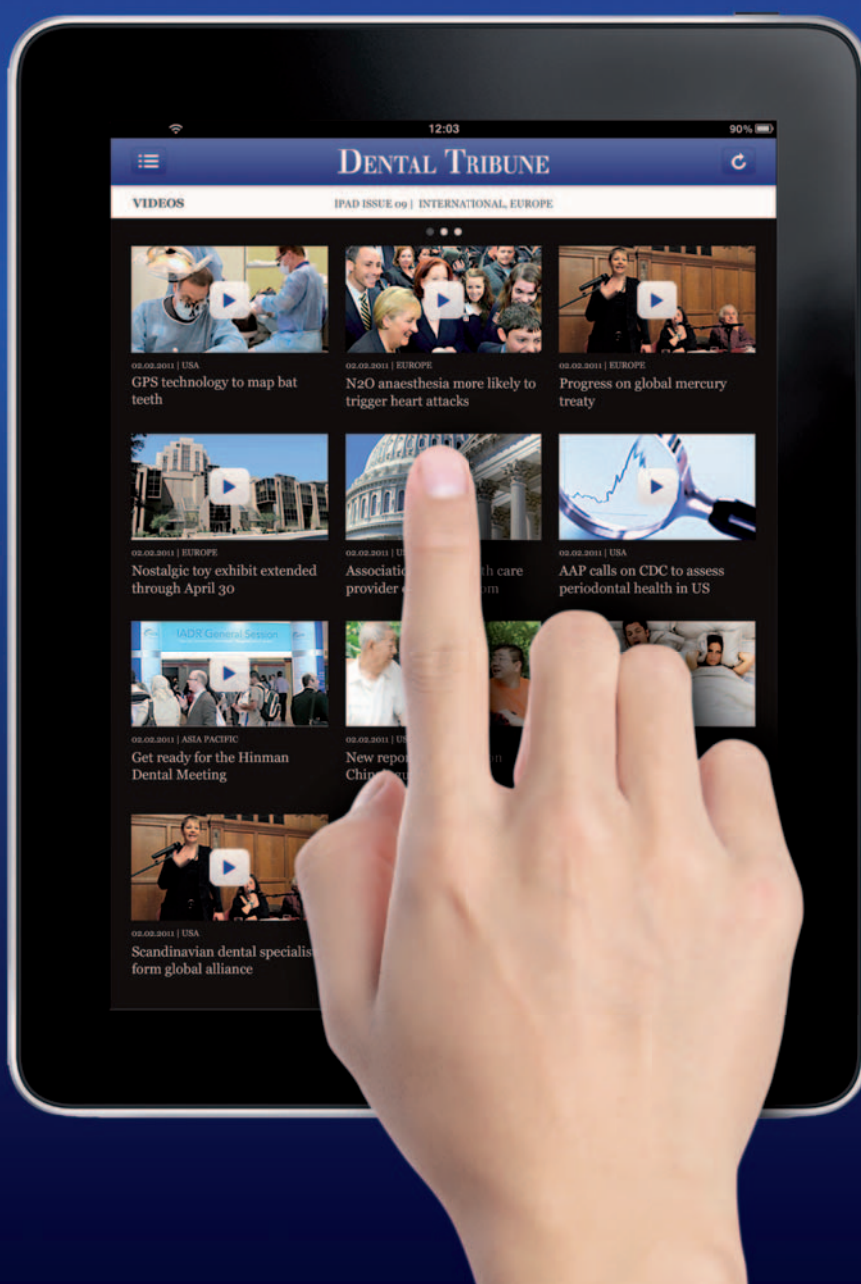**Fig. 15**



# Dental Tribune for iPad – Your weekly news selection

Our editors select the best articles and videos from around the world for you every week. Create your personal edition in your preferred language.

[ipad.dental-tribune.com](http://ipad.dental-tribune.com)



# Vital amputation of permanent teeth

Author\_Dr Robert Teeuwen, Germany

The vital amputation (VA) of deciduous teeth with the goal of maintaining their functionality for a limited period is a widely accepted measure. Vital amputation of permanents, however, is only approved for limited indications. While therapeutic agents such as calcium hydroxide (Ca(OH)<sub>2</sub>) and mineral trioxide aggregate (MTA) are recommended for VAs, formaldehyde (CH<sub>2</sub>O) containing agents are a controversial subject.

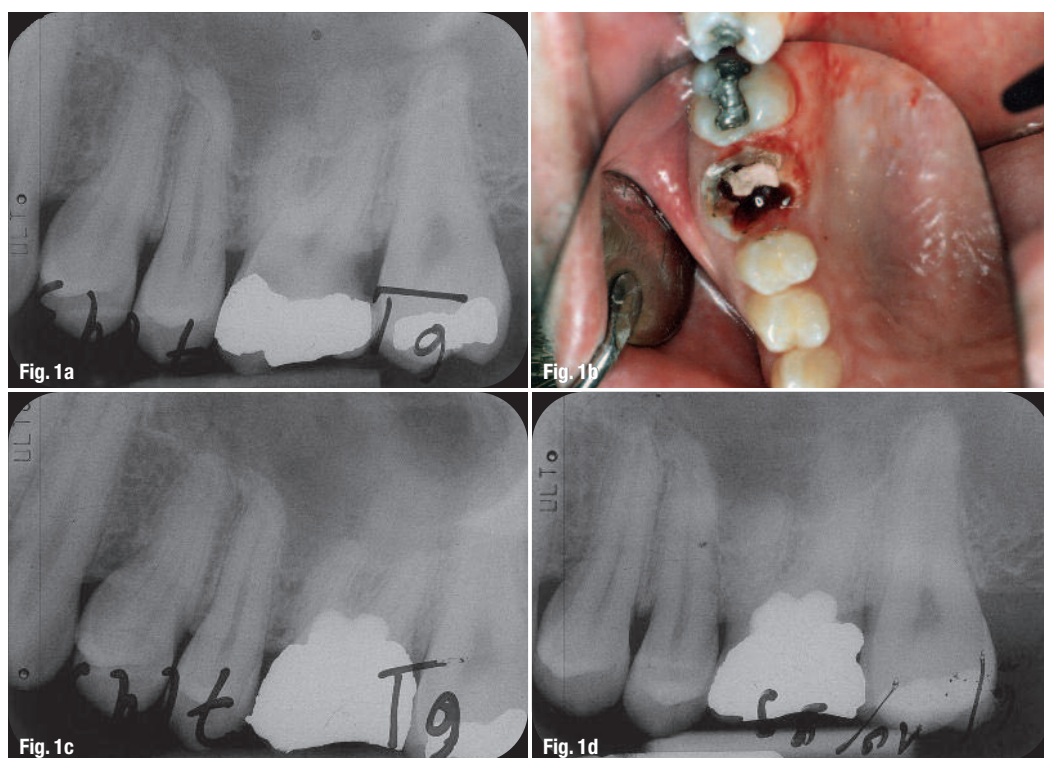
The European Society of Endodontology (ESE) defines pulp amputation as a procedure during which part of the exposed vital pulp tissue is removed with the aim of maintaining vitality and function of the remaining parts of the pulp.<sup>1</sup> ESE recognises the following indications for VAs (i.e. pulpotomy):

1. treatment of deciduous teeth;
2. treatment of permanents with incomplete root growth; and
3. emergency measure.

Indications 2 and 3 include the option of a later definitive root-canal treatment (RCT).

Seidler recommends VA for the accidentally opened pulp of young molars and extremely curved, narrow root canals.<sup>2</sup> Stern considers difficulty in opening the mouth an indication for VAs as well.<sup>3</sup> McDougal *et al.* extend the indication for pulpotomy when there are economic concerns, as some patients are unable or unwilling to bear the expense of a RCT.<sup>4</sup> According to Swift *et al.*, a successful VA may be

**Figs. 1a–d** 24-year-old patient, VA 16 (16 July 1993): before VA (a); heavy bleeding from the pulp after N2 VA, 16 July 1993 (b); after VA and amalgam filling (c); X-ray control, 29 September 1999 (d).



expected following traumatic or mechanical carious pulp exposure.<sup>5</sup> We consider predictable success with the following prerequisites:

- \_ non-inflamed pulp;
- \_ bacteria-proof closure; and
- \_ use of a pulp-compatible capping material.

Seidler states the following regarding the success of VA:<sup>2</sup>

- \_ A higher rate of success is observed in cases of iatrogenic pulp exposure.
- \_ Treatment success is reduced in cases of complete root growth.
- \_ Molars are more successfully treated than incisors.

For a pulpotomy with Ca(OH)<sub>2</sub>, Jensen presupposes that there is no pain existent anamnestically.<sup>6</sup> Teixeira *et al.* corroborate the significance of pain prior to VA.<sup>7</sup> In their study of 41 Ca(OH)<sub>2</sub> vitally amputated permanent teeth, anamnestic pain existed in 12 cases. The pulpotomy of these aching teeth led to failure after six to eight months in 50% of the cases (*n* = 6), while all other vitally amputated teeth were considered successfully treated.

McDougal *et al.* report on 73 eugenol pulpotomies on aching permanent molars and premolars.<sup>4</sup> A clinical success rate of 90% after six months and 78% after 12 months was observed. The teeth, which were free of pain at check-up, were radiologically controlled and it was shown that 49% of the teeth were free of pathological findings after six months and 42% after 12 months.

According to Jensen, pulpotomy is an attempt to stimulate hard tissue healing at the area of amputation.<sup>6</sup> Fountain and Camp point out that a pulpotomy may result in canal calcification, internal resorption or necrosis of the pulp.<sup>8</sup> Kozlow and Massler refer to literature that reports the formation of a dentine bridge in rat teeth under non-calcium-containing materials, such as wax, amalgam, acrylic resin and zinc oxide eugenol.<sup>9</sup> In human teeth, the bridging under Ca(OH)<sub>2</sub> was successful in 43% of the cases and under antibiotics in 23% of the cases. During their own tests on rat teeth, the authors assessed good reparative reactions with complete bridging following pulpotomy with Ca(OH)<sub>2</sub>, zinc oxide eugenol, cortisone and silver amalgam.

According to Alacam, various materials are recommended for pulpotomy: Ca(OH)<sub>2</sub>, formocresol, glutaraldehyde, ferrous sulphate, zinc oxide eugenol and polycarboxylate cement.<sup>10</sup> Salako *et al.* compared MTA, formocresol, ferrous sulphate and bio-active glass with regard to their pulpotomy compat-

ibility and found MTA to be the ideal pulpotomy agent.<sup>11</sup>

Agents that contain CH<sub>2</sub>O and Ca(OH)<sub>2</sub> are historically established VA agents for deciduous and permanent teeth. Massler *et al.* report a clinical success rate of 92% following VA with Ca(OH)<sub>2</sub>.<sup>12</sup> Taking post-operative X-rays into account, the success rate was reduced to 75% after one year and dropped to 65% after two to five years. The authors suggest several reasons for this failure:

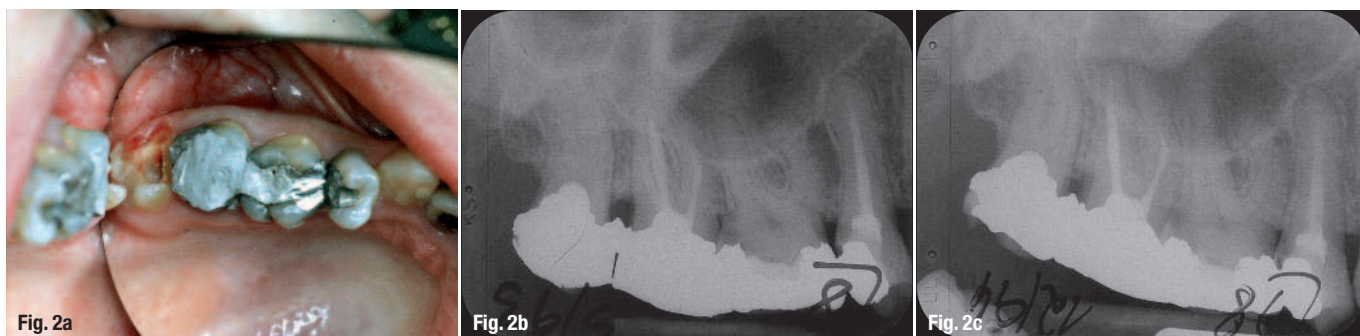
- \_ pulp already heavily inflamed initially;
- \_ too much pressure applied during application; and
- \_ disposal of the blood coagulum via haemostatic agents.

1 <sup>st</sup> group (31 teeth)	2 <sup>nd</sup> group (6 teeth)
(no pathological findings radiographically, no anamnestic pain) 17 teeth with complete root growth, 14 teeth with incomplete root growth	3 with periodontal gap enlargement – 2 of them with pain, 3 with apical ostitis, 5 teeth with complete root growth, 1 tooth with incomplete root growth.
<b>Table I</b>	

Mejäre and Cvek performed partial pulpotomies using Ca(OH)<sub>2</sub> on 37 permanent teeth (35 molars, 2 premolars).<sup>13</sup> The patients were six to 15 years old and their pulpotomy had to be performed at least two years prior to inclusion in the study. Check-ups were performed at an average of 56 months (24 to 140). The teeth were separated into two groups (Table I). Two failures occurred in the first group, in teeth with incomplete root growth (after ten days and 48 months). The other 29 teeth (93.5%) were treated successfully. In the second group, two failures occurred (after 10 and 24 months) in teeth with periodontal gap enlargement (one tooth with complete root growth and the other with incomplete root growth).

Molven states that there were no pathological findings in 1,391 root-filled roots in 51.6% of the cases and in 236 pulpotomized roots in 65% of the cases.<sup>14</sup> Asgary and Eghbal report the successful use of a new VA agent called CEM, a cement mixture enriched with Ca, in 205 pulpotomies on molars.<sup>15</sup> For comparison, 202 molars were extirpated vitally. The root-canal filling (RCF) was performed via lateral condensation with AH Plus (DENTSPLY DeTrey) as sealant. After seven days, 38% of the pulpotomy-treated and 60% of the root-canal-treated patients reported needing analgesics. After six months, 88.94% of the patients underwent a radiological check-up. The pulpotomy patients revealed a significantly higher success rate (*p* < 0.001).

The most frequently used VA agent for deciduous teeth is formocresol, a mix of CH<sub>2</sub>O, cresol, glycerine



**Figs. 2a–c** 30-year-old patient, VA 28 (3 May 1993): prepared cavity (a); after VA and amalgam filling (b); X-ray control, 17 December 1994 (c).

and water. A survey showed that formocresol pulpotomies on deciduous teeth were performed by general dentists in 73% of the cases and by paediatric dentists in 98.2% of the cases.<sup>16</sup> The frequency of use on permanent teeth was lower: 18.9% for general and 55.4% for paediatric dentists.

Frankl considers the advantage of pulpotomy compared with RCT as there being no instrument fractures or perforations during pulpotomy.<sup>19</sup> A possible failure could always be countered with a RCT. He asserts that Ca(OH)<sub>2</sub> pulpotomies can be successful only if teeth are asymptomatic prior to treatment and for accidentally opened pulp and, therefore, bleeding from the pulp.

Powder	Liquid
Zinc oxide 63.0 %	Eugenol 77.0 %
Titanium dioxide 3.6 %	Rose oil 1.8 %
Bismuth subcarbonate 10.0 %	Lavender oil 1.2 %
Bismuth subnitrate 15.0 %	Peanut oil 20.0 %
Paraformaldehyde 7.0 %	
Red lead (lead oxide) 1.4 %	

**Table II**

Fisch published the results of pulp amputations of 600 teeth, which were performed with the CH<sub>2</sub>O-containing preparation Triopaste.<sup>17</sup> Check-ups were done between six months and 18 years after amputation. Examination of the X-ray controls revealed a pathological apex in 9%. Eleven teeth were histologically examined. Hard substance formation was observed in the form of apical foramen closures and apposition at the lateral canal walls, which partially led to obliteration of the canal lumen.

During an accelerated test lasting up to 2.5 months, Overdiek tested N2 as CH<sub>2</sub>O-containing VA agent on human teeth. He observed that for several weeks following N2 application there was a possibility of a hard substance barrier forming.<sup>18</sup>

Over a period of 12 years, Stern<sup>3</sup> carried out 175 N2 pulpotomies under relative isolation on teeth with complete root growth, regardless of possible anamnestic pain. Fifteen per cent of the patients experienced increased pain after treatment, which subsided within 48 hours. Four patients, however, developed pulpitis, which resulted in the extraction of three teeth and conservative RCT of one tooth. Stern was able to track the outcome of 35 vitally amputated teeth over a longer period. During the course of check-ups, two teeth were extracted, one of them due to a fracture. Five years after treatment, Stern observed advancing calcification of the nerve channels.

According to the literature, N2 VA on deciduous teeth renders significantly better results than Ca(OH)<sub>2</sub> pulpotomy. Therefore, Frankl performed N2 pulpotomies on permanent teeth as well.<sup>19,20</sup> He selected only asymptomatic teeth whose pulp had been accidentally exposed for treatment. The treatment was performed under a rubber dam and thus pulp bleeding did not have any effect. Two hundred and fifty cases were re-examined for up to 13 years. The age of the patients ranged between 22 and 55 years. Failures manifested by pain within 48 hours amounted to 2%. The aim of the following study was to analyse the success and failure rates of N2 VAs on permanent molars, and to compare these rates with vital molar extirpations done within the same period.

### Material and method

The study was conducted in my dental practice, which is located in a rural area. Between 1992 and 1998, 795 VAs and 945 vital extirpations (VEs) were performed on molars. After treatment, 85 VA and 93 VE patients did not return to the practice and were thus excluded from the study, leaving 710 VAs and 852 VEs for analysis.

During the treatment period, only N2, which was approved by the district president of Düsseldorf, Germany, on 8 February 1990, was used as therapeutic agent (see Table II for composition).

The root canals were prepared according to the N2 method: relative isolation, no root-canal rinsing and root-canal preparation with reamers only.<sup>21</sup> For the RCF, N2 mixed to a creamy consistency was applied with a lentulo spiral. The VA cavities were prepared 1 to 2 mm into the canals. N2 mixed to a paste was

# FDI World Dental Federation

Leading the World to Optimal Oral Health

## 2012 Hong Kong FDI Annual World Dental Congress

29 August - 1 September 2012

Join us in Hong Kong, world capital of oral health 2012

### for a

- unique global perspective in dentistry and oral health
- face-to-face encounters with your peers worldwide
- range of views from the international experts
- pick of the latest news of groundbreaking dental research
- joint celebration of the 100<sup>th</sup> FDI Annual World Dental Congress

### with featured

top-flight national, regional and international speakers to address the most important challenges and issues in dental practice, enabling dentists and dental teams to transfer cutting edge knowledge into their daily clinical work and management of their practices.

### in a

- meeting point of the ancient and the innovative
- world-class focal point of trade, business and technology
- vibrant and bustling city of cultural diversity
- centre of tourism and leisure

### and showcasing

the latest technology and equipment development from leading international companies at the world dental exhibition

**29 August to 1 September 2012**

Hong Kong Convention and Exhibition Centre  
Hong Kong, S.A.R. China

Deadline for abstract submission: 30 March 2012  
Early Bird registration until 31 May 2012



*Leading the world into a new century of oral health*

[www.fdicongress.org](http://www.fdicongress.org)

[congress@fdiworldental.org](mailto:congress@fdiworldental.org)

inserted into the cavity with a filling instrument and lightly pressed with cotton. Minor bleeding was irrelevant. In cases of heavier bleeding, the inserted N2 was removed after a few minutes and then replaced with freshly mixed N2. A synthetic closure of the cavity performed within the same sitting required a lining, which is not necessary for an amalgam closure. X-ray controls were later viewed at double and sevenfold magnification. The apical condition was differentiated as follows: apically without pathological findings, apically uncertain and apically pathological. The root with the worst apical findings was evaluated. This was also applicable for the classification of RCF levels.

Failures without accompanying X-rays were termed Mi1 and failures with accompanying X-rays were termed Mi2. The total failure percentage was not determined by simply adding Mi1 and Mi2, but by adding the number of Mi1s to the number of X-rays taken. The percentage of failures was then determined from this sum. The statistical analysis was performed using SPSS (version 18).

### Results

Of the VA patients 47.6% were male and of the VE patients 52.4% were male. The practice owner treated 70.1% ( $n = 498$ ) of the VA patients and 49.1% ( $n = 418$ ) of the VE patients and all the rest were treated by an assistant. The average age of VA patients was 34.6 years and that of VE patients was 30.6 years. The average observation period was 53.8 months (max. 165) for VAs and 49.4 months (max. 169) for VEs. Of the 710 VA cases 504 (71%) and of the 852 VE cases 496 (58.1%) were subject to follow-up X-ray controls.

A total of 61 VA and 77 VE failures were registered and classified as without accompanying X-ray (Mi1) or with accompanying X-ray (Mi2). Fifty-one of the 61 VA

failures were followed-up with X-rays. Not all of the accompanying X-rays of the Mi2 failures revealed a failure.

Two VA failure X-rays and ten VE failure X-rays were wrongly evaluated as negative. Ten VA Mi1 cases were removed because of pain, three of them within a few hours after VA.

In two cases, a granuloma at an extracted root was indicated in the patient files. In two additional cases, the extraction followed after six and 11 days. In 12 of the 16 VE cases, extractions were performed because of pain (one day to 21 months after VE). Patients who visited the practice after pulpotomy made positive a negative reference to anamnestic symptomatic pain 241 times and 157 times, respectively. Subsequently, the failure rate was 10.8% ( $n = 26$ ) in the first case and 7.0% ( $n = 11$ ) in the latter case. The difference was insignificant statistically ( $p = 0.114$ ).

The failure diagnosis after VA was most frequently made for the lower second molar (18.5%) and after VE for the lower first molar (19%). The lower wisdom teeth were conspicuous because the failure rate was only 4.7% after VA, and no failure at all was observed after VE. Not every failure diagnosis led to therapeutic consequences such as extractions.

Altogether, 206 (28.6%) VA and 123 (14.4%) VE teeth were extracted during the follow-up phase (very statistically significant difference;  $p = 0.000$ ). The largest number of extractions, namely 51.9% ( $n = 107$ ) of the VAs and 46.3% ( $n = 57$ ) of the VEs, were performed because the teeth had been destroyed or fractured. The lower wisdom teeth were the most frequently affected in the case of pulpotomy (61.8%;  $n = 21$ ) and the upper second molars in the case of VE (64%;  $n = 16$ ).

Table III Summarised VE results.

Tooth	Σ	I		II		III		Failure IV			V	VI	
		Recall		Extraction		X-ray post VE		IV a Mi 1	IV b Mi 2		IV c Mi 3	X-ray + Mi 1	Fail. Σ
		n	%	n	%	n	%	n	n	%	n	n	%
16/26	269	241	89.6	42	17.4	142	58.9	3	22	15.5	25	145	17.2
17/27	168	152	90.5	25	16.4	89	58.6	4	7	7.9	11	93	11.8
18/28	5	5	100	1	20.0	2	40.0	-	-	-	-	2	-
36/46	274	249	90.9	24	9.6	148	59.4	4	25	16.9	29	152	19.0
37/47	201	177	88.1	25	14.1	97	54.8	3	9	9.3	12	100	12.0
38/48	28	28	100	6	21.4	18	64.3	-	-	-	-	18	0,0
	945	852	90.2	123	14.4	496	58.2	14	63	12.7	77	510	15.1

Tooth	Σ	I		II		III		Failure IV			V	VI	
		Recall		Extraction		X-ray post VA		IV a Mi 1	IV b Mi 2	IV c Mi 3	X-ray + Mi 1	Fail. Σ	
		n	%	n	%	n	%	n	n	%	n	%	
16/26	109	98	89.9	23	23.5	73	74.5	1	7	9.6	8	74	10.8
17/27	202	179	88.6	45	25.1	127	70.9	3	9	7.1	12	130	9.2
18/28	112	100	89.3	41	41.0	72	72.0	2	9	12.5	11	74	14.9
36/46	118	111	93.2	28	27.0	78	70.3	2	8	10.3	10	80	12.5
37/47	140	123	87.6	35	37.8	90	73.2	2	15	16.7	17	92	18.5
38/48	114	99	86.8	34	34.3	64	64.6	-	3	4.7	3	64	4.7
	795	710	89.3	206	28.6	504	71.0	10	51	10.1	61	514	11.9

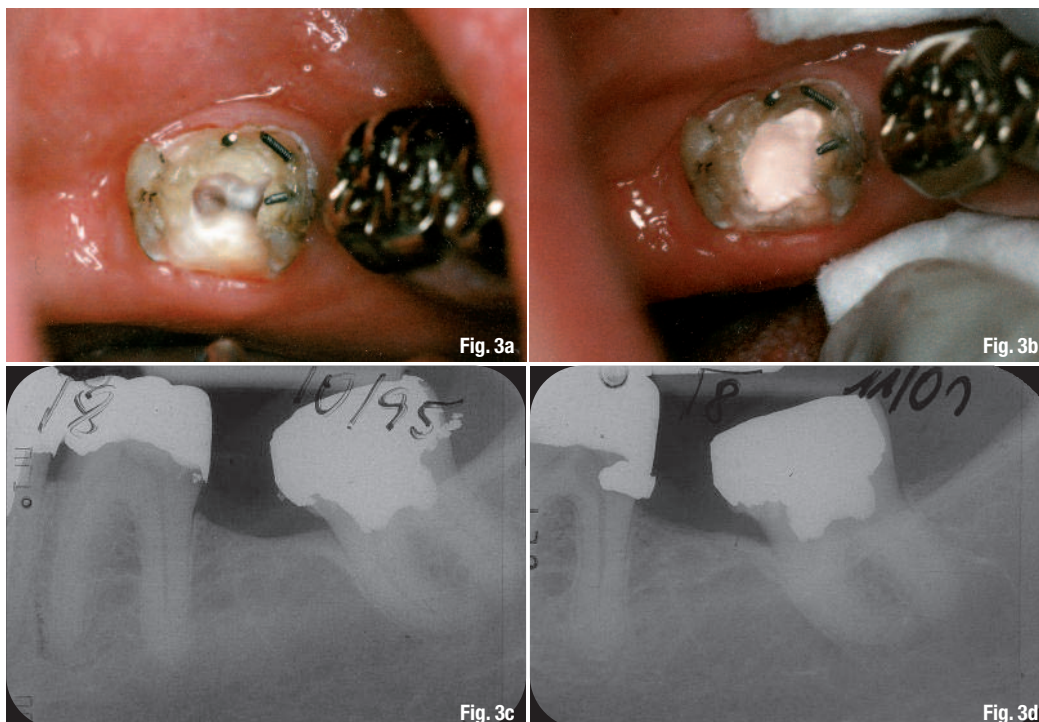
A failure was decisive for the removal of 23.3% ( $n = 48$ ) of the extracted VA teeth and 36.6% ( $n = 45$ ) of the extracted VE teeth. Most frequently extracted due to failure were the vitally amputated upper second molars (34.8%;  $n = 8$ ), and the vitally extirpated lower second molars (54.2%;  $n = 13$ ). The lower wisdom teeth (34 extractions ( $n = 3$ ; 8.8%) in the pulpotomy group) and the upper second molars (42 extractions ( $n = 13$ ; 31%) in the VE group) were extracted least often. The VE and VA results are shown in Tables III and IV.

Furthermore, the question of whether the RCF level following VE had any significance with regard to the failure rate was pursued. The RCF levels were

divided into three levels. The total failures of these three groups were calculated as described under material and method (Table V).

Without considering the indication range, anamnestic symptoms, tooth position and RCF level, the total failure rate was 11.9% for VAs and 15% for VEs (statistically insignificant;  $p = 0.644$ ). The VE failure rate of the RCF level of -4, -3 corresponded exactly to the VA failure rate of 11.9%. There was no statistically significant difference ( $p = 0.226$ ) in failure between RCF levels -4, -3 and -2, -1, 0. The RCF level of -5 showed significantly more failures compared with the RCF levels of -4, -3 ( $p = 0.020$ ) and -2, -1, 0 ( $p = 0.002$ ).

Table IV\_Summarised VA results.



Figs. 3a-d\_53-year-old patient, VA 38 (31 October 1995): prepared cavity (a); N2 applied (b); after VA and amalgam filling (c); X-ray control after six years (d).

## Discussion

A direct comparison between VAs and VEs, especially as regards incomplete root fillings, was only possible within limits, as the number of VAs consisted mainly of a negative selection, which otherwise would have been entrusted to the pliers. The twice as high extraction frequency of vitally amputated teeth compared with that of vitally extirpated teeth (28.6% versus 14.4%) may be attributed to the adverse baseline situation. Fractured or destroyed teeth were the reason for extraction for 51.9% of all extractions in the case of VAs. For VEs, this rate was 46.3%. However, the extraction reason "endodontic failure" was attributed in 36.6% of the extractions to the VA teeth and in 23.3% of the VE teeth.

RCF level	X-ray + Mi1	Failures	
	n	n	%
-5	195	43	22,1
-4, -3	194	23	11,9
-2, -1, 0	124	11	8,9

**Table V** VE failures of molars according to RCF levels.

Anamnestic pain causing an increased frequency of failure in VA cases, which was also observed by Teixeira *et al.* following Ca(OH)<sub>2</sub> treatment,<sup>7</sup> was statistically insignificant. Stern<sup>3</sup> und Frankl<sup>19,20</sup> also point out increased pain following VA. This was observable during our study as well. Nevertheless, the total failure rate for vitally amputated teeth was lower (11.9%) than the average rate of 15.1% for vitally extirpated teeth.

The evaluation of pulpotomy cases only with accompanying X-rays revealed a failure rate of 10.1%, which is comparable to the 9% Fisch encountered with the Triopaste.<sup>17</sup> Frankl reports only 2% of failures after N2 VA, although he had done stringent case selection.<sup>19,20</sup> In contrast, the radiological-pathological findings concerning eugenol pulpotomies in pain-free teeth amounted to 58% after 12 months.<sup>4</sup> Fifty per cent of all Ca(OH)<sub>2</sub> pulpotomies of aching teeth resulted in failure after six to eight months.<sup>7</sup> Massler *et al.* observed a total failure of 65%, two to five years after Ca(OH)<sub>2</sub> VAs.<sup>12</sup>

The correlation between failure and RCF level following VEs was investigated. Adequately filled teeth (-2, -1 *ad apicem*) showed a failure rate of 8.9%, heavily underfilled teeth a rate of 22.1%. Hence, the conclusion may be drawn that the success rate of VAs corresponds to the one of properly performed root fillings following VEs, and is far superior to a noticeably underfilled root filling. Molven attributes a more favourable peri-apical situation to pulpotomized than to root-filled roots.<sup>14</sup>

In their study, Asgary and Eghbal do not explain the technical performance of the RCF.<sup>15</sup> However, they establish that pulpotomies are statistically significantly superior to RCTs of vital molars, although radiological failure is neither defined nor numerically expressed. Additionally, the follow-up time of six months is considered very brief.

## Summary

A comparison of 710 N2 VAs and 852 N2 root-filled molars after VE was done. The average follow-up period was 53.8 months for VAs and 49.4 for VEs. The total failure rate (radiological and clinical) was 11.9% following VAs, which is equivalent to that of VEs with slight underfilling (RCF level -4, -3). Adequately filled root canals led to fewer failures (8.9%) than VAs. With a failure rate of approximately 19%, the lower first VE- and second VA-molars were most frequently affected.

During the follow-up period, 28.6% of all VA and 14.4% of VE teeth were extracted. Fractured or destroyed teeth were the reason for extraction in 51.9% of all VA and in 46.3% of all VE cases. The extraction reason "endodontic failure" occurred less frequently after VA (23.3%) than VE (36.6%).

## For the practice

The patient should be advised of possible pain following the subsiding anaesthetic effect. Analgesics are indicated after VA. An N2 VA is more successful than an insufficient root filling after VE. Vital amputation is indicated in cases of almost inaccessible canal systems, open apical foramina and for economic reasons.

Instead of an extraction or the impossibility of a VE with adequate root filling, it is possible to consider—besides a full pulpotomy, which was the subject of the present study—a partial pulpotomy on:

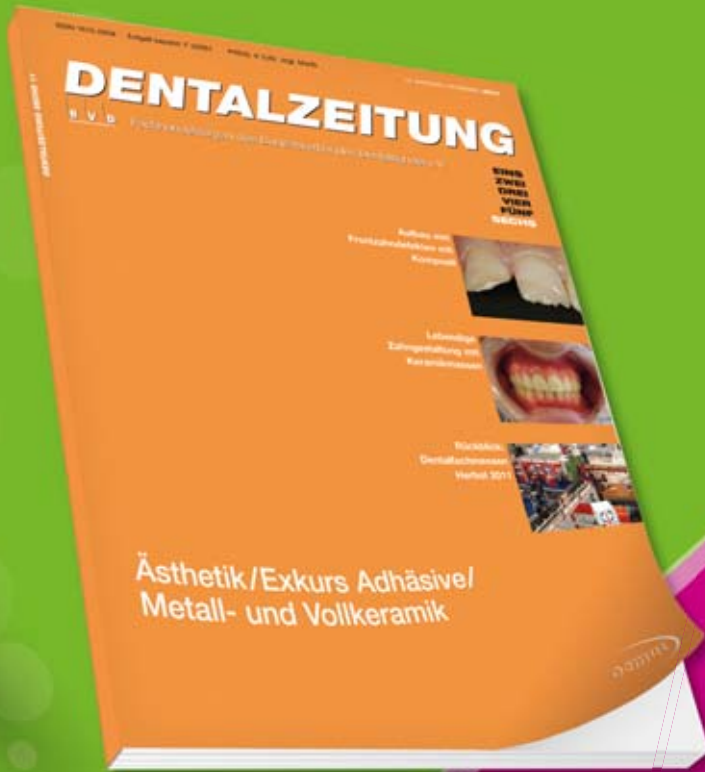- \_upper molars: VA of the buccal canals, filling of the palatal root;
- \_lower molars: VA of the mesial canals, filling of the distal root; and
- \_deep crown margin caries, partial removal of the pulp cavum.

*Editorial note: A complete list of references is available from the publisher.*

_contact	roots
	<p><b>Dr Robert Teeuwen</b>                  Berliner Ring 100                  52511 Geilenkirchen                  Germany</p> <p>robteeuwen@t-online.de</p>



# INNOVATION + INFORMATION



Fax: +49 341 48474-290

You can also subscribe via [www.oemus.com/abo](http://www.oemus.com/abo)

[www.oemus.com](http://www.oemus.com)

I would like to subscribe to **Dentalzeitung** (6 issues per year) for € 34 including shipping and VAT for German customers, € 36 including shipping and VAT for customers outside Germany, unless a written cancellation is sent within 14 days of the receipt of the trial subscription. The subscription will be renewed automatically every year until a written cancellation is sent to OEMUS MEDIA AG, Holbeinstr. 29, 04229 Leipzig, Germany, six weeks prior to the renewal date.

I would like to subscribe to **ZWP** (10 issues per year) for € 70 including shipping and VAT for German customers, € 72 including shipping and VAT for customers outside Germany, unless a written cancellation is sent within 14 days of the receipt of the trial subscription. The subscription will be renewed automatically every year until a written cancellation is sent to OEMUS MEDIA AG, Holbeinstr. 29, 04229 Leipzig, Germany, six weeks prior to the renewal date.

Last Name, First Name

Street

ZIP/City/County

Fon, fax

E-mail

**Notice of revocation:** I am able to revoke the subscription within 14 days after my order by sending a written cancellation to OEMUS MEDIA AG, Holbeinstr. 29, 04229 Leipzig, Germany.

Signature

Signature

# The passive income practice

Author\_Dr Phillip Palmer, Australia

Photos: Yuri Arcurs

Exit planning has traditionally been a fairly simple task for dentists. The choices a dentist faced were either winding down the number of days worked, thereby gradually easing into retirement, or working until three to six months before wanting to stop, and then advertising the practice for sale. After negotiations with the buyer, dentists would sell and walk away—much like a house sale. Sometimes there would be a good handover of patients and staff, and sometimes this process would be less than ideal.

More recently, other options for exit planning have become available for practice owners. Over the last three to four years, for example, many dentists in Australia having sold their practices stayed on to work as employee dentists for the new owner. This model in particular has increased in popularity recently with corporate entities often being the buyer. Another model is deferred sale/employee with view, whereby a new dentist (Dr Junior) works for a year as an employee for Dr Senior. If all goes well, a contract is signed for the purchase of half (or even all)



the practice in some years hence. The employed dentist continues to work as an associate, and the transaction is settled after the agreed time. This technique assures Dr Senior both a buyer and extra income from Dr Junior during the years as an employee. Through the incremental percentage technique, after a similar trial period, the practice contracts are exchanged and incrementally each year a further percentage of the practice changes hands from Dr Senior to Dr Junior.

In each case, after the practice is sold, the ex-owner commonly takes the money he made from the sale, goes on a holiday and then invests whatever is left in real estate or the stock market to fund his retirement. For a practice here in Australia grossing say AUS\$800,000 per year, if sold on the open market could bring up to AUS\$500,000. If that entire sum were used to purchase a residential investment property, one would be lucky to net more than AUS\$30,000 per year, and probably less, to fund retirement.

Another way to exit plan and fund a dentist's retirement is to establish the passive income practice, also known as the "never sell concept". Using this method, the practice is set up in such a way as to be self-managed, with little effort (1 day/month) needed from the owner when the practice is mature. The profit from the practice can be as high as 30% after payment of all normal expenses and clinicians' wages.

If maintained as a going concern and run properly, there is no reason to expect a return from the AUS\$800,000 grossing practice of less than AUS\$200,000 p.a. (and still maintain an asset worth at least AUS\$500,000).

Obviously, for this option to work, the practice and the staff need to be trained to be self-managed and to provide a certain level of service and communication. Basically, they would need to have a

deep knowledge and understanding of the systems needed to run a practice.

Some degree (the more, the better) of management, leadership and business skills is also required by the owner, including the ability to look at and analyse the right numbers or to motivate key staff members to manage the practice and outperform through the judicious use of incentives, including well-designed bonus systems. As the owner dentist is no longer present full-time in the passive income practice, there also needs to be regular training in communication and the provision of service, i.e. clinical training.

There definitely needs to be more than one clinician. Rarely is there sufficient profit over and above the employee dentist's wage (40% after lab) to warrant running the practice as a business with such a small staff.

There are plenty of horror stories out there, especially after the global financial crisis, of retired dentists needing to return to practice because the practice sale did not fund their retirement the way they expected it to. The never sell concept represents a new way of looking at the asset that is your practice and how it can bring you returns long after your clinical career comes to an end.

#### \_about the author

CAD/CAM



Former dentist **Dr Phillip Palmer** is currently Director of Prime Practice and Dentist Job Search and regarded as Australia's leading expert in the business of dentistry. He can be contacted at [info@primepractice.com.au](mailto:info@primepractice.com.au).

# Critical thinking: The missing link in endodontic education

Author\_ Dr Barry Lee Musikant, USA

After years of teaching endodontic programmes around the country, I can say with strong conviction that the process of critical thinking has not been applied to the mechanics of endodontics. Not for one moment am I critical of a programme's emphasis on diagnosis, histology and pathology. The incorporation of microscopes has vastly improved dentists' abilities to seek out fine structure that can be the difference between success and failure.

perform the entire shaping procedure or to create a glide path for the subsequent use of rotary NiTi files.

If K-files had been chosen as the most appropriate instrument to use after critical analysis, we would expect these instruments at least initially to shape canals more easily than other instruments. We would expect that such problems as loss of length because of the apical impaction of debris, distortion to the outside wall, elbowing and frank perforation would be less inclined to occur because of superior design and method of usage. Yet K-files are associated with all the above problems, whereas their counterpart, K-reamers, is far less likely to produce such issues. In fact, critical thinking was not applied to the choice of instruments. Tradition, inertia and simple prejudice take the place of effective analysis.

Let's examine how critical analysis would prevent this widespread mistake that is perpetrated on our student bodies over the years. Take a look at a photograph of a K-file (Fig. 1). Please note that the shank is composed of 30 flutes along its 16mm of working length. The greater the number of flutes, the more horizontally oriented they are. Compare the 30 flutes on a K-file to the 16 that are present on the shank of a reamer (Fig. 2). Also, please note that with approximately half the flute number, each flute is significantly more vertically oriented along the length of the reamer shank. Fewer flutes lead to less engagement along length. Resistance in apical negotiation is directly related to the reduction in engagement.

A watch-winding motion is the recommended way to use both the reamers and the K-files. Yet, when a watch-winding motion is applied to the more hori-




Fig. 1

Fig. 1\_Photograph of a K-file. Note the high number of flutes that are more horizontal in nature.

Where critical thinking is missing is in the selection of the design and utilisation of the instruments used to shape the canals. For the most part, K-files are the instruments recommended for the initial shaping of canals. I have never detected any evidence that the decision to use K-files resulted from an analysis of what works best. It is simply a tool that has been handed down from generation to generation either to




Fig. 2

Fig. 2\_Photograph of a relieved reamer. Note the flat side and the vertical flutes.

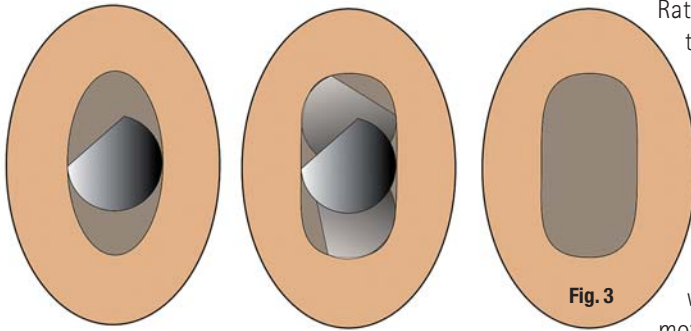


Fig. 3

Rather, he must remove the reamer from the canal, place a 45° bend at the tip and, with a light peck-and-twist motion, attempt to manually negotiate around the obstacle. On the other hand, if tug-back is present from the outset, the dentist knows to continue apical negotiation using either the recommended watch-winding motion or a twist-and-pull motion until the apex is reached.

Fig. 3 Illustration of an asymmetrical instrument's ability to distinguish and clean an oval-shaped canal.

zontally oriented flutes of a K-file, the threads tend to embed themselves into the canal walls without shaving any of the dentine away in the process. Increasing the amount of engagement does not help in shaping the canal. Compare the action of these flutes with the more vertical orientation of the flutes on the reamer. Using the same watch-winding stroke applied to the K-files, the blades being more at right angles to the plane of motion will immediately start shaving dentine from the walls of the canal, further reducing the degree of engagement and the subsequent resistance encountered as the reamers negotiate apically.

Clinically, the dentist encounters less resistance when using reamers because there is less engagement along length, resulting from fewer flutes to begin with and their greater ability to shave dentine rather than embed into it. Embedment leads to increased resistance. Shaving dentine further reduces the smaller amount of engagement that was already present. The design and utilisation of the K-file works against the very goals it wants to attain. Reamers are designed and utilised in a way that is compatible with their goals. Critical thinking would make these basic points obvious. Controlled clinical testing of both designs would immediately demonstrate the superiority of reamers to K-files.

The comparison could easily stop at this point, and reamers would be the unquestioned winner, but there are other advantages that accrue to the user as well. With less engagement along length, a cutting blade more or less at right angles to the plane of motion that removes dentine rather than embeds into it, a more flexible instrument that is a consequence of fewer twists along the length of the shank, the reamer gives the dentist a superior tactile perception, giving him the ability to differentiate between the tip of the instrument hitting a solid wall or engaging within a tight canal. Both situations will either stop or slow down apical progress.

However, if the tip of the instrument is hitting a wall, there will be no tug-back when the reamer is withdrawn, telling the dentist that he must not attempt to proceed further.

A K-file that is already so heavily engaged along length cannot make the distinction between a solid wall and a tight canal. The resistance along length obscures what the tip of the instrument is encountering. Using a K-file, all a dentist may know is that he is short of length. Using an aggressive twist-and-pull motion, the proper length can be regained even when employing a K-file with a non-cutting tip. However, too often the dentist will discover that the original anatomy has been lost with the apical third transported to the outside wall of a curved canal. This is the effect when a solid wall or impacted debris is encountered, but not recognised as such because of the excessive engagement of the K-file along length.

The absence of critical thinking is recapitulated by maintaining the continued use of K-files. First, we abdicate the use of reamers without making any comparisons. Worse, while not learning the benefits of reamers, we also lose our evolutionary potential to improve upon a tool that in its present state is superior to K-files.

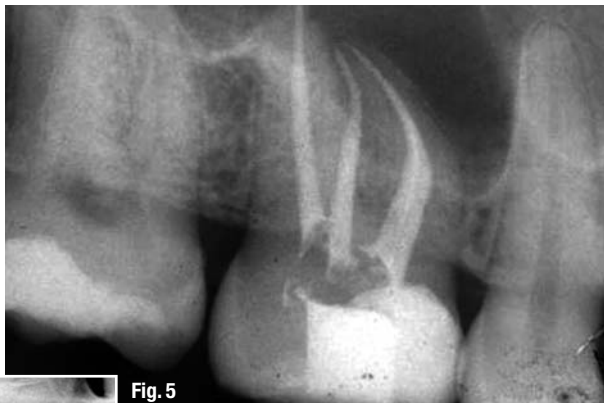Critical thinking demonstrates that reamers are superior to K-files for several reasons, one of the main reasons being reduced engagement along length. By placing a flat along the entire working length of the reamer, we now have a reamer that has even less engagement along its working length. The result is an



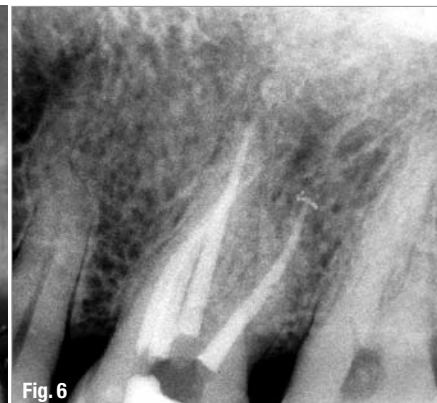Fig. 4

Fig. 4 The Endo-Express reciprocating handpiece (Essential Dental Systems).

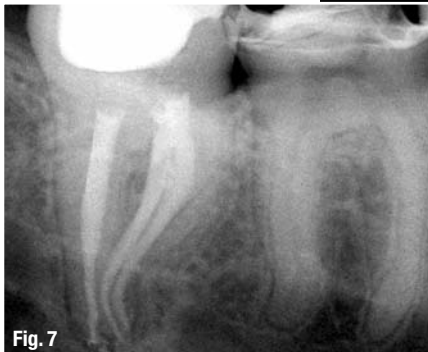**Figs. 5–7** Radiographs showing clinical results achieved with relieved reamers in a reciprocating handpiece.



**Fig. 5**



**Fig. 6**



**Fig. 7**

instrument that is even more flexible because it is thinner in cross-section, includes two vertical columns of chisels that cut equally effectively in both the clockwise and counter-clockwise direction and is asymmetrical in cross-section, giving it the ability to differentiate between a round and oval canal. No symmetric instrument can differentiate between a round and oval canal.

The ability to make this distinction tells the dentist when to widen the canals to greater dimensions for superior mechanical cleansing and better chemical debridement via the irrigants (Fig. 3).

Without critical thinking, no one knows that a reamer is superior to a K-file and without that knowledge, no one knows that a reamer can be modified to further improve its functionality. Perhaps, most importantly, without the benefit of critical thinking, those designing instruments to eliminate the shortcomings of K-files do not eliminate them. They merely reduce them, still incorporating their use in the creation of the glide path<sup>1</sup>, and then proceed to introduce rotary NiTi systems that, while overcoming the limitations of K-files, introduce significant new problems that add cost, anxiety and unpredictability to canal shaping.

In the meantime, critical thinking would clearly demonstrate that relieved reamers (Fig. 3) are not only good for glide path creation but work far more safely when used for the entire shaping procedure. Stainless-steel relieved reamers are quite effective at recording the curvatures of a canal.<sup>2</sup> Unlike NiTi, they do not snap back to the straight position, a property that increasingly distorts the apical end of curved canals as the tip size and taper of the instruments increase.

The greater stiffness of stainless steel is compensated for by the relieved reamer design, never exceeding a .02 taper and routinely straightening the coronal curve prior to the use of larger-tipped instruments. Used either in a tight watch-winding stroke or in a

30° reciprocating handpiece (Fig. 4), the tip of the instrument confined to such a short arc of motion always stays centred in the canal. As long as patency is maintained, these relieved reamers will not deviate from the original pathway. Patency<sup>3</sup> is maintained by going 0.5 mm beyond the constriction through a 25 relieved reamer, a technique that is easy to master and is completely predictable in its results.

Unless one is exposed to the critical thinking needed to open one's mind to better working alternatives, the entire cascade of learning is stopped before it starts.

Without critical thinking, one will never learn that reamers are safer, more efficient and more effective than K-files. Without learning the superiority of reamers, one will never learn that relieved reamers are superior to non-relieved reamers. If one does not use reamers, one will not be exposed to the advantages of non-distorted shaping using a 30° reciprocating handpiece. Without the exposure to a 30° reciprocating handpiece, one will never appreciate the absence of torsional stress and cyclic fatigue<sup>4</sup> that plagues rotary NiTi, leading to unpredictable separation. And, without the appreciation that instruments will simply not break, one will not confidently shape canals to the larger dimensions that are often required to ensure proper debridement and irrigation. Examples of cases done with relieved reamers in a reciprocating handpiece are shown in Figures 5–7.

We have been indoctrinating our students for too long. It is about time that we educate them. Critical thinking is the way for students to make rational decisions. They will become better dentists and serve the needs of their patients better when these skills are honed. There may be those out there who dispute the conclusions that critical thinking will produce, but I defy anyone who says this is not the proper way to educate.

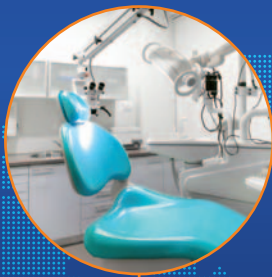*Editorial note: A complete list of references is available from the publisher.*

<b>_contact</b>	<b>roots</b>
<p><b>Dr Barry Lee Musikant</b>                  Essential Dental Systems, Inc.                  89 Leuning Street                  S. Hackensack, NJ 07606                  USA                    info@edsdental.com</p>	

# Post and search for jobs & classifieds worldwide on the largest media platform in dentistry!

Our global online classifieds and career sections are the best solution for filling job vacancies or selling and purchasing equipment for the dental office. Your postings will be available to over 650,000 dental professionals, all readers of the Dental Tribune newspapers, which are published in more than 25 languages worldwide. For more information and free posting opportunities please go to:

[www.dental-tribune.com](http://www.dental-tribune.com)



## DENTAL TRIBUNE

— The World's Dental Newspaper —

# Rubber dam hazards?

Author\_ Dr Kenneth S. Serota, Canada

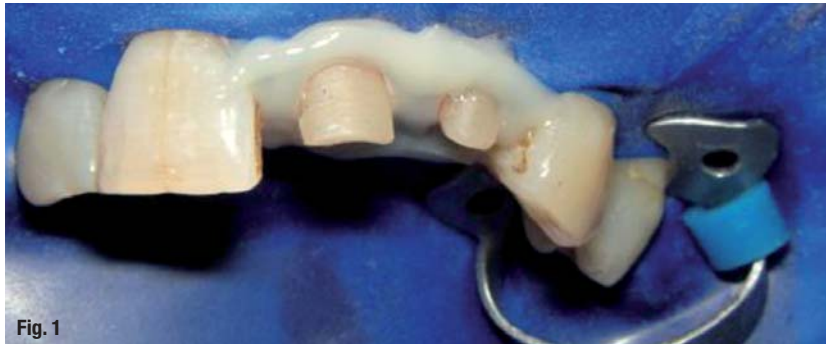

Fig. 1

The September issue of *Oral Health* included an article by Dr Ellis Neiburger entitled *Rubber dam hazards*. The contextual inaccuracy, skewed perspective and postulatory bias of the author was disingenuous at best and horrifying at its worst. I'm not certain how it managed to secret itself into our beloved centenarian journal, but it did. Before I comment on the text, I'd like to share a scientific article with you published by Smith and Pell in the *British Medical Journal* in 2003 (entitled *Parachute use to prevent death and major trauma related to gravitational challenge: systematic review of randomised controlled trials*) to give my concern about this article's publication an element of *gravitas*. The abstract reads:

**Objectives:** To determine whether parachutes are effective in preventing major trauma related to gravitational challenge.

**Design systematic:** Review of randomised controlled trials.

**Data sources:** Medline, Web of Science, Embase, and the Cochrane Library databases; appropriate Internet sites and citation lists.

**Study selection:** Studies showing the effects of using a parachute during free fall.

**Main outcome measure:** Death or major trauma, defined as an injury severity score > 15.

**Results:** We were unable to identify any randomised controlled trials of parachute intervention.

**Conclusions:** As with many interventions intended to prevent ill health, the effectiveness of parachutes has not

been subjected to rigorous evaluation by using randomised controlled trials. Advocates of evidence-based medicine have criticised the adoption of interventions evaluated by using only observational data. We think that everyone might benefit if the most radical protagonists of evidence-based medicine organised and participated in a double blind, randomised, placebo-controlled, cross-over trial of the parachute.

Not wishing to misjudge nor malign the author, I searched the many publications attributed to Dr Neiburger in the literature using Google Scholar. My personal favourite was *Similar mandibular osseous lesions in Tyrannosaurus Rex and man*,<sup>1</sup> followed closely by *Voodoo Barbie and the dental office*,<sup>2</sup> not to be outdone by *Water line biofilm dangers—A tempest in a teapot*.<sup>3</sup> Of note, none of the references pertaining to the hazards were dated beyond 1990.

As to the inaccuracies, rather than repeating the text, I'll answer the "factoids": rubber dam is routinely used in the vast majority of endodontic and restorative procedures by contemporary dentists; sterilisation of the rubber dam can be done readily; reuse is the most scurrilous of the factoids proposed; colour is not an issue, in fact it can be used to enhance photographic documentation; the physical and chemical properties of the dam enable it to be used with most if not all dental materials and its strength cannot be in dispute, as the average endodontic procedure does not require multiple replacement; damage from clamps occurs because of improper placement; the sheer enormity of clamp sizes and design allows for literally any clinical situation with tissue injury essentially non-existent; there are a raft of alternatives to clamp placement (Fig. 1); the issues pertaining to time for placement, phobias, material residue in pockets anon ... even providing a rebuttal to the text gives it a undeserved credibility.

Dentistry is perched on a slippery slope. In North America alone, it represents a silo of approximately \$60 billion. Evidence-based science has been replaced by eminence-based science and the concept of "non-fiduciary advocacy" has been lost in the ether. I wish I possessed Randy Lang's erudition and Will Rogers' wit. His recent editorial on a specific orthodontic band of dubious value beyond the strength of its marketing showcased the fact that even amongst those whose



focus is narrowed by a specialty, a segment can be catalysed through market forces to recognise something as the holy grail, when another faction sees the same product as having the value of a Gwyneth Paltrow GOOP-substantiated cleanse.

In my own area of interest, a recent article by one of the better-known clinicians questioned the value of the wealth of new endodontic products coming to market, especially the latest NiTi iteration that reintroduced reciprocation. The essence of the article was, "if it ain't broke, don't fix it", which then included the take-away message that the product long associated with the reputation of the author had served the discipline well and it too required only a paucity of instruments to achieve 100% predictable clinical success.

To bring this to a purposeful conclusion, I would encourage you to google Bayes' theorem. It is in essence an equation and depending upon whether you are a frequentist, a subjectivist or an objectivist, the theorem suggests that if we assign some *a priori* probabilities and then compute *a posteriori* probabilities, the degree of confidence in some hypotheses can be conditioned by the new data that becomes available. For example, the Venn diagram (Fig. 2) relates to a population, the number expected to have a type of cancer, the number that are indeed positive for the cancer and the number that show a false positive by virtue of a test for markers. Alter the variable, consider the efficacy of lasers by way of example, the degree of penetration into the dental profession, the advocacy of those that use them and the perception of the value inherent based upon their need to see viable applications and substantiated results. It is a technology that will inevitably prove to be an invaluable tool, albeit currently in its infancy. Read all publications with extreme caution—think HealOzone.

Dentistry is getting very complicated as technology and innovation alter its construct. The one essential aspect that must never be overlooked is the need to sustain biological fundamentalism through assiduously conceived investigations and authorship that follows the Cochrane Collaborative principles. We are about to enter a decade wherein it is manifestly conceivable that teeth can be regenerated or replicated and achieve morphological and functional integration into the gnathostomatic apparatus. While it may not impact on the \$4 billion a year whitening arena of oral services, it will impact on many others. The number of rubber dam hazard articles may well breach the levees and floodgates and overwhelm the profession, decimating the landscape and relocating

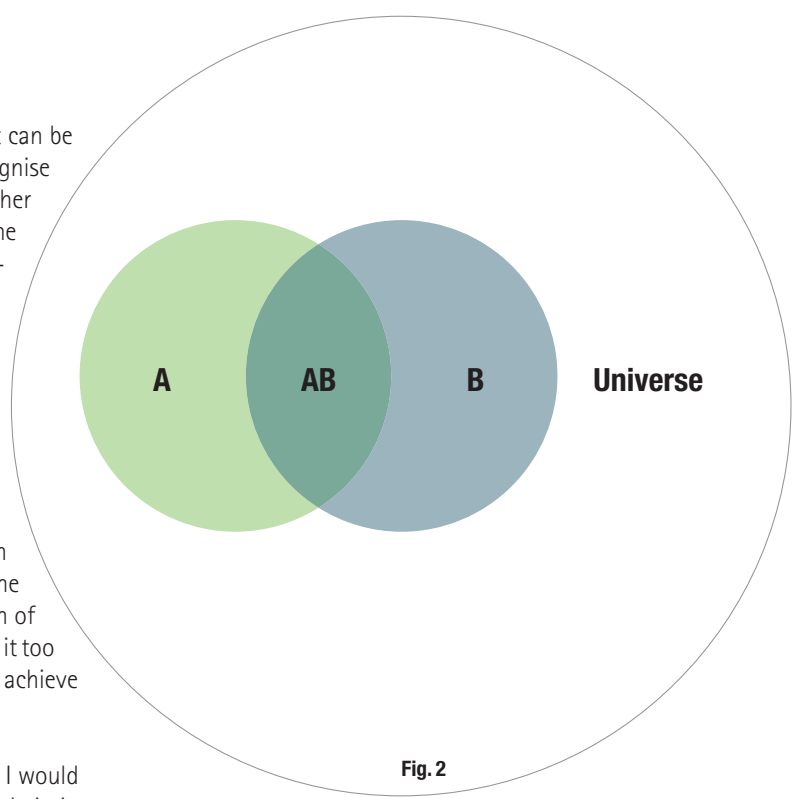



Fig. 2

the populace. It is *Oral Health's* job to stand on guard, "oh Canada, to stand on guard for thee".

References

1. Neiburger EJ. Similar mandibular osseous lesions in Tyrannosaurus rex and man. *J Mass Dent Soc.* 2005 Fall;54(3):14–7.
2. Neiburger EJ. Voodoo Barbie and the dental office. *N Y State Dent J.* 2001 Jun-Jul;67(6):26–7.
3. Neiburger EJ. Water line biofilm dangers a tempest in a teapot. *J Mass Dent Soc.* 2001 Winter;49(4):20–1.

\_about the author
roots

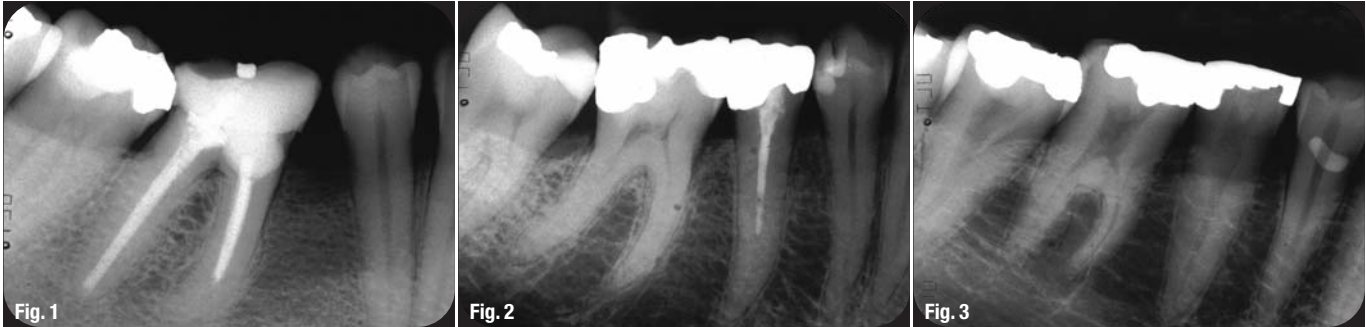


**Dr Kenneth S. Serota** graduated from the University of Toronto in 1973 and was awarded the George W. Switzer Memorial Key for Excellence in Prosthodontics. He received his Certificate in Endodontics and Master of Medical Sciences degree from the Harvard-Forsyth Dental Center in Boston.

A recipient of the American Association of Endodontics Memorial Research Award for his work in nuclear medicine screening procedures related to dental pathology, his passion is education, and most recently e-learning, and rich media. Dr Serota provided an interactive endodontic programme for the Ontario Dental Association from 1983 to 1997 and was awarded the ODA Award of Merit for his efforts in the provision of continuing education.

The author of more than 60 publications, Dr Serota is on the editorial board of *Endodontic Practice*, *Endo Tribune* and *Implant Tribune*. He founded ROOTS, an online educational forum for dentists from around the world who wish to learn cutting-edge endodontic therapy, and recently launched IMPLANTS ([www.rximplants.com](http://www.rximplants.com)) and [www.tdonline.org](http://www.tdonline.org) in order to provide dentists with a clear understanding of the endodontic–implant algorithm in foundational dentistry.

# Dental X-rays can predict fractures



**Fig. 1** Reference images presenting the trabecular pattern as dense trabeculation in a woman with small intertrabecular spaces ...

**Fig. 2** ... mixed dense plus sparse trabeculation in a woman with small intertrabecular spaces cervically and larger spaces more apically ...

**Fig. 3** ... and sparse trabeculation in a woman with large intertrabecular spaces.

By using dental X-rays, the risk of fractures can now be predicted long before a fracture actually occurs, Swedish researchers at the University of Gothenburg's Sahlgrenska Academy have found.

In a previous study, researchers at the Academy and the Public Dental Service of the Region Västra Götaland had demonstrated that a sparse bone structure in the trabecular bone in the mandible is linked to a greater probability of having previously had fractures in other parts of the body.

The Gothenburg researchers followed this research with a new study that demonstrates that it is possible to use dental X-rays to investigate the bone structure in the lower jaw, which enables doctors to predict who is at greater risk of fractures in the future.

"We have discovered that sparse bone structure in the lower jaw in mid-life is directly linked to the risk of fractures in other parts of the body later in life," said Prof Lauren Lissner, researcher at the Institute of Medicine at the Sahlgrenska Academy.

The study draws on data from *The prospective population study of women in Gothenburg*, which was begun in 1968. "Given that this study has now been running for over 40 years, the material is globally unique," the Academy stated. The ongoing study includes 731 women, who have been examined on several occasions since 1968, when they were 38 to 60 years old. X-ray images of their jaw bone were analysed in 1968 and 1980 and the results related to the incidence of subsequent fractures. "The youngest cohort is now over 80 years old. Many of the cohorts, who were

born earlier, have died. We regularly check the cohorts' status by monitoring the mortality and hospital registries," Lissner told **roots**.

According to the Academy, for the first 12 years, fractures were self-reported during follow-up examinations. It is only since the 1980s that it has been possible to use medical registers to identify fractures. A total of 222 fractures were identified during the whole observation period.

The study found that the bone structure of the jaw was sparse in around 20 per cent of the participants aged 38 to 54 when the first examination was carried out, and that these participants were at a significantly greater risk of fractures.

The researchers also concluded that the older the person, the stronger the link between sparse bone structure in the jaw and fractures in other parts of the body. Although the study was carried out on women, the researchers believe that the findings could be generalised to men.

"Dental X-rays contain lots of information on bone structure," said Grethe Jonasson, researcher at the Research Centre of the Public Dental Service in Västra Götaland, who initiated the fractures study. "By analysing these images, dentists can identify people who are at greater risk of fractures long before the first fracture occurs."

The study *A prospective study of mandibular trabecular bone to predict fracture incidence in women* was published in the October issue of the *Bone* journal.

# THE BUSINESS OF DENTISTRY



**INTERNATIONAL DENTAL  
EXHIBITION AND MEETING  
APRIL 20 - 22, 2012**

**Limited space available. Secure your booth now!**

**We Bring the Asia Pacific Markets to You.** IDEM Singapore connects you with over 6,000 dental traders, distributors and practitioners from the Asia Pacific region. Enriched with opportunities from the trading and showcasing of high-quality dental equipment to learning and development in the field of dental practice, this event is a "must-attend" for every dental and associated professional.

Endorsed By



Supported By



Held In



In Co-operation With



Co-organiser



**North America**

Franz Balve  
Koelnmesse Inc  
Tel: +1 732 933 1117  
Fax: +1 732 741 6437  
f.balve@koelnmessenfta.com

**International**

Stephanie Sim  
Koelnmesse Pte Ltd  
Tel: +65 6500 6723  
Fax: +65 6296 2771  
s.sim@koelnmesse.com.sg

# “The integrated systems provide enormous support for the user during root-canal preparation”

An interview with Dr Emanuele Ambu, Italy



Dr Emanuele Ambu

**\_Dr Emanuele Ambu** is an internationally recognised endodontic expert. During the 15<sup>th</sup> Annual Congress of the European Society of Endontology (ESE), which took place from 14 to 17 September in Rome, Italy, the dedicated Italian specialist offered interesting insights into his working methods. He explained why it is particularly important to have high-quality instruments in endodontics and why he therefore likes to work in collaboration with the Japanese company Morita.

**\_Marcel Meurer:** *Dr Ambu, what are you intensively involved in at the moment?*

**Dr Ambu:** In practical research, I am currently focusing on the application of digital volume tomography in endodontic treatment. I am also involved in the so-called hybrid concept, which is a working method that enables quicker, more reliable preparation of the root canal.

**\_How important is it in endodontics to be up to date on the state of the art of this specialised field?**

Extremely important! During the last 15 years, there has been a whole series of paradigm shifts in the area of root-canal treatment (RCT). Newly developed instruments and materials definitely support the endodontists, thus ensuring a much more reliable and easier treatment procedure. There are now rotary nickel-titanium instruments (NiTi files) that enable preparation of the root canal within a few minutes. Moreover, instruments such as the apex locator also help considerably to improve the quality of any endodontic treatment, as the entire therapy can be performed more quickly and with less pain for the patient. In addition, there is technological progress regarding the cleaning and sealing procedures of the root canal, and microscopy and 3-D volume tomography (CBCT) have considerably facilitated endodontic treatment success. Surgical microscopes and 3-D volume tomography are extremely essential in treatment planning and in the therapy itself to ensure successful completion of complex endodontic cases. At the end of the day, it is our duty as conscientious dental practitioners always to treat patients according to state-of-the-art techniques.

**\_How important are specialist congresses such as the ESE for you? What are the most important findings that you took with you this year from Rome?**

I think specialist society congresses are very important. Since I joined the ESE in 1999, I have not missed one single congress. This year's event in particular, was one of the most interesting: over 200 lectures, fantastic poster presentations and also the fact that Rome is a city that radiates a special magic, even for Italians like me. I was personally involved during the congress in presentations about pulp regeneration and the application of CBCT systems in endodontic treatment.

**\_There appears to be some kind of competition between endodontics and implantology. Do you think there is some rivalry between these two specialist disciplines?**

I think it is wrong to talk about rivalry between the two areas of dentistry. Each case must be examined very carefully. The main priority of each dentist should be to try to conserve the tooth, by utilising other treatment areas. This includes the periodontal and restorative techniques of dentistry, which the treating dentist should take into consideration and fully exploit. When there is no possibility of conserving the tooth, there is also no objection to providing a dental restoration with a crown on an implant. An implant should therefore not be used solely because it is the cheaper option for the patient or because it is easier for the dentist to place an implant. Far too many teeth are extracted nowadays because of inadequate endodontic skills and knowledge. Nowadays, we know that there is virtually no difference between the long-term success rates of RCTs and implants. There is of course no golden rule for when RCT should be carried out and when the time is right for an implant. However, the American Association of Endodontics issues very clear statements on the subject: the endodontic treatment of a hopeless tooth is just as unethical as the extraction and replacement of a restorable tooth with an implant.

*Where is the "art" in root-canal treatment? In other words, what are the challenges and what determines the degree of difficulty?*

According to Dr Herbert Schilder, the aim of endodontic treatment is always the complete removal of bacteria from the root-canal system. This allows apical periodontitis to be controlled, and prevents its occurrence following treatment. In fact, this aim is relatively easy to achieve: dentists must complete all treatment steps carefully—beginning with correct isolation of the treatment site using a rubber dam to the permanent restoration of the tooth. Treatment of a single-rooted, straight tooth is much easier than treatment of a molar with four severely curved root canals. Nevertheless, we now have instruments and techniques available that enable reliable treatment of all teeth.

*You have had the opportunity to try out the Soaric endodontic treatment unit from Morita. How does the workstation support dentists during treatment?*

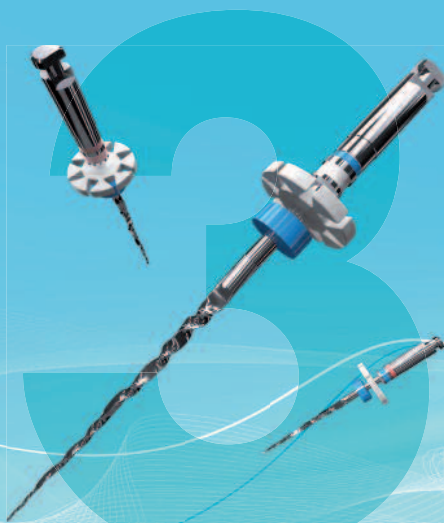I had the opportunity at the IDS in Cologne and the congress in Rome to test Soaric and to work on a phantom head. I really appreciate the integrated endodontic system of the treatment unit. Soaric is fitted with an endo motor with integrated apex locator, making it easier to use the rotary instruments. I think that Soaric is fantastically well suited for endodontic treatment. The attachment for direct connection of a surgical microscope indicates that Soaric was entirely developed for endodontic experts.

AD

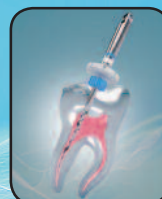# iRaCe

## Quick, Effective and Safe

### Only 3 instruments for most cases Single-length technique

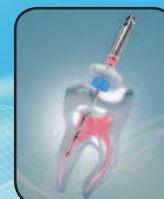

R1 - 15/.06



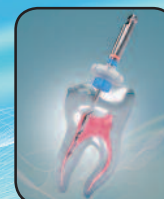up to WL

R2 - 25/.04



up to WL

R3 - 30/.04



up to WL

**FKG**  
DENTAIRE  
Swiss Dental Products  
www.fkg.ch

[www.iRaCe.ch](http://www.iRaCe.ch)



*\_In general, do you personally perform treatment alone (two-handed treatment) or rather with an assistant (four-handed treatment)?*

I always work using four-handed treatment with an assistant. I am often also supported by a colleague during surgical procedures. However, I am convinced that Soaric also provides an excellent opportunity to treat alone. The instruments are arranged pretty well, so they enable the dentist to perform an intuitive treatment procedure.

*\_In your opinion, what makes Morita one of the leading suppliers of units and instruments for root-canal treatment?*

The name Morita is familiar to every endodontic specialist, not least because of the electronic apex locators (Root ZX, J. Morita). The company is one of the leading manufacturers of integrated endodontics. Integrated systems in particular, such as the DentaPort or the old TriAuto ZX (the first endodontic handpiece with an integrated apex locator) or the new TriAuto mini, provide the user with enormous support during root-canal preparation.

*\_Which instrument is indispensable for an endodontist?*

We require all instruments and equipment that enable us to perform good treatment. In my opinion, a surgical microscope, apex locator and an appropriate endodontic handpiece are the minimal requirements for providing good treatment. I personally believe that an electronic apex locator is indispensable. The root canal can be prepared conventionally using files and sealed with gutta-percha heated over a flame. What we really must establish during root-canal preparation, however, is the exact working length!

*\_Which is the most important instrument for root-canal preparation? How many files do you require as a rule?*

We have developed a technique—the hybrid concept—which allows us to prepare a root canal using only three instruments. For preparation, we require the TriAuto mini, but not in automatic mode. We reach the apex simply by using a 10 K-file, to create a glide path. In this way, we reduce the likelihood of the rotary instruments fracturing. The second instrument is then used: the 35.08 EndoWave rotary file is used to enlarge the access of the crown and middle third to the root canal. The working length is determined using the apex locator. We reach the apex using the 20.06 EndoWave file and can completely prepare the root canal using this file. In accordance with the principle of estimating the apical extension, we widen the canal with the rotary instruments and use the attachment with the largest diameter. We use the TriAuto mini in auto-

matic mode in the case of canals with severe curvatures. With this technique, we reduce the risk of damage to the tooth structure outside the canal. We then reach the apex automatically using the smallest rotary instrument in the world, the MGP 1 (a rotary NiTi file with a conicity of 0.02 mm and a #10 tip diameter).

Then follows MGP 2 and MGP 3 (also with a conicity of 0.02 mm and #15 and 20 diameters). The DentaPort or the TriAuto mini in combination with the Root ZX mini can be used in the automatic mode. In this mode, rotation starts as soon as the file tip is inserted into the canal opening. Once the apex has been reached, the unit is simply removed by rotating the files in a counter-clockwise direction. Using a glide path of 20.02, the 35.08 EndoWave file can prepare the crown and middle third of the root canal, even with severe curvatures. The apex is then reached and prepared using the 20.04 EndoWave file and finally preparation is completed using the 20.06 EndoWave file.

*\_What makes a good file?*

The ideal instruments should be reliable. It is particularly important that the files are fracture resistant and can be used several times.

*\_What advice would you give to young colleagues for their career path when they start in endodontics?*

I would strongly advise young colleagues, when starting their endodontic career, to observe the endodontic treatment protocols and guidelines and use high-quality instruments. We use certain instruments and units for a very long time in our professional life, particularly because they are of good quality. For example, I have been working with my first Root ZX since 1993, which is still in good working order. I use it together with some newer apex locators from Morita.

*Editorial note: A video demonstrating Morita's hybrid concept is available on [www.dental-tribune.com/articles/content/id/6828](http://www.dental-tribune.com/articles/content/id/6828) or simply scan the QR code with you smartphone.*



## \_contact

## roots

**J. Morita Europe GmbH**  
Justus-von-Liebig-Straße 27a  
63128 Dietzenbach  
Germany

[www.morita.com/europe](http://www.morita.com/europe)

The 32nd Moscow International Dental Forum

# Moscow 2012

The 32nd Moscow International Dental Forum



**Dental-Expo**  
international dental fair

**September 17-20**

Crocus Expo exhibition grounds

more than  
**450**  
exhibitors

more than  
**25000**  
attendees

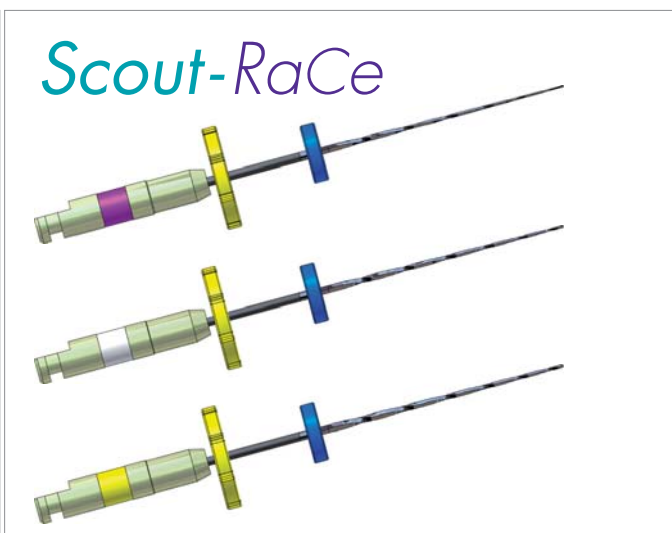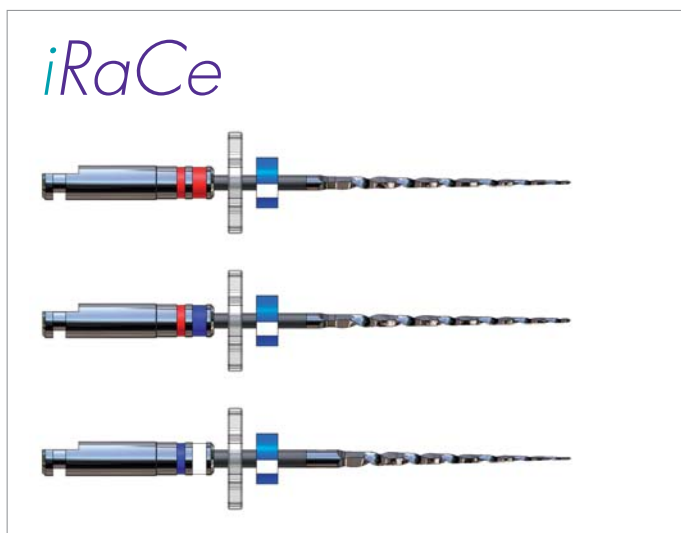
more than  
**35**  
countries

[www.dental-expo.com](http://www.dental-expo.com)

**DENTALEXPO®**



# FKG Dentaire introduces *iRaCe* and *Scout-RaCe*



FKG Dentaire specialises in the development, manufacture and distribution of dental products, for the endodontic specialty in particular. This year, the Swiss company introduced *iRaCe* and *Scout-RaCe*, two new and advanced rotary NiTi instrument systems for safe and effective root-canal preparation.

## *iRaCe*— Quick, effective and safe sequence

Thanks to their exclusive features, only three *iRaCe* rotary NiTi files are needed to treat most cases (straight, slightly curved and/or large). The *iRaCe* sequence is easy to learn and to apply, resulting in considerable time-savings.

The *iRaCe* rotary NiTi files offer the following features:

- \_ exclusive rounded Safety Tip for perfect guidance;
- \_ alternating cutting edges and thus no screwing-in effect and no pulling in;
- \_ sharp cutting edges, yielding time-savings through efficient cutting;
- \_ electrochemical polishing, resulting in better resistance to torsion and cyclic fatigue;
- \_ SafetyMemoDisc to master fatigue and control the number of uses;

new shank enables easy identification of ISO sizes (large ring) and taper (thin ring; yellow: 2%, red: 4%, blue: 6%).

Furthermore, two additional instruments— *iRaCe Plus*—have been developed to allow for the treatment of difficult cases, such as severely curved, narrowed and calcified canals.

## *Scout-RaCe*— Mechanical scouting sequence

*Scout-RaCe* enables a faster and better shaping of the glide path than manual files. *Scout-RaCe* 10.02 can be used directly after a manual instrument ISO 08 up to working length, followed by *Scout-RaCe* 15.02 and *Scout-RaCe* 20.02. Thanks to its exceptional flexibility, *Scout-RaCe* follows the canal anatomy perfectly.

*Scout-RaCe* offers the following features:


- \_ extreme flexibility thanks to the 0.02 taper;
- \_ exclusive rounded Safety Tip;
- \_ unique anti-screwing design;
- \_ sharp cutting edges;
- \_ electrochemical polishing for better resistance to torsion and fatigue;
- \_ SafetyMemoDisc for mastering metal fatigue and controlling the number of uses.

_contact	roots
<p><b>FKG Dentaire</b> Rue du Crêt-du-Loche 4 2304 La Chaux-de-Fonds Switzerland</p> <p>info@fkg.ch www.fkg.ch</p>	



# implants

international magazine of oral implantology



You can also subscribe via  
[www.oemus.com/abo](http://www.oemus.com/abo)

 **Subscribe now!**

I hereby agree to receive a free trial subscription of **implants international magazine of oral implantology** (4 issues per year).

I would like to subscribe to **implants** for € 44 including shipping and VAT for German customers, € 46 including shipping and VAT for customers outside of Germany, unless a written cancellation is sent within 14 days of the receipt of the trial subscription. The subscription will be renewed automatically every year until a written cancellation is sent to OEMUS MEDIA AG, Holbeinstr. 29, 04229 Leipzig, Germany, six weeks prior to the renewal date.

▶ **Reply** via Fax +49 341 48474-290 to OEMUS MEDIA AG or via E-mail to [grasse@oemus-media.de](mailto:grasse@oemus-media.de)

## One issue free of charge!

Last Name, First Name

Company

Street

ZIP/City/County

E-mail

Signature

Notice of revocation: I am able to revoke the subscription within 14 days after my order by sending a written cancellation to OEMUS MEDIA AG, Holbeinstr. 29, 04229 Leipzig, Germany.

Signature

Holbeinstr. 29, 04229 Leipzig, Germany, Tel.: +49 341 48474-0, Fax: +49 341 48474-290, E-Mail: [grasse@oemus-media.de](mailto:grasse@oemus-media.de)

OEMUS MEDIA AG



# Dental symposium at home? AMED goes virtual

Author\_ Dr Terrell F. Pannkuk, USA



The energy and expense of running a physical meeting has become a significant problem for many organisational leaders in 2011. With the worst economy since the Great Depression, the Japan tsunami affecting 40% of our membership, and the annual meeting scheduled to be held in one of the most exclusive areas in the world, the Academy of Microscope Enhanced Dentistry (AMED) found itself entering a perfect storm.

"The man of virtue makes the difficulty to be overcome his first business, and success only a subsequent consideration" (Confucius) came to mind as AMED President, Dr Bill Lannan, and I took a step away from tradition this past March after our very successful Santa Barbara 2010 meeting. We regrouped and brainstormed a new idea: a virtual dental conference with no physical meeting space at all!

We developed a live three-day online programme with multiple webinar channels and an interactive website with chatting capability for attendees. The meeting was organised into corporate forums, research and academic presentations, and featured clinical presentations.

Most sessions were presented live with nearly 50 presenters in the three days. Teams of moderators, co-moderators and guests were packed into my dental office computer network, as mission control to ensure the smooth running of the conference. We were in touch live around the dental world from 10 to 12 November. Presenters spoke from Brussels to Florence to Taiwan to Frankfurt to Sao Paolo to Tokyo to London to Melbourne to Haifa to Vancouver to Athens to Riga to Cape Town to Newport Beach, all simultaneously with multiple channels. Real-time group Q & A followed each presentation in every time zone. The attendees from 26 countries said that they were having much fun staying up all night interacting and listen-

ing to some of the most talented dentists in the world lecturing from their homes on their computers as if they were in one giant global room together. There were even impromptu live presentations. It was dental Woodstock, a ground-breaking event!

The meeting is now online for registrants to view the presentations if they were unable to see them live. Up to 28 self-instructional ADA CERP CE credits are available by filling out surveys on the conference site. The AMED site is now an active communication hub where invitations are sent out for impromptu lectures by some of the presenters. The unique aspect of the AMED conference is that it continues to attract participation well after the meeting. The buzz keeps going on.

Attendees are able to see their colleagues' online presentations through the AMED website and are then able to chat with them online. The virtual exhibit hall, individual presentation pages, and overview page are great places to meet. The attendees can also write comments on the presenters' page and obtain feedback directly from the presenters. We plan to continue these virtual meetings and will add more presentations to our exclusive video-viewing library.

Please join the experience by logging onto [www.microscopdentistry.com](http://www.microscopdentistry.com). Members who register for the meeting will receive indefinite access as a member benefit and non-members can register for the event with 30-day access.

## \_contact

roots

### AMED Central Office

P.O. Box 15834  
Fort Wayne, IN 46885-5834  
USA

[info@microscopdentistry.com](mailto:info@microscopdentistry.com)  
[www.microscopdentistry.com](http://www.microscopdentistry.com)



WWW.SINODENT.COM.CN

# SINO-DENTAL 2012

## June 9-12, 2012

China National Convention Centre · Beijing

Joint Organizers

International Health Exchange and Cooperation Centre,  
Ministry of Health, P. R. China  
Chinese Stomatological Association  
Peking University School of Stomatology

Supporter

Ministry of Health, P.R. China

Contact us: Ms.Sunny Ms. Carol  
Tel: (86)10-88393922/3917  
E-mail: info@sinodent.com.cn

[www.sinodent.com.cn](http://www.sinodent.com.cn)

# Ten years of DGEndo and the launch of DGET

Author\_ Oscar von Stetten, Germany



## Thursday: Pre-congress and general meeting

The first Annual Meeting of the DGET began with a pre-congress event featuring six industry workshops. Since root-canal preparation (RCP) is an important and recurring issue in practice, a range of automated RCP systems with various features was presented. Prof. Michael Baumann, for instance, presented a system for implementing the crown-down method following a specified instrument sequence.

Drs Christoph Zirkel and Josef Diemer discussed RCP with reciprocating motion, a frequent topic of debate over recent months. Here, the reduced risk of instrument breakage and rapid preparation after the glide path has been established is of particular interest to most colleagues. However, in addition to the benefits, the weaknesses and limitations of these new systems were also discussed. The often-advocated one-file endo approach cannot always be implemented.

In his lecture, Dr Christian Gernhardt followed along the same lines, stating that "it is ok to use more than one file". He highlighted the advantages and

From 3 to 5 November, over 450 guests broke visitor records during the tenth Annual Meeting of the German Society of Endodontology (DGEndo) held at the Kameha Grand hotel in Bonn, Germany. The meeting simultaneously marked the end of DGEndo and the launch of the German Society of Endodontology and Traumatology (DGET). With an excellent programme and an impressive line-up of international speakers, the meeting was probably the most important German endodontics event of the year.



Dr Christian Gernhardt



Dr Christoph Zirkel



3-D presentation

disadvantages of various file systems and offered advice on how to react to specific anatomical features to ensure treatment success.

In his workshop entitled *From hot to cold*, Dr Dieter Pahncke explained preparation methods with ultra-flexible files and discussed various filling techniques.

I presented a workshop—*Documentation with the dental microscope*—that was met with great interest. Participants were able to examine and test many of the solutions currently offered by the industry. Twelve different documentation solutions were presented, a number that is testimony to the depth and complexity of the field. Of enormous interest were the fundamental physics—not necessarily simple but nonetheless important—that clearly illustrated the limits posed by optics. However, a whole range of practical tips was offered on how to make documentation more useful.

Members attending the general meeting in the evening were given a clear outline of the current efforts and achievements of the board. During the elections, board members were re-elected unani-

mously, demonstrating confidence in the existing board and its strategies in promoting the society's interests. The day closed with a good meal in a relaxed atmosphere.

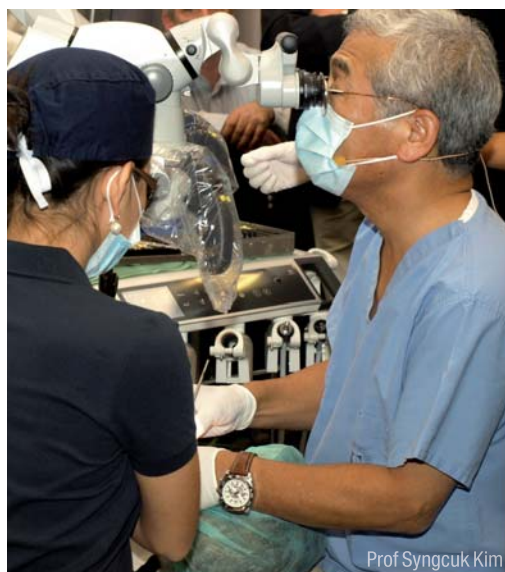### **Friday: Main congress and birthday party**

The main scientific programme was opened by Dr Christian Gernhardt in an excellent manner, as always. He was followed by Prof Marco Versiani, who presented fascinating  $\mu$ CT images of the complex root-canal anatomy and clearly and skilfully put these images in the context of our everyday clinical work. Thereafter, Dr Arnaldo Castellucci gave a concise yet entertaining summary of improvements in non-surgical endodontics. He focused on the use of ultrasonic instruments in endodontic treatment and the establishment of a glide path for subsequent rotary preparation.

After an excellent lunch, the programme continued with an insight into the fascinating field of adhesion to dentine following endodontic treatment. Prof Junji Tagami from Tokyo demonstrated this complex issue in a clear and interesting manner. The essence of



Prof Michael Baumann



Prof Syngueuk Kim



Kameha Grand

Photographs courtesy of Eric Müller,  
OEMUS MEDIA.

his lecture was that chemically altered dentine does not allow for complete adhesion. Therefore, fresh dentine has to be uncovered by mechanically removing the altered layer, if good adhesion is to be achieved.

Prof Markus Haapasalo from Vancouver—without a doubt one of the most experienced researchers and clinicians in his field worldwide—spoke on the highly complex issue of treatment planning and disinfection of canal structures and gave a very good insight into possible disinfection strategies.

The day ended with a big birthday celebration in the Puregold Bar at the Kameha Grand. In his speech on the occasion of DGEndo's tenth anniversary, Dr Hans-Willi Herrmann gave an interesting insight into the history of the society—naturally, in his very own inimitable style that had the audience laughing on several occasions. Celebrations in the bar then continued into the early hours.

### **\_Saturday: Main congress**

The following day began with a lecture by Prof Thomas Kvist from Gothenburg, which was well attended despite the partying the previous evening. He spoke on success rates in endodontics and their significance for strategic treatment planning.

Dr Roy Nesari from San Francisco then gave a most entertaining presentation on the marketing concept at his endodontic practice. He explained his particular focus on communication with referring physicians, staff motivation and practice development. He certainly raised a number of interesting aspects regarding marketing, while maintaining participants' interest and offering useful ideas.

Prof Roland Weiger from Basel gave the audience an extremely comprehensive update on dental traumatology. According to Prof Weiger, developments in trauma treatment are far advanced and it is important to put this fundamental issue back into focus. His extremely informative lecture was followed by an announcement that a smartphone app—a detailed and handy reference for correct and rapid therapy planning—is to be developed in collaboration with the DGET in 2012.

### **\_3-D live operation: The grand finale**

The highlight of this year's congress was the microsurgical apicectomies carried out live on two lower molars by Prof Syngcuk Kim. Particularly exciting for participants, the procedure was projected live in 3-D thanks to technology from Zeiss. As always, it was both fascinating and inspiring to watch such an experienced surgeon. Prof Kim had already operated live during the very first annual DGEndo meeting in 2001. With his participation in the tenth annual congress, we have come full circle.

This event clearly was a milestone. Looking back at ten successful years of DGEndo and one year after the foundation of the DGET, we are in an excellent position to drive forward endodontic advances in Germany.

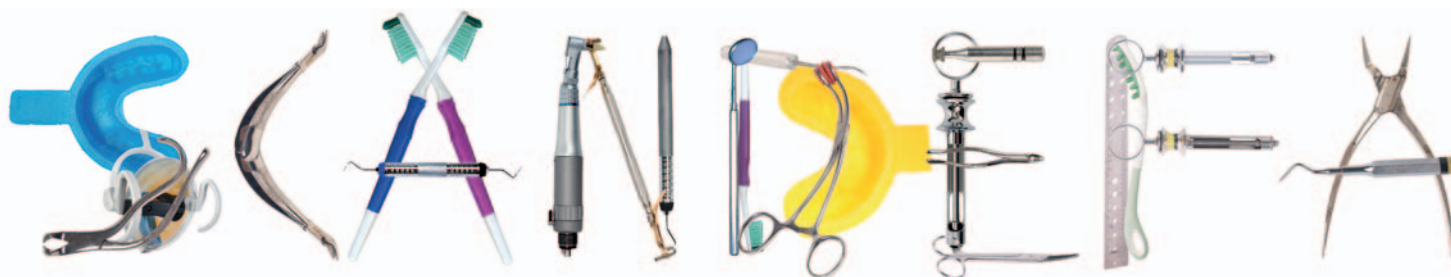"Ten years of DGEndo came to a close this weekend and that is how it should be. The first annual convention of the DGET was a clear testimony to just how dynamically our field is developing," commented Dr Christoph Zirkel. "Never before have we welcomed so many participants, have so many students registered, have we launched so many new and exciting projects in just one weekend. On behalf of the board, I would like to thank all those who have given us their support and had confidence in us. We will make every effort to continue to earn the trust placed in us." \_

#### **\_contact**

#### **roots**

**DGET**  
Holbeinstraße 29  
04229 Leipzig  
Germany


sekretariat@dget.de  
www.dget.de



**APRIL 26- 28, 2012 • BELLA CENTER • COPENHAGEN • DENMARK**

**Welcome to the 45th Scandinavian Dental Fair  
The leading annual dental fair in Scandinavia**

# SCANDEFA 2012



**The 45th SCANDEFA invites you to exquisitely meet the Scandinavian dental market and sales partners from all over the world in springtime in wonderful Copenhagen**

## **SCANDEFA 2012**

Is organized by Bella Center and is being held in conjunction with the Annual Scientific Meeting, organized by the Danish Dental Association ([www.tandlaegeforeningen.dk](http://www.tandlaegeforeningen.dk)).

175 exhibitors and 11.422 visitors participated at SCANDEFA 2011 on 14,220 m<sup>2</sup> of exhibition space.

## **Exhibit at Scandefa**

Book online at [www.scandefa.dk](http://www.scandefa.dk)  
Sales and Project Manager, Christian Olrik  
[col@bellacenter.dk](mailto:col@bellacenter.dk), T +45 32 47 21 25

## **Travel information**

Bella Center is located just a 10 minute taxi drive from Copenhagen Airport. A regional train runs from the airport to Orestad Station, only 15 minutes drive.

## **Check in at Bella Center's newly built hotel**

Bella Sky Comwell is Scandinavia's largest design hotel. The hotel is an integral part of Bella Center and has direct access to Scandefa. Book your stay on [www.bellasky.dk](http://www.bellasky.dk)

# International Events

## 2012

### **Pan Arab Endodontic Conference**

11–14 January 2012  
Dubai, UAE  
[www.paec2012.com](http://www.paec2012.com)

### **Swiss Society for Endodontology International Conference**

20 & 21 January 2012  
Lausanne, Switzerland  
[www.endodontology.ch](http://www.endodontology.ch)

### **DGET Spring Academy**

2 & 3 March 2012  
Heidelberg, Germany  
[www.dget.de](http://www.dget.de)

### **Russian Endodontic Congress**

30 March–1 April 2012  
Moscow, Russia  
[www.congress2012.endoforum.ru/e/index.html](http://www.congress2012.endoforum.ru/e/index.html)

### **SCANDEFA**

26–28 April 2012  
Copenhagen, Denmark  
[www.scandefa.dk](http://www.scandefa.dk)

### **Trans-Tasman Endodontic Conference**

21–23 June 2012  
Queensland, Australia  
[www.tteconference.com](http://www.tteconference.com)

### **Skand Endo**

23–25 August 2012  
Oslo, Norway  
[nina.gerner@c2i.net](mailto:nina.gerner@c2i.net)

### **FDI Annual World Dental Congress**

29 August–1 September 2012  
Hong Kong, China  
[www.fdiworldental.org](http://www.fdiworldental.org)

### **ROOTS Summit**

18–20 October 2012  
Foz do Iguaçu, Brazil

### **DGET Annual Meeting**

1–3 November 2012  
Leipzig, Germany  
[www.dget.de](http://www.dget.de)

## 2013

### **International Dental Show**

12–16 March 2013  
Cologne, Germany  
[www.ids-cologne.de](http://www.ids-cologne.de)

### **IFEA World Endodontic Congress**

23–26 May 2013  
Tokyo, Japan  
[www2.convention.co.jp/ifea2013](http://www2.convention.co.jp/ifea2013)

### **ESE Biennial Congress**

12–14 September 2013  
Lisbon, Portugal  
[www.e-s-e.eu](http://www.e-s-e.eu)





## submission guidelines:

Please note that all the textual components of your submission must be combined into one MS Word document. Please do not submit multiple files for each of these items:

- \_ the complete article;
- \_ all the image (tables, charts, photographs, etc.) captions;
- \_ the complete list of sources consulted; and
- \_ the author or contact information (biographical sketch, mailing address, e-mail address, etc.).

In addition, images must not be embedded into the MS Word document. All images must be submitted separately, and details about such submission follow below under image requirements.

### Text length

Article lengths can vary greatly—from 1,500 to 5,500 words—depending on the subject matter. Our approach is that if you need more or less words to do the topic justice, then please make the article as long or as short as necessary.

We can run an unusually long article in multiple parts, but this usually entails a topic for which each part can stand alone because it contains so much information.

In short, we do not want to limit you in terms of article length, so please use the word count above as a general guideline and if you have specific questions, please do not hesitate to contact us.

### Text formatting

We also ask that you forego any special formatting beyond the use of italics and boldface. If you would like to emphasise certain words within the text, please only use italics (do not use underlining or a larger font size). Boldface is reserved for article headers. Please do not use underlining.

Please use single spacing and make sure that the text is left justified. Please do not centre text on the page. Do not indent paragraphs, rather place a blank line between paragraphs. Please do not add tab stops.

Should you require a special layout, please let the word processing programme you are using help you do this formatting automatically. Similarly, should you need to make a list, or add footnotes or endnotes, please let the word processing programme do it for you automatically. There are menus in every programme that will enable you to do so. The fact is that no matter how carefully done, errors can creep in when you try to number footnotes yourself.

Any formatting contrary to stated above will require us to remove such formatting before layout, which is very time-consuming. Please consider this when formatting your document.

### Image requirements

Please number images consecutively throughout the article by using a new number for each image. If it is imperative that certain images are grouped together, then use lowercase letters to designate these in a group (for example, 2a, 2b, 2c).

Please place image references in your article wherever they are appropriate, whether in the middle or at the end of a sentence. If you do not directly refer to the image, place the reference at the end of the sentence to which it relates enclosed within brackets and before the period.

In addition, please note:

- \_ We require images in TIF or JPEG format.
- \_ These images must be no smaller than 6x6 cm in size at 300 DPI.
- \_ These image files must be no smaller than 80 KB in size (or they will print the size of a postage stamp!).

Larger image files are always better, and those approximately the size of 1 MB are best. Thus, do not size large image files down to meet our requirements but send us the largest files available. (The larger the starting image is in terms of bytes, the more leeway the designer has for resizing the image in order to fill up more space should there be room available.)

Also, please remember that images must not be embedded into the body of the article submitted. Images must be submitted separately to the textual submission.

You may submit images via e-mail, via our FTP server or post a CD containing your images directly to us (please contact us for the mailing address, as this will depend upon the country from which you will be mailing).

Please also send us a head shot of yourself that is in accordance with the requirements stated above so that it can be printed with your article.

### Abstracts

An abstract of your article is not required.

### Author or contact information

The author's contact information and a head shot of the author are included at the end of every article. Please note the exact information you would like to appear in this section and format it according to the requirements stated above. A short biographical sketch may precede the contact information if you provide us with the necessary information (60 words or less).

### Questions?

Claudia Salwiczek (Managing Editor)  
c.salwiczek@oemus-media.de

# roots

international magazine of endodontology

## Publisher

Torsten R. Oemus  
[oemus@oemus-media.de](mailto:oemus@oemus-media.de)

## CEO

Ingolf Döbbecke  
[doebbecke@oemus-media.de](mailto:doebbecke@oemus-media.de)

## Members of the Board

Jürgen Isbaner  
[isbaner@oemus-media.de](mailto:isbaner@oemus-media.de)

Lutz V. Hiller

[hiller@oemus-media.de](mailto:hiller@oemus-media.de)

## Managing Editor

Claudia Salwiczek  
[c.salwiczek@oemus-media.de](mailto:c.salwiczek@oemus-media.de)

## Executive Producer

Gernot Meyer  
[meyer@oemus-media.de](mailto:meyer@oemus-media.de)

## Designer

Josephine Ritter  
[j.ritter@oemus-media.de](mailto:j.ritter@oemus-media.de)

## Copy Editors

Sabrina Raaff  
Hans Motschmann

## Published by

Oemus Media AG  
Holbeinstraße 29  
04229 Leipzig, Germany  
Tel.: +49 341 48474-0  
Fax: +49 341 48474-290  
[kontakt@oemus-media.de](mailto:kontakt@oemus-media.de)  
[www.oemus.com](http://www.oemus.com)

## Printed by

Messedruck Leipzig GmbH  
An der Hebemärchte 6  
04316 Leipzig, Germany

## Editorial Board

Fernando Goldberg, Argentina  
Markus Haapasalo, Canada  
Ken Serota, Canada  
Clemens Bargholz, Germany  
Michael Baumann, Germany  
Benjamin Briseno, Germany  
Asgeir Sigurdsson, Iceland  
Adam Stabholz, Israel  
Heike Steffen, Germany  
Gary Cheung, Hong Kong  
Unni Endal, Norway  
Roman Borczyk, Poland  
Bartosz Cerkaski, Poland  
Esteban Brau, Spain  
José Pumarola, Spain  
Kishor Gulabivala, United Kingdom  
William P. Saunders, United Kingdom  
Fred Barnett, USA  
L. Stephan Buchanan, USA  
Jo Dovgan, USA  
Vladimir Gorokhovskiy, USA  
James Gutmann, USA  
Ben Johnson, USA  
Kenneth Koch, USA  
Sergio Kuttler, USA  
John Nusstein, USA  
Ove Peters, USA  
Jorge Vera, Mexico



Claudia Salwiczek, Managing Editor




## Copyright Regulations

\_roots international magazine of endodontology is published by Oemus Media AG and will appear in 2011 with one issue every quarter. The magazine and all articles and illustrations therein are protected by copyright. Any utilisation without the prior consent of editor and publisher is inadmissible and liable to prosecution. This applies in particular to duplicate copies, translations, microfilms, and storage and processing in electronic systems.

Reproductions, including extracts, may only be made with the permission of the publisher. Given no statement to the contrary, any submissions to the editorial department are understood to be in agreement with a full or partial publishing of said submission. The editorial department reserves the right to check all submitted articles for formal errors and factual authority, and to make amendments if necessary. No responsibility shall be taken for unsolicited books and manuscripts. Articles bearing symbols other than that of the editorial department, or which are distinguished by the name of the author, represent the opinion of the afore-mentioned, and do not have to comply with the views of Oemus Media AG. Responsibility for such articles shall be borne by the author. Responsibility for advertisements and other specially labeled items shall not be borne by the editorial department. Likewise, no responsibility shall be assumed for information published about associations, companies and commercial markets. All cases of consequential liability arising from inaccurate or faulty representation are excluded. General terms and conditions apply, legal venue is Leipzig, Germany.

# roots

international magazine of endodontology



You can also subscribe via  
[www.oemus.com/abo](http://www.oemus.com/abo)

 **Subscribe now!**

I would like to subscribe to **roots** for € 44 including shipping and VAT for German customers, € 46 including shipping and VAT for customers outside Germany, unless a written cancellation is sent within 14 days of the receipt of the trial subscription. The subscription will be renewed automatically every year until a written cancellation is sent to OEMUS MEDIA AG, Holbeinstr. 29, 04229 Leipzig, Germany, six weeks prior to the renewal date.

▶ **Reply** via Fax to +49 341 48474-290 to OEMUS MEDIA AG or via E-mail to [grasse@oemus-media.de](mailto:grasse@oemus-media.de)

Last Name, First Name

Company

Street

ZIP/City/Country

E-mail

Signature

Notice of revocation: I am able to revoke the subscription within 14 days after my order by sending a written cancellation to OEMUS MEDIA AG, Holbeinstr. 29, 04229 Leipzig, Germany.

Signature

# With an extra small head



Endea contra-angle handpieces. The new standard in mechanical endodontics. With their new and extra small heads Endea NiTi contra-angle handpieces provide even better access to the treatment area. For the best results in the shortest amount of time.