

# CLEARFIL ESTHETIC CEMENT for crowns and bridges

Authors\_ Dr Harry Denissen & Thomas Reiter, the Netherlands



**\_In aesthetic dentistry,** the shape and shade of a ceramic crown or bridge are extremely important. The dentist can create the mock-up for the crown/bridge by shaping the patient's teeth or existing restorations using CLEARFIL composite resin. Addition, subtraction and aesthetic shaping can easily be done in the composite resin with diamond burs and discs. The shade of the restoration can be assessed by conventional visual or spectrophotometric means. Then, the ceramic restoration with the desired shape and shade has to be cemented.

dam therefore studied the possibilities of cementing crowns and bridges made of etchable and non-etchable ceramics with the new CLEARFIL ESTHETIC CEMENT (Kuraray). This cement is a dual-cured luting composite resin. The etchable ceramic restoration is treated by applying 5% hydrofluoric acid (HF) gel to the inner surface for obtaining micro-retention. The non-etchable ceramic restoration surface is cleaned with 40% phosphoric acid gel. Both etchable and non-etchable ceramic restorations are conditioned by applying CLEARFIL CERAMIC PRIMER, a silane surface treatment agent based on the adhesive monomers MDP and MPS. Try-in pastes with five different shades are available to determine the matching cement shade to be used: Universal, Brown, Clear, Opaque Yellow and Opaque White. The preparation surfaces of the teeth are treated with the self-etching CLEARFIL ED PRIMER II Liquids A and B. Thereafter, the two components of the chosen cement are automatically mixed and applied to the inner surface of the restoration being cemented.

The effect of CLEARFIL ESTHETIC CEMENT on the Lab colour coordinates of ceramics used for computer-generated restorations has been studied.<sup>1</sup> The cement must be available in various shades and the cementing procedure with a rubber dam in place should be easy. The Academic Centre for Dentistry Amster-

## **\_CLEARFIL composite resin for the mock-up of the crown**

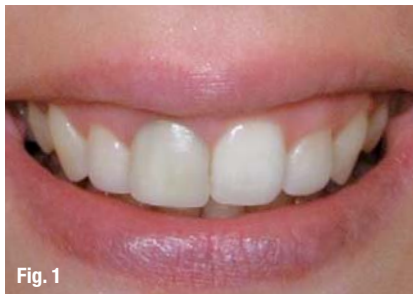

Fig. 1

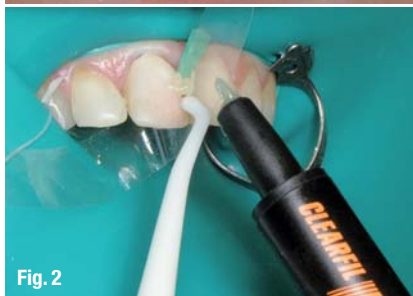

Fig. 2

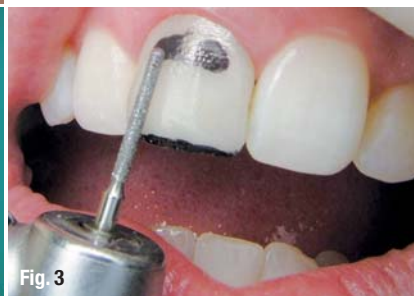

Fig. 3

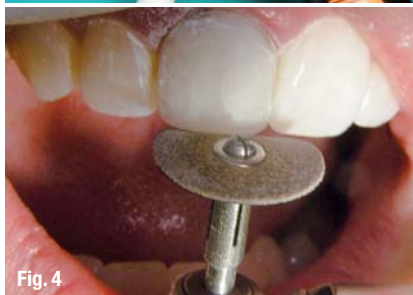

Fig. 4

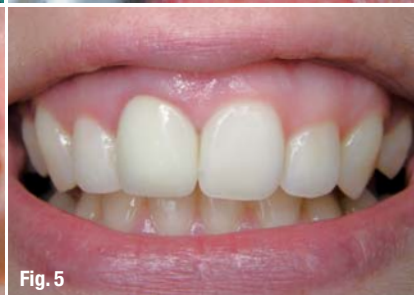

Fig. 5

**Fig. 1\_**The patient desired a correction of shape and shade of the veneer on tooth #11. The veneer did not fit at the margin, was too bulky, too long and the shade was not ideal. Additionally, the lateral incisor was hidden behind the veneer.

**Fig. 2\_**Addition of CLEARFIL composite resin for the mock-up of the crown.

**Fig. 3\_**Subtraction of the composite resin and shaping with diamond bur.

**Fig. 4\_**Contouring of the mock-up with discs.

**Fig. 5\_**The CLEARFIL composite resin mock-up for the crown after polishing. Shape, length and position were improved. The mock-up was planned to be in the mouth for at least one week.

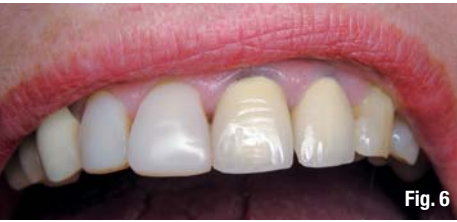

Fig. 6

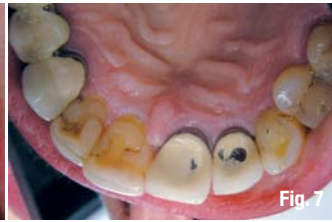

Fig. 7

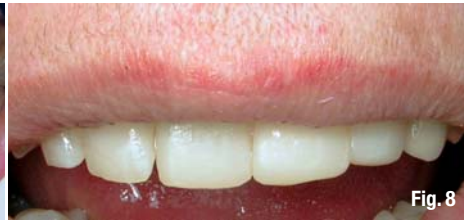

Fig. 8

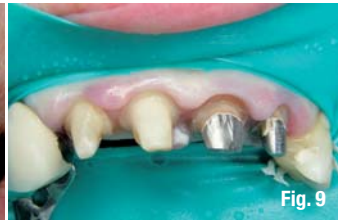

Fig. 9

**\_CLEARFIL cement for etchable ceramic crowns**

Fig. 6\_The patient desired aesthetic and functional rehabilitation of the upper anterior teeth.

Fig. 7\_Palatinal view of the defective crowns (#21 and 22) with cavities along the gingival margins and the two bleached neighbouring teeth (#11 and 12) with large leaking and discoloured fillings.

Fig. 8\_The aesthetic and functional mock-up in composite resin for the anterior crowns.

Fig. 9\_Tooth preparations with shoulder margins for crowns. Clinical experience has shown that it is almost impossible and therefore unwise to remove well-anchored metal posts and cores. The shade of the cement should compensate for the difference in background.

Fig. 10\_The anatomic temporary composite resin crown with the shape of the mock-up was coated with silver powder for the laser-beam scanning procedure.

Fig. 11\_The 3-D digital drawing of the anatomic crown after the scanning procedure in the CEREC inLab unit (Sirona).

Fig. 12\_A cervical view of the CAD of the anatomic crown.

Fig. 13\_Insertion of a block of monochromatic etchable ceramic (IPS e.max CAD, Ivoclar Vivadent) in the spindle of the inLab scan and milling unit.

Fig. 14\_The milling procedure (CAM) of the anatomic crown.



Fig. 10

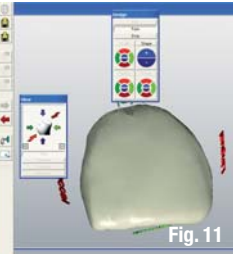


Fig. 11




Fig. 12

Fig. 15a\_The CAD/CAM anatomic crown after crystallisation to obtain strength and tooth shade. The CAD/CAM crown had the full incisal edge contour of the mock-up.

Fig. 15b\_The same crown after cut-back. The incisal edge was cut back to mimic the lobe shape of the mamelons. The incisal and middle parts of the labial surface were also cut back to serve as a dentine build-up coping for the porcelain veneer.

Fig. 16\_Creative handwork was necessary to obtain an optimal aesthetic result by porcelain veneering the cut-back labial/incisal surface.



Fig. 13



Fig. 14

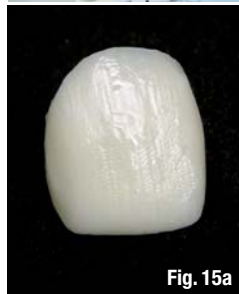

Fig. 15a

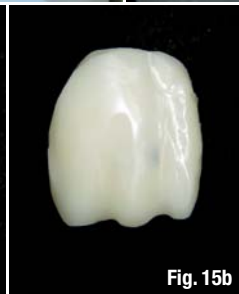


Fig. 15b



Fig. 16

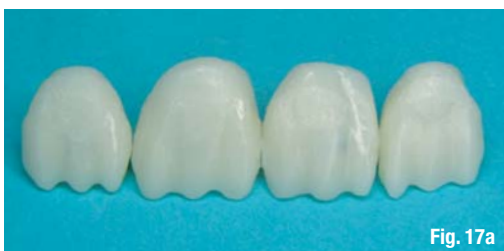

Fig. 17a

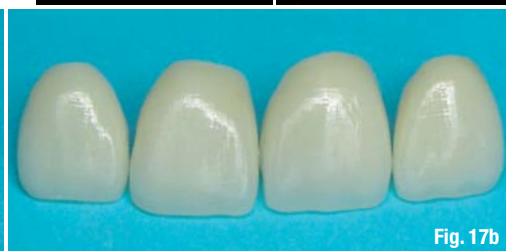

Fig. 17b

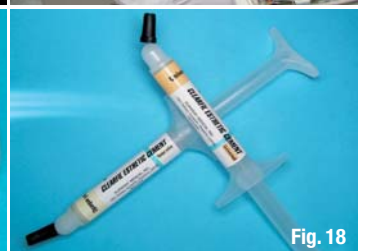

Fig. 18

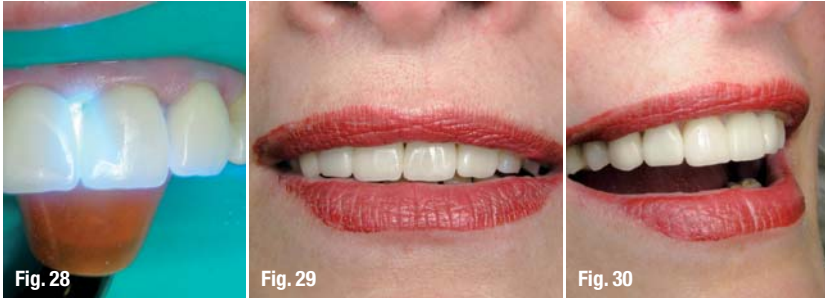
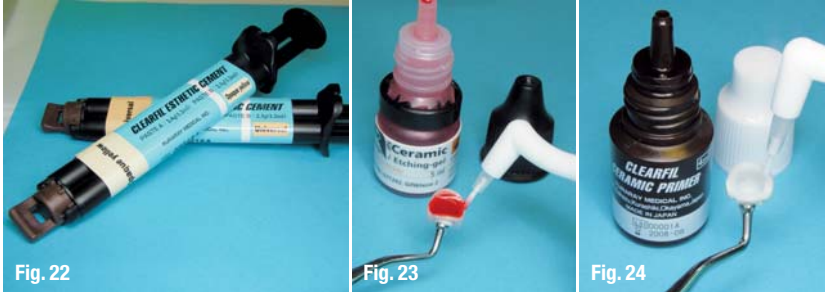
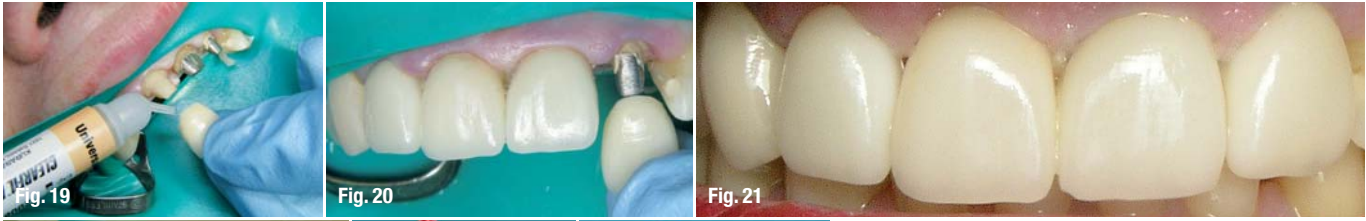Fig. 17a\_The cut-back CAD/CAM crowns before labial/incisal porcelain veneering.

Fig. 17b\_The CAD/CAM crowns after labial/incisal porcelain veneering and ready for placement.

Fig. 18\_The CLEARFIL try-in pastes for obtaining the matching cement shade for the crowns. The crowns are placed with different shade pastes on teeth with and without posts and cores.

Fig. 19\_The CLEARFIL try-in paste was applied to the crown to assess the matching cement for the vital teeth.

Fig. 20\_Positioning of the crown with Opaque Yellow try-in paste for a tooth with a post and core.

Fig. 21\_The crowns after seating with try-in pastes. The Opaque Yellow paste masked the metal cores. The shade corresponded to the crowns on the vital teeth with the universal try-in paste.

Fig. 22\_CLEARFIL ESTHETIC CEMENT (Universal and Opaque Yellow) was chosen for cementation of the crowns. The cement is a dual-cured composite resin.

Fig. 23\_Before cementation, the crown was ultrasonically cleaned in acetone, rinsed with water and dried. The etchable inner surface of the crown was conditioned with 5% HF gel.

Fig. 24\_CLEARFIL CERAMIC PRIMER was applied to the inner surface of the crown.

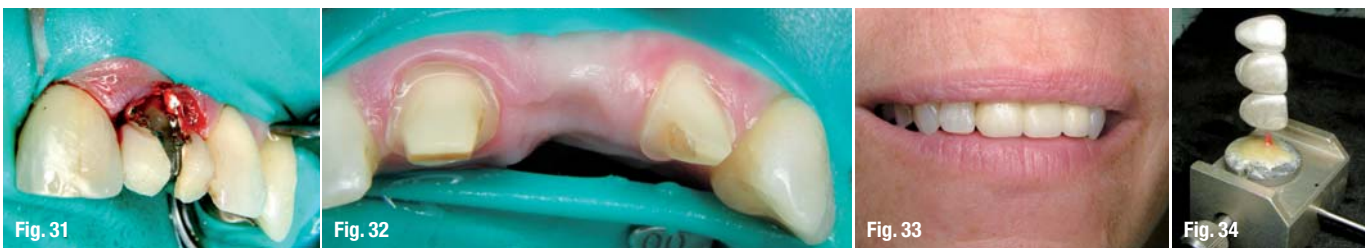Fig. 25\_CLEARFIL ALLOY PRIMER for conditioning the metal surface of the cast cores.

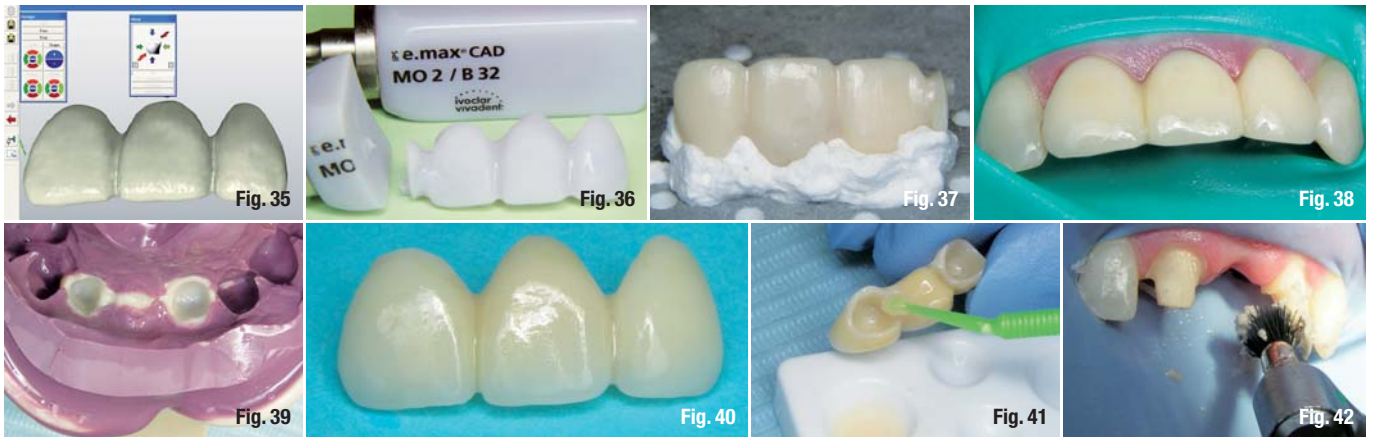Fig. 26\_The self-etching CLEARFIL PRIMER (a mixture of ED PRIMER II Liquids A and B) for conditioning the preparation surfaces of the teeth.

Fig. 27\_Application of the cement in the crown using the standard mixing tip of the CLEARFIL ESTHETIC CEMENT system.

Fig. 28\_After positioning and initial light-curing, the excess cement was removed with a scaler and dental floss. The final light-curing was done in various directions in sessions of 60 seconds.

Figs. 29 & 30\_The patient after placement of the CAD/CAM crowns with labial porcelain veneers using CLEARFIL ESTHETIC CEMENT.





**\_CLEARFIL cement for etchable ceramic bridges**

**Fig. 31**\_A patient with a fractured root on #21. Because of multiple ill-fitting and discoloured restorations in the neighbouring teeth #11 and 22, it was decided to place a three-unit bridge.

**Fig. 32**\_Shoulder preparations on the neighbouring teeth for the abutment crowns after healing. CLEARFIL composite resin was used to fill the remaining defects on the tooth surfaces.

**Fig. 33**\_The mock-up for the three-unit bridge in composite resin. Simple corrections can be made to the anatomy of the bridge with regard to shape aesthetics, occlusion and articulation before final approval by the patient and production of the restoration.

**Fig. 34**\_Scan model of the three-unit anatomic temporary bridge with the shape of the mock-up. The bridge was coated with silver powder prior to scanning.

**Fig. 35**\_CAD for the three-unit bridge before milling.

**Fig. 36**\_A block of etchable ceramic (IPS e.max CAD) was used for milling the anatomic bridge in the CEREC inLab. The milled CAD/CAM bridge was still in the soft phase before crystallisation.

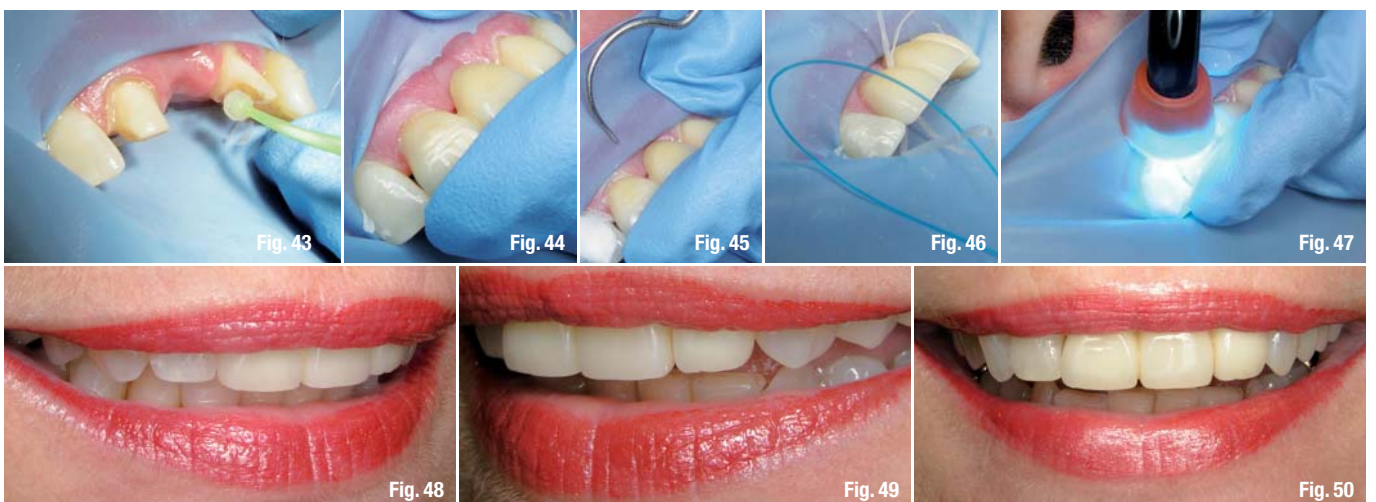
**Fig. 37**\_The anatomic CAD/CAM bridge after crystallisation in the porcelain furnace, which imparted it with strength and tooth colour.

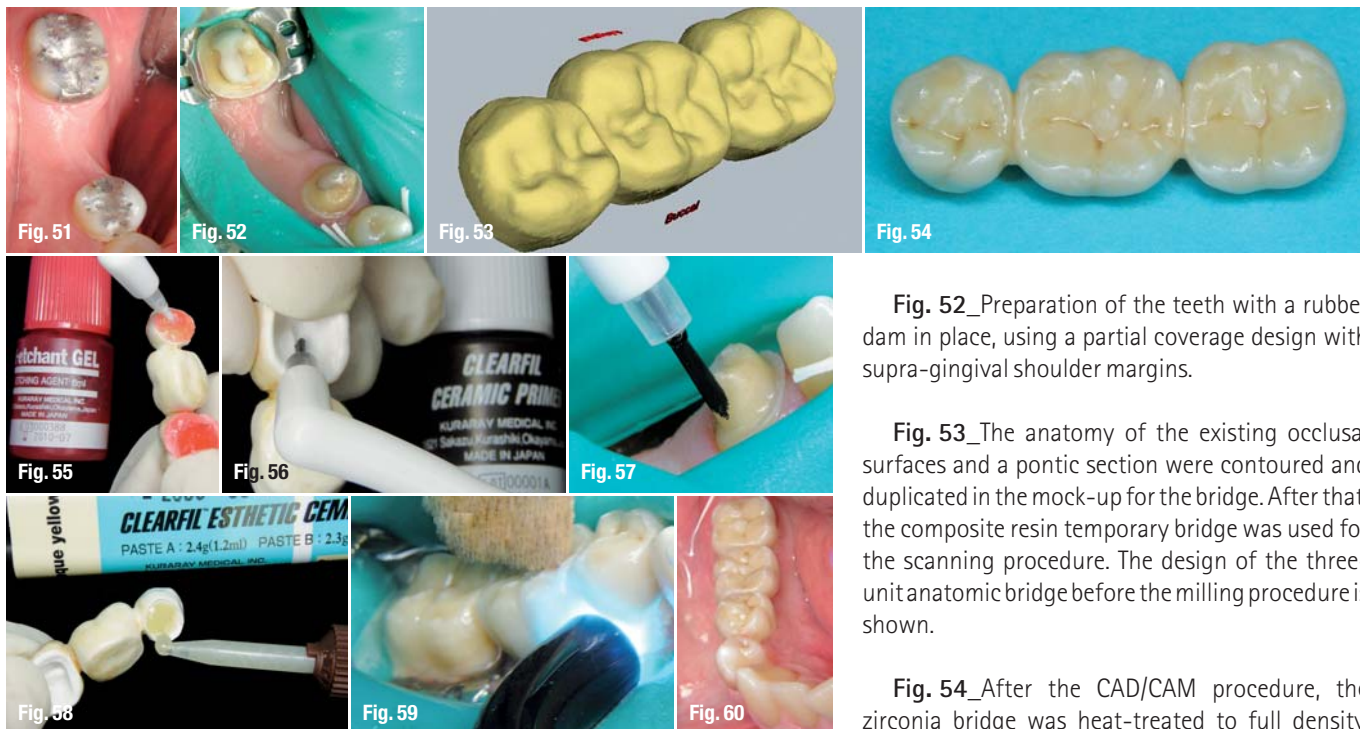**Fig. 38**\_The CAD/CAM bridge placed in the mouth for the second impression. Note the healed anatomy of the gingival tissues around the bridge components.

**Fig. 39**\_The second impression with the CAD/CAM bridge for the cut-back technique and porcelain veneering of the restoration.

**Fig. 40**\_The three-unit IPS e.max CAD bridge just before placement. The aesthetics of the monochromatic CAD/CAM product were optimised by the manual creative work of the dental technician.

**Fig. 41**\_The inner surfaces of the abutment crowns were etched with 5 % HF gel and treated with CLEARFIL CERAMIC PRIMER. After 60 seconds,





the silane primer was dried with a mild, oil-free airflow.

**Fig. 42**\_The teeth were polished with pumice before insertion of the bridge. A rubber dam with a large opening that isolated the prepared and neighbouring teeth was used.

**Fig. 43**\_Application of the self-etching CLEARFIL ED PRIMER II to the preparation surfaces of the teeth. The primer was dried with compressed air until the surfaces were shiny.

**Fig. 44**\_Immediately after treating the restoration and tooth surfaces, the bridge was inserted with CLEARFIL ESTHETIC CEMENT.

**Fig. 45**\_After initial curing of the cement for a few seconds, the cement was removed with a probe.

**Fig. 46**\_A bridge needle and floss were used to remove the excess cement underneath the pontic.

**Fig. 47**\_Final light-curing of the cement at all sites for 60 seconds.

**Figs. 48–50**\_Patient with the cemented bridge.

**\_CLEARFIL ESTHETIC CEMENT for non-etchable ceramic crowns and bridges**

**Fig. 51**\_Treatment planning for a strong three-unit zirconia bridge with abutment crowns on the second premolar and second molar.

**Fig. 52**\_Preparation of the teeth with a rubber dam in place, using a partial coverage design with supra-gingival shoulder margins.

**Fig. 53**\_The anatomy of the existing occlusal surfaces and a pontic section were contoured and duplicated in the mock-up for the bridge. After that, the composite resin temporary bridge was used for the scanning procedure. The design of the three-unit anatomic bridge before the milling procedure is shown.

**Fig. 54**\_After the CAD/CAM procedure, the zirconia bridge was heat-treated to full density, followed by a minor occlusal cut-back and veneering with zirconia liner, deep dentine, stains and glaze.

**Fig. 55**\_Owing to its microstructure, zirconia is very dense and inert. Therefore, it cannot be HF etched or blasted with aluminium oxide particles. The inner surfaces of the abutment crowns were cleaned with K-etchant gel (40 % phosphoric acid; Kuraray Medical Inc.).

**Fig. 56**\_Silane treatment by applying the CLEARFIL CERAMIC PRIMER to the inner surfaces of the abutment crowns.

**Fig. 58**\_Treatment of the preparation surface of the premolar using the CLEARFIL ED PRIMER II Liquids A and B.

**Fig. 58**\_The mixed pastes of the CLEARFIL ESTHETIC CEMENT system were syringed into the abutment crown.

**Fig. 59**\_Placement of the bridge and light-curing of the cement.

**Fig. 60**\_The veneered anatomic CAD/CAM zirconia bridge after cementation.

**\_Reference**

1. Denissen H, Dozic A, van Waas M, Feilzer A. Effects of 5 manipulative variables on the color of ceramics used for computer-generated restorations. *Quintessence International*, 2007;38: 401–8.

**\_contact** **cosmetic**  
dentistry

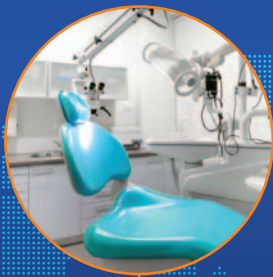**Kuraray Europe GmbH**  
Industriepark Höchst  
Building F 821  
65926 Frankfurt/Main  
Germany

dental@kuraray.eu  
www.kuraray-dental.eu (EU)  
www.kuraraydental.com (USA)

# Post and search for jobs & classifieds worldwide on the largest media platform in dentistry!

Our global online classifieds and career sections are the best solution for filling job vacancies or selling and purchasing equipment for the dental office. Your postings will be available to over 650,000 dental professionals, all readers of the Dental Tribune newspapers, which are published in more than 25 languages worldwide. For more information and free posting opportunities please go to:

[www.dental-tribune.com](http://www.dental-tribune.com)



## DENTAL TRIBUNE

— The World's Dental Newspaper —