

cosmetic dentistry

— beauty & science

4²⁰¹¹

| **case report**

Cosmetic periodontal surgery

| **clinical technique**

Clinical application of a new flowable base material for direct and indirect restorations

| **industry report**

Professional in-office whitening of non-vital teeth

دانشگاه

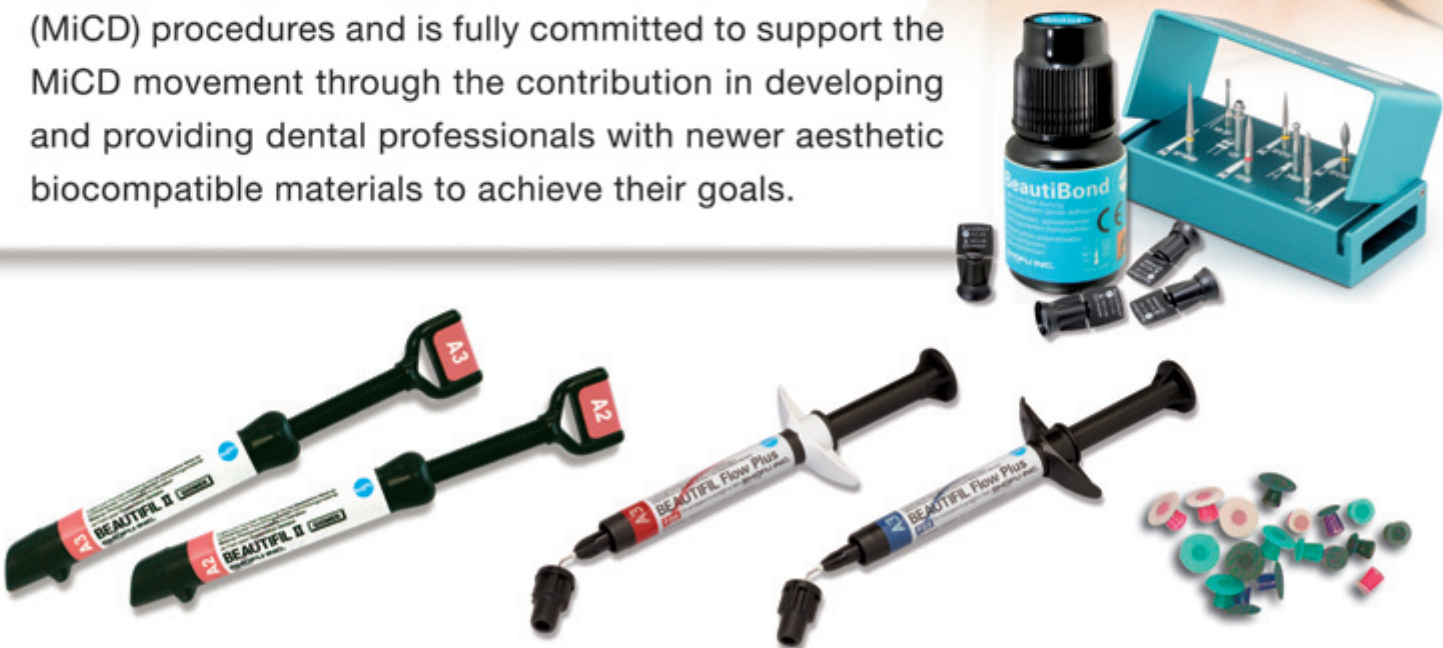

Adopt the trend...



Minimally Invasive
Cosmetic Dentistry

SHOFU recognizes the development of new clinical techniques in minimally invasive cosmetic dentistry (MiCD) procedures and is fully committed to support the MiCD movement through the contribution in developing and providing dental professionals with newer aesthetic biocompatible materials to achieve their goals.



For more information, simply contact your nearest **SHOFU** dealer.



SHOFU INC. SINGAPORE BRANCH

Tel (65) 6377 2722 Fax (65) 6377 1121 eMail mailbx@shofu.com.sg website www.shofu.com.sg

Dear Reader,

_Welcome to our fourth and final issue of 2011. I hope you have had a wonderful year in terms of your health, progress and prosperity!

The year 2011 was a very important one for aesthetic dentistry. The International Federation of Esthetic Dentistry, an apex body of aesthetic academies around the world, recently organised its seventh biennial scientific meeting in Rio de Janeiro in collaboration with the Brazilian Society of Aesthetic Dentistry. As executive council member and guest speaker at the meeting, I was excited to note the global trend towards cosmetic dentistry. With more than 1,100 registrations and delegates from all around the world, the meeting was very successful in sharing knowledge and experiences about the cosmetic dental practice in different parts of world. There were 42 oral presentations from the UK, Germany, Nepal, Greece, Korea, Japan, Italy, Israel, Belgium, Switzerland, the USA and host country Brazil. High quality clinical cases—many of them with a focus on excellence, precision and quality aesthetic case finishing—were presented by world-class clinicians.

As I have been advocating minimally invasive cosmetic dentistry for many years, it was quite exciting for me to note that almost all speakers mentioned the role of and their concern with the biological cost of the treatment they provide. Today, the Hollywood Smile concept is slowly fading. Aesthetic dentists are focusing on customised smile design with respect to naturo-mimetic dentistry and are applying minimally invasive approaches.

However, I have also noticed that while aesthetic case finishing and excellence in visual elements are in focus, invisible components, like occlusal forces, are not. Force finishing—balanced bite forces with harmonised teeth contact timing—is the missing link in cosmetic dentistry and must be incorporated to achieve long-term health, function and aesthetics of the cosmetic work that we perform.

I personally foresee that apart from aesthetic results, harmonised teeth, muscles and joints (TMJ) will become the major criteria in the future to evaluate clinical success in cosmetic dentistry. The value of function in achieving aesthetics will be better understood and slowly, the concept of TMJ harmony will be implemented in cosmetic dentistry for the true promotion of naturally pleasing, functionally balanced and healthy smiles for our patients.

In this issue, we have gathered various clinical articles related to your clinical practice and I hope you will enjoy them.

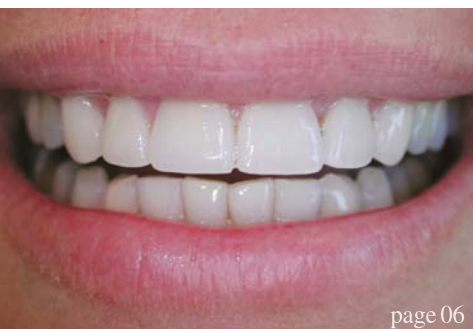Yours faithfully,



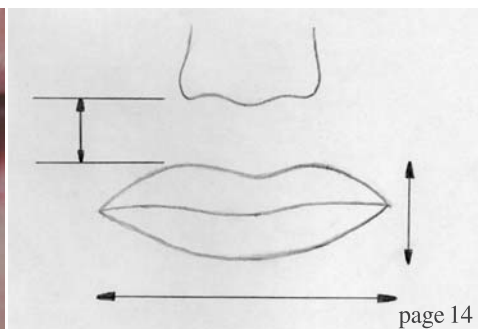
Dr Sushil Koirala
Editor-in-Chief
President Vedic Institute of Smile Aesthetics (VISA)
Kathmandu, Nepal



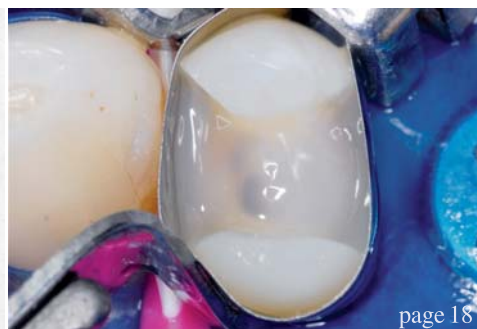Dr Sushil Koirala
Editor-in-Chief



page 06



page 14



page 18

| editorial

03 **Dear Reader**

| Dr Sushil Koirala, Editor-in-Chief

| case report

06 Making a **single veneer** blend so naturally that it's **undetectable**

| Dr L. Emery Karst

10 Cosmetic periodontal surgery: **Multiple gingival graft techniques (Part II)**

| Dr David L. Hoexter

| special

14 Aesthetic guidelines for **natural-looking dentures**

| Björn Maier

| clinical technique

18 Clinical application of **a new flowable base material** for direct and indirect restorations

| Prof Peet van der Vyver

| practice management

24 **Connectivity in the dental world**

| Shane Hebel

| industry report

28 **CLEARFILE ESTHETIC CEMENT** for crowns and bridges

| Dr Harry Denissen & Thomas Reiter

34 **Professional in-office whitening** of non-vital teeth

| Dr Ludwig Hemeler

36 **Anterior tooth restoration—An exciting experience**

| Dr David Hacmoun

38 **Simplifying direct composite resin restorations in the aesthetic zone**

| Dr Ian E. Shuman

| industry news

42 **The new PANAVIA POST—Long-lasting and reliable**

| Kuraray

| meetings

44 **DFCIC—Where science meets the art of beauty**

| Dr Dobrina Mollova

46 **You really don't have to leave Europe!**

| Dr Philip Lewis

48 **International Events**

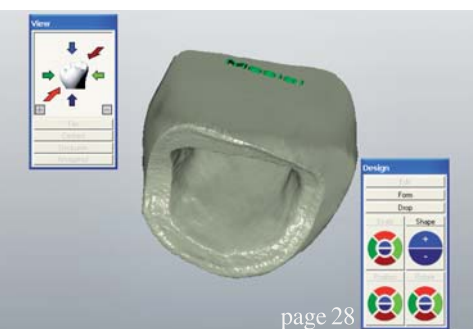
| about the publisher

49 | submission guidelines

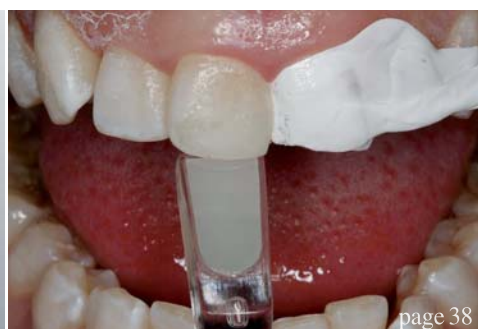50 | imprint



Cover image courtesy of Ekaterina Pokrovskaya.



page 28



page 38



page 44

Some things last forever.

PANAVIA™ POST

The new glass fiber post with excellent mechanical durability – your solution for long-lasting, reliable restorations.

PANAVIA™ POST is a fiber post made of resin reinforced glass fibers with high mechanical durability and an optimal elastic modulus for your reliable restorations. This effect is achieved thanks to Kuraray's unique monomer technology and surface treatment technology.

While other posts will lose their stability inside the post and might break, PANAVIA™ POST stays strong and stable – due to a strong adhesion between the glass fiber and the resin.

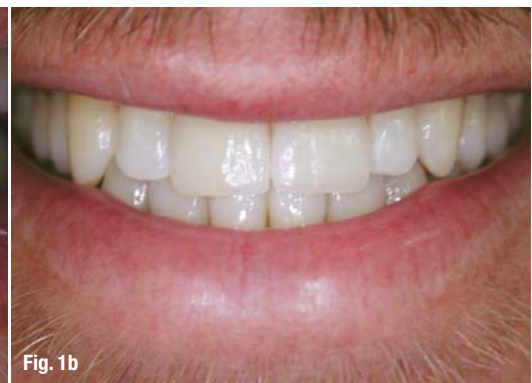
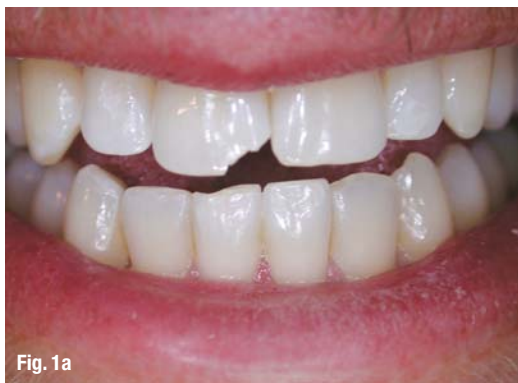
Your benefits:

- ✓ Excellent mechanical durability of long-term restoration
- ✓ Low risk of debonding and root fracture
- ✓ Esthetic restoration and ideal light-curing property

Making a **single veneer** blend so naturally that it's **undetectable**

Author_ Dr L. Emery Karst, USA

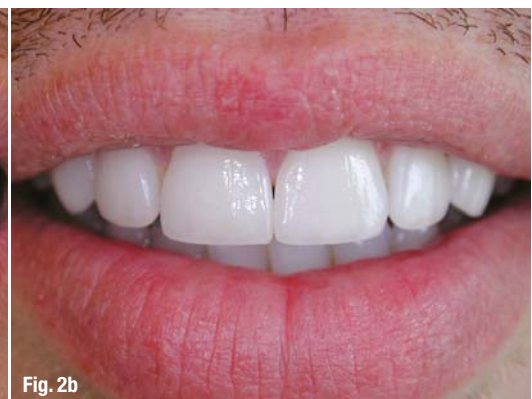
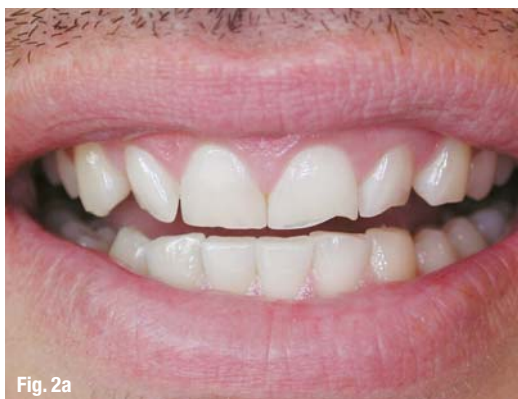
_As patients get older, anterior teeth commonly show wear, chipping and discoloration. These changes are the result of a number of factors associated with ageing. There is increased awareness of these unattractive teeth and the desire to have a more youthful appearance. Because of the recent media attention on changing one's appearance with veneers, there is a much greater demand for cosmetic dentistry procedures.

Over the years in the practice of dentistry, I have developed products and techniques that

have improved my practice significantly. However, it was not until I took on an associate, who had been in practice for 18 years that I became aware that these were new and innovative ideas to him, as well as to other dentists he knew.

I have been placing veneers for more than 25 years and developed a technique that can make a single veneer blend so naturally with the other teeth that it is undetectable. Various nuances in technique make preparing and bonding veneers quick and easy.



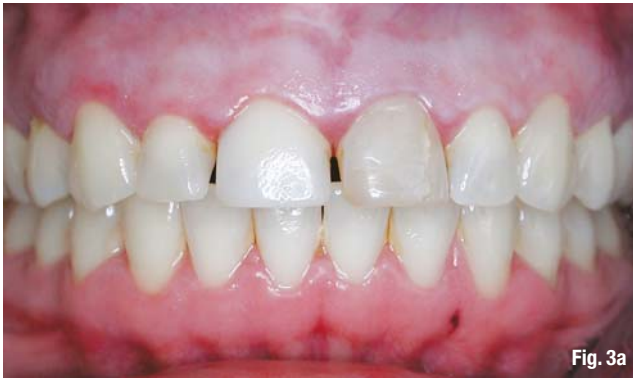

Fig. 3a

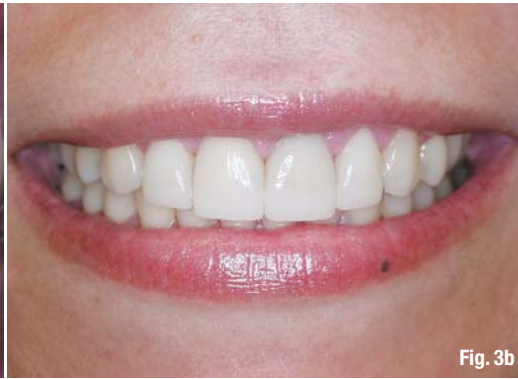

Fig. 3b

I have a CEREC machine that works especially well for a single veneer. Six or eight veneers can be done on the CEREC, but this is then rather time consuming. Two or three cases of the same number of teeth could have been prepared, impressions taken and sent to a laboratory in the same period. It is more cost effective to use a laboratory but you have to have the best laboratory available to you if you expect perfect results.

Feldspathic porcelain is the only material that will look natural. Pressed ceramics will look more opaque, somewhere between a porcelain-fused-to-metal restoration and a natural tooth. For patients requesting brilliant white, feldspathic porcelain can work well too and one can adjust the colour by the bonding composite used under the veneer.

Very little shade adjustment can be done under pressed ceramic porcelain. Flowable composites work the best and come in many shades, which makes shade adjustments easy. The flowable composite by Kerr has the right consistency for veneers and with OptiBond Solo the company offers the strongest bonding agent.

The preparation requires only a little more than 0.5 mm of reduction so that it does not go through the enamel, if possible. The bond is

the best on enamel. There should be the same reduction over the total facial surface for the laboratory to make a perfect veneer. Cut three or four depth grooves of 0.5 mm then remove the enamel to the grooves.

If instant orthodontics is the treatment plan, some teeth may need to be reduced more and others less. Run the preparation interproximally from gingival to incisal to hide the margin visually, but do not break the contact point.

The gingival margin should be at the gingival crest or a little below. It should have a chamfer for ease of finishing, precluding any chipping at the margin. Some dentine will show through at the gingival margin because the enamel is less thick there. If there is room, insert a thin piece of gingival braid, which can be left there during the impression. Reduce the incisal by approximately 1 mm so the finish line is on the lingual, and round the incisal-facial junction so that there are no potential fracture lines in the veneer.

When the veneers come back from an excellent laboratory there should be little or no adjustments necessary before bonding them to the teeth. Etch them with hydrofluoric acid gel for at least three minutes. Rinse them thoroughly, neutralise them with a baking-soda slurry and

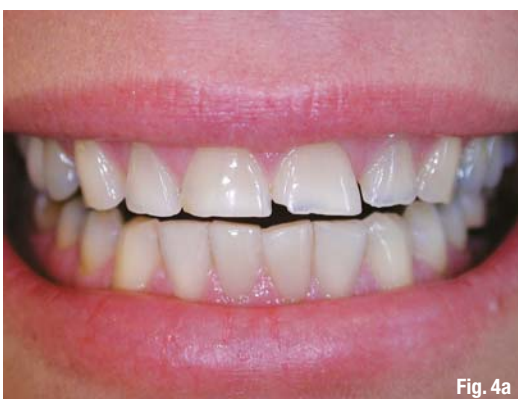

Fig. 4a

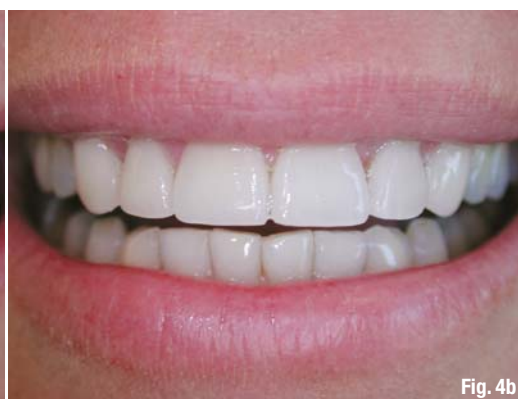
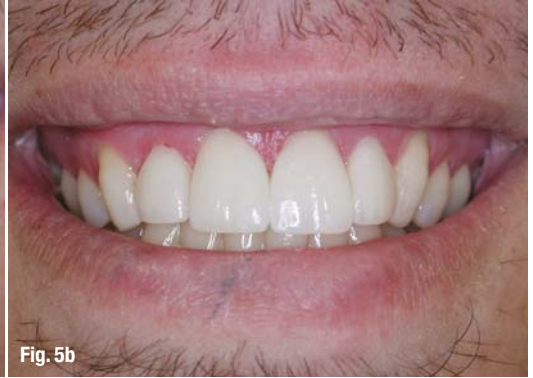
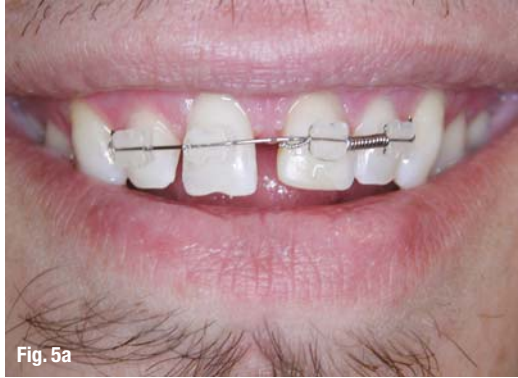Fig. 4b



then rinse them thoroughly again. Dry them with a dry air source until a chalky appearance is visible on the interior of the veneer.

Ceramic primer is then applied for one minute. Dry until it is chalky again and apply another coat of ceramic primer. Leave the primer on while the teeth are etched with phosphoric acid gel for 30 seconds. Rinse thoroughly and dry the teeth and veneers until a chalky appearance shows on both.

Turn the operatory light off and then apply bonding to the teeth and the veneers. Place the flowable composite onto the veneers one at a time for placement. Place all of the veneers and ensure they are correctly situated.

With two hands, hold the distal two veneers (teeth #5 and 6) in place leaving a space only large enough for a curing light to shine in between. Shield the rest of the veneers with your hand so that the light will not set any of the other composite except the interproximal space between veneers #5 and 6. Cure for only two seconds. Now cure the distal of veneer #5 for two seconds.

Move your hands to veneers #6 and 7, shielding the rest of the veneers and holding veneer #5 and 6 in place, leave just enough room to cure the space between #5 and 6 for two seconds. Repeat the same process for the rest of the veneers, moving from #7 to 8 and so on, until all of the interproximal spaces have been cured for two seconds each, including the distal of the last veneer on the other side.

Now cure the centre of each veneer for two seconds and then the lingual incisal of each for two seconds too. If cured for longer than this, it is very difficult to remove the excess composite and much time is consumed in the process.

The first step in removing the excess composite is the use of a Bard-Parker #12 scalpel. With a palm grasp and your thumb resting on the incisal edge of a tooth, engage the flat side of the blade close to the incisal edge and push gingivally to loosen the interproximal composite.

Continue until most of the composite has been loosened and removed. Use a Wedelstadt chisel in the same fashion to loosen the gingival composite. To break the contact, a serrated interproximal strip is used in a cross-cut sawing fashion.

The Bard-Parker #12 scalpel is used again to remove more interproximal composite. Blue-tipped diamond strips are then used to remove any remaining composite and a yellow-tipped diamond strip is used to smooth. Adjust the bite, polish and you are done. Figures 1a to 5b demonstrate the good results of the technique described in this article.

_about the author

cosmetic dentistry



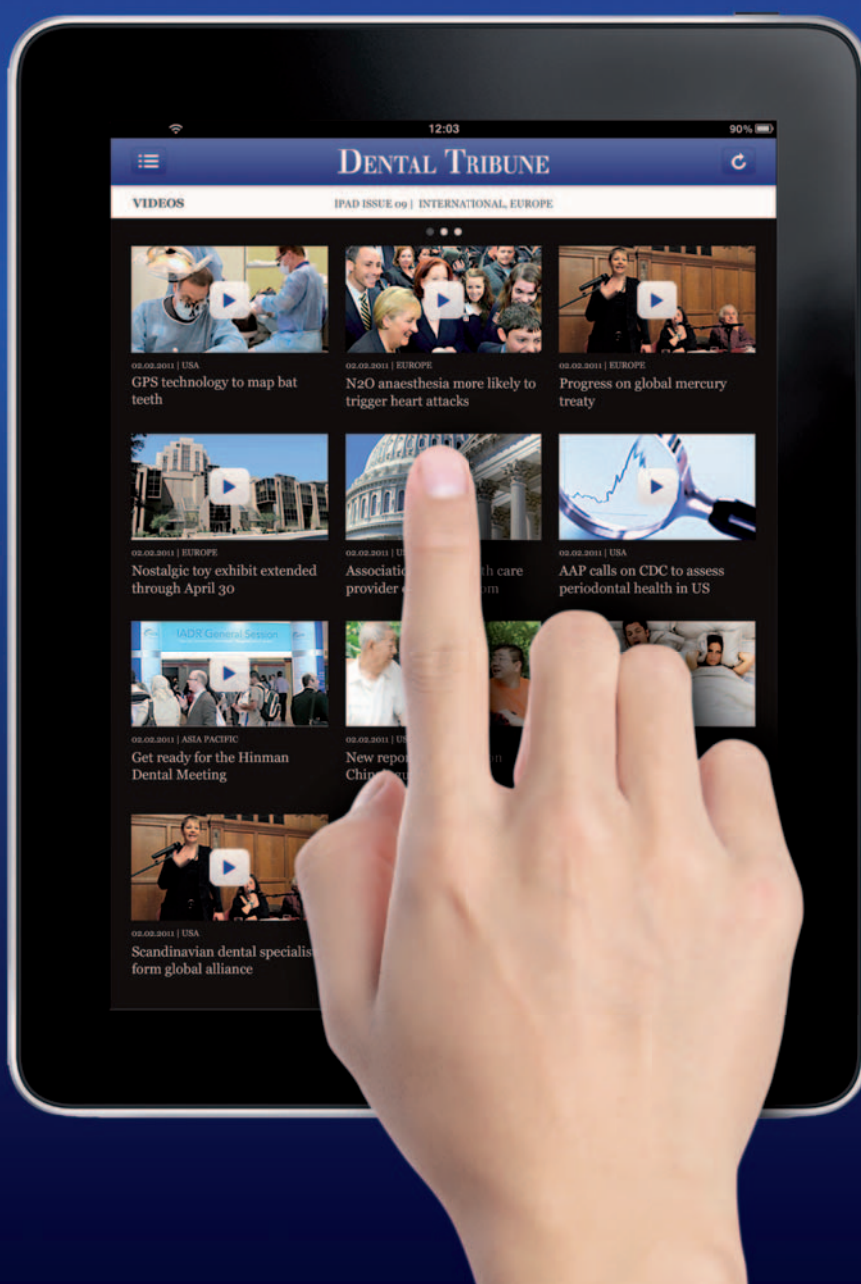Dr L. Emery Karst, a graduate of Loma Linda University's School of Dentistry, has been practising the art of cosmetic dentistry for more than 20 years. Although he enjoys cosmetic dentistry the most, he also regularly

undertakes work in endodontics, implants, crown and bridge and other techniques. Dr Karst's articles on endodontics and cosmetic techniques have been published in *Dentistry Today*. He also lectured on endodontics at the Oregon State Dental Convention in 2010.

Dental Tribune for iPad – Your weekly news selection

Our editors select the best articles and videos from around the world for you every week. Create your personal edition in your preferred language.

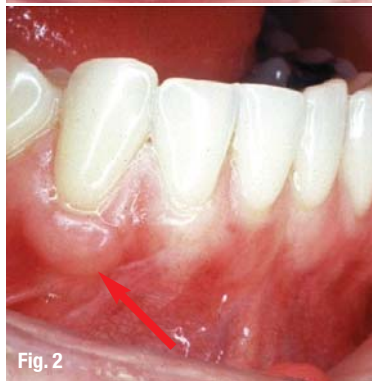
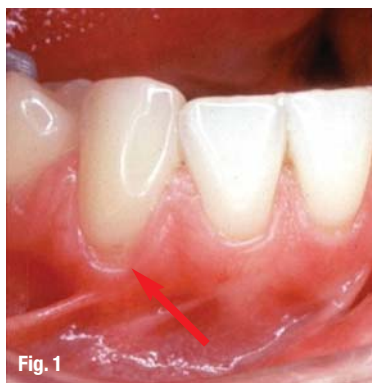
ipad.dental-tribune.com



Cosmetic periodontal surgery: Multiple gingival graft techniques (Part II)

Author_ Dr David L. Hoexter, USA

_In today's new information age, patients want a better quality of life. They want to keep their youthful, bright smile more than ever; keep their natural teeth; have their teeth feel and look better; and have a glowing smile. In recent years, dentistry appears to have concentrated almost exclusively on accomplishing this smile by focusing on the crown portion of the tooth. Restorative materials are being made available to help dentists create the crown's natural colouring, whitening, and hues. The crown has been lengthened, squared, made ovoid, rounded and shortened. Reproduction of the crown's original shape and colour has also been attempted.



Aesthetic dentistry must now turn its focus towards achieving an aesthetic totality, not just the perfect crown or restoration. Many materials have been developed to help achieve an artistic tooth colour, but the desired aesthetic result still depends on the background accentuating the desired image—something great painters have long known and created in fine oil paintings. This background must both drape around and emphasise the object. It can make or break the object that clinicians wish people to see. If the background is distracting, the object loses its importance.

For example, cosmetically, if a crown is restored correctly against a healthy, pinkish-white gingiva, the patient's illusionary smooth smile line can be successfully achieved and viewed. However, if that same crown is placed against an unhealthy, inflamed, reddish gingiva, the eye's focus will be towards the unaesthetic area. A porcelain laminate placed against a natural pink gingiva is simply more pleasing and compatible with its background.

As mentioned in Part I of this series, achieving consistently successful dental aesthetics is mostly a function of creating desired illusions. The first step

is ensuring that certain fundamental principles of health are preserved, respected and maintained.

Achieving healthy periodontia is the prerequisite and basis for sustaining this illustration of oral health. It is essential for restorative aesthetics, as well as natural dentition, enabling clinicians to better their chances of achieving successful restorative results and maintaining the results. By incorporating the use of tissue colours, hues, forms and symmetrical appearances one can achieve and maintain the desired aesthetic goal.

As in other forms of art, a symmetrical appearance tends to focus the observing eye on the overall illusion. Assuming there is no pathology, symmetry of colour zones and hue is vital to gain the desired illusion and distract attention from a defective area.

The gingival layer of keratinised tissue is at the margin of natural teeth and around the crowns. The muco-gingival junction separates the outstanding colour demarcation of the pinkish keratinised attached gingiva from the mobile alveolar mucosa, which is a reddish-blue zone. Nature's colourations of these zones in symmetrical form are what clinicians must strive for to achieve and maintain health and aesthetics.

If, for example, an adequate zone of attached gingiva were unevenly distributed in the same quadrant, the reddish-blue alveolar mucosa would be out of place and draw negative attention. In contrast, if the attached gingiva locally were to encroach on the alveolar mucosa, a colour reversal would occur, resulting in a large, uneven pink zone against an uneven reddish-blue background.

In the past, oversized free gingival grafts have frequently been used to replace absent or inadequate zones of attached gingiva. Those large donor grafts were protective but had an unaesthetic appearance; an encroachment of colours into the alveolar mucosa

would usually occur. Even though this pink invasion was subtler compared with the reddish-blue of the alveolar mucosa invading the gingiva, it nevertheless broke the illusion of a symmetrical background.

As a further example, overgrowth of tissue, i.e. fibrous hyperplasia, changes the shape of the tissue, thereby partially covering the tooth and changing the appearance of its size. If covered by hyperplastic keratinised gingiva, the tooth appears smaller, especially when compared with the adjacent tooth. This overgrowth may be of developmental, iatrogenic or systemic origins. The result is unaesthetic. These can and should be corrected, which will be discussed in future parts of this series.

In referring to cosmetic illusion using gingival colours, it is important to reflect on examples of non-symmetrical colour breaks of the gingiva. They represent an unhealthy situation and are an eyesore because they disrupt aesthetics.

In a case of inflammation, permanent pathology may occur, resulting in irreversible unaesthetic root exposure (recession). A vertical reddish colour at the gingival margin may warn that pathology is starting.

Several techniques are reported to correct recession, but in reality, the result is not predictable for restored health. Therefore, it is predictably easier and aesthetically more achievable to treat the inflammation earlier. Without a healthy zone of attached gingiva, a crown's margin will become exposed, thus exhibiting an unattractive contrasting colour. It might be the underlying metal margin of the crown or the yellow colour of the recessed tooth's root.

Without a healthy zone, a laminate's margin will probably collect plaque and lead to inflammation and bleeding gingiva. As mentioned previously, this can draw negative attention and most likely lead to recession and irregular gingival pattern variations.

Part II of this series discusses and illustrates cosmetic periodontal surgery, utilising various gingival graft techniques to correct defects, obtain health, and produce colour, hues and forms that appear to be symmetric.

This type of surgery makes for happy patients who smile with brilliant confidence.

Case I

A young woman was referred to my office with exposed, unsightly longer-looking teeth. They appeared longer owing to her receding gums. Although the patient had a low caries rate and a good oral hygiene

technique, she had been told by a previous dentist that she had weak and ugly gums. She noted that her gums bled periodically when brushing, and complained about their unattractive appearance, which made her stiffen her lower lip when smiling. She was intelligent and self-conscious of her problem. She desired to have the recession stopped and the aesthetics to smile with confidence.

Examination revealed that the lower right cuspid had recession (Fig. 1), showing an exposed buccal root. There was an absence of attached gingiva, leaving the area surrounded by alveolar mucosa. Therefore, the tooth was surrounded by reddish tissue, which made the root more visibly unattractive. The contrast of deep red colour surrounding an exposed root was accentuated when the lip was retracted, showing a frenum pull. This made it difficult for her to keep the area free of plaque. In contrast, adjacent teeth had pink attached gingiva.

The surgical technique chosen to correct this defect, restore her health and enhance her aesthetics was a variation of the lateral oblique pedicle graft technique.

Treatment

The #28, 27 and 26 area was anaesthetised using 0.001 % lidocaine. The local anaesthetic was infiltrated locally both buccally and lingually. A #15 blade was used to incise an outline, which included all the interproximal keratinised tissue of teeth #28 and 27, as well as the buccal aspect of #28. The poor, small buccal zone of tissue was removed from the #27 buccal area.

The recipient site was then prepared. The tooth was lightly scaled. A periodontal elevator (Hoexter-elevator, Hu-Friedy) was utilised to reflect the tissue. The incision also included the alveolar mucosal area, allowing ease of mobility. The graft flap was rotated so the largest portion of the keratinised area could

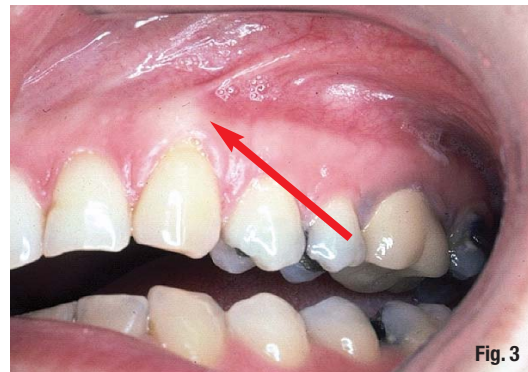

Fig. 3

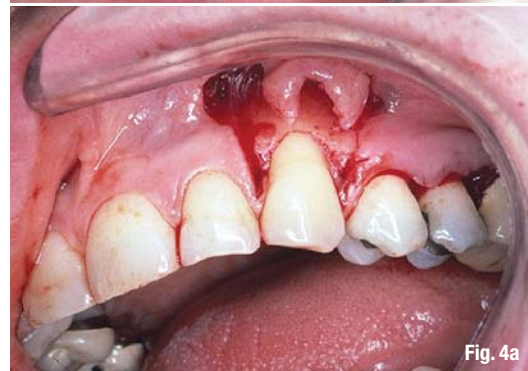

Fig. 4a

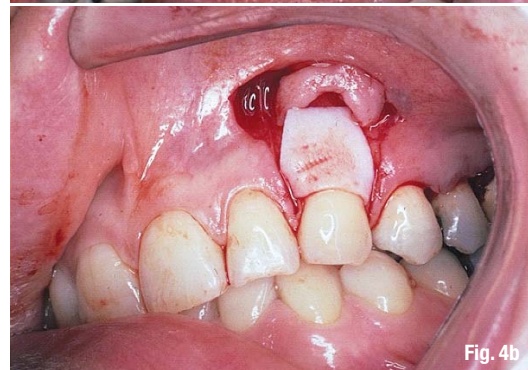

Fig. 4b

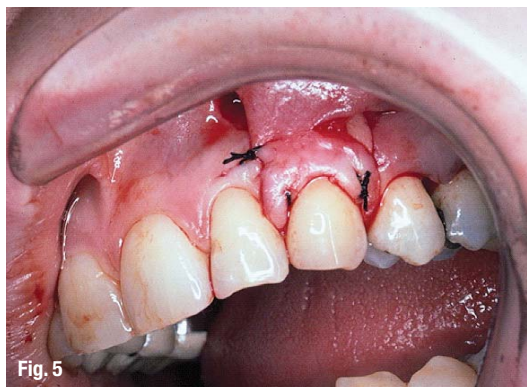

Fig. 5

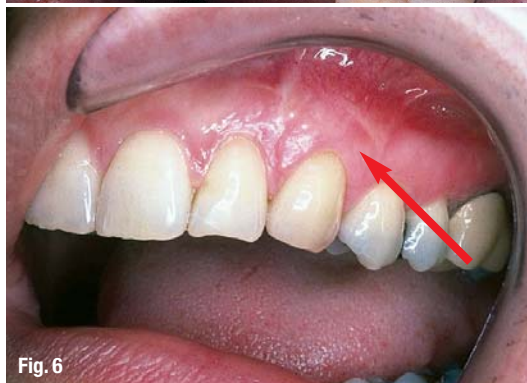

Fig. 6

be employed to cover the recessed area and the newly exposed recipient buccal blood supply of tooth #27. To stabilise the graft in our desired position, a sling suturing technique was utilised. The area was covered with a periodontal dressing (COE-PAK, GC). Tetracycline 250 mg was prescribed q.i.d. for seven days. An analgesic was also prescribed.

The results present an obviously healthy and restored symmetrical, pink zone of attached gingiva and continuity with the adjacent area. The recession was gone, the length and width of the attached gingival was symmetrically blended with the adjacent area, and the frenum pull had been corrected. Figure 2,

taken 15 years post-operatively, attests to the durability of the results using this technique.

The results enabled the patient to smile with confidence, without hesitation. She no longer had the reflexive action of holding her lip back. The procedures also permitted her to maintain good oral hygiene, reassured her that her teeth would be retained (recession indicates age to some), and achieved a maintainable, normal colour balance, which collectively created an aesthetically pleasing appearance.

Case II

The predictability of the results of root recession coverage has been improved in recent years with the utilisation of guided tissue regeneration (GTR). This case demonstrates another gingival graft technique: the coronal repositioned gingival graft. It uses GTR using an acellular collagen membrane, which adds to the predictability of acquiring a blood supply. The resultant zone of attached gingival and root coverage blend aesthetically into the background with a symmetrical width and lateral flow of healthy, pink keratinised tissue.

From the initial appearance of tooth #11 (Fig. 3), the longer-appearing cuspid with recession is evident, which made it stand out and caused the area to be unattractive and noticeable. Figures 4a and b show the acellular membrane placed over the exposed buccal root of #11, after the buccal flap had been reflected. The tissue was sutured with a con-

tinuous suture covering the exposed root in the desired final position and the acellular membrane (Fig. 5; the acellular collagen preferred in this technique in my office is supplied by CK Dental). Figure 6 shows the healed area four months later. The recession had been reclaimed by a healthy attached gingival zone. The results allowed a symmetrical appearing zone of pink, keratinised tissue to blend into the area. The cuspid no longer appeared to be greater in length than the surrounding dentition. The linear, even shape of the teeth was aesthetically pleasing. The overall result is easily maintained by the background of correct colour, texture, and symmetrical zone of appearance and health.

Summary

Fortunately, in these particular cases, the patients' dental awareness made it possible for them to request correction of their oral health and aesthetics. These illustrations demonstrate the aesthetic awareness and desires of today's society. Practitioners must be able to recognise and work towards these goals. By creatively using variations of techniques to achieve such results, the art of dentistry is mastered. Achieving health is primary, but providing a maintainable, healthy and pleasing appearance is also significantly desirable and important.

*Editorial note: Part I of this series—Cosmetic periodontal surgery: Pre-prosthetic soft-tissue ridge augmentation—was published in **cosmetic dentistry** Vol. 3, Issue 4/09. A PDF is available from the publisher.*

about the author

cosmetic
dentistry



Dr David L. Hoexter is a clinical professor in Periodontics at Temple University, Philadelphia, and Director of the International Academy for Dental Facial Esthetics. He is a diplomate of implantology in the International Congress of

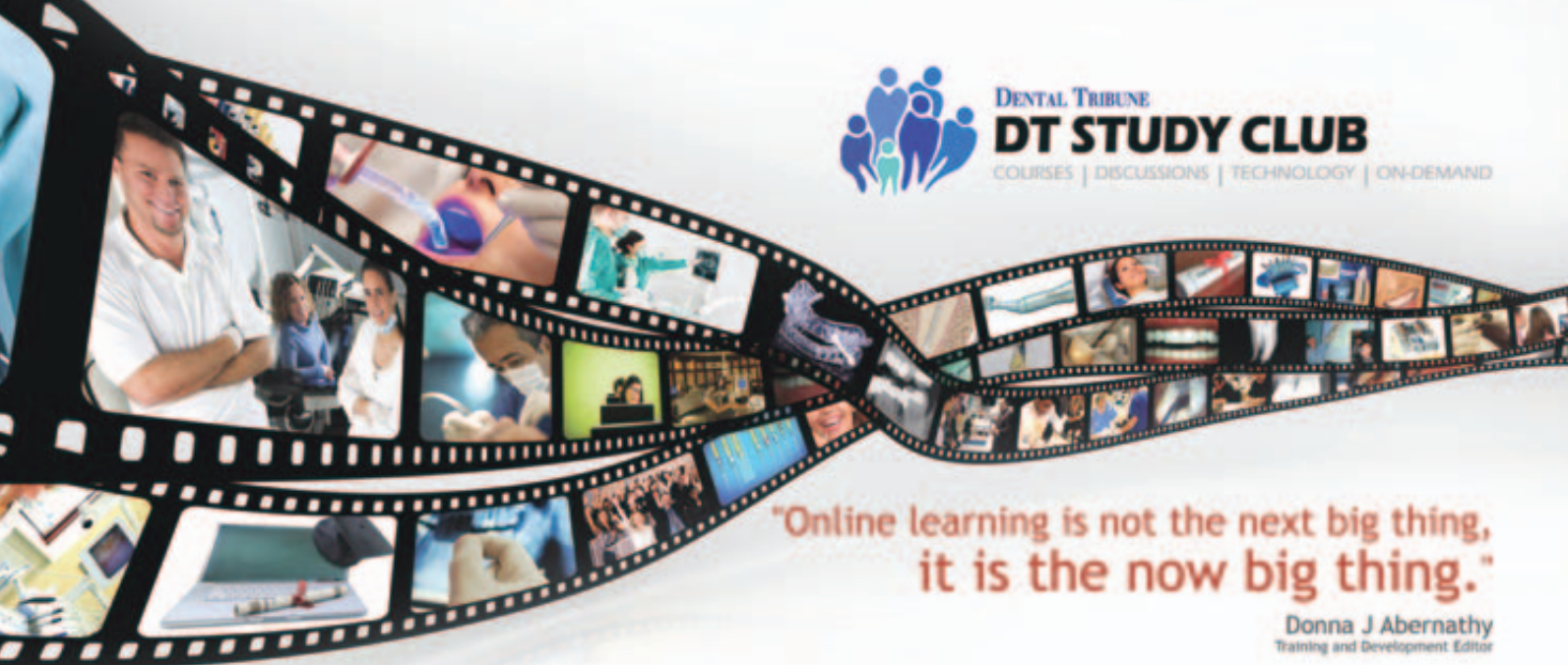Oral Implantologists and the American Society of Osseointegration, and a diplomate of the American Board of Aesthetic Dentistry. Hoexter lectures throughout the world and has published nationally and internationally. He has been awarded 11 fellowships, including Fellow of the American College of Dentists, of the International College of Dentists, and of the Pierre Fauchard Academy. He maintains a practice at 654 Madison Ave., New York City, that specialises in periodontics, implantology and aesthetic surgery. He can be contacted on +1 212 355 0004 or at drdavidlh@aol.com.



DENTAL TRIBUNE

DT STUDY CLUB

COURSES | DISCUSSIONS | TECHNOLOGY | ON-DEMAND



**"Online learning is not the next big thing,
it is the now big thing."**

Donna J Abernathy
Training and Development Editor

DTSC - COURSES, COMMUNITY, TECHNOLOGY, ON-DEMAND

The DT Study Club makes all of this is possible from the comfort of your own computer and without travel expenses. In other words, welcome to the community!

The purpose of this study club is to provide practitioners like yourself an opportunity to learn and network with like-minded colleagues in a friendly, non-threatening environment. We encourage you to take advantage of Dental Tribune's global outreach to access a variety of fresh perspectives and cultures, enhancing your educational mix.

24/7 LIVE AND INTERACTIVE ONLINE COURSES

Fulfill your yearly CE requirements with our growing list of archived ADA CERP approved courses.



DISCUSSION FORUMS

focused on helping today's practitioners to stay up to date. Networking possibilities that go beyond borders to create a truly Global Dental Village



VIDEO REVIEWS OF PRODUCTS

Our opinion leaders unveil new products, services, and give you their first impressions of the industry's hottest topics.



PEER REVIEWED CASE STUDIES

Upload, comment, participate. We encourage you to share your cases for review with like-minded practitioners.



 REGISTER FOR FREE ON WWW.DTSTUDYCLUB.COM

CONTESTS WITH CHANCES TO WIN FREE TUITION FOR ADA/CERP C.E. ACCREDITED WEBINARS

SPONSORSHIP AND SPEAKING INQUIRIES:
JULIA WEHKAMP, J.WEHKAMP@DTSTUDYCLUB.COM, (416) 907-9836.

ADACERP
CONTINUING EDUCATION RECOGNITION PROGRAM



PRACTICE MANAGEMENT



GENERAL DENTISTRY



COSMETICS



ENDODONTICS



IMPLANTOLOGY



PERIODONTICS




ORTHODONTICS



DENTAL HYGIENE

WWW.DTSTUDYCLUB.COM



Aesthetic guidelines for natural-looking dentures

Author_ Björn Maier, Germany

_Natural-looking dentures have always been a great challenge for the dental technician or prosthodontist. With so many different brands of acrylic tooth systems on the market, it can be easy to overlook the basics of tooth shape and its relation to the physiology of the face.

In this article, I consider the morphology of the anterior teeth in particular. Tooth shapes vary enormously between individuals and to the untrained eye, a system of defining these shapes probably seems remote. However, if you look at the face as a whole, you will very quickly understand how nature constitutes the relationship between tooth shape and facial physiology through human genetic development (Figs. 1–3). This article will help you to identify the corresponding characteristics of tooth shape through a systematic approach suitable for each case.

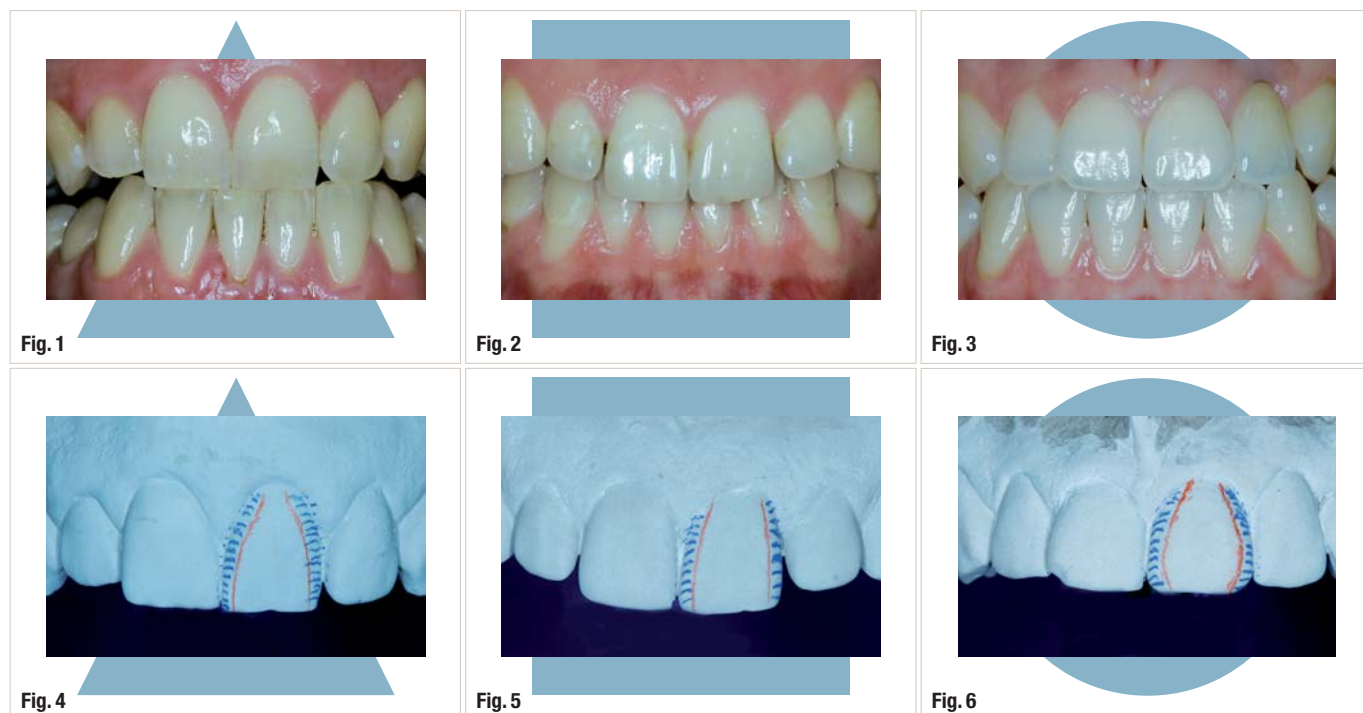
First of all, it may help to peruse the illustrations in order to understand the system and the connections between the illustrations.

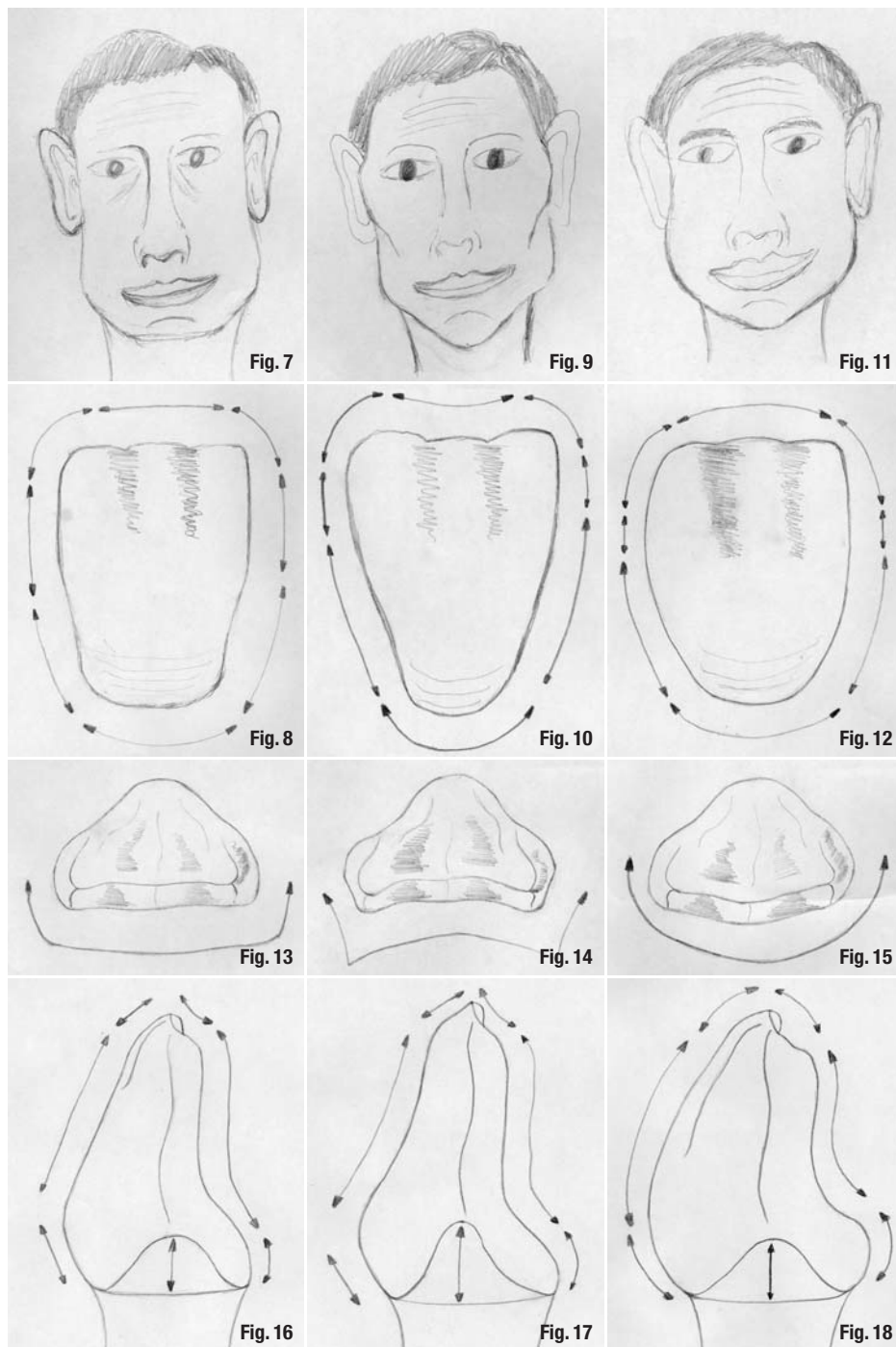
Consider general anterior tooth morphology and you will recognise, in addition to the obvious characteristics, further specific individual features, like the difference between a central incisor and a canine. Although the variety of different shapes of the anterior teeth appears to be immense, this can be quiet deceiving. If one leaves aside the tooth positions and the colour of the tooth, the general morphology consists of two factors (Figs. 4–6):

1. the basic shape of the tooth, i.e. definitive width; and
2. the marginal ridges or line angles of the tooth, which defines the optical width.

This correlation of optical width and definitive width leads to the different shapes of teeth. This morphological variety can be subdivided into three basic principles. These three fundamental archetype shapes are square (athletic), tapering (leptosome) or ovoid (pyknic). All other tooth shapes are considered to be hybrid shapes.

- Fig. 1_** The triangular tooth shape.
Fig. 2_ The rectangular tooth shape.
Fig. 3_ The oval tooth shape.
Fig. 4_ When looking at the marginal ridges or line angles, the square tooth shape is recognisable.
Fig. 5_ When looking at the marginal ridges or line angles, the triangular tooth shape is recognisable.
Fig. 6_ When looking at the marginal ridges or line angles, the oval tooth shape is recognisable.





Figs. 7 & 8_An athletically built person with an angular face (square). The labial tooth shape resembles the reversed shape of the face.

Figs. 9 & 10_The leptosome tooth shape of a thin or skinny person with the individual characteristics of the marginal ridges.

Figs. 11 & 12_Person with a rounded (ovoid) form of the face (pyknic) and the ovoid tooth shape with the individual characteristics of the marginal ridges.

Fig. 13_Even from the incisal aspect, the respective shape characteristics are visible.

Fig. 14_The triangular type (leptosome) with an introverted labial surface.

Fig. 15_The ovoid type (pyknic) with an extroverted labial surface.

Fig. 16_Detailed characteristics when viewed from the approximal.

Fig. 17_Detailed characteristics of the triangular tooth shape.

Fig. 18_Detailed characteristics of the ovoid tooth shape.

In 1914, Leon Williams suggested a now famous classification system of tooth shape, theorising that these three fundamental shape types are reflected in the "Kretschmer Construction Types" (facial outline types). The shape of the tooth is equal to the horizontally flipped shape of the face (Figs. 7-18). For example, an athletically built person with an angular face would have square-shaped teeth (Figs. 7, 8, 13 & 16). A thin person with a peaked chin (leptosome) would have triangular-shaped teeth (Figs. 9, 10, 14 & 17).

Today, this classification of the tooth shapes based on the shape of the face is considered to be antiquated. Hence, it only serves as a very rough general guide when selecting a set of anterior acrylic teeth for a patient case. In the fifties, the "dentogenic concept" by Frush and Fisher spread across the US and then to other parts of the world. According to this concept, a "personality spectrum" can also be added to help obtain the shape of the tooth. Next to clinical, intra-oral and facial relation considerations, the age, sex, and other characteristics of the patient are

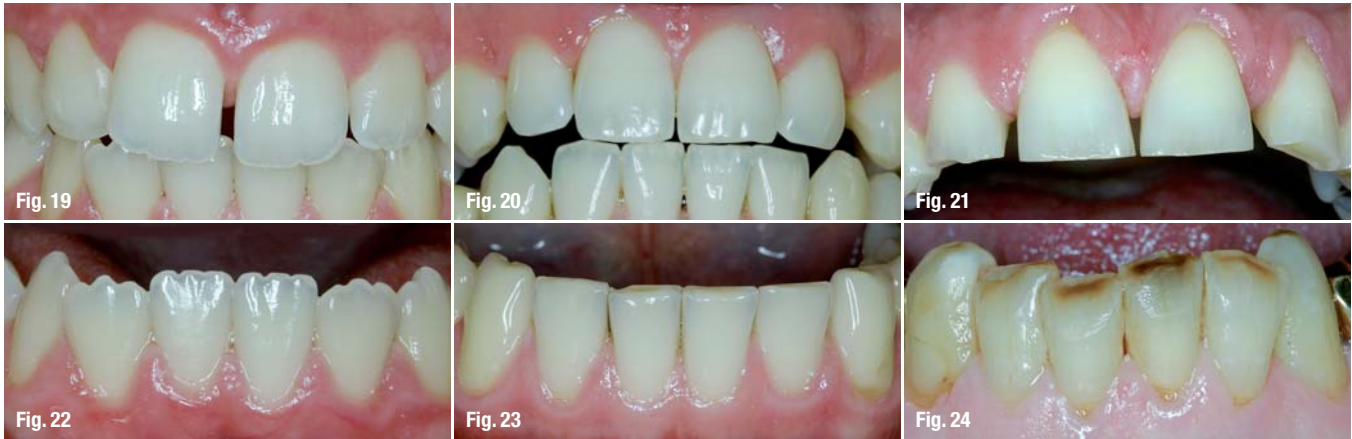

Fig. 19 Twelve-year-old patient with nicely indented incisal edges.

Fig. 20 Comparison of a 30-year-old patient with abraded incisal edges ...

Fig. 21 ... and a 50-year-old patient with strongly worn incisal edges.

Fig. 22 Mandibular anteriors of a 12-year-old patient with strong mamelons.

Fig. 23 Mandibular anteriors of a 30-year-old patient.

Fig. 24 A set of lower anteriors with strong occlusal wear facets.

also considered. Today, taking all of these factors into account, one will most likely derive some sort of hybrid shape based on one of the three original basic shapes.

The concept of the three basic shapes with regard to the labial effect of a tooth can be demonstrated when viewed from the incisal perspective. A study by Yammamoto demonstrates this well (Figs. 13–15). From the incisal perspective, the relative flatness of the square shape, the concavity of the triangular shape and the convexity of the ovoid shape is apparent.

Another decisive aspect of a successful natural reproduction is the design of the marginal ridges or line angles, which has an effect on the 3-D appearance of the tooth.

Besides the shape and the width of the tooth crown, the width of the root is also a decisive factor. Up to now, I have restricted the consideration of the tooth to the labial and incisal view. In order to be able to replicate the 3-D appearance of the tooth, we must also consider the labial curvature of the tooth (Figs. 16–18). From this point of view, the incisal triangle features can also be divided into the three basic components. For each individual case, it is then necessary to derive the respective hybrid shape.

After this has been considered, the following types can be derived from the mesial view:

The oval anatomy type

- The two well-developed labial marginal ridges are the key characteristic feature of this anatomy type.
- A strong labial depression and a wide labial transitional surface are present. The difference between the mesio- and the disto-approximal surface is noticeable. The distal face is wider than the mesial.
- The growth lobes are generally not very prominent with this tooth shape type.

The three-angled anatomy type

- The mesial and distal marginal ridges are again distinct but not as strong as with the oval anatomy type.
- The labial surfaces are relatively wide, without a noticeable difference in width between the mesial and the distal.
- The labial and proximal growth lobes are prominent.

The square anatomy type

- The characteristic feature of this anatomy type is the indistinct marginal ridges, which can sometimes cause a rather plain look.
- A well-developed central marginal ridge is present, which appears quite prominent when viewed from the incisal edge.
- The labial and approximal depressions are somewhat strongly developed, although not as strongly as with the triangular type.

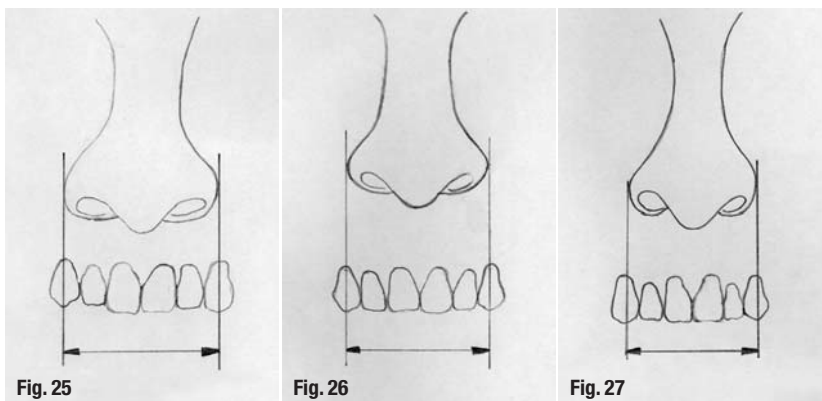
The marginal ridges or line angles develop in the sulcus and run parallel to the basic outer shape of the tooth towards the incisal edge. At the incisal aspect, the progression of the marginal ridges differs between un-abraded juvenile teeth and worn aged teeth (Figs. 19–24).

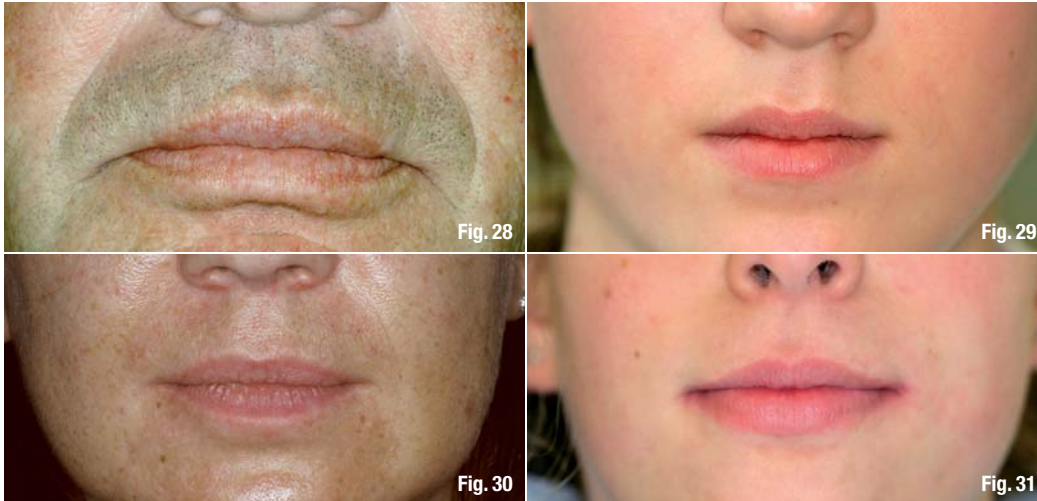These different morphological characteristics are evident in the case of adjacent teeth, which makes the

Fig. 25 The nose base determines the width of the upper anterior teeth (Gerber).

Fig. 26 The average nose type correlates with the average width of anterior acrylic teeth.

Fig. 27 A narrow nose base is an indication of slender anteriors.





Figs. 28–31 _These images show just a few of the many dento-facial varieties that can be found in nature.

reconstruction of a single tooth quite easy. A great deal of information is needed in order to rebuild the shape of a tooth and to recreate a natural, harmonious look. It becomes more complicated when it is necessary to replace the whole anterior segment or the dentition in an entire jaw. For this reason, the knowledge of the anatomical features of the single tooth is very important.

A further aid for determining the definitive width of the teeth is the width of the nose base, which agrees in most cases with the width of the front teeth (Figs. 25–27). In his theory, Gerber suggests, amongst other things, that from an embryo-genetic view the proportion of the nose base and the width of the nose root can be determined (Figs. 28–31).

When it comes to determining the length of the anteriors, some clues can be derived from the age of the patient.

The lip type is of great importance here. In vertical perspective, we distinguish between a full and thin lip and/or between a long and short upper lip (Figs. 32–34). Patients with short upper lips expose more of their teeth than patients with longer upper lips. The lips outline the space that is subdivided by the arrangement of the teeth, which typically determines certain aesthetic key factors. One can achieve harmony with the remaining parts of the oral region by weakening or intensifying the visible tooth areas.

_Conclusion

In this article, I have only paid attention to the upper anteriors. The main reason for this is that the upper anteriors are aesthetically much more significant than the lower anteriors. The different shapes of teeth can be observed on both the upper and lower anteriors from the facial, mesial and distal aspects.

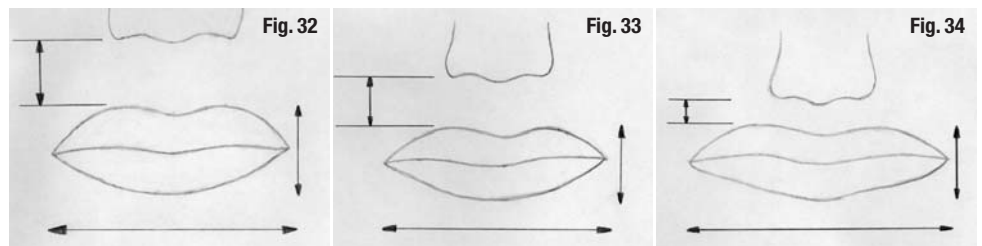
This method for achieving aesthetic harmony can be summarised as:

1. analysis of the facial parts, i.e. face shape type;
2. analysis of the dento-facial parts, i.e. lip-nose type; and
3. analysis of the intra-oral area, i.e. bite situation and remaining dentition._

Fig. 32 _Very full lips suggest long upper anteriors.

Fig. 33 _The standard lip type.

Fig. 34 _The shallow lip type suggests relatively short anteriors. This is also due to the small distance between the nose and the upper lip.



_about the author

cosmetic
dentistry



Björn Maier completed an apprenticeship as a precision mechanic in 1995 and subsequently completed an apprenticeship as a dental technician in his parent's dental laboratory in 1999. He then worked in the US, Germany and Switzerland. From 2006 to 2007, he completed the course at the Master School in Stuttgart, Germany, and opened up his own laboratory, Zahntechnik Björn Maier in spring 2007. He also lectures internationally.

Zahntechnik Björn Maier

Ludwigstr. 10
89415 Lauingen
Germany

info@bjoern-maier.com

Clinical application of a new flowable base material for direct and indirect restorations

Author_ Prof Peet van der Vyver, South Africa

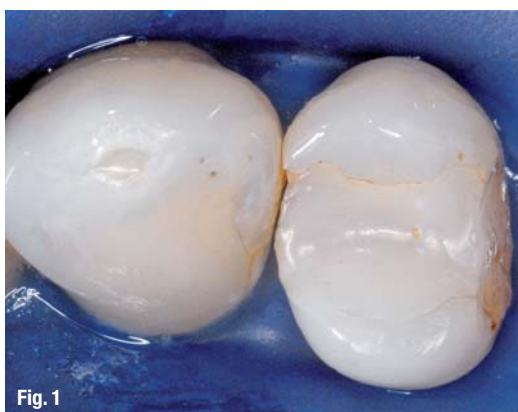

Fig. 1

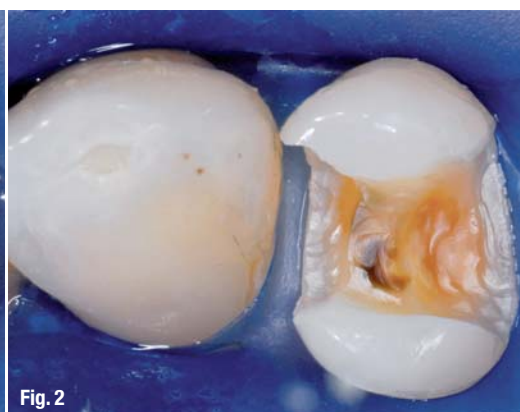


Fig. 2

Recent developments in composite resin materials and bonding technology have made the routine use of these materials in posterior teeth possible.¹ Direct posterior composite resin restorations are now predictable and durable, and in many instances their superior aesthetic and tooth-supporting properties make them the ideal treatment option when restoring the posterior dentition.² The main shortcomings of composite resin materials are polymerisation shrinkage³ and polymerisation

stress. Polymerisation stress can result in contraction forces on the cusps that can result in cuspal deformation,⁴ enamel cracks and ultimately decrease the fracture resistance of the cusps.⁵

Cavity configuration and the method of insertion of composite resin into the cavities can influence the gaps at the interface between the dentine/enamel and the restoration.⁶ According to Davidson and De Gee,⁷ the parallel walls of a box-shaped cavity may restrict the flow of composite during polymerisation, causing stresses at the resin-dentine interface.⁸

The present generation of chemically or light-activated flowable composites undergoes free volumetric shrinkage of 4 to 9 % as compared with regular viscosity and packable composites at 2 to 5 %, with an average of 3.5 %. According to Jensen and Chan, polymerisation shrinkage stresses have the potential to initiate failure of the composite-tooth interface, which could cause deformation of the tooth, which in turn might result in post-operative sensitivity and which could even open pre-existing enamel microcracks.⁹

SDR Smart Dentin Replacement (DENTSPLY DeTrey) is marketed as a low stress flowable base material that can be placed in layers of up to 4 mm



Fig. 3a

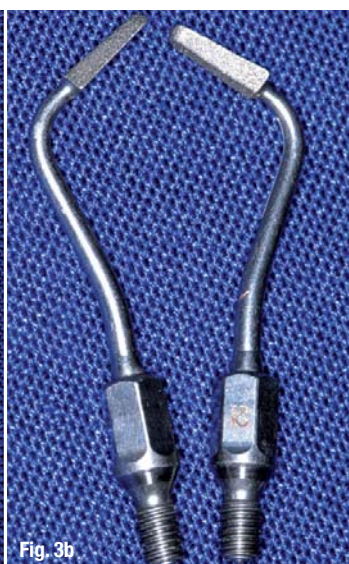

Fig. 3b

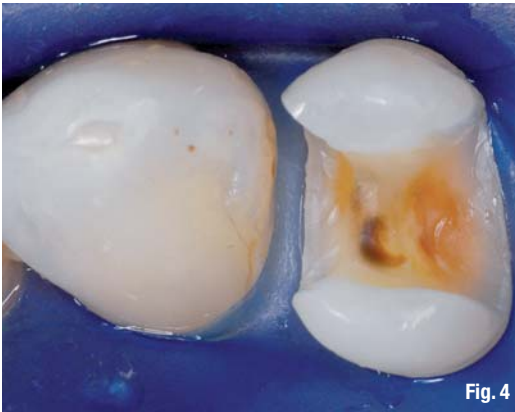


Fig. 4

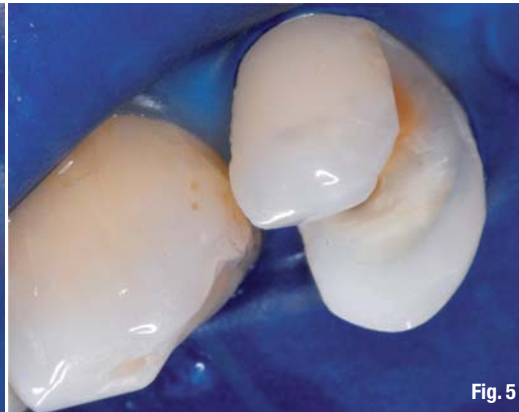

Fig. 5

in thickness and each bulk increment light-cured for only 20 seconds, on condition that at least 2 mm on the occlusal surface is left for regular viscosity composite resin. According to the manufacturer, a polymerisable modulator was chemically embedded into one of the monomers. The viscoelastic behaviour of this monomer and of the overall composition of the flowable composite allows the material to dissipate much more energy than induced during curing by polymerisation of the monomers. This leads to a reduction of remaining polymerisation stress by up to 60 % compared with conventional flowable composite resins.¹⁰ The volumetric shrinkage is 3.6 % but more importantly, the stress generated during the polymerisation is 1.4 MPa, whereas many other flowable composites are above 4 MPa. The material is available in only one universal shade and can be used with any dentine bonding system.

Figures 1 to 19 outline a clinical case report that illustrates the benefits and clinical application of this new innovative flowable base material for direct posterior composite resin restorations.

Base materials are mainly indicated for reducing the volume of filling material¹¹ or for creating adequate geometry for the cavity preparation for inlay/onlay preparation techniques.¹² The shape of the cavity preparation will depend on the extent of the decay or the geometry of the restoration to be replaced. The removal of decay often creates un-

wanted undercuts, which are not compatible with the principles of cavity preparation design for inlays/onlays. In order to preserve as much sound enamel/dentine as possible, the internal tapered design should be obtained by the application of a base material.¹²

Sherrer *et al.*¹³ demonstrated that the resistance to fracture for full ceramic crowns is significantly influenced by the elasticity of the core material and luting cement. Because of the favourable properties of the SDR material, it might be the ideal material to block out undercuts in order to preserve additional enamel for adhesion and to improve cuspal strength during ceramic inlay cavity preparations.

Figures 20 to 29 demonstrate a clinical case report to illustrate the clinical application of the SDR flowable base material to allow ideal cavity preparation design for indirect posterior inlay/onlay restorations.

Case I: SDR as base material for posterior composite restoration

Fig. 1 Pre-op view of an isolated upper right maxillary sextant. Examination of the upper right first premolar revealed a defective composite restoration. Note the poor interproximal contact between the premolar and canine, as well as the inadequate contour on the distal aspect of the existing composite restoration.

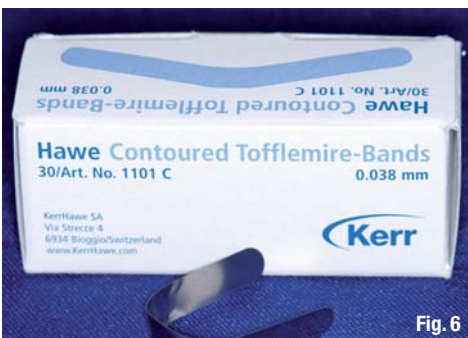

Fig. 6

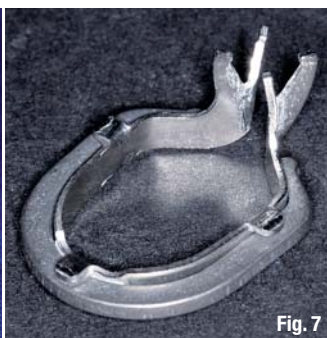


Fig. 7

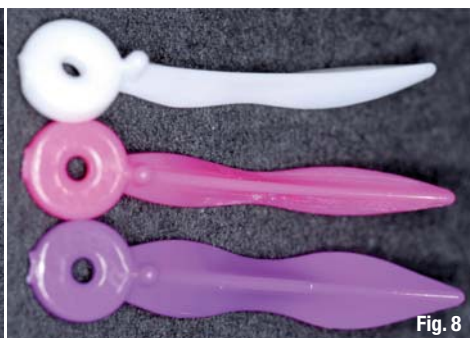

Fig. 8

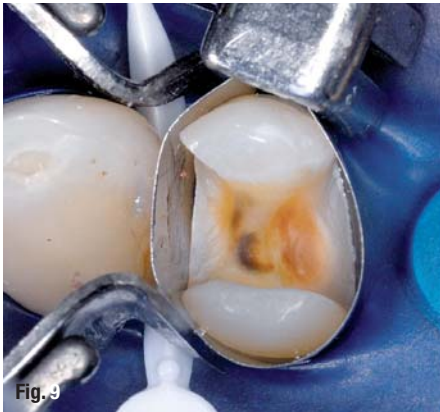

Fig. 9



Fig. 10



Fig. 11

Fig. 2 Initial cavity preparation after removal of the defective composite restoration.

Fig. 3 SONICflex air-driven scaler and SONICflex prep ceram tips (both KaVo) that were used to redefine the margins of the proximal boxes.

Fig. 4 Final cavity preparation after caries removal and preparation of the enamel margins of the proximal surfaces with the SONICflex prep ceram tips to ensure removal of any unsupported enamel.

Fig. 5 Angulated view of final cavity preparation. Note the extended depth of the distal gingival margin from the occlusal surface.

Fig. 6 Hawe Contoured Tofflemire-Bands (Kerr) were used in a Tofflemire holder to ensure correct contour of the definitive restoration. A circular matrix rather than a sectional matrix was selected because of the missing upper first molar.

Fig. 7 V-Ring (Triodent) was utilised to create separation between the canine and premolar in order to ensure a tight interproximal contact point.

Fig. 8 Wave-Wedges (Triodent) of various sizes were utilised to seal the matrix band against the mesial gingival cavity margin to gain a tight

marginal seal, reducing the possibility of contamination to ensure the establishment of an uncompromised bond strength.

Fig. 9 Matrix assemblage: Hawe Contoured Tofflemire-Band in a Tofflemire holder, activated V-Ring and small Wave-Wedge (white). Note the inadequate adaptation of the matrix band to the mesial gingival margin on the buccal aspect of the cavity preparation. The small wedge was replaced with a larger Wave-Wedge (pink; Fig. 12) to achieve improved adaptation of the matrix band to the gingival enamel margin.

Fig. 10 Enamel and dentine surfaces were etched for 15 seconds with 36 % phosphoric acid, rinsed with water and lightly air-dried. Two coats of XP BOND (DENTSPLY) were applied to the etched enamel and dentine surfaces, agitated with a micro-brush for 15 seconds, lightly air-dried and light-cured for 20 seconds with a VALO light-curing unit (ULTRADENT).

Fig. 11 The SDR Compula Tip has a fine tip for precise dispensing of the material with the attached macro-dispensing tip.

Fig. 12 After the bonding protocol, the SDR material was dispensed using slow, steady pressure from the deepest portions of the mesial and

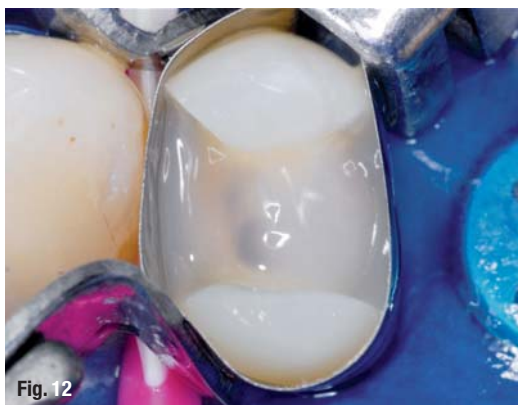

Fig. 12

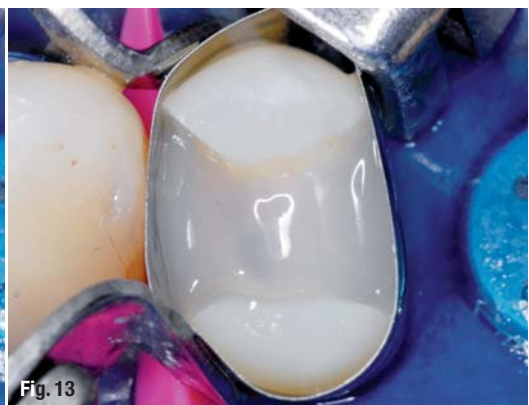

Fig. 13

distal proximal box preparations. After a 4 mm increment had been dispensed, the material was left undisturbed for a few seconds to self-level before it was light-cured for 40 seconds from the occlusal aspect.

Fig. 13 Another 4 mm increment of SDR was dispensed on top of the previous layer up to approximately 3 mm from the cavo-surface margin. The material was again left undisturbed to allow for self-levelling before it was light-cured for 40 seconds.

Fig. 14 The remaining part of the cavity preparation was filled with Tetric N-Ceram (Ivoclar Vivadent), a regular viscosity composite resin.

Fig. 15 The Class II cavity was transformed into a Class I cavity according to the Bichacho technique:¹⁴ mesial and distal marginal ridges were built up with a regular viscosity composite resin, one at a time and light-cured.

Fig. 16 Successive increments of composite were applied in an oblique layering technique, sculpted with a pointed composite instrument and light-cured for 40 seconds. The inclination of the remaining cavo-surface slopes was used as indication to reconstitute the occlusal morphology.



Fig. 14

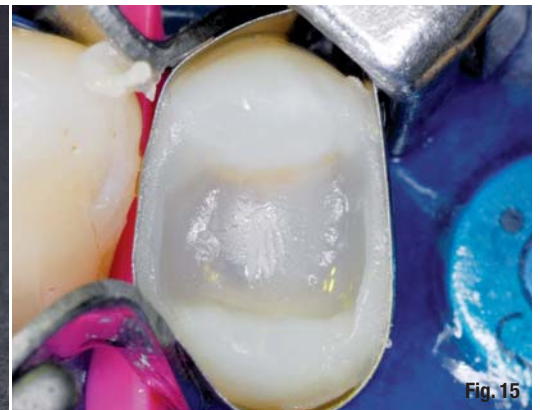

Fig. 15

Fig. 17 Completed restoration after finishing and polishing with an egg-shaped, 30-fluted carbide finishing bur (Endenta) and sequential finishing with OptiDiscs (Kerr).

Fig. 18 Angulated view of the buccal cusp, demonstrating no signs of enamel cracking that could have been caused by polymerisation shrinkage of the bulk fill flowable SDR base material.

Fig. 19 Immediate post-op occlusal view after polishing with diamond polishing paste (ULTRA-DENT Diamond Polish), illustrating the optimal aesthetics, improved interproximal contour and the shape of the composite restoration. Note the optical integration of the composite resin and SDR with the surrounding tooth structure.

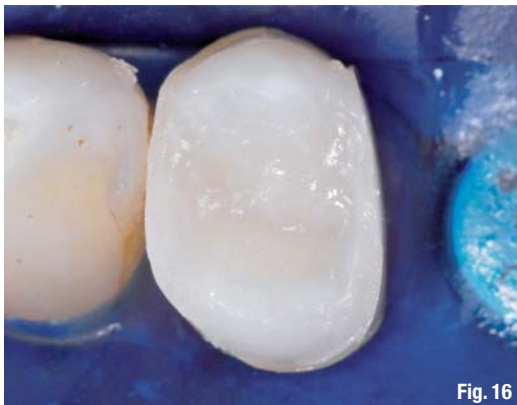

Fig. 16

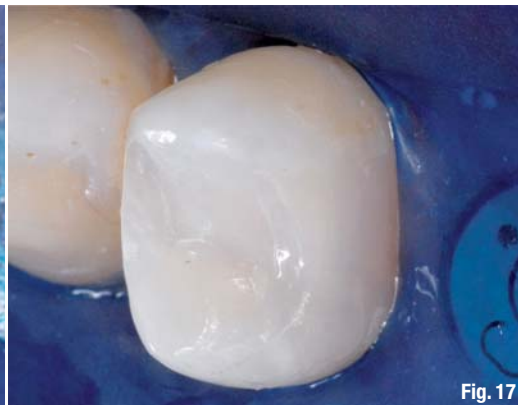

Fig. 17

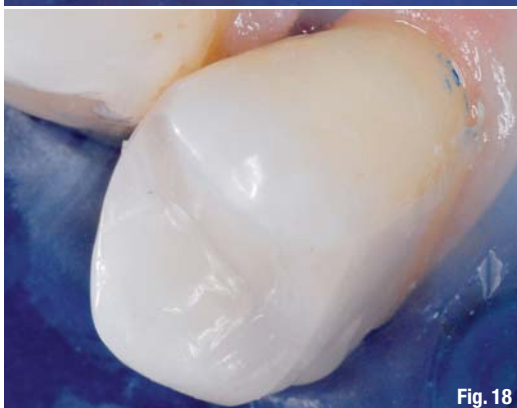

Fig. 18

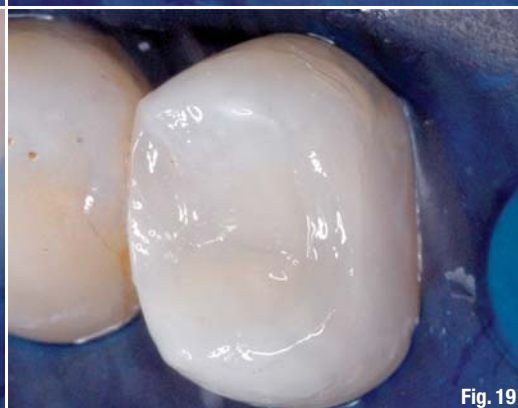

Fig. 19

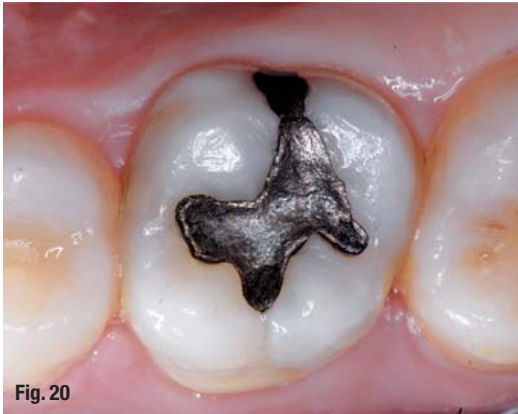

Fig. 20

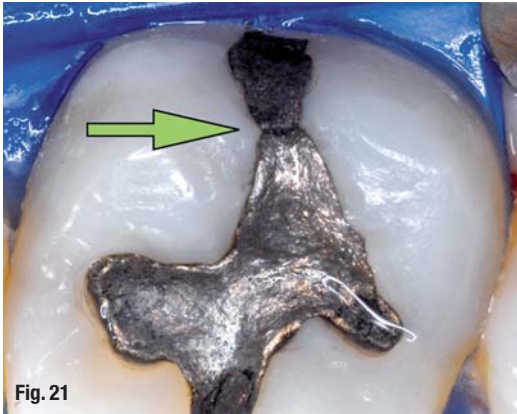


Fig. 21

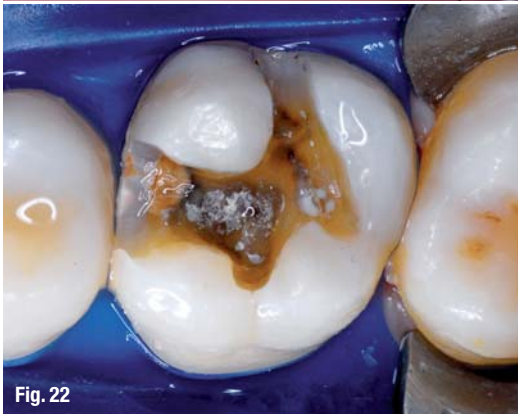

Fig. 22

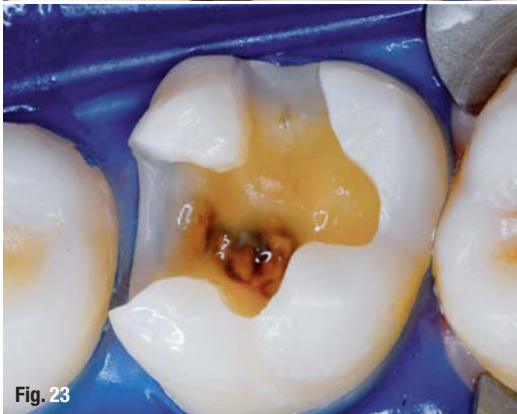

Fig. 23

was utilised to identify the caries-affected tooth structure.

Fig. 23_Final cavity preparation after removal of caries left undercuts on axial wall preparations and an irregular pulpal floor plane.

Fig. 24_After etching with phosphoric acid and application of XP BOND (Fig. 10) according to the manufacturer's instructions, the SDR flowable base material (Fig. 11) was applied to the treated tooth structure. The objective was to block out undercuts on the axial wall preparations and to level the pulpal floor plane. After light-curing, the ideal cavity preparation was achieved using a medium grit diamond bur.

Case II: SDR as base material for posterior ceramic inlay restoration

Fig. 20_Pre-op view of the upper right maxillary sextant. Clinical and radiographic examination of the upper right first molar revealed a previously placed occluso-palatal amalgam restoration and interproximal decay on the mesial aspect of the tooth.

Fig. 21_Pre-op view of the isolated upper right maxillary molar. This magnified view revealed a fracture in the amalgam restoration (arrow) and extensive creep of the restoration margins.

Fig. 22_Cavity outline after removal of the defective amalgam restoration and decay on the mesial marginal ridge. A caries indicator (ULTRADENT)

Fig. 25_After making an impression with Aquasil Soft Putty and Aquasil Light Body the tooth was temporised with Integrity (all DENTSPLY). A porcelain inlay fabricated in the laboratory from IPS e-max Press (Ivoclar Vivadent) was etched with 9.5 % hydrofluoric acid (ULTRADENT Porcelain Etch) for 20 seconds, rinsed with water and air-dried. Silane coupling agent (Calibra, DENTSPLY) was applied and left to dry for one minute before the treated porcelain surface was coated with a thin layer of Prime & Bond NT mixed with Self-Cure Activator (both DENTSPLY).

Fig. 26_At the cementation appointment, the upper right sextant was isolated with a rubber dam and the temporary inlay removed. A single floss ligature was utilised around the upper first molar to guarantee optimal isolation. The cavity preparation line angles were cleaned with OptiClean (Kerr) to ensure removal of any remnants of the temporary

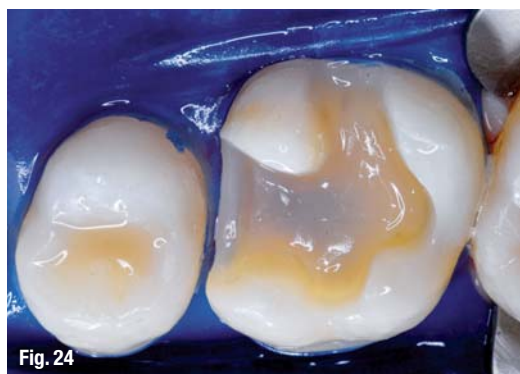

Fig. 24

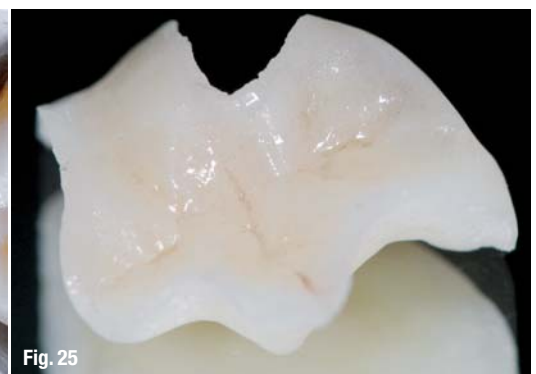
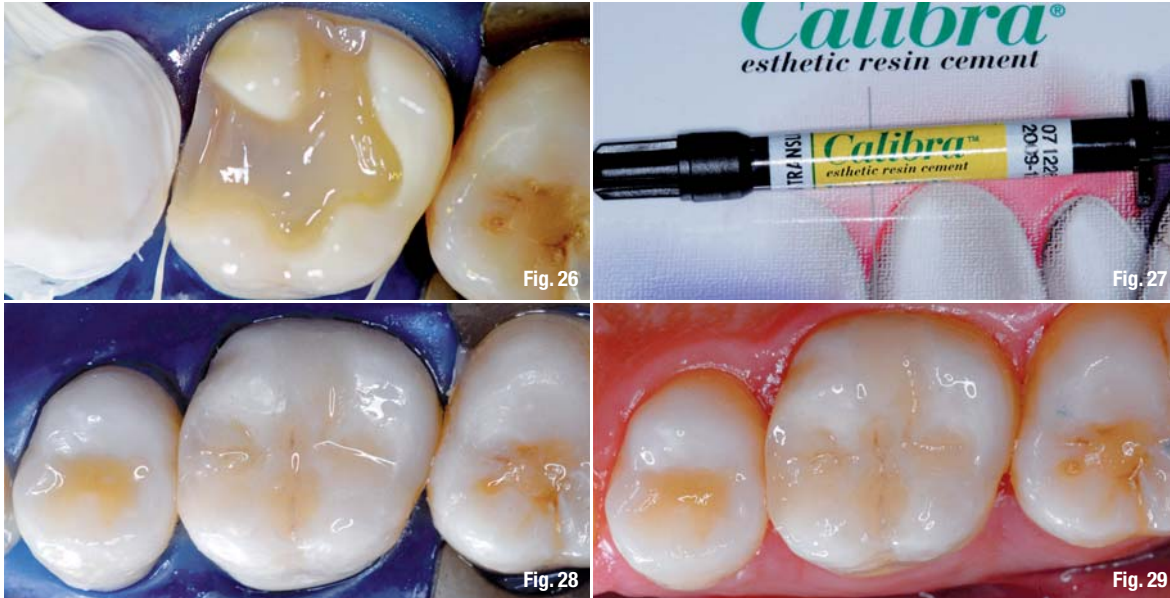
Fig. 25



cement. Plumber's tape was folded around the upper first premolar to act as an isolation medium during cementation.

Fig. 27—The cavity preparation for bonding was done using XP BOND mixed with the Self-Cure Activator according to the manufacturer's instructions. The translucent shade of Calibra Esthetic Resin Cement (DENTSPLY) was used as a luting cement for cementation of the prefabricated inlay.

Fig. 28—Occlusal view after cementation of the porcelain inlay. Final light-curing of the cement was done from the occlusal and palatal direction for 30 seconds, respectively, using the VALO light-curing unit.

Fig. 29—Immediate post-op view after removal of the rubber dam. The final restoration reflects optimal restoration of aesthetics, occlusal anatomy, marginal ridges and interproximal integrity.

Conclusion

Providing the clinician with a flowable base material for posterior direct and indirect restorations that can be placed and cured in bulk must be one of the most exciting technological advancements in dentistry towards technique simplification for what are generally regarded as highly technique-sensitive procedures.

SDR exhibits excellent adaptation to the preparation walls owing to its flowable nature, reducing the possibility of void formation on the margins, which could lead to post-operative sensitivity or aesthetic failure of the restoration. Another unique characteristic of the SDR material is the self-levelling feature, which eliminates the need to mani-

pulate or sculpt the material before curing. This also creates an ideal surface for the addition of any regular viscosity composite resin to complete direct restorations, providing the desired strength, aesthetics and wear resistance for occlusal surfaces.

The reduced polymerisation stress of the SDR base material on normal and compromised cusps after conventional cavity preparation might provide the clinician with an improved and simplified operative technique to offer patients more durable posterior restorations.

Acknowledgement

I would like to acknowledge Mr Greg Flint for fabrication of the ceramic inlay.

Editorial note: Reprinted with permission, courtesy of International Dentistry South Africa ©2010. Int Dent S Afr, 12/5 (2010): 18–27. A complete list of references is available from the publisher.

A video demonstrating the self-levelling properties of SDR is available on www.dentaltribune.com/articles/content/id/6974 or simply scan the QR code with your smartphone.



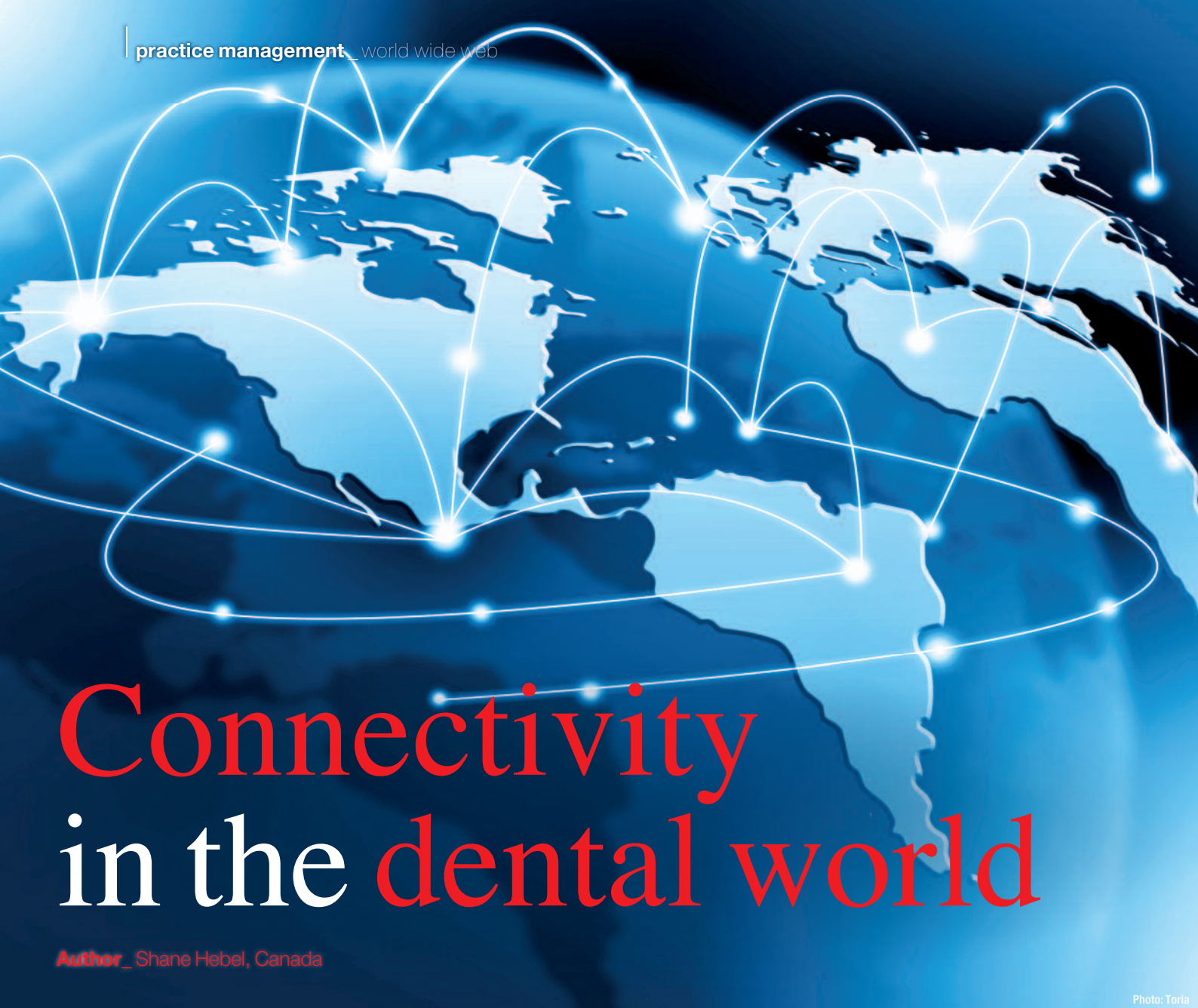about the author

cosmetic
dentistry



Prof Peet van der Vyver

is a part-time lecturer at the University of Pretoria's School of Dentistry and in private practice in Sandton, Gauteng, South Africa.



Connectivity in the dental world

Author | Shane Hebel, Canada

Photo: Toria

_We live in a time in which things are changing exponentially and the way that we go about doing business is drastically evolving. The Internet has become a major player in businesses that never thought that it could apply to them. Instead of battling the Internet with a long stick and keeping it out of the dental industry, it has always been our philosophy to leverage it in new and innovative ways that can be used to the advantage of health-care professionals worldwide.

After a lot of research and brainstorming, we discovered that the real reason that people are online and using products is because of a little thing called connectivity. Many people are online because it allows them to connect and engage with other people who have similar ideas, views or interests. We knew that our mission of serving as a communications and learning hub was lacking, as we were not serving every aspect of our clients' needs in this area of dentistry. This led to a few feverish weeks of programming, writing and networking to bring you the latest suite in the 'Hub'.

_Introducing My Dental Buddies!

MyDentalBuddies is a network of dental bloggers, community members and dentists, who can collaborate to provide information to the dental community at large. This free initiative is a social network that allows users to connect and engage with fellow dentists around the world! This is a HUGE opportunity to learn in a collaborative and innovative way to increase your efficiency and effectiveness in your own personal practice.

In one day, more than 100 million people signed onto Facebook. Twitter generated more than 300 million tweets. Approximately 3 million people 'checked in' to their current location and 35,000 hours of video was uploaded to YouTube. The Internet is an extremely busy place for all of that to happen in a single day!

You may ask why that is relevant to you. Fantastic, you say, more teenagers are uploading pictures of the

party they went to last night. You may be thinking that this massive amount of sharing has no more value than the latest episode of *Jersey Shore*. However, this is where you may benefit from a change in perspective! Although social media started as just that, a place to socialise, it has expanded into a massive enterprise that has since evolved into a realm with numerous applications for anyone in the world.

Let us take a few minutes to really dig into what social media is and why it can benefit YOU. Who cares about how it can benefit Lady Gaga or President Obama. I want to know how it can benefit ME in my life and why it is such a big deal.

Unfortunately, this time around our good friend Wikipedia let us down. Wikipedia defines 'social media' as "the use of web-based and mobile technologies to turn communication into interactive dialogue". Okay, so that tells us the specifics of what social media does. It allows people to connect online. Well, that's cool. E-mail did that. Why is social media so special?

Let us bring it down a peg and see if we can gain some further insight. "If you make customers unhappy in the physical world, they might each tell six friends. If you make customers unhappy on the Internet, they can each tell 6,000 friends," Jeff Bezos, CEO of amazon.com, said. WOAHH, now that provides a lot of insight! Social media allows people to interact with thousands and thousands of people that they would not have access to otherwise. *And they can tell them whatever they want. Uncensored. Fantastic!*

So, social media allows people to say whatever they want online without being censored. Social media is a +1 for free speech. However, we still have not answered the question: *what does that mean for you?* Well, let us go down one step further with some specific examples. If your customers are telling 6,000 people that they are at the dentist and they are lovin' it—that's really good. If they are telling 6,000 people that your office is terrible—that's not so good for you. Being part of the social network and getting involved in communication areas that your patients are in will give you an unprecedented look into your 'online reputation' and give you a chance to really see what your patients are saying.

So now we're spying!?! Fantastic, just what you want to do in the health-care industry. The news industry recently tried that and the resulting News Corp and James Murdoch phone-hacking scandal has resulted in worldwide embarrassment for both the media industry and the governments in which those companies operated. However, there are more



Photo: carlfossell.com

aspects of social media that are very beneficial to you, and not in a creepy kind of way. When people think of social media, their minds immediately jump to huge websites like Facebook and Twitter. While these websites embody the values of social media, they're not the end-all and be-all of the social media landscape.

Social media is about *connecting* and *collaborating* online. Take a look at LinkedIn, tumblr, YouTube and the many other social media websites out there today. These are social media tools. These are social networks. These are YOUR networks. They are places where you can come to connect with fellow people, to collaborate and to LEARN. That is the most important part of all of this! Social media provides an extremely effective medium for active learning, participation and collaboration.

Social media is one major player on the Internet, but it is not the only way that the Internet is changing the dental industry. The Internet has a vast array of resources that are making our world faster paced, more dynamic and more thought-provoking. It is also changing the way that we compete and how we do business. The health-care industry has long been a profession in which competition is not considered

a large factor. Many individuals stayed with a health-care professional for their entire lives and that was the end of it. Once again, the Internet has played a part in upsetting the status quo and changing the way that people view healthcare. Websites like WebMD.com and the online directories of health-care professionals in different areas have opened up the possibility of competition where one did not exist before. Dentists and other health-care professionals are starting to have to change the way that they do things in order to compete in this new marketplace.

This is one area where dentists are currently lacking. It is so easy to fall into a set routine and not think about new or different ways to do things. I mean, why bother? Your practice is making money. Why do you need to be innovative?

Emily Ford, *The Sunday Times*, recently wrote an article on that very topic. Innovation is a huge new part of the dynamic connected world. People are constantly collaborating to come up with more and more innovative solutions to problems and it is important to keep up with this changing environ-



One of the most important things that dentists do in their practice is selling. Now, this is not the way things have been done in the past. Many dentists still operate under the belief that patients come to them for health care, not to be sold to. However, let's look at some of a dentist's vocabulary in sales terms and see what happens:

- _diagnosis:* which product will work best for the patient
- _case options:* pitching
- _case acceptance:* making the sale
- _treatment:* delivery of product.

Are you still as convinced that sales do not exist in the dental industry? The Internet is responsible for a huge number of changes in the dental industry and as a result health-care professionals are constantly having to be innovative in order to survive in a more competitive and dynamic workplace.

I stumbled across this cool article recently that talks about innovation in the workplace, a fascinating read and very applicable to the dental industry!

Ford suggested a few tips for innovating at work, which have been given a dental twist to make them especially applicable to your practice.

Make innovation a priority

Always look for new ways you can do things, new products you can use and new ways of interacting with your staff and patients. Not only will it make your days new and exciting, it will benefit your practice in the long run too!

Take risks and embrace failure

If you buy a new instrument and it does not work, what did you lose? A little bit of time and money? What would have happened if it worked? You may have saved a ton of time, made the quality of treatment increase and made a patient's ordeal less painful. Do you think that it is worth it? I definitely do! By embracing failure, you can learn new things quickly, learn what works and what does not in your practice, and ultimately help your practice to succeed with the increased knowledge that you will have.

Eyes on the future

Think of it this way: when you know where you're going, you can figure out the fastest and easiest way to get there. By planning ahead, you can spend time thinking of innovative and new ways of doing things that will make your future endeavours that much easier. By knowing where you're going, you can constantly be on the lookout for things that will help you get there, making the whole process faster and more efficient.

Foster creativity at all levels

Encourage your staff to do the same as you! Ask them to be constantly thinking about ways they could change the way that they do things. Would something else work better than what they're currently doing? Could they use a new tool to make their job easier? No one will know the answers to these questions better than them, so have them start thinking about it! Your staff are a huge resource in coming up with creative and innovative ideas in your practice.

Break the rules

Ask a ton of questions! Why do you do something a certain way? Has anyone ever tried doing it another way? We get so entrenched in our beliefs, habits and routines that over time we stop thinking about why we do things and just do them. Bring that back! Question the things you do everyday—ask yourself why you do them and whether there's a better way. Chances are that you'll find a few things that will make your practice a more productive and efficient place!

Collaborate across boundaries

Everyone has insights to share. Your receptionist or assistant may notice things that you do not. Get them involved in the process! Chances are that they have some great ideas of things that you could be doing in your practice that you are not. Using your staff effectively is one of the best things that you could do and by involving them in this process you are giving them ownership of the success of the practice and motivating them to make it better!

Innovating does not have to be a one-man show either. The Internet is connecting us in ways that we could not have even dreamed of in the past and it is important to be involved in every way that you can. Although the Internet provides both a valuable resource and fierce competition for your time and your professional career, it is not the only tool for collaboration and shared learning that is out there today.

Here is a new and interesting thought: why don't you ask your employees for their ideas? Your employees may have a ton of cool and innovative ideas for ways that you could make your practice more efficient and effective. However, they are probably not telling you these ideas! Why not? Well, for starters, you never asked! Many people won't share their opinions about some things (especially business) because they are scared that they will seem like they do not know what they are talking about. No one likes that feeling!! If your employees know that their ideas are welcome you will probably find them flooding in!

What does this all boil down to? It comes down to *connectivity* and *collaboration*. That's it. Those two simple words are what the future of the dental industry (and every other industry) is going to come down to. The ability to collaborate with other like-minded individuals, share ideas, innovate and ultimately create a better working system are what the Internet, social media and connective sites are all about.

This is what we are about at My Dental Buddies. My Dental Buddies is a connective website for you, for dentists, staff and other health-care professionals in the dental industry. We recognise the importance of collaborating socially and innovating together and want to bring that to you. It is a portal, a blank slate that the users of the site can fill with whatever content they feel is important to them. That is the beauty of the uncensored Internet; whatever is most important to the largest number of people is what gets talked about. We strive to leverage the Internet to make your dental practice the best that it can be. Please help us to do the same!_

Editorial note: A complete list of sources is available from the publisher.

_about the author

**cosmetic
dentistry**


Shane Hebel is currently a student studying Finance and Accounting at the Schulich School of Business. He is a sales and marketing executive for My Dental Hub. He is involved in a number of organisations that promote collaboration, connectivity and education, including Impact Entrepreneurship Group, Standard International and, of course, My Dental Buddies.

shane@mydentalhub.com
www.about.me/shane.hebel
www.linkedin.com/in/shanehebel
www.twitter.com/shane_hebel

CLEARFIL ESTHETIC CEMENT

for crowns and bridges

Authors_ Dr Harry Denissen & Thomas Reiter, the Netherlands



_In aesthetic dentistry, the shape and shade of a ceramic crown or bridge are extremely important. The dentist can create the mock-up for the crown/bridge by shaping the patient's teeth or existing restorations using CLEARFIL composite resin. Addition, subtraction and aesthetic shaping can easily be done in the composite resin with diamond burs and discs. The shade of the restoration can be assessed by conventional visual or spectrophotometric means. Then, the ceramic restoration with the desired shape and shade has to be cemented.

dam therefore studied the possibilities of cementing crowns and bridges made of etchable and non-etchable ceramics with the new CLEARFIL ESTHETIC CEMENT (Kuraray). This cement is a dual-cured luting composite resin. The etchable ceramic restoration is treated by applying 5% hydrofluoric acid (HF) gel to the inner surface for obtaining micro-retention. The non-etchable ceramic restoration surface is cleaned with 40% phosphoric acid gel. Both etchable and non-etchable ceramic restorations are conditioned by applying CLEARFIL CERAMIC PRIMER, a silane surface treatment agent based on the adhesive monomers MDP and MPS. Try-in pastes with five different shades are available to determine the matching cement shade to be used: Universal, Brown, Clear, Opaque Yellow and Opaque White. The preparation surfaces of the teeth are treated with the self-etching CLEARFIL ED PRIMER II Liquids A and B. Thereafter, the two components of the chosen cement are automatically mixed and applied to the inner surface of the restoration being cemented.

The effect of CLEARFIL ESTHETIC CEMENT on the Lab colour coordinates of ceramics used for computer-generated restorations has been studied.¹ The cement must be available in various shades and the cementing procedure with a rubber dam in place should be easy. The Academic Centre for Dentistry Amster-

_CLEARFIL composite resin for the mock-up of the crown

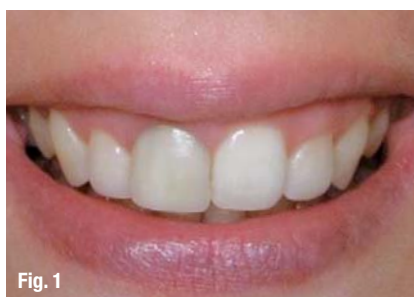

Fig. 1

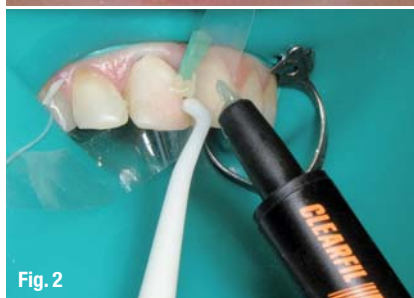

Fig. 2

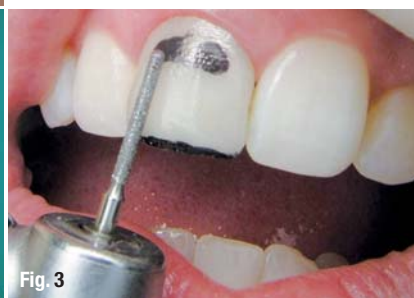

Fig. 3

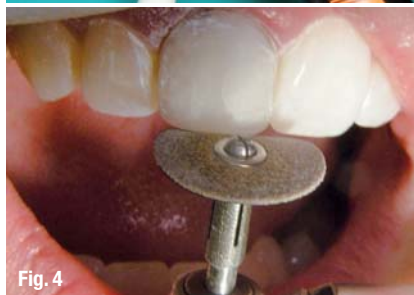

Fig. 4

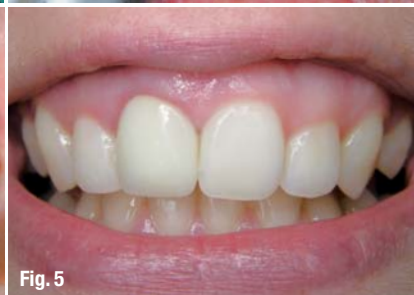

Fig. 5

Fig. 1_The patient desired a correction of shape and shade of the veneer on tooth #11. The veneer did not fit at the margin, was too bulky, too long and the shade was not ideal. Additionally, the lateral incisor was hidden behind the veneer.

Fig. 2_Addition of CLEARFIL composite resin for the mock-up of the crown.

Fig. 3_Subtraction of the composite resin and shaping with diamond bur.

Fig. 4_Contouring of the mock-up with discs.

Fig. 5_The CLEARFIL composite resin mock-up for the crown after polishing. Shape, length and position were improved. The mock-up was planned to be in the mouth for at least one week.

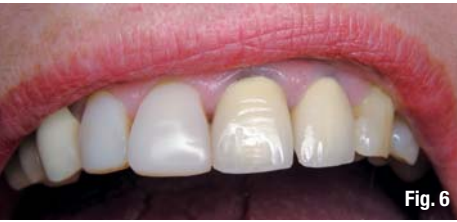

Fig. 6

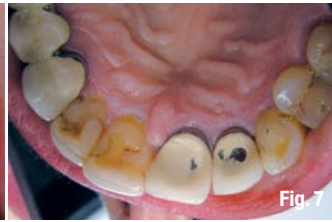

Fig. 7

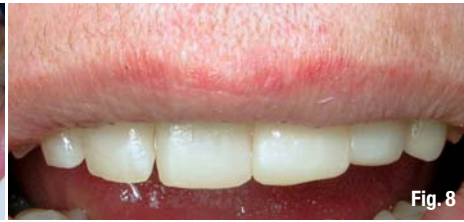

Fig. 8

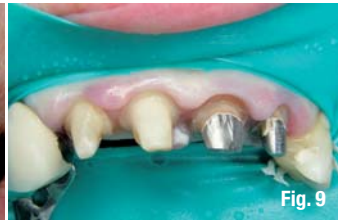

Fig. 9

_CLEARFIL cement for etchable ceramic crowns

Fig. 6_The patient desired aesthetic and functional rehabilitation of the upper anterior teeth.

Fig. 7_Palatal view of the defective crowns (#21 and 22) with cavities along the gingival margins and the two bleached neighbouring teeth (#11 and 12) with large leaking and discoloured fillings.

Fig. 8_The aesthetic and functional mock-up in composite resin for the anterior crowns.

Fig. 9_Tooth preparations with shoulder margins for crowns. Clinical experience has shown that it is almost impossible and therefore unwise to remove well-anchored metal posts and cores. The shade of the cement should compensate for the difference in background.

Fig. 10_The anatomic temporary composite resin crown with the shape of the mock-up was coated with silver powder for the laser-beam scanning procedure.

Fig. 11_The 3-D digital drawing of the anatomic crown after the scanning procedure in the CEREC inLab unit (Sirona).

Fig. 12_A cervical view of the CAD of the anatomic crown.

Fig. 13_Insertion of a block of monochromatic etchable ceramic (IPS e.max CAD, Ivoclar Vivadent) in the spindle of the inLab scan and milling unit.

Fig. 14_The milling procedure (CAM) of the anatomic crown.



Fig. 10

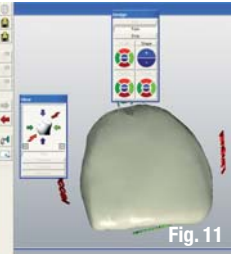


Fig. 11




Fig. 12

Fig. 15a_The CAD/CAM anatomic crown after crystallisation to obtain strength and tooth shade. The CAD/CAM crown had the full incisal edge contour of the mock-up.

Fig. 15b_The same crown after cut-back. The incisal edge was cut back to mimic the lobe shape of the mamelons. The incisal and middle parts of the labial surface were also cut back to serve as a dentine build-up coping for the porcelain veneer.

Fig. 16_Creative handwork was necessary to obtain an optimal aesthetic result by porcelain veneering the cut-back labial/incisal surface.




Fig. 13



Fig. 14

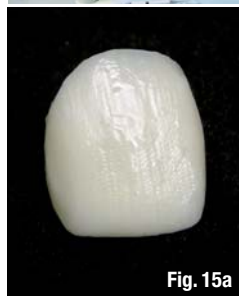

Fig. 15a

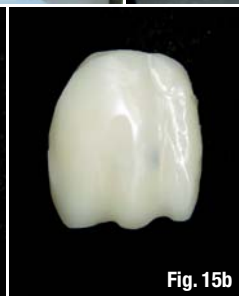


Fig. 15b

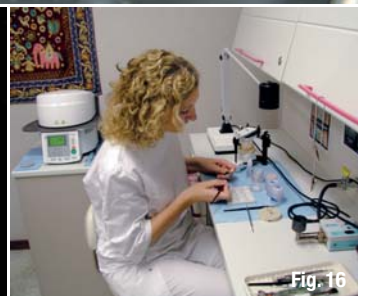

Fig. 16

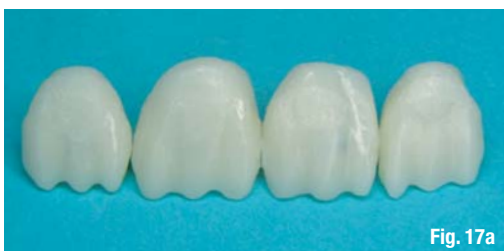

Fig. 17a

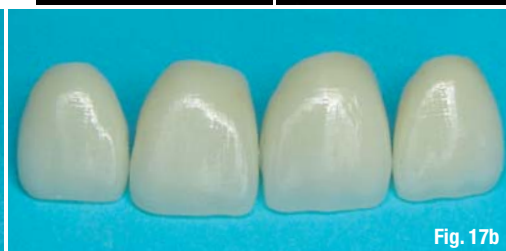

Fig. 17b

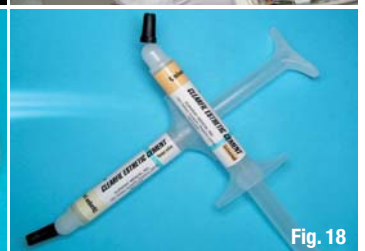

Fig. 18

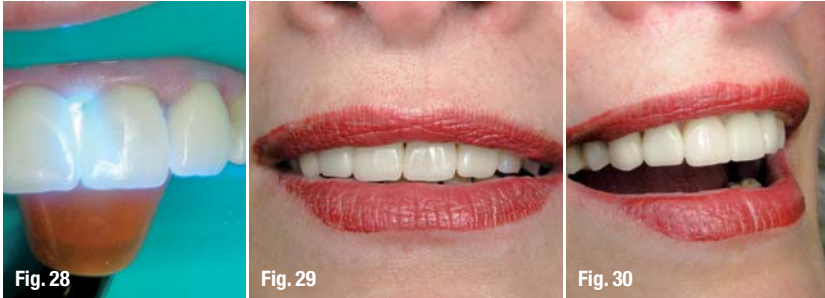
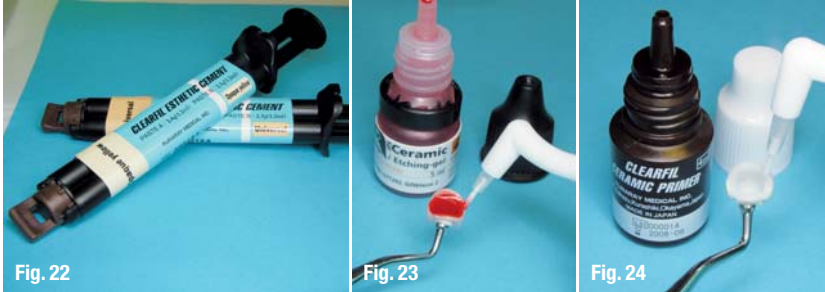
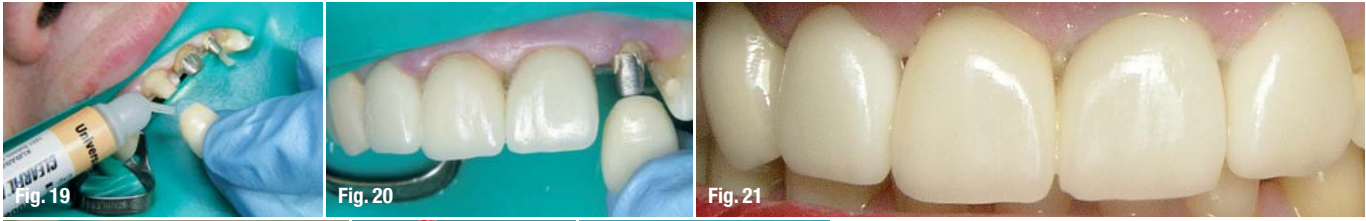Fig. 17a_The cut-back CAD/CAM crowns before labial/incisal porcelain veneering.

Fig. 17b_The CAD/CAM crowns after labial/incisal porcelain veneering and ready for placement.

Fig. 18_The CLEARFIL try-in pastes for obtaining the matching cement shade for the crowns. The crowns are placed with different shade pastes on teeth with and without posts and cores.

Fig. 19_The CLEARFIL try-in paste was applied to the crown to assess the matching cement for the vital teeth.

Fig. 20_Positioning of the crown with Opaque Yellow try-in paste for a tooth with a post and core.

Fig. 21_The crowns after seating with try-in pastes. The Opaque Yellow paste masked the metal cores. The shade corresponded to the crowns on the vital teeth with the universal try-in paste.

Fig. 22_CLEARFIL ESTHETIC CEMENT (Universal and Opaque Yellow) was chosen for cementation of the crowns. The cement is a dual-cured composite resin.

Fig. 23_Before cementation, the crown was ultrasonically cleaned in acetone, rinsed with water and dried. The etchable inner surface of the crown was conditioned with 5% HF gel.

Fig. 24_CLEARFIL CERAMIC PRIMER was applied to the inner surface of the crown.

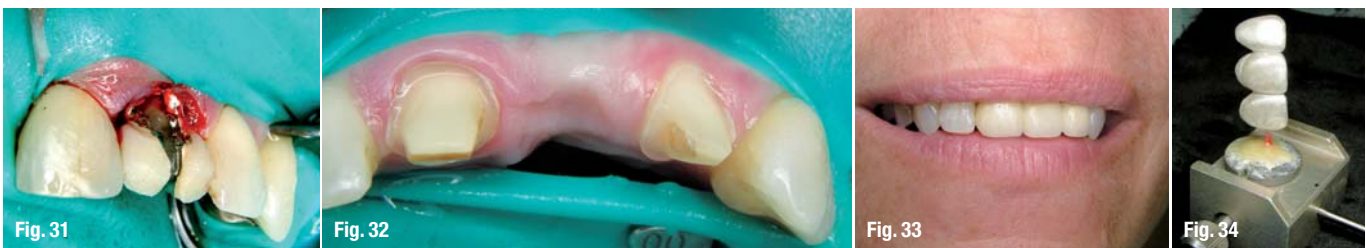Fig. 25_CLEARFIL ALLOY PRIMER for conditioning the metal surface of the cast cores.

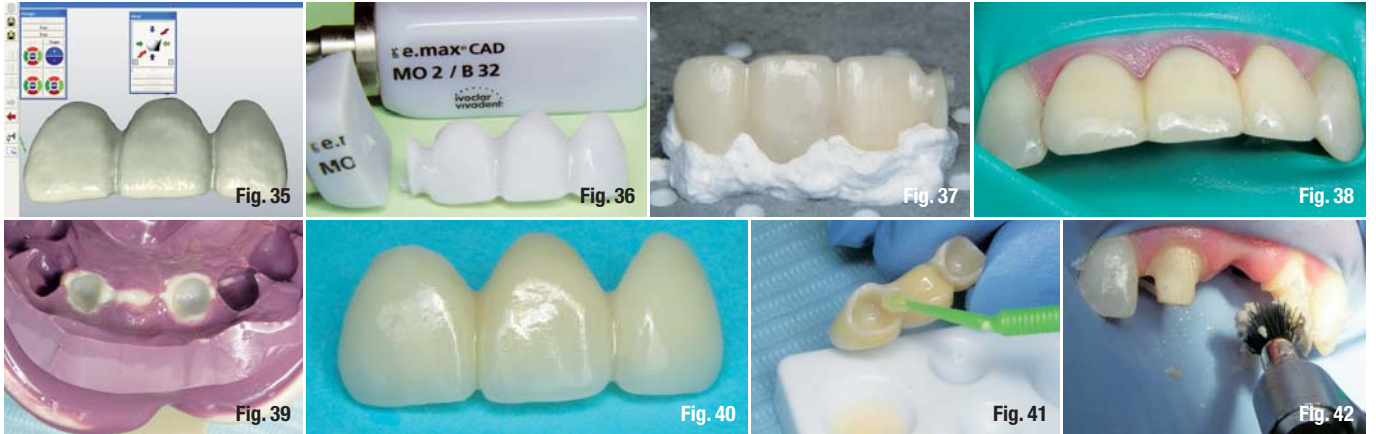Fig. 26_The self-etching CLEARFIL PRIMER (a mixture of ED PRIMER II Liquids A and B) for conditioning the preparation surfaces of the teeth.

Fig. 27_Application of the cement in the crown using the standard mixing tip of the CLEARFIL ESTHETIC CEMENT system.

Fig. 28_After positioning and initial light-curing, the excess cement was removed with a scaler and dental floss. The final light-curing was done in various directions in sessions of 60 seconds.

Figs. 29 & 30_The patient after placement of the CAD/CAM crowns with labial porcelain veneers using CLEARFIL ESTHETIC CEMENT.





_CLEARFIL cement for etchable ceramic bridges

Fig. 31_A patient with a fractured root on #21. Because of multiple ill-fitting and discoloured restorations in the neighbouring teeth #11 and 22, it was decided to place a three-unit bridge.

Fig. 32_Shoulder preparations on the neighbouring teeth for the abutment crowns after healing. CLEARFIL composite resin was used to fill the remaining defects on the tooth surfaces.

Fig. 33_The mock-up for the three-unit bridge in composite resin. Simple corrections can be made to the anatomy of the bridge with regard to shape aesthetics, occlusion and articulation before final approval by the patient and production of the restoration.

Fig. 34_Scan model of the three-unit anatomic temporary bridge with the shape of the mock-up. The bridge was coated with silver powder prior to scanning.

Fig. 35_CAD for the three-unit bridge before milling.

Fig. 36_A block of etchable ceramic (IPS e.max CAD) was used for milling the anatomic bridge in the CEREC inLab. The milled CAD/CAM bridge was still in the soft phase before crystallisation.

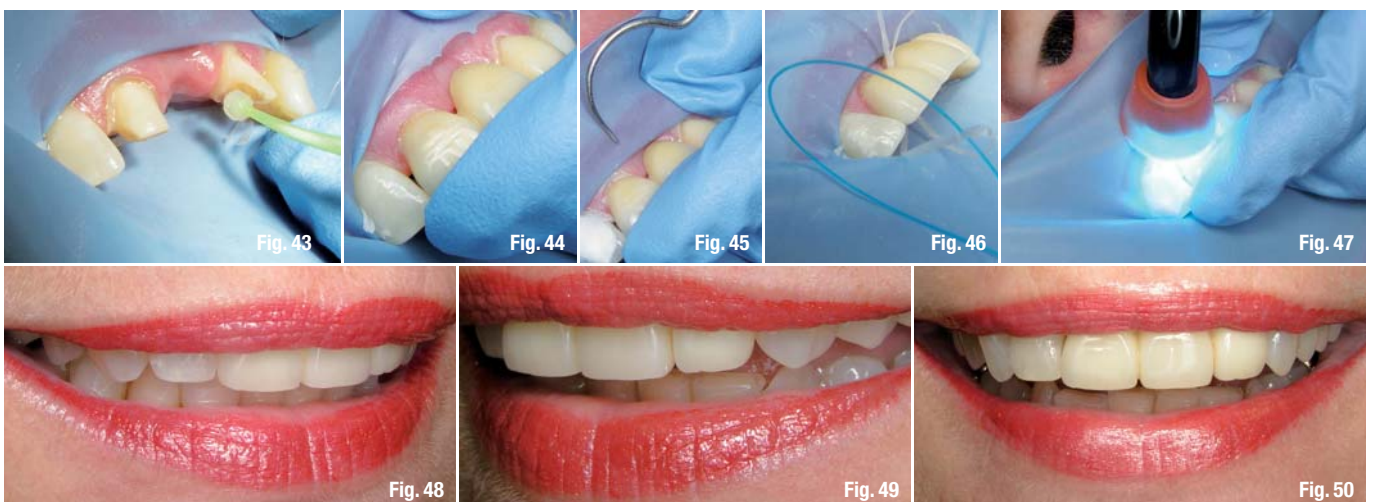
Fig. 37_The anatomic CAD/CAM bridge after crystallisation in the porcelain furnace, which imparted it with strength and tooth colour.

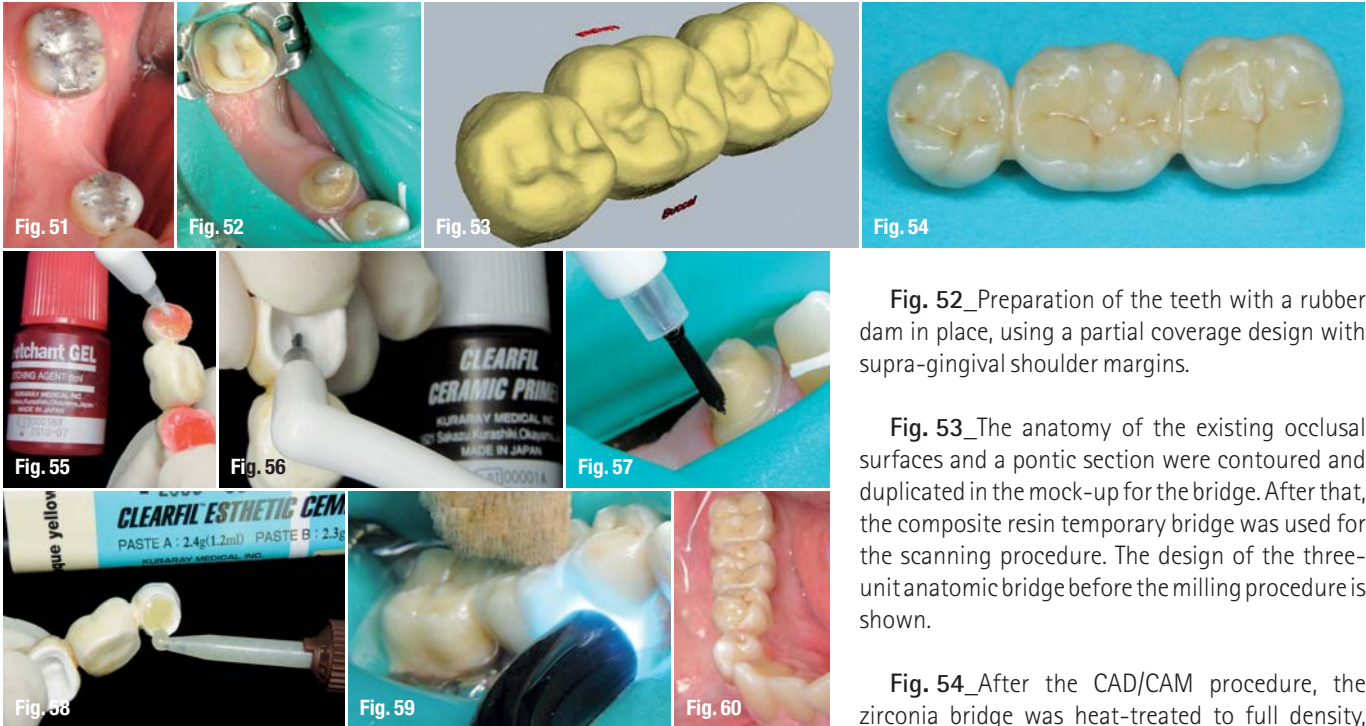
Fig. 38_The CAD/CAM bridge placed in the mouth for the second impression. Note the healed anatomy of the gingival tissues around the bridge components.

Fig. 39_The second impression with the CAD/CAM bridge for the cut-back technique and porcelain veneering of the restoration.

Fig. 40_The three-unit IPS e.max CAD bridge just before placement. The aesthetics of the monochromatic CAD/CAM product were optimised by the manual creative work of the dental technician.

Fig. 41_The inner surfaces of the abutment crowns were etched with 5 % HF gel and treated with CLEARFIL CERAMIC PRIMER. After 60 seconds,





the silane primer was dried with a mild, oil-free airflow.

Fig. 42_The teeth were polished with pumice before insertion of the bridge. A rubber dam with a large opening that isolated the prepared and neighbouring teeth was used.

Fig. 43_Application of the self-etching CLEARFIL ED PRIMER II to the preparation surfaces of the teeth. The primer was dried with compressed air until the surfaces were shiny.

Fig. 44_Immediately after treating the restoration and tooth surfaces, the bridge was inserted with CLEARFIL ESTHETIC CEMENT.

Fig. 45_After initial curing of the cement for a few seconds, the cement was removed with a probe.

Fig. 46_A bridge needle and floss were used to remove the excess cement underneath the pontic.

Fig. 47_Final light-curing of the cement at all sites for 60 seconds.

Figs. 48–50_Patient with the cemented bridge.

_CLEARFIL ESTHETIC CEMENT for non-etchable ceramic crowns and bridges

Fig. 51_Treatment planning for a strong three-unit zirconia bridge with abutment crowns on the second premolar and second molar.

Fig. 52_Preparation of the teeth with a rubber dam in place, using a partial coverage design with supra-gingival shoulder margins.

Fig. 53_The anatomy of the existing occlusal surfaces and a pontic section were contoured and duplicated in the mock-up for the bridge. After that, the composite resin temporary bridge was used for the scanning procedure. The design of the three-unit anatomic bridge before the milling procedure is shown.

Fig. 54_After the CAD/CAM procedure, the zirconia bridge was heat-treated to full density, followed by a minor occlusal cut-back and veneering with zirconia liner, deep dentine, stains and glaze.

Fig. 55_Owing to its microstructure, zirconia is very dense and inert. Therefore, it cannot be HF etched or blasted with aluminium oxide particles. The inner surfaces of the abutment crowns were cleaned with K-etchant gel (40 % phosphoric acid; Kuraray Medical Inc.).

Fig. 56_Silane treatment by applying the CLEARFIL CERAMIC PRIMER to the inner surfaces of the abutment crowns.

Fig. 58_Treatment of the preparation surface of the premolar using the CLEARFIL ED PRIMER II Liquids A and B.

Fig. 58_The mixed pastes of the CLEARFIL ESTHETIC CEMENT system were syringed into the abutment crown.

Fig. 59_Placement of the bridge and light-curing of the cement.

Fig. 60_The veneered anatomic CAD/CAM zirconia bridge after cementation.

_Reference

1. Denissen H, Dozic A, van Waas M, Feilzer A. Effects of 5 manipulative variables on the color of ceramics used for computer-generated restorations. *Quintessence International*, 2007;38: 401–8.

_contact **cosmetic**
dentistry

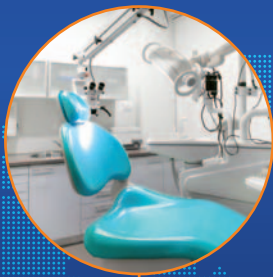Kuraray Europe GmbH
Industriepark Höchst
Building F 821
65926 Frankfurt/Main
Germany

dental@kuraray.eu
www.kuraray-dental.eu (EU)
www.kuraraydental.com (USA)

Post and search for jobs & classifieds worldwide on the largest media platform in dentistry!

Our global online classifieds and career sections are the best solution for filling job vacancies or selling and purchasing equipment for the dental office. Your postings will be available to over 650,000 dental professionals, all readers of the Dental Tribune newspapers, which are published in more than 25 languages worldwide. For more information and free posting opportunities please go to:

www.dental-tribune.com



DENTAL TRIBUNE

— The World's Dental Newspaper —

Professional in-office whitening of non-vital teeth

Author _Dr Ludwig Hermeler, Germany

_A dazzling white smile has been a symbol of beauty, health and vitality for hundreds of years. Discolouration, especially when the front teeth are affected, means a significant disturbance of aesthetics and can decrease a patient's self esteem. SDI's latest in-office tooth-whitening product, Pola Office+, is one of the fastest systems on the market. Its powerful hydrogen-peroxide-based gel and ease of use characteristics along with the clinical procedure for whitening of non-vital teeth and the beautiful results of this minimally invasive technique are described in this article (cases I & II).

discolouration and grey-black staining is known to be caused by the corrosion of silver posts. Possible treatment options are discussed below.

Thermo-catalyst bleaching method

The bleaching gel is placed into the pulp chamber followed by application of a heating source such as a specially designed heating lamp or by using hot instruments directly in the pulp chamber or on the lingual-buccal surface of the tooth. The gel is repeatedly applied and heated. An uncontrolled rise in temperature bears the risk of unwanted side effects such as cervical resorption. Therefore, this method is no longer in practice.

Walking bleach technique

The root filling is removed approximately 2 mm under the dentine-cement line and the bleaching mixture is placed in the pulp chamber, sealed and left *in situ* for several days. A fresh peroxide mixture then replaces the previous mixture in the chamber and the chamber is resealed. This is repeated until the desired result is obtained. This technique is widely accepted and delivers good results.

Modern in-office tooth whitening technique

In case I (Figs. 1 & 2), Pola Office+ was used as in-office bleach. The gel was placed into the chamber and onto the surface of the tooth for the recommended time. The gel was then removed and fresh gel re-applied. This step was repeated several times. Please note: The bleaching gel does not stay in the tooth for several days as is done with the walking bleach technique. The clinical advantages of this technique are discussed in detail below.

_Preparation and lingual entry of the cavity

The following are the contra-indications for internal tooth whitening:

Fig. 1 _Pre-treatment, case I.

Fig. 2 _Post-treatment, case I.

Fig. 3 _Pre-treatment, case II.

Fig. 4 _Drawing of the lingual entry of the cavity.

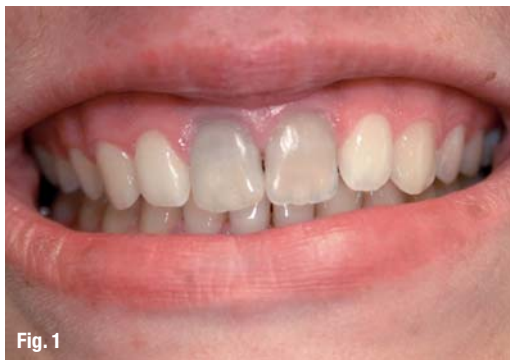

Fig. 1

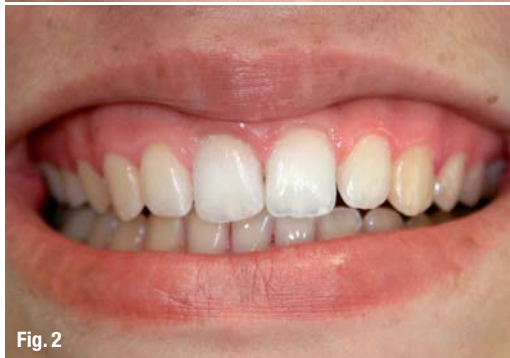

Fig. 2

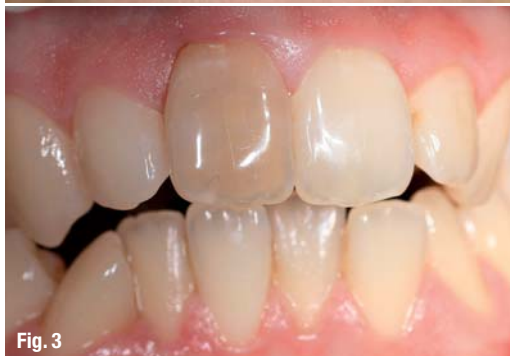

Fig. 3




Fig. 4

- _ apical periodontitis;
- _ apical resorption;
- _ insufficient root fillings; and
- _ insufficient fillings.

Owing to the functioning root canals, the risk of peri-apical lesions can be minimised. An X-ray can show whether old root fillings need to be redone. Amalgam fillings and silver posts need to be removed because they will quickly re-stain the bleached tooth owing to leakage of silver ions.

In case II, the front teeth had been subjected to trauma (Fig. 3). Digital radiographic examination of tooth #11 indicated that internal bleaching could be carried out for this patient. Special attention was paid to the lingual entry of the cavity (Fig. 4). The lingual filling was removed with diamond drills. At the cemento-enamel junction, the entry to the root filling was carefully opened with a rose drill, while cleaning the incisal crown.

Healthy and hard tooth substance should be preserved, even if discoloured, to avoid weakening the tooth unnecessarily. The root filling should be removed approximately 2 to 3 mm under the cemento-enamel junction and it should be sealed with a thick layer of glass-ionomer cement (GIC). It is best to use a dual-curing GIC, mixed by hand and formed to a small ball, so it can be easily placed into the opened canal. The GIC is placed in an apical position to the clinical crown. The required depth of the internal entry can be measured and determined using a PA probe (Fig. 5) in the cavity and at the vestibular tooth surface.

_In-office bleaching

Pola Office+ is the advanced version of the well-known in-office tooth-whitening system, Pola Office, which has been used successfully for several years. Both whitening products contain desensitising agents, such as potassium nitrate, to reduce post-operative sensitivities in vital teeth. The dual-barrel syringe system of Pola Office+ (Fig. 6) always delivers a consistent mixture of freshly activated gel that can be easily applied with a fine applicator tip, even in hard-to-reach areas (Fig. 7). Excess gel is removed with a cotton pellet. A thin layer of gel should be applied on the vestibular surface of the

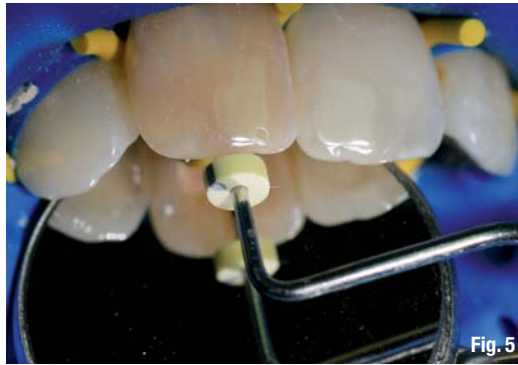

Fig. 5

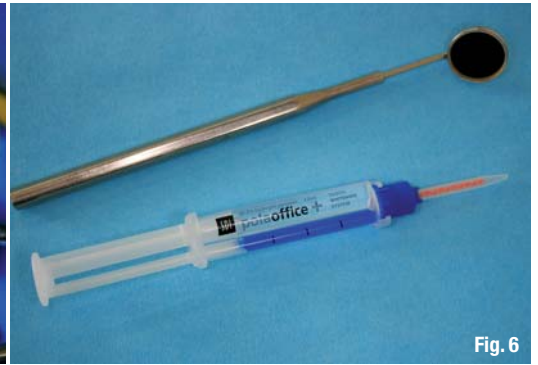

Fig. 6

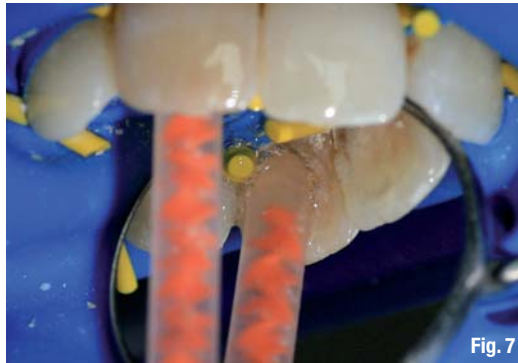

Fig. 7

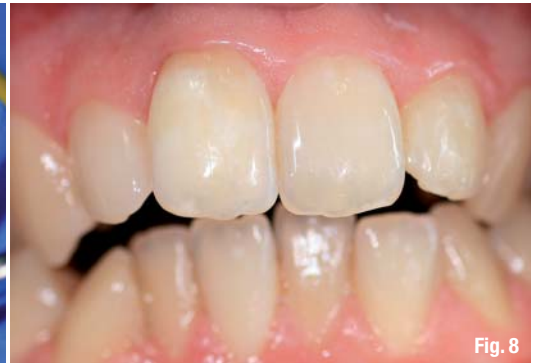

Fig. 8

tooth. For cases I and II, the gel was left on the tooth for eight minutes and then removed using a surgical aspirator tip. There is no need to use a halogen lamp because the material is not heat activated.

The application steps can be repeated up to three times, so that the material is on the tooth for a maximum of four times for 8 minutes (32 minutes in total) in one session. The active ingredient of Pola Office+ is 37.5% hydrogen peroxide and the gel rapidly releases peroxide ions upon contact with the tooth, enabling a shorter contact time compared with its competitors (Fig. 8).

Both cases were treated in just one session. After the whitening treatment, calcium-hydroxide cement was left in the cavity for several days. The tooth was restored with Ice nano-hybrid composite (SDI) after two weeks, using Bleach and A2 opaque shades.

_Result

With SDI's new in-office system, Pola Office+, patients can have whiter and brighter teeth in less than one hour. The easy-to-handle, dual barrel and auto-mixing syringe system is economical and optimises the workflow of the practice. In addition, the desensitising agents and neutral pH make Pola Office+ the ideal tooth-whitening material for vital and non-vital teeth. Tooth whitening using minimally invasive techniques is enjoyable for the clinician and allows the patients to smile with confidence.

Fig. 5_Checking the depth of the cavity with a PA probe.

Fig. 6_Pola Office+.

Fig. 7_Application of gel using an auto-mixing tip.

Fig. 8_Post-treatment, case II.

_contact **cosmetic**
dentistry

SDI Limited
3-13 Brunsdon Street
Bayswater, Victoria, 3153
Australia

info@sdi.com.au
www.sdi.com.au

Anterior tooth restoration— An exciting experience

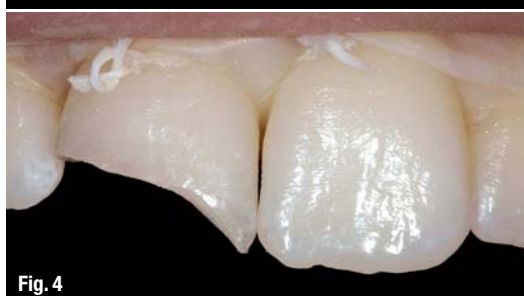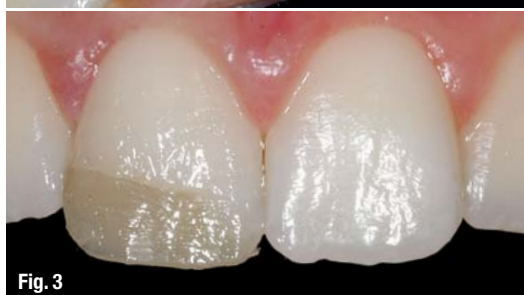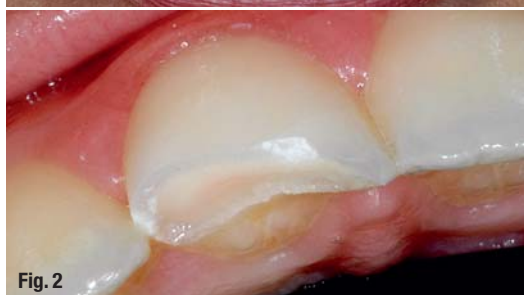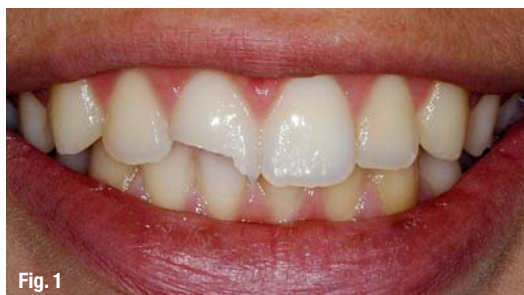Author | Dr David Hacmoun, France

Fig. 1 Pre-op view, showing fractured central incisor.

Fig. 2 Considerable loss of dental enamel; fracture line near the pulp.

Fig. 3 Mock-up made of composite resin (A4) for the palatal silicone matrix.

Fig. 4 Preparation of a feather edge under rubber dam isolation.



A very close inspection of dental enamel reveals its intricate fabric. Reproducing these fine structures and shade nuances seems a daunting task. Owing to the research and development efforts of dental composite manufacturers over the past few years, materials are now available that greatly facilitate the placement of restorations. Nevertheless, the appearance of composite resin restorations is often marred by a greyish shimmer. The following clinical case shows a way to avoid this problem and realise the natural-looking results envisioned by the patient.

An 11-year-old male patient presented to our surgery with a fractured central incisor (Fig. 1). The clinical examination revealed that the tooth was sensitive to temperature and percussion. A fracture close to the pulp was diagnosed (Fig. 2). Clinical evidence of a periodontal trauma was not found. I recommended that the tooth be reconstructed by layering composite resin using a minimally invasive and conservative restorative technique.

Shade selection

I determined the shade in daylight at the beginning of the treatment before the teeth were dried. I used the shade guide of the composite resin, which I subsequently used during the restorative procedure (Tetric EvoCeram, Ivoclar Vivadent). In order to check the selected tooth colour, I applied a composite layer to a tooth

and polymerised it. For the cervical area, I chose dentine shade A2 and for the incisal area, enamel A1.

The mock-up

The treatment area was locally anaesthetised and the tooth was reconstructed free-handedly using a composite resin (deviating from the tooth colour), without preparation or the application of an adhesive. I decided to use an easily recognisable shade, in this case A4 (Fig. 3). After polymerisation, the shape and exact position of the margin and the occlusion were refined. Finally, a silicone matrix of the palatal surface and the margin was fabricated with a putty impression material. This matrix would facilitate the subsequent layering procedure. After the fabrication of the silicone matrix, the provisional restoration (mock-up) was removed. Later, a composite resin in the desired tooth colour would be placed.

The cementation protocol

When the adhesive is applied to the restoration, it is important to ensure that the tooth surface is not too wet. The placement of a rubber dam with ligatures is standard procedure. The rubber dam provides an unobstructed view of the treatment field and increases the safety and comfort of the practitioner and the patient.

The tooth substance was prepared with a feather edge in the labial enamel. This preparation design ensures tight sealing and forms the basis for an unobtrusive transition between the natural tooth structure and the composite resin (Fig. 4). The enamel and dentine were cleaned with a 0.2% mixture of pumice and pure chlorhexidine (PAROEX, GUM). Next, Tetric CS Desensitizer (Ivoclar Vivadent) was applied.

Owing to the wide enamel edge, the Total Etch technique (Ivoclar Vivadent) was used in the present case. That is, the tooth was etched with phosphoric acid before the adhesive was applied. Therefore, the enamel was etched for 30 seconds and the dentine

for 15 seconds with Total Etch. This etching gel contains 37% phosphoric acid. The surfaces were rinsed for 20 seconds and then carefully dried according to the wet-bonding principle (adhesion to moist surfaces). As a result, the enamel was dry, while the dentine remained somewhat moist. This drying step requires utmost care when this type of adhesive is used. If the moisture content within the dentine tubules is too high or if the collagen fibres collapse owing to excessive drying, the penetration of the adhesive, and therefore the bond strength, will be reduced.

The single-component adhesive Excite (Ivoclar Vivadent) was applied to the enamel and dentine and allowed to react for ten seconds. An indirect stream of air was used to evaporate the solvent contained in the adhesive. In the process, the air spray was applied to a mirror in the mouth, which was held at an angle to the prepared tooth surface. As soon as the surface was lustrous, the adhesive was further polymerised for ten seconds (low power mode of the bluephase G2 LED curing light, Ivoclar Vivadent).

Layering of the composite resin

First, the composite resin was applied to the palatal areas. The enamel material A1 was applied in the silicone matrix. In order to avoid the formation of bubbles, the composite resin was distributed very carefully. The matrix was placed in the patient's mouth and positioned on the palatal surface with light pressure. The composite resin was polymerised for 15 seconds using the soft start mode (Fig. 5). Small lobes of dentine material (A2) were subsequently applied. The position of these lobes was individually determined. The aesthetic results were based on the contralateral teeth, which served as a comparison. In this case, the mamelons were clearly separated. They ended below the incisal edge (Fig. 6). By observing the existing anatomical features, a natural-looking and aesthetic outcome was achieved.

The composite resin was applied in small amounts, which were periodically cured with the bluephase curing light in the soft start mode. The dentine material was then applied and light-cured. Next, the incisal edge of the tooth, that is, the outermost part of the restoration, was reconstructed. Small amounts of the translucent incisal material T were placed between the dentine mamelons. A probe came in useful in these narrow areas. Finally, the entire labial surface was coated with Tetric EvoCeram Bleach 1, ensuring that both the dentine lobes and the incisal edge were completely covered. The Bleach shade made the tooth appear

lighter. The dentine material imparted the composite resin restoration with a tooth-like appearance. The Bleach shade was responsible for the tooth's natural-looking brightness.

Surface finishing

The aesthetic outcome is largely based on the successful recreation of the surface texture. The imitation of the shape and surface details is just as important as that of the fine colour nuances. In the treatment of a child's tooth in particular, it is important to take the micro- and macro-anatomical structure into consideration. The surface was finished with finishing diamonds (first red, then yellow). Spray was not used. Work was done using a surgical microscope. The restoration was finally polished with the Astropol system (using water spray; Ivoclar Vivadent). In contrast to polishing discs, these rubber tips do not harm the surface structure.

Conclusion

The fabrication of natural-looking, highly aesthetic restorations is a rewarding task with Tetric EvoCeram materials and the increment technique. The Bleach shade on the tooth surface brightens the restoration. This approach is extremely helpful in the restoration of children's teeth. With the help of this adhesive technique, teeth can be restored in a minimally invasive manner (Figs. 7 & 8).

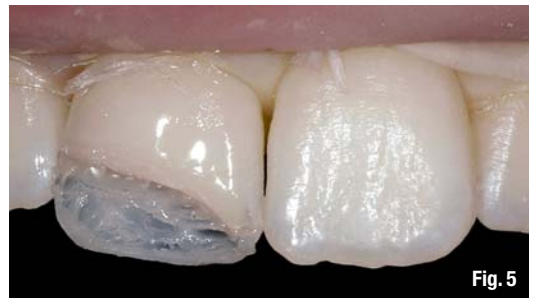

Fig. 5

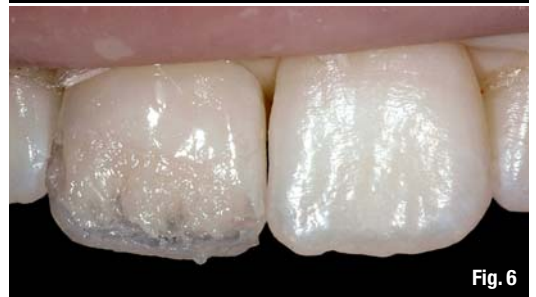

Fig. 6

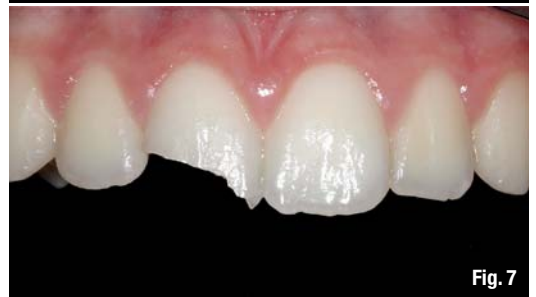

Fig. 7

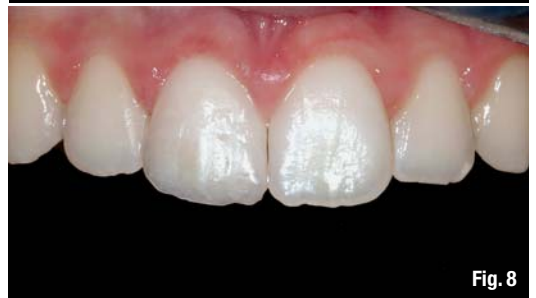

Fig. 8

Fig. 5 Build-up of the palatal surface with enamel material (A1). The precision of the morphology is already impressive at this stage.

Fig. 6 Lobes are created with dentine material (A2). The translucent material is placed between these mamelons.

Fig. 7 A comparison: before ...

Fig. 8 ... and after: the Bleach shade on the surface of the restoration imparts the tooth with the necessary brightness.

contact

cosmetic
dentistry



Dr David Hacmoun

33 bv Albert 1er
06600 Antibes
France

doc.hacmoun@hotmail.fr

Simplifying direct composite resin restorations in the aesthetic zone

Author_ Dr Ian E. Shuman, USA

_The ability to create highly aesthetic direct composite resin restorations in a simplified manner has long been a goal for dentists. In the past, difficulties with direct composite resins have included shade matching, handling properties, premature setting under operatory lights, and overall ease of use. This article will describe a composite resin system (Amaris, VOCO) that has demonstrated desirable properties for use in both posterior teeth and especially in the aesthetic zone. Thereafter, a case report demonstrating the use of the material will be presented.

_Two-step shade matching concept

Tooth colour, with its varying shades and translucencies, is difficult to achieve between composite

systems; for example, resins based on the porcelain VITA Classical shade guide (Vident) cannot achieve the desired results with consistency. Most composite systems work on the principle of matching composite to the basic shade ranges found in dentine and enamel. In order to create the polychromatic effect found in natural enamel and dentine, several things must happen.

To mimic the optical properties of hydroxyapatite enamel rods, composite resin must create the illusion of the way light is reflected in the natural tooth. Dentine is by nature opaque, providing teeth with their basic shades of yellow, brown, gray and blue. Enamel is by nature a white-translucent shade, providing teeth with their natural value.

Fig. 1_Pre-op situation: maxillary anterior teeth were discoloured, fractured and sensitive.

Fig. 2_Stained enamel was removed and a scalloped margin prepared.

Fig. 3_Margins were created at the interproximal surfaces of both teeth.

Fig. 4_A dual-cure, self-etching bonding agent (Futurabond DC) was applied.

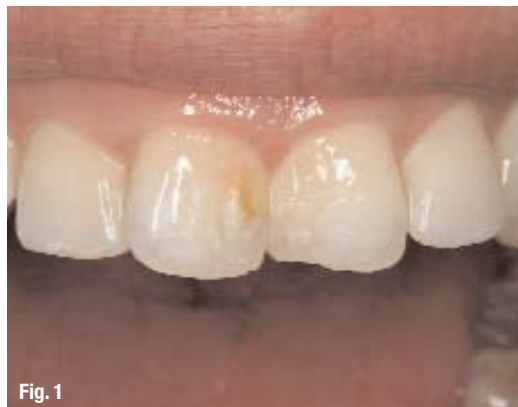

Fig. 1

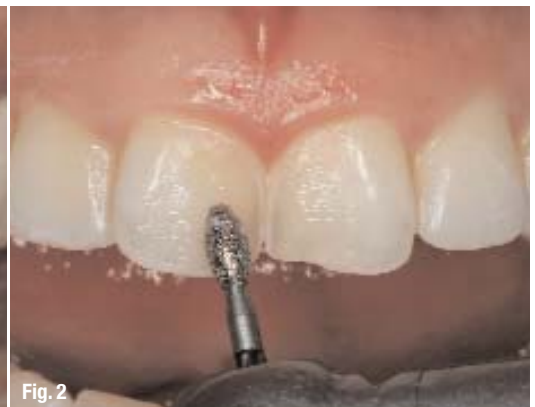

Fig. 2

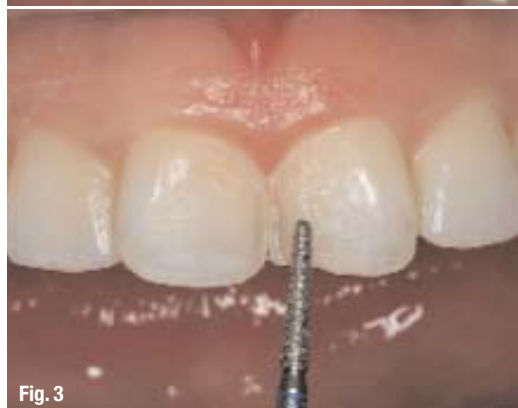

Fig. 3

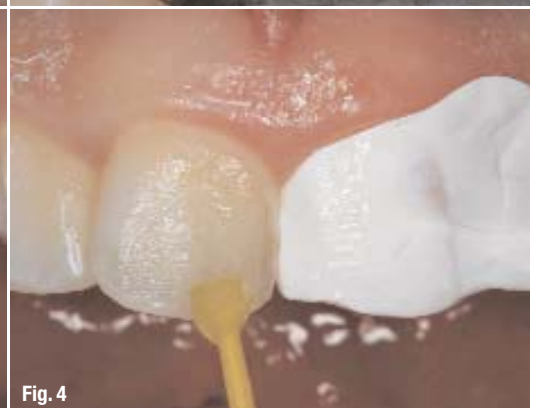

Fig. 4

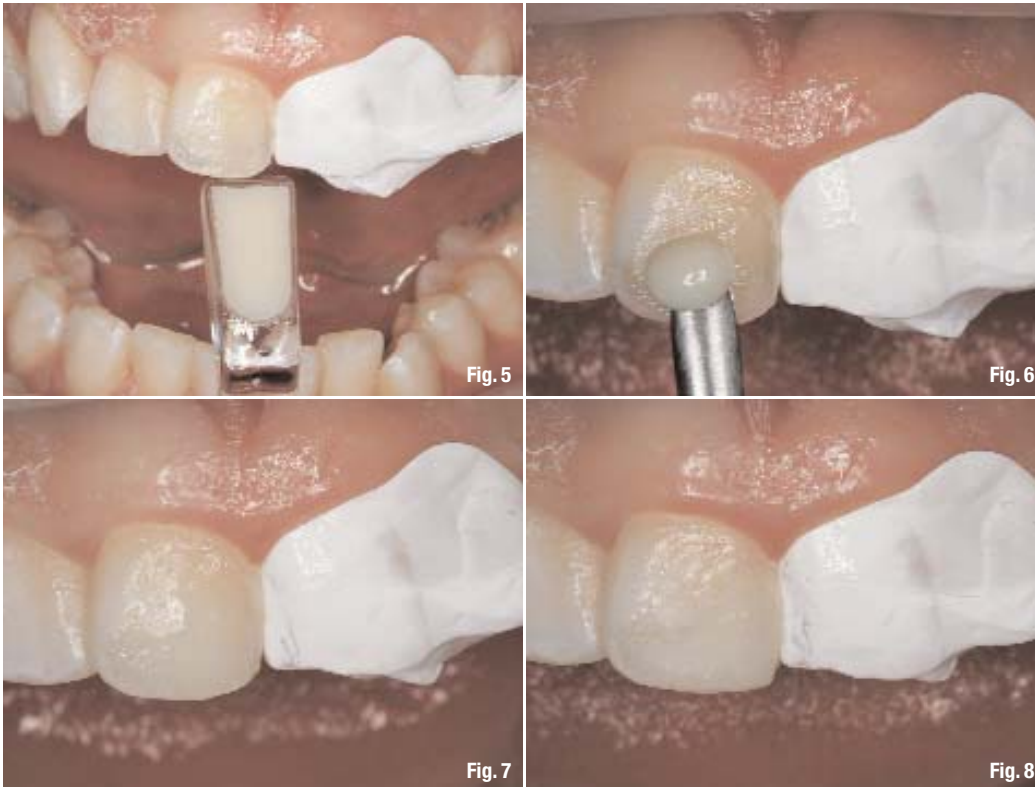


Fig. 5 A custom shade tab was used to determine the correct opaque dentine colour.

Fig. 6 O1 composite (Amaris) was tried against the prepared tooth.

Fig. 7 An initial layer of O1 was applied.

Fig. 8 A second O1 increment was then placed.

Using this basic principle, aesthetic restoration accomplished when using Amaris is simplified with an easy-to-understand, two-step shade concept with five opaque dentine and three translucent enamel shades.

Selecting the correct shade is simplified by using the custom shade guide, which is made from original light-cured composite material. Colour matching is greatly simplified because one does not have to employ a complicated and time-consuming multilayer shade technique. With minimal effort, colour matching is developed along the way. The colour of dentine shines through enamel and this system offers a shade system that follows this natural principle, simplifying direct aesthetic composite restorations into two simple steps. The material demonstrates an excellent chameleon-like effect with non-opaque shades and outstanding shade matching on the tooth. This excellent adaptation makes complex (shade) layering techniques unnecessary, and delivers an aesthetic result with fewer shades.

Application possibilities

Amaris is a hybrid composite suitable for all classes of restorations. It is stable in posterior teeth and highly aesthetic for anterior teeth. A flowable version (Amaris Flow) supplements the restorative possibilities. With excellent wettability properties, the material flows directly out of the syringe into extremely small cavities. It is available in two

special universal shades: HT (High Translucent) and HO (High Opaque).

The HT flowable is ideal for highly translucent incisal edges and small enamel or incisal defects, and as a high-gloss finishing layer. HO flowable is perfect for thinly masking discolouration, covering amalgam stains, mimicking the cervical areas in older teeth, blending with adjacent PFM crowns, and as a restorative base following endodontic treatment. Optimal matching of Amaris Flow to Amaris paste (in shade and translucency) allows combined application with the composite-bonded-to-flowable technique, without reducing the stability or aesthetics.

Surface hardness and abrasion

The abrasion caused by chewing load is still a central aspect of the durability of restorative dental materials. High abrasion rates in the posterior tooth region lead to edge fractures and loss of the occlusion. Abrasion in the anterior tooth region leads to loss of lustre, which makes the restoration appear dull and unattractive. Thus, it is a fundamental goal of the development of restoratives to optimise hardness and abrasion resistance. The extremely high filler content (80.0 w/w%) provides the Amaris highly aesthetic hybrid composite with an exceptionally hard surface. This ensures a durable restoration owing to its high physical strength and high polish abrasion resistance.

Fig. 9_A custom shade tab was used to determine the correct translucent enamel colour.

Fig. 10_TL composite (Amaris) was tried against the prepared tooth.

Fig. 11_TL composite was then sculpted to shape, completing the restoration.

Fig. 12_The restored maxillary right central incisor next to the unrestored left central incisor.

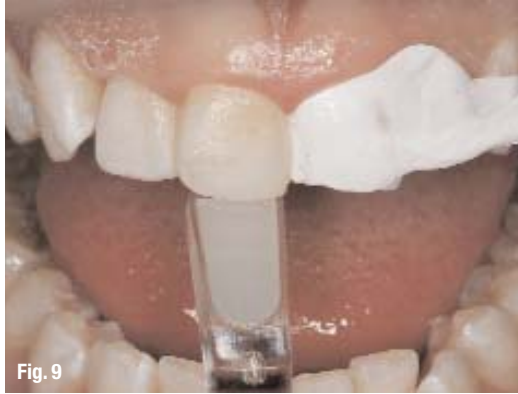

Fig. 9

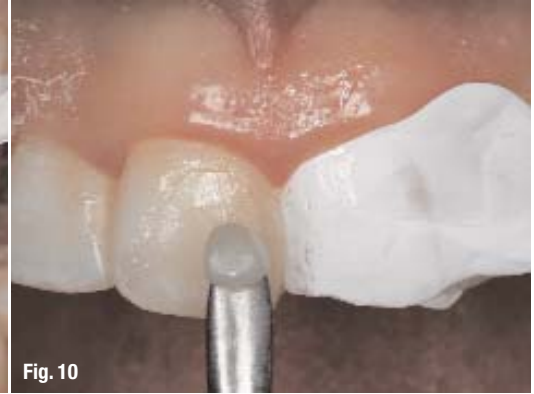

Fig. 10

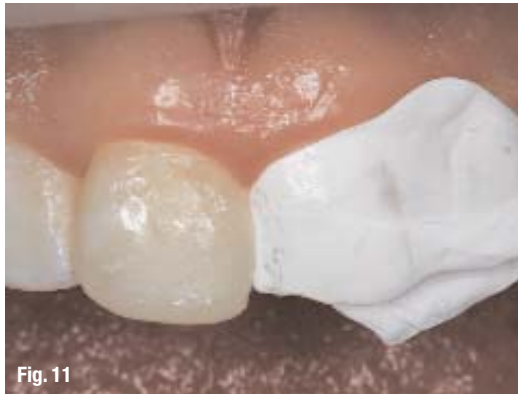

Fig. 11

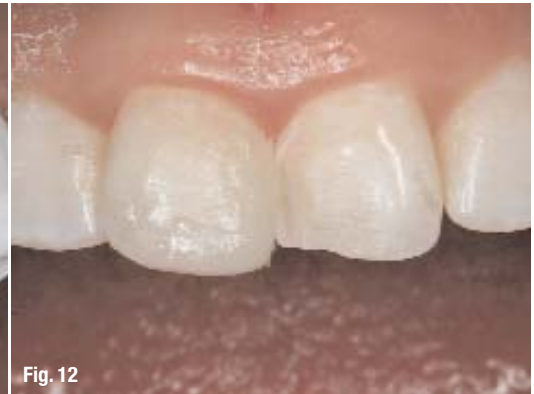

Fig. 12

Many filling materials can be polished to a high gloss simply because they are not particularly hard, but these materials lose their shine within a short amount of time owing to poor abrasion resistance; aesthetics at the price of durability is not a good compromise. In my experience, Amaris composite exhibits excellent polishing characteristics, high gloss and very good gloss retention. In addition, up to eight minutes of handling time in ambient operatory light, an additional bleach opaque shade and two flowable choices cover all clinical situations, helping to make this a versatile material.

The following case report demonstrates a clinical situation for which this composite system was successfully utilised to achieve optimal anterior aesthetics.

_Case report

The patient, a 23-year-old female, presented with the chief complaint of discoloured, fractured and sensitive maxillary anterior central incisors (Fig. 1). A direct composite restoration was selected as the treatment of choice to correct the aesthetic deficiencies, tooth sensitivity and structural flaws with minimal tooth reduction. Following administration of local anaesthesia, minimal tooth preparation was accomplished using a football-shaped diamond bur (SS White) and a standard round-end, tapered chamfer diamond bur (SS White). The stained enamel was removed and a scalloped preparation margin was created at the interproximal of both central incisors (Figs. 2 & 3). Discolouration at the composite-tooth junction (i.e. margin) is an indication of micro-leakage and can be an in-

Fig. 13_A dual-cure bonding agent (Futurabond DC) was applied to the left central incisor.

Fig. 14_O1 dentine replacement was applied.

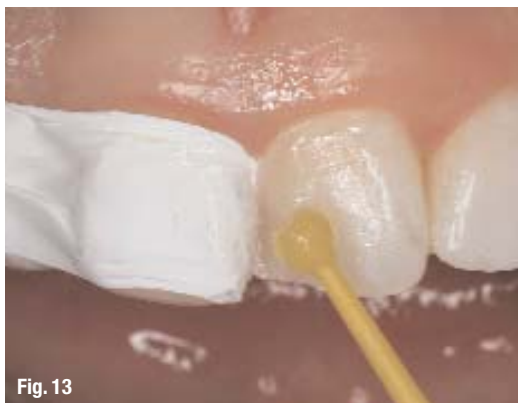

Fig. 13

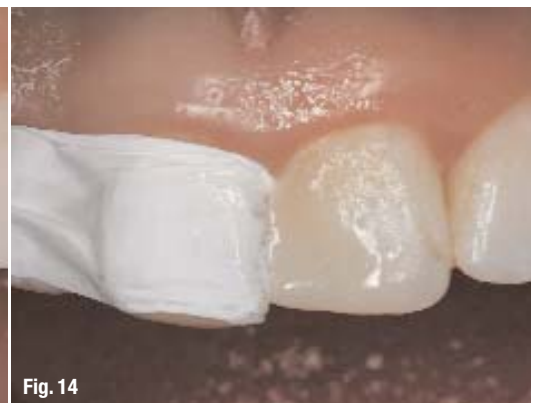

Fig. 14

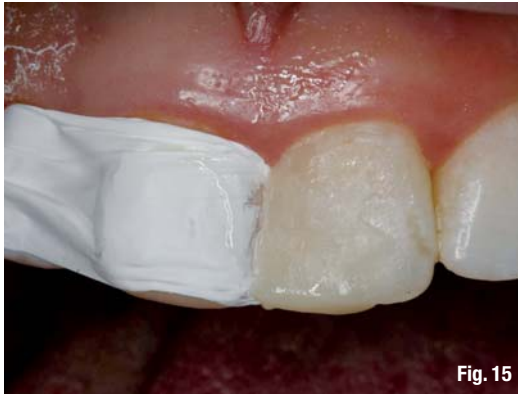

Fig. 15

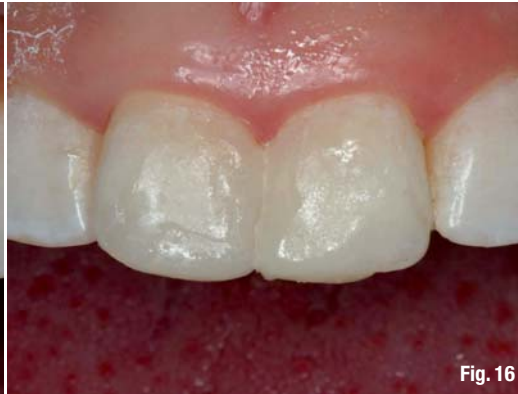

Fig. 16

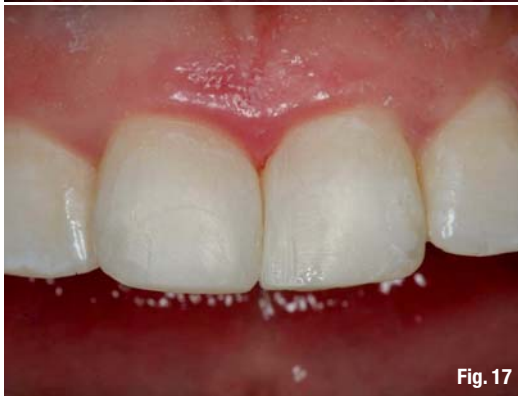

Fig. 17

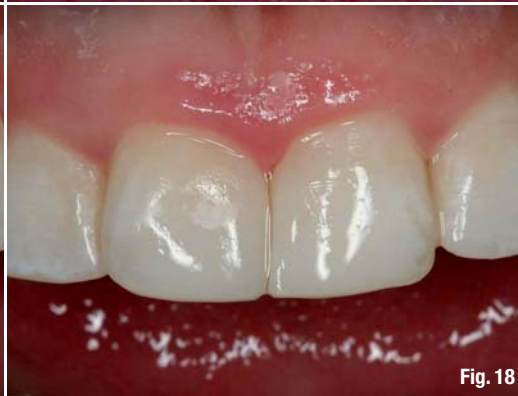

Fig. 18

Fig. 15_A final layer of TL composite was placed.

Fig. 16_The maxillary central incisors restored with unfinished composite.

Fig. 17_The restorations after contouring and shaping, before finishing and polishing.

Fig. 18_The completed case.

indicator of the presence of caries. The frequency of margin discolouration is affected by the adhesive chosen, the adhesive technique utilised, the composite itself and the finishing technique employed.

The left central incisor was first isolated from the bonding procedure using Teflon tape. The right central incisor was then treated with a dual-cure, nano-reinforced, self-etching adhesive (Futura-bond DC, VOCO; Fig. 4) and light-cured. Next, an opaque-dentine shade button was selected that best matched the tooth. The Opaque (O1; Amaris shade tab, VOCO) was matched to both the prepared tooth and the adjacent unprepared lateral incisor (Fig. 5). The O1 composite was then tried against the prepared tooth (Fig. 6) and sculpted, leaving a 0.5 mm thickness for the final enamel layer (Figs. 7 & 8). This composite was designed so that it would not stick to the instruments, allowing it to be shaped in the cavity with simple movements with almost no pressure.

Next, the Translucent Light (TL) was matched to both the prepared tooth and the adjacent lateral incisor (Fig. 9). Then, the TL composite was tried against the prepared tooth (Fig. 10), and this final enamel layer was sculpted to shape (Figs. 11 & 12). These same steps were then taken for the maxillary left central incisor (Figs. 13–15). Once both maxillary central incisors had been restored (Fig. 16) and the occlusion checked, the restorations were fin-

ished to proper anatomic morphology (Fig. 17) and polished (Fig. 18).

_Conclusion

A technique for placing direct composites that allows a predictable outcome in the aesthetic zone has been demonstrated. In my opinion, the simplicity of shade matching and aesthetics, ease of application, finishing and polishing, and the strength and durability make Amaris an ideal choice as a direct restorative material.

_about the author

cosmetic
dentistry



Dr Ian Shuman runs a general, reconstructive and aesthetic dental practice in Pasadena, Maryland (USA). As an educator and author, he is a pioneer in developing advanced, minimally invasive techniques. His mission is to teach dental professionals current methods for creating beautiful, long-lasting restorations that preserve the maximum amount of tooth structure. He is a Fellow of the Pierre Fauchard Academy and a member of the American Dental Association and the American Academy of Implant Dentistry. He can be contacted at ian@ianshuman.com.

The new PANAVIA POST— Long-lasting and reliable



Kuraray Europe has now developed PANAVIA POST, a glass-fibre post with excellent mechanical durability, which offers the superb properties of PANAVIA F 2.0 and hence provides an ideal solution for especially long-lasting and reliable restorations.

The new PANAVIA POST is made of methacrylate and non-epoxy-based, resin-reinforced glass fibre, characterised by particularly high durability and an optimal elastic modulus. The secret lies in Kuraray's unique monomer and surface treatment technology.

Together the proven PANAVIA F 2.0 and the new PANAVIA POST provide an ideal combination for perfect restorations. The extremely powerful adhesion between the individual components inside and outside the post prevents debonding and root fracture.

For many years, PANAVIA F 2.0 has been regarded as the solution for guaranteed permanent adhesion, especially for high quality and difficult restorations.

The design of the PANAVIA POST—a combined cylindrical-conic form with a rounded undercut at the apex—and its elastic modulus (very similar to dentine) minimise the risk of losing the post or of root fracture. Since the post is metal free, its translucency meets the most sophisticated aesthetic demands of dentists and patients.

Kuraray recently launched PANAVIA POST on European markets. Only the Benelux countries will have to wait a little bit longer—until 1 January 2012—to enjoy the excellent features of this latest member of the PANAVIA family.



_contact

cosmetic
dentistry

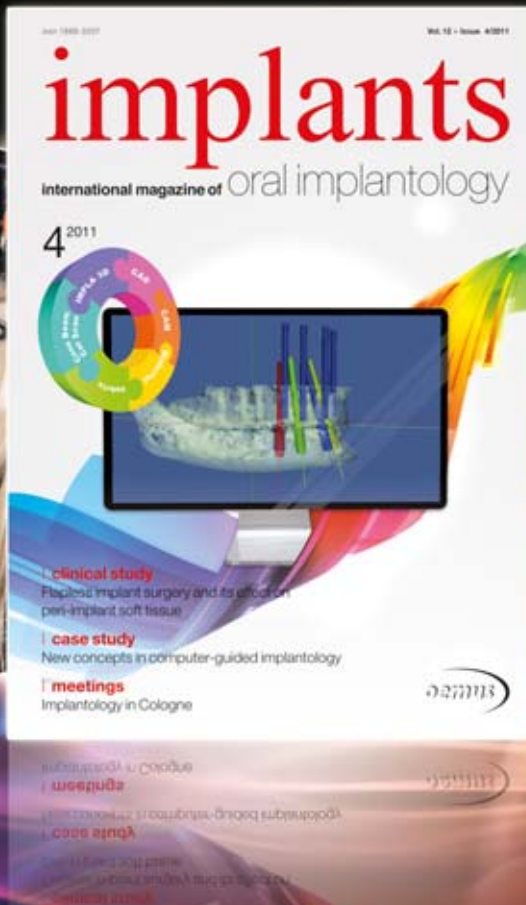Kuraray Europe GmbH

Industriepark Höchst, Building F 821
65926 Frankfurt/Main
Germany

dental@kuraray.eu
www.kuraray-dental.eu (EU)
www.kuraraydental.com (USA)

implants

international magazine of oral implantology



You can also subscribe via
www.oemus.com/abo

 **Subscribe now!**

I hereby agree to receive a free trial subscription of **implants international magazine of oral implantology** (4 issues per year).

I would like to subscribe to **implants** for € 44 including shipping and VAT for German customers, € 46 including shipping and VAT for customers outside of Germany, unless a written cancellation is sent within 14 days of the receipt of the trial subscription. The subscription will be renewed automatically every year until a written cancellation is sent to OEMUS MEDIA AG, Holbeinstr. 29, 04229 Leipzig, Germany, six weeks prior to the renewal date.

▶ **Reply** via Fax +49 341 48474-290 to OEMUS MEDIA AG or via E-mail to grasse@oemus-media.de

One issue free of charge!

Last Name, First Name

Company

Street

ZIP/City/County

E-mail

Signature

Notice of revocation: I am able to revoke the subscription within 14 days after my order by sending a written cancellation to OEMUS MEDIA AG, Holbeinstr. 29, 04229 Leipzig, Germany.

Signature

Holbeinstr. 29, 04229 Leipzig, Germany, Tel.: +49 341 48474-0, Fax: +49 341 48474-290, E-Mail: grasse@oemus-media.de

OEMUS MEDIA AG



DFCIC—Where science meets the art of beauty

Author_Dr Dobrina Mollova, UAE



The third Dental–Facial Cosmetic International Conference (DFCIC), which took place at the Jumeirah Beach Hotel in Dubai from 28 to 29 October 2011, was a great success, achieving record attendance and further establishing its status as the dental industry’s leading international conference.

More than 700 participants and 105 industry representatives from 29 countries gathered in the business hub on the Persian Gulf. Participants had the chance to feel out the latest opinions and trends, and received first-hand insights from the industry. There was also plenty of opportunity to share experiences with colleagues, make new and strengthen existing relationships, and hone ideas and knowledge.

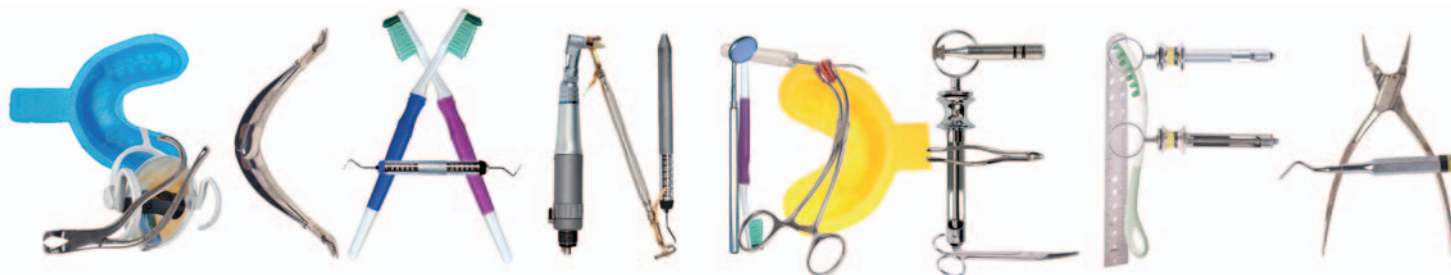The international event brought together world-renowned experts, speakers and specialists in the various fields of dental and facial cosmetics from the Middle East, Europe and the US. The conference featured an exciting programme of six pre- and post-conference workshops designed to provide participants with practical knowledge. The range of sessions allowed atten-

dees to focus on their specific areas of interest and expertise.

We would like to thank our sponsors—Sirona, Ivoclar Vivadent, 3M ESPE, VITA, Noble Medical Equipment, Heraeus Kulzer, KaVo, Pharmapal, SMS Medical and Dental Supplies, GSK, Philips Sonicare, Al Mazroui Medical & Chemical Supplies, to name a few—for their invaluable support!

Next year’s conference will be held from 9 to 10 November 2012.

_contact	cosmetic dentistry
<p>CAPP Knowledge Village, Building 9, Office 8 P.O. Box 502221 Dubai UAE</p> <p>info@cappmea.com www.cappmea.com</p>	



APRIL 26- 28, 2012 • BELLA CENTER • COPENHAGEN • DENMARK

Welcome to the 45th Scandinavian Dental Fair
The leading annual dental fair in Scandinavia

SCANDEFA 2012



The 45th SCANDEFA invites you to exquisitely meet the Scandinavian dental market and sales partners from all over the world in springtime in wonderful Copenhagen

SCANDEFA 2012

Is organized by Bella Center and is being held in conjunction with the Annual Scientific Meeting, organized by the Danish Dental Association (www.tandlaegeforeningen.dk).

175 exhibitors and 11.422 visitors participated at SCANDEFA 2011 on 14,220 m² of exhibition space.

Exhibit at Scandefa

Book online at www.scandefa.dk
Sales and Project Manager, Christian Olrik
col@bellacenter.dk, T +45 32 47 21 25

Travel information

Bella Center is located just a 10 minute taxi drive from Copenhagen Airport. A regional train runs from the airport to Orestad Station, only 15 minutes drive.

Check in at Bella Center's newly built hotel

Bella Sky Comwell is Scandinavia's largest design hotel. The hotel is an integral part of Bella Center and has direct access to Scandefa. Book your stay on www.bellasky.dk

You really don't have to leave Europe!

Author_Dr Philip Lewis, UK



more than 30 excellent lecturers, nearly all from the UK and Europe, delivered a meeting that was described by the delegates as "the best one ever".

What is the secret of the success of a major seminar? *Balance*—balance between subjects and ideas and between approach and execution. *Variety*—most delegates were general practitioners; therefore, a conference concentrating on a single theme would not have been appropriate to everyone present.

The theme of the meeting was "Minimal intervention". How can we produce the best possible results while doing the least amount of damage? The days of aggressive crown and veneer preparation are over. This seminar highlighted the use of composite resin and minimal or no-preparation full or additional veneers.

And there was more! The meeting offered lectures and workshops on numerous subjects to help build better practices, as well as seminars on photography, practice management, marketing and team-building for clinicians and all dental team members.

Who was speaking? There were too many to list I therefore apologise to those not mentioned! Amongst the well-known clinicians who shared their experience and learning was Dr Mauro Fra-



Fig. 1 Delegates register for the event.
Fig. 2 The audience shows approval!
Fig. 3 Dr David Bloom explained the principles of clinical photography.
Fig. 4 Dr Rahul Doshi looked at minimally invasive restoration.

There was a time not so very long ago when dentists looking for advanced education, especially in the field of cosmetics, really had no choice but to travel to the USA.

Times have changed!

At the recent eighth Annual Conference of the British Academy of Cosmetic Dentistry (BACD),





deani, who lectured on the opening day of the three-day conference. This outstanding clinician explained in detail the choice and protocols demanded for the production of metal-free ceramic restorations.

Dr Sanjay Sethi, who is passionate about minimal intervention but requires the very best aesthetics for his patients, stressed that all dentistry must follow strict ethical guidelines.

Prof Trevor Burke expanded on the theme of "Do no harm" and encouraged practitioners to make the best possible use of remaining tooth structure as a framework for building reliable restorations.

For Dr Federico Ferraris adhesion is the key! Whether using direct or indirect procedures the avoidance of micro-leakage is paramount in producing excellent longevity.

Dr Joerd van der Meer spoke about digital impression, a technology that is improving rapidly and opening exciting possibilities.

In his lecture, Dr Jason Smithson explained that warm composite undergoes better monomer conversion, leading to stronger posterior composite fillings, and described his technique in detail.

Our dental trade partners supported the conference with an exhibition that featured more than 40 companies supplying a variety of products from further educational material to high-technology equipment.

Let's get back to balance—this time I am referring to the balance between work and play! Delegates enjoyed many treats during the meeting, including entertainment during the Opening Ceremony, a drinks reception featuring traditional Turkish dancing and a Gala Charity Dinner, during which a substantial sum was raised to support Bridge2Aid, a charity working amongst the underprivileged in Africa.

Balance is important. This year, there were few American accents. Next year, there will be more. It is valuable to consider trends and treatments from both sides of the Atlantic to be able to form a balanced view of the international future of dentistry and make decisions about where we want to place ourselves in this.

If you missed this meeting, you missed what delegates described as "The best BACD meeting ever!"

Make sure you come to the next one!_

Fig. 5_Dr Mauro Fradeani received excellent feedback from delegates following his superb presentation.

Fig. 6_Dr Sanjay Sethi (left) was welcomed by BACD President Dr Nik Sisodia.

Fig. 7_Dr Jason Smithson gave a masterful presentation on the use of posterior composite.

Fig. 8_Dr Lennart Jacobsen described cohesive treatment planning.

Fig. 9_Prof Trevor Burke stressed the importance of preserving natural tissue.

Figs. 10–13_The accompanying trade show highlighted products from a large number of companies.

Figs. 14–16_Impressions from the Opening Ceremony.

_contact

cosmetic
dentistry

BACD

29 Harley Street
London W1G 9QR
UK

info@bacd.com
www.bacd.com

International Events

2012

SCANDEFA

26–28 April 2012
Copenhagen, Denmark
www.scandefa.dk

AACD Scientific Session

2–5 May 2012
Washington, DC, USA
www.aacd.com

EAED Spring Meeting

24–26 May 2012
Çeşme, Turkey
www.eaed.org

IACA 2012

26–28 July 2012
Hollywood, FL, USA
www.theiaca.com

AAED Annual Meeting

7–10 August 2012
Naples, FL, USA
www.estheticacademy.org

FDI Annual World Dental Congress

29 August–1 September 2012
Hong Kong, China
www.fdiworldental.org

SCAD Annual Conference

28 & 29 September 2012
Chicago, IL, USA
www.scadent.org

Dental–Facial Cosmetic

International Conference
9 & 10 November 2012
Dubai, UAE
www.cappmea.com

2013

International Dental Show

12–16 March 2013
Cologne, Germany
www.ids-cologne.de

EAED Spring Meeting

30 May–1 June 2013
Crete, Greece
www.eaed.org

FDI Annual World Dental Congress

29 August–1 September 2013
Seoul, Korea
www.fdiworldental.org



submission guidelines:

Please note that all the textual components of your submission must be combined into one MS Word document. Please do not submit multiple files for each of these items:

- _ the complete article;
- _ all the image (tables, charts, photographs, etc.) captions;
- _ the complete list of sources consulted; and
- _ the author or contact information (biographical sketch, mailing address, e-mail address, etc.).

In addition, images must not be embedded into the MS Word document. All images must be submitted separately, and details about such submission follow below under image requirements.

Text length

Article lengths can vary greatly—from 1,500 to 5,500 words—depending on the subject matter. Our approach is that if you need more or less words to do the topic justice, then please make the article as long or as short as necessary.

We can run an unusually long article in multiple parts, but this usually entails a topic for which each part can stand alone because it contains so much information.

In short, we do not want to limit you in terms of article length, so please use the word count above as a general guideline and if you have specific questions, please do not hesitate to contact us.

Text formatting

We also ask that you forego any special formatting beyond the use of italics and boldface. If you would like to emphasise certain words within the text, please only use italics (do not use underlining or a larger font size). Boldface is reserved for article headers. Please do not use underlining.

Please use single spacing and make sure that the text is left justified. Please do not centre text on the page. Do not indent paragraphs, rather place a blank line between paragraphs. Please do not add tab stops.

Should you require a special layout, please let the word processing programme you are using help you do this formatting automatically. Similarly, should you need to make a list, or add footnotes or endnotes, please let the word processing programme do it for you automatically. There are menus in every programme that will enable you to do so. The fact is that no matter how carefully done, errors can creep in when you try to number footnotes yourself.

Any formatting contrary to stated above will require us to remove such formatting before layout, which is very time-consuming. Please consider this when formatting your document.

Image requirements

Please number images consecutively throughout the article by using a new number for each image. If it is imperative that certain images are grouped together, then use lowercase letters to designate these in a group (for example, 2a, 2b, 2c).

Please place image references in your article wherever they are appropriate, whether in the middle or at the end of a sentence. If you do not directly refer to the image, place the reference at the end of the sentence to which it relates enclosed within brackets and before the period.

In addition, please note:

- _ We require images in TIF or JPEG format.
- _ These images must be no smaller than 6x6 cm in size at 300 DPI.
- _ These image files must be no smaller than 80 KB in size (or they will print the size of a postage stamp!).

Larger image files are always better, and those approximately the size of 1 MB are best. Thus, do not size large image files down to meet our requirements but send us the largest files available. (The larger the starting image is in terms of bytes, the more leeway the designer has for resizing the image in order to fill up more space should there be room available.)

Also, please remember that images must not be embedded into the body of the article submitted. Images must be submitted separately to the textual submission.

You may submit images via e-mail, via our FTP server or post a CD containing your images directly to us (please contact us for the mailing address, as this will depend upon the country from which you will be mailing).

Please also send us a head shot of yourself that is in accordance with the requirements stated above so that it can be printed with your article.

Abstracts

An abstract of your article is not required.

Author or contact information

The author's contact information and a head shot of the author are included at the end of every article. Please note the exact information you would like to appear in this section and format it according to the requirements stated above. A short biographical sketch may precede the contact information if you provide us with the necessary information (60 words or less).

Questions?

Claudia Salwiczek (Managing Editor)
c.salwiczek@oemus-media.de

cosmetic dentistry

_ beauty & science

Publisher

Torsten R. Oemus
oemus@oemus-media.de

CEO

Ingolf Döbbecke
doebbecke@oemus-media.de

Members of the Board

Jürgen Isbaner
isbaner@oemus-media.de

Lutz V. Hiller
hiller@oemus-media.de

Editor-in-Chief

Dr Sushil Koirala
skoirala@wlink.com.np

Co-Editor-in-Chief

Dr So Ran Kwon
smileksr@hotmail.com

Managing Editor

Claudia Salwiczek
c.salwiczek@oemus-media.de

Executive Producer

Gernot Meyer
meyer@oemus-media.de

Designer

Franziska Dachsel
f.dachsel@oemus-media.de

Copy Editors

Sabrina Raaff
Hans Motschmann

Published by

Oemus Media AG
Holbeinstraße 29
04229 Leipzig, Germany
Tel.: +49-341/4 84 74-0
Fax: +49-341/4 84 74-2 90
kontakt@oemus-media.de
www.oemus.com

Printed by

Messedruck Leipzig GmbH
An der Hebemärchte 6
04316 Leipzig, Germany

Advisory Board

Dr Michael Miller, USA
Dr Seok-Hoon Ko, Korea

Editorial Board

Dr Anthony Au, Australia
Dr Bao Baicheng, China
Dr Helena Lee, Singapore
Dr Hisashi Hisamitsu, Japan
Dr Jiraporn Charudilaka, Thailand
Dr Mostaque H. Sattar, Bangladesh
Dr Ratnadeep Patil, India
Dr Sim Tang Eng, Malaysia
Dr Suhit Raj Adhikari, Nepal
Dr Takashi Nakamura, Japan
Dr Vijayaratnam Vijayakumaran, Sri Lanka



Claudia Salwiczek, Managing Editor

cosmetic
dentistry _ beauty & science
is the official publication of:



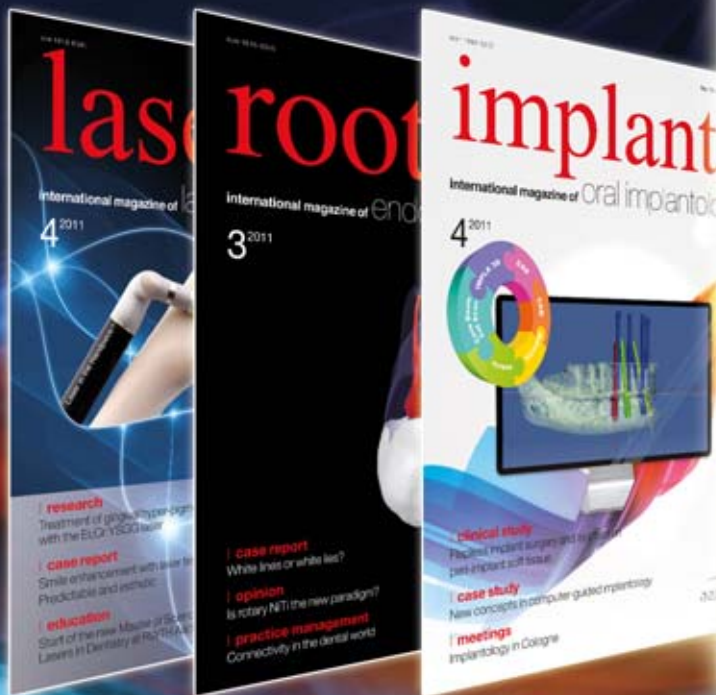Copyright Regulations

_cosmetic dentistry_beauty & science is published by Oemus Media AG and will appear in 2011 with one issue every quarter. The magazine and all articles and illustrations therein are protected by copyright. Any utilisation without the prior consent of editor and publisher is inadmissible and liable to prosecution. This applies in particular to duplicate copies, translations, microfilms, and storage and processing in electronic systems.

Reproductions, including extracts, may only be made with the permission of the publisher. Given no statement to the contrary, any submissions to the editorial department are understood to be in agreement with a full or partial publishing of said submission. The editorial department reserves the right to check all submitted articles for formal errors and factual authority, and to make amendments if necessary. No responsibility shall be taken for unsolicited books and manuscripts. Articles bearing symbols other than that of the editorial department, or which are distinguished by the name of the author, represent the opinion of the afore-mentioned, and do not have to comply with the views of Oemus Media AG. Responsibility for such articles shall be borne by the author. Responsibility for advertisements and other specially labeled items shall not be borne by the editorial department. Likewise, no responsibility shall be assumed for information published about associations, companies and commercial markets. All cases of consequential liability arising from inaccurate or faulty representation are excluded. General terms and conditions apply, legal venue is Leipzig, Germany.

cosmetic

dentistry _ beauty & science



You can also subscribe via
www.oemus.com/abo

 **Subscribe now!**

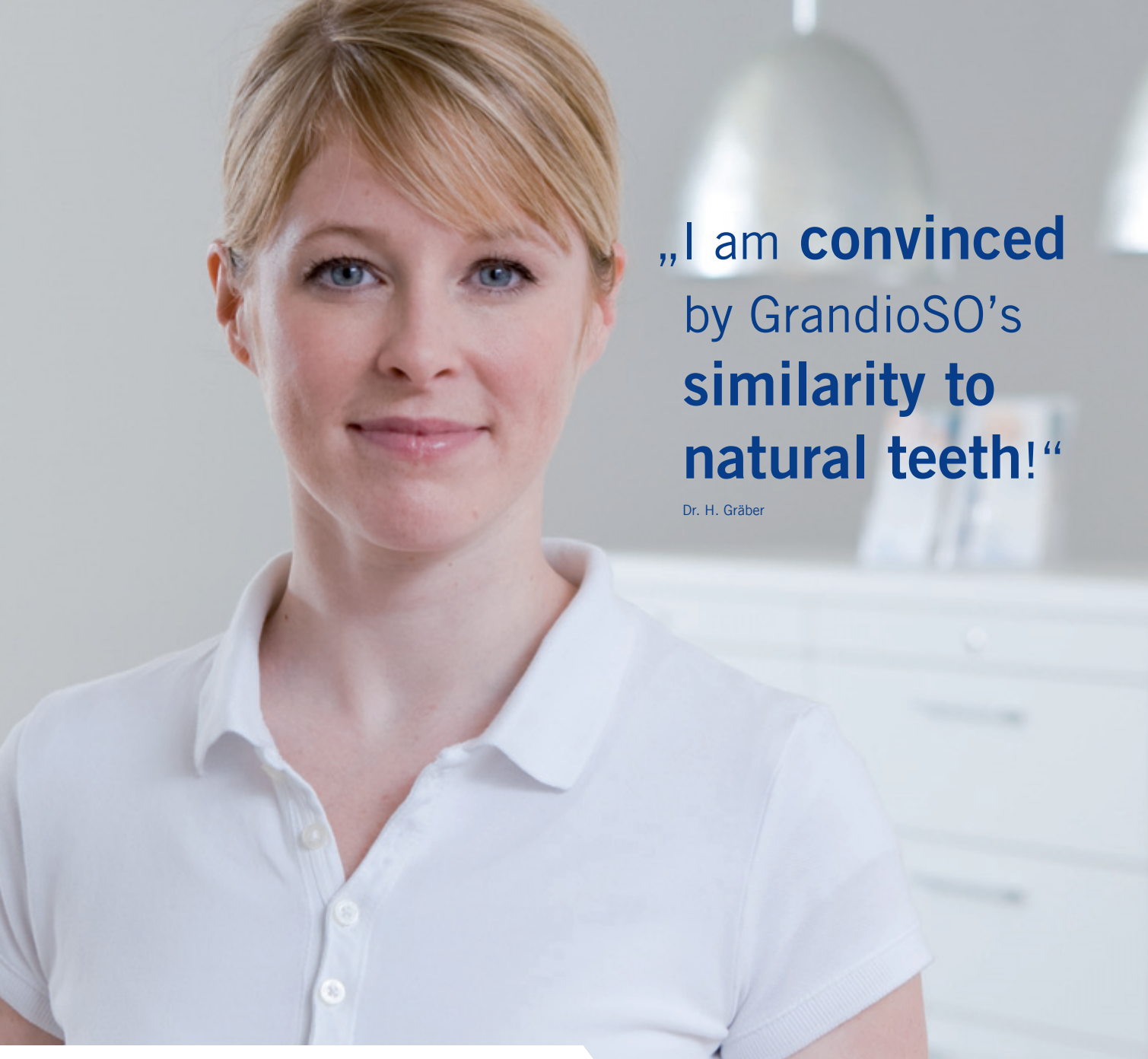
I would like to subscribe to **cosmetic dentistry** for € 44 including shipping and VAT for German customers, € 46 including shipping and VAT for customers outside Germany, unless a written cancellation is sent within 14 days of the receipt of the trial subscription. The subscription will be renewed automatically every year until a written cancellation is sent to OEMUS MEDIA AG, Holbeinstr. 29, 04229 Leipzig, Germany, six weeks prior to the renewal date.

▶ **Reply** via Fax +49 341 48474-290
 or via E-mail to grasse@oemus-media.de

Last Name, First Name	
Company	
Street	
ZIP/City/County	
E-mail	Signature

Notice of revocation: I am able to revoke the subscription within 14 days after my order by sending a written cancellation to OEMUS MEDIA AG, Holbeinstr. 29, 04229 Leipzig, Germany.

Signature



„I am **convinced**
by GrandioSO's
similarity to
natural teeth!“

Dr. H. Gräber

SO TOOTH-LIKE

In the sum of its physical properties, Grandio®SO is the filling material that on a world-wide scale is most similar to natural teeth.* The advantages you will gain are: durable, reliable restorations, and above all satisfied patients.

- Meeting highest demands, universally usable in the anterior and posterior areas
- Natural opacity for tooth-like results using only one shade
- Intelligent colour system with new shades that make good sense: ^{VC}A3.25 and ^{VC}A5
- Smooth consistency, high light stability, simple high-gloss polishing



* Please feel free
to request our scientific
product information.

GrandioSO

