

cosmetic dentistry — beauty & science

1 2012

| special topic

TouchWhite—Next-generation tooth whitening

| clinical technique

RED bonding: Predictable cementation of indirect aesthetic restorations

| practice management

My marketing plan



Fotona[®]
choose perfection

The universe at your fingertips.

TouchWhite™ Laser Assisted Tooth Whitening

A perfect white smile now faster and safer than ever before

- Utilizing the unique laser tissue interaction of the Er:YAG laser wavelength and Fotona's VSP pulse mode
- Up to 10 times shorter treatment times
- Safer - no unnecessary thermal burden on the tooth or pulp
- More comfortable for patients while achieving the same or better whitening efficacy
- Any bleaching gel color can be used
- Perfect, natural looking results after one single treatment

Available only with



LightWalker[®]



www.fotona.com

www.lightwalkerlaser.com

90812/1.0

Dear Reader,

_Welcome to the first issue of **cosmetic dentistry**! The year 2011 was very successful for us and I would like to thank our readers, authors, supporting companies and the entire team of the **cosmetic dentistry** magazine for their support.

This year, we are planning to present articles in **cosmetic dentistry** in a different way. In each issue, we will focus on certain clinical aspects, such as porcelain restorations, direct bonding, implant treatment, occlusion, etc. We will focus on introducing new authors with a variety of clinical cases and treatment strategies.

With the recent advancement in materials, science and technology, the dental practice is becoming increasingly technology based, leading to an increase in treatment costs. In many developing countries, people cannot afford regular dental treatment owing to their inability to afford health insurance and poor government health care. However, it is interesting to note that even in these countries, the demand for cosmetic dentistry is growing. The influence of global media, increased migration and exposure to global fashion trends are the main reasons for the global popularity of cosmetic dentistry.

Reducing the cost of cosmetic treatment should be the focus of today's cosmetic dentists if we wish to deliver services to everyone who needs and wants them. During my international lecture activities, I have noticed that most young clinicians today want to treat cases using complex procedures immediately rather than use simple cosmetic procedures, such as anterior tooth alignment, tooth whitening, bonding and cosmetic contouring procedures (type I cases), which can enhance smiles significantly. Certainly, procedures like implant and bridge placement and full-mouth restorations generate good financial income; however, these services demand extensive knowledge and a vast amount of clinical experience. It is to be noted that a large number of type I cases are treated in the general cosmetic dental practice. Once these cases are treated properly, with long-term health, function and aesthetic in mind, the volume of type II and type III cases will slowly start to increase as well.

Ongoing education is a fundamental requirement in dentistry, but choosing the right knowledge and skills training is not an easy job. In this issue of **cosmetic dentistry**, we present clinical articles mostly related to type I cases. I hope you will enjoy reading our first issue of 2012!

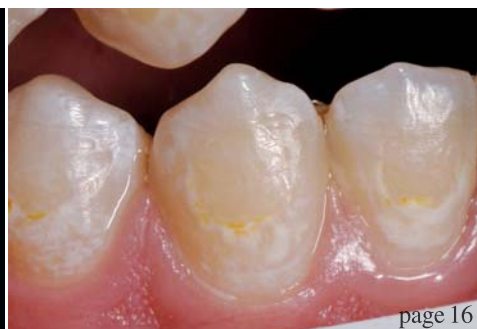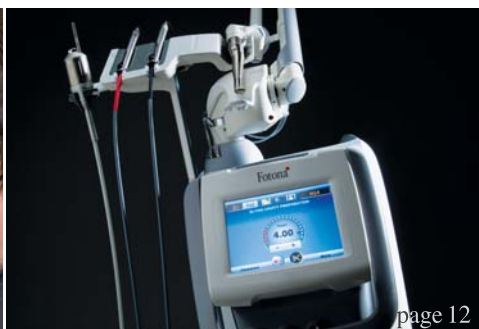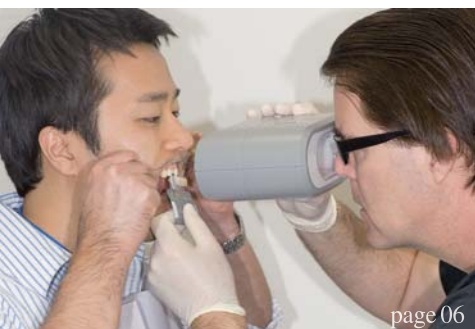Yours faithfully,



Dr Sushil Koirala
Editor-in-Chief
President Vedic Institute of Smile Aesthetics (VISA)
Kathmandu, Nepal



Dr Sushil Koirala
Editor-in-Chief



| editorial

- 03 **Dear Reader**
| Dr Sushil Koirala, Editor-in-Chief

| special topic

- 06 **Shade analysis and communication: 2012**
| Prof Edward A. McLaren
- 12 **TouchWhite—Next-generation tooth whitening**
| Dr Jugoslav Jovanović
- 16 **The problem of white spot lesions**
| Dr Derek Mahony

| practice management

- 18 **My marketing plan**
| Dr James Goolnik

| clinical technique

- 22 **RED bonding: Predictable cementation of indirect aesthetic restorations**
| Dr Irfan Ahmad

| industry report

- 34 **Shining results**
| Dr Monica Basile & Michele Temperani

| industry news

- 38 **CLEARFIL S³ BOND PLUS: High-tech and high speed for high performance**
| Kuraray

| meetings

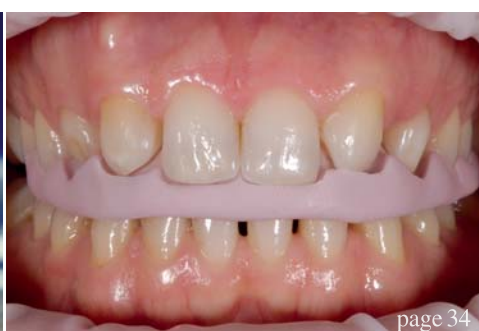- 40 **International Events**

| about the publisher

- 41 | submission guidelines
- 42 | imprint



Cover image courtesy of Alena Ozerova.



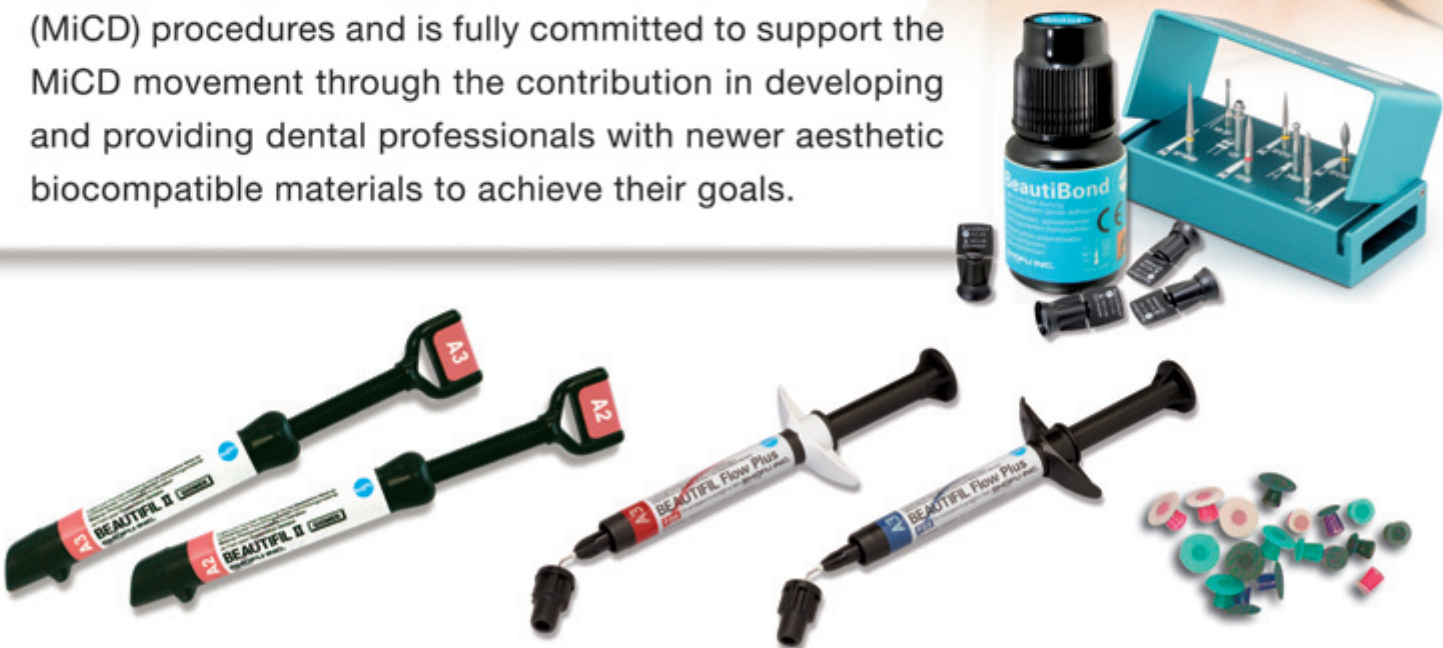

Adopt the trend...



Minimally Invasive
Cosmetic Dentistry

SHOFU recognizes the development of new clinical techniques in minimally invasive cosmetic dentistry (MiCD) procedures and is fully committed to support the MiCD movement through the contribution in developing and providing dental professionals with newer aesthetic biocompatible materials to achieve their goals.



For more information, simply contact your nearest **SHOFU** dealer.



SHOFU INC. SINGAPORE BRANCH

Tel (65) 6377 2722 Fax (65) 6377 1121 eMail mailbx@shofu.com.sg website www.shofu.com.sg

Shade analysis and communication: 2012

The essential elements of evaluating and communicating tooth colour

Author_Prof Edward A. McLaren, USA

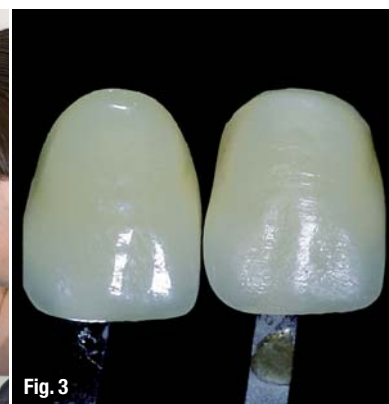
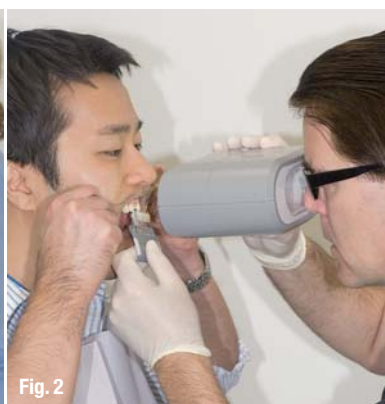
Fig. 1 Using two OttLites held at tooth level 24 inches from the patient to control lighting colour temperature.
Fig. 2 Using the Trueshade light and magnifier to control light.
Fig. 3 Image of two of the same shade guides with different surface texture. Notice the one with a different texture is perceived as a different colour.

With ever increasing emphasis on aesthetics in dentistry, and patient demands to fabricate ceramic restorations that mimic natural teeth that are indistinguishable from adjacent natural teeth, the ability to evaluate tooth shade information correctly and communicate it to the ceramist effectively is now more critical than ever. Correctly evaluating tooth shade is as much an art as a science.

Many articles¹⁻⁷ and even whole books⁷ have been devoted to this topic, yet in hundreds of informal polls of technicians, problems with shade analysis is the second reason given for remakes, with impression/preparation problems being the first.

Many factors contribute to this problem: lighting variables that contribute to perception errors; multiple shade systems available with a lack of standardisation in colour systems and corresponding porcelain systems; individual human variables in colour perception; lack of understanding of colour science, especially as it relates to tooth shade; and the ability to interpolate shade information into a porcelain layering technique that obtains the desired shade. A full article could be devoted to each of those topics. There are many references in dental and non-dental literature on the topics of colour,

colour as it relates to teeth and human perception of colour. The objective of this paper is not to offer an exhaustive review of these topics but to distil the essential aspects of evaluating and communicating tooth colour. Also, to offer the reader an efficient and effective method for evaluating and communicating tooth shade.

This article will focus on:

- _ understanding how lighting (illumination) affects colour perception, and more importantly how to control it;
- _ understanding the parameters of colour that are most critical in evaluating tooth shade and how to access them relative to the tooth;
- _ the ideal set-up and use of current shade guides;
- _ the use of digital photography for communication; and
- _ the integration of computerised shade-analysis devices into the technique of taking and communicating tooth colour.

Understanding lighting and the effect on colour perception

The perception of colour is affected by three primary factors:

- _ the character of the light;
- _ the observer; and
- _ the object being viewed.

A change in the condition of any of the three will cause a change in perception of colour. Thus, differing viewing conditions, that is changes in light or changes in position, can alter perception.⁸ It is impossible to try and match tooth colour under every lighting and positional possibility. One then should try to match under the conditions in which the restoration is most likely to be viewed. Relative to tooth position most people are viewed standing up at conversational distance, so this is the best position in which to place the patient to evaluate shade. Too often, shade is taken with the patient lying back, which increases the chance of a misperception. The reason this happens is the shade guides do not have the same optical properties as the natural tooth. At different viewing angles, they look different, that is a perceived match from one viewing angle may not be a perceived match at another viewing angle.

Shade-analysis rule 1: take the shade with the patient sitting up, eye to eye at conversational distance.

There are many different types of light we are all exposed to, as will be your patients and the restorations you make. When the shade guides are manufactured, they are compared to a standard in a controlled lighting situation. It is very controversial as to what colour temperature light to use to view shade, that is 5,000, 5,500, or 6,500 K.⁹⁻¹² Most shade guides are fabricated to match a standard in a 5,500 K light source. As already stated, shade guides do not have the same optical properties as natural teeth. This means they do not reflect light in the same manner in all lighting conditions as the corresponding shade tooth would. Thus, visual shade matching should only be done in a lighting environment that is close to 5,500 K. From my experience, if the shade guide is matched to the teeth in a 5,500 K light, then it will match well in most lights, but if it is matched in a strongly biased light (for example blue) the restoration will only match in that light.

There are many different companies that sell florescent lights. Full-spectrum, colour corrected with a colour temperature of 5,500 K are the lights best suited for visual shade taking. Ideally, it is best to outfit the operatory with this type of lighting, but an inexpensive way to control light is to use two OttLites (Fig. 1) held

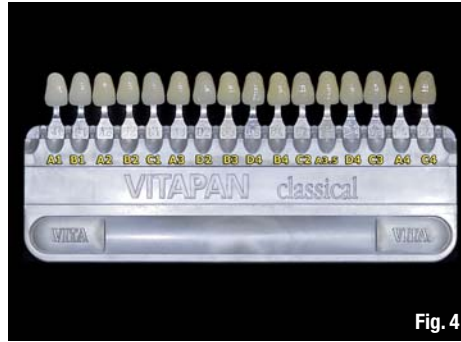

Fig. 4

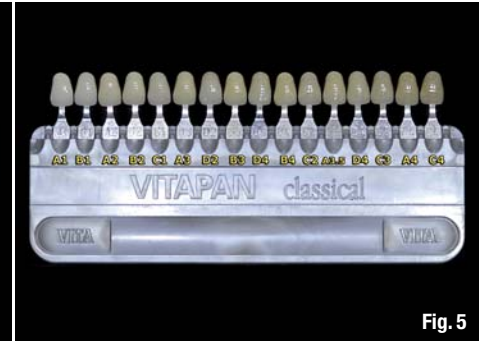

Fig. 5

at 61 cm from the patient at tooth level. Also, there are several innovative self-contained lighting devices available in dentistry. Optilume Trueshade (Optident Dental Products) works well for this and has a magnified viewer (Fig. 2).

There are many other things that could be covered about controlling the viewing conditions. The quantity of light and the hydration of the tooth are very important. Make sure when you are shade matching that there are no overt shadows on the teeth or shade guide and that the light is not so strong as to create specular highlights (reflective white spots). Also, the teeth need to stay hydrated. Saliva dries quickly, especially with cheek retractors in the mouth. We use a medium viscosity clear glaze liquid (Smile Line Glaze liquid, Smile Line USA) to wet the teeth and the shade guide. It is important to wet both, as differences in surface texture between the shade guide and the tooth can create a misperception. The same liquid on both surfaces can neutralise this (Fig. 3).

Shade-analysis rule 2: use full-spectrum, colour corrected lighting, keeping the teeth adequately hydrated.

Understanding colour parameters critical to dental shade analysis

A basic understanding of colour terminology is necessary for one to be able to evaluate differences from the shade guide and to communicate colour to the ceramist. Colour has been defined in many

Fig. 4 Classical Shade Guide in colour with the correct value relationship. Note how tabs with dissimilar chromas look very different in value.

Fig. 5 Classical guide in black and white with the correct value relationship.

Fig. 6 Using the Classical guide arranged by value and working by a process of elimination to obtain to four tabs that cover the value range of the tooth being evaluated.

Fig. 7 Using the Classical guide to select the chroma level.

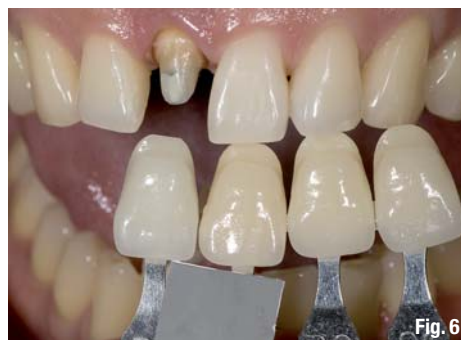

Fig. 6

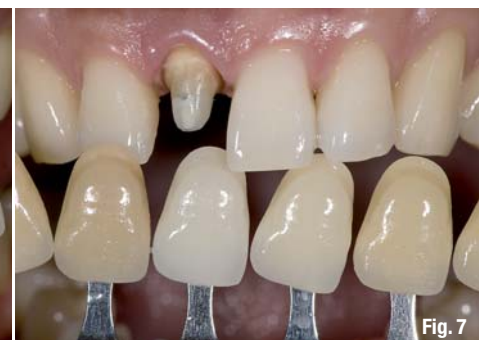

Fig. 7




Fig. 8

Fig. 8_ The 3D-Master arranged with just the M shades from 0 to 5 value.

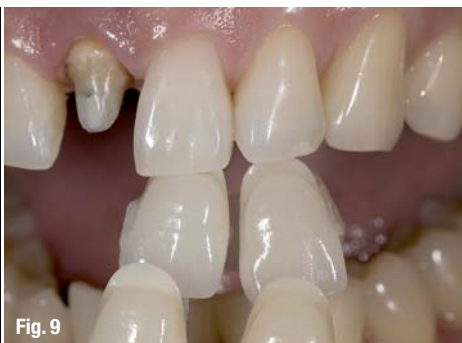

Fig. 9

Fig. 9_ Choosing the value for a patient case.

different ways. The most widely used colour ordering or descriptive system used in dentistry was developed by Mussell.¹³ He defined colour according to three dimensions:

- _hue, the specific wavelength of light energy that would be labelled red, green or blue and everything in between;
- _chroma, the intensity, concentration or amount of a given hue (for example lighter yellow or deeper yellow); and
- _value, or the lightness or darkness of a colour.

In real terms, if more light reflects off an object and hits our eyes, it will be perceived as brighter or higher in value. Conversely, if less light reflects off an object and hits our eyes, it will be perceived as darker or lower in value.

There is a fourth dimension of colour, translucency, that is important when evaluating tooth colour because teeth are translucent and translucency is directly related to the perception of value. When evaluating tooth colour, the most important colour dimension to match is the value and a close second the translucent zones. Next in importance are the chroma zones present in the teeth being evaluated. The least important dimension of colour relative to matching natural teeth is the hue. In natural teeth, the hue range is very narrow and in my experience matching the specific hue is unimportant as long as value/translucency and chroma

are closely matched. In the discussion on shade guides and their use, I will give detailed descriptions on how to evaluate value, translucency and chroma in the shade-analysis process.

Ideal set-up and use of current shade guides

The VITA Classical Shade Guide (Vident) has been the standard shade guide used in dentistry for several decades. More recently, the VITA 3D-Master Shade Guide and a recent significant upgrade, the VITA Linearguide, have been available for shade analysis.¹⁴ The 3D-Master guide and Linearguide are based on actual spectrophotometer analysis of natural teeth¹⁵ and are my preferred guide, but more than 50% of dentists still use the Classical guide, so I will go through its optimised set-up and use and then detail the use of the newer guides.

VITA Classical Shade Guide

Every dentist and ceramist is familiar with the VITA Classical guide. This shade guide was initially developed several decades ago with the last modification or update in the 1960s. It was adequate for that time but analysis of the shade guide shows several problems that lead to the many shade mismatches that still exist. First, the shade guide poorly covers the measured range of natural teeth.¹⁶ Nothing can be done about this except either changing the guide or using a different one. Second is the value arrangement. The value arrangement as reported by the company is different from what has been measured.¹⁶ Figures 4 and 5 show the value arrangement as we measured it in both grey scale and colour images. A1 as we measured is higher in value than B1 and D2 is lower in value than A3. You will probably notice that the colour image of the value arrangement will be hard to believe, that is the tabs right next to each other that have significantly different chromas will appear to have significantly different values, when in fact they are very similar (view the black and white image). This is a problem with human perception that has not been discussed in dentistry before: if two objects have similar values but different chromas the observer will perceive the higher in chroma tab as lower in value when this is not the case. This is exactly what is happening when A1 is compared with B1 (Fig. 5). As previously stated, A1 is higher in chroma than B1 and thus perceived as lower in value when in fact it is higher in value. The same is true for other areas on the Classical guide. This

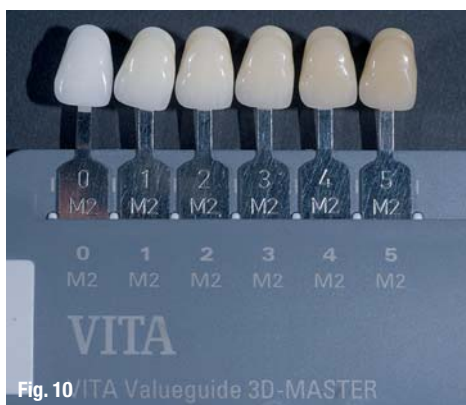

Fig. 10 VITA Valueguide 3D-MASTER

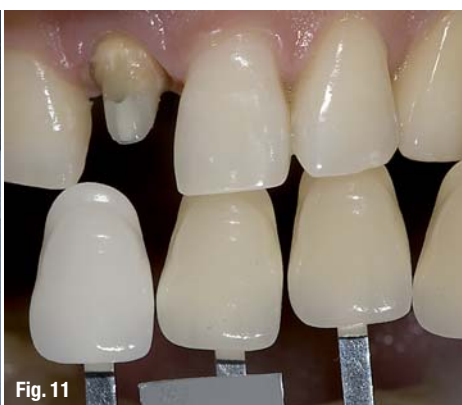

Fig. 11

I believe is the fundamental reason for the level of shade mismatches with this guide.

The first step in minimising this problem and using this shade guide effectively is to arrange the guide by value as shown. As stated earlier, choosing the correct value is most important, as is recording the value zones within the tooth being evaluated. After arranging the guide by value, lightly wet the teeth and shade guide with a clear glaze liquid. The best way to choose a shade is not to see first what appears to be a match, but to look first for obvious mismatches and eliminate them from the shade guide. The goal is to eliminate enough tabs so that you have remaining a range of tabs in which clearly one tab is slightly higher in value and one tab is slightly lower in value. Experience has shown that no fewer than four tabs will accomplish this value range determination (Fig. 6). Several images will be taken and the discussion of how to do it and the importance of calibrated images will come in the next section. Next, to narrow and simplify the chroma and hue choices, I use a second VITA Classical guide set up conventionally, that is A series, B series, C series and D series. I have found at this point that I can work with just the A and B series. I evaluate the A shades that are in the red-yellow (orange) range and then the B shades next to the teeth. I determine whether the teeth appear to have an orangish or yellowish hue. If they appear yellowish, I use the B shades; if they appear reddish or orangish, I use the A shades. I then hold up either the A or B shades next to the teeth to choose the appropriate level of chroma and take chroma images (Fig. 7).

VITA 3D-Master Shade Guide and the Linearguide

The 3D-Master was developed to be able to cover the range of measured natural teeth.¹⁵ More recently, the Linearguide was developed. It is the same shades as the 3D-Master but in a much better tab holder that allows more accurate positioning and evaluation. Because of the similarities between the two, I will describe their use concurrently. Over ten years of personal experience has shown this to be the superior shade-analysis system.

The system is arranged first around choosing the value. There are six value levels that are equally spaced $5 \Delta E$ apart within the colour space.¹⁴ ΔE is a mathematical measurement of the distance between two points in colour space—the human eye can only differentiate points that are greater than $2 \Delta E$ apart.

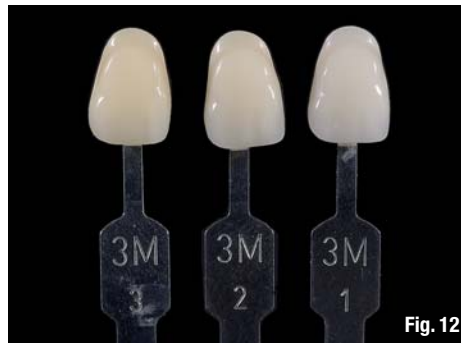

Fig. 12

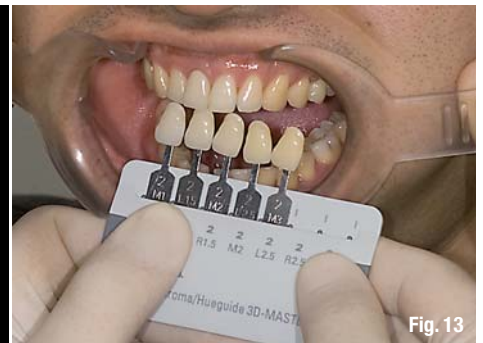

Fig. 13

I have found that the L and R shades can be removed from the shade guide, leaving only the M shades (Fig. 8). This vastly simplifies the value-taking process. The procedure for choosing the value is best done by a process of elimination as described earlier. The two or three closest value groups are chosen so that the range has something that is perceived as slightly higher in value and something slightly lower in value than the natural teeth (Fig. 9). With the Linearguide, it is even easier. The six value groups are in their own holder and tabs can be evaluated more easily (Fig. 10). Again, work by a process of elimination, choosing two or three of the closest values (Fig. 11). Several value images are then taken.

The next step is to determine the level of chroma, of which there are three in most of the M shades. They are labelled 1, 2 and 3 (Fig. 12). Again, it is best accomplished by a process of elimination, recording the closest match or noting if it is between two chroma levels. The chroma levels are all exactly equidistant from each other within the colour space. With the Linearguide, all the different chromas of all three hues are in a special holder (Fig. 13). Using this system makes it easier to determine whether the chroma is at an in-between level. I pass the chroma guide of the closest value in the same plane as the natural teeth and then photograph the two closest chromas (Fig. 14).

The last step is to choose the specific hue. If the value and chroma are matched, experience has shown that an observer would not notice a shade

Fig. 12 Image demonstrating chroma levels with the 3D-Master guide.

Fig. 13 Image demonstrating chroma levels with the Linearguide.

Fig. 14 Choosing the chroma for a patient case. The same image can be used to determine whether the teeth are redder or yellower than the M hue group shown.

Fig. 15 Image of hydrated tooth with shade tab.

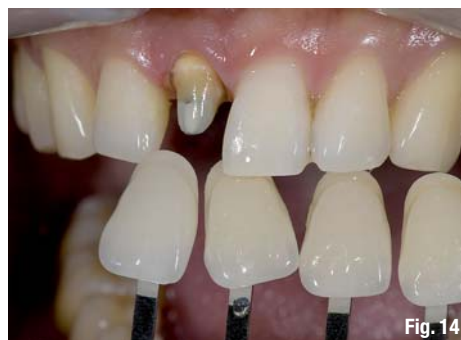

Fig. 14

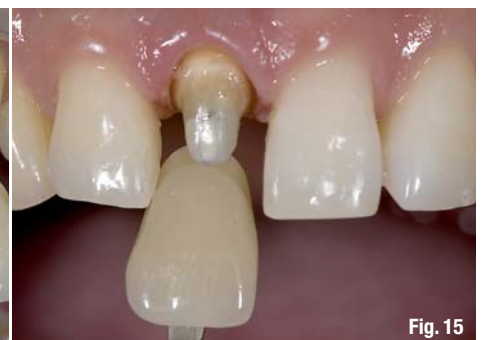

Fig. 15

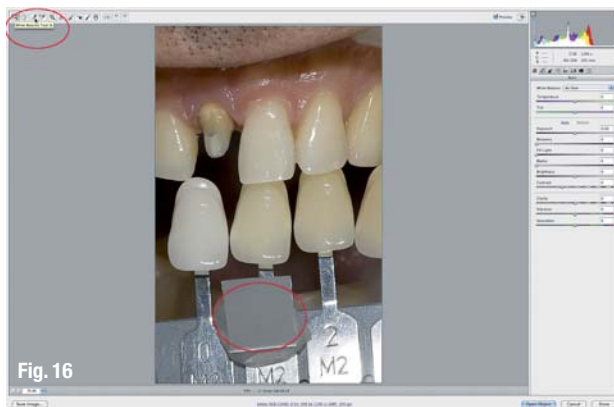

Fig. 16

Fig. 16 Image of Camera Raw in Photoshop. The white balance eyedropper is activated by clicking and then the grey card is clicked on. This will neutralise a colour cast.

mismatch for mismatches in hue as long as the hue is within the natural tooth range, but is noteworthy to evaluate whether there is a reddish, orangish or yellowish hue to the teeth. There are three specific hues, a middle hue (orangish), which corresponds to the middle range of natural teeth, a yellower hue, and a redder hue equidistant in colour space from the middle hue. I would first evaluate the M hue of the closest value match relative to the tooth (Fig. 14), and decide whether it matches or if it is redder or yellower and then record the chosen hue. The final determination for the hue will be determined from the photography and computer analysis described in the next sections. Specific characteristics (such as crack lines or decalcifications) can be recorded with high quality photography.

Digital photography for shade communication

The second part of my shade-taking technique is to record the value and chroma images previously described using digital photography. Information on camera and flash selection and specific camera settings is covered in detail elsewhere and the reader should review the references.¹⁷⁻¹⁹

The most important points are:

- _ use a digital SLR camera that allows interchangeable lenses,
- _ record shade images in RAW file format,

_ control exposure and white balance ideally with manual exposure at specific flash/subject distances.

There are four images necessary for shade communication. One image is taken with the two or three value shade tabs closest to the teeth being matched using the 3D-Master or the Linearguide (Fig. 9). With the Classical guide, the four closest value tabs should be in the image (Fig. 6). Remember the goal is to have a range of values. Ideally, one tab should be slightly higher in value and one slightly lower in value. The second image is with the two closest chroma matches to the teeth. Again, one tab is slightly higher in chroma and one slightly lower. The third image is an image with what is perceived as the closest value, using a small piece of digital grey card that has been attached to the shade tab (you could do this with the first value image). I attach the digital grey card using white utility wax (Fig. 9). The reason for this is it allows the ability to correct colour bias that is inherent, as all flashes have subtly different colour temperatures and depending on the charge state of the flash capacitor can also affect the colour temperature of the flash. This technique will be discussed later. The fourth image (Fig. 15) is an image of the hydrated prepared tooth with a closely matched shade tab. This is for the ceramist to see the preparation colour to be able to modify the build-up or core colour as necessary to compensate for the preparation colour.

It is critical that all the images be taken with the shade guide and the teeth to be matched in the same vertical plane, as objects closer to the film plane will be perceived as brighter and objects farther away will be perceived as darker. The shade guide and the teeth should be wet with a glaze liquid as previously mentioned. This photographic information will be used by the ceramist to visualise contrasts between the shade guide and the natural teeth.

Photoshop to isolate the shade images

There are many uses of Photoshop (Adobe) for image management and manipulation. The scope of this article does not allow me to go into the use of Photoshop for these issues. Photoshop or Photoshop elements are used for two specific purposes in shade analysis and communication.

To correct a colour balance, open the shade images in Camera Raw and in the image window click on 'select all'. Then click on the white balance tool (Fig. 16) in the upper left of the Camera Raw window, then click on the grey card that is in the

Fig. 17 Image with backgrounds neutralised in Photoshop. It is much easier to evaluate colour.

Fig. 18 Image using the Easyshade compact.

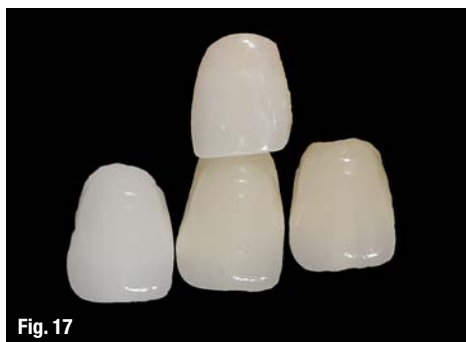

Fig. 17

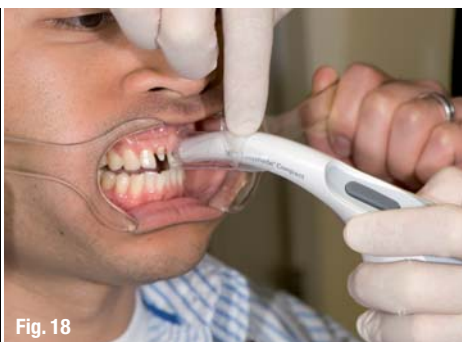

Fig. 18

image and the colours will be rebalanced if there is a colour bias. This will be applied to all the images selected.

Photoshop is an ideal tool to isolate (select out) the shade guides and the teeth to be matched from their surrounding backgrounds and then neutralise the backgrounds (Fig. 17). The reader is directed to the detailed technique to do this that has been previously published.¹⁸

Integrating computerised shade-analysis devices

The third and equally important aspect of my shade-taking technique is using computerised shade-taking technology. Computers, the Internet and all digital technologies permeate every area of daily life, and dentistry is no different. Several digital shade-analysis technologies have been introduced to dentistry. Today, we would not be able to work without one of the digital shade-analysis systems but the systems have not evolved to the point that they can replace human perception. It would not be useful in an article of this type to go into the science and technology aspects of the various systems, rather it would be useful to tell you the practical application in state-of-the-art shade analysis and communication.

The computerised systems we tested in-house take a better base shade than the average human shade taker, but humans can detect the subtle variances of tooth colour better. So by experience, we believe the computers can be used to take base shades, then along with visual perception and high quality digital photography, the three used together will give accurate shade information to be used by the ceramist. I take my visual shade before taking a computerised shade so that it does not bias my perception. We have several systems at UCLA (University of California, Los Angeles), the VITA Easyshade (Vident), Shade-X and Shade-Rite (both X-Rite), and the Crystal Eye (Minolta), and there are several others on the market. All of them work to a certain extent. We believe from experience that a device should be simple and give an accurate base shade. Easyshade (Fig. 18) in our tests is the easiest to use for base shade and has been proven to provide as or more accurate base shade than the average visual shade taken by a group of dentists. If photographs are not taken (which is not recommended), the Crystal Eye also gives good shade information and a digital image, but the system is much more expensive. Figures 19 and 20 are before and after images of a single central incisor fabricated using this technique.

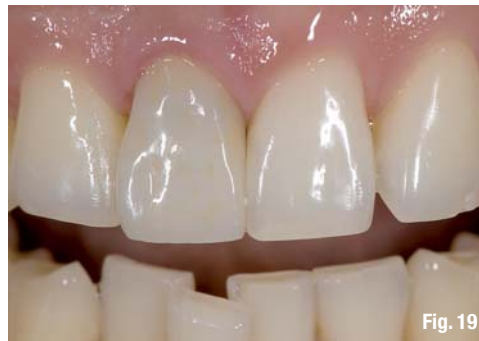

Fig. 19

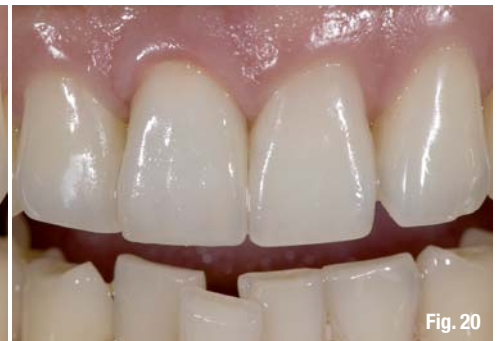

Fig. 20

Fig. 19 Pre-op image of a crown of which the patient complained that the restoration was too low in value.
Fig. 20 Post-op image of a single central incisor using VM 13 (Vident).

Summary

A three-part system for shade analysis and communication has been detailed in this paper. All three parts are interdependent and when used in concert have reduced remakes for shade mismatches in the UCLA's Center for Esthetic Dentistry clinic by more than 80 %.

Editorial note: A complete list of references is available from the publisher.

about the author

cosmetic
dentistry



Prof Edward A. McLaren

maintains a private practice limited to prosthodontics and aesthetic dentistry. He is Director of the UCLA Center for Esthetic Dentistry, which offers a full-time didactic and clinical programme for graduate dentists. He is also the founder and Director of the UCLA School for Esthetic Dental Design. Prof McLaren is a member of the American College of Prosthodontists, Pacific Coast Society for Prosthodontists, International College of Prosthodontists, American Academy of Esthetic Dentistry, International Society of Dental Ceramics, International Association for Dental Research, American Association for Dental Research, American Dental Association and California Dental Association. He is actively involved in many areas of prosthodontic and materials research and has published several articles. He conducts ongoing clinical research on various restorative systems. He has presented numerous lectures, hands-on clinics and postgraduate courses on ceramics and aesthetics.

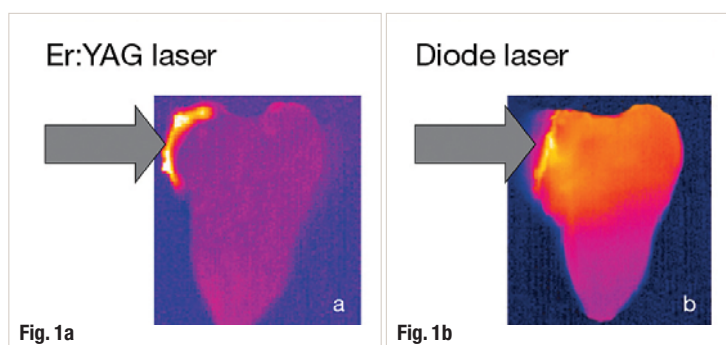
Prof Edward A. McLaren

UCLA Continuing Dental Education
Box 951668, Room A0-121 CHS
Los Angeles, CA, USA

TouchWhite— Next-generation tooth whitening

Author_Dr Jugoslav Jovanović, Bosnia and Herzegovina

White teeth have long been cosmetically desirable. Studies suggest that at least a third of dental patients are not satisfied with the colour or aesthetic appearance of their natural teeth.¹⁻³ As demand for aesthetic dental care has grown steadily over the years, many methods have been introduced to whiten teeth that are naturally off-white or that have become stained through smoking and dietary factors.^{4,5}



Figs. 1a & b Lateral view thermal images of a tooth under Er:YAG (a) and diode (b) laser illumination.

The most basic methods for enhancing the appearance of discoloured teeth involve the application of gels, pastes or liquids that are mechanically applied to the tooth surface to remove stains through an abrasive process. More effective methods involve tooth-whitening products that activate a chemical bleaching effect during contact with the stained teeth.⁶

Many dental practitioners also employ lasers or other high-intensity light sources to enhance the bleaching process and reduce the overall treatment time. However, not all laser-assisted tooth-whitening methods are equal.

A more effective and patient-friendly tooth-whitening solution is presented in this paper. The novel and proprietary TouchWhite method (Fotona) eliminates the main disadvantages of other laser-assisted whitening methods. The procedure is simple to perform, requiring only a standard water-based bleaching agent that is heated by means of a pulsed Er:YAG laser source. The key

to the superior effectiveness of the procedure lies in the unique nature of this particular laser wavelength and the specific TouchWhite treatment parameters.

TouchWhite versus traditional laser-assisted tooth whitening

In order to understand the reason that TouchWhite is superior to other bleaching methods, it is helpful to take a closer look at some of the main concerns and disadvantages of typical laser-assisted bleaching solutions:⁷

To start with, other laser bleaching systems require a specialised (and more costly) bleaching gel that contains a special high-tech blend of light-absorbing particles, together with a compatible laser device that emits light at the exact, corresponding absorption wavelength of the absorbing particles.

It can be inconvenient and more difficult to clean teeth that have been coloured by gels that are infused with these particles after the procedure.

The dental practitioner has little choice but to trust that the added light-absorbing particles are non-toxic, biocompatible, and effective enough at absorbing laser light to guarantee a safe treatment.

Unfortunately, the density of the light-absorbing particles in laser-enhanced bleaching gels is typically such that light from the laser source is not fully absorbed in the relatively thin layer of gel that is applied to the tooth surface. Owing to this inefficient light absorption, some of the laser energy will be transmitted directly into dental tissues. This can lead to an undesired heating of the patient's whole tooth and dental pulp, possibly leading to pain and irreversible damage. Indeed, some of the treatment procedures recommend applying laser light to a tooth until the patient reports feeling pain.

The TouchWhite method uses a very different approach, which eliminates all such concerns

about safety owing to the unique way in which the Er:YAG laser wavelength interacts with the bleaching gel.

Before taking a closer look at the TouchWhite method, however, let's first quickly review some of the basics of dental bleaching gels.

— Bleaching gel effectiveness

Bleaching gels consist mainly of water and a bleaching agent containing hydrogen peroxide (H_2O_2). Water is the principal component of bleaching gels and commonly accounts for more than 50% of the gel by weight. The bleaching agent itself is present in an amount ranging from 3 to 50% by weight.

In a typical tooth-whitening process, the bleaching gel is applied to the teeth and allowed to remain in contact for up to an hour. The intensity of the bleaching effect depends on both the duration of contact and the rate of activation of the gel, which can be increased by raising the temperature. Heat serves to increase the rate of activation of free radicals in H_2O_2 , accelerating the speed at which whitening can be achieved.^{8,9}

In particular, higher gel temperatures facilitate:

- faster generation and greater mobility of H_2O_2 in the bleaching gel;
- decomposition of H_2O_2 into OH and O;
- an enhanced diffusion rate into the tooth; and
- an enhanced reaction time between the active peroxide species (radicals of OH or atomic oxygen O) and the compounds of the enamel and dentine.

Typical temperature increases in the gel that are desirable for dental treatments are between 10 and 40 °C.

— Light absorption

The use of high-intensity light for increasing the temperature of H_2O_2 to enhance the chemical bleaching of teeth was first reported by Abbot in 1918.¹⁰ In modern dental offices, lasers are frequently used to deliver a controlled beam of high-intensity light to thermally activate the bleaching gel.

Many manufacturers of laser- and light-based bleaching systems claim that there is improved light absorption, reduced tooth heating, and even photochemical activation of the bleaching gel following the addition of an activator, absorber or colourant to the gel.^{11,12} In principle, this concept

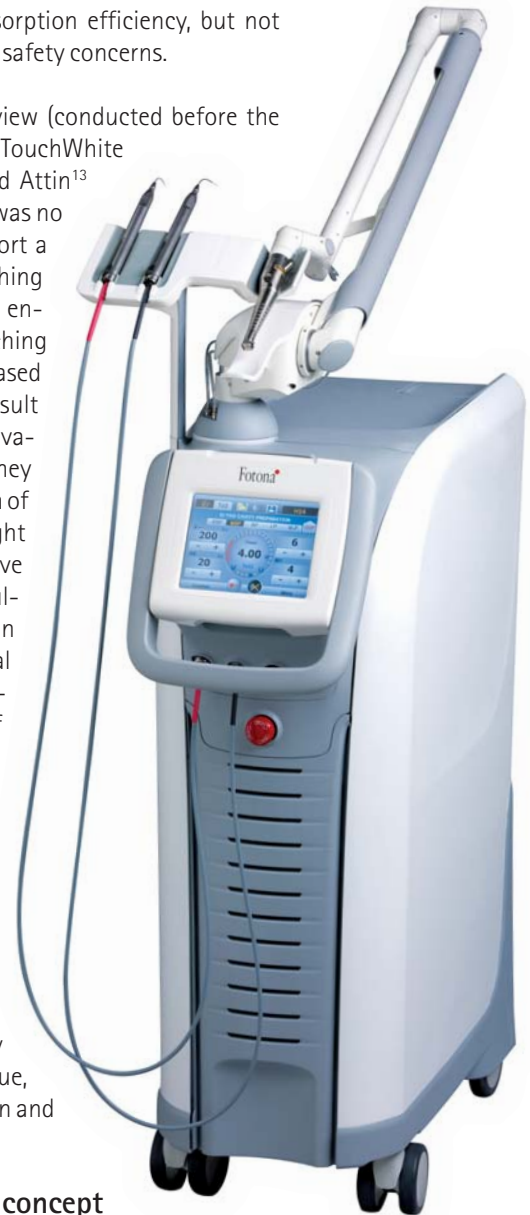does improve the absorption efficiency, but not enough to alleviate all safety concerns.

In a systematic review (conducted before the introduction of the TouchWhite method), Buchalla and Attin¹³ concluded that there was no real evidence to support a photochemical bleaching effect and that the enhanced rate of bleaching with laser- or light-based treatments was the result of photothermal activation. Additionally, they warned that activation of bleaching agents by light or laser energy may have an adverse effect on pulpal tissue owing to an increase in intra-pulpal temperature exceeding the critical value of 5.6 °C. This is because most laser wavelengths are not fully absorbed in the relatively thin layer of the gel that is deposited on the tooth surface. As a result, the laser energy is transmitted directly into the dental tissue, possibly leading to pain and permanent damage.

— The TouchWhite concept

The TouchWhite method uses a very different approach, which eliminates these concerns by making optimum use of the unique properties of the Er:YAG laser wavelength, which is the laser wavelength that is most highly absorbed in water. Water is the major component of dental bleaching gels, and owing to the nearly instantaneous absorption of the Er:YAG beam in water, the need for having special light-absorbing particles in the gel is removed entirely. All of the Er:YAG laser energy is used for direct heating of the bleaching gel, thus preventing any risk of thermal injury to the tooth.

During the application of the Er:YAG laser during TouchWhite, the beam of light is fully absorbed in the first 10 to 50 μ of the gel, and deeper gel layers are subsequently heated by means of thermal diffusion away from the laser-heated surface layer.



There is no direct heating of dental tissue or pulp, as is the case with other laser-assisted whitening methods. The TouchWhite procedure, in fact, represents the safest, least invasive laser-assisted tooth-whitening method available.

It is also worth noting that with TouchWhite, the laser parameters are customised for bleaching treatments so that the laser fluence of each laser pulse is below 0.5 J/cm², which is well below the

23-24-14-15-25-12-22 for the upper teeth and #33-43-34-44-35-45-32-42-31-41 for the lower teeth.

Each tooth is irradiated for 20 seconds in the same sequence as the gel application. The parameter settings for the Fotona Er:YAG laser are as follows: frequency 10 Hz, power 0.55 W, pulse duration VLP, handpiece R093. The handpiece is moved in a sweeping motion across the gel surface.

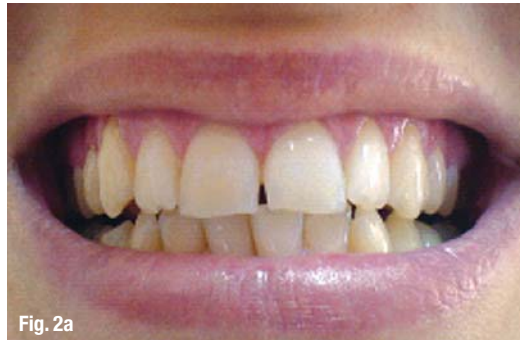

Fig. 2a

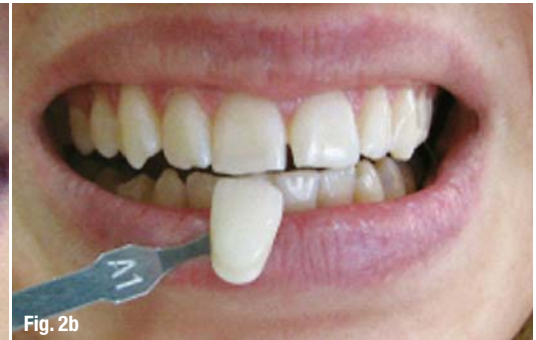

Fig. 2b

Figs. 2a & b Before (a; A3 VITA shade guide) and immediately after (b; A1 VITA shade guide) images of the TouchWhite Er:YAG laser-assisted whitening procedure.

ablation threshold of dental tissues. Since the ablation threshold for enamel is approximately 3.5 J/cm², there is no risk of accidental damage.¹⁴

Figure 1 shows the lateral view thermal image of a tooth during Er:YAG and diode laser (810 nm) illumination of bleaching gel.¹⁵ As can be seen in the first image (Fig. 1a), the Er:YAG wavelength is fully absorbed by the gel, and there is no direct heating of the underlying tooth.

In contrast, the diode wavelength is poorly absorbed in the gel and the transmitted light directly heats the entire tooth. For this reason, the Er:YAG laser power is utilised more effectively and the gel can be heated to higher temperatures without compromising the safety of the tooth or the pulp. As a consequence, the tooth-whitening speeds can be safely increased by five to ten times with TouchWhite.¹⁵

The TouchWhite procedure

The Fotona TouchWhite bleaching kit contains gingival protection, bleaching gel and after-bleaching care material, packed in a syringe. The complete bleaching kit should be stored in a refrigerator (3–8 °C). Before application, the kit is taken out of the refrigerator, the gel is mixed in the amount needed for the procedure, and the mixed gel is left to rest for four to eight minutes at room temperature.

The gel is then applied to the teeth with a spatula in a predetermined sequence #11-21-13-

In the unlikely event that pain or sensitivity occurs in any tooth, the handpiece should be moved to the next tooth immediately.

Pay careful attention not to irradiate two neighbouring teeth at the same time. The whole procedure is repeated three times so that every tooth is irradiated three times for 20 seconds each.

Once the three-cycle illumination of all teeth has been completed, the gel is removed with an aspirator and the tooth surface is thoroughly rinsed with a water spray. The colour is checked with a shade guide and shown to the patient. The procedure can be repeated up to three times in a single appointment if necessary.

Research supporting TouchWhite

In vitro measurements and clinical studies have shown that with TouchWhite, whitening treatment times can be safely shortened to between one to two minutes, down from ten to 15 minutes when no laser activation is applied. The method is effective and safe, as confirmed by temperature measurements in the pulpal chamber.

The TouchWhite method was first proposed and studied by the Laser and Health Academy in partnership with the European manufacturer Fotona. Later, the Aachen Dental Laser Center (AALZ) in Germany performed a detailed *in vitro* study of the temperature elevation in the pulp chamber under different Er:YAG laser-whitening scenarios, fol-

lowed by a clinical study of Er:YAG laser-assisted whitening.¹⁵ Both studies confirmed the TouchWhite method to be safe and highly effective in shortening the activation times of the bleaching gels.

Another introductory clinical study conducted at the Kozarac Dental Clinic in 2009 tested an Er:YAG laser-assisted whitening method in which the bleaching gel was illuminated for three sequences of 20 seconds, with ten-second intervals between each sequence (according to the studies conducted by Fotona and AALZ, this illumination mode can shorten the bleaching time from ten to 15 minutes to 1.5 to two minutes).¹⁶ Five patients with 16 intrinsically stained teeth (12 vital and four non-vital) were treated with Fotona tooth-whitening gel (35% H₂O₂). One to three treatment sessions were conducted depending on the intensity of discolouration.

The results of this initial study confirmed that the Er:YAG laser applied in a three-sequence mode can be used safely and effectively for the bleaching of discoloured vital and non-vital teeth. Since then, the TouchWhite procedure has been performed on numerous additional patients.

In comparison with diode and Nd:YAG bleaching, the Er:YAG laser-assisted whitening method has proven to be more comfortable for patients, while achieving the same or better whitening efficacy in shorter treatment times.

As an example, Figure 2 shows before and after photographs for one of the cases.

Proper diagnosis—The key to success

As with all medical treatments, the key to success with TouchWhite is proper diagnosis. Dentists are often asked by patients to provide an expert opinion on the causes of tooth discolouration. To answer this question properly and to provide the patient with the best possible treatment options, it is essential to understand the relationship between tooth development and the various agents that can cause improper and undesirable tooth colour. There are more than 50 different conditions operating locally or systemically that can cause developmental disturbances in tooth formation.

Each cosmetic dental practitioner must be able to recommend, based on prior knowledge and experience, which procedure to perform in order to achieve the most desirable results for the patient—whether through bleaching or prosthetic crowns and veneers.

Experience with TouchWhite demonstrates that the conditions that can be successfully treated with the procedure are:

- intrinsic discolouration in the formative phase (fluorosis—brown or opaque, and tetracycline staining); and
- intrinsic discolouration in the post-formative phase (colour due to pulpal necrosis, iatrogenic factors due to root and crown fillings, and discolouration due to ageing).

For other intrinsic discolourations, whether in the formative or post-formative phase, prosthetic solutions should be considered.

Conclusion

The TouchWhite process makes use of the unique properties of the Er:YAG laser wavelength, which is well absorbed by water—the major component of aqueous bleaching gels—thus eliminating the need for special light-absorbing particles in the gel. Since the Er:YAG laser beam is fully absorbed by the bleaching gel, it consequently does not directly heat the patient's hard tissue or pulp.

Furthermore, the laser parameters are adjusted so that the laser fluence of each laser pulse is significantly below the ablation threshold for dental tissues. Because of these optimal laser characteristics and protective parameter settings, the TouchWhite procedure represents the safest, most effective and minimally invasive laser-assisted tooth-whitening method available.

Editorial note: A complete list of references is available from the publisher.

about the author

cosmetic
dentistry



Dr Jugoslav Jovanović is a researcher and lecturer in the field of laser-based oral applications and dentistry. As a member of several international organisations in laser-assisted dentistry, he has published numerous articles and has lectured at domestic and international congresses and workshops. He practises laser dentistry in his private practice in Kozarac (Bosnia and Herzegovina), where he focuses mainly on endodontics, periodontics, oral surgery and aesthetic dentistry.

The problem of white spot lesions

A new method for remineralisation post-orthodontic treatment

Author_Dr Derek Mahony, Australia

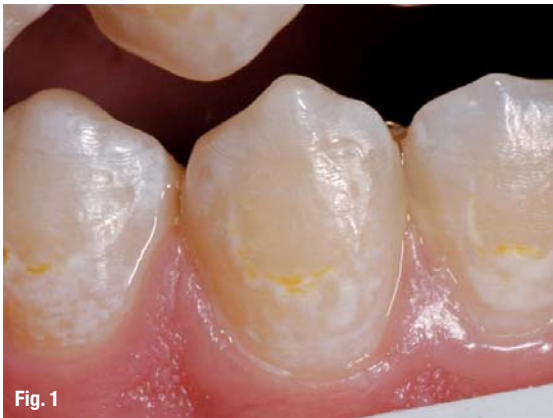

Fig. 1

_Demineralised white spot lesions occur frequently after orthodontic treatment. Some teeth are more prone to demineralisation, typically the maxillary lateral incisors and the mandibular canine teeth. The disto-gingival area of the labial enamel surface is the area most commonly affected (Fig. 1). In the first few weeks after removal of

Various treatment methods have been proposed to assist the process of remineralisation. It is important to note that fluoride should not be used in high concentration, as it tends to prevent demineralisation and can lead to further unsightly staining. Low concentrations of fluoride, however, may assist remineralisation, such as those found in casein calcium phosphate materials. Additionally, stimulation of salivary flow by chewing sugar-free gum is helpful.

This article will describe a revolutionary new approach to the cosmetic treatment of white spot lesions (Fig. 3). With Icon, a microinvasive technology from German manufacturer DMG, demineralised enamel can be filled and reinforced without drilling or anaesthesia (Figs. 4 & 5).

Fig. 1 Typical white spots: C-shaped or irregular. the fixed appliances, there is a reduction in white spot lesion size and appearance, possibly due to the action of saliva (Fig. 2).

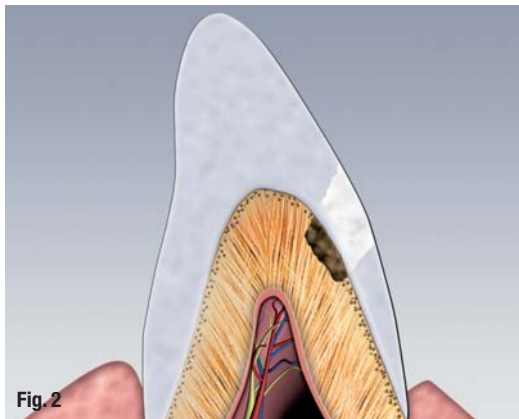


Fig. 2

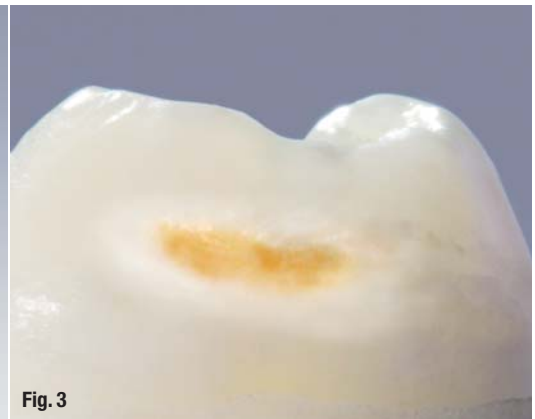

Fig. 3

Fig. 2 Smooth surface caries lesion.

Fig. 3 Clinical image of an incipient caries lesion.

Fig. 4 Clinical image of an incipient caries lesion.

Fig. 5 Pore system of an incipient caries lesion.

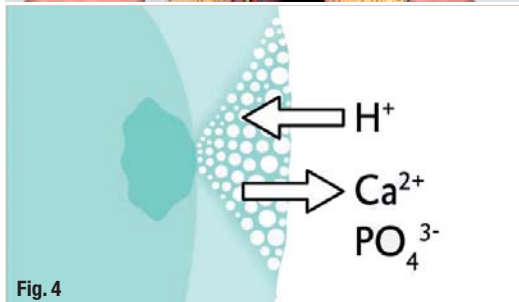


Fig. 4

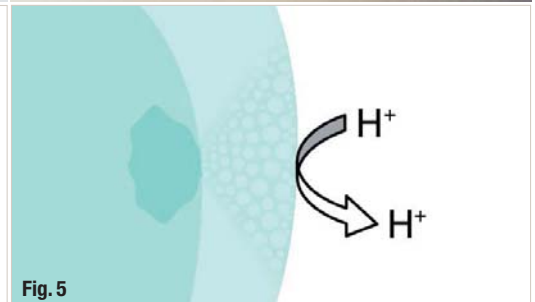
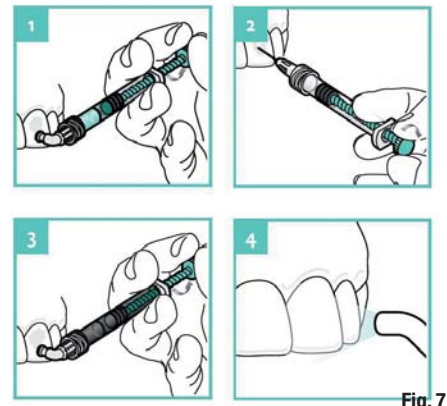
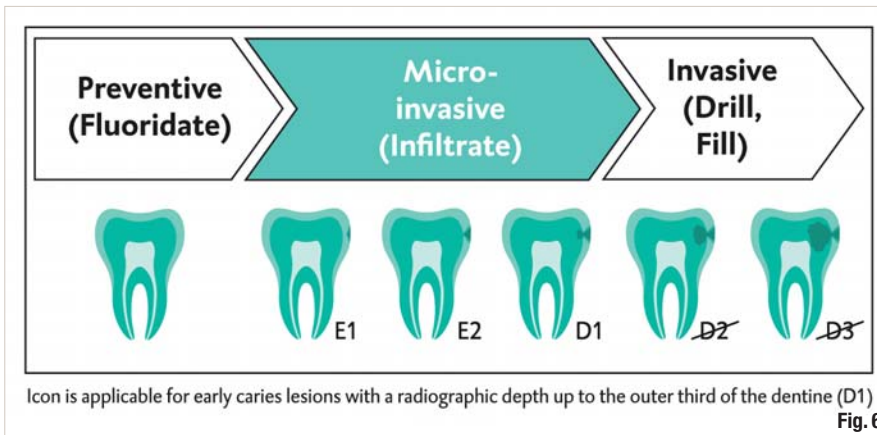


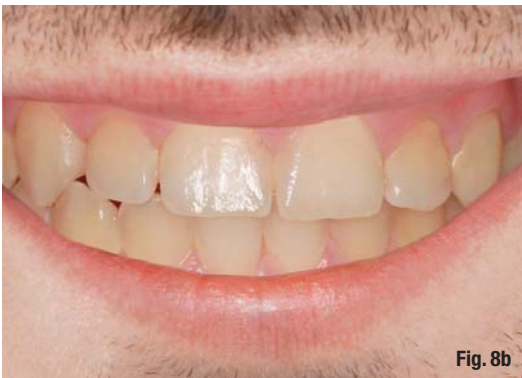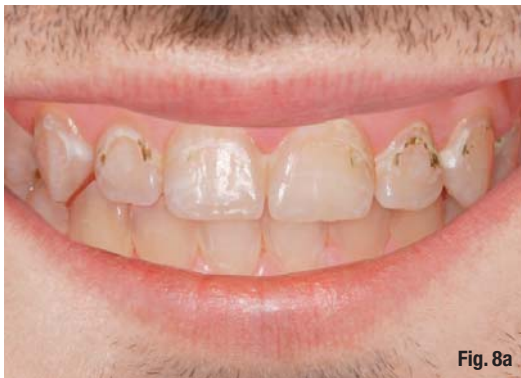Fig. 5



One of the reasons that earlier approaches to the treatment of white spot lesions have fallen short is that fluoride therapy is not always effective

earlier. I would recommend that clinicians try the Icon product when attempting to remineralise white spot lesions post-orthodontic treatment. This

Fig. 6 _The first treatment to bridge the gap between prevention and restoration.
Fig. 7 _Smooth surface procedure.



Figs. 8a & b _Lesions before and after Icon treatment.


in the advanced stages, and the use of restorative fillings usually sacrifices significant amounts of healthy tooth structure. Instead of adopting a wait and see approach, Icon has been shown to arrest the progress of early enamel lesions up to the first third of dentine in one simple procedure (Fig. 6), without unnecessary loss of healthy tooth structure.

is not just minimally invasive dentistry; it is micro-invasive dentistry.

In the procedure described here, the surface area of the white spot lesion is eroded with a 15% HCl gel, which opens the pore system of the lesion. This is then dried with ethanol, followed by the application of Icon onto the lesion with the application aid. The extremely high penetration coefficient enables it to penetrate into the lesion pores. Excess material is then removed, and the material is light-cured. The total treatment time should be about 15 minutes (Fig. 7).

The cosmetic treatment of cariogenic white spots in one visit can be very appealing, especially to young patients and their parents (Figs. 8a & b). No drilling or anaesthesia is required and those patients who have already demonstrated poor compliance with their brushing can be treated

_about the author



Dr Derek Mahony is a world-renowned specialist orthodontist, who has spoken to thousands of practitioners about the benefits of interceptive orthodontic treatment. Early in his career, Dr Mahony learned from leading clinicians the dramatic effect functional appliance therapy can afford patients in orthodontic treatment. He has combined the fixed and functional appliance approach ever since. His lectures are based on the positive impact such a combined treatment approach has had on his orthodontic results and the benefits this philosophy provides from a practice management perspective. Dr Mahony is a contributing editor to the *Journal of Clinical Paediatric Dentistry*, *International Orthodontic Journal* and *Spanish Journal of Dentofacial Orthopaedics*. He can be contacted at info@derekmahony.com.

My marketing plan

Author_Dr James Goolnik, UK

_2012: are you staring into the abyss? Have you a thought out a plan for how you are going to continue growing your business? Are you going to continue doing what you do and see diminishing returns in our struggling economy or wing it and take up opportunities as they present themselves?

I would suggest you formulate your vision for three years from now. Include every area: team, marketing, sales, operations, customer service, finance, etc.

You need to imagine that you are walking into your practice three years from now. What do you see? What are patients saying about your practice? What is the team talking about in the staff

room? What does your day look like? What treatments are you carrying out? What are your plans for the evening? Think about it NOW and WRITE it down. Studies repeatedly show that writing your thoughts down and then sharing them with your close friends make them more likely to happen. It makes you accountable.

Your vision document will probably fill three pages. Re-read and refine it. Once you are happy with it, share it with your team. It will help them understand their role and whether this is the sort of practice they would love to be associated with. Once you have your plans, don't just bury them away in your desk. Take them out at least every month and read them out loud. Do they still excite you? Perhaps you have changed your mind. Tweak and revisit this picture regularly.

_Marketing first steps

Before you formulate an expensive plan of how you are going to populate your daybook with loads of new patients, ask yourself: Do you know what sort of patients you want to treat? Do you know why your current patients come and see you? What is your ideal patient?

Everyone has a different idea of what makes a patient ideal; some characteristics are non-negotiable, like 'pays their bills on time'; some may not be important to you, like 'smells nice'. For me, the ideal patient:

- _ is punctual and informs you if he or she is running late;
- _ pays bills on time without hassle;
- _ is a raving fan (enjoys being in your practice and refers others, who also become raving fans)—some practices never need to do any marketing; the raving fans do it for them;
- _ respects you and other team members—often they are respectful to the clinical team but not to the office staff;
- _ listens to your clinical advice and then makes an informed decision;
- _ attends all maintenance and hygiene appointments as prescribed; and

**State-of-the-art Dentistry
in the heart of London**



INVESTOR IN PEOPLE

Have you ever been concerned about your breath or the colour, position or shape of your teeth?

Have you ever held back from speaking or smiling fully in professional or social situations and been less than 100% self-confident as a result?

At Bow Lane Dental Group we go beyond the obvious, not just helping our patients to create and maintain their dental health but also teaming up with them to bring a beautiful smile into their lives.

When you visit us, we ask you about your dental history, listen to your concerns and work with you to define and agree a plan of action that makes sense for you.

Feel confident with a Bow Lane Signature Smile™.

To contact us visit www.bowlanedental.com

Tel. 020 7236 3600
Bow Lane Dental Group 2a Bow Lane London EC4M 9EE

Fig. 1

smells nice and knows which end of a toothbrush to use and actually uses it!

Just ask your existing patient base and as you slowly weed out the subprime ones you will eventually be left with a majority of ideal patients. Among these, there will be some who fit all the criteria but only attend when they have a mini-crisis. They are to all intents and purposes ideal because when they visit you they follow all your advice and become healthy again, although they usually disappear into the ether until another mini-crisis looms.

Many clinicians find asking for referrals quite stressful and wonder what to do if the patient refuses. I have never had this happen, probably thanks to a technique I have developed. It needs a bit of practice, but the following line (your version of it) tends to work, especially if it is delivered after a course of treatment:

"You know what, Mrs Graham, I have really enjoyed taking care of you over the last few weeks. Our practice grows by recommendations from people like you. If you know any family members, friends or colleagues who need treatment I would love to take care of their dental needs. Here are a couple of my business cards."

I would empower all of the clinical team to have this conversation at the end of a course of treatment before the patient goes back into the re-care system. I also believe in the use of referral cards (Fig. 1). These should encompass the ethos of your practice and establish an emotional connection to what you believe in.

What do you do when they contact you?

Often the first contact is asking for prices. It is impossible for you to know whether such prospective patients are just fishing around to compare prices and that is the way they judge dental services. Perhaps that is the only way they know to judge dentistry and it is your opportunity to educate them that dentistry is not chosen on price alone. Does your team just reply back to them, do they try to call them and encourage them to visit your practice? Often the team replies to an e-mail, doesn't get a response and then deletes the e-mail. What would your results be if you tried again a day later to contact them?

If still no joy, perhaps contact them again in a week. "You recently contacted us and we have

BOW LANE DENTAL GROUP

Dentistry AWARDS

Click the LIKE button to receive EXCLUSIVE special offers from our award winning London dental practice.

- ✓ Savings on dental hygienist and fresh breath treatments
- ✓ Offers on teeth whitening using Zoom Advanced Power
- ✓ Discounts off teeth straightening with Invisalign and the Inman Aligner
- ✓ Group deals on cosmetic dentistry, smile makeovers and dental implants

LONDON DENTAL PRACTICE OF THE YEAR - Bow Lane Dental Group

Dentistry AWARDS 2006

Fig. 2

been unable to get in touch. I was just seeing whether your dental needs have already been taken care of. If not, we would love to have the opportunity to show you how Bow Lane is different from other practices. Please get back in contact and we look forward to welcoming you to our practice." I would then file their contact details and perhaps if they had asked about a specific service, say Invisalign, then make contact again when you have an offer or new information on that particular service.

Online presence

You don't need an award-winning website, but can the type of patients you are trying to attract find you online? When they find you, is what they see attractive, giving them confidence in contacting you? Do you have many different ways for them to contact you?

I have noticed recently more new patients contacting me via Facebook or Twitter. I think this is because dentists can seem inapproachable and hidden behind the reception team. They tend to ask a simple question and the conversation grows from that. I am in the middle of a €6,000 treatment plan on a patient from Vienna. He found me



Fig. 3

through Facebook and there were 24 e-mails over a two-month period until he started treatment. How easy is it for a patient to have a conversation with you (Fig. 2)?

Why should a patient be friends with your practice on Facebook or Twitter? People like to



Fig. 4

feel part of something, a community. People like to talk, share stories and get access to unique information, whether it is hearing about something first or getting deals. Think about the newsletters you subscribe to, the people you follow on Twitter, etc. If they are always trying to sell something, you quickly get bored or find them inauthentic.

No matter what the technology you are using is, it is about a quality interaction with like-minded people. I get concerned when people get all excited about the latest thing, for example QR (quick response) codes (Fig. 3). It does not stop you communicating with that person any differently; it is just a fast way of them accessing information. Don't just jump on the next bandwagon; get your team interacting in an authentic and engaging way FIRST. The only way you can do this is to hire the right people and then it's over to good leadership and training.

Are the different ways of contacting you clearly visible? Gone are the days when dentists were stuck in ivory towers. The consumer is well informed and their attitude to discounts and deals is really changing.

Now not just about saving money: it's the excitement, the chase of the best deal. Groupon has opened consumers eyes. I definitely don't recommend that a dental practice start advertising on these sites; some practices nearly went bankrupt when they did.

MORE FOR LESS: While many people may have less money to spend right now, consumers everywhere will forever look to experience more. What is your customer experience?

THE MEDIUM IS THE MOTIVATION: Consumers are now being alerted to offers and deals via new (and therefore infinitely more exciting and attractive) technologies.

BEST OF THE BEST: With instant mobile or online access to not only deals but also reviews, consumers can now be confident they're getting the best price for the best product or service. What does your Google review say?

And next? An even bigger 'deal ecosystem', more personalisation, more loyalty schemes, more pressure on you to deliver deal-immune brilliance as an integral part of your dental care.

Brush strokes:

- _ Look at ALL your marketing materials and practice stationery. Is it all on brand?
- _ Take a look at your Google reviews.
- _ Take a look at your website on mobile devices like the Blackberry, iPhone and iPad.
- _ Why should a patient follow you on social media?

There has never been a better time to be in dentistry. But what does the future hold?_

_ about the author

cosmetic
dentistry



Dr James Goolnik is founder of the Bow Lane Dental Group in London, England. It was voted London practice of the year in 2006. Dr Goolnik is immediate past-president of the British Academy of Cosmetic Dentistry and serves on the Board of the British Dental Bleaching Society. He has produced the world's first dental practice iPhone app. He recently launched the *Heart Your Smile* campaign (Fig. 4), an inspirational movement for changing the public's perception of UK dentistry. Dr Goolnik is a key opinion leader and was voted the most influential person in UK Dentistry in 2011. He is the author of *Brush: Proven strategies to make you and your dental business shine*, which can be purchased via his website www.jamesgoolnik.com or www.amazon.com. All the profits go to building a dental clinic in Cambodia.

FDI World Dental Federation

Leading the World to Optimal Oral Health

2012 Hong Kong

FDI Annual World Dental Congress

29 August - 1 September 2012

Join us in Hong Kong, world capital of oral health 2012

for a

- unique global perspective in dentistry and oral health
- face-to-face encounters with your peers worldwide
- range of views from the international experts
- pick of the latest news of groundbreaking dental research
- joint celebration of the 100th FDI Annual World Dental Congress

with featured

top-flight national, regional and international speakers to address the most important challenges and issues in dental practice, enabling dentists and dental teams to transfer cutting edge knowledge into their daily clinical work and management of their practices.

in a

- meeting point of the ancient and the innovative
- world-class focal point of trade, business and technology
- vibrant and bustling city of cultural diversity
- centre of tourism and leisure

and showcasing

the latest technology and equipment development from leading international companies at the world dental exhibition

29 August to 1 September 2012

Hong Kong Convention and Exhibition Centre
Hong Kong, S.A.R. China

Deadline for abstract submission: 30 March 2012
Early Bird registration until 31 May 2012



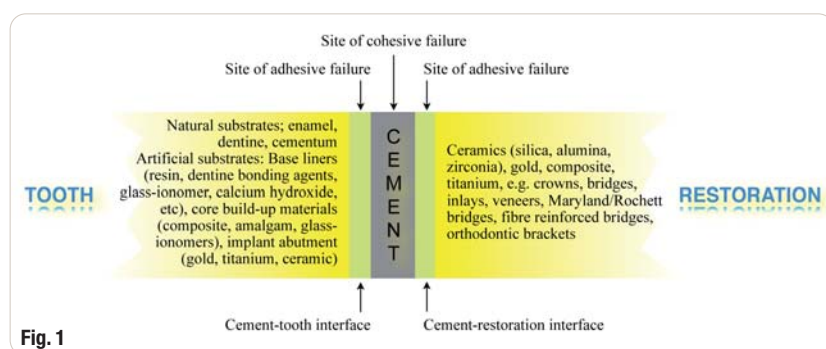
Leading the world into a new century of oral health

www.fdicongress.org

congress@fdiworldental.org

RED bonding: Predictable cementation of indirect aesthetic restorations

Author_ Dr Irfan Ahmad, UK



This is applicable to both direct and indirect aesthetic restorations.

Bonding to enamel is an established protocol, but bonding to dentine has proved more challenging and undergone considerable changes. However, the majority of current dentine bonding agents (DBA) is capable of efficacious bonding to dentine, but the method for achieving this goal is still debatable. Some authorities advocate self-etch DBA, while others prefer a total-etch approach, and further research will no doubt elucidate the validity of these methods.

Fig. 1 Cementation mechanism: two interfaces are created between the tooth and restoration—cement–tooth interface and cement–restoration interface.

Most contemporary aesthetic dental treatment relies on resin-based aesthetic dentistry (RED). The essence of RED is achieving an efficacious bond to natural tooth substrate, be it enamel or dentine, for a long-lasting restoration.

Irrespective of the technique used, RED bonding is a quintessential requirement for success and durability of aesthetic dental restorations. It

Formulation	Varieties	Advantages	Disadvantages	Cementation mechanism:	
				Cement–tooth interface	Cement–restoration interface
RMGI Polyalkenoic acid with addition of a methacrylate component (e.g. HEMA) and fillers	Pre-capsulated, chemical and light-cured	Adhesion to dentine, thin film thickness, antimicrobial, fluoride releasing, low solubility, adheres to moist tooth substrate, reduced chemical trauma to pulp	Mechanically weaker than resins, significant post-cementation dimensional changes may fracture weak ceramics	Chemical adhesion	Mechanical interlocking
CR Polymer infiltrated with filler particles	Chemical, light- and dual-cured, low and high viscosities, shade tints to modify colour	High compressive strength, superior optical properties	Technique sensitive, hydrolytic degradation, shade shift over time, possible post-op sensitivity with poor technique	Micromechanical adhesion and/or chemical adhesion	Chemical adhesion
AR Polymer infiltrated with filler particles with the addition of an adhesive functional phosphate monomer (e.g. MPD)	Dual-cured, self-etch, self-adhesive, antibacterial, fluoride releasing	High compressive strength, superior optical properties, chemical bonding to cast-metal, alumina and zirconia substructures	Technique sensitive, hydrolytic degradation, shade shift over time, lower bond strength compared with CR, reduced post-op sensitivity compared with CR	Micromechanical adhesion and/or chemical adhesion	Chemical adhesion

Table 1

Type of restoration	Restorative material	Ideal cement	Possible cement
Cast-metal crowns and inlays, intra-radicular posts, PFM crowns and FPDs (bridges)	High gold and semi-precious alloys	AR, RMGI	ZP, PC, CR
Maryland/Rochette bridges and splints	Semi-precious alloys	AR	CRD
Fibre-reinforced composite bridges and splints	Composite, fibre	AR	CRD
Light-transmitting intra-radicular posts	Fibre, zirconia	AR	CRD
Orthodontic fixed brackets	Metal alloy	AR	CRD
Inlays and onlays	Composite or silica-based ceramic	AR	CRD
PLVs (feldspathic)	Silica-based ceramics	CRL	AR
All-ceramic crowns, e.g. feldspathic, leucite-reinforced pressed glass, lithium disilicate	silica-based ceramics	AR, CRD	RMGI
All-ceramic crowns and FPDs of glass-infiltrated alumina, densely sintered alumina, zirconia substructures	Alumina- and zirconia-based ceramics	AR, RMGI	
Implant-supported crowns or FPDs	PFM, or alumina- and zirconia-based ceramics	AR, RMGI	ZOE

Key
 AR: adhesive resin; CR: conventional resin; CRL: conventional resin, light-cured; CRD: conventional resin, dual-cured; FPD: fixed partial denture; PC: polycarboxylate; PLV: porcelain laminate veneer; RMGI: resin-modified glass ionomer; ZOE: zinc/oxide eugenol; ZP: zinc phosphate.

Table II

is worth noting that 50 % of clinical performance of dental cements is influenced by operator variables,¹ including an exacting clinical technique together with mixing, dispensing and loading the cement. The remaining risk factors are tooth preparation design (ideal 12° convergence angle for adequate resistance form), material properties, location of tooth in the mouth and patient factors, such as oral hygiene.

_ Interfaces

The primary function of dental cement is retaining an indirect restoration on an intra-oral abutment, which can be natural tooth substrate or an artificial restorative material. The mechanisms by which cements achieve retention can broadly be termed "luting" or "bonding". Luting is non-adhesive retention, and bonding implies a closer attachment of the cement to the restoration and tooth, which includes micromechanical and chemical adhesion.

The cementation mechanism of cements is classified as:

1. non-adhesive or mechanical interlocking retention by engaging tooth surface and restoration intaglio surface irregularities, measuring 20 to 100 µm (this mechanism is applicable to all dental cements);
2. micromechanical "adhesion" by engaging finer surface irregularities <2 µm created by etching,

- air abrasion, and usually in combination with a DBA by formation of a hybrid layer (0.5 to 10 µm);
3. chemical (molecular) adhesion by bipolar, Van der Waals forces and chemical bonds, which is the ideal that contemporary cements strive to achieve.

In order to understand the cementation mechanism, two interfaces between the cement and the tooth/restoration complex require consideration. On the tooth side, the substrate is dentine, enamel or cementum, and this is called the "cement-tooth interface". On the opposing side is the artificial restoration, termed the "cement-restoration interface" (Fig. 1). Some cements of-

Table I Properties of contemporary permanent dental cements and luting mechanisms at cement-tooth and cement-restoration interfaces.
Table II Choice of cement depending on type of restoration and restorative material.

Table III Retentive and non-retentive restorations.

Type of restoration	Intra-coronal	Extra-coronal
Inlay	Non-retentive	
Onlay		Non-retentive
PLV		Non-retentive
Maryland/Rochette bridges and splints		Non-retentive
Fibre-reinforced composite bridges and splints		Non-retentive
Orthodontic brackets		Non-retentive
Full-coverage crown		Retentive
FPD		Retentive
Implant-supported crowns and FPD		Retentive

Table III

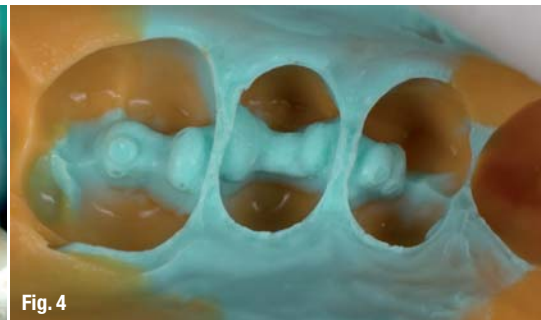
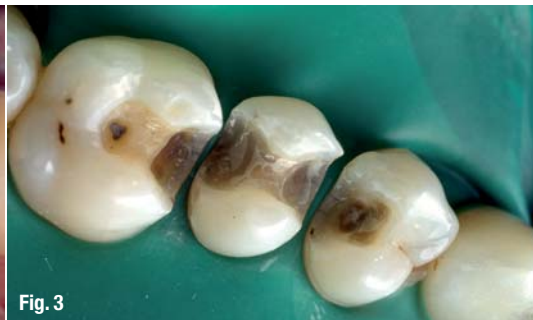
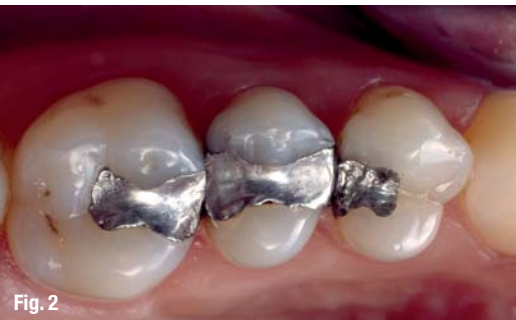
Fig. 2

Fig. 3

Fig. 4

Fig. 2 Defective amalgam restorations requiring replacement.

Fig. 3 After removing the amalgam fillings, no attempt is made to extend the cavity to create undercuts, thereby maintaining the structural integrity of the tooth. Also, soft carious dentine is excavated, but hard, discoloured infected dentine is left *in situ* to preserve tooth substrate.

Fig. 4 An impression is taken for fabricating indirect ceramic inlays.

fer chemical adhesion at both interfaces. However, a vast number of interfaces are possible depending on the substrate on the tooth and restoration sides. These interfaces are the weakest link and account for adhesive failure. Cohesive failure is the breakdown of the cement or fracture of the tooth or the restoration.

A tight and secure seal is essential for preventing micro-leakage between the concealed interfaces beneath the bulk of the restoration and at the "open" margins exposed to the oral cavity. Furthermore, exposed margins are also vulnerable to occlusal stresses transmitted from the coronal part of the restoration to the cervical aspect, and the cement should be resilient to these forces in order to maintain a long-lasting hermetic seal.

Contemporary cements

At present, there is no single cement that can ubiquitously be used for all indirect restorations. The choice of cement depends on the type of restoration, the restorative material and prevailing clinical scenarios. Judicial selection is imperative for efficacious cementation and longevity of a prosthesis. Contemporary permanent cements for definitive restorations are broadly categorised as resin-modified glass ionomers (RMGI) and resins (Table I). The latter are further divided into conventional resins (CR) and adhesive resins (AR).² True AR are only those that contain the monomers MDP (10-methacryloyloxydecyl dihydrogen phosphate) or 4-META (methacryloxyethyl trimellitate anhydride),^{3,4} e.g. Maxcem Elite

(Kerr), RelyX Unicem (3M ESPE), and Panavia 21, Panavia F2.0, Clearfil SA (Kuraray Dental).

Selecting a permanent cement

The choice of cement for an indirect prosthesis depends on the type of restoration, the restorative material from which the restoration is made, and the clinical situation. (Table II summarises the ideal choice of cement depending on the type of restoration and restorative material.)

Type of restoration

Indirect restorations are categorised as intra-coronal or extra-coronal. In addition, the restoration can be retentive or non-retentive (Table III). Retentive restorations gain retention and resistance from of the geometry of the tooth preparation (e.g. crown preparation), and therefore adhesive cementation is not obligatory. Consequently, these restorations can be luted with traditional cements such as zinc phosphate or glass-ionomer varieties, which are less technique sensitive. Conversely, non-retentive restorations have limited retentive tooth preparation features and are predominantly, or totally, reliant on RED bonding to the tooth substrate, e.g. Maryland/Rochette, fibre-reinforced fixed partial dentures (FPD), porcelain laminate veneers (PLV) and inlays/onlays.

This paradigm shift from retentive to non-retentive restorations has been possible owing to advances in dental material technology and adhesive clinical techniques, placing a greater

Fig. 5 Plaster cast showing undercuts in the cavity preparations, which will eventually be filled with the permanent resin-based cement.

Fig. 6 The cavity undercuts are blocked on the plaster cast to facilitate fabrication of the ceramic inlays.

Fig. 7 Post-cementation of ceramic inlays with a resin-based cement.

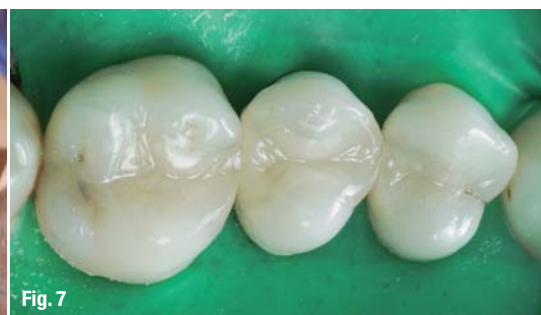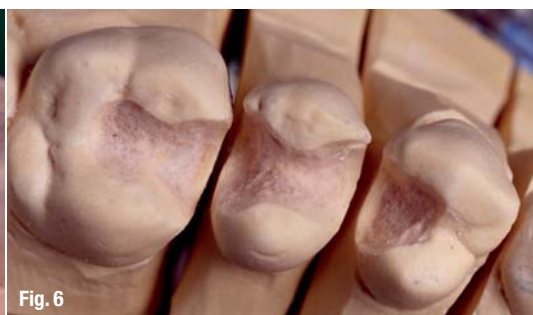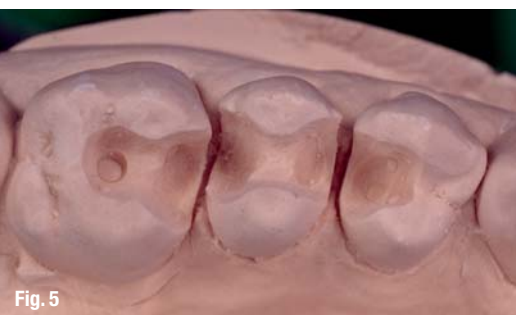


Fig. 5

Fig. 6

Fig. 7

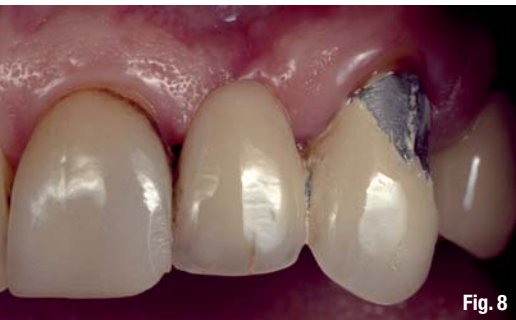

Fig. 8



Fig. 9




Fig. 10

emphasis on preserving natural tooth substrate. Whereas in the past, preparation design was geometric and extensive (dictated by the properties of the restorative material), it is now amorphous and minimalist (dictated by the extent of disease; Figs. 2–7).

Aesthetic restorations

Essentially, any restoration that achieves health and function can also be aesthetic. However, the term “aesthetic restorations” usually refers to tooth-coloured restorations or prostheses. Aesthetic restorations can be direct, using resin-based composites, or indirect, fabricated exclusively from a single ceramic material or with a strong substructure (ceramic or metal) that is subsequently veneered with a weaker overlying porcelain. This is the basis for the extremely successful porcelain-fused-to-metal (PFM) crowns and FPD.

The major disadvantage of PFM restorations is poor aesthetics at the cervical margins, presenting as greying owing to visibility of the metal substructure or “shine through” thin periodontal biotype gingivae. Therefore, a concerted effort has been made to seek alternatives, using dense, high strength ceramic cores to support aesthetic weaker porcelains. Although ceramics are capable of mimicking the appearance of natural teeth, they are plagued with fracturing in an aqueous and dynamic oral environment. Water imbibitions and occlusal stresses propagate crack formation of any exposed surface irregularities within the ceramic, leading to chipping or catastrophic frac-

tures. Furthermore, even if the surface is highly polished or glazed, the tenet for using ceramics in the oral cavity is that they must be supported by either the natural tooth substrate or an underlying high strength substructure.

Ceramics are inherently brittle materials (high modulus of elasticity) and therefore susceptible to fractures. Microscopic imperfections within the material are termed “Griffith flaws”, which grow into cracks and, if unimpeded, lead to catastrophic fracture of the ceramic. The cracks are propagated by the hostile oral environment: dynamics (occlusal forces) and humidity (stress corrosion). Furthermore, static fatigue is time dependent, which eventually results in breakage (Fig. 8).

Many strengthening mechanisms are used for halting fracture propagation, including reinforcement and infiltration with glasses, and phase transformation toughening. Preventing fractures also depends on the clinical scenario, method of fabrication of the restoration, and the manufacturing technique and strengthening process of the ceramic.

In order for ceramics to survive in the oral cavity, they must be supported by either the natural tooth substrate or a substructure. Two types of ceramic restorations are possible: first, a uni-layer restoration that is entirely composed of a single ceramic, gaining support through an adhesive bond to the underlying tooth substrate; and, second, a bi-layer restoration that has a supporting substructure for the aesthetic veneering

Fig. 8 Delamination of the veneering porcelain on the distal abutment of a FPD.

Fig. 9 Plaster cast of tooth preparations for a full-coverage crown.

Fig. 10 Uni-layer restorations are entirely fabricated of a single ceramic, and gain support from the underlying tooth.

Fig. 11 Bi-layer restorations are fabricated from a dense core (metal or ceramic), which supports an overlying aesthetic veneering porcelain.

Fig. 12 All-ceramic crowns fabricated from silica-based ceramics, which are the most aesthetic type of indirect restorations.

Fig. 13 Porcelain laminate veneers are delicate restorations requiring careful handling to prevent inadvertent breakage during the cementation procedure.



Fig. 11


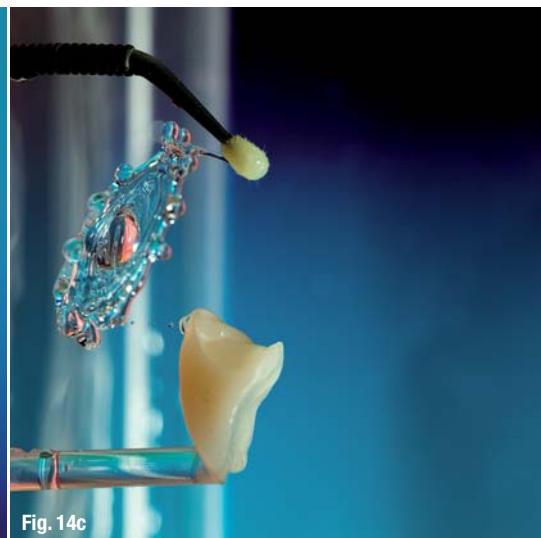
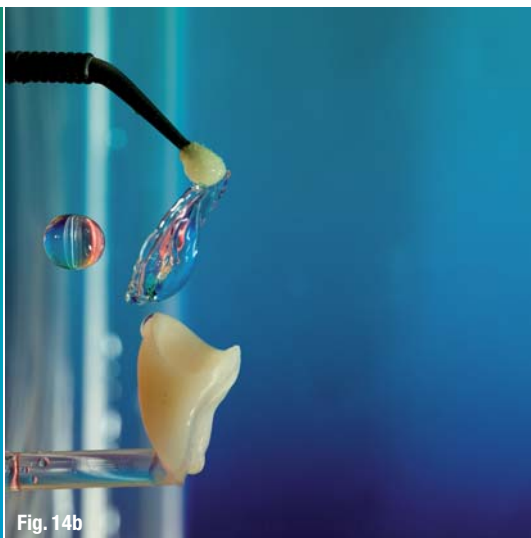


Fig. 12



Fig. 13



Figs. 14a–c Applying a silane-coupling agent onto the fitting surface of a silica-based ceramic restoration forms silica–silane bonds, resulting in chemical adhesion at the cement–restoration interface.

Fig. 15 Poor enamel-etching pattern with a seventh-generation DBA.

Fig. 16 Profound enamel-etching pattern with OptiBond XTR.

Figs. 17a & b OptiBond XTR has deeper penetration into the dentine tubules with a reduced film thickness of only 5 µm, compared with 35 µm of other self-etch bonding agents.

porcelain (Figs. 9–11). This substructure can be either metal or a dense, high strength ceramic core, and these restorations can be either bonded with a resin cement or luted with RMGI.⁵

Dental ceramics can arbitrarily be categorised as silica, alumina or zirconia based. Silica-based materials are weaker materials with a high glass content and excellent optical properties, making them the most aesthetic type of ceramic, e.g. feldspathic, leucite-reinforced, lithium disilicate and synthetic porcelains (Fig. 12). Alumina and zirconia have reduced glass content, reduced translucency and poorer light transmission, making them less aesthetic but offering greater

strength, e.g. alumina (flexural strength of 700 MPa) and zirconia (flexural strength of >1000 MPa). However, owing to their hardness and inferior optical properties, uni-layered alumina and zirconia restorations are impractical. Hence, these high strength ceramics are ideal for bi-layer prostheses, acting as an underlying dense core for supporting weaker silica-based aesthetic porcelains for both single and multiple-unit FPDs.





Clinical scenario

The final aspect that determines the choice of cement is the clinical scenario. If the resistance and retention form of the tooth abutment is less than the ideal of 6° axial tapers (12° convergence angle), a resin cement is a prudent choice for reinforcing and improving the fracture strength of the abutment/cement/restoration complex.⁶ Similarly, when a remake of a restoration with poor marginal integrity is not immediately possible, it may be possible to seal open margins using resin cements.

Finally, if a dry environment is challenging, e.g. deep sub-gingival margins, RMGI is a better choice since it is less sensitive to moisture.

Bonding indirect aesthetic restorations

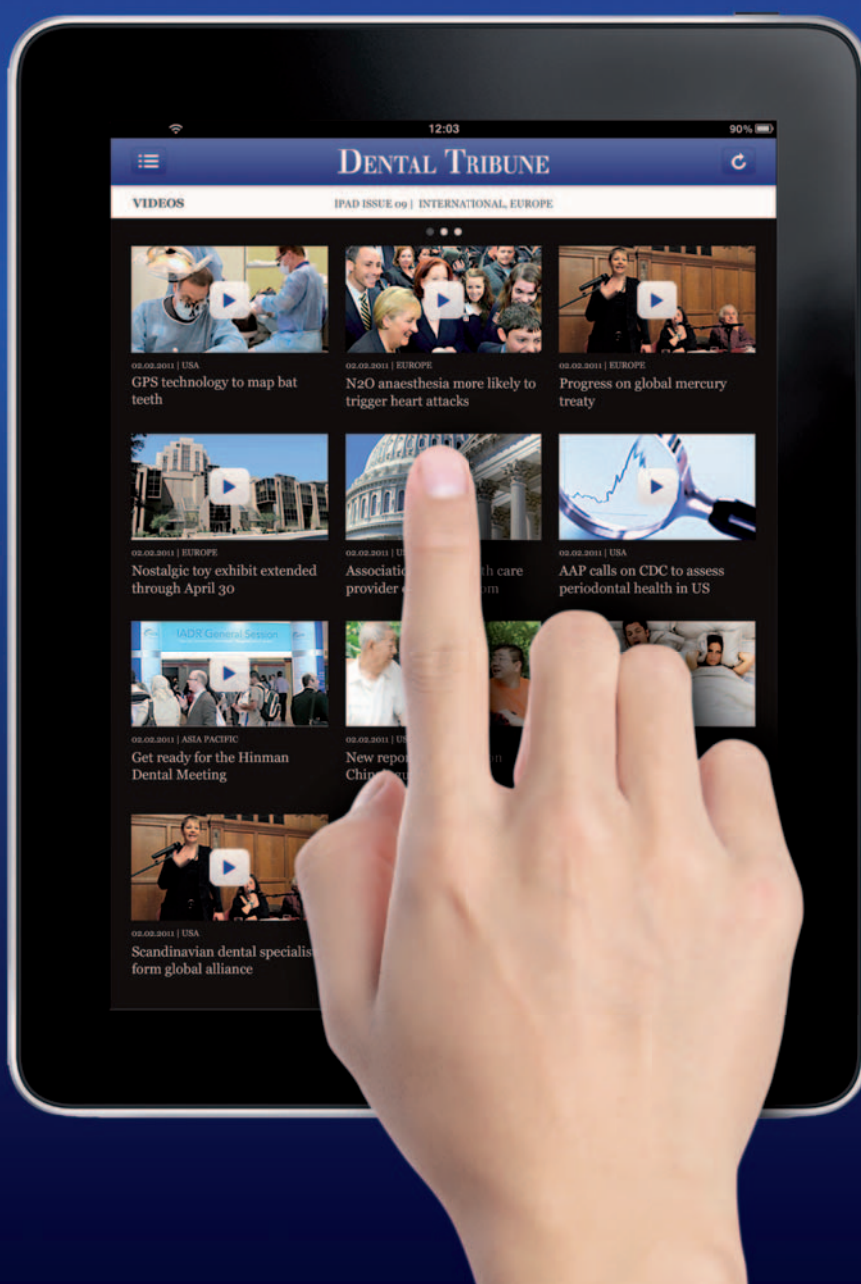RED bonding indirect aesthetic restorations is demanding and technique sensitive. Failure to follow meticulous clinical protocols,




Dental Tribune for iPad – Your weekly news selection

Our editors select the best articles and videos from around the world for you every week. Create your personal edition in your preferred language.

ipad.dental-tribune.com





Figs. 18a–c_OptiBond XTR incorporates an adhesive monomer and is copiously applied to the fitting surfaces of ceramic restorations, achieving chemical adhesion at the cement–restoration interface.

or using inappropriate materials, is a recipe for disaster. Furthermore, aesthetic restorations are unique because they are often non-retentive, thin, delicate and fragile, requiring careful manipulation to prevent breakage during the cementation procedure (Fig. 13).

Choice of cement

The choice of permanent cement for definitive aesthetic restorations is either RMGI or resin. Although RMGIs offer chemical adhesion to dentine, they are unsuitable for aesthetic restorations owing to poor mechanical properties, inferior optical properties (profound opacity), making translucent silica-based ceramics appear dull, and a limited selection of shades, making accurate shade matching difficult. Furthermore, RMGIs undergo significant post-cementation dimensional changes that may fracture weaker uni-layer ceramic restorations.⁷ Therefore, the ideal cement for aesthetic restorations is a resin, which has superior mechanical, optical and physical properties (Table I). In addition, newer resin cements also offer low film thicknesses of 8 to 21 μm ,⁸ comparable with that of RMGI, resulting in reduced micro-leakage.⁹ The disadvantages of resins are hydrolytic degradation, chromatic instability over time, post-operative sensitivity

and requiring adherence to a stringent adhesive technique.

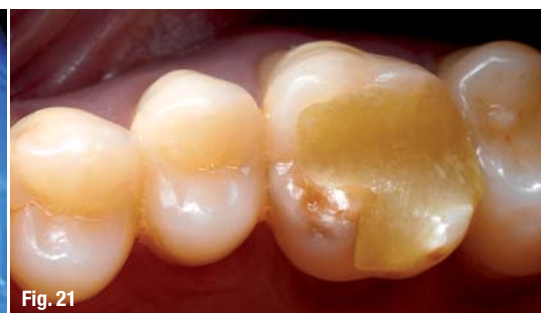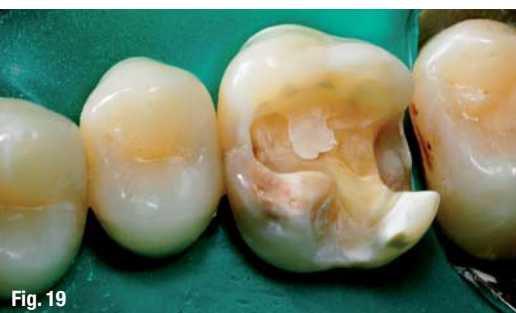The next decision is choosing between AR and CR cement. The AR variety of resin cements is inappropriate for aesthetic restoration cementation owing to their limited shade availability and because the uncontrollable working time of dual-cure setting causes difficulty cleaning excess set cement. Besides, many aesthetic restorations require minimal preparation and are usually finished within enamel. Since self-etch ARs do not require separate enamel etching with 37% phosphoric acid, the higher pH primer in AR may not create an adequate enamel-etching pattern for efficacious bonding.¹⁰ For these reasons, a CR is therefore the ideal choice of cement for bonding tooth-coloured aesthetic restorations.

The CR cements are recommended for uni-layered, non-retentive, silica-based ceramics (lower flexural strength of 100 to 300 MPa), offering increased translucency, assuming the underlying tooth substrate is an acceptable colour. These ceramics are amenable to etching with hydrofluoric acid (HF) for enhanced mechanical retention, and when treated with silane (Figs. 14a–c) create silica–silane chemical bonds at the cement–restoration interface. However, CR must

Fig. 19_Cavity preparation for an inlay on the maxillary first molar.

Fig. 20_Impression of inlay cavity using an addition silicone impression material.

Fig. 21_Temporary restoration *in situ*.



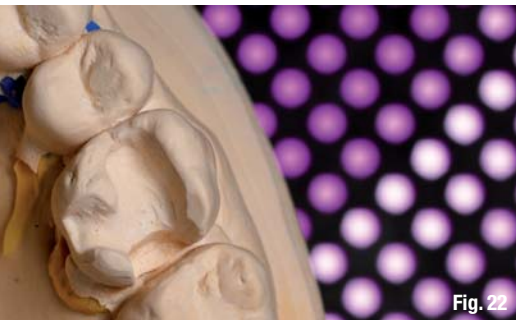

Fig. 22

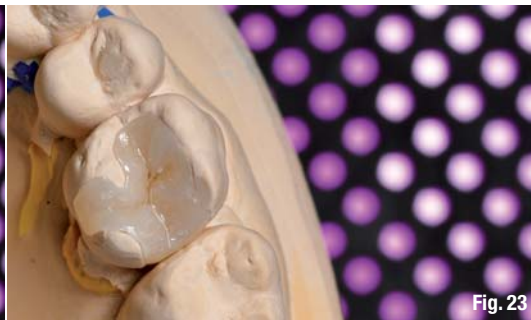

Fig. 23

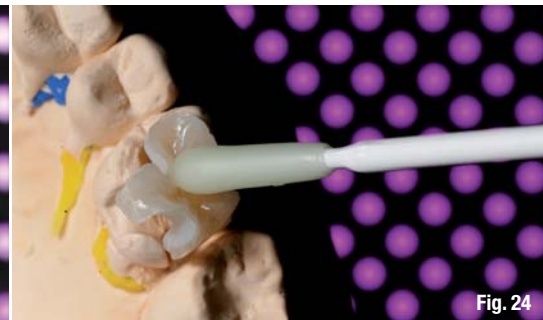


Fig. 24

be used in combination with a separate DBA, either a total-etch or self-etch system. Conventional resins have numerous shades and try-in pastes for precise shade matching. In addition, light-cured CR can be used for restorations with thicknesses of 1.5 to 2 mm or thinner and dual-cured CR for thicknesses of >2 mm or opaque cores, thereby increasing their versatility and clinical applications.

NX3 Nexus (Kerr) is a CR cement available in a large selection of tooth-coloured shades, enabling accurate shade matching. Its try-in pastes precisely correspond to the definitive cement shades, allowing colour assessment and alteration before final cementation. The defining features of NX3 are chromatic stability over time and compatibility with most seventh-generation DBAs.

A major concern with resin cements, especially associated with dual-cured resin cements, is ageing colour shift causing unsightly yellowing below translucent, aesthetic restorations. This is attributed to the amine-initiated setting reaction of the luting agents. To mitigate the latter, NX3 Nexus incorporates an amine-free redox initiator system that guarantees chromatic stability over time.

It is also essential that the CR and DBA be compatible with each other. Compatibility is particularly an issue with self-etch DBA agents owing to the residual acidic inhibition layer that retards or impedes setting of dual- or dark-cured resin cements. NX3 has excellent bond compatibility

with seventh-generation total-etch and self-etch DBA without requiring an activator for dual-cured adhesives. This simplifies clinical protocols and ensures predictable bonding at the cement-tooth interface, and in combination with a DBA has a shear bond strength (SBS) of approximately 34 MPa for dentine and 30 MPa for enamel. At the cement-restoration interface, NX3 chemically adheres to most restorative materials, including resin-based composites, porcelain CAD/CAM blocks, alumina, zirconia and cast metal, achieving a maximum SBS of over 30 MPa. Finally, NX3 offers the choice of light or dual curing, allowing restorations with reduced light penetration, i.e. thicker than 2 mm or highly opaque (e.g. alumina or zirconia cores), to be predictably cemented.

Dentine bonding agent

Achieving RED bonding with CR cements requires use of a DBA. The adhesion mechanism of resin cements and DBA at the cement-tooth interface is both micromechanical, by forming a hybrid layer, and chemical, by bonding with calcium ions from the hydroxyapatite of the tooth substrate. In order to resist the polymerisation stresses of the overlying resin cement, the bond strength of the DBA should be greater than 25 MPa.

OptiBond XTR (Kerr) is the latest self-etch, universally compatible DBA for direct and indirect restorations. The XTR is a retro-step to the sixth-generation bonding agents, eliminating many of the drawbacks of existing single-component

Fig. 22 Plaster cast of inlay cavity showing clearly defined margins.

Fig. 23 Completed silica-based ceramic inlay on plaster cast.

Fig. 24 Careful handling of the delicate inlay is essential during pre-treatment of the fitting (or intaglio) surface.

Fig. 25 Pre-treatment of intaglio surface: etching with HF acid.

Fig. 26 Pre-treatment of intaglio surface: rinsing off HF acid and drying with warm air until the surface appears frosty.

Fig. 27 Pre-treatment of intaglio surface: application of OptiBond XTR adhesive, dry, light-cure and store in a light-sealed container while the pre-treatment of the intra-oral abutment is carried out. NB: Application of silane onto the fitting surface of the porcelain is unnecessary when using OptiBond XTR.




Fig. 25

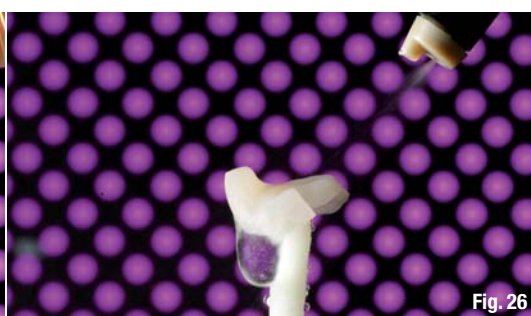


Fig. 26

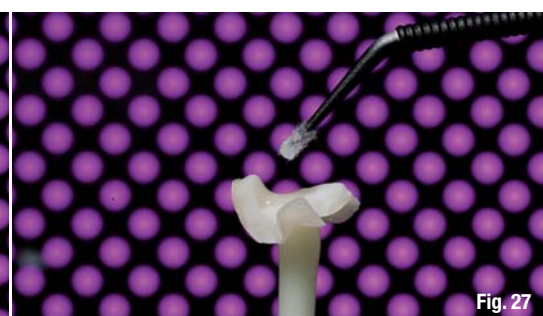


Fig. 27

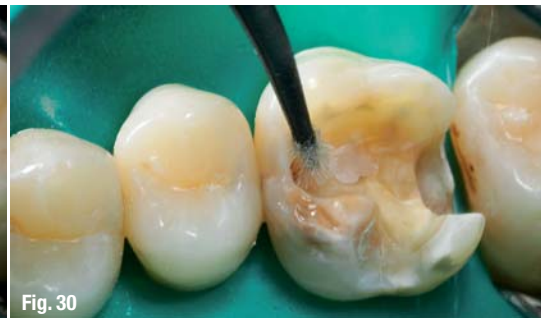
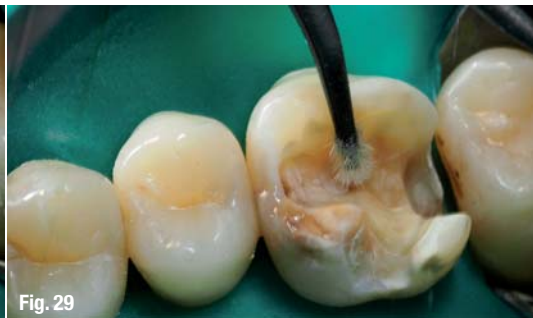
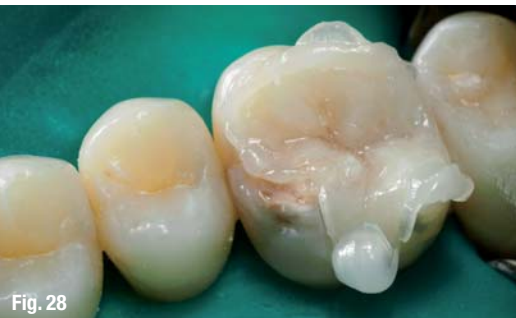Fig. 28 Pre-treatment of intra-oral abutment: isolation with rubber dam, removal of temporary dressing and thorough cleansing cavity with pumice, rinsing and drying. The inlay is seated using water-soluble NX3 try-in pastes for verifying colour and selecting the corresponding shade of the permanent cement.

Fig. 29 Pre-treatment of intra-oral abutment: OptiBond XTR primer is applied to both enamel and dentine, and continuously scrubbed for 20 seconds. This is followed by gentle drying for 5 seconds.

Fig. 30 Pre-treatment of intra-oral abutment: OptiBond XTR adhesive is lightly brushed for 15 seconds, air-dried for another 5 seconds and light-cured for 10 seconds.

Fig. 31 Cementation technique: the selected shade of light-cured NX3 is dispensed onto the inlay, or directly into the prepared cavity, avoiding introducing air.

Fig. 32 Cementation technique: after wiping away excess cement and ensuring patent contact points, NX3 is light-cured for 10 seconds from all aspects. All occlusal checks are carried out post-cementation to avoid damaging the ceramic beforehand. Any necessary adjustments, together with the margins are polished with OptiDiscs and Opti1 Step polishing tips (both Kerr).

seventh-generation DBAs. Compared with seventh-generation DBAs, XTR does not require selective etching of enamel margins owing to its profound etching pattern on both cut (prismatic) and uncut (aprismatic) enamel (Figs. 15 & 16) and is fully compatible with all dual- and self-cured resin-based composites and cements. It has an SBS greater than most self-etch systems of approximately 30 MPa. Another problem with self-etch DBA is inadequate penetration of the adhesive into the dentine tubules following etching, which results in post-operative sensitivity and large film thicknesses. XTR overcomes this by penetrating deeper into dentine tubules, reducing the film thickness to less than 5 µm, SBS to dentine of 37 MPa, and post-operative sensitivity (Figs. 17a & b). Finally, XTR can be used with any CR cement for bonding indirect aesthetic restorations, and in combination with Nexus NX3 achieves dentine bond strengths of nearly of 42 MPa.

Cementation protocols

As mentioned previously, nearly half of all risk factors relating to successful cementation depends on operator factors, which leaves little latitude for errors. The cementation protocol can be divided into three distinct processes: pre-treatment of the intaglio or fitting surface of the restoration, pre-treatment of the intra-oral abutment, and clinical steps for cementation.

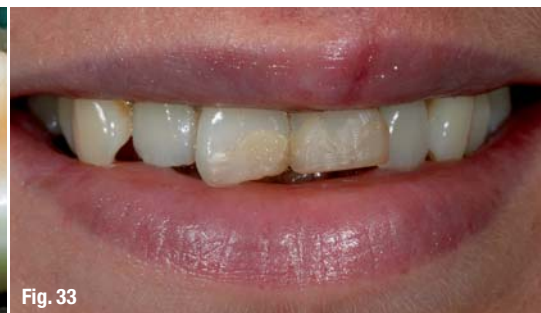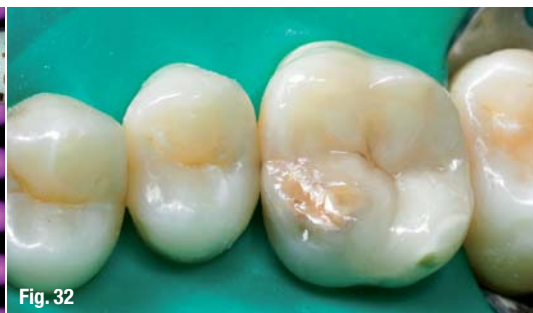1. Pre-treatment of intaglio surface

The conditioning of the intaglio surface depends on the restorative material and the choice

of cement (RMGI, CR, AR). The preferred method for silica-based restoration is chemical conditioning, using HF acid (4–10% for 3 minutes), followed by application of warm silane or DBA, which increases the SBS between ceramics and the dentine substrate at the cement–restoration interface.¹¹ However, prolonged etching with HF acid can excessively dissolve the glass filler particles in the ceramic, making the surface smooth and negating the etching process. In addition, gross alteration to glass particles also compromises the strength of the ceramic.

Hydrofluoric and phosphoric acids cannot be used to etch metal, alumina or zirconia, but may be used for cleansing to ensure a contamination-free intaglio surface. The surface roughness or micro-irregularities of high strength dense ceramics must be created during the manufacturing process. Air abrasion of zirconia and alumina fitting surfaces prior to cementation is controversial. To date, there is no long-term data to verify this practice, and air abrasion of zirconia can cause transformation change from the tetragonal to the monoclinic phase, weakening and reducing the life expectancy of the restoration.¹² Other chemical agents include alloy primers or tin plating for some casting alloys.

Another benefit of using OptiBond XTR is that the adhesive liquid contains an adhesive monomer that provides true chemical adhesion for most restorative materials at the cement–restoration interface (Figs. 18a–c). Therefore, application of silane, or other alloy primers, to the fitting surface is superfluous.



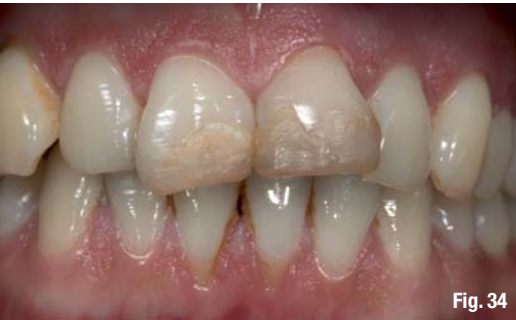

Fig. 34

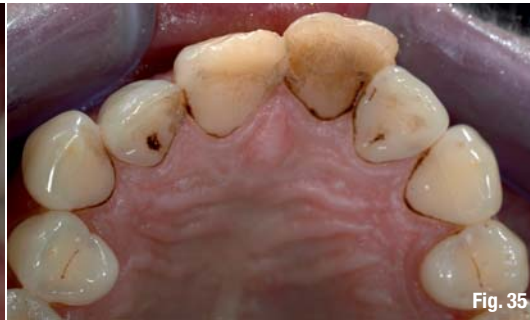

Fig. 35

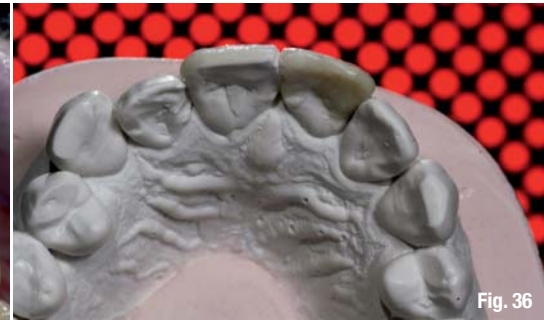

Fig. 36

2. Pre-treatment of intra-oral abutment

Pre-conditioning of the intra-oral abutment is begun by removing the temporary restoration and provisional cement, which is accomplished mechanically using hand instruments, air abrasion, pumice paste or ultrasonic devices. Complete removal of the provisional cement is essential for avoiding compromising the bond strength between the natural tooth substrate (or artificial abutment, e.g. intra-radicular post/cores or implant abutments) and the permanent cement. Higher SBSs are achieved when the temporary cement is removed with an effective dentine cleaner using a total-etch technique.¹³ Alternately, immediate dentine sealing prior to taking an impression may also enhance bond strength.¹⁴

The next stage is isolation, either with a rubber dam or intra-sulcular gingival retraction cords. A dry environment is essential for resin-based cements. A rubber dam is the ideal choice for cementing inlays in posterior teeth but may be unsuitable for anterior teeth because the retaining metal clamps can potentially traumatise the gingival margin, leading to recession, especially for anterior teeth with thin periodontal biotypes. A gingival retraction cord, dry or impregnated with an astringent, not only allows visualisation of the abutment margins, but also acts as a physical barrier to avoid excess cement entering the delicate gingival sulcus. However, the use of a retraction cord may be inappropriate around implant abutments because it may lacerate the friable epithelial attachment.

Tooth abutment pre-treatment depends on the type of cement being used. If RMGI is employed, no further conditioning is usually necessary, whether the abutment is dentine, enamel or artificial restorative material, e.g. a composite, amalgam, cast-metal and ceramic core or titanium, alumina or zirconia implant abutments. For CR cements, where the abutment is natural tooth substrate, pre-treatment involves application of a DBA, i.e. self-etch or total-etch. If an artificial abutment is present, the conditioning depends on the restorative material of the abutment, e.g. for composite and amalgam core build-ups, the pre-treatment is air abrasion followed by etching with phosphoric acid.

3. Clinical procedure

After pre-treatment of the intaglio surfaces and intra-oral abutments, the next stage is dispensing the chosen cement. One of the major factors that reduces cement strength is introduction of air into the cement, e.g. 10% porosity can reduce strength by 55%. Porosity is related to the method of mixing,¹⁵ polymerisation shrinkage during the setting reaction, and disintegration of the cement owing to fatigue and thermo-cycling. For this reason, auto-mixing dispensers and pre-capsulated cartridges are ideal for a smooth, reduced porosity mix.¹⁶

Depending on the restoration, the cement is dispensed onto either the fitting surface or intra-oral abutment, and the restoration correctly located and seated with pressure, with or without an ultrasonic insertion technique for high vis-

Fig. 33 Dento-facial view showing poor aesthetics of the maxillary central incisors.

Fig. 34 Pre-op defective, discoloured and poorly contoured resin composite fillings on the maxillary central incisors.

Fig. 35 The left central incisor is facially inclined and overlapping the lateral incisor.

Fig. 36 Diagnostic wax-up to simulate pseudo-realignment of the left central incisor so that it is in line with the maxillary arch.

Fig. 37 Transparent vacuum stent fabricated from a plaster cast of the diagnostic wax-up for intra-oral composite mock-up for gaining patient acceptance of the proposed aesthetics, and for making chairside temporary acrylic restorations.

Fig. 38 Minimally invasive PLV preparations on the central incisors finished within enamel with distinct finish lines, by a healthy periodontium.

Fig. 39 Chairside-fabricated acrylic temporary veneers using the vacuum stent of the wax-up.

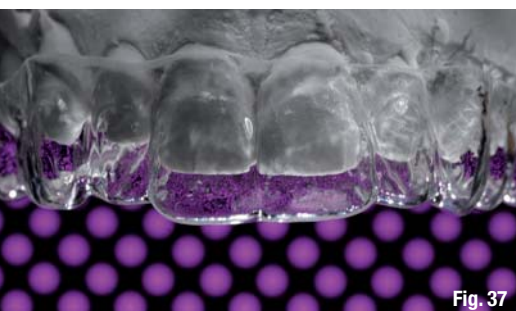


Fig. 37

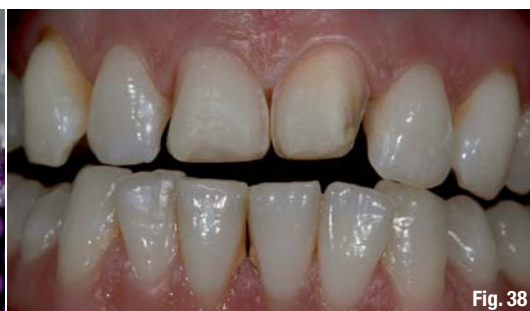

Fig. 38

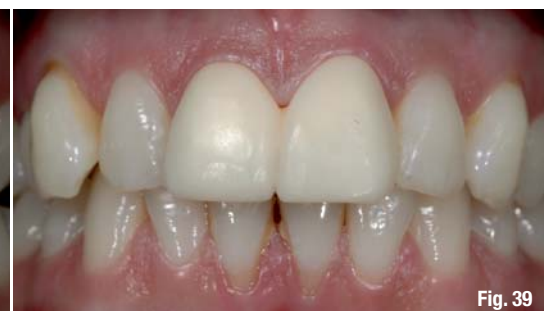

Fig. 39

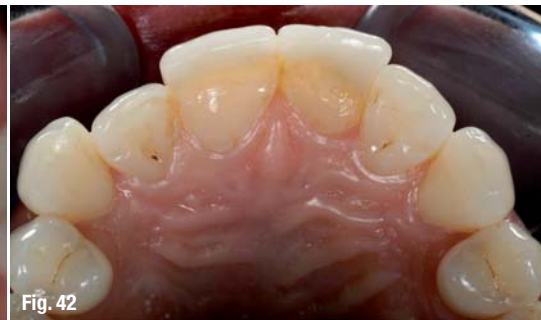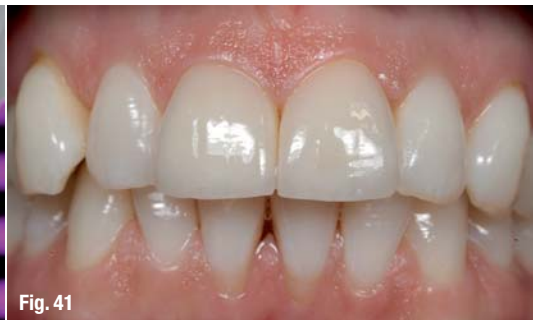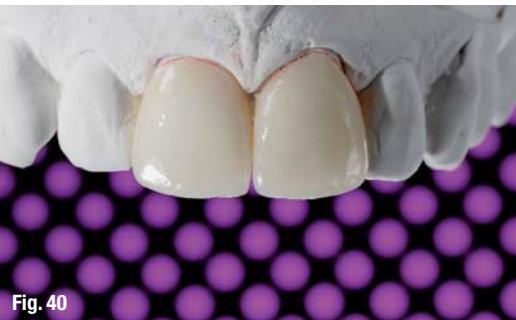


Fig. 40

Fig. 41

Fig. 42

Fig. 40 Two silica-based ceramic PLV for the central incisors.

Fig. 41 PLV cemented with a resin-based cement, showing harmonious integration with the surrounding dentition and impeccable gingival health.

Fig. 42 Post-op incisal view showing the pseudo-realignment of the left central incisor.

cosity cements. Excess cement is immediately wiped off, and floss is used to clear the interproximal areas. If a retraction cord is placed beforehand, this is now removed together with excess cement and the restoration firmly held in place during light-curing from all aspects with an appropriate light intensity and duration (20 second for halogen lights and 10 seconds for LED lights of 800 mW/cm²).

After setting, a #12 blade is used to trim set excess cement. The occlusion is checked and adjusted accordingly. Finally, minor adjustments and margins are polished with silicone tips, interproximal diamond strips, and the sulcus irrigated with chlorhexidine solution to wash out remnants of set cement and to promote gingival health.

To illustrate the above three processes of cementation, two case studies are presented in Figures 19 to 32 (cementation of a ceramic inlay) and Figures 33 to 45 (PLVs).

Conclusion

Cementation is the penultimate clinical procedure, besides review and maintenance, for the provision of indirect restorations. Fitting indirect restorations requires adherence to stringent clinical procedures for ensuring success and longevity. Achieving these objectives involves understanding the mechanism of adhesion, the

benefits and limitations of contemporary cements, and selecting the most appropriate cement depending on the type of restoration, the restorative material and the prevailing clinical situation. For aesthetic tooth-coloured restorations, the ideal choice is RED bonding with CR cements.

It is observed in the dental literature that all-ceramic restoration survival rates are now approaching those of metal-ceramic prostheses. However, providing metal-ceramic units is relatively technique insensitive, unlike all-ceramic prostheses, which are highly technique sensitive. Forgetting this basic difference in clinical practice is costly, frustrating and embarrassing, and although clinical judgement may be forgiven, the patient may not be so forgiving.

Editorial note: A complete list of references is available from the publisher.

Fig. 43 Post-op dento-facial view (compare with Fig. 33).

Fig. 44 Pre-op facial view.

Fig. 45 Post-op facial view.

Notice elimination of the left central incisor imbrication over the left lateral incisor.

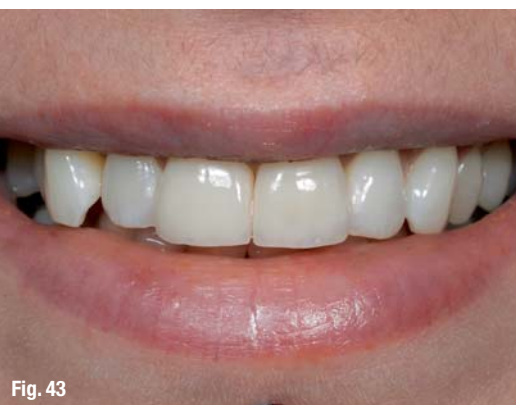

Fig. 43


Fig. 44

Fig. 45

_contact	cosmetic dentistry
<p>Dr Irfan Ahmad The Ridgeway Dental Surgery 173 The Ridgeway, North Harrow Middlesex, HA2 7DF UK</p> <p>iahmadbds@aol.com www.irfanahmadtrds.co.uk</p>	

implants

international magazine of oral implantology



You can also subscribe via
www.oemus.com/abo

 **Subscribe now!**

I hereby agree to receive a free trial subscription of **implants international magazine of oral implantology** (4 issues per year).

I would like to subscribe to **implants** for € 44 including shipping and VAT for German customers, € 46 including shipping and VAT for customers outside of Germany, unless a written cancellation is sent within 14 days of the receipt of the trial subscription. The subscription will be renewed automatically every year until a written cancellation is sent to OEMUS MEDIA AG, Holbeinstr. 29, 04229 Leipzig, Germany, six weeks prior to the renewal date.

▶ **Reply** via Fax +49 341 48474-290 to OEMUS MEDIA AG or via E-mail to grasse@oemus-media.de

One issue free of charge!

Last Name, First Name

Company

Street

ZIP/City/County

E-mail

Signature

Notice of revocation: I am able to revoke the subscription within 14 days after my order by sending a written cancellation to OEMUS MEDIA AG, Holbeinstr. 29, 04229 Leipzig, Germany.

Signature

Holbeinstr. 29, 04229 Leipzig, Germany, Tel.: +49 341 48474-0, Fax: +49 341 48474-290, E-Mail: grasse@oemus-media.de

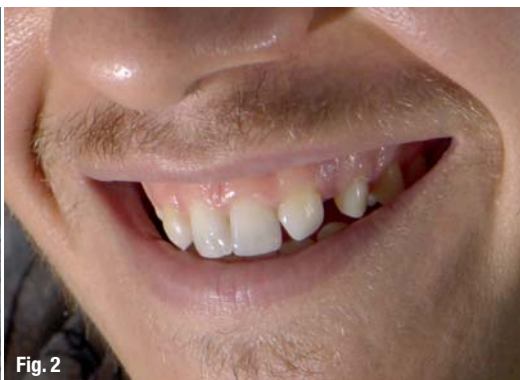
OEMUS MEDIA AG



Shining results

Minimally invasive and aesthetic restorative treatment

Authors_Dr Monica Basile & Michele Temperani, Italy



structure is paramount. For this purpose, procedures have to be planned in detail by the dental team, consisting of the dentist and dental laboratory technician.

_An uncommon preoperative situation

The 30-year-old patient was dissatisfied with his smile and requested that we correct his front teeth (Fig. 1). The problem was evident at speaking distance from the patient. The overall appearance of the dentition was marred by gaps between the teeth (diastema) and the unusual shape of the upper lateral incisors (Fig. 2). A panoramic scanning dental X-ray revealed the failed development of teeth #12 and 22 (Fig. 3). As a result, the canines had moved into the position of the lateral incisors. In the past, the appearance of both canines had been slightly adjusted to that of the incisors. Moreover, it is important to note that the dental arch featured two deciduous canines.

_What patients want

The patient let us know exactly what he wanted and did not want. Today's patients are usually knowledgeable and well informed. They clearly express their ideas and demand tailor-made solutions. This particular patient had been searching for a suitable and non-invasive treatment for quite a long time. Previous treatment plans had incorporated the removal of the two deciduous teeth and replacing them with implants. However, the patient did not agree with this solution. He wanted to keep his natural teeth until they fell out of their own accord, even though the lifespan of these teeth was limited. Until this time, however, the patient wanted to have a gap-free and even-looking anterior dentition, in other words, an attractive smile. We were unable to predict the survival rate of the deciduous teeth on the basis of the X-rays. Nevertheless, a thorough examination showed that they were still securely in place. Furthermore, there were no signs of periodontal disease. The patient was fully aware of the limited lifespan of the deciduous teeth and asked for a reversible solution in order to prevent the existing tooth structure from being permanently damaged. He wanted to make sure that further treatment in

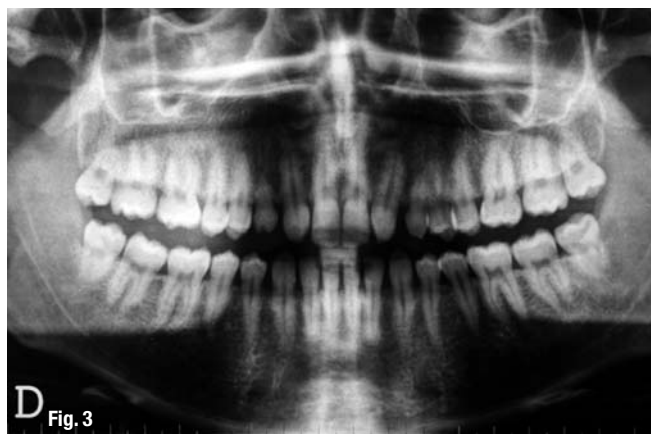Fig. 1 The 30-year-old patient was dissatisfied with the appearance of his smile.

Fig. 2 The gaps in the front row of teeth and the unusual shape of the upper lateral incisors bothered the patient.

_With the availability of a wide range of innovative restorative materials, the aesthetic demands of patients can be met efficiently and effectively by the collaborative efforts of practised dental teams. As the technology behind these materials has become increasingly sophisticated, clinical cases that were considered to be challenging previously can now be treated without having to compromise on aesthetics or remove healthy dental tissue. We describe our approach to cases such as these in the following article.

Flawless teeth are associated with good health and vitality. A bright smile radiates self-confidence and heightens a person's attractiveness. State-of-the-art aesthetic dentistry can achieve small wonders in this respect. The shape and colour of teeth, as well as their length and position, can be adjusted. Nevertheless, in all these treatments, preservation of healthy tooth

Fig. 3 A panoramic scanning dental X-ray revealed that teeth #12 and 22 had failed to develop.



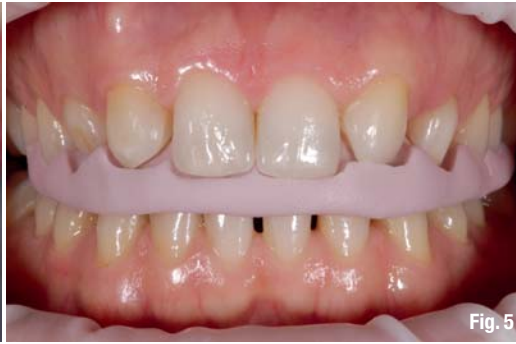
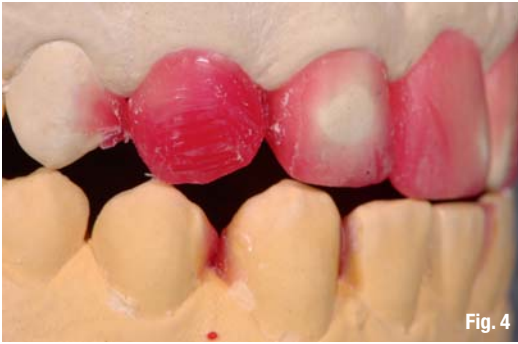
Fig. 4 _ A diagnostic wax-up and a silicone matrix were fabricated.

Fig. 5 _ The silicone matrix was used to produce a mock-up of the restoration.

the future would be possible without having to make functional or aesthetic compromises.

Planning the correct way

As usual, we documented the preoperative situation with photographs. In addition, we determined the where and how of the restorative procedure on the basis of working models. Our aim was to produce an appearance that would meet the requirements of the patient. A diagnostic wax-up was produced and a silicone matrix was created in the dental laboratory, taking into account the clinical requirements and the technical limitations (Fig. 4). In cases such as this one, the materials that are selected for the treatment are an important component of the treatment plan. As a result, it must be clear at the beginning of the clinical procedure what should be done ideally and what can be accomplished from a practical point of view. In this case, the corresponding information was transferred to the clinical situation by means of a direct mock-up, which was produced on the basis of the previously

fabricated silicone matrix (Fig. 5). Therefore, a composite resin was applied to teeth #14 and 24. The size of the two deciduous teeth was increased and the appearance of the existing canines was transformed with the composite resin to look like lateral incisors (Fig. 6). Even though the proportions of the central incisors were not yet in harmony with the overall appearance, the patient was satisfied with the aesthetics of the try-in of this minimally invasive solution.

Implementation

The final restorative procedure involved ten teeth. With the mock-up as a reference, the shape, size and minimal thickness of the restorations were established. Measures were taken to ensure the predictability of the quality and control of the technical and clinical aspects of the procedure (Figs. 7 & 8). On the basis of the wax-ups fabricated on the working models, six very thin veneers (facial) were planned for teeth #14, 24, 53, 63, 11 and 21. The veneers were so thin that the teeth did not require

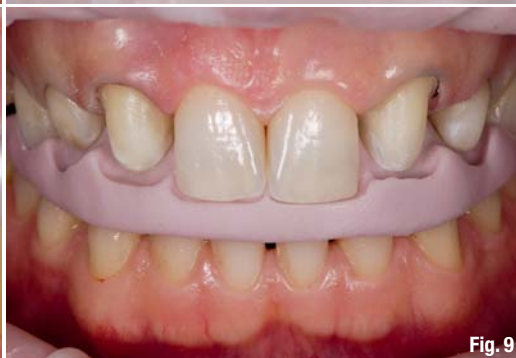
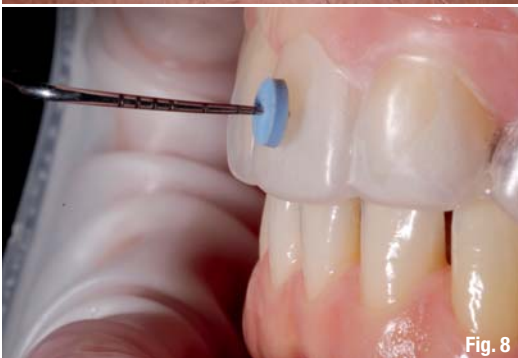
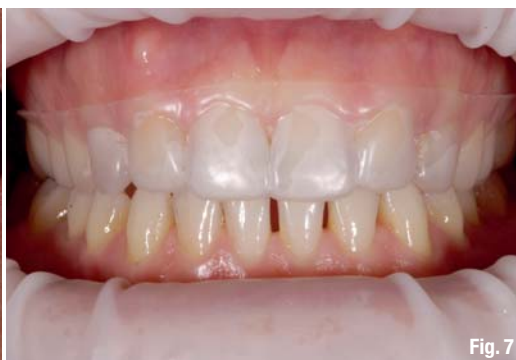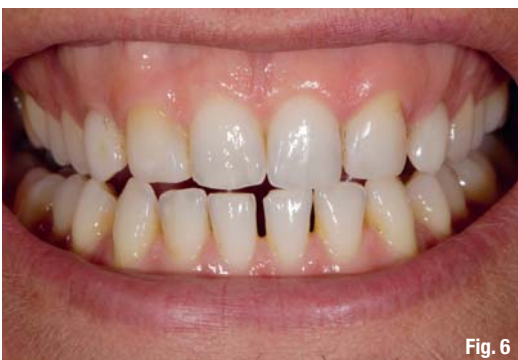Fig. 6 _ The finished mock-up (composite resin). The patient was satisfied with the prospective result.

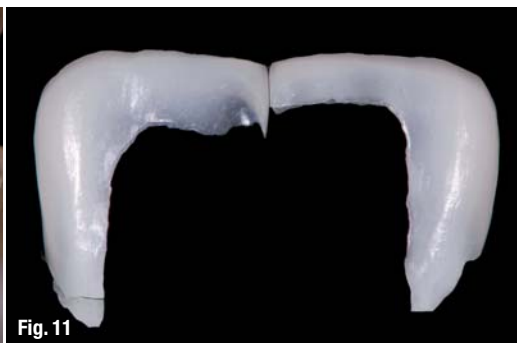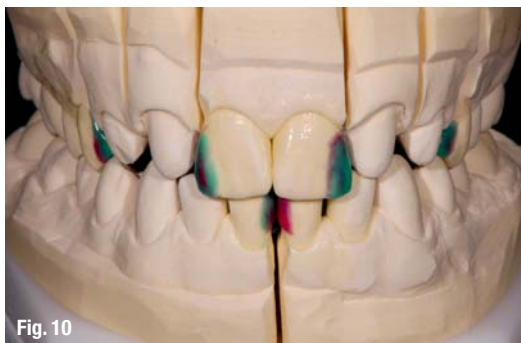Fig. 7 _ Reference patterns of the mock-up were fabricated for the permanent restoration...

Fig. 8 _ ...and the necessary volume and the minimal thickness were established.

Fig. 9 _ The prepared teeth.

Fig. 10 The restorations were modelled in the dental laboratory and...

Fig. 11 ...reproduced with pressed ceramics.

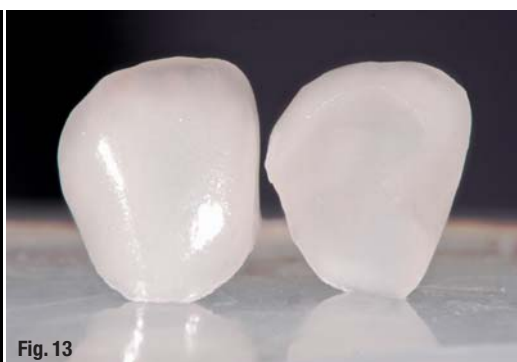

preparation. Teeth #12 and 22 were prepared for two conventional veneers. They were the only two teeth that required the removal of 0.6 mm of the dental enamel. Furthermore, mesial micro-preparation of teeth #41 and 31 was planned with the aim of augmenting these teeth with the corresponding veneers. Despite the smallness of this corrective step, it served to close what the patient considered to be an unattractive gap in the lower jaw (Fig. 9).

Skill and precision

This case required utmost skill and precision. The restoration involved six very thin non-prep veneers (Fig. 10). Moreover, two veneers had to be fabricated for teeth with micro-preparation (the deciduous canines were only ground on the distal side to remove 0.3 mm of the dental enamel), as well as two veneers for teeth that had been reduced by 0.6 mm. We decided to use IPS e.max Press lithium disilicate glass-ceramic (Ivoclar Vivadent) to produce the ten restorations. This material is used to fabricate

monolithic restorations, which are characterised by high strength (400 MPa) and exceptional aesthetics. We used the new IPS e.max Press Value ingots for the veneers on the central incisors and the two deciduous teeth. The brightness of restorations can be carefully controlled with this material. As a result, smooth integration into the existing dentition is ensured (Fig. 11). In the present case, the high translucency of this material enabled us to lengthen the edges of the central incisors. Therefore, the proportions of the teeth were more balanced, which enhanced the patient's smile. Instead of a Value ingot, an IPS e.max Press Opal ingot was used to construct the lower incisors. In contrast to the shades of the Value ingots, these blocks are opalescent and the level of this optical property can be adjusted as necessary (Fig. 12). Furthermore, these materials are characterised by their ability to match the shade of the underlying tooth structure. As a result, certain physical properties, such as brightness and opalescence, which are often difficult to reproduce, can be faithfully imitated or even enhanced.



Figs. 12–14 The material used for the film-thin veneers (IPS e.max Press) enabled utmost translucency to be achieved and the opacity to be adjusted according to the requirements.

Fig. 15 Some of the veneers were much thinner than a fingernail.

In order to improve the appearance of the canines and make them look like lateral incisors, we also used the press technique, but combined it with the cut-back technique. Owing to the shallowness of the preparation, a very delicate framework was required. Therefore, we chose a highly translucent ingot (IPS e.max Press HT, shade BL3) for this purpose. The pressed substructure was subsequently built up with IPS e.max Ceram using the conventional layering method (Fig. 13). If the relationship between a monolithic restoration and the supporting dental tissue is incorrect in the anterior region, it may be difficult to adjust the shade satisfactorily. In other words, if little natural tooth structure is available for the shade adjustment, the restoration may lack sufficient brightness and it may fail altogether. Therefore, the aim in the case described was to remove as little tooth structure as possible.

A steady hand

It is thoroughly understandable that the dental practitioner was slightly apprehensive when she opened the packet from the laboratory, as the delicate veneers were much thinner than a fingernail (Figs. 14 & 15). The subsequent challenge was to place these restorations precisely. The teeth, with the exception of the two permanent canines and the minimally prepared deciduous canines, had not been ground. As a result, there were no clear references for the placement of the veneers. Nevertheless, the OpraStick (Ivoclar Vivadent) proved to be a useful placement tool. This disposable auxiliary aid allowed the individual restorations to be handled without the risk of dropping or breaking them. Another important aspect of the treatment was that the dental technician was on hand to offer invaluable advice on the positioning of the restorations he had fabricated.

In addition, the cementation material selected was decisive for the successful shade adaptation of the restoration. In accordance with the recommendations for cementing restorations that are thicker than 1.5 mm, a dual-cure adhesive luting composite (Variolink II, Ivoclar Vivadent) was used to place the faced crowns. First, a suitable cement shade was established with the help of the special try-in pastes. Next, the ceramic restorations were etched with hydrofluoric acid and the enamel areas were conventionally conditioned. Monobond Plus (Ivoclar Vivadent) was used to condition the restorations, which were subsequently placed with the adhesive luting composite. Furthermore, at the try-in, the flowable composite Tetric EvoFlow (Ivoclar Vivadent) was chosen to cement the eight veneers. The flowability of the product was enhanced by warming it at 37°C for 20 minutes before application. Each individual veneer was placed under the

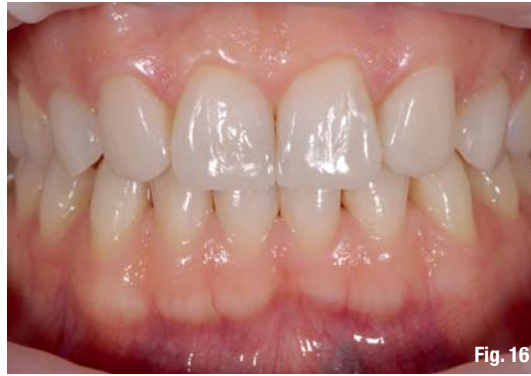

Fig. 16



Fig. 17

watchful eyes of the dental technician and only polymerised once it was correctly in place on the tooth.

Conclusion

The subsequent working steps were carried out with the same care as cementation. Excess cement was removed completely and all the necessary checks, such as the occlusion in lateral and vertical movements, were carried out. Although aesthetics played an important part in the treatment plan, functional aspects were not ignored in any way. Even though the ceramics and cements used are by far stronger and more adaptable to natural dentition than the materials used in the past, their function has to be checked nevertheless to avoid any undesirable consequences. The effect of the restorations immediately following cementation and at the one-week and one-month recall satisfied everyone involved. The materials we had selected allowed us to offer the patient minimally invasive treatment and highly aesthetic results (Figs. 16 & 17).

Editorial note: A complete list of references is available from the publisher.

_contact

cosmetic
dentistry



Dr Monica Basile

Viale Morgagni Giovan Battista, 1
50134 Florence
Italy

studio@spinbas.191.it



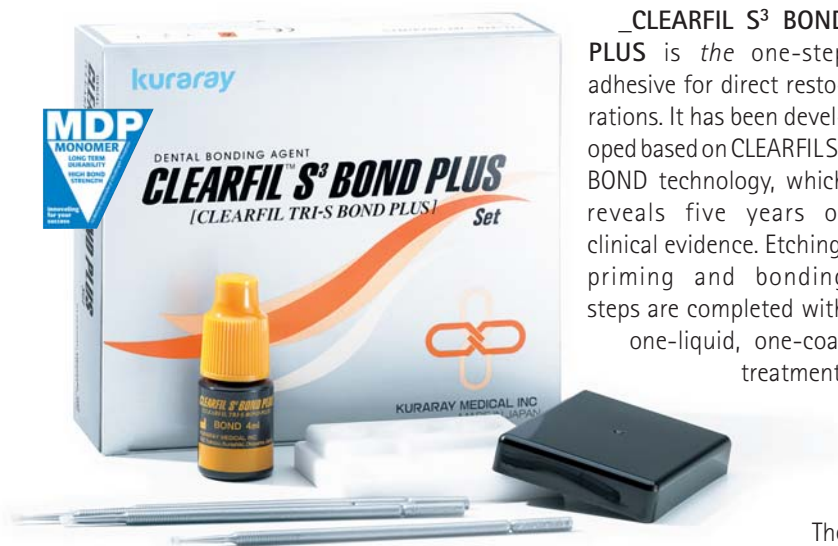Michele Temperani

Via Livorno, 54/2
50142 Florence
Italy

lab@temperani.191.it

CLEARFIL S³ BOND PLUS

High-tech and high speed for high performance



CLEARFIL S³ BOND PLUS is the one-step adhesive for direct restorations. It has been developed based on CLEARFIL S³ BOND technology, which reveals five years of clinical evidence. Etching, priming and bonding steps are completed with one-liquid, one-coat treatment.

CLEARFIL S³ BOND PLUS is easy and comfortable to use because time-intensive work steps, such as shaking the bottle, exact mixing and application of several components, multiple layering and rubbing in on the tooth surface, are no longer necessary.

The high bond strength of CLEARFIL S³ BOND PLUS is the result of two Kuraray innovative technologies: the high performance initiator and the proven MDP monomer. The new high performance initiator for light-curing improves clinical performance by building up more active radicals than conventional initiators and making the bond more impervious to water thanks to the increased polymerisation ratio.

The excellent bond strength to enamel and dentine of CLEARFIL S³ BOND PLUS marks a new standard among one-step adhesives, enabled by Kuraray's innovative adhesive technology, which has been successful for more than 30 years. Its fast and simple applica-

The integrated adhesive monomer MDP ensures a strong chemical bond to hydroxyapatite. In use for more than 25 years in successful products like PANAVIA F 2.0 and CLEARFIL SE BOND, the MDP monomer attains a high bond strength and reliable adhesive durability to tooth structure.

tion combined with its fluoride-releasing property makes CLEARFIL S³ BOND PLUS the ideal choice for all kinds of clinical situations, including paediatric therapy and core build-ups with the new CLEARFIL DC CORE PLUS. Furthermore, the system allows for precise and economic dosing.

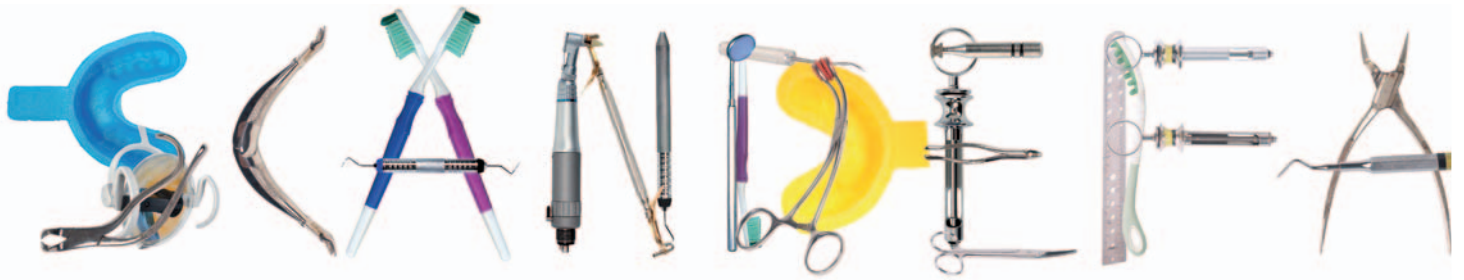The stable interface between tooth and composite resin is furthermore ensured by Kuraray's unique Molecular Dispersion Technology contained in CLEARFIL S³ BOND PLUS. The technology allows hydrophilic and hydrophobic components of the bond to be homogeneously combined—constantly. Thus, there is no phase separation, resulting in the formation of a homogenous layer on the preparation surface. The bond, showing no water voids, excels through its excellent bond performance.

CLEARFIL S³ BOND PLUS is always ready to use and will have users persuaded of its durable high bond strength.

The main benefit of using one-step adhesives is to reduce technical errors, thanks to a short application time and simple handling. The time-saving procedure makes CLEARFIL S³ BOND PLUS ready for immediate use in only three short steps: apply, air-dry, light-cure—all done in less than 30 seconds.



_contact	cosmetic dentistry
<p>Kuraray Europe GmbH Industriepark Höchst, Building F 821 65926 Frankfurt/Main Germany</p> <p>dental@kuraray.eu www.kuraray-dental.eu (EU) www.kuraraydental.com (USA)</p>	



APRIL 26- 28, 2012 • BELLA CENTER • COPENHAGEN • DENMARK

**Welcome to the 45th Scandinavian Dental Fair
The leading annual dental fair in Scandinavia**

SCANDEFA 2012



The 45th SCANDEFA invites you to exquisitely meet the Scandinavian dental market and sales partners from all over the world in springtime in wonderful Copenhagen

SCANDEFA 2012

Is organized by Bella Center and is being held in conjunction with the Annual Scientific Meeting, organized by the Danish Dental Association (www.tandlaegeforeningen.dk).

175 exhibitors and 11.422 visitors participated at SCANDEFA 2011 on 14,220 m² of exhibition space.

Exhibit at Scandefa

Book online at www.scandefa.dk
Sales and Project Manager, Christian Olrik
col@bellacenter.dk, T +45 32 47 21 25

Travel information

Bella Center is located just a 10 minute taxi drive from Copenhagen Airport. A regional train runs from the airport to Orestad Station, only 15 minutes drive.

Check in at Bella Center's newly built hotel

Bella Sky Comwell is Scandinavia's largest design hotel. The hotel is an integral part of Bella Center and has direct access to Scandefa. Book your stay on www.bellasky.dk

International Events

2012

SCANDEFA

26–28 April 2012
Copenhagen, Denmark
www.scandefa.dk

IADFE Annual Spring Meeting

26–29 April 2012
Rome, Italy
www.iadfe.org

IADR General Session & Exhibition

20–23 June 2012
Iguaçu Falls, Brazil
www.iadr.org

IACA 2012

26–28 July 2012
Hollywood, FL, USA
www.theiaca.com

AAED Annual Meeting

7–10 August 2012
Naples, FL, USA
www.estheticacademy.org

FDI Annual World Dental Congress

29 August–1 September 2012
Hong Kong, China
www.fdiworldental.org

SCAD Annual Conference

28 & 29 September 2012
Chicago, IL, USA
www.scadent.org

Dental–Facial Cosmetic International Conference

9 & 10 November 2012
Dubai, UAE
www.cappmea.com



2013

International Dental Show

12–16 March 2013
Cologne, Germany
www.ids-cologne.de

EAED Spring Meeting

30 May–1 June 2013
Crete, Greece
www.eaed.org

FDI Annual World Dental Congress

29 August–1 September 2013
Seoul, Korea
www.fdiworldental.org

AACD Scientific Session 2012

2–5 May 2012
Washington, DC, USA
www.aacd.com

ESCD & SSER Joint Meeting

17–19 May 2012
Bucharest, Romania
www.sser.ro

EAED Spring Meeting

24–26 May 2012
Çeşme, Turkey
www.eaed.org

submission guidelines:

Please note that all the textual components of your submission must be combined into one MS Word document. Please do not submit multiple files for each of these items:

- _ the complete article;
- _ all the image (tables, charts, photographs, etc.) captions;
- _ the complete list of sources consulted; and
- _ the author or contact information (biographical sketch, mailing address, e-mail address, etc.).

In addition, images must not be embedded into the MS Word document. All images must be submitted separately, and details about such submission follow below under image requirements.

Text length

Article lengths can vary greatly—from 1,500 to 5,500 words—depending on the subject matter. Our approach is that if you need more or less words to do the topic justice, then please make the article as long or as short as necessary.

We can run an unusually long article in multiple parts, but this usually entails a topic for which each part can stand alone because it contains so much information.

In short, we do not want to limit you in terms of article length, so please use the word count above as a general guideline and if you have specific questions, please do not hesitate to contact us.

Text formatting

We also ask that you forego any special formatting beyond the use of italics and boldface. If you would like to emphasise certain words within the text, please only use italics (do not use underlining or a larger font size). Boldface is reserved for article headers. Please do not use underlining.

Please use single spacing and make sure that the text is left justified. Please do not centre text on the page. Do not indent paragraphs, rather place a blank line between paragraphs. Please do not add tab stops.

Should you require a special layout, please let the word processing programme you are using help you do this formatting automatically. Similarly, should you need to make a list, or add footnotes or endnotes, please let the word processing programme do it for you automatically. There are menus in every programme that will enable you to do so. The fact is that no matter how carefully done, errors can creep in when you try to number footnotes yourself.

Any formatting contrary to stated above will require us to remove such formatting before layout, which is very time-consuming. Please consider this when formatting your document.

Image requirements

Please number images consecutively throughout the article by using a new number for each image. If it is imperative that certain images are grouped together, then use lowercase letters to designate these in a group (for example, 2a, 2b, 2c).

Please place image references in your article wherever they are appropriate, whether in the middle or at the end of a sentence. If you do not directly refer to the image, place the reference at the end of the sentence to which it relates enclosed within brackets and before the period.

In addition, please note:

- _ We require images in TIF or JPEG format.
- _ These images must be no smaller than 6x6 cm in size at 300 DPI.
- _ These image files must be no smaller than 80 KB in size (or they will print the size of a postage stamp!).

Larger image files are always better, and those approximately the size of 1 MB are best. Thus, do not size large image files down to meet our requirements but send us the largest files available. (The larger the starting image is in terms of bytes, the more leeway the designer has for resizing the image in order to fill up more space should there be room available.)

Also, please remember that images must not be embedded into the body of the article submitted. Images must be submitted separately to the textual submission.

You may submit images via e-mail, via our FTP server or post a CD containing your images directly to us (please contact us for the mailing address, as this will depend upon the country from which you will be mailing).

Please also send us a head shot of yourself that is in accordance with the requirements stated above so that it can be printed with your article.

Abstracts

An abstract of your article is not required.

Author or contact information

The author's contact information and a head shot of the author are included at the end of every article. Please note the exact information you would like to appear in this section and format it according to the requirements stated above. A short biographical sketch may precede the contact information if you provide us with the necessary information (60 words or less).

Questions?

Magda Wojtkiewicz (Managing Editor)
m.wojtkiewicz@oemus-media.de

cosmetic dentistry

_ beauty & science

Publisher

Torsten R. Oemus
oemus@oemus-media.de

CEO

Ingolf Döbbecke
doebbecke@oemus-media.de

Members of the Board

Jürgen Isbaner
isbaner@oemus-media.de

Lutz V. Hiller

hiller@oemus-media.de

Editor-in-Chief

Dr Sushil Koirala
skoirala@wlink.com.np

Co-Editor-in-Chief

Dr So Ran Kwon
smileksr@hotmail.com

Managing Editor

Magda Wojtkiewicz
m.wojtkiewicz@oemus-media.de

Executive Producer

Gernot Meyer
meyer@oemus-media.de

Designer

Franziska Dachsel
f.dachsel@oemus-media.de

Copy Editors

Sabrina Raaff
Hans Motschmann

Published by

Oemus Media AG
Holbeinstraße 29
04229 Leipzig, Germany
Tel.: +49-341/4 84 74-0
Fax: +49-341/4 84 74-2 90
kontakt@oemus-media.de
www.oemus.com

Printed by

Löhnert Druck
Handelsstraße 12
04420 Markranstädt, Germany

Advisory Board

Dr Michael Miller, USA
Dr Seok-Hoon Ko, Korea

Editorial Board

Dr Anthony Au, Australia
Dr Bao Baicheng, China
Dr Helena Lee, Singapore
Dr Hisashi Hisamitsu, Japan
Dr Jiraporn Charudilaka, Thailand
Dr Mostaque H. Sattar, Bangladesh
Dr Ratnadeep Patil, India
Dr Sim Tang Eng, Malaysia
Dr Suhit Raj Adhikari, Nepal
Dr Takashi Nakamura, Japan
Dr Vijayaratnam Vijayakumaran, Sri Lanka



Magda Wojtkiewicz, Managing Editor

cosmetic
dentistry _ beauty & science
is the official publication of:



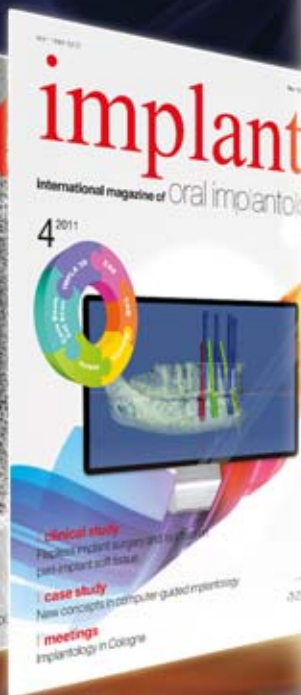
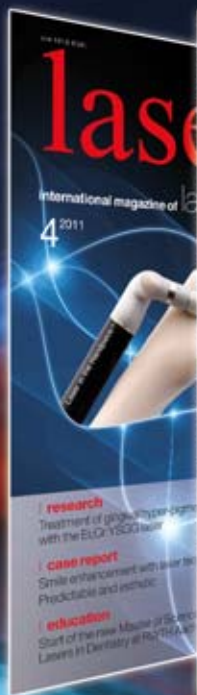Copyright Regulations

_cosmetic dentistry_beauty & science is published by Oemus Media AG and will appear in 2012 with one issue every quarter. The magazine and all articles and illustrations therein are protected by copyright. Any utilisation without the prior consent of editor and publisher is inadmissible and liable to prosecution. This applies in particular to duplicate copies, translations, microfilms, and storage and processing in electronic systems.

Reproductions, including extracts, may only be made with the permission of the publisher. Given no statement to the contrary, any submissions to the editorial department are understood to be in agreement with a full or partial publishing of said submission. The editorial department reserves the right to check all submitted articles for formal errors and factual authority, and to make amendments if necessary. No responsibility shall be taken for unsolicited books and manuscripts. Articles bearing symbols other than that of the editorial department, or which are distinguished by the name of the author, represent the opinion of the afore-mentioned, and do not have to comply with the views of Oemus Media AG. Responsibility for such articles shall be borne by the author. Responsibility for advertisements and other specially labeled items shall not be borne by the editorial department. Likewise, no responsibility shall be assumed for information published about associations, companies and commercial markets. All cases of consequential liability arising from inaccurate or faulty representation are excluded. General terms and conditions apply, legal venue is Leipzig, Germany.

cosmetic

dentistry _ beauty & science



You can also subscribe via
www.oemus.com/abo

 **Subscribe now!**

I would like to subscribe to **cosmetic dentistry** for € 44 including shipping and VAT for German customers, € 46 including shipping and VAT for customers outside Germany, unless a written cancellation is sent within 14 days of the receipt of the trial subscription. The subscription will be renewed automatically every year until a written cancellation is sent to OEMUS MEDIA AG, Holbeinstr. 29, 04229 Leipzig, Germany, six weeks prior to the renewal date.

▶ **Reply** via Fax +49 341 48474-290
 or via E-mail to grasse@oemus-media.de

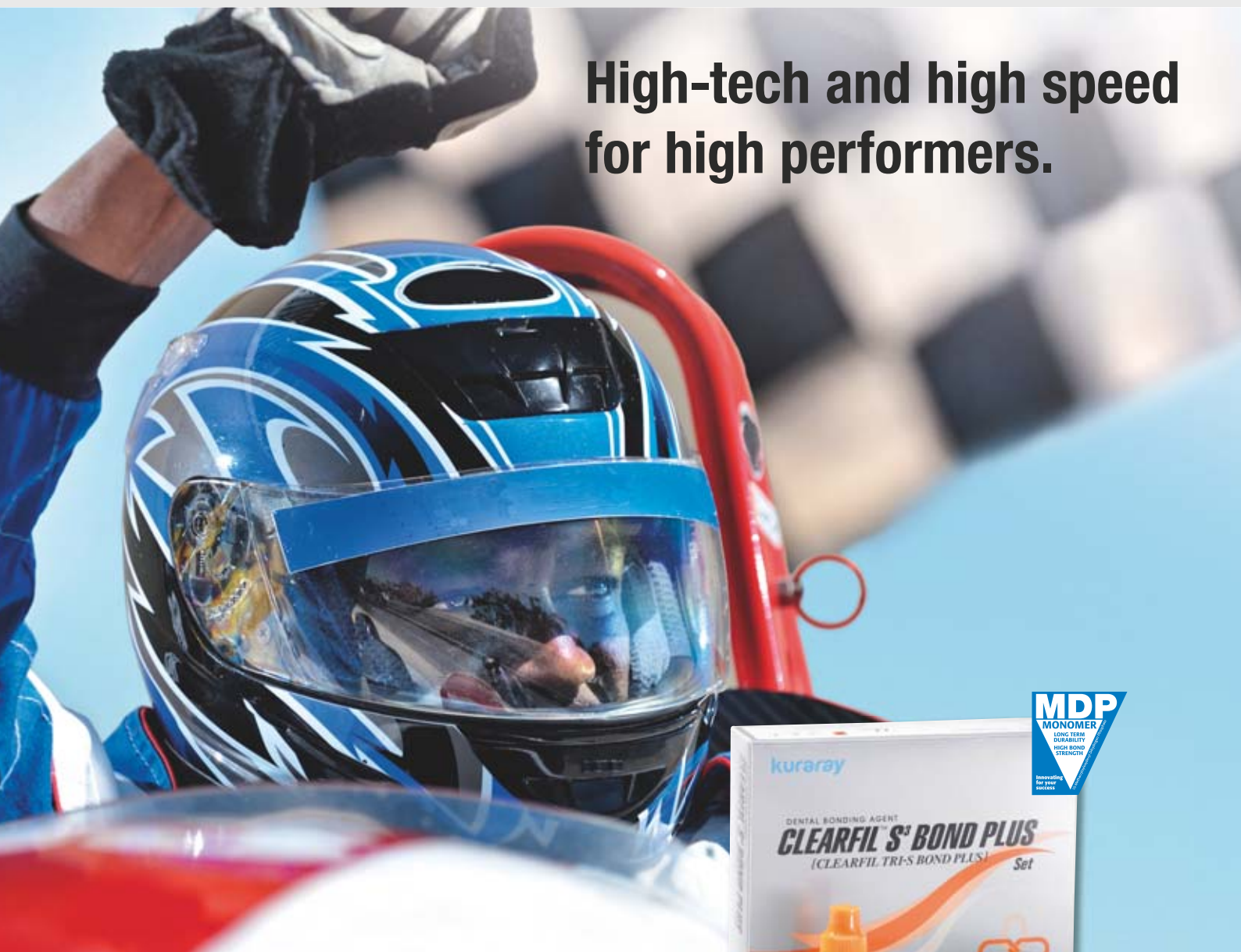Last Name, First Name	
Company	
Street	
ZIP/City/County	
E-mail	Signature

Notice of revocation: I am able to revoke the subscription within 14 days after my order by sending a written cancellation to OEMUS MEDIA AG, Holbeinstr. 29, 04229 Leipzig, Germany.

Signature

kuraray

High-tech and high speed for high performers.



CLEARFIL™ S³ BOND PLUS

**The time saving one-step adhesive –
your solution for fast and simple application**

Are you looking for a one-step adhesive that ensures “Speed – Simplicity – Strength”? Then CLEARFIL™ S³ BOND PLUS, Kuraray’s time-saving adhesive for fast and simple application, is the ideal solution for you.

Thanks to its short application time and very simple procedure compared with other recent one-step products CLEARFIL™ S³ BOND PLUS allows a high error tolerance while creating excellent bond strength to enamel and dentin.



Furthermore CLEARFIL™ S³ BOND PLUS ensures a stable interface between tooth and composite resin due to Kuraray’s new high performance initiator for light-curing, the original adhesive monomer MDP and the innovative Molecular Dispersion Technology.

**CLEARFIL™ S³ BOND PLUS –
it’s your choice for a fast and easy bond!**