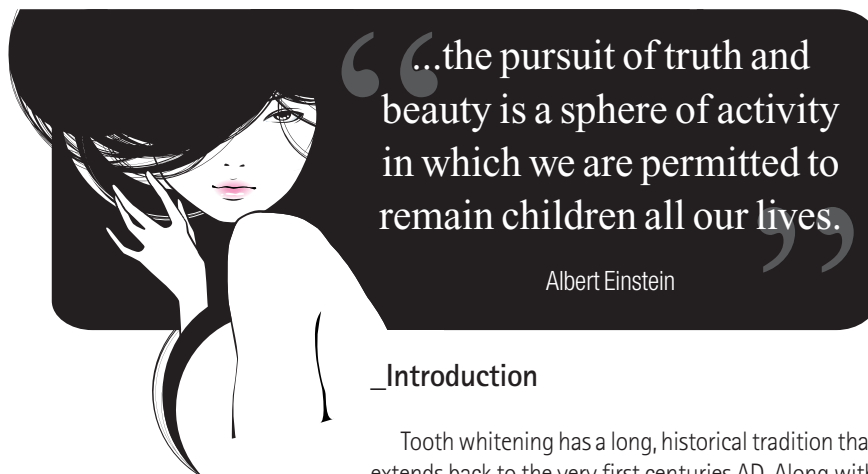


# Bleaching: New approaches to a traditional minimally invasive therapy

## CosmEt(h)ics vs. aesthEt(h)ics

**Authors**\_Dr Kresimir Simunovic & Monica Tuzza, Switzerland



### \_Introduction

Tooth whitening has a long, historical tradition that extends back to the very first centuries AD. Along with tooth extractions, it was an accepted practice already in medieval times, performed by applying aqua fortis (a solution of nitric acid) after a simple rough polishing of the enamel surface. The procedure was performed by the "dental surgeons" on duty in those days, known as barbers.

In the 19<sup>th</sup> century, new methods were developed with oxalic acid (Chappel 1887) and super-peroxide, which is thus the first documented use of hydrogen peroxide ( $H_2O_2$ ; Harlan 1884). In 1918, Abbot discovered a fundamental formula for tooth bleaching, entailing a combination of light, heat production and the chemical interactions of stabilised  $H_2O_2$  at 35% (superoxol). Since then, the formula has been refined continuously, but not changed in essence.

Studies in the late sixties by Zach and Cohen, and Nyborg and Brännstorm determined the safety settings to control heat influence on the pulp, and in 1970 the effectiveness of  $H_2O_2$  on dentine was established. During the sixties and seventies, carbamide peroxide was used

as an oral antiseptic, with an additional whitening effect discovered during treatment. This phenomenon was subsequently analysed (Klusmier 1960), and Haywood and Heymann later developed the original home-bleaching process. The first commercial products were launched on the market as White & Brite by Omni (1989) and Opalescence by Dent Mat (1991), among many others.

The current home-bleaching process entails the chemical decomposition of carbamide peroxide into  $H_2O_2$ , among others, but with an effect that is six times weaker in comparison to the original protocol. In the late sixties, Nutting and Poe developed the walking bleach method for non-vital teeth, which involved placing a mixture of superoxol and sodium perborate into the pulp chamber for a week, a protocol that was further adapted without altering the basics.

An entirely new series of heat sources like plasma and LED lamps, combined with corresponding bleaching gels, paved the way to the new millennium with names like BriteSmile (Discus Dental) and the various generations of Zoom.

Professional literature on bleaching and cosmetics emerged at the beginning of the nineties, with the first publications by the pioneers Goldstein and Garber, followed by many others.

### \_Thermocatalytic or photocatalytic?

The two principles are not mutually exclusive. The bleaching procedure was described step by step in 1991 in Albers' ADEPT report. It involves a redox process in which complex, dark-pigmented carbon rings are reduced through oxidation to more simple chains that ab-

# Moscow 2012

The 32nd Moscow International Dental Forum



**Dental-Expo**  
international dental fair

**September 17-20**

Crocus Expo exhibition grounds

more than  
**450**  
exhibitors

more than  
**25000**  
attendees

more than  
**35**  
countries



[www.dental-expo.com](http://www.dental-expo.com)

**DENTALEXPO®**



Fig. 1

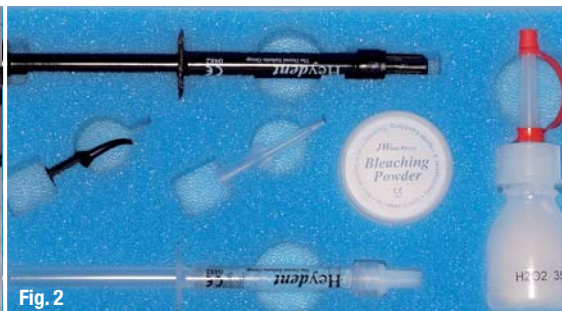

Fig. 2

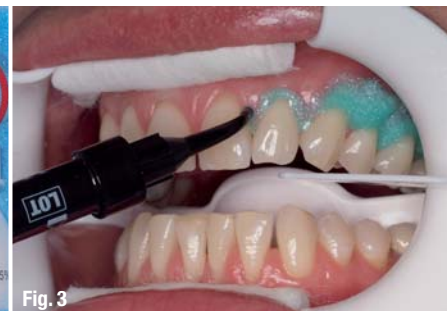

Fig. 3

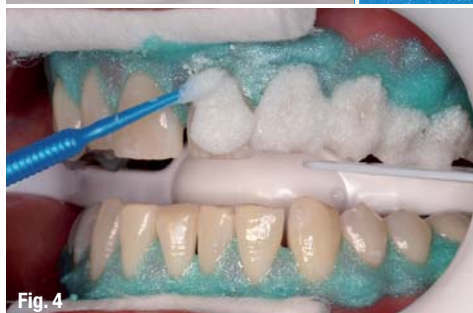

Fig. 4

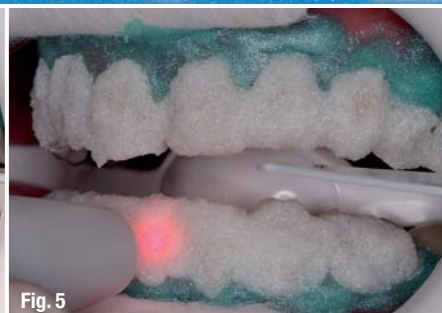

Fig. 5

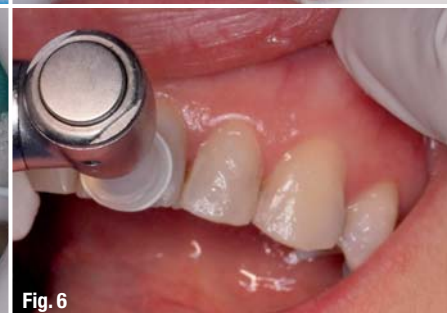

Fig. 6

sorb less light, reflecting light more intensively and appearing brighter. The redox process continues until the saturation point is reached. Thus, it functions as an absolute emergency stop to avoid any fatal decomposition of the tooth structure to  $\text{CO}_2$  and  $\text{H}_2\text{O}$  through ruptures of the molecular structures, which would result in noxious complete oxidation.

### Laser-assisted or laser-activated?

Since November 2009, dental practitioners have had the choice of a new innovative laser-activated whitening method, initiated by a wavelength-specific chromophore or activator as an essential part of the bleaching powder. Additional  $\text{TiO}_2$  limits the thermal side-effects, allowing a maximal increase of 1.5 to 2 °C at the delicate border between the bleaching gel and the enamel surface.

A corresponding large series of ESEM analyses from the University of Vienna (Prof Andreas Moritz and Prof Johann Wernisch) provided no evidence of any change in the enamel-surface morphology before and immediately after bleaching. Consequently, there is no longer any need for specific 48-hour post-operative instructions about smoking or food and drink consumption, a

conclusion supported by several basic studies. There is no risk either of any kind of pigment staining the teeth during the first two days.

From our clinical experience, we have concluded that post-operative complaints or sensitivities are very rare and limited to the day of treatment. In addition, the whitening process continues for about two more days post-operatively and the final result is often a natural-looking aesthetic whitening of several shades. This protocol even improves grey tones: a revolutionary outcome, since those shades are very challenging for any external whitening process.

The protocol of this new method of laser-activated tooth whitening includes protective glasses and a bleaching set, with a wavelength-dependent activator in the bleaching powder and  $\text{H}_2\text{O}_2$  liquid (about 25%). They are mixed to a creamy consistency and then left to rest for two minutes. Pumice (no prophylaxis paste) is used to remove biofilm from the teeth, and the gingiva is covered by the liquid dental dam (Figs. 1–3). After the dental dam set, the mixture is applied to the buccal tooth surfaces (Fig. 4) and then irradiated at the chosen wavelength, scanning each surface for 30 seconds. Three or four cycles per session are allowed and a final applica-

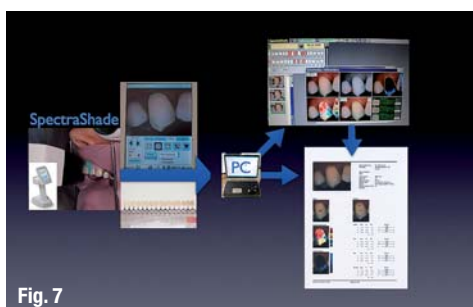


Fig. 7

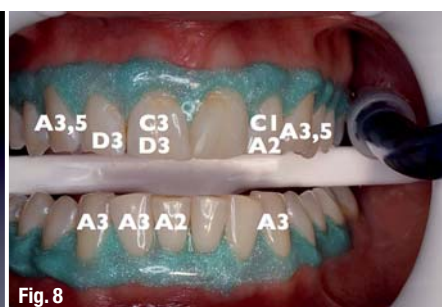


Fig. 8

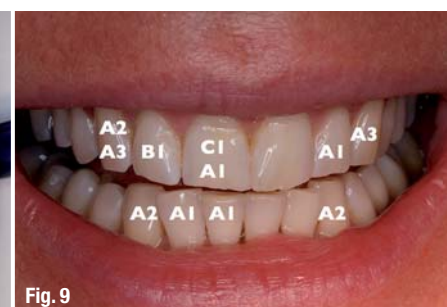

Fig. 9





## Laser-activated whitening: Three cases from our office

**Fig. 16**

### Case 2

**Fig. 17**



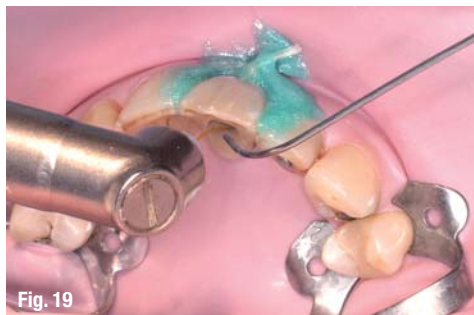

Fig. 19

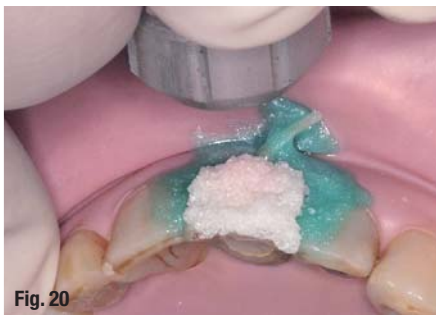

Fig. 20

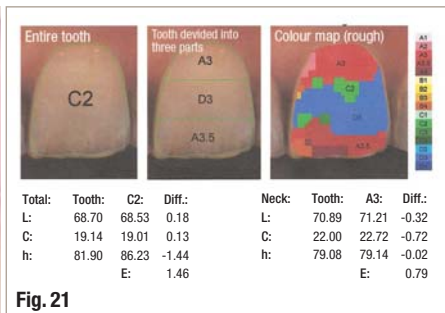


Fig. 21

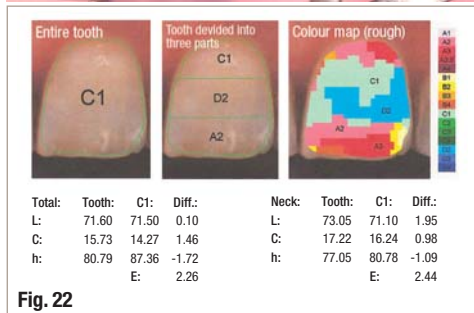


Fig. 22

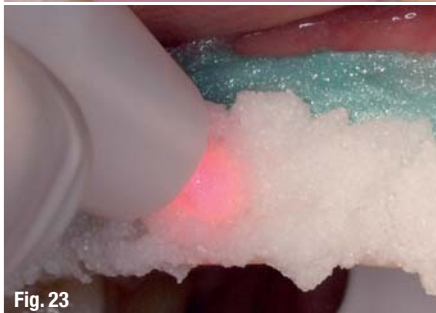

Fig. 23

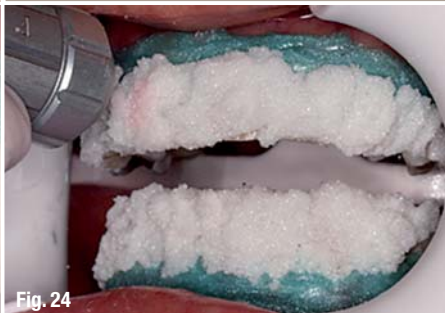

Fig. 24

### Case 3

The third case was treated using combined two-step whitening before the definitive aesthetic restoration. The first step entailed combined laser-assisted endodontic revision of the non-vital left maxillary central incisor using Er:YAG and Nd:YAG lasers (Fidelis Plus III, Fotona), followed by selective external bleaching using an Nd:YAG laser with the R24 hand piece for four cycles of 60 seconds each (Figs. 19 & 20). In addition, Figs. 21 & 22 show the final results of the spectrometric analysis of the central left incisor (after selective external bleaching of this surface only). The second step involved complete combined bleaching of both arches using an 810 nm diode laser (ARC) with a photo-biomodulation (PBM) hand piece for two cycles of 30 seconds each and an Nd:YAG laser with the R24 hand piece (Fotona) for one cycle of 30 seconds (Figs. 23–24). Figs. 25 & 26 offer a comparison between the situation before any treatment and after the final bleaching (before definitive restorations).

### Conclusion

This new and innovative addition to the field of laser-assisted tooth whitening is a precious enrichment to minimally invasive therapies that are part of the daily

office routine. Tooth bleaching is a prudent evidence-based choice in cases of aesthetic imbalance, often because tooth-shade variation is an evident social, private and professional obstacle, and the clinician's professional knowledge and the patient's treatment needs are the focus. For the laser user, tooth bleaching is a safe and cost-saving alternative because the bleaching powder can be adapted to the in-office laser wavelength(s) via specific activators. Handling is easy and can be carried out by assistants as part of a low-level energy laser treatment.

\_contact

laser

**Dr Kresimir Simunovic and Monica Tuzza**

Office for Laser-Assisted Dentistry  
Seefeldstr. 128  
8008 Zurich  
Switzerland

ksimunovic@smile.ch  
www.simident.ch

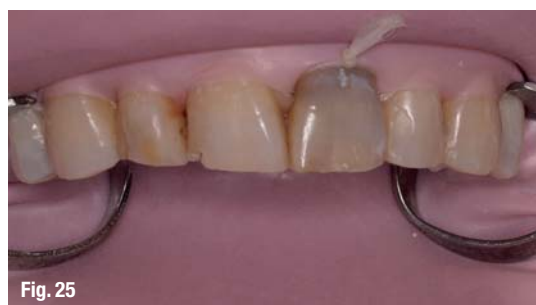

Fig. 25

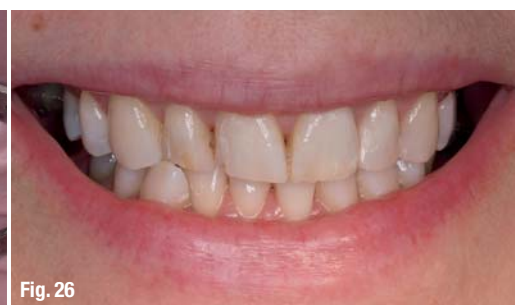

Fig. 26

تحت رعاية  
سمو الشيخ حمدان بن راشد آل مكتوم  
نائب حاكم دبي، وزير المالية  
رئيس هيئة الصحة بدبي

Under the Patronage of  
**H. H. Sheikh Hamdan Bin Rashid Al Maktoum**  
Deputy Ruler of Dubai, Minister of Finance  
President of the Dubai Health Authority

## مؤتمر الإمارات الدولي لطب الأسنان ومعرض طب الأسنان العربي UAE INTERNATIONAL DENTAL CONFERENCE & ARAB DENTAL EXHIBITION



Delivering Science & Technology

5 - 7 February, 2013 | مركز دبي الدولي للمؤتمرات والمعارض  
Dubai International Convention & Exhibition Centre

[www.aeedc.com](http://www.aeedc.com)

Organised by



In Cooperation with



Strategic Partner



Supported by



Strategic Sports Club Partner



**INDEX® Conferences & Exhibitions Organisation Est.**

Dubai Healthcare City, Ibn Sina Medical Complex #27, Block B, Office 203, P.O. Box: 13636, Dubai, United Arab Emirates  
Tel: +971 4 3624717, Fax: +971 4 3624718, E-mail: [info@aeedc.com](mailto:info@aeedc.com), Website: [www.index.ae](http://www.index.ae)