

Consideration of an uncommon approach in the atrophied posterior zone

Part II: Extraction-plus technique

Authors Drs Maen Aburas, UAE & Ralf Gutwald, Germany

Introduction

In the past, it was a significant challenge for clinicians to achieve implantation in the alveolar ridge of the posterior zone with restricted bone height, for which the alternative treatment choices were limited. However, procedural and technological developments have enabled implantation in most cases of severe bone resorption through the use of complex bone-augmentation techniques, such as bone transmission, sinus lift, distraction and nerve transposition, and the use of bone substitute, membrane and nail fixation, which might increase the risk of complication and failure.

Generating new bone in a free-end saddle in the vertical dimension is very difficult to achieve and some patients are unwilling to go through such a protracted treatment plan, considering the possible impact on their general health and psychological condition, as well as the cost. This scenario means that we have to find a good solution for those patients who cannot undergo such a difficult procedure, bearing in mind that the use of short implants alone is not advisable in many cases. The onus is on us to come up with a simple and standard means of implantation to save time and pain and to minimise the risk of complication and failure. The principle of the new technique proposed here—the extraction plus technique—is the extraction and sacrifice of the adjacent natural tooth, followed by the insertion of a long implant to support shorter implants that are inserted where bone height is limited. Through this new technique, we can convert a complicated procedure (guided bone regeneration—GBR) into a simple standard procedure with less pain, saving time and costs, and minimising the risk of complications.

Conclusion for surveys

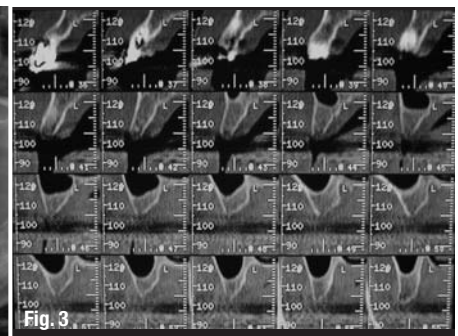
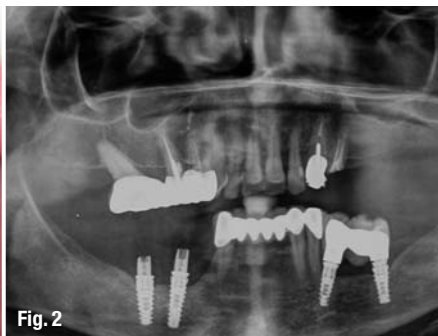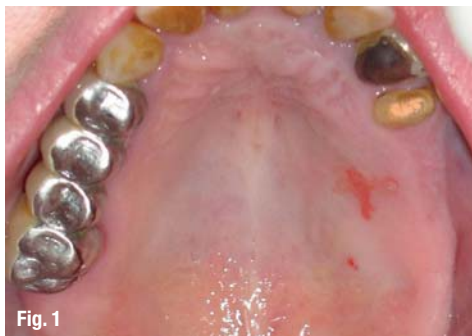The extraction plus technique was considered by the respondents as one of the better alternatives, especially when the tooth to be extracted was unhealthy, but less so when it was healthy. Using the short-implant technique in the mandible was pre-

Fig. 1 Occlusal view of the maxilla, tooth #24.

Fig. 2 Diagnostic panoramic radiograph at the time of presentation.

Fig. 3 Diagnostic CT scan sections, left maxilla: sinus floor and alveolar ridge height.

Generating new bone in a free-end saddle in the vertical dimension is very difficult to achieve and some patients are unwilling to go through such a protracted treatment plan, considering the possible impact on their general health and psychological condition, as well as the cost. This scenario means that we have to find a good solution for those patients who cannot undergo such a difficult procedure,



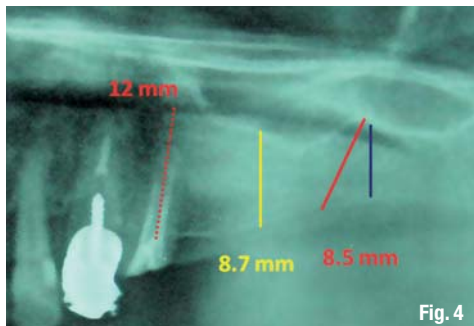


Fig. 4

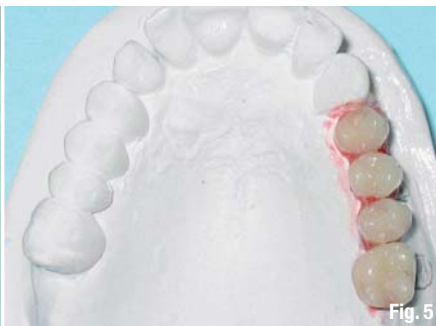

Fig. 5

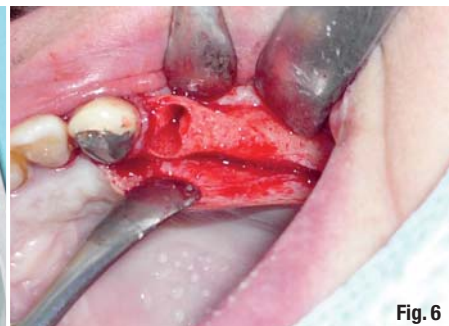

Fig. 6

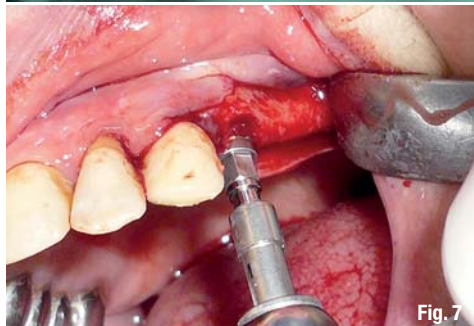


Fig. 7

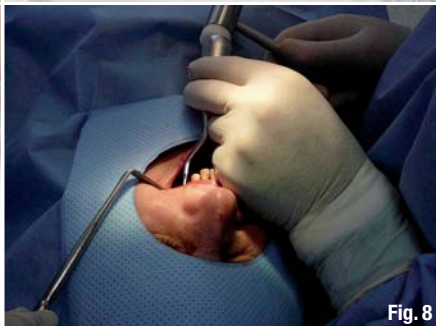

Fig. 8

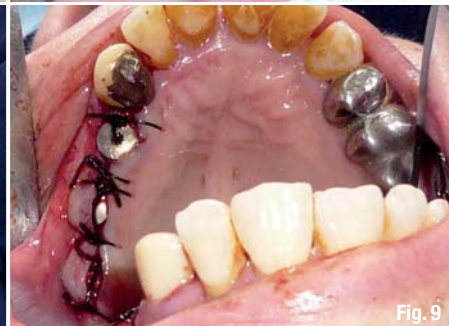

Fig. 9

ferred to using it in the maxillary posterior zone. The internal sinus-lift procedure was the most preferable technique for the maxilla. Overall, the clinicians found complicated alternatives, such as bone distraction and nerve transposition, the least preferable.

Clinical case II: Unilateral free-end saddle left maxilla

In March 2008, a healthy, non-smoking 67-year-old female presented with a unilateral free-end saddle left maxilla and bilateral implants in the mandible. Medical findings revealed that the patient had been diagnosed with osteoporosis on 25 July 2006. She had undergone 21 months of treatment with Fosavance (bisphosphonates plus vitamin D) as recommended by her orthopaedic surgeon. The patient's chief complaint was difficulty in chewing food owing to missing teeth on the upper left side.

The intra-oral examination revealed fixed dental prostheses on teeth #14, 15 to 17, and 34 to 43, a crown on #23 and an implant bridge on #35 to 37.

Lingual stains were detected on teeth #11 to 13, and 21 and 22, and three quarters of tooth #24 crown were broken. The radiographic findings confirmed a bridge over two implants on the posterior left mandible with insufficient marginal adaptation, root-canal treatment (teeth #14, 15, 23 and 24) and an implant posterior to tooth #43, which was extended to the mental foramen. This explained the loss of sensation in the lower right lip and limited bone height on the upper posterior left from 7 to 8.5 mm (Figs. 1–3).

The treatment plan was to avoid any extensive surgical procedure alternatives, for example by considering osteoporosis medication such as bisphosphonates. It was therefore decided not to do the sinus-lift procedure in the free-end saddle maxilla. In this complicated case, the extraction plus technique helped to simplify the procedure to extracting tooth #24 and replacing it with an immediately placed long implant (Tapered Effect, Straumann; 12 mm in length, 4.1 mm in diameter) in the left maxilla. This implant was combined with two short implants (Standard Plus, Straumann; 8 mm in length, 4.1 mm

Fig. 4 Panoramic radiograph, left maxilla: limited bone height treatment plan.

Fig. 5 Occlusal view of the cast: wax-up of the planned prosthesis.

Fig. 6 Situation after extraction of tooth #24: alveolar walls intact.

Fig. 7 Immediate placement of a Tapered Effect implant.

Fig. 8 Use of the bone condenser to improve bone quality in the sites of the short implants.

Fig. 9 Repositioning of the flaps and a single 3-0 silk suture.

Fig. 10 Post-op radiograph: the insertion according to plan, tilting of the last implant to avoid perforation of the sinus floor.

Fig. 11 Occlusal view of the implants after a long healing period.

Fig. 12 Positioning the cylinder's rest on the snap-on impression caps for the closed-tray impression technique.

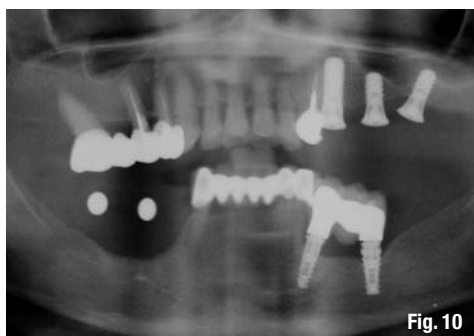


Fig. 10

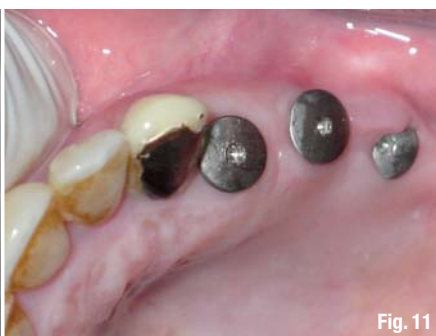

Fig. 11

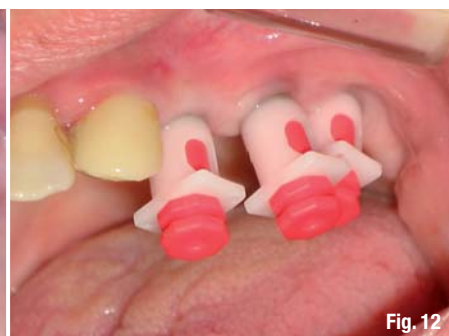

Fig. 12

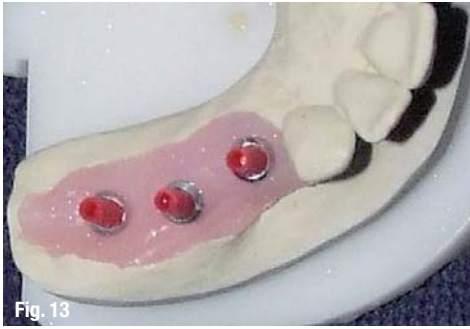

Fig. 13

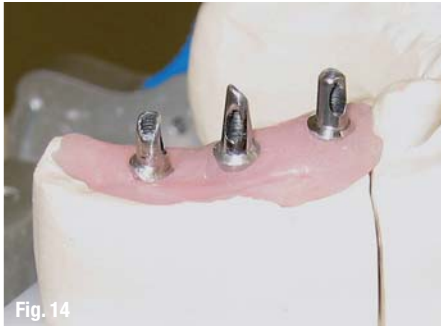

Fig. 14

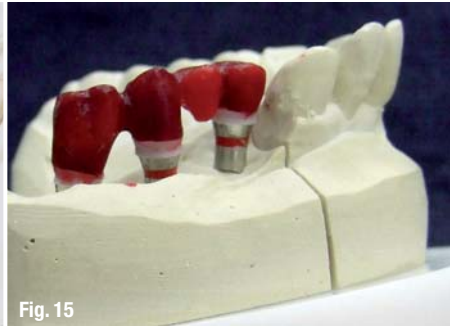

Fig. 15

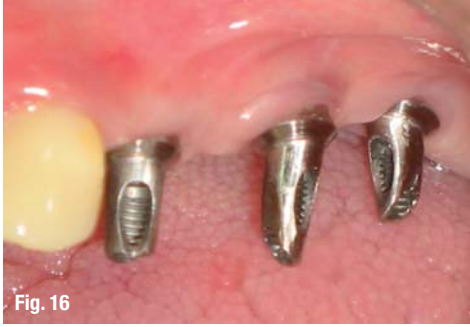

Fig. 16

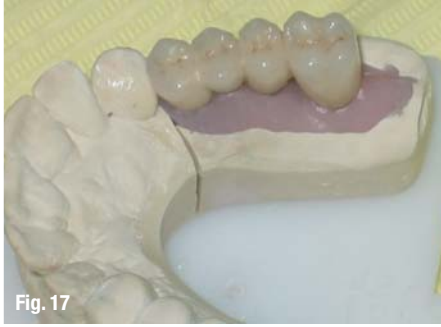

Fig. 17

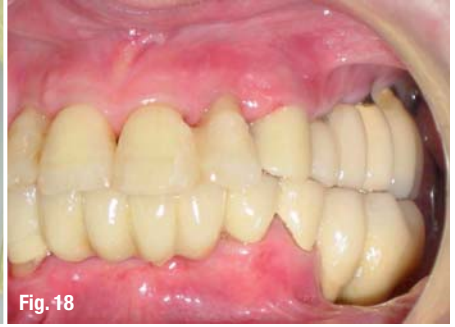

Fig. 18

Fig. 13 Occlusal view of the master cast in the laboratory: a Straumann prosthetic planning kit to select appropriately angled abutments to illustrate the parallelism.

Fig. 14 Lateral view of the master cast: optimal parallelism of the abutments.

Fig. 15 Lateral view: bridge framework wax-up.

Fig. 16 Lateral view: angled synOcta abutment seated in the mouth and torqued to 35 Ncm.

Fig. 17 Palatal view: final restoration seated in the master cast.

Fig. 18 Lateral view: final restoration seated in the mouth in maximum intercuspation.

Fig. 19 Occlusal view: final restoration seated in the mouth, outcome corresponds to the cast plan.

Fig. 20 Radiograph of the outcome: insertion of the final restoration in the mouth, reimplantation in the right mandible.

in diameter) in the place of teeth #25 and 26 (Figs. 4 & 5).

The surgical procedure was done as planned through the extraction of tooth #24 with a non-traumatic tooth removal technique. No damage to the surrounding alveolar ridge occurred, and the immediate placement of a long implant (Tapered Effect; 12 mm in length, 4.1 mm in diameter) in the extraction site followed. The second and third implants (Standard Plus; 8 mm in length, 4.1 mm in diameter, with a regular neck) were inserted using a bone-condensation technique. The third implant was tilted distally in order to gain maximum bone contact with the implant surface—the limited alveolar bone height helps avoid perforation of the sinus floor. The prime stability of the implants was confirmed and the flaps were repositioned according to a non-submerged protocol. Furthermore, a post-operative panoramic radiograph was taken as planned (Figs. 6–10). The patient came back for the prosthetic stage after a long vacation in January 2009. First, the peri-implant mucosa was assessed and determined to be healthy, with no bleeding on probing around the im-

plant. Percussion of the implants indicated well-integrated and stable implants. It was therefore decided to take a definitive impression for the final restoration, which was then made using snap-on impression caps. After the impression and the master cast were ready, a prosthetic planning kit (Straumann) was used to select suitable abutments and confirm the parallelism. Two 15° abutments and one 20° abutment from the synOcta implant system (Straumann) were selected (Figs. 11–14). The metal framework was constructed and tried in, and the X-ray revealed good marginal adaptation. The framework was then returned to the laboratory for ceramic application. Then angled synOcta abutments were seated in the mouth and torqued to 35 Ncm. The final bridge restoration was adjusted and verified in the mouth. Lastly, temporary cementation was done (Figs. 15–20).

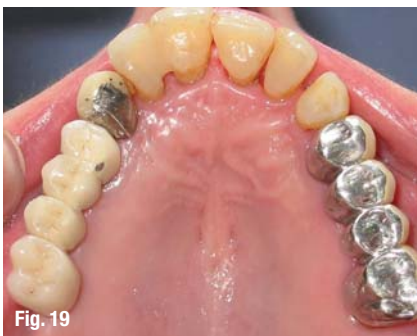

Fig. 19

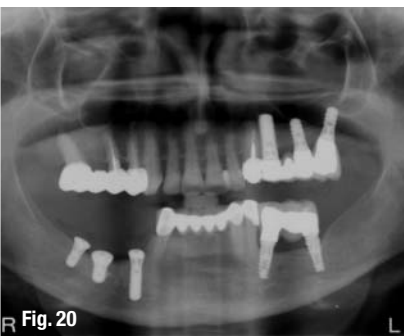

Fig. 20

_contact

implants

Dr Maen Aburas

Dr Aburas Dental Center LLC
Room 401, Doha Center Building,
Al Maktoum Road, Deira, Dubai
UAE, P.O Box 11048

Dr Ralf Gutwald

Hugstetter Str. 55
79106 Freiburg/Breisgau
Germany

ralf.gutwald@uniklinik-freiburg.de

Geistlich Symposia at Europerio7, Vienna



Geistlich lecture Friday, June 8, 2012

Topic Interactive discussion: Surgical and non surgical peri-implantitis treatment concepts
Time 16:00-17:00
Room Strauss 1

Geistlich lecture Saturday, June 9, 2012

Topic Interactive session: How to treat multiple recessions? An innovative treatment concept
Time 11:00-12:00
Room Stolz 1-2

*Don't miss
these interactive
sessions!*

