

The same-day tooth: From the diagnosis to the final restoration

Author_Dr Stefanos G. Kourtis, Greece

_Introduction

The restoration of missing anterior teeth is both a challenging task for the clinician and a stressful treatment for the patient. The final aesthetic result is of major importance—for the patient, dentist and dental technician. Moreover, the patient has high expectations, aesthetic demands and concerns about the cosmetic result of the final restoration. Even before treatment is started, the patient is usually concerned about the final outcome, as well as the provisional restoration used during osseointegration. The aim of this case report is to

present the clinical stages of rehabilitation of a central incisor from diagnosis to final restoration.

_Case presentation

A 29-year-old female patient without any apparent contributory medical history presented for treatment. The patient complained about the aesthetic appearance of the anterior maxillary region. The right central incisor appeared elongated, showed increased mobility (Grade I+) and was sensitive to palpation. The gingival margin of this tooth showed signs of infection, both labially and

Fig. 1_Initial clinical situation.

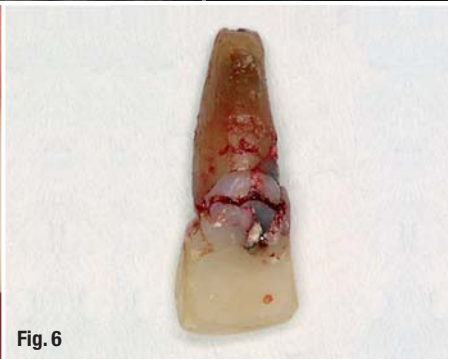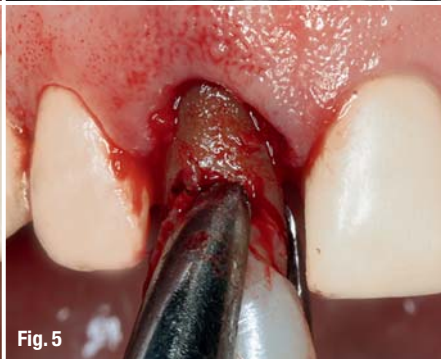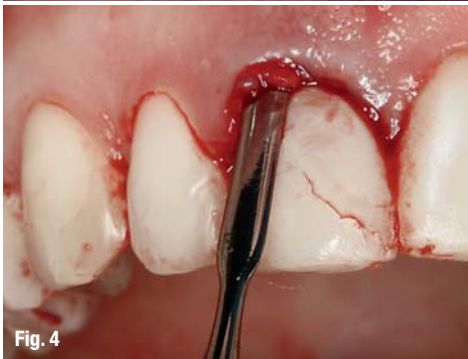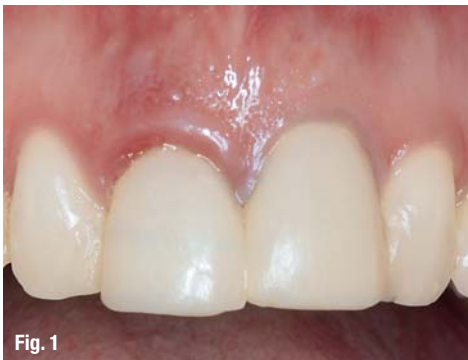Fig. 2_Initial radiographic situation.

Fig. 3_Detailed X-ray examination.

Fig. 4_Periodontal fibres cut by utilising a periosteal elevator.

Fig. 5_Atraumatic tooth extraction.

Fig. 6_The horizontal root fracture was evident on the extracted tooth.

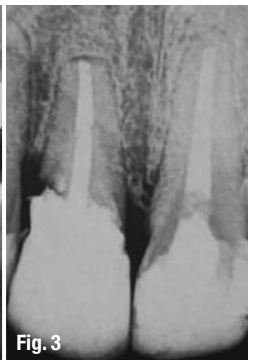
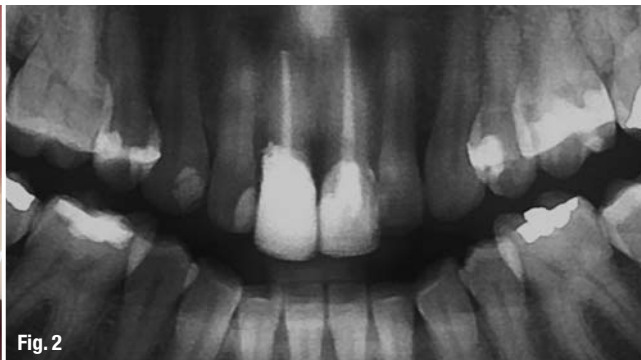
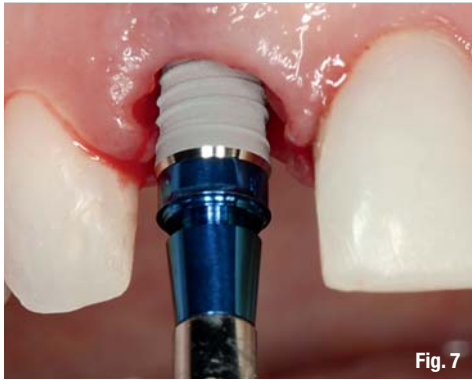



Fig. 7

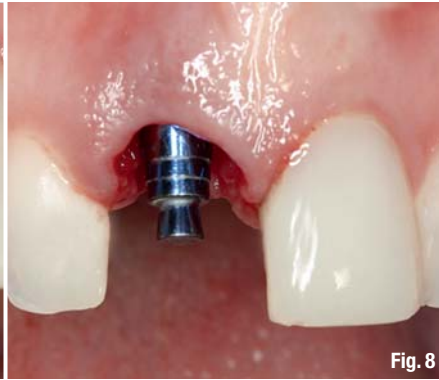

Fig. 8

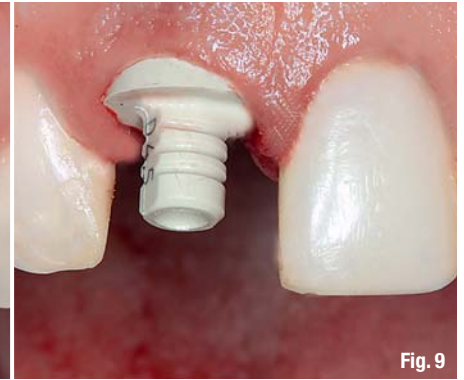

Fig. 9

palatally. Hence, its periodontal conditions differed evidently from those of the remaining dentition. The left central incisor was discoloured and had extensive composite resin restorations with inadequate fit at the margins (Fig. 1).

A possible tooth or root fracture was suspected. The patient was asked about recent injuries or trauma to the maxillary region, and she reported a traffic accident six months previously. After this incident, both incisors showed extreme sensitivity and were treated endodontically. Radiographic examination with panoramic and intra-oral X-rays revealed a root fracture of the right central incisor

2 mm below the cemento-enamel junction (Figs. 2 & 3). The tooth had a poor prognosis and needed to be extracted. In contrast, the left central incisor showed no signs of root fracture. The treatment plan included the extraction of tooth #11, an immediate implant placement and the use of an immediate provisional. In addition, the prosthetic rehabilitation of the natural tooth #21 completed the rehabilitation. All-ceramic crowns were selected as the final restorations for the two central incisors at the end of the osseointegration period of the implant.

The patient had a high smile line and was extremely concerned about her aesthetic appearance

Fig. 7_Immediate placement of a XIVE S plus implant.
Fig. 8_Final position of the implant.
Fig. 9_Insertion of an EsthetiCap provisional abutment.

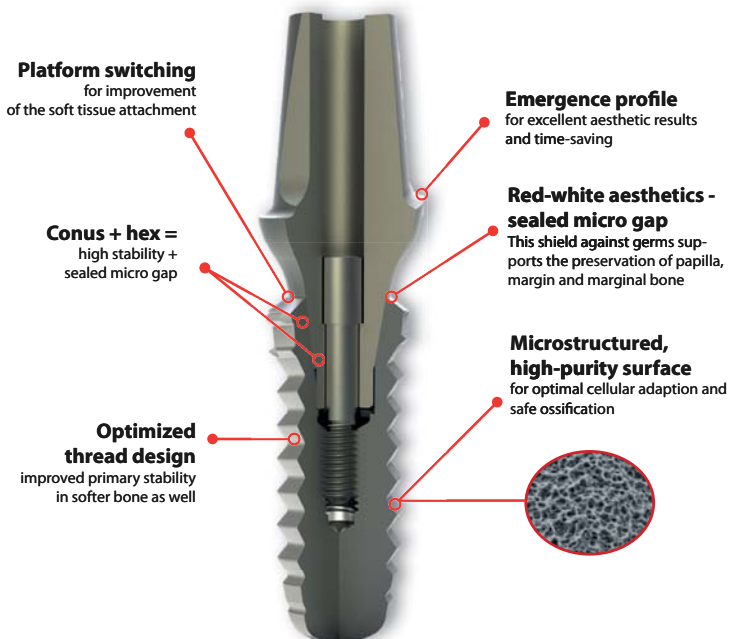
AD



YOUR ADVANTAGE! THE 2 IN 1 CONCEPT: Conical connection - with anti-rotation hex!

**DEALERS
WANTED!**

The new IMPLA™ hybrid connection



Special Promotion for your start into the IMPLA™ system:

30 implants, abutments, gingiva formers, lab analogs, transfers and surgical kit!

Promotion Code: P121154

Be ahead of your competition!

- » Wide range of trainings available for you and your team
- » Controlled German Quality
- » Great results + maximum security = satisfied customers



Call us today and become a partner.
For additional information visit our website:
www.schuetz-dental.com



IMPLA™

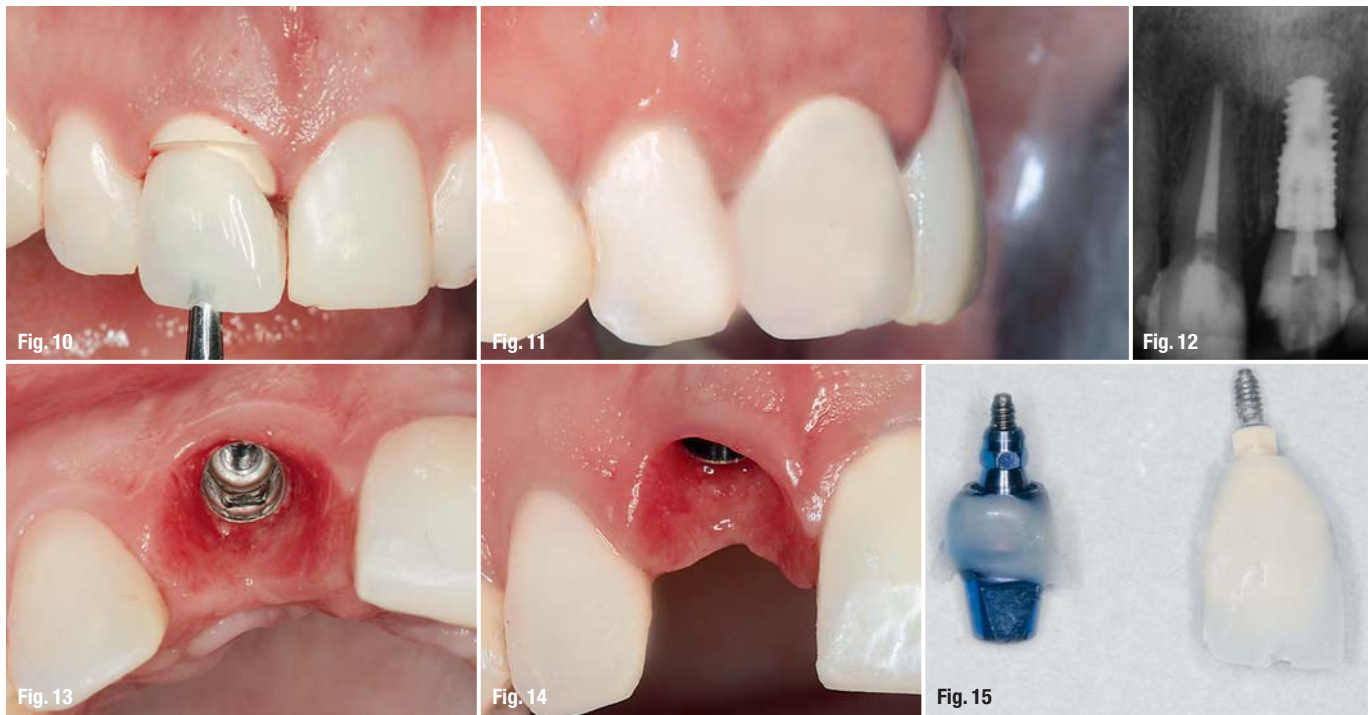

Fig. 10 Implant-supported, screw-retained provisional restoration.

Fig. 11 Clinical situation one week post-implant placement.

Fig. 12 Corresponding X-ray.

Fig. 13 Occlusal view of the soft-tissue contour at the end of osseointegration.

Fig. 14 Facial view of the soft-tissue contour at the end of osseointegration.

Fig. 15 Impression coping customised in the cervical area to match the emergence profile of the provisional crown.

at all stages of the treatment. Before the start of the surgical treatment, initial impressions were taken with alginate. Study models were fabricated based on these and then mounted on a semi-adjustable articulator. A detailed wax-up was made for tooth #11 and a provisional crown was fabricated from heat-polymerised acrylic resin. The provisional crown was trimmed at the interior surfaces for use with a provisional implant abutment.

The periodontal fibres surrounding tooth #11 in the alveolar socket were loosened with a periosteal elevator (DENTSPLY Friident) and the tooth was extracted atraumatically (Figs. 4 & 5). The horizontal fracture of the root below the cervical area of the extracted tooth verified the initial diagnosis (Fig. 6). The socket walls were considered intact and inspection revealed no signs of fenestration. Any residual fibres were scraped off. The implant site was then prepared according to the manufacturer's guidelines and a XIVESplus implant (DENTSPLY Friident; 4.5x 11 mm) was inserted with sufficient initial stability, which was mainly achieved on the palatal side of the implant site. The implant collar was placed 3 mm below the cemento-enamel junction of the adjacent teeth (Figs. 7 & 8).

The titanium TempBase abutment, which acted as the placement head, was removed from the implant and an EsthetiCap plastic abutment (both DENTSPLY Friident) was fitted on the implant (Fig. 9). The design of this anatomically shaped abutment supports the soft tissue and interdental papillae adequately. Furthermore, it enables the creation of a

suitable emergence profile from the moment of implant placement. The highly polished surfaces prohibit accumulation of dental plaque and facilitate oral hygiene. At this stage, soft-tissue support is crucial for achieving an aesthetic result for the provisional restoration and maintaining it to the final stage.

The previously fabricated provisional crown was fitted on the abutment with autopolymerised acrylic resin, maintaining the access hole on the palatal aspect for the fixation screw (Fig. 10). Furthermore, the outer contour of the provisional crown was checked repeatedly to ensure support of the gingival margin without excessive pressure, which could lead to tissue shrinkage. The provisional crown was designed 1 mm shorter than tooth #21 to avoid possible occlusal loading at maximum intercuspation or side movement (Fig. 11). The implant position in the socket and the abutment fit were checked radiographically (Fig. 12).

The osseointegration period of four months was uneventful and the soft tissue around the implant did not exhibit any signs of inflammation. The interdental papillae were maintained in shape, height and volume (Figs. 13 & 14). In order to support the soft tissue around the implant for impression taking, a prefabricated impression coping was customised using photopolymerised low-viscosity composite material (Figs. 15 & 16). For this implant, an all-ceramic prefabricated zirconium CERCON abutment (DENTSPLY Friident) was selected. This abutment offers adequate soft-tissue support and a suitable



Behind every successful
implantologist is an Implantmed



Scan the QR code with
your mobile telephone
for more information on
Implantmed

With the new Implantmed you perform implant procedures with maximum precision. The unit is easy to operate and guarantees longer working without fatigue – thanks to the **lightweight**, yet **powerful motor** and the ergonomically-shaped contra-angle handpiece. And the integrated **thread cutter function** helps you with especially hard bone.

implantmed

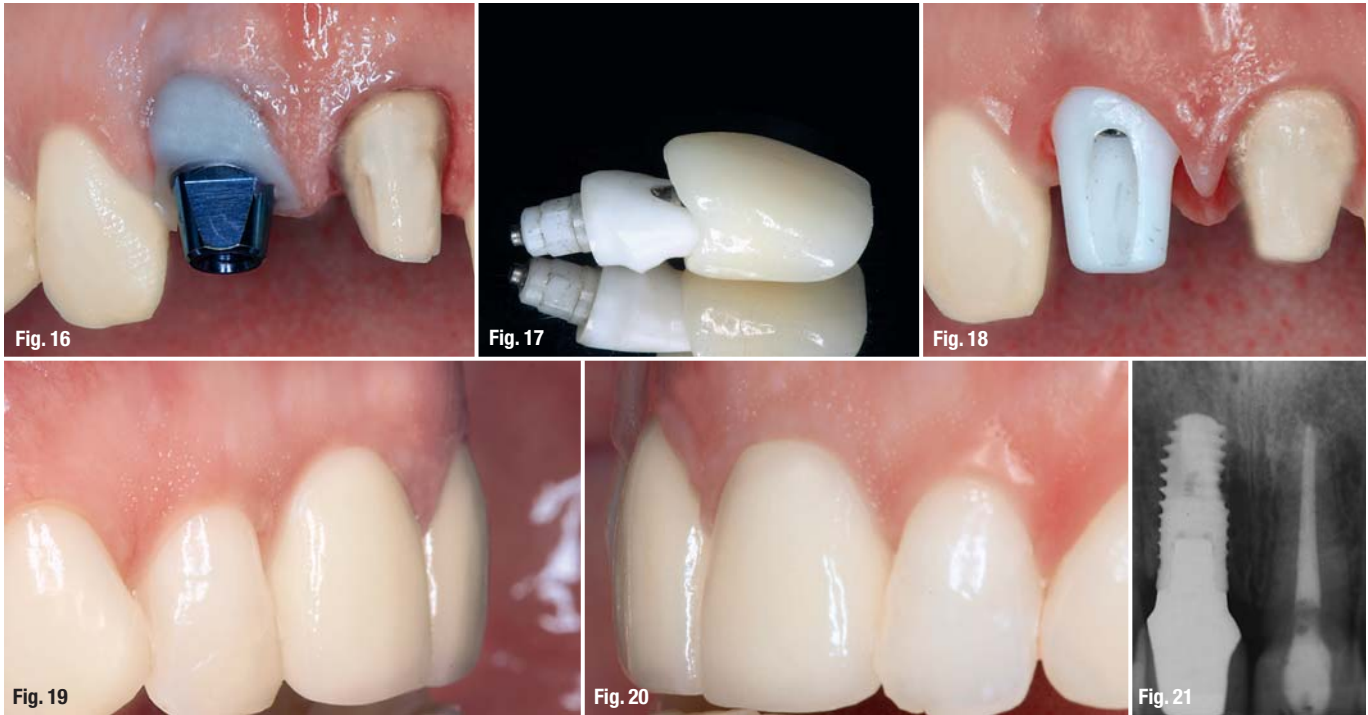

Fig. 16 Impression for the prepared natural tooth and the XiVE S plus implant.

Fig. 17 All-ceramic crown and corresponding implant abutment (CERCON).

Fig. 18 Try-in of the modified ceramic CERCON abutment.

Fig. 19 Final clinical result: buccal view of the implant restoration.

Fig. 20 Buccal view of the restored natural tooth.

Fig. 21 Radiographic control at one year post-implant placement.

emergence profile for the crown (Figs. 17 & 18). The use of ceramic abutments prevents discoloration in the gingival area even when the soft issue is thin. Two porcelain crowns were fabricated to the desired shape and colour (Figs. 19 & 20). The final result fulfilled the patient's aesthetic demands and her initial insecurity dissolved after the insertion of the implant and the provisional restoration. The hard- and soft-tissue condition around the implant was stable at the one-year recall (Fig. 21).

Discussion and conclusion

Implant placement subsequent to tooth extraction in conjunction with the use of provisionals in the anterior maxillary region is certainly challenging for the dental practitioner. However, this treatment modality offers several advantages, including reduced clinical time, a single local anaesthetic injection, a flapless procedure and immediate placement of the implants. From the patient's point of view, the immediate incorporation of a fixed implant-supported provisional restoration is very acceptable and even requested. With the clinical procedure described here, both dentist and patient can evaluate the aesthetics of the restoration. Soft-tissue support is enhanced and achievement of the desired result is facilitated. With initial implant stability, proper tissue management and correct use of the available implant components, a predictable aesthetic result can be produced. On the other hand, occlusal control, oral hygiene and a regular recall programme should be considered prerequisites for maintaining a long-lasting restoration.

Single-tooth implants have shown high success rates in both the anterior and the posterior regions of the maxilla and the mandible.¹⁻⁴ Immediate post-extraction implant placement has been done since the early years of the clinical application of implants with very good clinical outcomes.⁵⁻⁸ Decisive factors for immediate implant placement are lack of infection in the periodontal tissues and an intact tooth socket. Immediate incorporation of a temporary restoration has been presented in the literature with most encouraging results.⁷⁻¹⁴ Although clinical experiences have advocated this clinical technique for many years, more extended long-term clinical studies are necessary to prove the efficacy of the method and establish a stable clinical protocol.

Editorial note: A complete list of references is available from the publisher.

_contact

implants

Dr Stefanos Kourtis

Dept. of Prosthodontics, University of Athens
Plaza Chrys. Smyrnis 14
17121 Athens
Greece

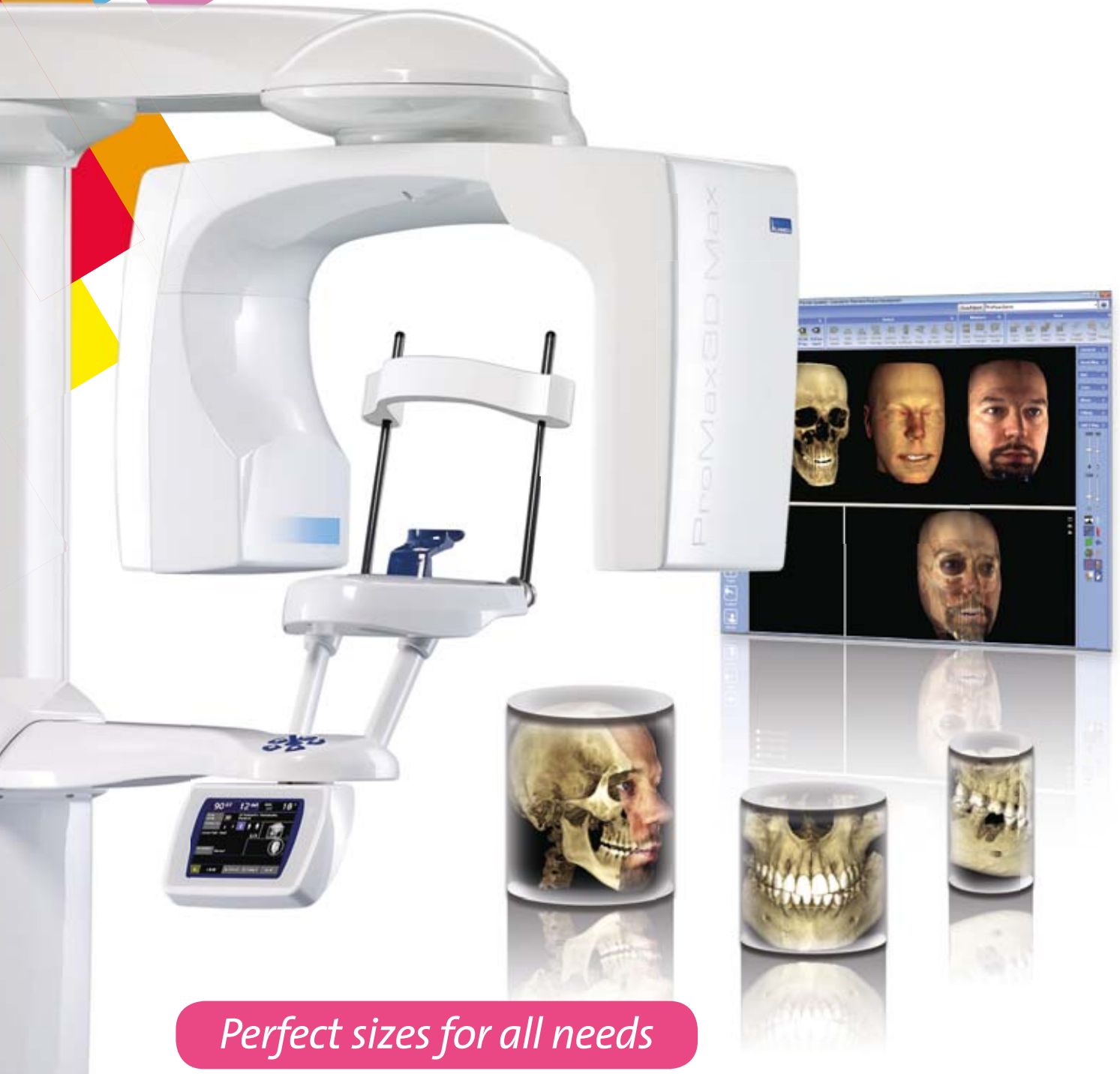Tel.: +30 21 0 935 7306

stefkour@dent.uoa.gr



Planmeca ProMax[®] 3D

Unique product family



Perfect sizes for all needs

3D X-ray • 3D photo • panoramic • cephalometric

Romexis[®] software completes 3D perfection



Digital perfection™

More information

www.planmeca.com

Planmeca Oy
Asentajankatu 6, 00880 Helsinki, Finland
tel. +358 20 7795 500, fax +358 20 7795 555
sales@planmeca.com

PLANMECA