

# The most important years in implantology

## A very personal retrospect

**Author\_**Dr Georg Bach, Germany

### \_Introduction

It all started with an inquiry from a well-known professional journal of implantology asking for a contribution to acknowledge their having been in business for 15 years. Then there was the incidental telephone call by an academic teacher who had accompanied and supported me in my first steps in implantology. When I asked him about the upcoming publication project, I received a both spontaneous and surprising reply, "The last 15 years—those were the most important years in implantology"! This from a renowned university professor who was instrumental in establishing implantology—I was impressed. Later on I had to ask myself, "Is this really true?" The result of my tracing this development is this article—a personal retrospective.

### \_Phases of implantology

If one considers oral implantology with regard to its major developments, three phases are evident: (i) the empirical and experimental phase; (ii) the arrival of implantology in universities and science; (iii) the mass phenomenon of implantology. I would like to add that this is a rough and probably superficial division to some extent. Please, how-

ever, allow me to apply it within the scope of this personal—and not exhaustive—review.

Looking back at these past fifteen years, I will barely touch on phase II, but will discuss phase III fully. This entails different directions and priority areas that colleagues working in implantology experienced. When I browsed through implantology textbooks and journals from this period, I realised even more that implantology had undergone considerable change in this relatively short period of 15 years. I would like to recount my highlights of implantology from this period in the following paragraphs.

### \_Farewell to the tristesse of papers

A seemingly minor issue to start with: the variety and quality of dentistry-specific print media and of digital media, particularly print layout, has developed substantially during the past 15 years. This holds true not only for implantology, but also for dentistry as a whole. The appearance of some professional journals up until the mid-1990s was reminiscent of an official legal amendment, but amazing things have happened since. The quality of colour printing (which is the norm now, but used to be subject to a surcharge for authors who wanted to include colour images), the accuracy of images, the paper—all of these make for a high

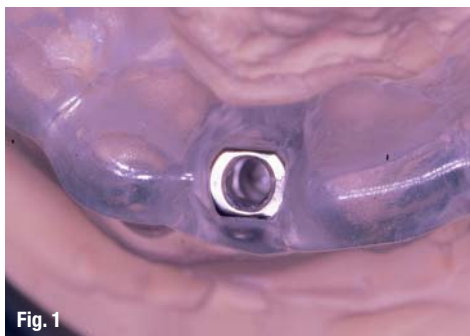


Fig. 1

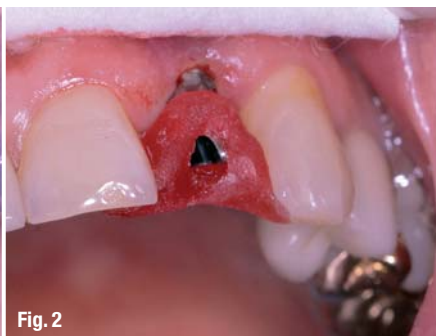

Fig. 2

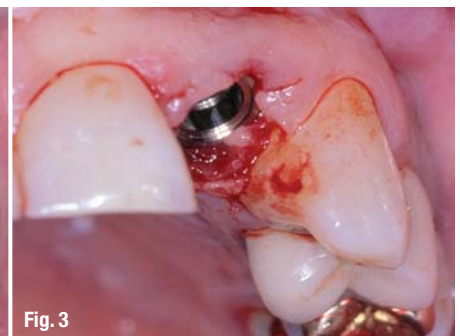

Fig. 3

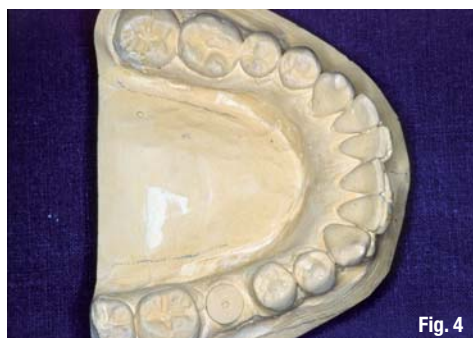

Fig. 4

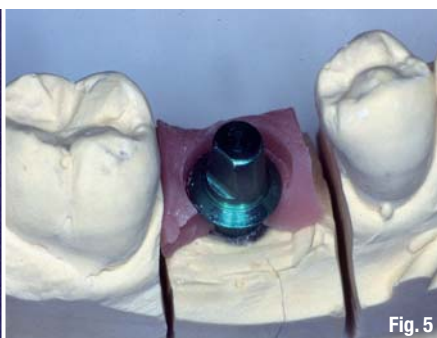


Fig. 5

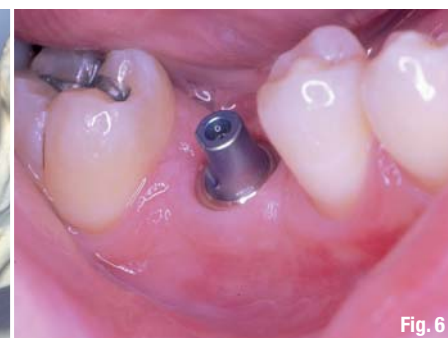

Fig. 6

quality appearance and leave a lasting impression on the reader. This has clearly been an advantage also for implantology because now highly complex correlations can be more easily conveyed and "sometimes a picture is worth a thousand words". Ideally, e-learning and electronic professional journals supplement the current training needs of the younger generation of dentists especially.

### The end of dogmas

While implantology was marked by many dogmas from its beginning and the mid-1990s, this had changed at the time when our 15-year observation period begins. However, implantology was later called into question in its entirety. Whether it was healing times, waiting times after augmentation or prosthetic concepts—everything underwent scrutiny. On the one hand, some of these dogmas did in fact prove to be no longer sustainable because of remarkable developments, especially improvements in implant surfaces. On the other hand, the mark was at times overshoot in the elimination of other dogmas, creating the need to back-track. This was a painful experience for both patients and implantologists.

One dogma that we encountered in the observation period was that of a strict refusal of immediate implant placement. There is general consensus today, however, that under suitable conditions an immediate implant placement can be a high quality and sustainable alternative to established procedures. One clinical case shows an immediate implant placement in the maxillary anterior teeth: the extraction and the immediate

implant placement of a maxillary anterior tooth that was not worth preserving under the guidance of a drilling template and implant position (Fig. 1), transfer into the oral cavity (Fig. 2), and the condition immediately after insertion of the implant crown (Fig. 3).

### The prospering of the implant market

A welcome variety of new implants, implant forms and prosthetic options has become a reality in the past 15 years. Special implants were developed for special indications so that now even a mandibular molar can be replaced by a corresponding sized implant, followed by insertion of a corresponding sized implant crown. Figures 4 to 7 show the clinical and dental appearance of these in a patient. Implantologists who placed several hundred implants annually were considered the big players on the implant market in the 1990s. Achieving the mark of 100,000 implants placed per year in Germany signified that the peak had been reached. This was not the case, since the one-million mark was also reached within the scope of a rapid, almost unimpeded development. While the increase has been slower in recent years and global economic developments even caused a brief decline, today we can assume that the implant market will continue to grow. The maximum growth phase falls into our observed period.

### Development in the eyes of implant manufacturers

From manufacturer to global player—this would be an accurate description of the development of

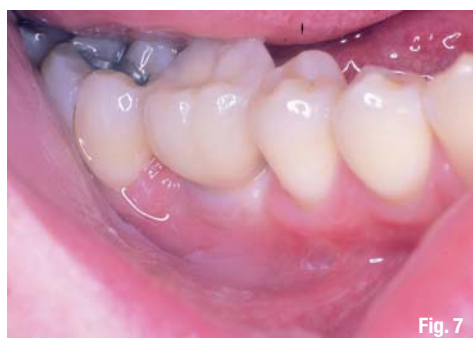

Fig. 7

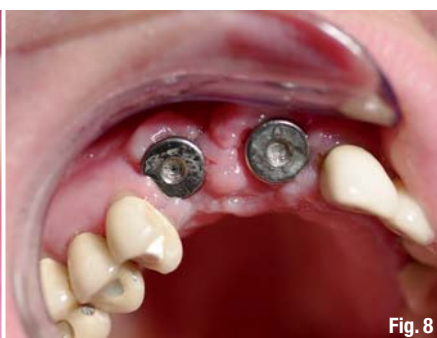

Fig. 8

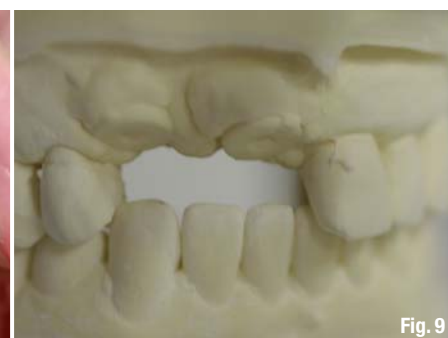
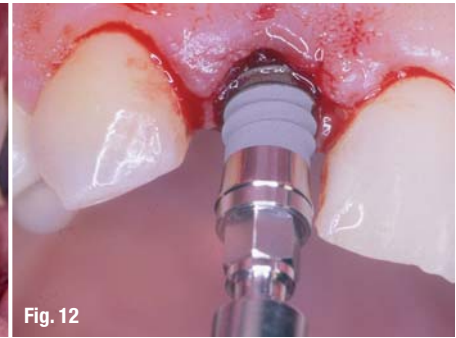
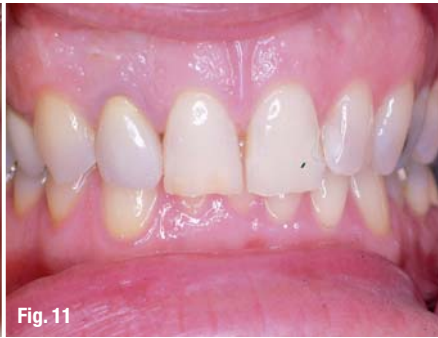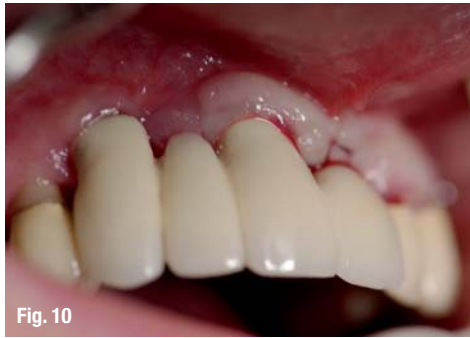Fig. 9



some implant manufacturers. The development of some of these companies over the past 15 years, the size of their companies and the number of their employees today are indeed impressive. And these prosperous companies share other characteristics as well: the acquisition of products and entire firms in order to expand or supplement their product portfolio and their pressing on to the field of digital dentistry (CAD/CAM, planning, etc.), into which these global players invest large sums of money. Revenues must be generated so that these investments can be made—and they are still made, albeit declining owing to the economic crisis.

Still, the implant market is booming. Although the consistently two-digit annual growth rates some implant manufacturers had started to become used to have become more moderate today, a great deal of money can be made with implants. As a result, an ever-increasing number of implant suppliers and systems make it impossible for the individual user to keep track. Aside from new systems, an increasing number of generics are being launched on the market.

### Focus on red–white aesthetics

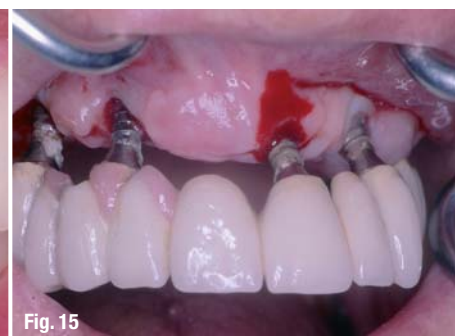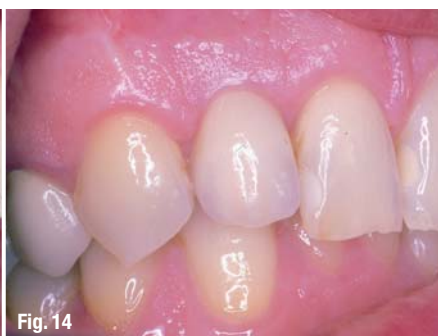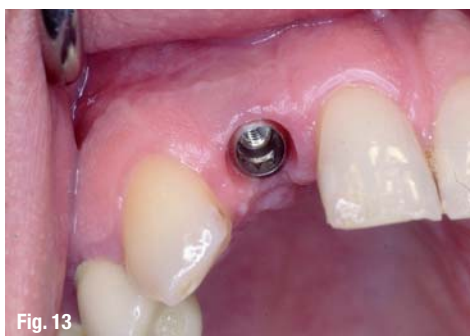The President of the German Society for Dental Implantology (Deutsche Gesellschaft für Zahnärztliche Implantologie), Prof. Frank Palm, aptly remarked, "What was celebrated as a triumph for some colleagues 20 years ago is today taken to court." Dentists who practised implantology were not prepared to find themselves confronted with a debate that had spread from North America to Europe: that of red–white aes-

thetics. This new focus on achieving the highest possible aesthetics for implant–prosthetic treatments was linked to implantology and distanced itself from surgery, which had been dominant up until that time.

In the early phase of implantology, the main focus was on safe placement and the best possible placement in the bone, sometimes even at the expense of subsequent prosthesis treatment owing to unfavourable placement of the artificial abutment teeth. Now, however, prosthetic standards and issues have become the centre of the discussion. Placement techniques were modified and new techniques were established in order to satisfy these requirements. Patients no longer, or only occasionally, accept demanding and complex cases like the following case.

Both implants in the anterior maxillary region were placed too far buccally, and there was a gap of 5.5 mm between the implant shoulder and the cemento–enamel junction of the adjacent teeth (Figs. 8–10). Treatment with a long-term temporary restoration would only have yielded an unsatisfactory aesthetic result. However, under certain surgical and dental conditions—as shown in our second example—superior results and stability for a period of ten years can be achieved even with challenging initial situations. In 1999, an immediate implant was placed in region 12. The following images show the steps of treatment (Figs. 11–13). The last image shows the condition after ten years (Fig. 14).

This development was made possible mainly by massive improvements in the area of augmentations,





which can now be performed with significantly higher predictability. This development was further enhanced by a considerable improvement in the training of implantologists. These improvements are significant for both undergraduate study and post-graduate training. Thus, the universities and professional associations who have contributed immensely in this area deserve much credit in this respect.

### The battle of healing times

It was but an episode, yet one that caused an incredible furor at the time: the debate about shortened healing times. Stimulated by a media hype in which the specialised press only played second fiddle and the lay press appeared to be in the lead, the healing times of some implant manufacturers were inflated. Values were corrected downwards almost on a daily basis. Some manufacturers went along with it, while others remained firm. Some participants felt they needed to be at the forefront, others stayed out of it. A short but remarkable ascent was followed by a rapid crash.

A personal highlight for me was an article in a tabloid newspaper that said, "Extraction in the morning; directly followed by augmentation and implantation; a firmly seated supra-construction implemented at lunch time, and then endless servings of spare ribs"! As can be seen from this euphoric statement, some got carried away, while others had to painfully back-track. What remains is the realisation that, owing to improved surfaces and other conditions, the long healing times recommended in the early phase of implantology can in fact be reduced considerably, but not at any cost.

### New options for improving the implant site

The afore-mentioned dominance of prosthetic implantology was only possible because many new and safer augmentation procedures were established during the observation period, enabling dentists to design the osseous bed for the implant as desired. Revolutionary augmentation procedures in the area of the maxillary posterior teeth, which had been the focus of discussion in the first year of the period in question, constituted another important approach for real progress.

Thanks to surgical techniques for sinus lifts, which underwent an incredible number of modifications also with regard to less invasive procedures, it was possible to treat areas of the jaw that had previously been considered impossible or that could only be restored for implantation by way of highly invasive orthodontic procedures. While initial sinus-lift procedures were generally reserved for highly specialised centres, they have now become common knowledge in implantology and are offered and performed extensively.

### Establishing virtual implantology

It seems easy to figure out what the old-school fraction must have thought about the new planning and placement options for oral implants. This fraction had already had

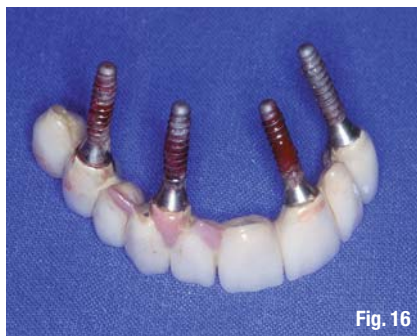

Fig. 16

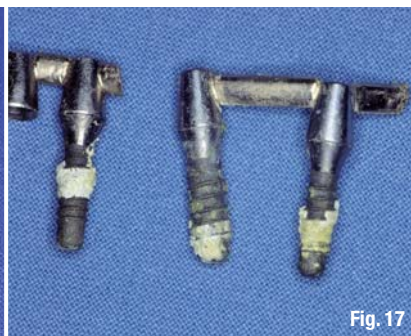
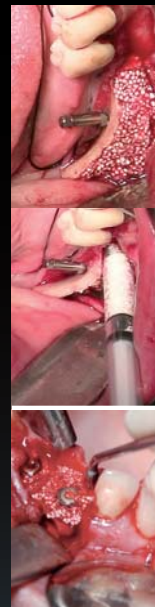
Fig. 17

sticky granules

bionic

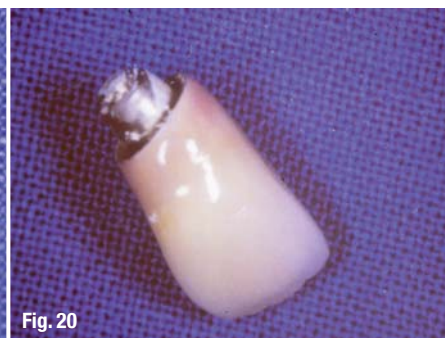
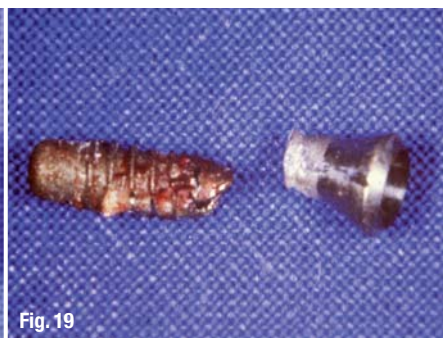
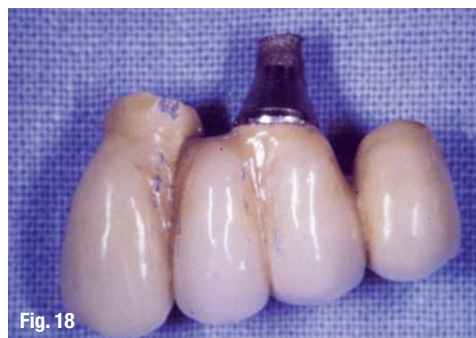**easy-graft®**  
**CRYSTAL**

**Ingenious:** Simple handling and accelerated osteoconduction for long-term volume preservation.

**SUNSTAR**  
**GUIDOR®**

Degradable Solutions AG  
A Company of the Sunstar Group  
Wagistrasse 23  
CH-8952 Schlieren / Zurich  
[www.easy-graft.com](http://www.easy-graft.com)



a hard time accepting the development from surgical to prosthetic implantology, and they were strictly against the new digital procedures that were emerging incredibly quickly. With the rapid spread of dental volume tomography, which opened a new dimension to dental image diagnostics, a multitude of planning programs and aids were placed on the market.

The suggestion by some opinion leaders to define validity and establish standards with regard to these new techniques, which are generally based on 3-D X-ray data, was especially frowned upon. I feel that a good compromise has been reached, owing to anticipatory and serious discussions held during consensus conferences and congresses, as well as at universities and within the dental associations.

These new techniques are immensely helpful in the treatment of complex cases, and they are even indispensable for highly complex cases. The treatment of simple cases usually does not require the use of these techniques. In fact, they should not be used in such cases owing to the radiation exposure when obtaining 3-D data.

### Of promises and realities

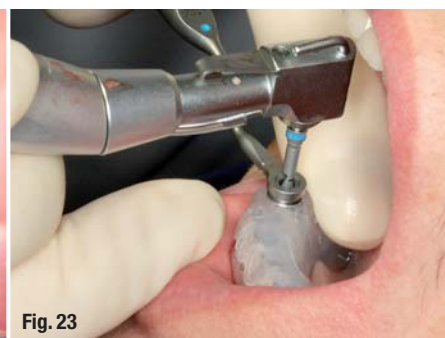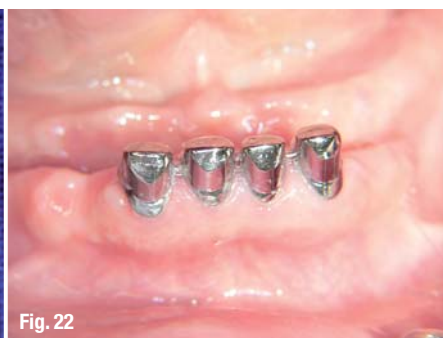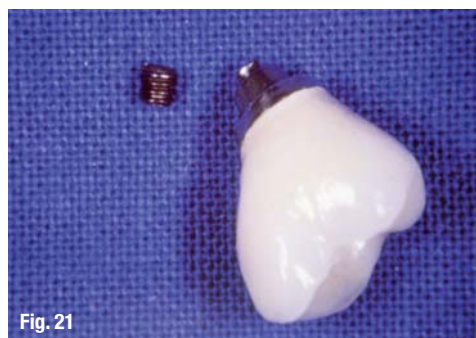
Themes of the congresses during the first decade of the observation period contained generally positive statements and depicted new opportunities in implantology, which exceeded the then current options by far and expressed a belief in boundless growth. This coincided with many posi-

tive statements and evaluations by implant manufacturers and distributors. However, all this changed considerably during the past five years.

Suddenly, new topics were given priority, which shaped specialists' conventions—topics that had previously been partially suppressed if not negated. I remember only too well the implant congress held by a very important American implant manufacturer in Frankfurt/Main in 1998, where I reported on a concept for the treatment of peri-implantitis developed at the University of Freiburg and was then rebuked by the main speaker, who was from the USA, during the ensuing panel discussion. He asserted that he had "not seen one case of peri-implantitis in twenty years of implantology—this phenomenon does not exist and, if it occurs, it can only be attributed to a lack in skill on the part of the implantologists." How times have changed. However, trouble-shooting and complications in implantology and even the word "failure" have been mentioned in the themes of many congresses held by leading professional associations of implantology in the past years.

### Patients' expectations

While a consistently positive and at times even euphoric tone prevailed regarding the topic of implants for many years, a few critical voices and later increasing criticism emerged at the beginning of the observation period. This was—concurrent with a noticeable increase in the number of implants—based on the considerable increase in





implantology failures and complications. The following images depict total implantological failure—the loss of a purely implant-supported complete maxillary restoration caused by an infaust peri-implantitis (Figs. 15–17), leaving profound osseous defects.

However, in line with the consistently positive evaluation of implants and the persisting promise that the use of implants would yield optimum results always—and often publicised by the lay press—our patients' expectations have increased considerably in the past 15 years. Patients assumed that, regardless of the individual situation, he or she would always receive the optimum results. In this regard, it seems reasonable to maintain a self-critical attitude and to concede that we did not always contradict this general assumption vehemently enough.

And then what was bound to happen, happened: at times, the result was not what the patient had expected. An awkward situation arises when the dentist, based on the initial diagnosis, considers the result to be successful and the patient considers it a failure. A long-time legal expert sums up this situation accurately by stating that, "Two-thirds of all

pending court proceedings were filed by patients whose expectations were disappointed." Rather unfortunately, the increasing number of court proceedings are mostly related to implantology. It cannot be by chance that the premiums for mandatory professional liability insurance have increased considerably.

### Emerging criticism

German periodontists Dr Thomas Kocher referred to implantology as "the red light district of dentistry". Whether this evaluation is justified is a matter to be decided individually. Personally, I do not agree with this evaluation, but a grain of truth might be found in its reference to overtreatment. In this regard, the extraction of teeth in favour of implants, even when not indicated, is a concern voiced increasingly by periodontists and those in favour of conservative treatment.

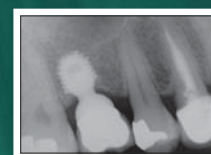We have to address this issue by individual evaluation of each patient, as well as through academic discussion. Implant versus tooth preservation has been a frequent debate at conventions and implant symposia in recent years. In my opinion, this would not have been possible ten years ago.

AD


# Minimize bone grafting procedures!

## With Bicon's SHORT® Implants you can:

- ▶ Avoid vital structures.
- ▶ Minimize bone grafting procedures.
- ▶ Maximize implant placement possibilities.
- ▶ Increase patient acceptance.
- ▶ Offer single unit restorations without splinting.
- ▶ Offer a clinically proven solution.



**SHORT®**  
IMPLANTS



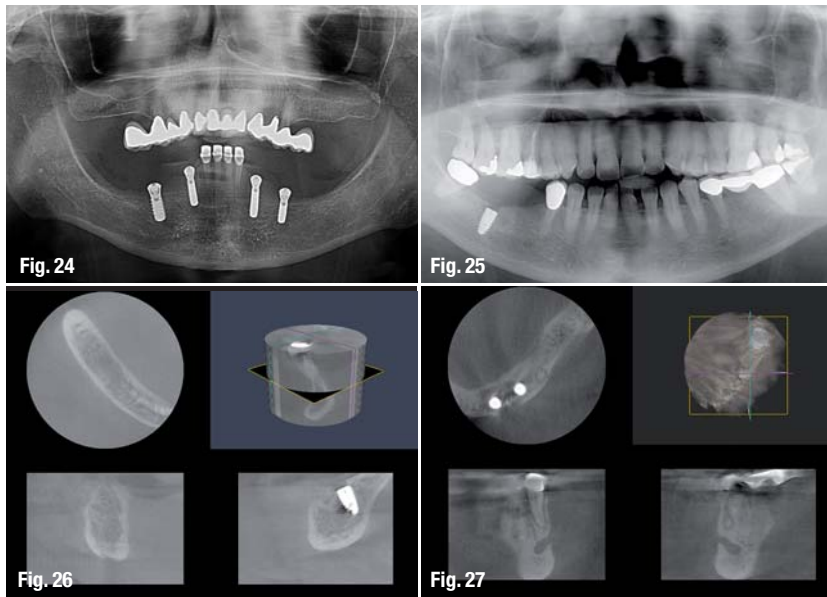
**bicon**  
DENTAL IMPLANTS

Bicon Europe Ltd.

Hauptstr. 1 ■ 55491 Buechenbeuren ■ Germany

Phone +49 (0)6543 818200 ■ Fax +49 (0)6543 818201

germany@bicon.com ■ [www.bicon.com](http://www.bicon.com)



3-D technology constituted a quantum leap for dental diagnostic imaging as a whole.

Today, we have almost unbelievable possibilities at our disposal that even the greatest optimists would not have considered possible 15 years ago: highly complex patient cases can now receive minimally invasive treatment and have implants placed even without the need for augmentation.

Our first case shows a highly atrophied mandible, in which four implants could be placed without any prior augmentation owing to 3-D data and planning (Figs. 22–24). Three-dimensional diagnostics are sometimes also employed to clarify facts when complications have arisen, for example neural lesions after implantation (Figs. 25 & 26) and bone necrosis after administration of bisphosphonates, and erroneously diagnosed as peri-implantitis (Fig. 27).

### \_Trouble-shooting concepts

Unexpected complications, such as implant fracture and failure of implant supra-structure connections (Figs. 18–21), necessitated the development of surgical and prosthetic trouble-shooting concepts and modification of constructions in implant and abutment design. However, these were not readily available and have not yet been finally agreed upon. In other words, they cannot be said to be common knowledge in implantology, at least not in the treatment of peri-implantitis. Similar statements can be made with regard to pre-implantology arguments, where a pleasing variety of surgical techniques and materials is listed, but no generally valid scheme has been agreed upon.

The fact that the need to develop and convey these trouble-shooting concepts is generally recognised today and that these concepts are yet widely supported by the participants on the implant market is gratifying. The specialist press has made a valuable contribution here and continues to do so—numerous articles that received a great deal of attention during the past 15 years are those that dealt with implantology and implant-prosthetic trouble-shooting.

### \_Digital implantology

I consider the establishment of 3-D diagnostic imaging, with all associated possibilities, to be the significant development during the 15-year observation period. It is true that only implantologists used the new 3-D technology during the initial phase of dental volume tomography (because they made up the group of dentists who could actually afford this expensive equipment); nevertheless,

### \_My personal conclusions

It is difficult to draw a conclusion regarding the development of implantology over the past 15 years because it has been so multifaceted and rapid. To conclude, I would therefore like to quote my academic teacher and former supervisor, Prof. Wilfried Schilli, who, as a founding member of the International Team for Implantology, was undoubtedly among the pioneers of implantology and has contributed to improving implantology through his university work: "Who would have thought that implantology could develop like it did in less than twenty years."

This very true statement encompasses many aspects: the admiration and appreciation of what has been achieved, the satisfaction with having initiated a procedure that is considered to be the safest in the entire field of medicine, and some criticism regarding any development in oral implantology that did not turn so well or went off course.

#### \_contact

#### implants

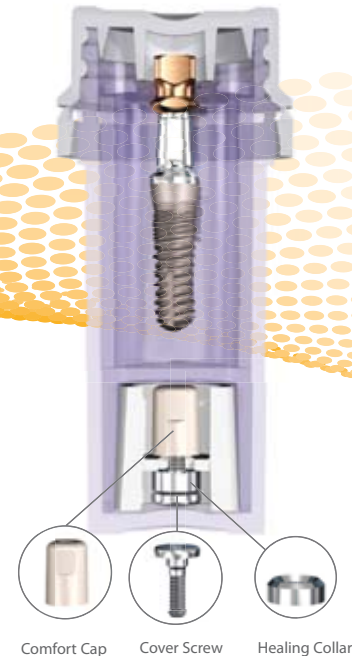
##### Dr Georg Bach

Rathausgasse 36  
79098 Freiburg/Breisgau  
Germany

Tel.: +49 761 22592

doc.bach@t-online.de

# Designed For Success, Packaged For Value



## SwishPlant™ Implant

All-in-One Packaging includes implant, straight abutment/transfer, cover screw & healing collar for only €145

## Swish™ Implant System Advantages:

Internal Octagon (Niznick US Pat. #4,960,381 Licensed to Straumann)

Prosthetic compatibility with Straumann's Tissue-Level implants (Standard, Standard Plus and Tapered Effect)

Internal square broached in flats of octagon for fixture-mount engagement (Pat. Pend.)

### Two Implant Designs & Packaging Options

Allows for selection based on price, packaging or thread design

**SwishPlus™** : €115 includes cover screw, healing collar & carrier compatible with Straumann tool & standard ratchet

- ① 2mm neck half textured for tissue-level or esthetic placement
- ② Micro-grooves for improved tissue attachment & reduced stress
- ③ Progressively-deeper single-lead threads for increased surface area & complete surgical compatibility
- ④ Self-tapping groove for increased initial stability
- ⑤ Tapered apical end to initiate self-tapping

**SwishPlant™** : €145 includes cover screw, healing collar, comfort cap & straight abutment/transfer

- ① 2mm neck lightly textured for bone- or tissue-level placement
- ② Micro-threads for improved tissue attachment, reduced stress & increased stability
- ③ Progressively-deeper double-lead threads for increased surface area & faster insertion
- ④ Self-tapping groove for increased initial stability
- ⑤ Tapered body for soft bone expansion




## SwishPlus™

Straight with Micro-Grooves & Straumann Threads

## SwishPlant™

Tapered with Micro-Threads & Double-Lead Threads



**Intro Offer: Make the switch & receive a FREE implant<sup>2</sup>**

All trademarks are property of their respective companies.

<sup>1</sup>System Variation: 3.3mmD & 5.7mmD SwishPlus™ are tapered; 3.3mmD also has SwishPlant™ threads.

<sup>2</sup>Terms and conditions apply.

**www.implantdirect.eu | 00800 4030 4030**