

# implants

international magazine of oral implantology

1 2012

| **overview**

The most important years in implantology

| **case report**

Immediate functional loading of the edentulous mandible

| **case study**

The same-day tooth: From the diagnosis to the final restoration







4<sup>TH</sup> INTERNATIONAL

# CAMLOG CONGRESS

MAY 3<sup>RD</sup> – 5<sup>TH</sup>, 2012

LUCERNE, SWITZERLAND



## FEEL THE PULSE OF SCIENCE IN THE HEART OF SWITZERLAND

- "State of the art" in implant dentistry
- Internationally renowned scientific committee, well-known speakers
- First-class workshops
- Lucerne – world-famous congress venue
- Groovy party – "Let's rock the Alps!"
- Attractive partner programs in Lucerne and surroundings
- Excellent price-performance ratio

## SCIENTIFIC COMMITTEE

Prof Jürgen Becker, Prof Fernando Guerra, Prof Frank Schwarz,  
Prof Thomas Taylor, Prof Hendrik Terheyden,  
Prof Georg Watzek, Prof Axel Zöllner



# Extreme points of view



Dr Georg Bach

**Extreme points of view** tamper with their seemingly convincing advantage of making hard facts appear as simple, clear and understandable pieces of information. Extreme points of view, however, also have one distinct disadvantage: They are usually simply wrong.

Currently, oral implantology is certainly undergoing a comprehensive process of change. The "implantological knowledge" of past decades has been turned upside down by the rush of developments and innovations of the past few years. Nothing seems to be way it once used to be. In the light of tremendous changes such as the following, falling for extreme points of view is a seemingly obvious response:

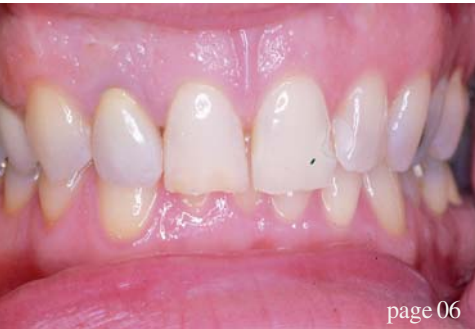Not only do whole treatment philosophies clash, but there is also a gaping conflict between the generations. Naturally, younger implantologists are attracted by new, digital opportunities introduced to our discipline, whereas older colleagues tend to rely on proven and conventional methods and usually focus on surgical solutions. Now, if we decided to name the former "computer game implantology" and the latter "medieval implantology" as a consequence, of course we would react in an extreme way in both of the two cases and, more importantly, we would also be wrong.

Instead, we should seek to balance our points of view to find answers to the most pressing issues of our discipline. In this tune, finding a common language which can satisfy both of these positions would undoubtedly be helpful. A possible impetus for starting the quest for a common language is provided by the initiative "Quality-driven implantology" by the German Society for Dental Implantology (Deutsche Gesellschaft für Zahnärztliche Implantologie, DGZI). It was launched only this year and will be the common theme for all future activities of the DGZI, including this issue of **implants**, the recently relaunched DGZI curriculum and our annual DGZI conference in the fall.

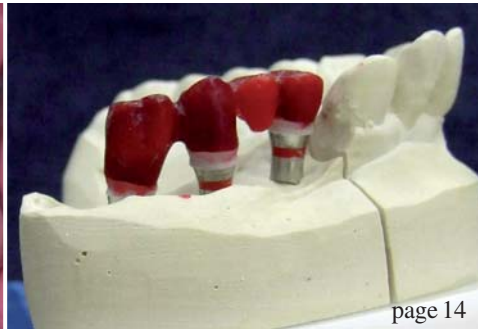Today I should also like to mention that we will meet for our annual conference in the Hanseatic City of Hamburg on 5 and 6 October, 2012. In this city of rich tradition, the DGZI, the oldest professional society for implantology in Europe, will contribute to finding answers to the questions resulting from the recent changes in our discipline—from your points of view.

With best regards,

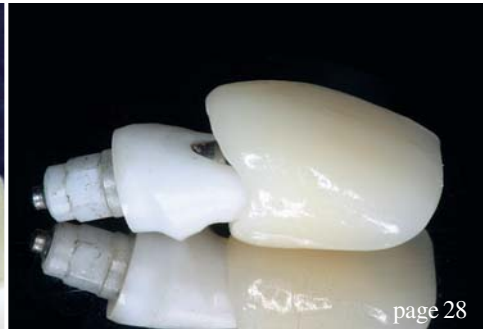Dr. Georg Bach



page 06



page 14



page 28

**| editorial**

03 **Extreme points of view**  
| Dr Georg Bach

**| overview**

06 **The most important years in implantology**  
| Dr Georg Bach

**| case report**

14 **Consideration of an uncommon approach in the atrophied posterior zone**  
| Dr Maen Aburas et al.

18 **Immediate functional loading of the edentulous mandible**  
| Dr Suhail M. Boutros

**| case study**

22 **New concepts in computer-guided implantology—Part II**  
| Dr Gian Luigi Telara

28 **The same-day tooth: From the diagnosis to the final restoration**  
| Dr Stefanos G. Kourtis

**| industry report**

34 **Minimally invasive crown lengthening as an alternative to implant treatment**  
| Prof Marcel Wainwright

**| education**

38 **Annual award for the advancement of dental research and development**  
| ITI Center

39 **Promotion of knowledge and international exchange at 20 ITI Scholarship Centers**  
| ITI Center

**| meeting**

40 **Mastering Tissue Response Successfully**

41 **International events 2012**

**| news**

42 **Manufacturer News**

48 **News**

**| about the publisher**

50 | imprint



Cover image "The Champions® implant system — Quality made in Germany" courtesy of Champions Implants, [www.champions-implants.com](http://www.champions-implants.com)



page 34

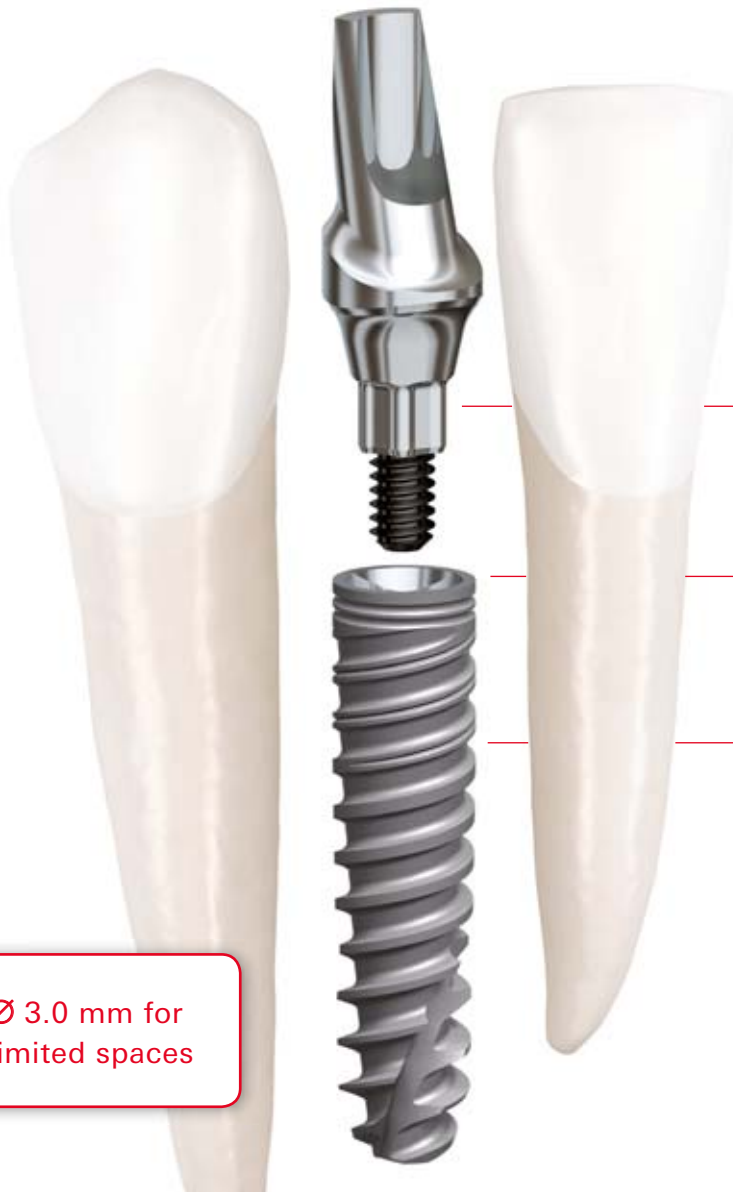

page 38



page 48

# Smaller and stronger.



Safe implant placement in areas with limited space.

Maximum material strength and strong sealed connection.

High initial stability and bone preservation.

NEW

Ø 3.0 mm for limited spaces

**It's called NobelActive 3.0.** This unique implant is the ideal solution for narrow spaces in the anterior region. The drilling procedure is designed to retain as much bone as possible, while the implant body and thread design condenses bone during insertion enhancing initial stability. The sharp apex and cutting blades enable you to adjust the implant position for optimal restorative orien-

tation. Together with the strong sealed connection and built-in platform shifting, NobelActive 3.0 allows you to safely produce excellent esthetic results. After 45 years as a dental innovator we have the experience to bring you future-proof and reliable technologies for effective patient treatment. **Their smile, your skill, our solutions.**



Visit [nobelbiocare.com/active3](http://nobelbiocare.com/active3)





# The most important years in implantology

## A very personal retrospect

Author\_Dr Georg Bach, Germany

### \_Introduction

It all started with an inquiry from a well-known professional journal of implantology asking for a contribution to acknowledge their having been in business for 15 years. Then there was the incidental telephone call by an academic teacher who had accompanied and supported me in my first steps in implantology. When I asked him about the upcoming publication project, I received a both spontaneous and surprising reply, "The last 15 years—those were the most important years in implantology"! This from a renowned university professor who was instrumental in establishing implantology—I was impressed. Later on I had to ask myself, "Is this really true?" The result of my tracing this development is this article—a personal retrospective.

### \_Phases of implantology

If one considers oral implantology with regard to its major developments, three phases are evident: (i) the empirical and experimental phase; (ii) the arrival of implantology in universities and science; (iii) the mass phenomenon of implantology. I would like to add that this is a rough and probably superficial division to some extent. Please, how-

ever, allow me to apply it within the scope of this personal—and not exhaustive—review.

Looking back at these past fifteen years, I will barely touch on phase II, but will discuss phase III fully. This entails different directions and priority areas that colleagues working in implantology experienced. When I browsed through implantology textbooks and journals from this period, I realised even more that implantology had undergone considerable change in this relatively short period of 15 years. I would like to recount my highlights of implantology from this period in the following paragraphs.

### \_Farewell to the tristesse of papers

A seemingly minor issue to start with: the variety and quality of dentistry-specific print media and of digital media, particularly print layout, has developed substantially during the past 15 years. This holds true not only for implantology, but also for dentistry as a whole. The appearance of some professional journals up until the mid-1990s was reminiscent of an official legal amendment, but amazing things have happened since. The quality of colour printing (which is the norm now, but used to be subject to a surcharge for authors who wanted to include colour images), the accuracy of images, the paper—all of these make for a high

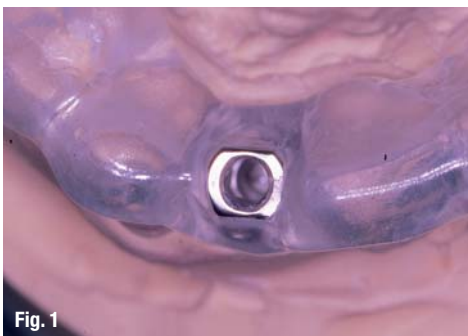


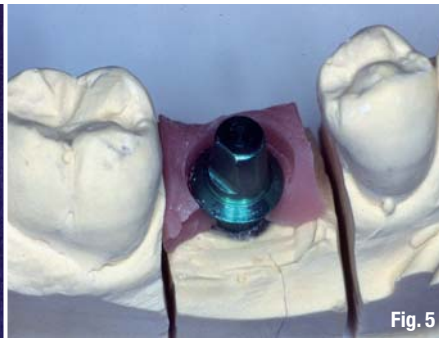
Fig. 1

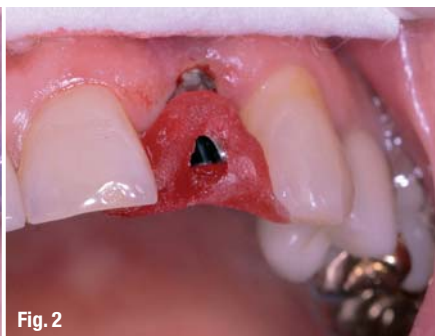

Fig. 2

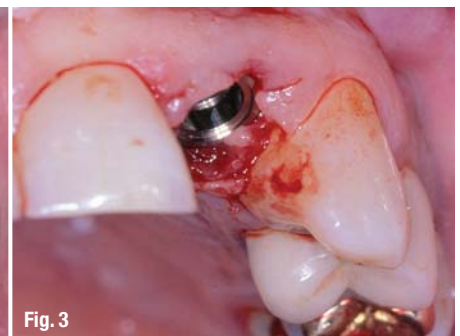
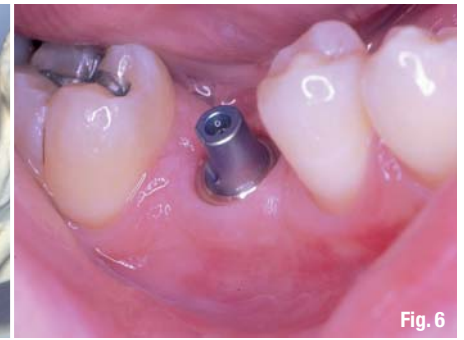
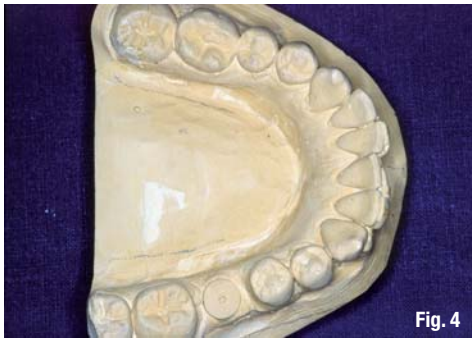Fig. 3



quality appearance and leave a lasting impression on the reader. This has clearly been an advantage also for implantology because now highly complex correlations can be more easily conveyed and "sometimes a picture is worth a thousand words". Ideally, e-learning and electronic professional journals supplement the current training needs of the younger generation of dentists especially.

### The end of dogmas

While implantology was marked by many dogmas from its beginning and the mid-1990s, this had changed at the time when our 15-year observation period begins. However, implantology was later called into question in its entirety. Whether it was healing times, waiting times after augmentation or prosthetic concepts—everything underwent scrutiny. On the one hand, some of these dogmas did in fact prove to be no longer sustainable because of remarkable developments, especially improvements in implant surfaces. On the other hand, the mark was at times overshoot in the elimination of other dogmas, creating the need to back-track. This was a painful experience for both patients and implantologists.

One dogma that we encountered in the observation period was that of a strict refusal of immediate implant placement. There is general consensus today, however, that under suitable conditions an immediate implant placement can be a high quality and sustainable alternative to established procedures. One clinical case shows an immediate implant placement in the maxillary anterior teeth: the extraction and the immediate

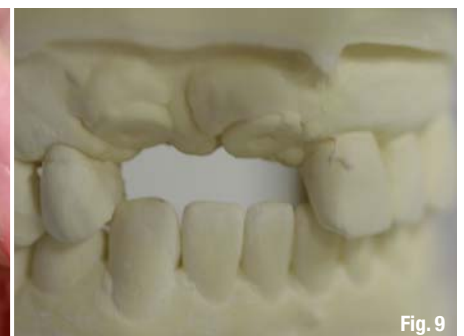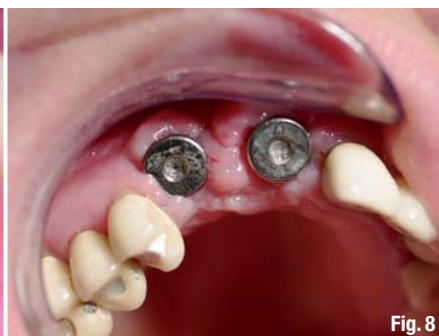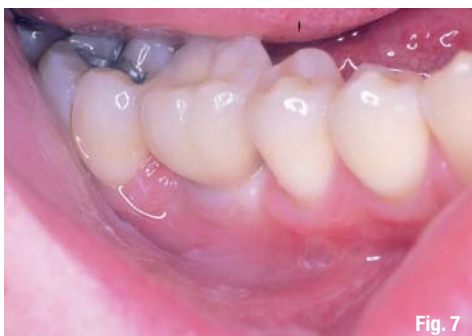implant placement of a maxillary anterior tooth that was not worth preserving under the guidance of a drilling template and implant position (Fig. 1), transfer into the oral cavity (Fig. 2), and the condition immediately after insertion of the implant crown (Fig. 3).

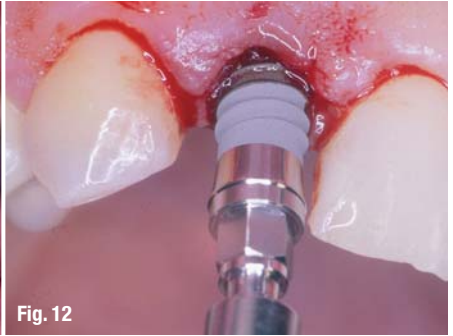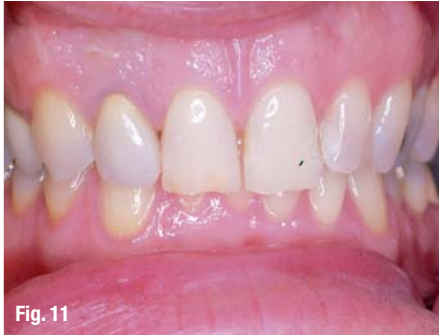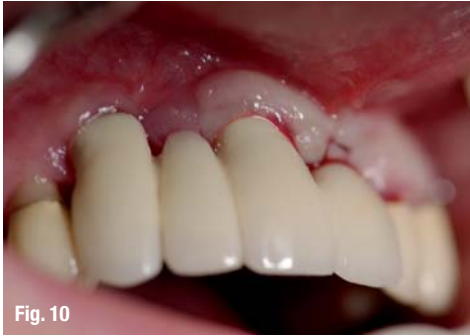### The prospering of the implant market

A welcome variety of new implants, implant forms and prosthetic options has become a reality in the past 15 years. Special implants were developed for special indications so that now even a mandibular molar can be replaced by a corresponding sized implant, followed by insertion of a corresponding sized implant crown. Figures 4 to 7 show the clinical and dental appearance of these in a patient. Implantologists who placed several hundred implants annually were considered the big players on the implant market in the 1990s. Achieving the mark of 100,000 implants placed per year in Germany signified that the peak had been reached. This was not the case, since the one-million mark was also reached within the scope of a rapid, almost unimpeded development. While the increase has been slower in recent years and global economic developments even caused a brief decline, today we can assume that the implant market will continue to grow. The maximum growth phase falls into our observed period.

### Development in the eyes of implant manufacturers

From manufacturer to global player—this would be an accurate description of the development of





some implant manufacturers. The development of some of these companies over the past 15 years, the size of their companies and the number of their employees today are indeed impressive. And these prosperous companies share other characteristics as well: the acquisition of products and entire firms in order to expand or supplement their product portfolio and their pressing on to the field of digital dentistry (CAD/CAM, planning, etc.), into which these global players invest large sums of money. Revenues must be generated so that these investments can be made—and they are still made, albeit declining owing to the economic crisis.

Still, the implant market is booming. Although the consistently two-digit annual growth rates some implant manufacturers had started to become used to have become more moderate today, a great deal of money can be made with implants. As a result, an ever-increasing number of implant suppliers and systems make it impossible for the individual user to keep track. Aside from new systems, an increasing number of generics are being launched on the market.

### Focus on red–white aesthetics

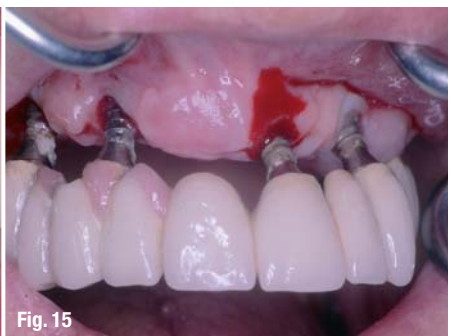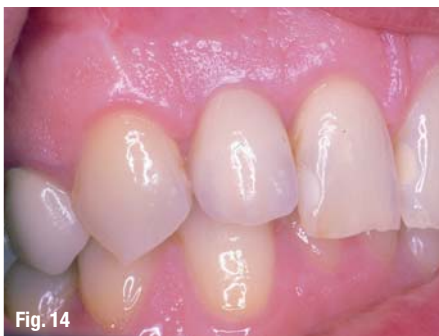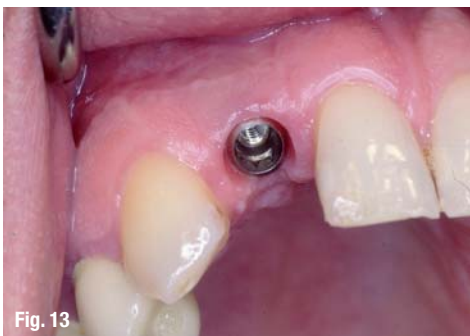The President of the German Society for Dental Implantology (Deutsche Gesellschaft für Zahnärztliche Implantologie), Prof Frank Palm, aptly remarked, “What was celebrated as a triumph for some colleagues 20 years ago is today taken to court.” Dentists who practised implantology were not prepared to find themselves confronted with a debate that had spread from North America to Europe: that of red–white aes-

thetics. This new focus on achieving the highest possible aesthetics for implant-prosthetic treatments was linked to implantology and distanced itself from surgery, which had been dominant up until that time.

In the early phase of implantology, the main focus was on safe placement and the best possible placement in the bone, sometimes even at the expense of subsequent prosthesis treatment owing to unfavourable placement of the artificial abutment teeth. Now, however, prosthetic standards and issues have become the centre of the discussion. Placement techniques were modified and new techniques were established in order to satisfy these requirements. Patients no longer, or only occasionally, accept demanding and complex cases like the following case.

Both implants in the anterior maxillary region were placed too far buccally, and there was a gap of 5.5 mm between the implant shoulder and the cemento-enamel junction of the adjacent teeth ( Figs. 8–10). Treatment with a long-term temporary restoration would only have yielded an unsatisfactory aesthetic result. However, under certain surgical and dental conditions—as shown in our second example—superior results and stability for a period of ten years can be achieved even with challenging initial situations. In 1999, an immediate implant was placed in region 12. The following images show the steps of treatment (Figs. 11–13). The last image shows the condition after ten years (Fig. 14).

This development was made possible mainly by massive improvements in the area of augmentations,





which can now be performed with significantly higher predictability. This development was further enhanced by a considerable improvement in the training of implantologists. These improvements are significant for both undergraduate study and post-graduate training. Thus, the universities and professional associations who have contributed immensely in this area deserve much credit in this respect.

### The battle of healing times

It was but an episode, yet one that caused an incredible furor at the time: the debate about shortened healing times. Stimulated by a media hype in which the specialised press only played second fiddle and the lay press appeared to be in the lead, the healing times of some implant manufacturers were inflated. Values were corrected downwards almost on a daily basis. Some manufacturers went along with it, while others remained firm. Some participants felt they needed to be at the forefront, others stayed out of it. A short but remarkable ascent was followed by a rapid crash.

A personal highlight for me was an article in a tabloid newspaper that said, "Extraction in the morning; directly followed by augmentation and implantation; a firmly seated supra-construction implemented at lunch time, and then endless servings of spare ribs"! As can be seen from this euphoric statement, some got carried away, while others had to painfully back-track. What remains is the realisation that, owing to improved surfaces and other conditions, the long healing times recommended in the early phase of implantology can in fact be reduced considerably, but not at any cost.

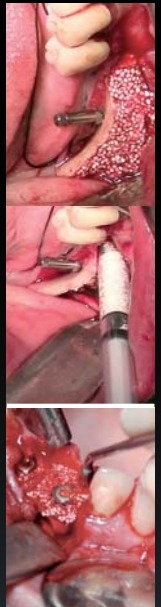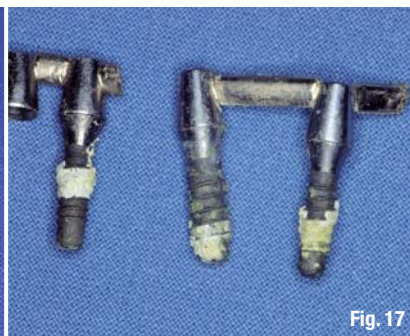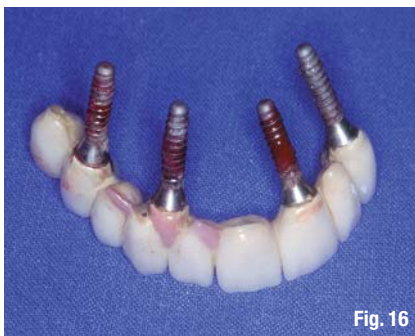### New options for improving the implant site

The afore-mentioned dominance of prosthetic implantology was only possible because many new and safer augmentation procedures were established during the observation period, enabling dentists to design the osseous bed for the implant as desired. Revolutionary augmentation procedures in the area of the maxillary posterior teeth, which had been the focus of discussion in the first year of the period in question, constituted another important approach for real progress.

Thanks to surgical techniques for sinus lifts, which underwent an incredible number of modifications also with regard to less invasive procedures, it was possible to treat areas of the jaw that had previously been considered impossible or that could only be restored for implantation by way of highly invasive orthodontic procedures. While initial sinus-lift procedures were generally reserved for highly specialised centres, they have now become common knowledge in implantology and are offered and performed extensively.

### Establishing virtual implantology

It seems easy to figure out what the old-school fraction must have thought about the new planning and placement options for oral implants. This fraction had already had



AD  
easy-graft®CRYSTAL  
bionic sticky granules

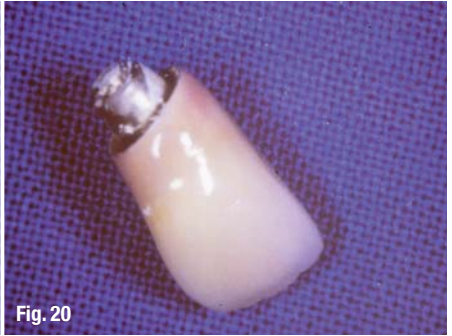
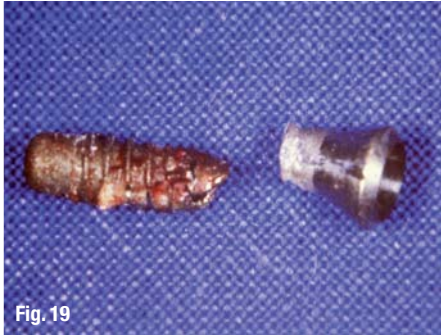
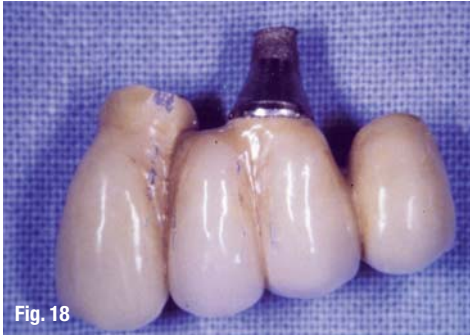
easy-graft®  
CRYSTAL

**Ingenious:** Simple handling and accelerated osteoconduction for long-term volume preservation.

SUNSTAR  
GUIDOR®

Degradable Solutions AG  
A Company of the Sunstar Group  
Wagistrasse 23  
CH-8952 Schlieren / Zurich  
[www.easy-graft.com](http://www.easy-graft.com)



a hard time accepting the development from surgical to prosthetic implantology, and they were strictly against the new digital procedures that were emerging incredibly quickly. With the rapid spread of dental volume tomography, which opened a new dimension to dental image diagnostics, a multitude of planning programs and aids were placed on the market.

The suggestion by some opinion leaders to define validity and establish standards with regard to these new techniques, which are generally based on 3-DX-ray data, was especially frowned upon. I feel that a good compromise has been reached, owing to anticipatory and serious discussions held during consensus conferences and congresses, as well as at universities and within the dental associations.

These new techniques are immensely helpful in the treatment of complex cases, and they are even indispensable for highly complex cases. The treatment of simple cases usually does not require the use of these techniques. In fact, they should not be used in such cases owing to the radiation exposure when obtaining 3-D data.

### Of promises and realities

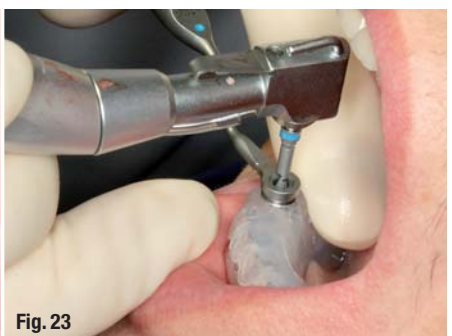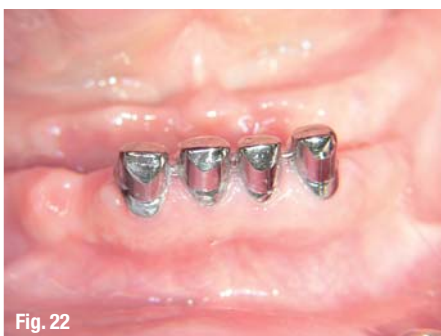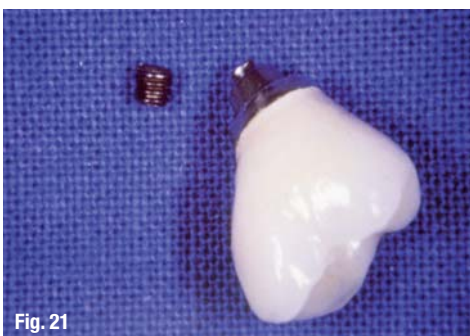Themes of the congresses during the first decade of the observation period contained generally positive statements and depicted new opportunities in implantology, which exceeded the then current options by far and expressed a belief in boundless growth. This coincided with many posi-

tive statements and evaluations by implant manufacturers and distributors. However, all this changed considerably during the past five years.

Suddenly, new topics were given priority, which shaped specialists' conventions—topics that had previously been partially suppressed if not negated. I remember only too well the implant congress held by a very important American implant manufacturer in Frankfurt/Main in 1998, where I reported on a concept for the treatment of peri-implantitis developed at the University of Freiburg and was then rebuked by the main speaker, who was from the USA, during the ensuing panel discussion. He asserted that he had "not seen one case of peri-implantitis in twenty years of implantology—this phenomenon does not exist and, if it occurs, it can only be attributed to a lack in skill on the part of the implantologists." How times have changed. However, trouble-shooting and complications in implantology and even the word "failure" have been mentioned in the themes of many congresses held by leading professional associations of implantology in the past years.

### Patients' expectations

While a consistently positive and at times even euphoric tone prevailed regarding the topic of implants for many years, a few critical voices and later increasing criticism emerged at the beginning of the observation period. This was—concurrent with a noticeable increase in the number of implants—based on the considerable increase in





implantology failures and complications. The following images depict total implantological failure—the loss of a purely implant-supported complete maxillary restoration caused by an infaust peri-implantitis (Figs. 15–17), leaving profound osseous defects.

However, in line with the consistently positive evaluation of implants and the persisting promise that the use of implants would yield optimum results always—and often publicised by the lay press—our patients' expectations have increased considerably in the past 15 years. Patients assumed that, regardless of the individual situation, he or she would always receive the optimum results. In this regard, it seems reasonable to maintain a self-critical attitude and to concede that we did not always contradict this general assumption vehemently enough.

And then what was bound to happen, happened: at times, the result was not what the patient had expected. An awkward situation arises when the dentist, based on the initial diagnosis, considers the result to be successful and the patient considers it a failure. A long-time legal expert sums up this situation accurately by stating that, "Two-thirds of all

pending court proceedings were filed by patients whose expectations were disappointed." Rather unfortunately, the increasing number of court proceedings are mostly related to implantology. It cannot be by chance that the premiums for mandatory professional liability insurance have increased considerably.

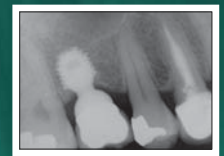### Emerging criticism

German periodontists Dr Thomas Kocher referred to implantology as "the red light district of dentistry". Whether this evaluation is justified is a matter to be decided individually. Personally, I do not agree with this evaluation, but a grain of truth might be found in its reference to overtreatment. In this regard, the extraction of teeth in favour of implants, even when not indicated, is a concern voiced increasingly by periodontists and those in favour of conservative treatment.

We have to address this issue by individual evaluation of each patient, as well as through academic discussion. Implant versus tooth preservation has been a frequent debate at conventions and implant symposia in recent years. In my opinion, this would not have been possible ten years ago.

AD


# Minimize bone grafting procedures!



## With Bicon's SHORT® Implants you can:

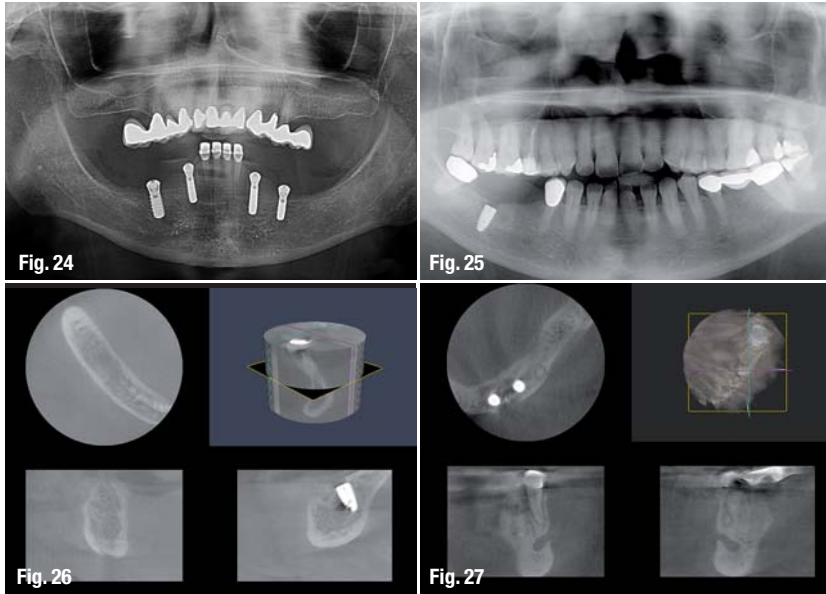
- ▶ Avoid vital structures.
- ▶ Minimize bone grafting procedures.
- ▶ Maximize implant placement possibilities.
- ▶ Increase patient acceptance.
- ▶ Offer single unit restorations without splinting.
- ▶ Offer a clinically proven solution.

## SHORT® IMPLANTS



Bicon Europe Ltd.  
 Hauptstr. 1 ■ 55491 Buechenbeuren ■ Germany  
 Phone +49 (0)6543 818200 ■ Fax +49 (0)6543 818201  
[germany@bicon.com](mailto:germany@bicon.com) ■ [www.bicon.com](http://www.bicon.com)





3-D technology constituted a quantum leap for dental diagnostic imaging as a whole.

Today, we have almost unbelievable possibilities at our disposal that even the greatest optimists would not have considered possible 15 years ago: highly complex patient cases can now receive minimally invasive treatment and have implants placed even without the need for augmentation.

Our first case shows a highly atrophied mandible, in which four implants could be placed without any prior augmentation owing to 3-D data and planning (Figs. 22–24). Three-dimensional diagnostics are sometimes also employed to clarify facts when complications have arisen, for example neural lesions after implantation (Figs. 25 & 26) and bone necrosis after administration of bisphosphonates, and erroneously diagnosed as peri-implantitis (Fig. 27).

### Trouble-shooting concepts

Unexpected complications, such as implant fracture and failure of implant supra-structure connections (Figs. 18–21), necessitated the development of surgical and prosthetic trouble-shooting concepts and modification of constructions in implant and abutment design. However, these were not readily available and have not yet been finally agreed upon. In other words, they cannot be said to be common knowledge in implantology, at least not in the treatment of peri-implantitis. Similar statements can be made with regard to pre-implantology arguments, where a pleasing variety of surgical techniques and materials is listed, but no generally valid scheme has been agreed upon.

The fact that the need to develop and convey these trouble-shooting concepts is generally recognised today and that these concepts are yet widely supported by the participants on the implant market is gratifying. The specialist press has made a valuable contribution here and continues to do so—numerous articles that received a great deal of attention during the past 15 years are those that dealt with implantology and implant-prosthetic trouble-shooting.

### Digital implantology

I consider the establishment of 3-D diagnostic imaging, with all associated possibilities, to be the significant development during the 15-year observation period. It is true that only implantologists used the new 3-D technology during the initial phase of dental volume tomography (because they made up the group of dentists who could actually afford this expensive equipment); nevertheless,

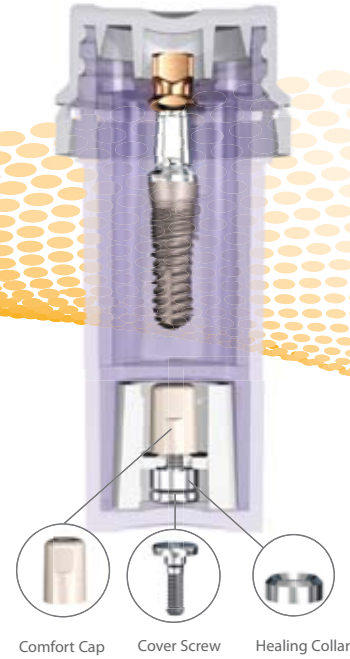
### My personal conclusions

It is difficult to draw a conclusion regarding the development of implantology over the past 15 years because it has been so multifaceted and rapid. To conclude, I would therefore like to quote my academic teacher and former supervisor, Prof. Wilfried Schilli, who, as a founding member of the International Team for Implantology, was undoubtedly among the pioneers of implantology and has contributed to improving implantology through his university work: "Who would have thought that implantology could develop like it did in less than twenty years."

This very true statement encompasses many aspects: the admiration and appreciation of what has been achieved, the satisfaction with having initiated a procedure that is considered to be the safest in the entire field of medicine, and some criticism regarding any development in oral implantology that did not turn so well or went off course.

<u>contact</u>	<b>implants</b>
<p><b>Dr Georg Bach</b>                  Rathausgasse 36                  79098 Freiburg/Breisgau                  Germany</p> <p>Tel.: +49 761 22592</p> <p>doc.bach@t-online.de</p>	

# Designed For Success, Packaged For Value



## SwishPlant™ Implant

All-in-One Packaging includes implant, straight abutment/transfer, cover screw & healing collar for only €145

## Swish™ Implant System Advantages:

Internal Octagon (Niznick US Pat. #4,960,381 Licensed to Straumann)

Prosthetic compatibility with Straumann's Tissue-Level implants (Standard, Standard Plus and Tapered Effect)

Internal square broached in flats of octagon for fixture-mount engagement (Pat. Pend.)

### Two Implant Designs & Packaging Options

Allows for selection based on price, packaging or thread design

**SwishPlus™** : €115 includes cover screw, healing collar & carrier compatible with Straumann tool & standard ratchet

- 1 2mm neck half textured for tissue-level or esthetic placement
- 2 Micro-grooves for improved tissue attachment & reduced stress
- 3 Progressively-deeper single-lead threads for increased surface area & complete surgical compatibility
- 4 Self-tapping groove for increased initial stability
- 5 Tapered apical end to initiate self-tapping

**SwishPlant™** : €145 includes cover screw, healing collar, comfort cap & straight abutment/transfer

- 1 2mm neck lightly textured for bone- or tissue-level placement
- 2 Micro-threads for improved tissue attachment, reduced stress & increased stability
- 3 Progressively-deeper double-lead threads for increased surface area & faster insertion
- 4 Self-tapping groove for increased initial stability
- 5 Tapered body for soft bone expansion

## SwishPlus™


Straight with Micro-Grooves & Straumann Threads

## SwishPlant™

Tapered with Micro-Threads & Double-Lead Threads



	Solid Abutment Kit	Straight Narrow Abutment	Straight Snap-On	Straight Contoured	15° Angled Contoured	Gold/Plastic	Zirconia/Ti Abutment	Angled Zirconia/Ti Abutment	Plastic Temporary Abutment	Ball Attachment	GPS™ Attachment	Angled GPS™ Attachment	Multiple-Unit w/Cap & Transfer	Multiple-Unit Straight	Multiple-Unit Angled
Our price	€75	€65	€65	€65	€65	€75	€90	€90	€27.50	€65	€75	€90	€65	€75	€75



**Intro Offer: Make the switch & receive a FREE implant<sup>2</sup>**

All trademarks are property of their respective companies.  
<sup>1</sup>System Variation: 3.3mmD & 5.7mmD SwishPlus™ are tapered; 3.3mmD also has SwishPlant™ threads.  
<sup>2</sup>Terms and conditions apply.

[www.implantdirect.eu](http://www.implantdirect.eu) | 00800 4030 4030

# Consideration of an uncommon approach in the atrophied posterior zone

## Part II: Extraction-plus technique

**Authors** Drs Maen Aburas, UAE & Ralf Gutwald, Germany

### Introduction

In the past, it was a significant challenge for clinicians to achieve implantation in the alveolar ridge of the posterior zone with restricted bone height, for which the alternative treatment choices were limited. However, procedural and technological developments have enabled implantation in most cases of severe bone resorption through the use of complex bone-augmentation techniques, such as bone transmission, sinus lift, distraction and nerve transposition, and the use of bone substitute, membrane and nail fixation, which might increase the risk of complication and failure.

Generating new bone in a free-end saddle in the vertical dimension is very difficult to achieve and some patients are unwilling to go through such a protracted treatment plan, considering the possible impact on their general health and psychological condition, as well as the cost. This scenario means that we have to find a good solution for those patients who cannot undergo such a difficult procedure, bearing in mind that the use of short implants alone is not advisable in many cases. The onus is on us to come up with a simple and standard means of implantation to save time and pain and to minimise the risk of complication and failure. The principle of the new technique proposed here—the extraction plus technique—is the extraction and sacrifice of the adjacent natural tooth, followed by the insertion of a long implant to support shorter implants that are inserted where bone height is limited. Through this new technique, we can convert a complicated procedure (guided bone regeneration—GBR) into a simple standard procedure with less pain, saving time and costs, and minimising the risk of complications.

### Conclusion for surveys

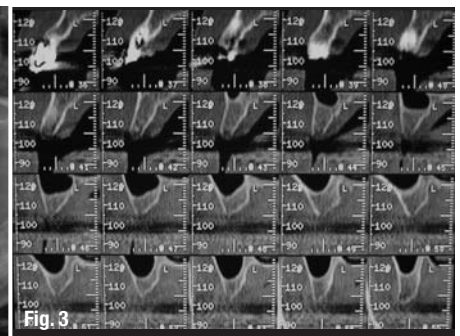
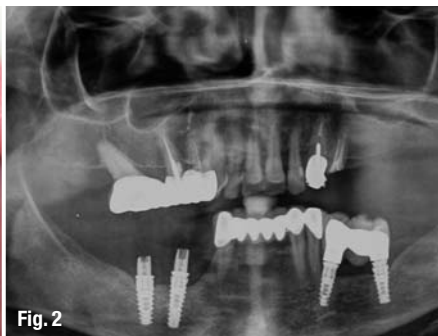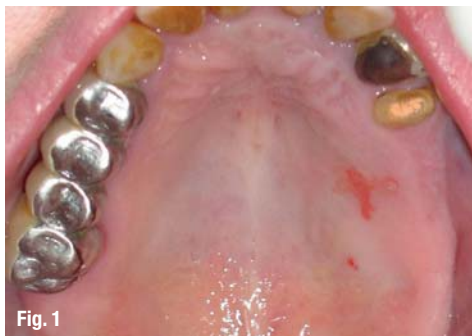The extraction plus technique was considered by the respondents as one of the better alternatives, especially when the tooth to be extracted was unhealthy, but less so when it was healthy. Using the short-implant technique in the mandible was pre-

**Fig. 1** Occlusal view of the maxilla, tooth #24.

**Fig. 2** Diagnostic panoramic radiograph at the time of presentation.

**Fig. 3** Diagnostic CT scan sections, left maxilla: sinus floor and alveolar ridge height.

Generating new bone in a free-end saddle in the vertical dimension is very difficult to achieve and some patients are unwilling to go through such a protracted treatment plan, considering the possible impact on their general health and psychological condition, as well as the cost. This scenario means that we have to find a good solution for those patients who cannot undergo such a difficult procedure,





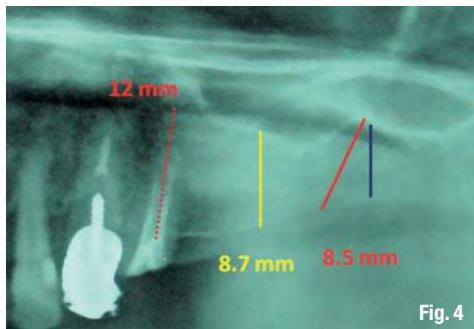


Fig. 4

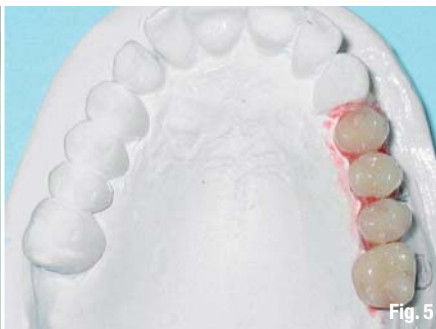

Fig. 5

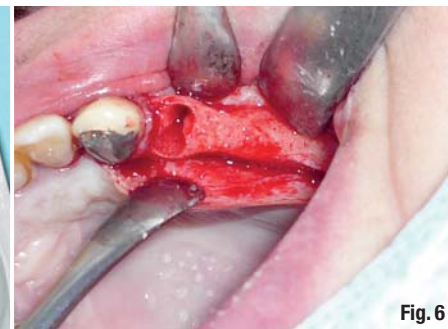

Fig. 6

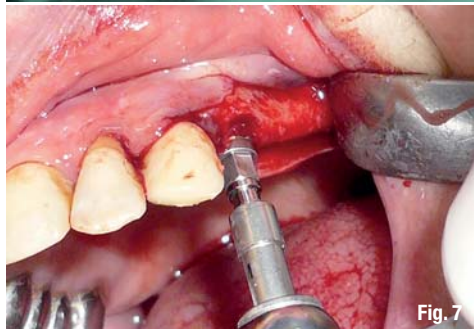


Fig. 7

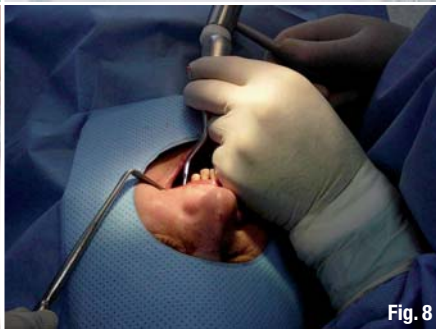

Fig. 8

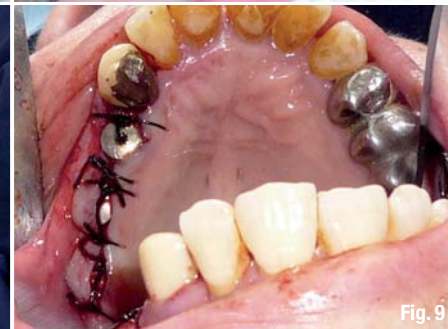

Fig. 9

ferred to using it in the maxillary posterior zone. The internal sinus-lift procedure was the most preferable technique for the maxilla. Overall, the clinicians found complicated alternatives, such as bone distraction and nerve transposition, the least preferable.

**Clinical case II:  
Unilateral free-end saddle left maxilla**

In March 2008, a healthy, non-smoking 67-year-old female presented with a unilateral free-end saddle left maxilla and bilateral implants in the mandible. Medical findings revealed that the patient had been diagnosed with osteoporosis on 25 July 2006. She had undergone 21 months of treatment with Fosavance (bisphosphonates plus vitamin D) as recommended by her orthopaedic surgeon. The patient's chief complaint was difficulty in chewing food owing to missing teeth on the upper left side.

The intra-oral examination revealed fixed dental prostheses on teeth #14, 15 to 17, and 34 to 43, a crown on #23 and an implant bridge on #35 to 37.

Lingual stains were detected on teeth #11 to 13, and 21 and 22, and three quarters of tooth #24 crown were broken. The radiographic findings confirmed a bridge over two implants on the posterior left mandible with insufficient marginal adaptation, root-canal treatment (teeth #14, 15, 23 and 24) and an implant posterior to tooth #43, which was extended to the mental foramen. This explained the loss of sensation in the lower right lip and limited bone height on the upper posterior left from 7 to 8.5 mm (Figs. 1–3).

The treatment plan was to avoid any extensive surgical procedure alternatives, for example by considering osteoporosis medication such as bisphosphonates. It was therefore decided not to do the sinus-lift procedure in the free-end saddle maxilla. In this complicated case, the extraction plus technique helped to simplify the procedure to extracting tooth #24 and replacing it with an immediately placed long implant (Tapered Effect, Straumann; 12 mm in length, 4.1 mm in diameter) in the left maxilla. This implant was combined with two short implants (Standard Plus, Straumann; 8 mm in length, 4.1 mm

**Fig. 4** Panoramic radiograph, left maxilla: limited bone height treatment plan.

**Fig. 5** Occlusal view of the cast: wax-up of the planned prosthesis.

**Fig. 6** Situation after extraction of tooth #24: alveolar walls intact.

**Fig. 7** Immediate placement of a Tapered Effect implant.

**Fig. 8** Use of the bone condenser to improve bone quality in the sites of the short implants.

**Fig. 9** Repositioning of the flaps and a single 3-0 silk suture.

**Fig. 10** Post-op radiograph: the insertion according to plan, tilting of the last implant to avoid perforation of the sinus floor.

**Fig. 11** Occlusal view of the implants after a long healing period.

**Fig. 12** Positioning the cylinder's rest on the snap-on impression caps for the closed-tray impression technique.

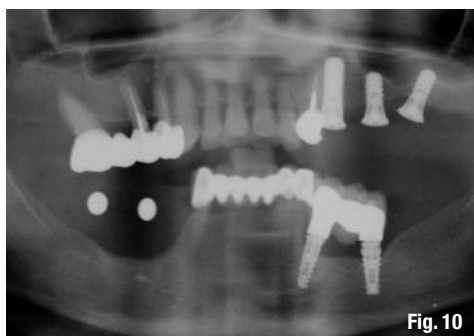


Fig. 10

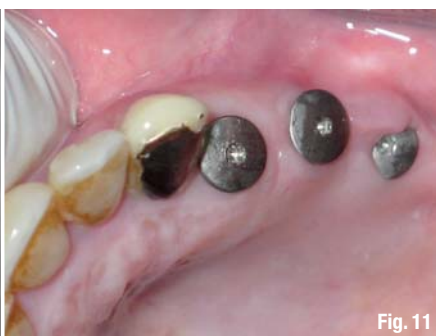

Fig. 11

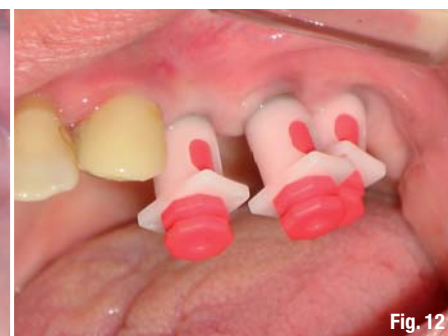

Fig. 12

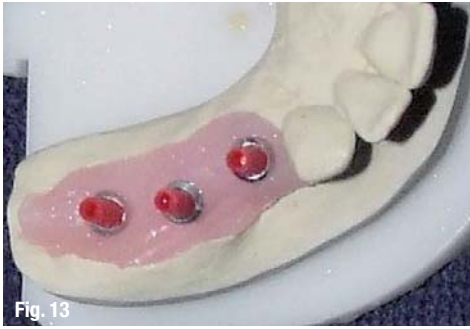

Fig. 13

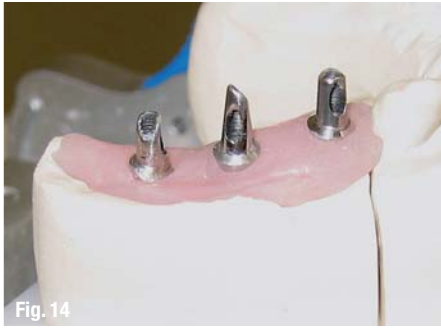

Fig. 14

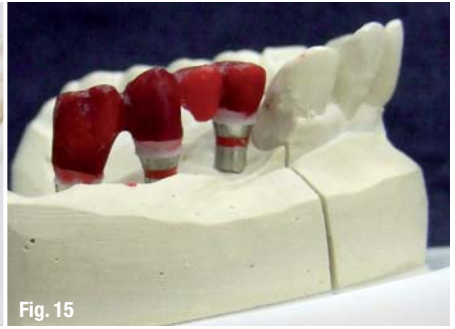

Fig. 15

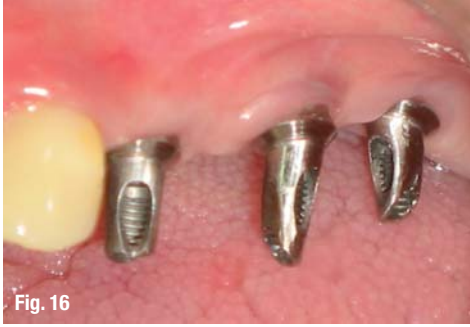

Fig. 16

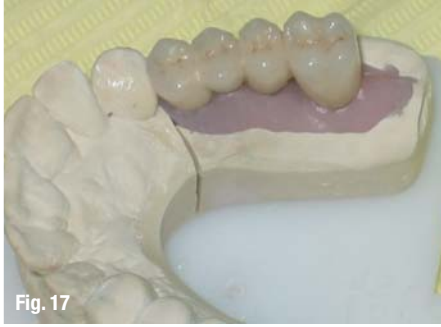

Fig. 17

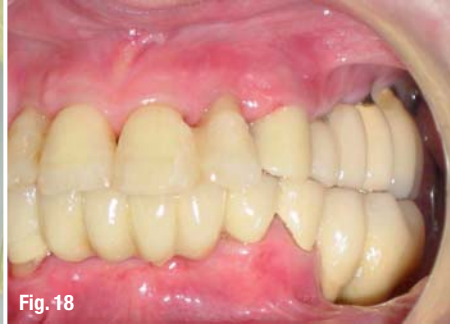

Fig. 18

**Fig. 13** Occlusal view of the master cast in the laboratory: a Straumann prosthetic planning kit to select appropriately angled abutments to illustrate the parallelism.

**Fig. 14** Lateral view of the master cast: optimal parallelism of the abutments.

**Fig. 15** Lateral view: bridge framework wax-up.

**Fig. 16** Lateral view: angled synOcta abutment seated in the mouth and torqued to 35 Ncm.

**Fig. 17** Palatal view: final restoration seated in the master cast.

**Fig. 18** Lateral view: final restoration seated in the mouth in maximum intercuspation.

**Fig. 19** Occlusal view: final restoration seated in the mouth, outcome corresponds to the cast plan.

**Fig. 20** Radiograph of the outcome: insertion of the final restoration in the mouth, reimplantation in the right mandible.

in diameter) in the place of teeth #25 and 26 (Figs. 4 & 5).

The surgical procedure was done as planned through the extraction of tooth #24 with a non-traumatic tooth removal technique. No damage to the surrounding alveolar ridge occurred, and the immediate placement of a long implant (Tapered Effect; 12 mm in length, 4.1 mm in diameter) in the extraction site followed. The second and third implants (Standard Plus; 8 mm in length, 4.1 mm in diameter, with a regular neck) were inserted using a bone-condensation technique. The third implant was tilted distally in order to gain maximum bone contact with the implant surface—the limited alveolar bone height helps avoid perforation of the sinus floor. The prime stability of the implants was confirmed and the flaps were repositioned according to a non-submerged protocol. Furthermore, a post-operative panoramic radiograph was taken as planned (Figs. 6–10). The patient came back for the prosthetic stage after a long vacation in January 2009. First, the peri-implant mucosa was assessed and determined to be healthy, with no bleeding on probing around the im-

plant. Percussion of the implants indicated well-integrated and stable implants. It was therefore decided to take a definitive impression for the final restoration, which was then made using snap-on impression caps. After the impression and the master cast were ready, a prosthetic planning kit (Straumann) was used to select suitable abutments and confirm the parallelism. Two 15° abutments and one 20° abutment from the synOcta implant system (Straumann) were selected (Figs. 11–14). The metal framework was constructed and tried in, and the X-ray revealed good marginal adaptation. The framework was then returned to the laboratory for ceramic application. Then angled synOcta abutments were seated in the mouth and torqued to 35 Ncm. The final bridge restoration was adjusted and verified in the mouth. Lastly, temporary cementation was done (Figs. 15–20).

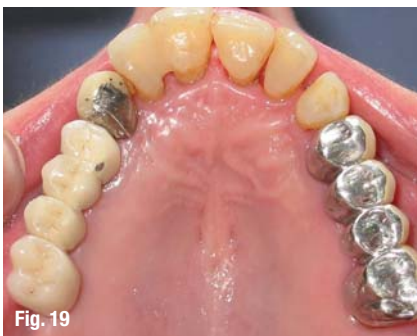

Fig. 19

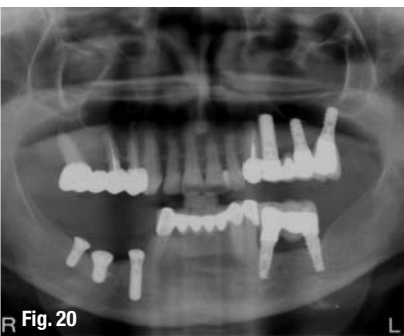

Fig. 20

**\_contact**

**implants**

**Dr Maen Aburas**

Dr Aburas Dental Center LLC  
Room 401, Doha Center Building,  
Al Maktoum Road, Deira, Dubai  
UAE, P.O Box 11048

**Dr Ralf Gutwald**

Hugstetter Str. 55  
79106 Freiburg/Breisgau  
Germany

ralf.gutwald@uniklinik-freiburg.de



# Geistlich Symposia at Europerio7, Vienna



## Geistlich lecture Friday, June 8, 2012

**Topic** Interactive discussion: Surgical and non surgical peri-implantitis treatment concepts  
**Time** 16:00-17:00  
**Room** Strauss 1

## Geistlich lecture Saturday, June 9, 2012

**Topic** Interactive session: How to treat multiple recessions? An innovative treatment concept  
**Time** 11:00-12:00  
**Room** Stolz 1-2

*Don't miss  
these interactive  
sessions!*





# Immediate functional loading of the edentulous mandible

## Tapered implants & overdentures

Author\_Dr Suheil M. Boutros, USA

### \_Abstract

The aim of this case report is to demonstrate the concept of immediate functional loading in the mandible using unsplinted implants to support a locator attachment-supported overdenture.

The patient was treated by placing four tapered implants in the anterior mandible. The implants were immediately loaded using individual unsplinted locators to support a removable overdenture. The patient was followed for 24 months. To date, none of the implants has lost osseointegration. The radiographic bone levels remain stable. The patient has been able to maintain healthy soft tissue around all individual implants and indicated that she is comfortable and is able to function well with her overdenture. This preliminary report presents a case in which individual immediately functionally loaded unsplinted implants maintained osseointegration when used to retain a removable locator overdenture.

### \_Introduction

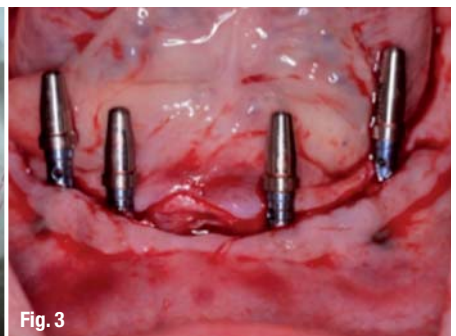
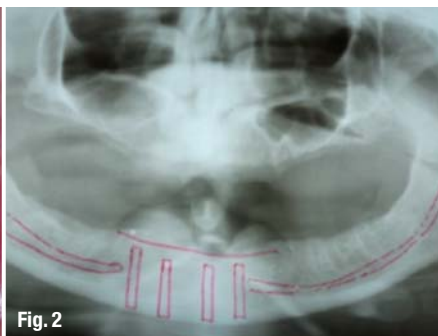
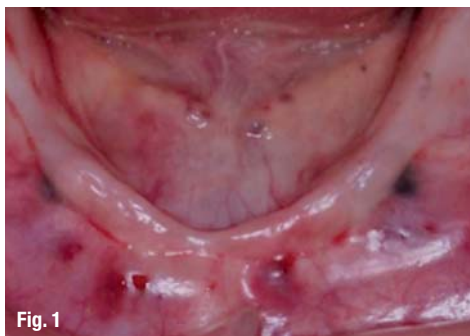Patients with an edentulous mandible may not be able to consume a normally textured diet. As they continue to lose alveolar bone height, the dislodgement pressure by the perioral musculature on the prosthesis becomes greater than its retentive aspects. This can cause discomfort, sores and trauma to the mental nerve. The placement of endosseous implants into the anterior mandible is an excellent therapy for reconstruction. It helps to restore edentulous patients to a normally textured diet, normal nutritional intake, better health and improved self-confidence.<sup>1-3</sup>

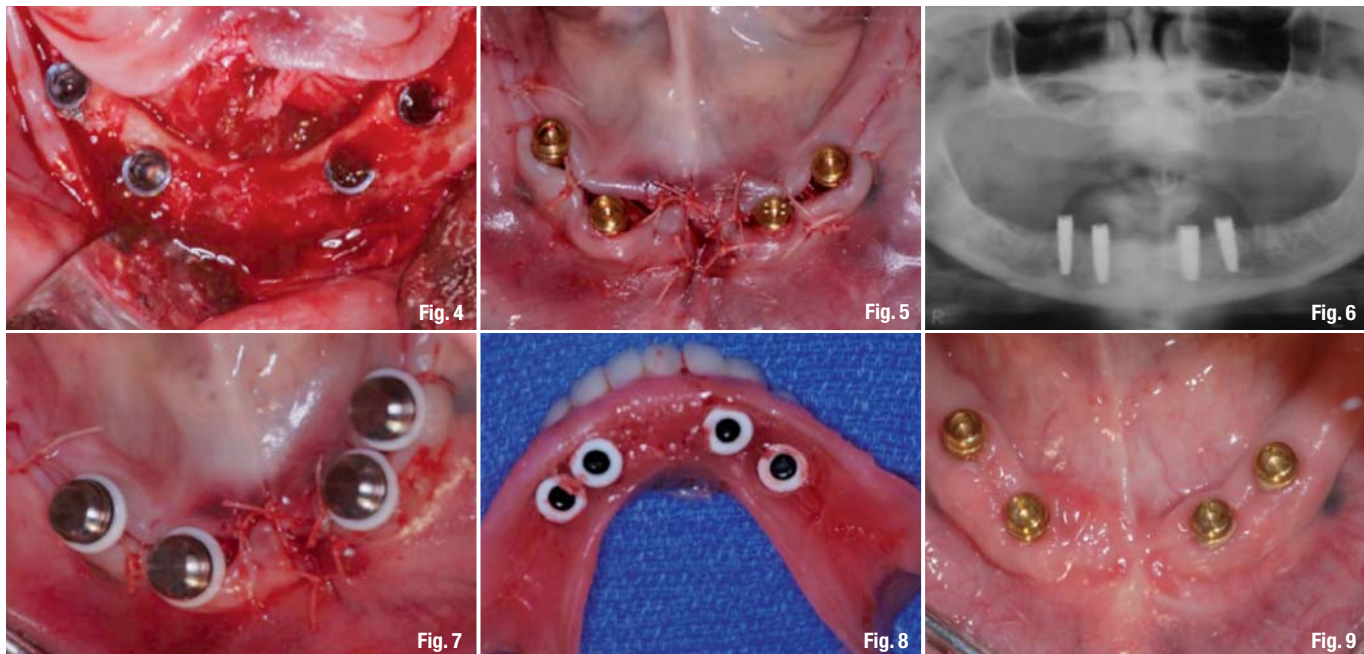
A locator-supported overdenture is a well-documented modality of treatment. The conventional method of treatment is to place the implants in a submerged two-stage approach. After allowing the implants to osseointegrate for three months, the implants are uncovered and the locators are delivered to support the overdenture. The concept of immediate functional loading has been documented in the

Fig. 1\_Mandible at the time of implant placement with moderate bone resorption.

Fig. 2\_Pre-op panoramic radiograph.

Fig. 3\_Guiding pins at the time of implant placement.





mandible and the maxilla: implants are connected rigidly and immediately after placement to avoid micro-motions, which can have a negative impact on the osseointegration process.<sup>4-8</sup>

A higher failure rate has been reported in only very few reports in the literature about immediate functional loading of individual implants to support a mandibular overdenture.<sup>9</sup> This case report demonstrates the use of tapered implants in the mandible to immediately load and support four separate implants by means of a locator-supported mandibular overdenture.

### Patient presentation

A 55-year-old female patient without any medical contra-indication for implant therapy presented with an ill-fitting, lower complete denture that she had been wearing for four years. The clinical and radiographic findings revealed slight to moderate mandibular ridge resorption with an ill-fitting lower denture (Figs. 1 & 2). The patient was given the option of placing four implants to support her existing lower

denture. The treatment plan was accepted and included an immediate functional loading by using a locator attachment-supported mandibular overdenture.

### Surgical treatment

At the surgical appointment, following the administration of local anaesthetic, a mid-crestal incision was performed and a full-thickness flap was reflected. In addition, osteotomies were prepared in type II bone. Bone taps were used to countersink the sites, after which four OSSEOTITE Tapered Certain implants (BIOMET 3i; 4 mm in diameter, 13 mm in length) were placed with the handpiece and hand ratchet. The implants were torqued to 35 N (Figs. 3 & 4).

### Prosthetic treatment

Immediately after implant surgery, the mandibular denture was seated in the patient's mouth and adjusted to provide clearance in the area of the locator(s). Four locators (4 mm in length) were torqued to 30 N (Figs. 5 & 6). Following the suture of the flap with

**Fig. 4** Four tapered implants at placement.

**Fig. 5** Flap was sutured around the locators using 4-0 vicryl suture.

**Fig. 6** Panoramic radiograph immediately after implant placement.

**Fig. 7** Occlusal view of the processing rings.

**Fig. 8** The processing rings were picked up directly in the mouth.

**Fig. 9** Occlusal view of the locators two weeks post-implant placement.

**Fig. 10** Buccal view of the locators two weeks post-implant placement.

**Fig. 11** The processing rings were removed ten weeks post-placement.

**Fig. 12** The blue retention rings were placed as the final rings.





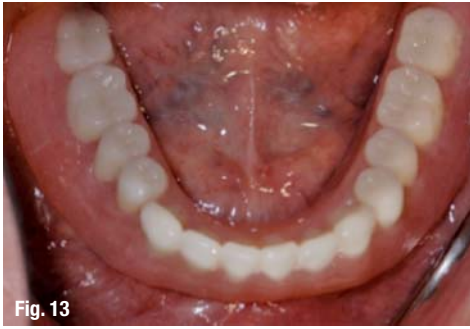

Fig. 13

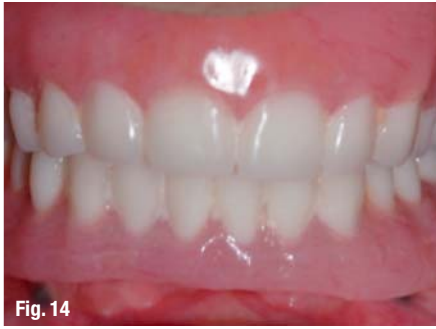

Fig. 14

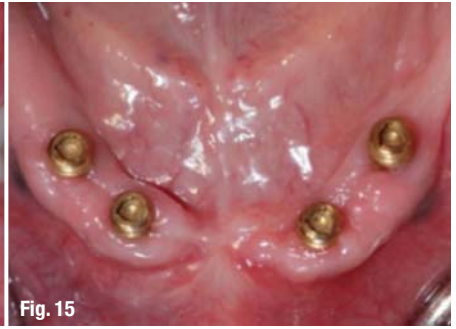

Fig. 15

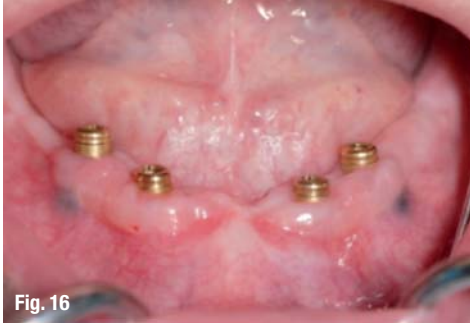

Fig. 16

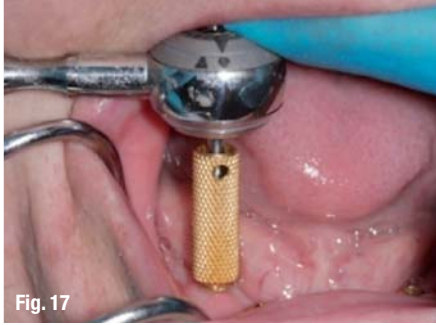

Fig. 17

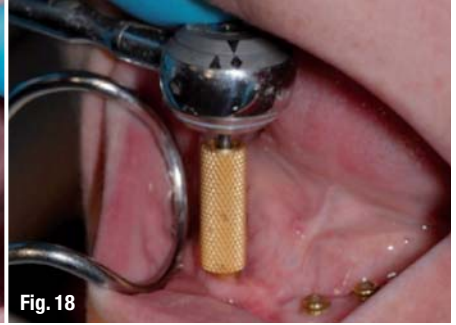

Fig. 18

**Fig. 13** Occlusal view of the overdenture in place at ten weeks post-placement.

**Fig. 14** Buccal view of the overdenture in place.

**Fig. 15** Occlusal view of the locators six months post-placement.

**Fig. 16** Buccal view of the locators six months post-placement.

**Fig. 17** Retorquing the locators to 30 N six months post-placement.

**Fig. 18** Retorquing the locators to 30 N six months post-placement.

4-0 vicryl, the processing rings were placed over the locators and were picked up directly in the mouth using hard self-curing acrylic (Rebase II, Tokuyama; Figs. 7 & 8). The patient was given post-operative instructions, including the use of 0.12% chlorhexidine gluconate (Peridex, Procter & Gamble) three times a day. She was furthermore prescribed 500 mg of amoxicillin (to be taken every six hours for seven days). The patient was then informed that the implant-supported overdenture was to be left in place for 48 hours. Two days later, she was seen for a follow-up visit and the healing process was uneventful. The black processing rings were switched to blue rings ten weeks after the placement (Figs. 9-14).

ment and all implants have maintained healthy soft tissue and a stable bone level.

### Clinical relevance

With a higher demand by patients for immediate implant placement and loading, the use of tapered implants can help achieve quick, economic and predictable results without having to use a rigid (bar) attachment, since they provide a high degree of primary stability.

*Editorial note: A complete list of references is available from the publisher.*

### Follow-up and maintenance

After six months, the patient returned for another follow-up visit and all four locators were torqued to 30 N (Figs. 15-21). It was determined that all four implants had achieved full integration. Currently, the patient is on a six-month recall to ensure the proper maintenance of the implants and the prosthesis. The last maintenance visit was 24 months post-place-

_contact	<b>implants</b>
<p><b>Dr Suheil M. Boutros</b>                  Periodontal Specialists of Grand Blanc                  8185 Holly Road, Suite 19                  Grand Blanc, MI 48439, USA                    sboutros@umich.edu</p>	

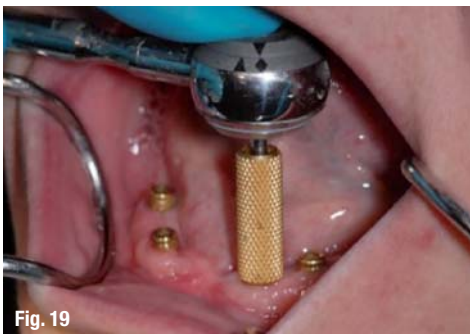

Fig. 19

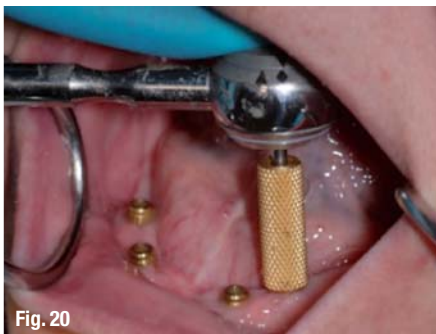

Fig. 20

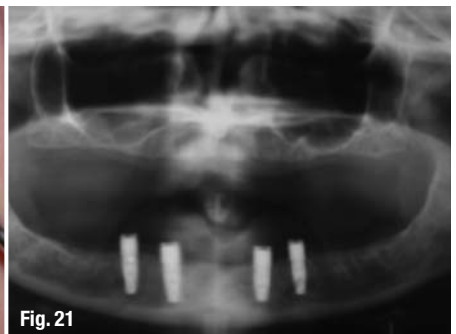


Fig. 21





## PERFECT FIT BY DESIGN

In combining Soft Tissue and Bone Level implants with a comprehensive prosthetic portfolio, Straumann has devised one system for all indications. The **Straumann® Dental Implant System** – excellent product quality designed for convincing, naturally esthetic outcomes.

Two dental implants are shown against a white background. The implant on the left is a soft tissue implant with a smooth, rounded top. The implant on the right is a bone level implant with a textured, threaded neck. Both implants are surrounded by dynamic splashes of green-tinted water, creating a sense of freshness and precision. A yellow callout box is positioned near the base of the bone level implant.

Featuring the  
SLActive® surface!

More information on [www.straumann.com](http://www.straumann.com)

COMMITTED TO  
**SIMPLY DOING MORE**  
FOR DENTAL PROFESSIONALS

data-transfer

resolution

high contrast

errors

accuracy

infra-red control

technology

# New concepts in computer-guided implantology

## Part II: Error analysis and accuracy verification

Author\_Dr Gian Luigi Telara, Italy

### Abstract

In recent years, there has been a growing interest in guided implantology. A digital work-up is certainly of great benefit for clinicians to better understand their patients' bone morphology and density and consequently to plan implant positions correctly, and to have their hands guided during implant placement by means of a surgical guide. There are many systems on the market today and many researchers have studied post-operative CT scans and planning scans by means of superimposition, in seeking to understand the secret to achieving perfect correspondence and the best system, but this perfect accuracy has not yet been found and there appears to be a mismatch between planning and the actual implant position.

I have developed a device (Dental Implant Positioning System, International PCT IT 2009 000192, WO 2010/125593 A1; patent pending) that respects

the implant's spiral movement in accordance with mathematical criteria. The same criteria are also important in theorising limits and achieving accuracy using computer-guided implantology.

### Introduction: Passive systems and the limits of the human visual, auditory and spatial resolution

Is it possible, using one technique, among the many on the market, to create repeatable results in terms of a final prosthesis? How many of the presently marketed systems in guided implantology really are passive? Do passive infra-red systems really facilitate repeatability?

Human visual resolution limits do not allow for accuracy: eye, ear and fine hand movements have not yet crossed this threshold. Human spatial resolution can be evaluated with reference to the modulation transfer function (MTF). This is also a good





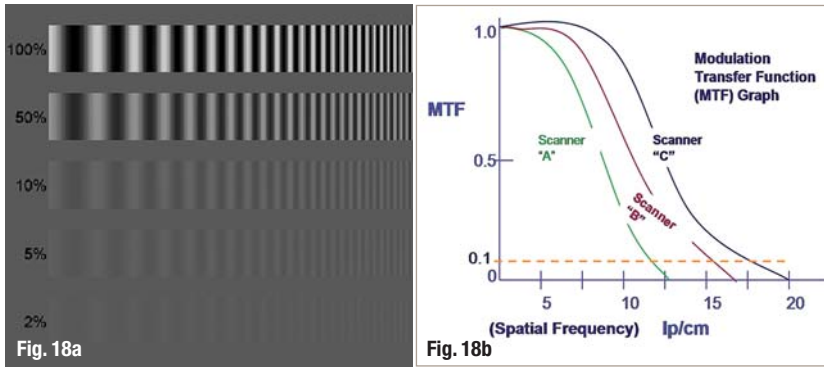


Fig. 18a-e\_MTF concept.

other optical system, have optical limits and owing to CT's MTF and intrinsic limits, CT scans can be considered low-resolution 3-D images. They also achieve spatial resolution levels far from those needed in our field to ascertain placement precision. Consequently, statistical inferences based on superimposition cannot be said to deliver valid proof.

### \_High-contrast spatial resolution

I scanned an implant using the latest NewTom CBCT (CB3D VG-I MARK 3), and viewed the scan using SimPlant Crystal (Materialise Dental) to verify the resolution and the precision of the measurement. The best I was able to achieve was 0.1 mm. This means that a real measurement of 1.43 mm could be achieved on CT within 1.33 and 1.53 mm, and 0.3 mm is the possible measurement error (Fig. 17a). The same difficulties also arise with MSCT scans (Fig. 17b).

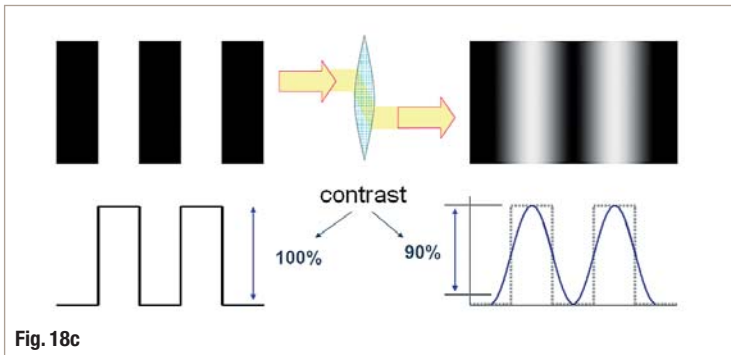


Fig. 18c

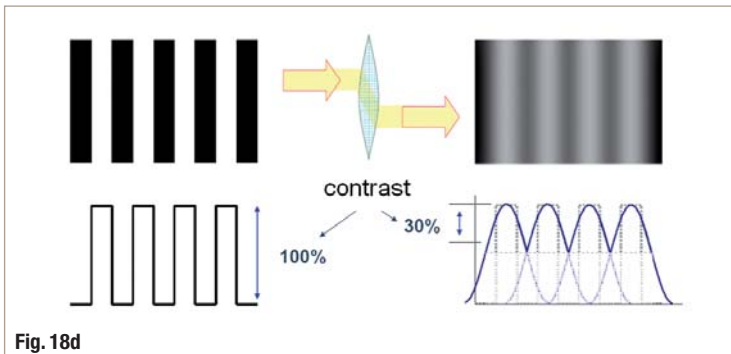


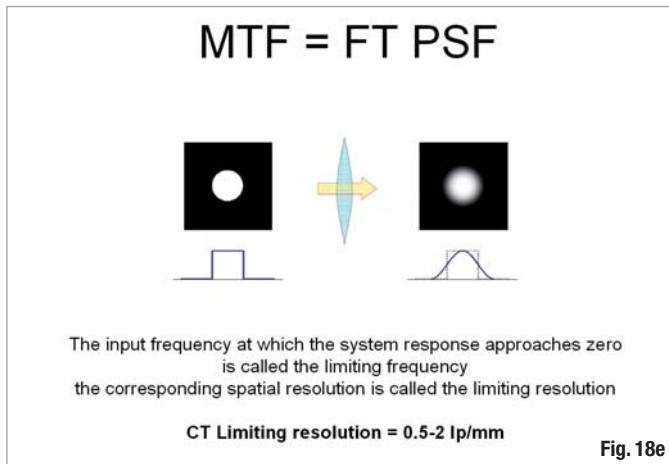
Fig. 18d

Spatial frequency is evaluated by means of MTF, the ratio between the output and the input signal, with one describing an ideal system with no loss of information at the output. MTF defines limiting resolution, which describes the ability of a system to perceive two objects as distinct. At high frequencies, that is a high number of line pairs per mm (lppm), MTF will approach zero (Figs. 18a & b). When taking MTF into account, we must evaluate a CT scan according to its optical performance. When the frequency is increased, a series of square waves, corresponding to a 1:1 ratio with combined white and black lines, changes into a series of bell-shaped waves. This process is termed the point spread function. As a result, the contrast decreases, which makes it increasingly difficult to visualise the edge of the lines. MTF is the Fourier transformation of the point spread function. When the frequency is low and the quality ratio is one, the wave corresponds perfectly to the square waves. When the frequency increases, the ratio decreases and the wave becomes increasingly bell shaped. At an MTF of 2%, the image will be of a uniformly grey colour (Figs. 18c & d). The CT scan limiting resolution is therefore 2 lppm at best (Fig. 18e).

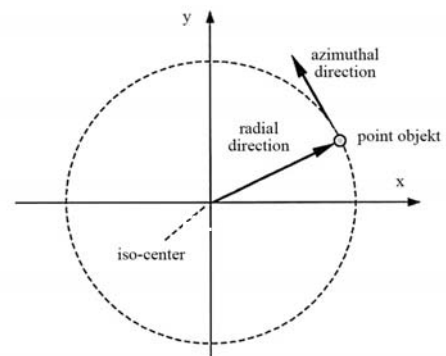
### \_Low-contrast spatial resolution

Moreover, we can extend our discussion to the contrast level at which an image is observed and analyse low-contrast spatial resolution.<sup>6</sup> When the contrast decreases at high frequencies, we have to cope with a low-contrast level image that is noise dependent. Furthermore, the optical spatial resolution properties depend on the part of the screen at which we are looking. The resolution is at its best at the isocentre, worsening both in the radial direction and along the circumference, the azimuthal direction (Fig. 19). While this phenomenon holds true for the cone beam in particular, a cone-beam effect is also achieved with MSCT: the more slices we have, that is, the greater the fan beam width of each subsequent MSCT scan, the greater the cone-beam effect (Figs. 20a & b). When the isocentre is considered the central part of the radiation fan, this effect can be seen in the outermost slices of the radiation fan beam especially (Fig. 20c). Axial reconstruction algorithms report this cone-beam effect in relation to a spiral path in the axial images (Fig. 20d).<sup>7</sup>

Compensating cone-beam reconstruction algorithms or spiral interpolation algorithms help to solve this problem, for instance the multi-row Fourier reconstruction. Similarly, an extension of the advanced single-slice rebinning method (ASSR), which combines the idea of ASSR with a z-filtering approach, has been proposed as a solution to this problem, but its validity has not been adequately



## Radial and azimuthal directions



demonstrated. This is because, thus far, interpolation has only shown a reorientation of the optical limits for both cone beam and MSCT.<sup>8,9</sup>

### Errors in sleeve placement

CT is also responsible for errors in sleeve placement inside the surgical guide. These errors are caused by an inescapable approximation in the CT resolution limits. CT cannot exceed its MTF limit, and this should be considered during planning and data transfer.

There can be repercussions on the sleeve placement inside the surgical guide, both for smooth or threaded sleeves. Sleeve position and axis are parameters associated with this procedure, and the distance to the ridge and adjacent teeth, as well as the sleeve axis, should be considered. However, from a practical perspective, they have no relevant influence on this procedure, but the limits given by these parameters are sufficient for the production of a surgical guide. Furthermore, they respect the structures adjacent to the implant site, for example plates and vascular adjacent structures, IANs, sinuses, nasal cavities, pterygopalatine fossae, mental foramina and adjacent roots.

Owing to the technical production limits of CT, the sleeve position in the surgical guide tends to be inaccurate, regardless of the technique applied (STL or stone surgery).

### Evaluation of data-transfer techniques

As for data transfer in the course of producing a surgical guide, the chosen technique should result in the sleeve being placed in the centre of the palate bone. In order to decide between CAD/CAM and stone surgery for this process, a cadaver study may help in comparing and evaluating the various techniques on the market.

In order to prove repeatability, each cadaver must be scanned several times. Each scan should consider the protocol of a different company or manufacturer. The corresponding surgical guides should be tested on the same cadaver in order to evaluate the precision of each technique in placing the sleeves in the centre of the bone, according to position and axis.

Surgical kits should fit into the mouth and I assume that the axis should respect the palate's anatomy. Furthermore, drilling and implant placement should be avoided in order to prevent inaccuracy errors other than those derived from using smooth sleeves. Likewise, a repeated scan for superimposition is not of any use. Mathematically speaking, a system can be considered reliable if its repeatability can be confirmed. In the cadaver study, the cadaver should therefore be tested to fit several repeated surgical guides. A similar technique proposed by Al-Harbi, in which the accuracy of the sleeve axis is assessed via CMM (coordinate measuring machine) and laser techniques, also appears promising.<sup>10</sup>

The study by Bou Serhal et al. is based on a cadaver study, but once again, the cadaver was scanned according to a superimposition protocol.<sup>11</sup> But why expect to obtain more information from a second CT scan if we know that CT can be imprecise? There are many articles on the reliability of CT and its correspondence to the anatomical truth, such as the studies by Lou et al.,<sup>12</sup> Brown et al.<sup>13</sup> and Damstra et al.<sup>14</sup>

However, these publications appear to restrict their interest to the scanned fiducial landmark measurements and record an error between 0.1 and 0.5 mm for 2-D CT. It is therefore my opinion that these studies fail to distinguish sources of error such as the MTF limit and smooth sleeves by concentrating on the superimposition of two low-quality 3-D images.

**Fig. 19** Radial and azimuthal resolution.

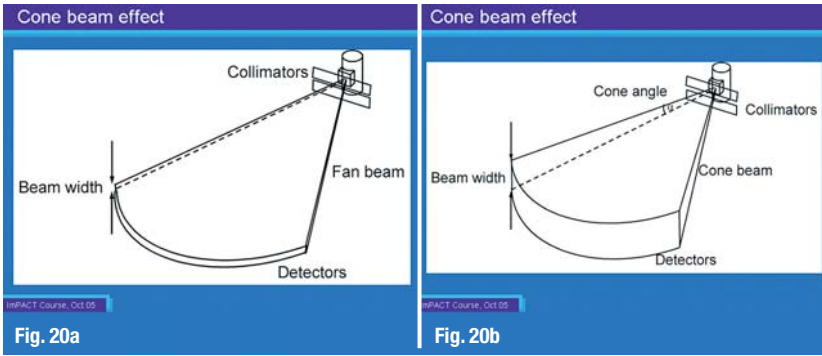


Fig. 20a-c\_ Cone-beam effect.  
Fig. 20d\_ Cone-beam effect interpolation.

### \_Reliability of STL surgical guides

The study by Stumpel<sup>15</sup> provides important information on the accuracy of STL surgical guides. Their reliability is ascertained via a teeth-borne surgical guide. After a stone model has been scanned and matched to the planning, the surgical guide is used like a jig and the correspondence between the STL model and the mouth is measured.

An HU threshold appropriate for the bone algorithm is necessary in order to avoid producing an STL model of inadequate size. The merging of planning and stone model scanning can further help improve its accuracy. The dimensional tolerance of an STL model is about 0.3 % when SLS or LS and stereolithography (either SL or SLA) are applied. These techniques yield tolerances of +/- 0.3% and a minimum of +/- 0.005.

Since less resolution is needed to produce a surgical guide than to ascertain implant position, the software can only be used for planning and STL surgical guide production. It cannot, however, be used for verifying the implant position. In order to embed either smooth or thread-timed sleeves that can guide drills and implants while respecting the pt. anatomy, 0.1 mm is sufficient.

### \_Moving on

Superimposition cannot differentiate between inaccurate sleeve placement and inaccuracies of the

sleeve position and axis of the surgical guide or inaccuracy resulting from using a smooth sleeve. Instead, these are confused, which leads to the conclusion that a comparison of planning and post-operative scans will not lead to any convincing results, even if the superimposition was perfectly executed and different kinds of software were used in unique clinical situations. At worst, the ALARA principle cannot be followed and patients are subjected to an inordinate amount of radiation.

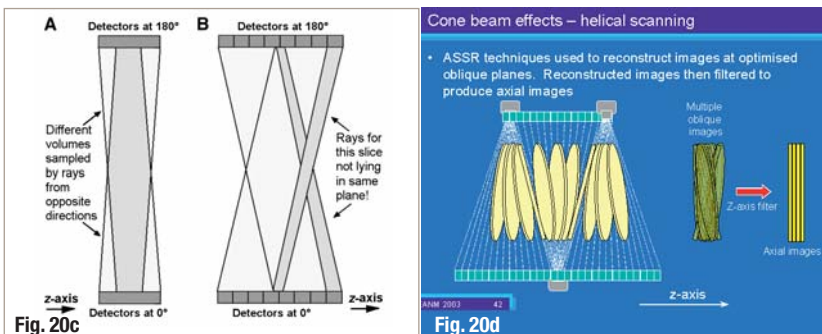
Once we accept that errors are likely when superimposition is done, we can consider other techniques. These techniques should be designed to avoid errors derived from using a smooth sleeve. An ideal system, for example, would allow for a prosthesis, and the surgical guide would allow for identical implant and analogue positions both in the model and in the mouth.

Thus, from now on, we can be extremely accurate when working with a thread-timed device in the implant phase. After the surgical guide has been made, we must demonstrate the accuracy of the implant placement. The surgical guide with its repeatable results allows us to work on an infinite number of master casts. Our n<sup>th</sup> master cast is the mouth, and its correctness can be evaluated by means of a jig.

In 2007, Nobel engineered a threaded device for zygomatic implants, which was considered for use in other Nobel implants (patent number: WO 2007/129955 A1). Their threaded guiding sleeve functions with a threaded implant mounter. They claim that these devices lack any vertical fastening features and do not use any notches to index the hex. Consequently, they warn that there may be no hex correspondence. Therefore, additional rotation may be needed. Additional rotation amounts to missing depth (it is mathematics: if you go on screwing, you deepen the screw itself); therefore, with a threaded sleeve, missing the depth because a system has not been adequately fastened means missing the hex as well. Additional rotation is only approximately adjusting a device that has lost the phase and these two parameters. These two parameters will be missed. In order to obtain the correct final hex position (and consequently also the depth), I invented a helical gear.

### \_Conclusion

Accuracy in implant placement appears to depend on the context of the respective case; for example, it appears less relevant when immediate loading is not the preferred option or if an impression can be taken immediately after implant placement. However, accuracy in implant placement can





help prevent cortical vascular perfusion disorders (cortical plate perfusions) or arterial vessel damage. This appears to be especially important in areas in which hard- and soft-tissue stability is required for long-term results, for example for biomechanical concepts that require submillimetric precision. Furthermore, tissue stability should be considered in all areas of the mouth for aesthetic and trophic reasons.

On the one hand, CT scans to date offer low-resolution 3-D images of the bone. The software available, on the other hand, delivers both good planning and safe sleeve positions and axes independently of the technique used to obtain a surgical stent. However, we cannot rely on the planning, since it cannot discriminate errors. As two superimposed low-resolution 3-D images cannot result in a high quality image of the implant, relying on the planning would increase imprecision in accuracy measurements. I therefore recommend platform positioning according to mathematical criteria in order to achieve a correct, prosthetically driven position.

When sleeve placement is considered, jig correspondence between the abutments on the master cast analogues and the same abutments' clinical position on the implants can help avoid inaccuracies in terms of either the sleeve position or the axes of the surgical guide. Furthermore, it can help evaluate inaccuracies resulting from using a smooth sleeve.

To date, no publications have reported on such a technique, presumably because this kind of verification can impose too much stress on any method owing to the time required to ensure precision this way. Indeed, repeatability seems incidental to the thread-timed sleeve. Thread timing can be an impasse on the way towards a precisely placed implant, since analogues and implants cannot be forced into the same positions both repeatedly and operator independently. In other words, it is unlikely that all relevant parameters, such as the position in the ridge and the axis, the depth and the rotational feature orientation, can be taken into account.

No publications have reported on such a technique, either, simply because no method has been concerned with verifying accuracy so precisely. Repeatability is incidental to a thread-timed sleeve (that is, something able to force both analogues and implants into place in the same repeatable and operator-independent positions). Thread timing is essential. If we do not accept this, we must accept imprecision. The parameters that define the platform—position in the ridge and axis, depth and rotational feature orientation—should all be re-

spected. If we miss one parameter with a smooth sleeve we miss them all. In the case reports cited, superimposition of the planning was done after the pts. had been scanned again post-operatively. There was complete accuracy between the master model and the clinical results. In order to furthermore demonstrate how this device could work independently of the way the surgical guide is produced, no industrially manufactured surgical guides were used. Instead, a digital cast and a stone cast were used with an approximate protocol for transferring data from the software and the stone model, and plain resin was chosen as the provisional material.

Moreover, it seemed important to understand that comparing post-operative clinical CT results to the planning through superimposition can be misleading in measuring the accuracy of an implant. Contrarily, a comparison between the clinical results with either an STL or stone model on which analogues were placed by using the same threaded guiding device offers better accuracy measurement. Although software is essential to planning and creating a surgical guide with an accurately embedded sleeve, accuracy relates to the concepts of thread timing and implant phase and not to software. In the case reports cited, software was therefore used to provide qualitative data exclusively.

In general, aggressive marketing tactics are an important ethical factor when computer-guided implant placement is considered. The Millennium Research Group has estimated a 20% growth in the number of guided implant placements by 2013. Similarly, dentists are likely to increasingly perceive the need for planning software and drilling templates. In the future, however, CAD/CAM techniques will not only be applied in planning, but also be used for surgery in order to enhance prosthesis and tissue stability. A passive device that is easy to handle and based on thread timing can pave the way to computer-guided progress.

*Editorial note: A list of references is available from the publisher.*

**\_contact**

**implants**

**Dr Gian Luigi Telara**

Studio Odontoiatrico Lippi Telara

Via Vorno, 9/4

55060 Guamo Lucca

Italy

Tel.: +39 05 8394 7568

lippitelara@gmail.com

# The same-day tooth: From the diagnosis to the final restoration

Author\_Dr Stefanos G. Kourtis, Greece

## \_Introduction

The restoration of missing anterior teeth is both a challenging task for the clinician and a stressful treatment for the patient. The final aesthetic result is of major importance—for the patient, dentist and dental technician. Moreover, the patient has high expectations, aesthetic demands and concerns about the cosmetic result of the final restoration. Even before treatment is started, the patient is usually concerned about the final outcome, as well as the provisional restoration used during osseointegration. The aim of this case report is to

present the clinical stages of rehabilitation of a central incisor from diagnosis to final restoration.

## \_Case presentation

A 29-year-old female patient without any apparent contributory medical history presented for treatment. The patient complained about the aesthetic appearance of the anterior maxillary region. The right central incisor appeared elongated, showed increased mobility (Grade I+) and was sensitive to palpation. The gingival margin of this tooth showed signs of infection, both labially and

Fig. 1\_Initial clinical situation.

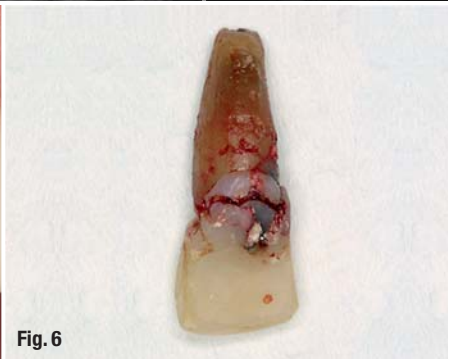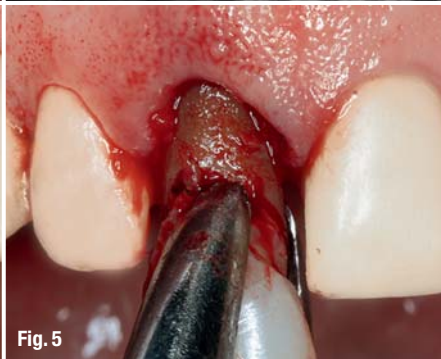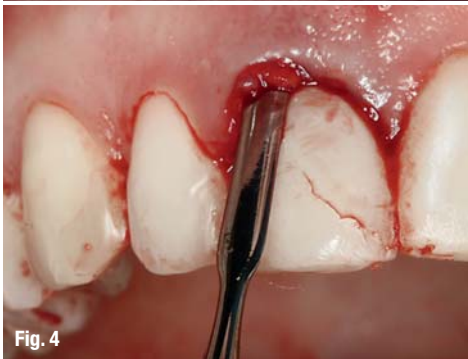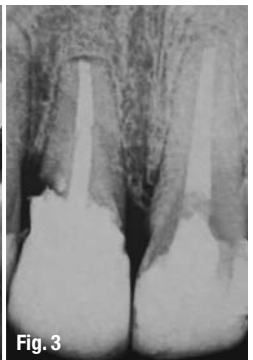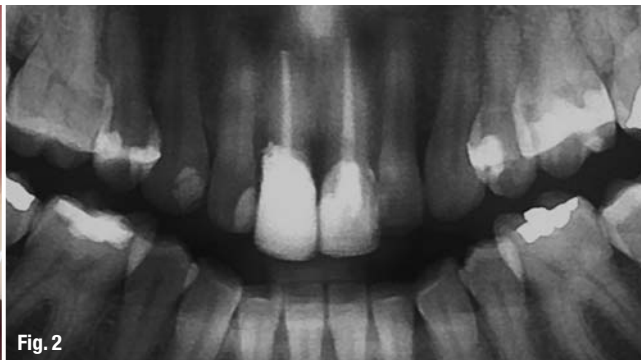
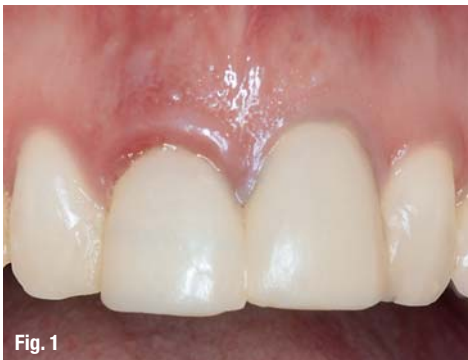Fig. 2\_Initial radiographic situation.

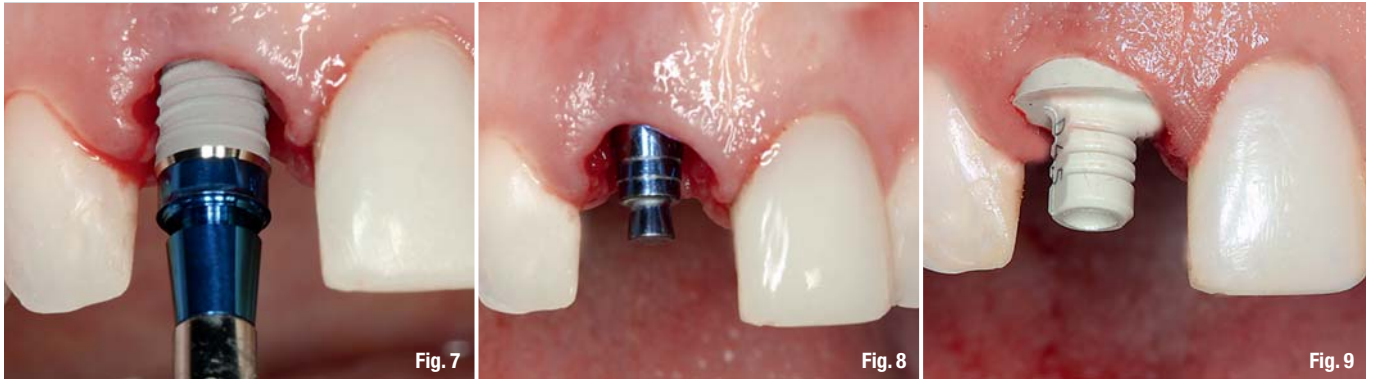Fig. 3\_Detailed X-ray examination.

Fig. 4\_Periodontal fibres cut by utilising a periosteal elevator.

Fig. 5\_Atraumatic tooth extraction.

Fig. 6\_The horizontal root fracture was evident on the extracted tooth.





palatally. Hence, its periodontal conditions differed evidently from those of the remaining dentition. The left central incisor was discoloured and had extensive composite resin restorations with inadequate fit at the margins (Fig. 1).

A possible tooth or root fracture was suspected. The patient was asked about recent injuries or trauma to the maxillary region, and she reported a traffic accident six months previously. After this incident, both incisors showed extreme sensitivity and were treated endodontically. Radiographic examination with panoramic and intra-oral X-rays revealed a root fracture of the right central incisor

2 mm below the cemento-enamel junction (Figs. 2 & 3). The tooth had a poor prognosis and needed to be extracted. In contrast, the left central incisor showed no signs of root fracture. The treatment plan included the extraction of tooth #11, an immediate implant placement and the use of an immediate provisional. In addition, the prosthetic rehabilitation of the natural tooth #21 completed the rehabilitation. All-ceramic crowns were selected as the final restorations for the two central incisors at the end of the osseointegration period of the implant.

The patient had a high smile line and was extremely concerned about her aesthetic appearance

**Fig. 7** Immediate placement of a XIVE S plus implant.  
**Fig. 8** Final position of the implant.  
**Fig. 9** Insertion of an EsthetiCap provisional abutment.

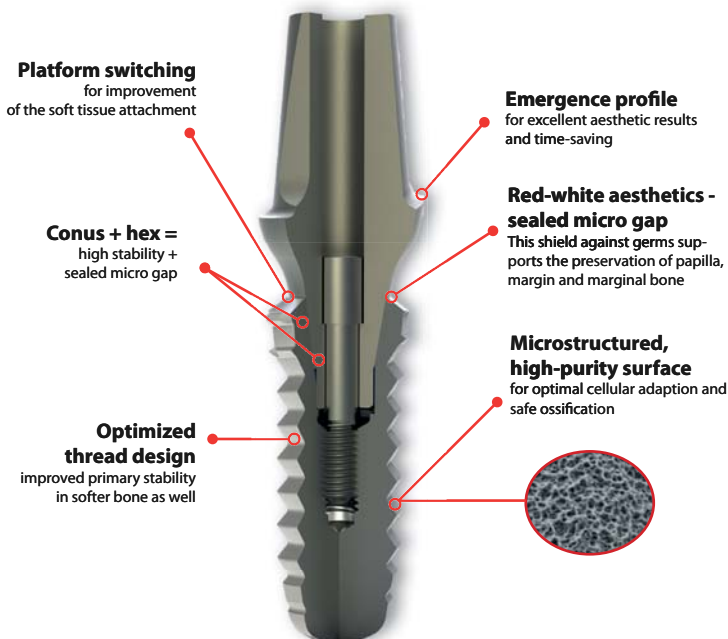
AD



**YOUR ADVANTAGE! THE 2 IN 1 CONCEPT:**  
**Conical connection - with anti-rotation hex!**



**The new IMPLA™ hybrid connection**



**Special Promotion for your start into the IMPLA™ system:**

**30 implants, abutments, gingiva formers, lab analogs, transfers and surgical kit!**

Promotion Code: P121154

**Be ahead of your competition!**

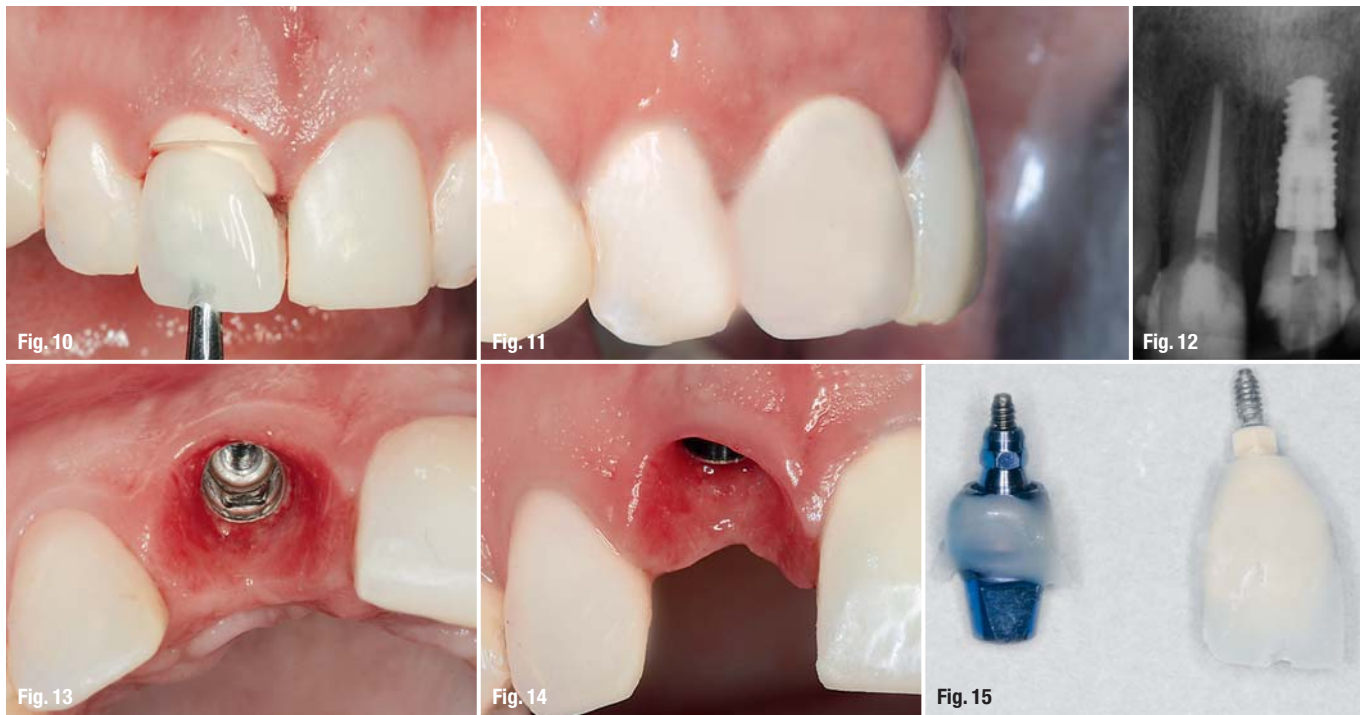- » Wide range of trainings available for you and your team
- » Controlled German Quality
- » Great results + maximum security = satisfied customers



**Call us today and become a partner.**  
 For additional information visit our website:  
[www.schuetz-dental.com](http://www.schuetz-dental.com)







**Fig. 10** Implant-supported, screw-retained provisional restoration.  
**Fig. 11** Clinical situation one week post-implant placement.  
**Fig. 12** Corresponding X-ray.  
**Fig. 13** Occlusal view of the soft-tissue contour at the end of osseointegration.  
**Fig. 14** Facial view of the soft-tissue contour at the end of osseointegration.  
**Fig. 15** Impression coping customised in the cervical area to match the emergence profile of the provisional crown.

at all stages of the treatment. Before the start of the surgical treatment, initial impressions were taken with alginate. Study models were fabricated based on these and then mounted on a semi-adjustable articulator. A detailed wax-up was made for tooth #11 and a provisional crown was fabricated from heat-polymerised acrylic resin. The provisional crown was trimmed at the interior surfaces for use with a provisional implant abutment.

The periodontal fibres surrounding tooth #11 in the alveolar socket were loosened with a periosteal elevator (DENTSPLY Friident) and the tooth was extracted atraumatically (Figs. 4 & 5). The horizontal fracture of the root below the cervical area of the extracted tooth verified the initial diagnosis (Fig. 6). The socket walls were considered intact and inspection revealed no signs of fenestration. Any residual fibres were scraped off. The implant site was then prepared according to the manufacturer's guidelines and a XIVESplus implant (DENTSPLY Friident; 4.5x 11 mm) was inserted with sufficient initial stability, which was mainly achieved on the palatal side of the implant site. The implant collar was placed 3 mm below the cemento-enamel junction of the adjacent teeth (Figs. 7 & 8).

The titanium TempBase abutment, which acted as the placement head, was removed from the implant and an EsthetiCap plastic abutment (both DENTSPLY Friident) was fitted on the implant (Fig. 9). The design of this anatomically shaped abutment supports the soft tissue and interdental papillae adequately. Furthermore, it enables the creation of a

suitable emergence profile from the moment of implant placement. The highly polished surfaces prohibit accumulation of dental plaque and facilitate oral hygiene. At this stage, soft-tissue support is crucial for achieving an aesthetic result for the provisional restoration and maintaining it to the final stage.

The previously fabricated provisional crown was fitted on the abutment with autopolymerised acrylic resin, maintaining the access hole on the palatal aspect for the fixation screw (Fig. 10). Furthermore, the outer contour of the provisional crown was checked repeatedly to ensure support of the gingival margin without excessive pressure, which could lead to tissue shrinkage. The provisional crown was designed 1 mm shorter than tooth #21 to avoid possible occlusal loading at maximum intercuspation or side movement (Fig. 11). The implant position in the socket and the abutment fit were checked radiographically (Fig. 12).

The osseointegration period of four months was uneventful and the soft tissue around the implant did not exhibit any signs of inflammation. The interdental papillae were maintained in shape, height and volume (Figs. 13 & 14). In order to support the soft tissue around the implant for impression taking, a prefabricated impression coping was customised using photopolymerised low-viscosity composite material (Figs. 15 & 16). For this implant, an all-ceramic prefabricated zirconium CERCON abutment (DENTSPLY Friident) was selected. This abutment offers adequate soft-tissue support and a suitable



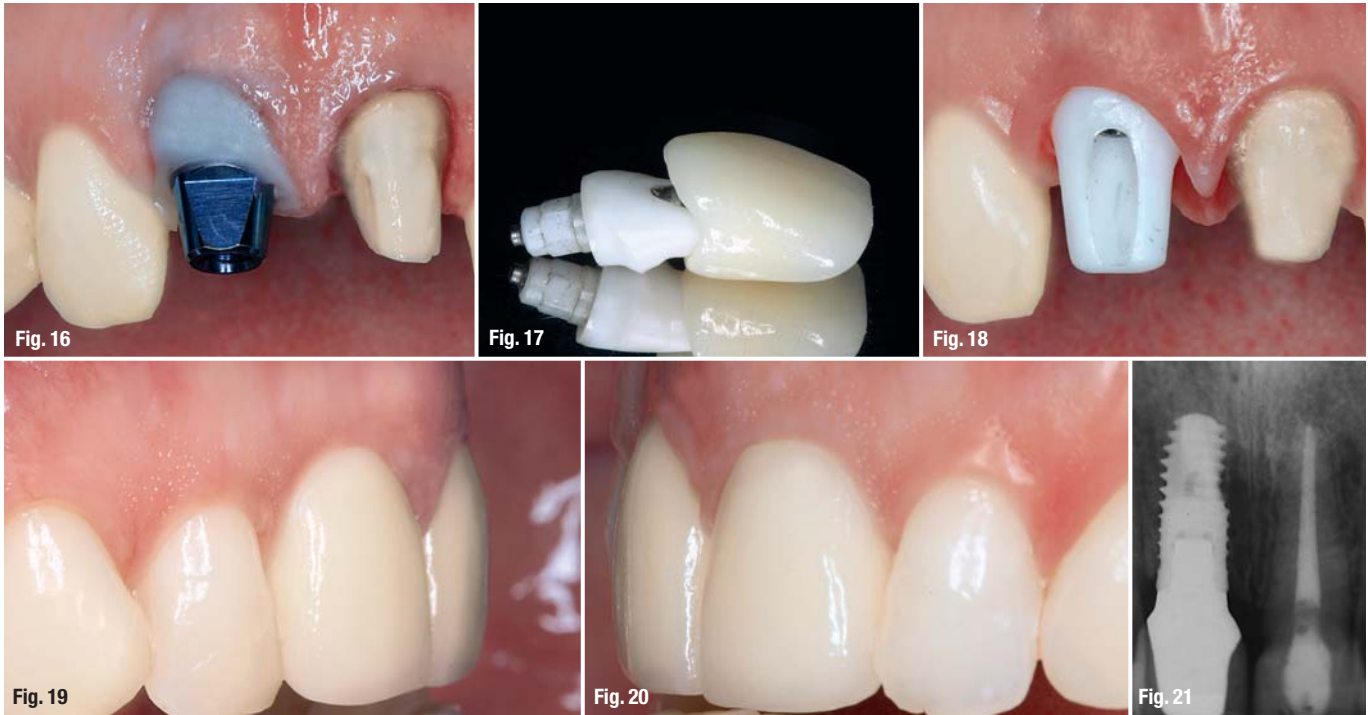Behind every successful  
implantologist is an Implantmed



Scan the QR code with  
your mobile telephone  
for more information on  
Implantmed

With the new Implantmed you perform implant procedures with maximum precision. The unit is easy to operate and guarantees longer working without fatigue – thanks to the **lightweight**, yet **powerful motor** and the ergonomically-shaped contra-angle handpiece. And the integrated **thread cutter function** helps you with especially hard bone.

implantmed



**Fig. 16** Impression for the prepared natural tooth and the XiVE S plus implant.

**Fig. 17** All-ceramic crown and corresponding implant abutment (CERCON).

**Fig. 18** Try-in of the modified ceramic CERCON abutment.

**Fig. 19** Final clinical result: buccal view of the implant restoration.

**Fig. 20** Buccal view of the restored natural tooth.

**Fig. 21** Radiographic control at one year post-implant placement.

emergence profile for the crown (Figs. 17 & 18). The use of ceramic abutments prevents discoloration in the gingival area even when the soft issue is thin. Two porcelain crowns were fabricated to the desired shape and colour (Figs. 19 & 20). The final result fulfilled the patient's aesthetic demands and her initial insecurity dissolved after the insertion of the implant and the provisional restoration. The hard- and soft-tissue condition around the implant was stable at the one-year recall (Fig. 21).

### Discussion and conclusion

Implant placement subsequent to tooth extraction in conjunction with the use of provisionals in the anterior maxillary region is certainly challenging for the dental practitioner. However, this treatment modality offers several advantages, including reduced clinical time, a single local anaesthetic injection, a flapless procedure and immediate placement of the implants. From the patient's point of view, the immediate incorporation of a fixed implant-supported provisional restoration is very acceptable and even requested. With the clinical procedure described here, both dentist and patient can evaluate the aesthetics of the restoration. Soft-tissue support is enhanced and achievement of the desired result is facilitated. With initial implant stability, proper tissue management and correct use of the available implant components, a predictable aesthetic result can be produced. On the other hand, occlusal control, oral hygiene and a regular recall programme should be considered prerequisites for maintaining a long-lasting restoration.

Single-tooth implants have shown high success rates in both the anterior and the posterior regions of the maxilla and the mandible.<sup>1-4</sup> Immediate post-extraction implant placement has been done since the early years of the clinical application of implants with very good clinical outcomes.<sup>5-8</sup> Decisive factors for immediate implant placement are lack of infection in the periodontal tissues and an intact tooth socket. Immediate incorporation of a temporary restoration has been presented in the literature with most encouraging results.<sup>7-14</sup> Although clinical experiences have advocated this clinical technique for many years, more extended long-term clinical studies are necessary to prove the efficacy of the method and establish a stable clinical protocol.

*Editorial note: A complete list of references is available from the publisher.*

### \_contact

### implants

**Dr Stefanos Kourtis**

Dept. of Prosthodontics, University of Athens  
Plaza Chrys. Smyrnis 14  
17121 Athens  
Greece

Tel.: +30 21 0 935 7306

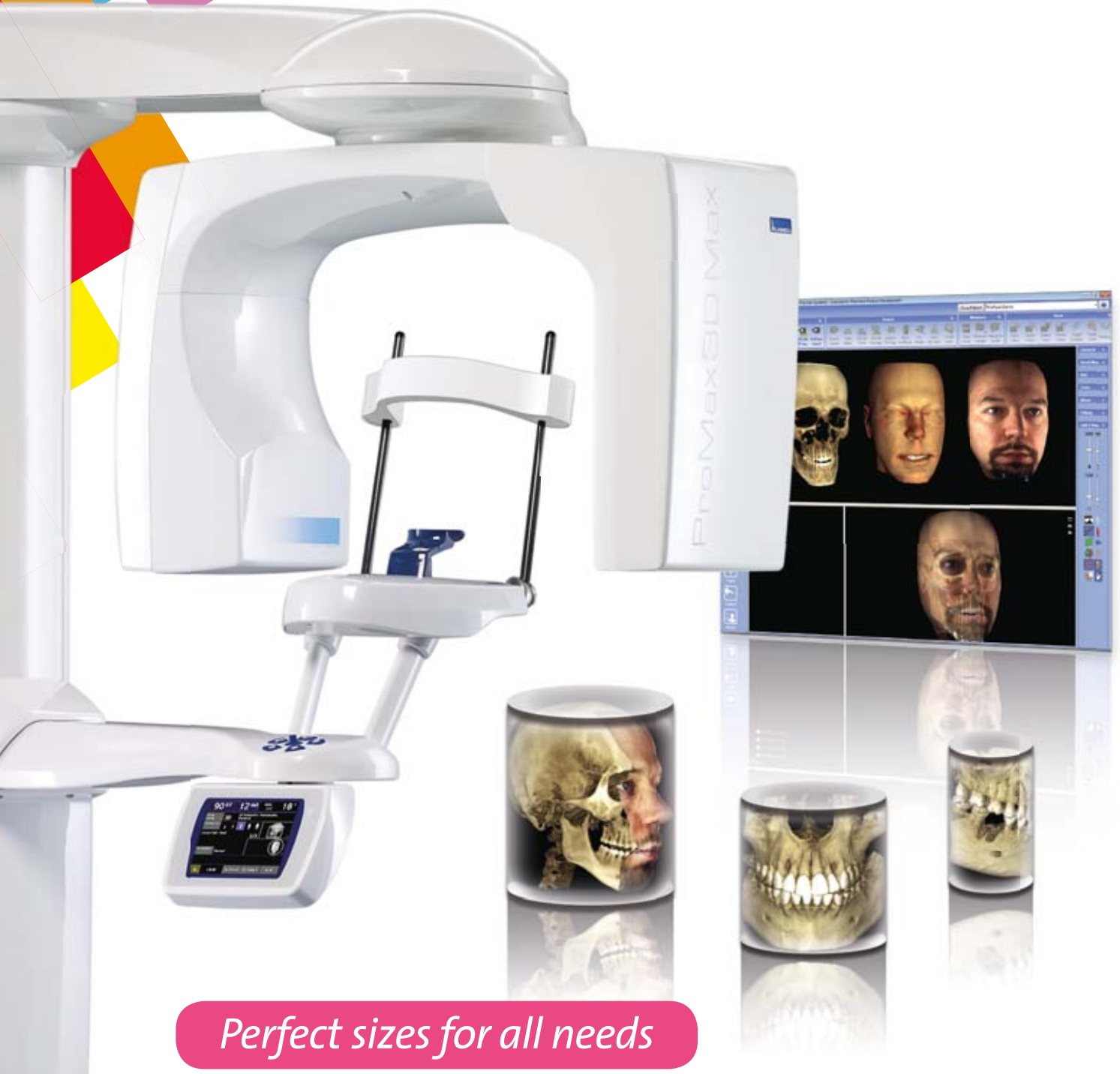stefkour@dent.uoa.gr





# Planmeca ProMax<sup>®</sup> 3D

*Unique product family*



*Perfect sizes for all needs*

*3D X-ray • 3D photo • panoramic • cephalometric*

*Romexis<sup>®</sup> software completes 3D perfection*



Digital perfection™

More information

[www.planmeca.com](http://www.planmeca.com)

Planmeca Oy  
Asentajankatu 6, 00880 Helsinki, Finland  
tel. +358 20 7795 500, fax +358 20 7795 555  
sales@planmeca.com

**PLANMECA**

# Minimally invasive crown lengthening as an alternative to implant treatment

Author\_Prof Marcel Wainwright, Germany

## \_Introduction

Crown fractures frequently force the treatment provider to make a clear-cut treatment choice between tooth preservation and dental implant treatment. Speakers at implantological congresses tend to present impressive implant/prosthetic solutions for anterior fracture cases, to the point where the audience could be tempted to believe that this was the only appropriate treatment alternative. The following case report documents a tooth preservation option that is simple to perform, minimally invasive and successful.

A 66-year-old male patient presented at our office with a fractured upper left lateral incisor (tooth #22). The clinical crown of this tooth had fractured in the marginal region, with the pulp of the tooth slightly

exposed in one location. The pulp tissue vitality test showed a weak positive result. The patient was completely free of pain symptoms. There was no root mobility. Available treatment options were discussed with the patient based on a single-tooth radiograph (Fig. 1). The neighbouring teeth #21 and 23 had been restored with all-ceramic crowns two years previously. However, a three-unit fixed prosthetic denture was rejected by the patient, as was surgical treatment with immediate implant placement following extraction.

Conservative tooth preservation was therefore the treatment of choice for patient and treatment provider alike. The patient was informed that tooth preservation could only be successful if the required orthograde root-canal instrumentation was possible, the tooth was symptom free and biological width could be restored prior to the fabrication of a crown restoration. If these requirements were not met, an implant/prosthetic solution would have to be resorted to as an alternative.

## \_Treatment sequence

Following extensive patient education and pre-therapeutic discourse, the patient received local anaesthetic, and tooth #22 was instrumented. This

**Fig. 1** Single-tooth radiograph showing fractured tooth #22.

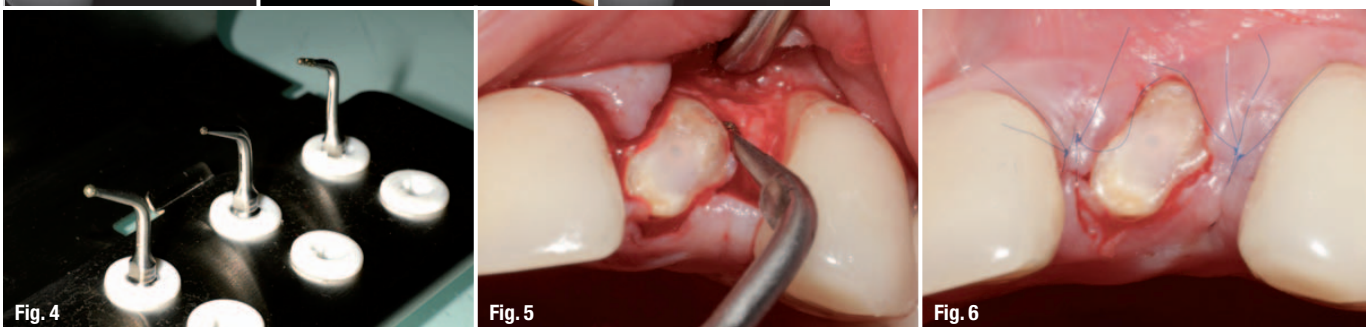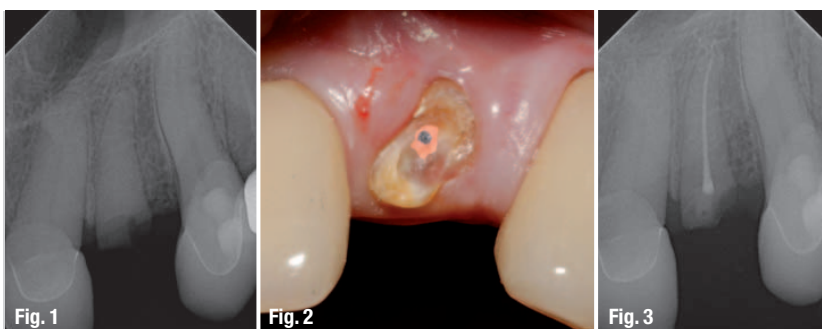
**Fig. 2** Thermoplastic root filling in tooth #22.

**Fig. 3** Radiograph of the orthograde root filling, found to be lege artis.

**Fig. 4** Crown-lengthening kit (Acteon).

**Fig. 5** Ultrasonic crown lengthening of tooth #22 using minimally invasive incisions.

**Fig. 6** Microsurgical 8-0 suture.



# laser

international magazine of laser dentistry

was initially difficult, as the root canal was slightly obturated. Following instrumentation to ISO 20, the tooth was prepared for a root filling. Instrumentation to more than ISO 20 did not appear advisable, as the reduced diameter of tooth #22 already constituted an increased fracture hazard during preparation of the endodontic post or in the presence of lateral forces.

At the same visit, an orthograde endodontic filling was placed using a thermoplastic restorative technique (Thermafil, DENTSPLY DeTrey) and Sealapex (SybronEndo; Fig. 2). The control radiograph showed that the root-canal filling had been placed *lege artis* (Fig. 3).

Surgical crown lengthening was planned for four weeks later. Like all surgical interventions at our clinic, this crown lengthening was performed using ultrasonic surgical instruments (Acteon). In this protocol, the surgeon employs a surgical kit containing multiple calibrated diamond instruments (Fig. 4). A minimal circumferential incision was performed under local anaesthesia, completely dispensing with extensive flap elevation procedures or relieving incisions.

The marginal bone was prepared approximately 2 mm farther apically to provide sufficient biological width for a subsequent crown (Berglundh 1992). The use of ultrasonic surgical instruments allows the surgeon to proceed quickly while protecting the tissue, as these instruments help reduce the risk of iatrogenic damage to the root dentine, a risk that is elevated when using conventional rotary instruments (Fig. 5). The site was sutured closed using a synthetic monofilament thread (8-0 Trofilene, Stoma; Fig. 6). Microsurgical suturing is indispensable in the anterior region. If it is neglected, this will result in tissue recession and impaired aesthetics.

The sutures were removed one week later. Wound healing was uneventful, and the patient was completely free of pain and other symptoms throughout the entire treatment. After an additional week, a post-and-core build-up was done using the Fibrapost and Sealacore system (Produits Dentaires; Fig. 7). The root canal was prepared with reamers, which are available in four different diameters (Fig. 8). The option to use the depth stop to pre-calibrate the reamer to the desired length was helpful, not least as a precaution against excessive preparation depths (Figs. 9 & 10). The root canal was prepared under copious irrigation and conditioned with a self-etching bonding system (Sealacore; Fig. 11).

The UDMA-based resin cement (Sealacore) was introduced into the root canal with a syringe and application tip (Fig. 12). The Fibrapost is a fibreglass-reinforced resin endodontic post (Fig. 13) with retention



## One issue free of charge!

You can also subscribe via  
[www.oemus.com/abo](http://www.oemus.com/abo)

 **Subscribe now!**

- I hereby agree to receive a free trial subscription of **laser international magazine of laser dentistry** (4 issues per year). I would like to subscribe to **laser** for € 44 including shipping and VAT for German customers, € 46 including shipping and VAT for customers outside Germany, unless a written cancellation is sent within 14 days of the receipt of the trial subscription. The subscription will be renewed automatically every year until a written cancellation is sent to OEMUS MEDIA AG, Holbeinstr. 29, 04229 Leipzig, Germany, six weeks prior to the renewal date.

**Reply** per Fax +49 341 48474-290 to OEMUS MEDIA AG or per E-mail to [grasse@oemus-media.de](mailto:grasse@oemus-media.de)

Last Name, First Name	
Company	
Street	
ZIP/City/Country	
E-mail	Signature

Notice of revocation: I am able to revoke the subscription within 14 days after my order by sending a written cancellation to OEMUS MEDIA AG, Holbeinstr. 29, 04229 Leipzig, Germany.

Signature



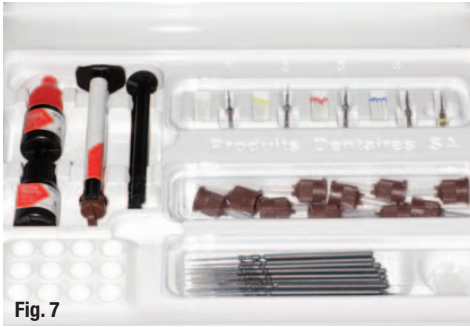

Fig. 7

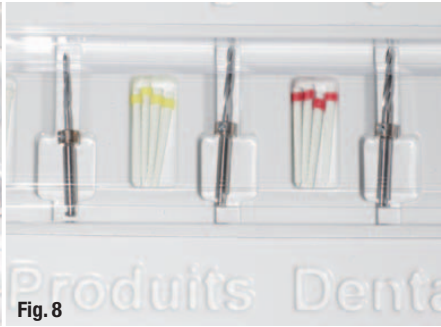

Fig. 8

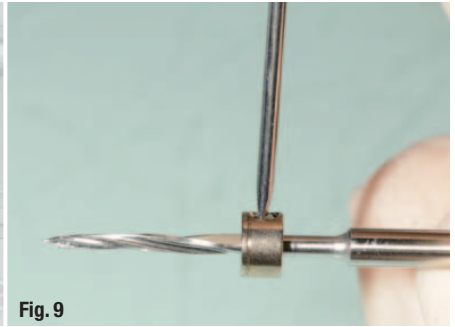


Fig. 9

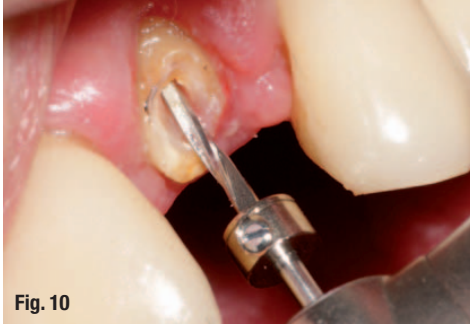

Fig. 10

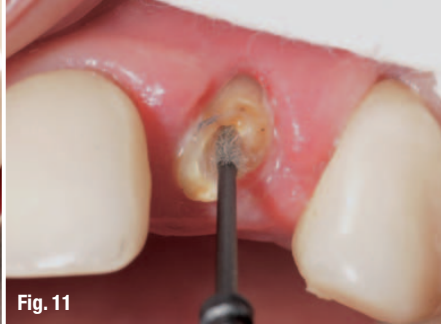

Fig. 11

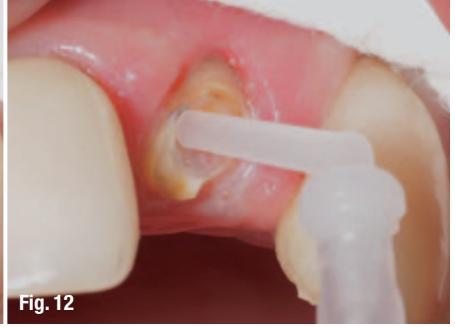

Fig. 12

**Fig. 7\_**Fibrapost and Sealacore system.

**Fig. 8\_**Endodontic reamers.

**Fig. 9\_**Defining preparation depth using the adjustable stop.

**Fig. 10\_**Endodontic preparation using a reamer.

**Fig. 11\_**Conditioning the lumen of the root canal for accepting the endodontic post.

**Fig. 12\_**Applying the resin cement.

grooves. Our clinic uses metal-free endodontic post systems exclusively, as their biomechanical properties are clearly superior to those of metal posts. One important aspect is the absorption of the vertical lateral masticatory forces, which is better for the resin posts than for the metal posts because the former have material characteristics resembling those of natural dentine. In addition, the optical properties of the system (translucency, transparency) facilitate highly aesthetic anterior solutions while eliminating the risk of corrosive discoloration.

native to implant/prosthetic treatment, provided that the tooth is free of pain, that the preconditions for endodontic treatment are met, and that the root is stable. Today's post-and-core systems are expected to be metal free and to offer easy handling and aesthetic long-term results.

Our experience with the Fibrapost and Sealacore system has been positive throughout; it has produced excellent results and suits our procedures well.

Following core shaping and preparation (Fig. 14), a polyether impression was taken for an all-ceramic crown (IPS e.max, Ivoclar Vivadent). The definitive crown was delivered a week after tooth preparation and cemented with a dual-curing self-adhesive cement (RelyX Unicem, 3M ESPE; Fig. 15).

**Fig. 13\_**Fibrapost with retention grooves.

**Fig. 14\_**Core placement and preparation.

**Fig. 15\_**All-ceramic crown in situ. Note the healthy and complete papillae and periodontal tissues.

### Summary

When the clinical crown of a tooth is lost due to fracture, surgical crown lengthening and tooth restoration based on a post and core is a viable alter-

### contact implants

**Prof Marcel Wainwright**  
DentalSpecialists  
Kaiserswerther Markt 25  
40489 Düsseldorf, Germany  
[www.dentalspecialists.de](http://www.dentalspecialists.de)




Fig. 13

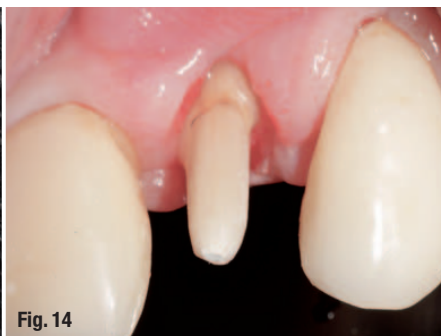

Fig. 14

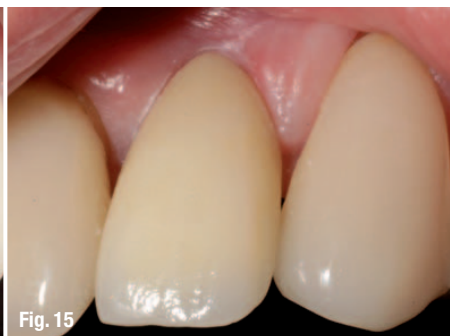

Fig. 15



# 42<sup>ND</sup>

October 5-6, 2012//Hamburg, Germany//Elysee Hotel

Congress President//Prof. Dr. Dr. Frank Palm/DE  
Scientific Director//Dr. Roland Hille/DE

## INTERNATIONAL ANNUAL CONGRESS OF THE DGZI




Quality driven implantology –  
On the way to long term success

### Speakers

Prof. Dr. Dr. Kai-Olaf Henkel/DE  
Prof. Dr. Dr. George Khoury/DE  
Prof. Dr. Dr. Albert Mehl/CH  
Prof. Dr. Herbert Deppe/DE  
Prof. Dr. Werner Götz/DE  
Prof. Dr. Shoji Hayashi/JP  
Prof. Dr. Andrea Mombelli/CH  
Prof. Dr. Dr. Frank Palm/DE  
Prof. Dr. Suheil Boutros/US  
Prof. Dr. Peter Rammelsberg/DE  
Prof. Dr. Anton Sculean/CH  
Prof. Dr. Dr. Jörg R. Strub/DE  
Prof. Dr. Hans-Peter Weber/US

Prof. Dr. Thomas Weischer/DE  
Priv.-Doz. Dr. Andreas Bindl/CH  
Dr. Tomohiro Ezaki/JP  
Dr. Daniel Ferrari, MSc/DE  
Dr. Sami Jade/LB  
Dr. Ramy Fahmy Rezkallah/EG  
Dr. Rolf Vollmer/DE  
Dr. Osamu Yamashita/JP  
ZTM Andreas Kunz/DE  
ZTM Tom Lassen/DE  
ZTM Christian Müller/DE  
Mohamed Moataz M. Khamis  
B.D.S., M.S., Ph.D./EG

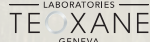Gold Sponsor:



Silver Sponsor:



Bronze Sponsor:



### FAX REPLY

**+49 341 48474-390**

Please send me further information on the  
42<sup>ND</sup> INTERNATIONAL ANNUAL CONGRESS  
OF THE DGZI October 5-6, 2012, in Hamburg, Germany.



Office Stamp



# Annual award for the advancement of dental research and development

Author: ITI Center



The International Team for Implantology (ITI), a leading academic organization dedicated to the promotion of evidence-based education and research in the field of implant dentistry, is inviting submissions for the highly regarded André Schroeder Research Prize as of February 1, 2012.

The André Schroeder Research Prize, which carries a cash endowment of CHF 20,000, is one of the most prestigious awards in implant dentistry today. It is awarded to independent researchers for their contribution to the advancement of research and development in implant dentistry. In this way the ITI promotes and supports the dissemination of new scientific findings in implant dentistry, oral tissue regeneration and related fields. The annual award is adjudicated by the ITI Research Committee that is made up of international specialists in implant dentistry and related fields. In 2012, it will be presented at the ITI Congress Canada which will take place from September 21–22 in Toronto.

The award was established 20 years ago and is dedicated to the late Professor André Schroeder (1918–2004), the founding ITI President, who pioneered implant dentistry and whose lifework con-

tributed significantly to the course of modern implant dentistry. Last year's winner was Dr Nikola Saulacic from the University of Bern, Switzerland, for his experimental study on "Bone Apposition to a Titanium-Zirconium Alloy Implant Surface".

Researchers who can demonstrate new findings in implant dentistry and related fields are invited to apply for the 2012 André Schroeder Research Prize. The application form can be downloaded from the ITI website as of February 1, 2012. The deadline for manuscript submission is April 15, 2012. More information about the André Schroeder Prize as well as the terms and conditions of participation are available at the ITI website [www.iti.org](http://www.iti.org).

[\\_contact](#)

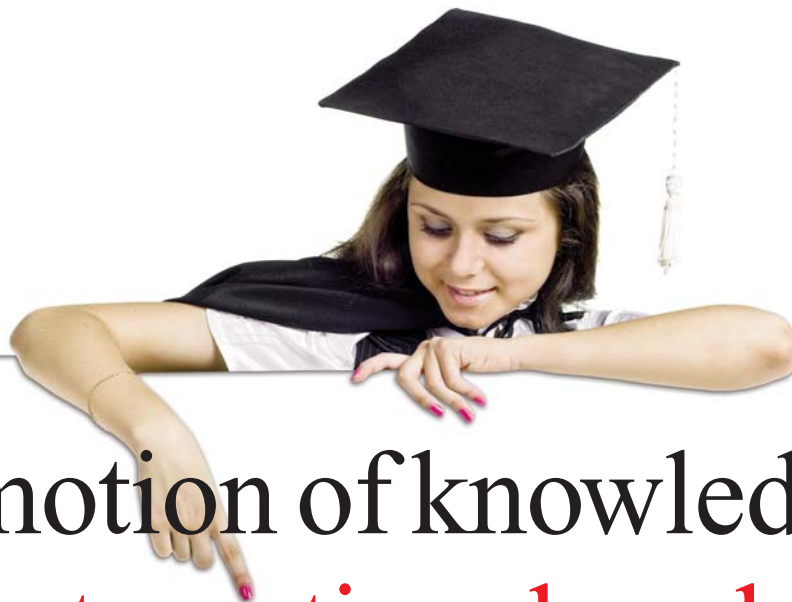[implants](#)

## ITI — International Team for Implantology

ITI Center, Peter Merian-Weg 10  
4052 Basel, Switzerland

[iticenter@iticenter.ch](mailto:iticenter@iticenter.ch)  
[www.iti.org](http://www.iti.org)





# Promotion of knowledge and **international exchange** at 20 ITI Scholarship Centers

**Author\_**ITI Center

The International Team for Implantology (ITI), a leading academic organization dedicated to the promotion of evidence-based education and research in the field of implant dentistry, is giving 25 young clinicians the opportunity to spend 12 months at one of the 20 ITI Scholarship Centers worldwide in order to enhance their knowledge and skills in implant dentistry.

The goal of the ITI Scholarship Program is to help young clinicians further their training in implant dentistry and to foster international exchange along with professional networking as an enriching educational experience. All ITI Scholarship Centers are renowned university departments or clinics under the supervision of a long-standing ITI Fellow. The Scholars are given insight into every aspect of implant treatment for patients during their one-year stay, during which special emphasis is placed on case planning, implant surgery and prosthetic restoration. Research and training are also part of the program in most Scholarship Centers.

The ITI supports each ITI Scholar with a stipend to the value of CHF 40,000 towards living expenses. In addition, each Scholar is given free ITI membership for the Scholarship year which includes, among others, free access to ITI Study Clubs and the ITInet, the ITI's global online platform. As ITI Members, they are also regularly invited to local activities and receive a welcome package with the latest copy of the ITI Treatment Guide.

Since 1998, the ITI has supported ITI Scholars and Scholarship Centers with more than 12 million Swiss Francs in total. 215 Scholars from more than 40 different countries have taken part in this annual program so

far and gained valuable experience for their future careers. "We find it important to give young clinicians this opportunity to learn from experienced mentors, discover other ways of working and new cultures," said Prof. Dr. Frauke Müller, Chair of the ITI Scholarship Committee. "After their scholarship year, they take the acquired knowledge back home to apply and disseminate it in their own country."

The ITI Scholarship Committee is responsible for evaluating and selecting the Scholars and continually receives an increasing number of applications for the program. More than 100 clinicians from 39 countries submitted an application this year out of which the 25 best qualified were chosen.

Further information on the ITI Scholarship Program and the terms and conditions of participation are available on the ITI website [www.iti.org](http://www.iti.org).



Prof Dr Frauke Müller, Chair of the ITI Scholarship Committee.

**\_contact**

**implants**

**ITI — International Team for Implantology**

ITI Center, Peter Merian-Weg 10  
4052 Basel, Switzerland

[iticenter@iticenter.ch](mailto:iticenter@iticenter.ch)  
[www.iti.org](http://www.iti.org)

# Mastering Tissue Response Successfully

As part of the 15<sup>th</sup> Friadent World Symposium, more than 2,500 dentists and technicians interested in dental implantology from 60 countries worldwide visited the Congress Center Hamburg (Germany) from 15 until 17 March 2012. More than 100 internationally recognized speakers from academia and industry discussed topics related to the conference theme "Mastering Tissue Response Successfully" under the scientific leadership of Dr David Garber (USA), Prof Fouad Khoury (Germany) and Prof Ye Lin (China). DENTSPLY Friadent Germany CEO Dr Werner Groll underlined the importance of stable periimplant-tissue conditions for the long-term success of implant treatment in his welcome address to the participants. With good reason, the company has focused much of its research and development work on this kind of issue: only when all components and treatment steps interlock perfectly, the increasing aesthetic demands of patients for implant-based prosthetics and for stable long-term tissue conditions are met, argues Dr Groll.

On Thursday, 15<sup>th</sup> of March, the World Symposium Pre-Congress began with two workshops on augmentation and soft tissue management, as well as the "Forum Dental Implants in Practice". On Friday and Saturday morning, the World Symposium was started with a half-hour common lecture session each. Afterwards, the program branched into several parallel conferences. While a broad mix of topics covered all clinical and scientific aspects of tissue preservation on Podium One, surgical and prosthetic issues were discussed on paral-

lel platforms. The participants were provided with a "Program Navigator" by DENTSPLY Friadent, making individual program proposals by considering personal preferences.

## Celebrating with friends

The evening event, which is traditionally part of the DENTSPLY Friadent World Symposium, was very popular with the guests. The visitors enjoyed the atmosphere of the Hamburg harbor and a lively piece of commercial tradition in "Warehouse 52". This classic storage shed from the Wilhelmine era today is one of the most popular event venues in Hamburg. With the shanty choir "De Klaashahns", brass band "schräg (slanted)" and the show band "Szenario", three completely different, but nevertheless excellent groups provided great entertainment. In summary, the 15<sup>th</sup> DENTSPLY Friadent World Symposium can be considered a great success. Once again, the company presented itself as an innovative premium provider of high-class topics and speakers at international level. The abundance of clinical studies presented in the course of the lectures demonstrates the company's consistent focus on user- and patient-friendly treatment solutions with a scientific foundation. Many participants are already looking forward to the next World Symposium, held in Vienna in 2014.

Lecture abstracts can be obtained under [www.dentsply-friadent.com/symposium](http://www.dentsply-friadent.com/symposium). This website is now smartphone-optimized. \_





# International events

**2012**

**ITI Congress Germany**

Cologne, Germany  
27–28 April 2012  
[www.iti.org/events](http://www.iti.org/events)

**6<sup>th</sup> CAD/CAM & Computerized Dentistry  
International Conference**

Dubai, UAE  
3–4 May 2012  
[www.cappmea.com](http://www.cappmea.com)

**4<sup>th</sup> International CAMLOG Congress**

Lucerne, Switzerland  
3–5 May 2012  
[www.camlogcongress.com](http://www.camlogcongress.com)

**ITI Congress Switzerland**

Biel, Switzerland  
5 May 2012  
[www.iti.org/events](http://www.iti.org/events)

**IADR General Session & Exhibition**

Rio de Janeiro, Brazil  
20–23 June 2012  
[www.iadr.org](http://www.iadr.org)

**OSSTEM Europe Meeting 2012 Lisbon**

Lisbon, Portugal  
22–23 September 2012  
<http://en.osstem.com>

**AAID 61<sup>st</sup> Annual Meeting**

Washington, DC, USA  
3–6 October 2012  
[www.aid-implant.org](http://www.aid-implant.org)

**42<sup>nd</sup> International Congress of DGZI**

Hamburg, Germany  
5–6 October 2012  
[www.dgzi-jahreskongress.de](http://www.dgzi-jahreskongress.de)





# Manufacturer News

## CAMLOG

### 4<sup>th</sup> International CAMLOG Congress

The conference motto "Feel the pulse of science in the heart of Switzerland" has obviously struck a chord with potential participants. Three months before the congress in Lucerne, the workshops taking place the day before the event on Mount Pilatus are already fully booked up. And for the thrilling party "Let's rock the Alps!" at 1,600 meters above sea level, CAMLOG has virtually been overrun by a wave of registrations; the Friday party was soon fully sold out and party registrations can now only be accepted for Saturday, May 5.



And to conclude the congress, the popular "Meet the experts" panel discussion will be held. Complex cases with compromised and demanding patients will be presented and discussed. The panel will be moderated by K.-L. Ackermann, G. Alcoforado, and A. Zöllner.

Registration for the Congress is still open, and besides the state-of-the-art congress program with world renowned speakers. Lucerne, with its picturesque town, its mountain views, and the lake, is absolutely worth a visit, too.

CAMLOG is looking forward to welcoming numerous guests to the 4<sup>th</sup> International Congress in the heart of Switzerland to "Feel the pulse of science in the heart of Switzerland", May 3 through 5, 2012.

For more information and registration, please go to: [www.camlogcongress.com](http://www.camlogcongress.com)



At the Lucerne Culture and Congress Center directly on Lake Lucerne, an internationally renowned panel of speakers will present current topics of implant dentistry, e.g. innovations in implant-abutment connections, long-term clinical experience with platform switching, the demographic shift and increasingly aging patients, as well as current trends in "digital dentistry".

#### CAMLOG Foundation

Margarethenstrasse 38  
4053 Basel, Switzerland

[foundation@camlog.com](mailto:foundation@camlog.com)  
[www.camlogfoundation.org](http://www.camlogfoundation.org)

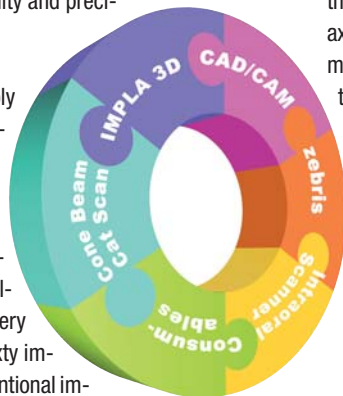
## Schütz Dental

### The Complete Digital Workflow becomes Reality - Now available!

Schütz Dental, Rosbach/Germany, offers a completely coordinated digital workflow starting at the dentist's office and ending in the lab where the restorations are produced with CAD/CAM technology. The digital process has been streamlined and accelerated by "simple clicks" and an adjustment of hardware and software components, for improved reliability and precision.

This efficient workflow includes five sensibly coordinated components: Three-dimensional function analysis of the jawbones by the zebris Jaw Motion Analysis registration system (component one), IMPLA™ 3-D navigation for computer assisted, virtual implantation (component two), and dental technology service at the lab even before the surgery (component three). With a range of over sixty implant systems presently available, all conventional im-

plant shapes are considered in the implantation software. Open interfaces facilitate data import and export, allowing to network Tizian™ Creativ RT CAD software with intraoral scanners (component four). Alternatively, the dentist can do a conventional impression. Finally, the dentist can integrate the temporary restoration produced by the lab, where all data converges. If one intermediate step or the complete process was not digitalized so far, the master model, the counter-bite or the bite registration are placed inside the Tizian™ scanner. This is where the computer job begins (component five): The technician designs the prosthesis on screen and sends the data to his milling unit. Schütz Dental offers three different milling systems: Tizian™ Cut, Tizian™ Cut eco plus and the five-axes system Tizian™ Cut 5. Tizian™ Translucent blanks produce aesthetic monolithic restorations. The system is completed by the Tizian™ ceramic system for technicians who want to finish their restorations with other processing technologies.



#### Schütz Dental GmbH

Dieselstr. 5-6  
61191 Rosbach, Germany

[info@schuetz-dental.de](mailto:info@schuetz-dental.de)  
[www.schuetz-dental.com](http://www.schuetz-dental.com)

DENTSPLY Friadent

**DENTSPLY Friadent World Symposium**

Again, for the 15<sup>th</sup> time, internationally renowned speakers and delegates active in implantology will meet together in March 2012 to share their scientific and practical experience and to discuss the latest insights within the context of the DENTSPLY Friadent World Symposium. The focus of the conference, which, as the first of its kind, can already look back on 20 years of continuity, is the topic of "Tissue Response" – with valuable background information and practical solutions for long-term stable hard and soft tissues in daily practice.

The implant position in the bone and the type and geometry of the connection are only some of the aspects that decide a successful integration of the implant restoration and hence the long-term esthetics. What role does the interaction between modern implant surfaces and bone play, and how can treatment concepts complement stable soft tissue support? This is the topic of the first surgically-oriented ses-



sions of the Symposium. But it's not only the surgery that has a direct influence on the long-term success of implant-supported solutions and healthy tissue conditions. Consequently, the basic principles of prosthetics also take center stage at the 15<sup>th</sup> DENTSPLY Friadent World Symposium.

Whether in the Marketplace, where visitors will experience the concepts and solutions from the scientific program live and can actively "come to grips" with them in the hands-on training sessions, or in the Poster Gallery, which offers all attendees the oppor-

tunity to present, discuss and submit their work for a Poster Award, scientific exchange is the focus of the Symposium, as well as at the workshops on anatomical compounds for "Bone Grafting Techniques" and "Soft Tissue Management", which take place as early as Thursday. There are more than enough reasons to take part again in the practice-orientated Symposium in 2012. "After this Symposium, visitors will be right up to date with dental treatment and implantological concepts. Numerous internationally recognized experts in the clinical, scientific and prosthetics fields will make sure of it", declares the associate professor, Dr Martin Groten, Director of Clinical Research & Education for DENTSPLY Friadent, already awakening interest in the run-up to the Symposium. You will find more information on the 2012 DENTSPLY Friadent World online: [www.dentsply-friadent.com/symposium](http://www.dentsply-friadent.com/symposium).

**DENTSPLY Friadent**

Steinzeugstraße 50  
68229 Mannheim, Germany

[friadent@dentsply.com](mailto:friadent@dentsply.com)  
[www.dentsply-friadent.com](http://www.dentsply-friadent.com)

Philips

**Dental Hygienists would recommend Sonicare DiamondClean to each other**

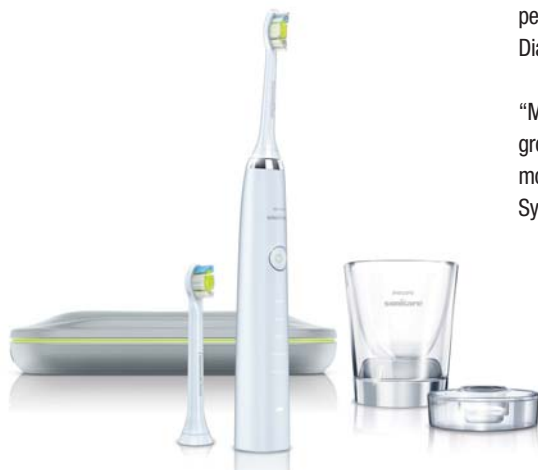Members of the German Society of Dental Hygienists (Deutsche Gesellschaft für Dentalhygieniker/-innen, DGDH e.V.) have put Philips Sonicare DiamondClean through its paces under day-to-day clinical conditions. "Afterwards, 85 % of the users wanted to recommend this sonic toothbrush to

their colleagues", reports Sylvia Fresman, chairman of the DGDH.

The dental hygienists especially liked the new brush head: having 44 % more bristles than the head of a ProResults brush, as well as a diamond-shaped arrangement of the bristles, the brush head plays a crucial role in Sonicare's cleansing performance. A total of 89 % of the testers described an intense cleansing experience, with 87 % stating that Sonicare DiamondClean was "pleasantly powerful and effective".

This model of the Philips Sonicare line can clean even hard-to-reach areas, 74 % of the test group confirmed. Moreover, 30 % of the testers stated that they perceived a whitening effect after using Sonicare DiamondClean.

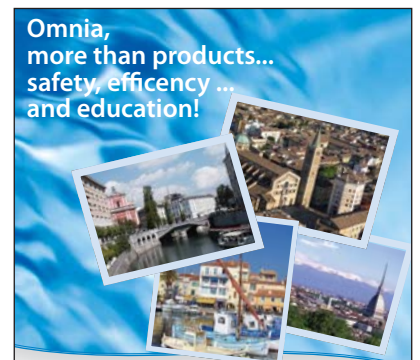"Most impressive to me was the fact that 65 % of the group said that Sonicare DiamondClean was one of the most remarkable new products in the past IDS year", Sylvia Fresmann adds.



**Philips GmbH**  
Lübeckertordamm 5  
20099 Hamburg, Germany

[sonicare.deutschland@philips.com](mailto:sonicare.deutschland@philips.com)  
[www.philips.de/sonicare](http://www.philips.de/sonicare)

AD



**Omnia Education Program**

OMNIA presents a complete program of education that will be held throughout 2012. 2 days courses divided into 3 parts:

- Lectures
- Live surgery
- Hands-on

The courses are held in international locations (Italy, Slovenia, France) by internationally english speaking surgeons. The lecture session will be followed by a live surgery and a hands-on session on animal jaws.

Only a restricted number of participants is admitted (12-20) to offer the due attention and support to each of them. Time will be also devoted to teambuilding activities which will change according to the different locations.




Via F. Delnevo, 190 - 43036 Fidenza (PR) Italy  
Tel. +39 0524 527453 - Fax +39 0524 525230  
VAT. IT 01711860344 - R.E.A. PR 173685  
Company capital € 200.000,00

[www.omniaspa.eu](http://www.omniaspa.eu) - [oep@omniaspa.eu](mailto:oep@omniaspa.eu)

Dentaurum Implants

**Cleaning made easy: tioLogic® easyClean**

Dentaurum Implants GmbH and Miele Professional have worked together to develop an innovative system solution for efficient and reproducible machine-based preparation. The heart of this development is the tioLogic® easyClean surgery tray, which enables consistent and outstanding machine-based cleaning and disinfection results in both dental practices and in centralized preparation centres in hospitals. Not only do these improvements offer huge savings in time and costs, but reproducible machine preparation results also significantly increase reliability for their users.



The combination of the innovative grid structure with special retaining clips fixes all rotary instruments and accessory components to hold them in position and to ensure that the instruments are completely cleaned by water and a cleaning agent. All drills and accessory components can be replaced in the correct position in

the tioLogic® easyClean tray, as they are used in the implant procedure to remain in the correct order at all times throughout the operation.

SMP GmbH of Tübingen, an independent institute specializing, among others, in the testing and validation of medical devices, was commissioned to test and validate the cleaning results. The tests were an impressive confirmation of the preparation results of the instruments and accessory components in the tioLogic® easyClean.

**Dentaurum Implants GmbH**

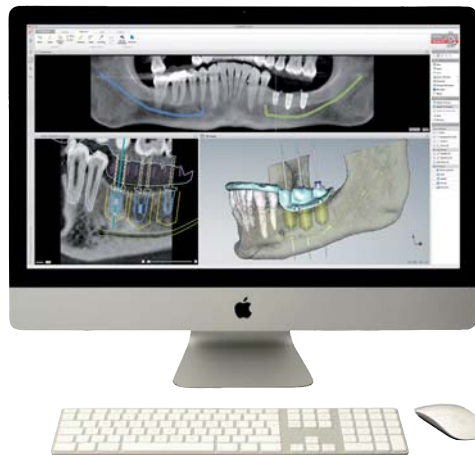Turnstraße 31  
75228 Ispringen, Germany

info@dentaurum-implants.de  
www.dentaurum.de

Nobel Biocare

**NobelClinician: Software now faster and easier to use**

The new update to NobelClinician makes the first advanced diagnostics and treatment planning software for Mac OS® X and Windows® even easier to use and faster to work with in your daily practice. Additionally, NobelClinician is now open to other major implant systems. The latest version of NobelClinician Software provides enhanced efficiency and safety with new visualization features. New features include a realistic 3-D visualization of the bone models with the artifact erasing function, visualization of the dental roots in 3-D, warning alerts if implants are placed too close to roots or nerves and the ability to quickly generate clinical reports.



The new update to NobelClinician also increases treatment flexibility by opening the software to other major implant systems. Users will now have the convenience of using one software to plan

treatments that involve implants from various providers. In addition to Nobel Biocare's assortment, Straumann® implant systems are also available with other major implant systems to come.

NobelClinician is the first advanced diagnostics and treatment planning software for both Mac OS® X and Windows®. It serves an increasing demand in the dental community as dental professionals frequently also use Apple devices in their dental practices.

**Nobel Biocare Deutschland GmbH**

Stolberger Straße 200  
50933 Köln, Germany

info.germany@nobelbiocare.com  
www.nobelbiocare.com

Implant Direct Sybron

**On the Winning Side with SwishPlus™**

„SwishPlus™ is compatible with Strauman Standard and Standard Plus implant systems” – this was the correct answer to Implant Direct Sybron’s quiz at the DGI’s annual congress in Dresden.



Like all implants by Implant Direct Sybron, SwishPlus™ comes with a self-tapping thread which helps simplify surgical procedures. Combined with the cone-shaped design of the implant's apex, the thread produces high primary stability. Its miniature threads in the upper part of the implant body allow

SwishPlus™ to support gingiva regeneration while reducing pressure on the crestal bone. SwishPlus™ can be placed both sub- and transgingivally. Mr Joachim Pappelau, sales manager at Implant Direct Sybron, is convinced that its compatibility with Strau-

mann Standard and Standard Plus implant systems makes SwishPlus™, “a smart choice, for we optimize existing implant concepts and make them available for a larger audience.”

Mr Pappelau continues by announcing the winner of the quiz, “Dr Nadine Hotz from Sigmaringen’s Klinik am Schloss is the lucky winner of our first prize, a brand-new Apple iPad2. Our congratulations!”

**Implant Direct Sybron**

Hardturmstrasse 161  
8005 Zürich, Switzerland

info@implantdirect.de  
www.implantdirect.de



Straumann

**Advanced implantology training for dental undergraduates**

Amsterdam's ACTA dental school, one of the leading international university centers for dentistry, and Straumann, a leader in implant and restorative dentistry and oral-tissue regeneration, are collaborating to enhance implantology training for dental undergraduates.

The shared goal of high-quality education in dentistry has brought ACTA and Straumann together. This collaboration has led to a novel dental education concept for oral implantology in the bachelor/master dental curriculum. From now on, ACTA's undergraduate program will include the teaching of all basic aspects of oral implantology, including prosthetics, diagnosis, compliance and treatment planning – subjects that are often covered only in postgraduate courses. The new curriculum has been made possible thanks to Straumann's commitment to supply materials for tooth-replacement solutions, planning software, as well as training for the key faculty staff at ACTA.

ACTA wanted to limit this program to one implant system, and the success of its previous collaborations made Straumann an obvious choice. The decision was also driven by the fact that it is considerably easier to train staff in surgical and prosthetic procedures using only a single implant system. Straumann offers a

comprehensive system for tooth replacement – from implant to crown – as well as state-of-the-art integrated digital solutions with seamless connectivity.

Professor Daniel Wismeijer, Chairman at ACTA's department of Oral Implantology and Prosthetic Dentistry, commented, "We have reserved 400 hours in an extra-training year to teach the students the basic principles of oral implantology. One of the main aspects of this additional training program is that all students must incorporate implantology into their treatment plans. This is a prerequisite to receive the dental degree. On a yearly basis, we expect to insert and restore 160 implants in the dental curriculum training."

Matthias Schupp, Head of Straumann's Western Europe region, noted: "We are pleased that Straumann has been selected as the system of choice in this project with ACTA. We see this as a long-term relationship that could shape dental education in the future. Working alongside dental faculties to support and advance training and education is important to Straumann, and we are exploring possibilities to introduce similar models to other universities as well".



**Straumann Holding AG**

Peter Merian-Weg 12  
4002 Basel, Switzerland.

info@straumann.com  
www.straumann.com

BioHorizons

**BioHorizons Symposium Series**

Please join us for the BioHorizons Symposium Series in Italy at the Rome Marriott Park Hotel from 18 to 20 October, 2012. This Symposium addresses a wide range of dental implant controversies including implant esthetics, implant complications and tissue regeneration. It is the perfect opportunity to stay current on the latest treatment options and remain aware of what techniques and products are supported by peer-reviewed research. This 2012



program has expanded to three days with a Biologics Forum on the afternoon of Thursday, October 18. Simultaneous interpretation will be available in Italian and Spanish. Enrollment will be limited to maintain an environment conducive to learning, so please register now to reserve your place at this outstanding educational event.

**BioHorizons GmbH**

Bismarckallee 9  
79098 Freiburg/Breisgau, Germany

info@biohorizons.com  
www.biohorizons.com

Bicon

**Universal Implant Design for Aesthetic Solutions**

Since 1985, the Bicon Dental Implant System has offered dentists approved solutions for missing dentition.

The Bicon implant design comprises plateaus, sloping shoulders and a bacterially-sealed, 1.5° locking taper implant-to-abutment connection. With the plateau design, cortical-like bone forms around and



between each plateau. This Haversian bone allows for the routine use of short implants of 5.0 mm. The sloping shoulder provides the necessary room for

the bone to support interdental papillae in favor of a natural gingival appearance. Bicon's universal abutment positioning of 360° facilitates the revolutionary cement- and screw-free Integrated Abutment Crown™, which consistently provides for an aesthetic, non-metallic gingival margin. Visit [www.bicon.com](http://www.bicon.com) for more information!

**Bicon Europe Ltd.**

Hauptstraße 1  
55491 Büchenbeuren, Germany

germany@bicon.com  
www.bicon.com

W&H

**W&H News App: Up-to-Date Information Directly to Your iPhone, iPod and iPad**

Experience W&H news and video in a completely new dimension, developed for all customers, partners and friends of W&H Dentalwerk. The new W&H News App is available free of charge for dentists, students and all those interested in dental matters. You have access to all news, reports, and studies, or you can explore dental videos of W&H. Staying informed has never been this easy and enjoyable.

Just a couple of taps of your finger and you can pick up current information on W&H and its products, 24 hours a day, seven days a week. Benefit from the wealth of experience of international experts and make use of topical reports and studies on W&H products as well as general dental issues. Experience interviews, application videos, instruction of instruments, company



presentation and many more. Contents are downloaded to your device in real-time via WLAN or 3G. Furthermore, this app is being constantly expanded to meet your needs and demands. You can even become a fan of W&H Dentalwerk on Facebook!

The app is available in German, English and Spanish. You will receive the version according to the language settings of your device automatically. The new W&H News App is available to download free of charge via App Store and Android Market. With its News App, W&H presents a platform which will support you both in your everyday work and in your dental life. Should you have any questions or remarks on the W&H news app, we would be pleased to receive your E-mail: e-marketing@wh.com.

**W&H Deutschland GmbH**  
 Raiffeisenstraße 4  
 83410 Laufen, Germany  
 office.de@wh.com  
 www.wh.com

Geistlich Pharma

**Membranes in Focus: 2<sup>nd</sup> International Meeting in Lucerne**

Membranes play a crucial role in allowing bones to regenerate predictably. At the 2<sup>nd</sup> International Expert Meeting held at the beginning of November 2011 in Lucerne, renowned experts agreed: the natural collagen membrane Geistlich Bio-Gide® impresses with its appropriate barrier function, good clinical handling and problem-free healing.

In the presentation block, the basic principles of bone regeneration were described in detail as well as the role of membranes in guided bone regeneration (GBR) and guided tissue regeneration (GTR). Prof Jan Lindhe (Sweden) demonstrated histologically that new bone is only formed in the region around blood vessels. Prof Daniel Buser (Switzer-



land) considers a few weeks to be realistic for the formation of temporary matrix in most cases. After this period the wound area has superficially healed and soft tissue integration of the membrane has begun. This in turn is attributable to the good tissue tolerance of Geistlich Bio-Gide®. Prof Jürgen Becker (Germany) explained that, preclinically, blood vessels are created within the porous membrane structure after just one week. According to Prof Becker, this could contribute to the augmentative success

of Geistlich Bio-Gide®, together with the soft tissue integration. Dr Jean-Louis Giovannoli (France) uses Geistlich Bio-Gide® membranes for peri-implantitis therapy, especially for three-wall defects. He considers the mechanical stabilisation of the augmentation material to be the most important function of the membrane.

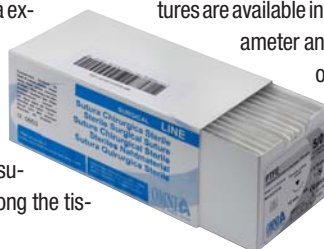Following intensive and partly controversial discussions, the experts in Lucerne agreed on the key requirements for GBR membranes. Besides a suitable barrier function and good clinical handling, uncomplicated behaviour in the event of dehiscence is desirable. Geistlich Bio-Gide® meets these conditions.

**Geistlich Pharma AG**  
 Bahnhofstrasse 4,  
 06110 Wolhusen, Switzerland  
 www.geistlich-pharma.com

Omnia

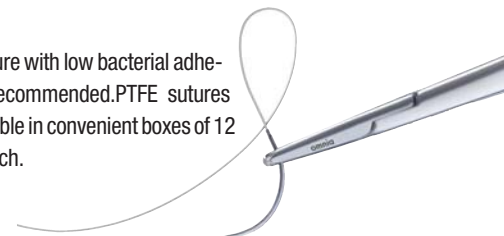
**Omnia introduces PTFE surgical sutures**

In addition to the traditional surgical sutures made of silk, polyester and absorbable PGA, Omnia expands its offer of surgical sutures by introducing the new generation of surgical sutures, PTFE sutures. Omnia PTFE sutures are soft, biologically inert and chemically non-reactive. Main features of PTFE sutures are a great fluency of the thread along the tis-



sues, strong knot holding, and stable quality in the long time. Compared to other monofilament synthetic sutures, this material is highly tolerated in the oral cavity. Further, PTFE sutures are ideal to limit inflammation, bleeding and other collateral effects which may occur during the soft tissue approximation. These sutures are available in different combinations of diameter and length with different kinds of needles. Omnia PTFE sutures are ideal for any implant, periodontal and bone graft surgery where the usage of a monofila-

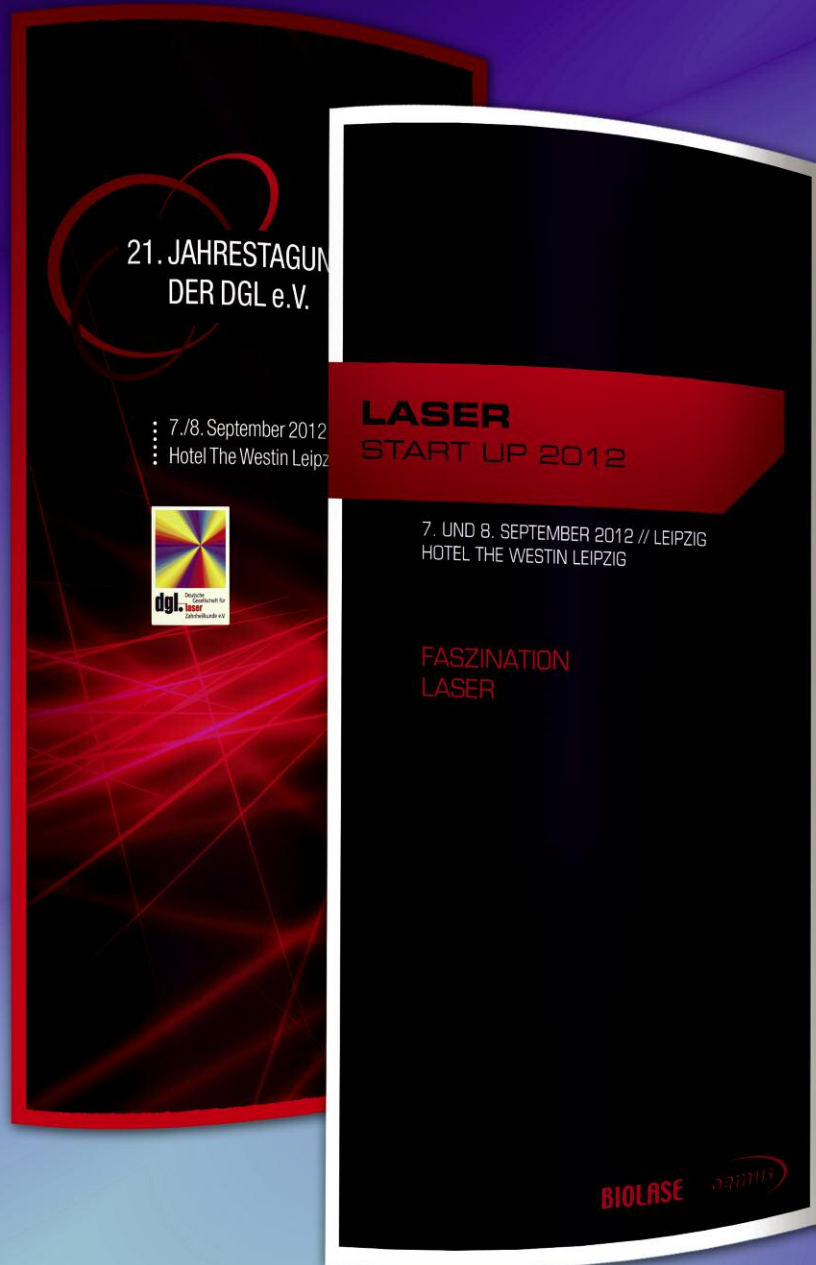ment suture with low bacterial adhesion is recommended. PTFE sutures are available in convenient boxes of 12 pieces each.



**Omnia SpA**  
 Via F. Delvevo, 190sx,  
 43036 Fidenza (PR), Italy  
 info@omniaspa.eu  
 www.omniaspa.eu

# » FASCINATION OF LASER DENTISTRY

## FOR EXPERTS AND BEGINNERS



SEPTEMBER 7-8, 2012//  
LEIPZIG//HOTEL THE WESTIN  
LEIPZIG, GERMANY

MAIN SPONSOR

**BIOLASE**

ORGANIZATION/  
REGISTRATION

OEMUS MEDIA AG  
Holbeinstraße 29  
04229 Leipzig, Germany  
Tel.: +49 341 48474-308  
Fax: +49 341 48474-390  
event@oemus-media.de  
www.dgl-jahrestagung.de  
www.startup-laser.de



## FURTHER INFORMATION

**PLEASE FAX THIS FORM**

+49 341 48474-390

Further information about:

LASER START UP 2012       21st ANNUAL CONGRESS OF THE DGL e.V

September 7-8, 2012, Leipzig, Germany

NAME/E-MAIL

OFFICE STAMP

implants 1/12



Silver nanoparticles could help

## Fight against oral infections

Yeasts that cause mouth infections can be killed using silver nanoparticles in the laboratory, scientists in Portugal have found. The researchers hope to test silver nanoparticles in mouthwash and dentures as a potential preventative measure against the infections, which are caused by *Candida albicans* and *Candida glabrata* and target the young, old and immunocompromised.

The study was conducted by Prof Mariana Henriques and her colleagues from the University of Minho in Largo do Paço, who investigated the anti-fungal properties of silver nanoparticles of different sizes to determine their effect against *C. albicans* and *C. glabrata*. These two yeasts cause various infections, including oral thrush and dental stomatitis, a painful infection that affects around seven out of ten denture wearers. Infections like these are particularly difficult to treat because the micro-organisms involved form biofilms.

The scientists used artificial biofilms in conditions that mimicked those of saliva as closely as possible. They then added different sizes and concentrations of silver nanoparticles and found that nanoparticles of different sizes were equally effective at killing the yeasts. Owing to the range of sizes of nanoparticles with anti-fungal properties, the researchers hope this will enable the nanoparticles to be used in many different applications.



Some researchers have expressed concerns regarding the safety of nanoparticle use but the Portuguese scientists stressed that this research is at an early stage and extensive safety trials will be carried out before any product reaches the market.

“With the emergence of candida infections, which are frequently resistant to the traditional anti-fungal therapies, there is an increasing need for alternative approaches. So, silver nanoparticles appear to be a new potential strategy to combat these infections,” Henriques said. “As the nanoparticles are relatively stable in a liquid medium they could be developed into a mouthwash solution in the near future.”

Moving forward, Henriques hopes to integrate silver nanoparticles into dentures, which could prevent infections from taking hold.

The study was published online in the Society for Applied Microbiology's Letters in Applied Microbiology journal.

Nobel Biocare appoints

## New Head of Global Operations

Nobel Biocare announced that Frank Mengis will be appointed Senior Vice President Global Operations and member of the Executive Committee, effective 1 July 2012. He will replace Ernst Zaengerle, who will be retiring. Frank Mengis has extensive senior



management experience in operations and manufacturing in the life sciences field including the dental industry. Most recently, he held senior management positions in Project Management and Development, Global Manufacturing, Operations and Quality Management at Straumann Institute. Prior to that, Frank Mengis was Head of Pharma Capital Investment Projects at Karl Steiner, Switzerland, after having held various management positions at F. Hoffmann-La Roche, Switzerland, in areas including galenic engineering and pharmaceutical manufacturing. Frank Mengis obtained a degree in Mechanical Engineering from the University of Karlsruhe, and completed the Advanced Management Program at Harvard Business School. Nobel Biocare would like to thank Ernst Zaengerle for his commitment and contribution to Nobel Biocare, and wishes him all the best for his future.

Increase until 2030

## German dental sector to grow considerably

While the dental sector in some countries may be facing hard times, German dental professionals and dental suppliers can look forward to the future. According to a recent study, about 76,000 jobs will be created in dental offices, dental laboratories and through dental retail sales until 2030. This represents an increase of 19 per cent compared with current figures. The study was conducted by the Institute of German Dentists (Institut der Deutschen Zahnärzte—IDZ) and WifOR Darmstadt, an independent economic research insti-

tute, upon the instruction of the National Association of Statutory Health Insurance Dentists (Kassenzahnärztliche Bundesvereinigung—KZBV) and the German Dental Association (Bundeszahnärztekammer—BZÄK). “The dental sector must not only be discussed as a cost factor. It's an economic factor and part of the health-care job machinery. Already, 400,000 people are working in the German dental sector,” said Dr Jürgen Fedderwitz, Chairman of the BZÄK Board. Prof Christoph Benz, Vice-President of BZÄK, commented:

“The job training rate in dental professions is traditionally high. Additionally, demographic developments will probably lead to a further employment stimulus.”

Both dental organisations pointed out that the positive forecast for the German dental sector depends on health policy representatives being willing to set stable conditions

References: KZBV/DTI

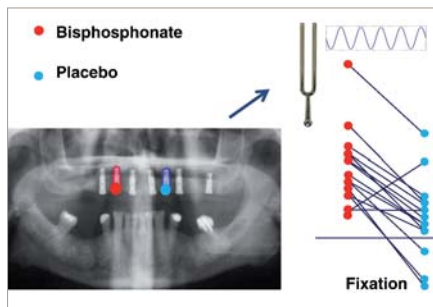
Study shows success

## New coating accelerates fixation of dental implants

Researchers from Linköping University in Sweden have successfully tested a new drug coating on humans that allows titanium implants to adhere to the bone better and more rapidly. The findings could benefit patients with difficulty chewing following dental treatment.

Millions of people have bad teeth replaced with dental implants, which are embedded into the jawbone and provide retention for artificial teeth. After the procedure, many patients are unable to chew food. Using the current technology, it may take four to six months before the bone surrounding the implant has healed and is strong enough for the patient to begin to benefit from surgery.

The new coating consists of a nanometre-thin layer of protein that adheres to the metal surface. At-



tached to the protein is a drug belonging to the class of bisphosphonates, usually used to treat osteoporosis.

Now, for the first time, this method has been tested on humans. The study involved 16 patients. Each of them received two implants—one ordinary im-


plant and a similar surface-treated implant as described above. Neither the patient nor the dental surgeon knew which was which. After six months, it was noted that for 15 of the 16 patients the surface-treated screw was markedly much better established. Already after two months, X-ray images showed positive changes in the tissue surrounding the surface-treated implants. According to the researchers, no complications occurred.

“It is the first time ever anyone has succeeded in reinforcing the bone around an implant with localised medication,” said study leader Per Aspenberg, Professor of Orthopaedics, who devised the method of using bisphosphonates in this way. The study was published online in the Bone journal.

Reference: DTI

Most efficient way explored

## Researchers investigate efficiency of bladed tooth shape



Using a combination of guillotine-based experiments and cutting-edge computer modelling, researchers at the University of Bristol have explored the most efficient ways for teeth to cut food. Their results demonstrate how precisely the shape of an animal's teeth is optimised to suit the type of food it eats. There is massive variety in tooth shapes in the natural world, from long, serrated teeth in Tyrannosaurus rex to triangular teeth in sharks and our own complex molars. Teeth can enable animals to crush, chop, grind or even cut food into pieces small enough to swallow. Such cutting instru-

ments, however, are not restricted to toothed animals. Bird beaks, insect mouth parts and even the roughened tongue of snails can also be used to break down food. Nevertheless, how teeth are able to cut and break down food has not been extensively examined. Now, two researchers at the University of Bristol's School of Earth Sciences have investigated this problem. In their study, research fellow Dr Philip Anderson and lecturer Dr Emily Rayfield used a unique double-bladed guillotine and measured the force needed by different tooth shapes to compress food materials. Finite-element analysis, a computational engineering technique, was then used to mimic these experiments and measure different variables, such as the total energy required. The researchers found that different shaped bladed teeth are optimised for different types of food.

“The actual hardness or toughness of the food item has a strong effect on what type of tooth shape is most efficient for cutting it,” Anderson said. “We looked specifically at V-shaped bladed edges,

which are similar to tooth shapes found in some sharks and the cheek teeth of many carnivorous mammals, and found that the angle of the V could be optimised for different foods.” According to Anderson, this sort of analysis is only possible with a computer model, which the researchers created to mimic the physical experiments. With the validated model, they were able to alter aspects of the tooth shape until they found a specific shape that used the least energy. “These results might seem rather obvious,” said Rayfield, “because we know tooth shape is adapted to diet. But we were surprised at the precision and predictability of the fit of tooth shape to dietary item.”

The researchers hope this new integrated methodology will create a new framework for exploring the evolutionary history of dental shape and how it relates to diet. Their study, “Virtual experiments, physical validation: Dental morphology at the intersection of experiment and theory”, was published ahead of print on 7 March in the Journal of the Royal Society Interface.

Reference: DTI

# implants

international magazine of oral implantology



#### Publisher

Torsten R. Oemus  
[oemus@oemus-media.de](mailto:oemus@oemus-media.de)

#### CEO

Ingolf Döbbecke  
[doebbecke@oemus-media.de](mailto:doebbecke@oemus-media.de)

#### Members of the Board

Jürgen Isbaner  
[isbaner@oemus-media.de](mailto:isbaner@oemus-media.de)

Lutz V. Hiller

[hiller@oemus-media.de](mailto:hiller@oemus-media.de)

#### Chief Editorial Manager

Dr Torsten Hartmann (V. i. S. d. P.)  
[hartmann@dentalnet.de](mailto:hartmann@dentalnet.de)

#### Editorial Council

Prof Dr Dr Frank Palm  
[frank.palm@klinikum-konstanz.de](mailto:frank.palm@klinikum-konstanz.de)

Dr Roland Hille  
[dr-hille@t-online.de](mailto:dr-hille@t-online.de)

Prof Dr Dr Kurt Vinzenz  
[kurt.vinzenz@aon.at](mailto:kurt.vinzenz@aon.at)

Dr Torsten Hartmann  
[hartmann@dentalnet.de](mailto:hartmann@dentalnet.de)

Dr Suheil Boutros  
[SMBoutros@aol.com](mailto:SMBoutros@aol.com)

#### Editorial Office

Georg Isbaner  
[g.isbaner@oemus-media.de](mailto:g.isbaner@oemus-media.de)

Claudia Jahn  
[c.jahn@oemus-media.de](mailto:c.jahn@oemus-media.de)

#### Executive Producer

Gernot Meyer  
[meyer@oemus-media.de](mailto:meyer@oemus-media.de)

#### Designer

Sarah Fuhrmann  
[s.fuhrmann@oemus-media.de](mailto:s.fuhrmann@oemus-media.de)

#### Customer Service

Marius Mezger  
[m.mezger@oemus-media.de](mailto:m.mezger@oemus-media.de)

#### Published by

OEMUS MEDIA AG  
Holbeinstraße 29  
04229 Leipzig, Germany  
Tel.: +49 341 48474-0  
Fax: +49 341 48474-290  
[kontakt@oemus-media.de](mailto:kontakt@oemus-media.de)

#### Printed by

Messedruck Leipzig GmbH  
An der Hebemärchte 6  
04316 Leipzig, Germany

#### implants

international magazine of oral implantology  
is published in cooperation with the German Association of Dental Implantology (DGZI).

#### DGZI President

Prof Dr Dr Frank Palm  
DGZI Central Office  
Feldstraße 80, 40479 Düsseldorf, Germany  
Tel.: +49 211 16970-77  
Fax: +49 211 16970-66  
[office@dgzi-info.de](mailto:office@dgzi-info.de)

[www.dgzi.de](http://www.dgzi.de)  
[www.oemus.com](http://www.oemus.com)

#### Copyright Regulations

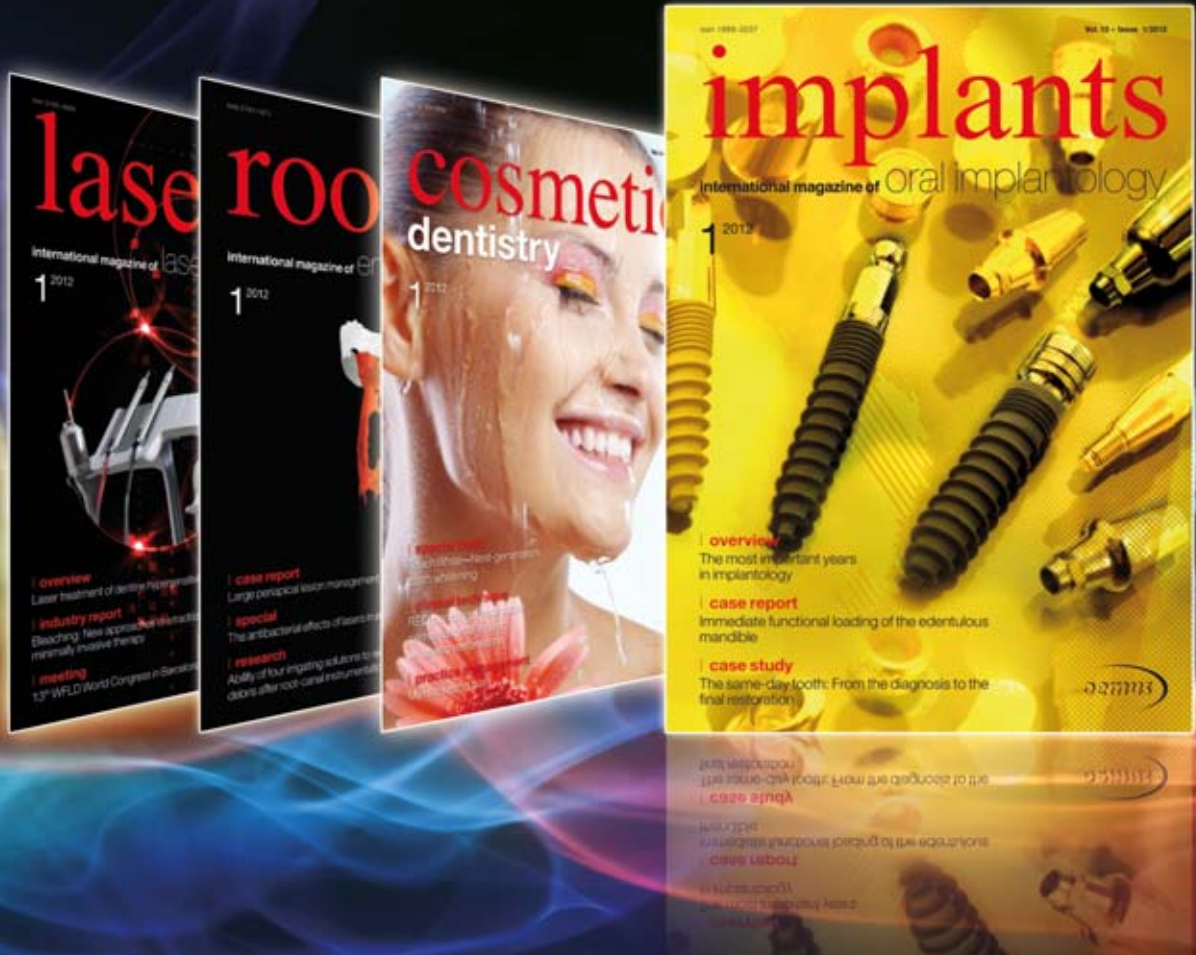\_implants international magazine of oral implantology is published by OEMUS MEDIA AG and will appear in 2012 with one issue every quarter. The magazine and all articles and illustrations therein are protected by copyright. Any utilization without the prior consent of editor and publisher is inadmissible and liable to prosecution. This applies in particular to duplicate copies, translations, microfilms, and storage and processing in electronic systems.

Reproductions, including extracts, may only be made with the permission of the publisher. Given no statement to the contrary, any submissions to the editorial department are understood to be in agreement with a full or partial publishing of said submission. The editorial department reserves the right to check all submitted articles for formal errors and factual authority, and to make amendments if necessary. No responsibility shall be taken for unsolicited books and manuscripts. Articles bearing symbols other than that of the editorial department, or which are distinguished by the name of the author, represent the opinion of the afore-mentioned, and do not have to comply with the views of OEMUS MEDIA AG. Responsibility for such articles shall be borne by the author. Responsibility for advertisements and other specially labeled items shall not be borne by the editorial department. Likewise, no responsibility shall be assumed for information published about associations, companies and commercial markets. All cases of consequential liability arising from inaccurate or faulty representation are excluded. General terms and conditions apply, legal venue is Leipzig, Germany.



# implants

international magazine of oral implantology



Subscribe now!

I would like to subscribe to **implants international magazine of oral implantology** (4 issues per year) for €44 including shipping and VAT for German customers, €46 including shipping and VAT for customers outside Germany, unless a written cancellation is sent within 14 days of the receipt of the trial subscription. The subscription will be renewed automatically every year until a written cancellation is sent to OEMUS MEDIA AG, Holbeinstr. 29, 04229 Leipzig, Germany, six weeks prior to the renewal date.

▶ Reply via Fax +49 341 48474-290 to OEMUS MEDIA AG or per E-mail to [grasse@oemus-media.de](mailto:grasse@oemus-media.de)

You can also subscribe via [www.oemus.com/abo](http://www.oemus.com/abo)

Last Name, First Name

Company

Street

ZIP/City/County

E-mail

Signature

Notice of revocation: I am able to revoke the subscription within 14 days after my order by sending a written cancellation to OEMUS MEDIA AG, Holbeinstr. 29, 04229 Leipzig, Germany.

Signature



# *tiologic*®

maximum  
safety

easy  
handling

perfect  
aesthetics

 **DENTAURUM**  
IMPLANTS