

# Restoration of **implant supported crowns**

## Uncommon problems and their solutions

Author\_Dr Igor Cernavin, Australia



[PICTURE: ©LEEDSN]

### Introduction

More than 40 years of experience have shown osseointegrated implants to be a highly predictable treatment modality, with unsuitable implant designs having been recognised and abandoned and risk factors for failure identified. Nevertheless, the author feels that in spite of having restored a significant number of implant-supported crowns, problems arise that are unexpected and not well recognised, often requiring considerable effort in arriving at a diagnosis and a solution. Below are a series of case reports presenting problems that the author has encountered over the years, among either his own patients or patients referred by general dental practitioners who

encountered such problems and were not able to solve them.

### Varying diameter of healing abutment and impression coping

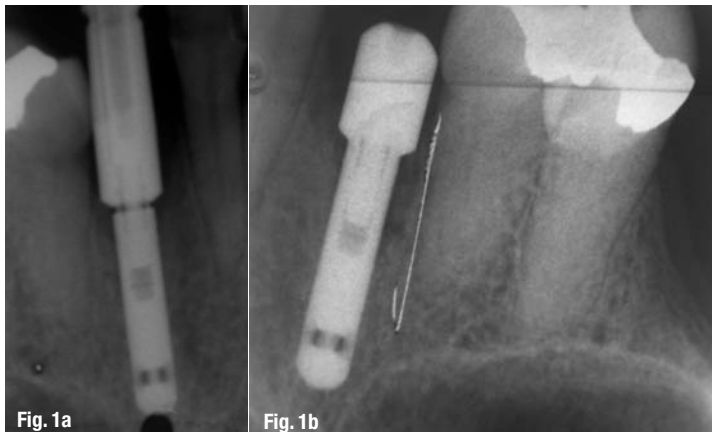
When this occurs and the impression coping is narrower than the healing abutment, there is no problem, but if the impression coping is wider than the healing abutment, bone may prevent the seating of the impression coping, and whilst clinically the impression coping may feel right, it is not and the subsequent crown/abutment will loosen (Fig. 1).

The author recommends that a radiograph always be taken to ensure that the impression coping is seated correctly. The radiograph should be taken using the bisecting technique, since if the beam does not pass through the joint between the impression coping and the implant, the coping may appear to be seated when in fact this may not be the case.

### Direct-to-fixture crowns

Direct-to-fixture crowns are a good way of restoring implants if the fixture is in an ideal position. However, in cases, especially in the molar region and for single units, in which the crown – fixture ratio is too great, the forces acting on the crown can lead to screw loosening. In such cases, it would be more prudent to use an

**Figs. 1a & b** Impression coping can impinge on bone.



abutment and then attach the crown to the abutment with a cross pin or in some other removable fashion. The abutment will alter the crown-root ratio significantly, thereby decreasing the forces on the abutment screw and decreasing the likelihood of the abutment screw loosening. Retrievability, using a cross pin or other method, will facilitate access to the abutment screw should it loosen.

Figure 2 shows such a case in which the crown-root ratio is too large for a direct-to-fixture crown. This case has the added problem of a regular-diameter implant with a wide-diameter crown, which would tend to increase the possibility of the screw loosening further. A wide-diameter implant would probably have been better here.

### Componentry mismatch?

The case presented in Figure 3 is very unusual. A radiograph was taken to verify seating of the impression coping and it was observed that the coping was seated halfway down the external hex and could be placed no farther (Fig. 3). It was clear from the radiograph that there was no bone or soft-tissue interference. Different impression copings were tried but the result was the same. The conclusion that the author finally reached

was that there must have been a mismatch between the diameter of the external hex on the fixture and the diameter of the impression coping. Once this concept was accepted, a laboratory impression coping was fabricated to allow for this and the coping seated correctly, with treatment proceeding uneventfully. The crowns have been in place for many years with no problems.

A mismatch in diameter between the external hex of the fixture and the diameter of the impression coping appears to be the only explanation for these cases. However, the author would be interested in other explanations.

### Implants and bisphosphonates

In the past, it was understood that there was a problem with the use of bisphosphonates and alveolar bone. A patient taking Fosamax was referred for implant replacement of the missing tooth #11. The fixture was placed by a periodontist, and after a suitable waiting period was restored by the author. All procedures were routine and uneventful, and the patient was pleased with the result. About one year after the crown had been placed, the patient rang, saying that the "implant had moved". This generally indicates that either the fixture has failed or the abutment or crown has loosened. The

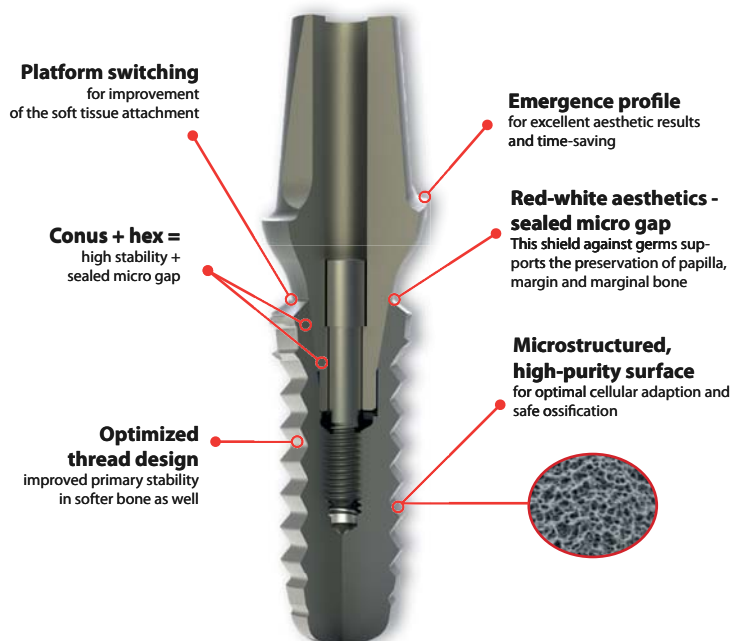
AD



**YOUR ADVANTAGE! THE 2 IN 1 CONCEPT:**  
Conical connection - with anti-rotation hex!

**DEALERS  
WANTED!**

### The new IMPLA hybrid connection



## Special Promotion for your start into the IMPLA system:

**30 implants, abutments, gingiva formers, lab analogs, transfers and surgical kit!**

Promotion Code: P121154

### Be ahead of your competition!

- » Wide range of trainings available for you and your team
- » Controlled German Quality
- » Great results + maximum security = satisfied customers

### Call us today and become a partner.

For additional information visit our website:  
[www.schuetz-dental.com](http://www.schuetz-dental.com)

Scan me.



Sign up for the exclusive IMPLA Newsletter:  
<http://sdent.eu/newe>



**IMPLA**

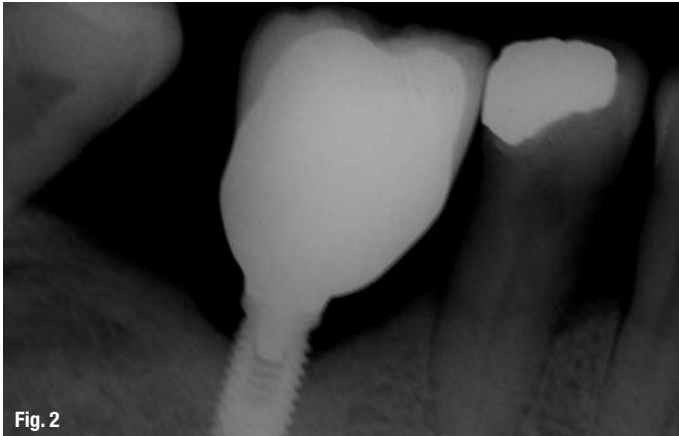


Fig. 2

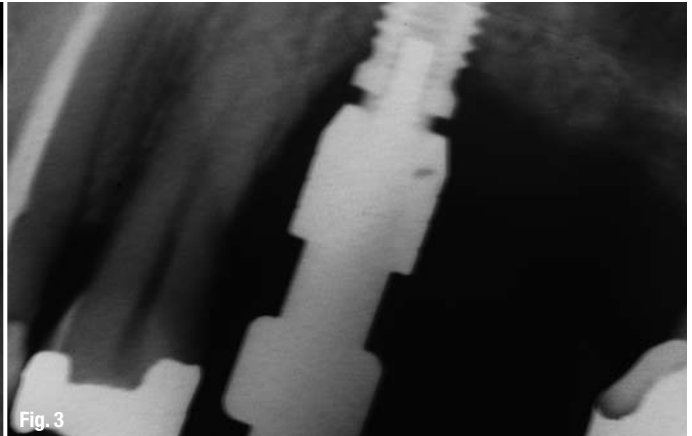


Fig. 3

**Fig. 2** Unfavourable crown root ratio for direct-to-fixture.

**Fig. 3** Mismatch in diameter between external hex of the fixture and the impression coping.

patient was examined and it was found that indeed the crown was now angled at approximately 30° labial to its original position (Fig. 4). Clinical and radiographic examination revealed that the fixture was sound, not tender to percussion and there was no probing depth. As the crown was retained with a cross pin, it was removed and it was found that the abutments screw was not loose. The crown was replaced and the patient agreed that she would leave things as they were to await further developments. The crown remained in place, symptom free, for a further six months, at which time the fixture exhibited clear clinical signs and symptoms of failure of integration, and was removed.

#### Fractured cross pins

Cross pins will rarely fracture, but when they do they usually fracture at the junction of the head and the body of the screw, thereby leaving the bulk of the screw holding the crown in place. Fortunately, the fracture mostly occurs after the cross pins have loosened and they can usually be unscrewed using a probe to catch the sharp edges, thereby removing the fractured portion of the screw and allowing removal of the crown and replacement of the screw with another. If the screw is not loose, carefully cutting the screw with a tungsten carbide bur, either cutting a slot and then unscrewing the screw or totally cutting the head of the screw until the crown can

be removed, is also possible but difficult to accomplish without damaging the crown.

#### Remarks

Implant-supported crowns and prostheses have been a tremendous boon to patients, allowing replacement of missing teeth without damaging adjacent teeth and placement of teeth in areas of the mouth where this would not otherwise have been possible; however, unusual and challenging situations are encountered that require considerable thought to obtain a solution.

**Fig. 4** Shifted implant retained crown.

**Fig. 5** Models comparing the original position of the fixture and the position of the implant retained crown after it had "shifted".

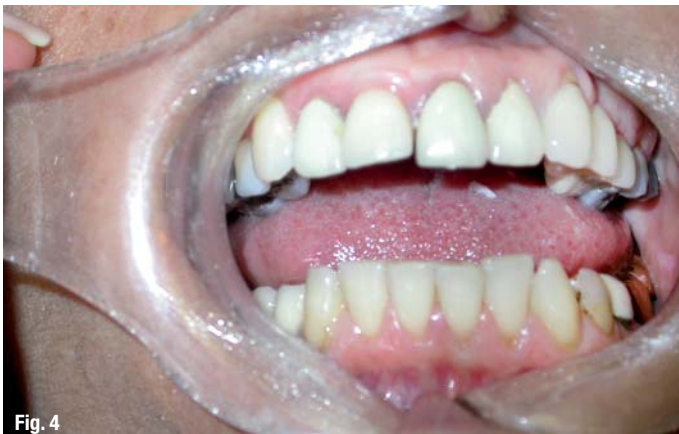

Fig. 4

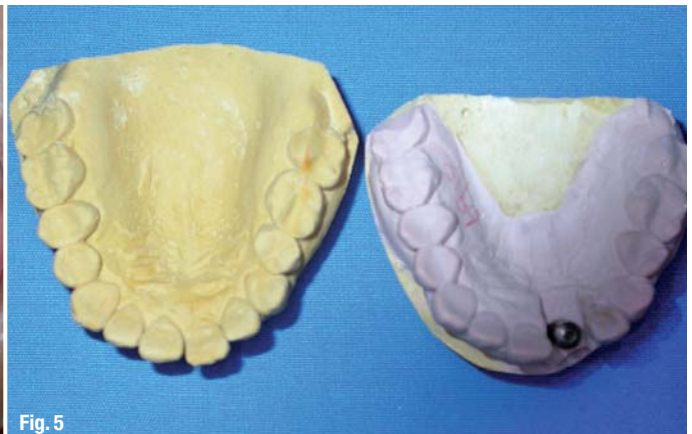


Fig. 5

<u>contact</u>	<b>implants</b>
<p><b>Dr Igor Cernavin</b>                  Prosthodontist, Honorary Senior Fellow                  Department of Restorative Dentistry, School of                  Dentistry, Faculty of Medicine, Dentistry and Health                  Sciences, University of Melbourne, Melbourne,                  Australia. Director of the Asia Pacific Institute of                  Dental Education and Research Pty Ltd.                  803 Malvern Road                  TOORAK, 3142, VIC, Australia</p> <p>Cernavin@unimelb.edu.au                  www.cernavin.com</p>	

# Celebrate the innovation of osseointegration with us.

Visit us at the Nobel Biocare Symposia 2012

March 21–23, Gothenburg

June 1–2, Avignon

June 9–11, Odessa

June 15–16, Hamburg

October 19–20, Rimini

October 19–20, Toronto

**SIGN UP NOW**

For more information and registration visit our website  
[nobelbiocare.com/symposia2012](http://nobelbiocare.com/symposia2012)

## **60 years since the discovery of osseointegration 30 years since the landmark conference in Toronto**

In 1952, Per-Ingvar Brånemark discovered the principles of osseointegration in Sweden. Thirty years later, in 1982, the discovery was acknowledged, and his subsequent findings confirmed at a landmark conference in Toronto. Yet another thirty years have passed, and Nobel Biocare will celebrate both these 60- and 30-year anniversaries in Sweden and Canada, as well as in France, Ukraine, Germany and Italy. Beginning in the hometown of osseointegration—Brånemark's Gothenburg—Nobel Biocare will gather some of the best-known names in the field to highlight how far Per-Ingvar Brånemark, together with Nobel Biocare and their supporters have brought the innovation of osseointegration. Scientific

and clinical experts from all over the world will exchange ideas and discuss promising areas for further exploration. The programs of all six Nobel Biocare Symposia 2012 will celebrate the origins and evolution of osseointegration as a practical and trusted treatment modality over the last six decades. Each program will also include lectures on recent advances in treatment, presented from surgical, prosthetic and laboratory perspectives. Speakers will look towards the future as well, presenting current trends and possible future developments for bone-anchored restorative dentistry.

**Join us and become a part of the next innovative chapter of osseointegration history.**

[nobelbiocare.com](http://nobelbiocare.com)

