

# Screwed versus cemented immediately functionally loaded implants

## A five-year prospective analysis

**Author** Dr Luca Di Alberti<sup>1</sup>, Prof Dario Bertossi<sup>2</sup>, Prof Lorenzo Lo Muzio<sup>1</sup> & Prof Pierfrancesco Nocini<sup>2</sup>, Italy

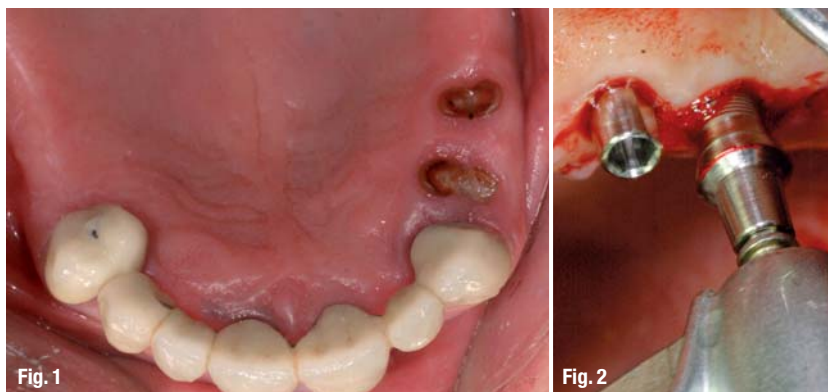


Fig. 1

Fig. 2

**Fig. 1** Case before treatment.

**Fig. 2** Implant insertion: SEVEN and Mistral implants are inserted flaplessly.

### \_Introduction

Immediate loading of oral implants has been defined as a situation in which the superstructure is attached to the implants no later than 72 hours after surgery (Aparicio et al. 2003; Cochran et al. 2004). The definition of immediate loading also includes occlusion with the teeth of the opposite jaw. Under these conditions, successful immediate loading of screw-type dental implants was reported as early as 1979 (Ledermann 1979).

The proposed exclusion criteria include insufficient bone volume, severe maxillo-mandibular skeletal discrepancy, drug and alcohol abuse, heavy smoking, local radiotherapy of the head and neck region for malignancies, uncontrolled diabetes, stroke, recent infarction, pregnancy at the time of evaluation, bleeding disorders or coumarin therapy, metabolic disorders, and general contra-indications for surgical procedures (Chiapasco et al. 2001; Chow et al. 2001; Hui et al. 2001; Proussaefs et al. 2002; Jaffin et al. 2004; Proussaefs & Lozada 2004; Ibanez et al. 2005).

The question of reducing the micro-movement has not yet been addressed in controlled studies dealing with the immediate loading of oral implants. Passive fit of provisional prostheses has been mentioned as an important factor in the osseointegration of immediately loaded implants. A prosthesis that is ill fitting may become loose, resulting in increased stress on the implants, which can lead to excessive micromotion and the loss of an implant (Jaffin et al. 2004). In this context, it has been hypothesised that screw-retained, passively fitting restorations may be superior to cement-retained ones with respect to this problem because they are less likely to become loose. If a cemented restoration is desired, the abutments should be long enough to provide adequate retention (Jaffin et al. 2004).

The ultimate goal of an immediate loading protocol is to reduce the number of surgical interventions and shorten the period between surgery and prosthetic delivery, without sacrificing implant success rates.

### \_Material and methods

The study was performed in two clinical centres by two investigators who followed the same clinical protocol for immediate occlusal loading of implants placed in the edentulous mandible or maxilla.

Thirty patients were enrolled in the study. Of these patients, ten maxillas and ten mandibles were treated with six implants and five implants, respectively, for a total of 110 implants as the test group for screwed implants, and ten patients (five maxillas and five mandibles) were the control group for cemented implants, with a total of 55 implants inserted. All of the patients were edentulous in the maxilla and/or

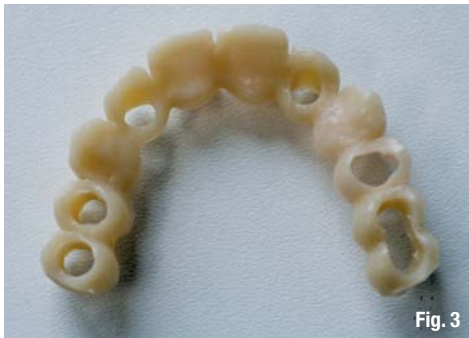

Fig. 3

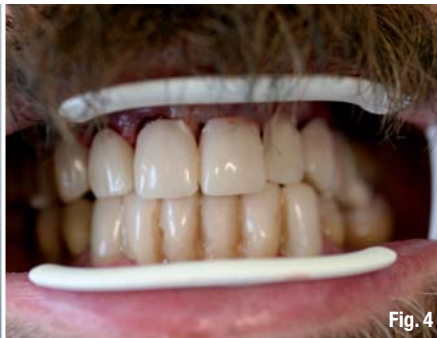

Fig. 4

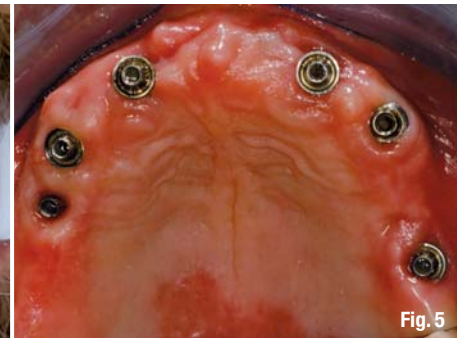

Fig. 5

mandible at the time of the surgery (Fig. 1). All of the patients were treated with SLA screw-shaped SEVEN and/or Mistral implants (MIS; Fig. 2). In addition, a provisional screwed embedded resin prosthetic appliance (Fig. 3) was fixed at the time of surgery for the test group and a provisional embedded resin prosthetic appliance (Fig. 4) was cemented at the time of surgery for the control group.

All clinicians followed the implant manufacturer's instructions for the implant site preparation and insertion procedure. The initial primary stability was assessed by setting the insertion torque of the surgical unit, and recorded according to the following modified classification: "tight" when torque was greater than 45 Ncm, "firm" between 30 and 44 Ncm, or "loose" when less than 30 Ncm (adapted from Testori et al. 2002). The length and the diameter of the individual implants can vary from subject to subject, depending upon bone quality and quantity at each surgical site. The treatment objective involved delivery of the provisional prosthesis within four hours of implant placement, by utilising the prosthetic procedure that best suited the clinical case. A reinforced acrylic provisional bridge was relined over provisional titanium multi-unit cylinders and immediately screwed onto the abutments for the test group. A provisional reinforced acrylic denture was then cemented over titanium abutments for the control group. The occlusion was carefully checked.

No specific diet was recommended to the patients. The patients were on a strict recall programme during the first six months: every week during the first month, and every two weeks between the second and third months, and every month until the sixth month. Orthopantomograms and periapical radiographs were obtained for image analysis at implant insertion. Periapical radiographs were also performed subsequently, after three, six, 12, 24, 48 and 60 months of occlusal loading (Figs. 5 & 6).

Peri-implant marginal bone change was evaluated utilising a computerised measuring technique applied to intra-oral periapical radiographs (RVG, Kodak). The evaluation of the marginal bone level around implants

was carried out using image analysis software (RVG). The bone loss at each follow-up visit was calculated for each implant by determining the difference between the baseline values.

## Results

Thirty patients were enrolled in the study. Of these, ten maxillas and ten mandibles were treated with six implants (Figs. 7 & 8) and five implants, respectively, in the test group (110 implants), and five maxillas and five mandibles in the control group (55 implants). Four implants were lost out of the 165 inserted. One implant belonged to the test group and three to the control group. The implants showed extensive marginal bone resorption and signs of peri-implantitis. The patients had a history of bruxism, smoking and/or poor oral hygiene and periodontitis. No patients enrolled in the study dropped out during the study period and all patients showed great satisfaction with the effectiveness of the treatment.

The RFA registrations showed higher values for mesial-distal measurements than for the buccal-palatal ones: 65.3 ISQ (SD 6) versus 55.8 ISQ (SD 6.9) for all implants. The marginal bone level was situated more coronally for the test implants at all stages of the trial. After six months, the marginal bone level was on average 0.9 mm (SD 1.1) below the implant shoulder for the test implants and 2.7 mm (SD 1.2) for the control implants. On average, 0.3 mm (SD 1) of bone loss was observed for the test implants and 0.8 mm (SD 1.2) for the control implants during the first 12 months ( $p = 0.05$ ). A similar proportion of patients showed one or more implants with bone loss. More patients and implants in the control group showed 2 to 3 mm of bone loss during these 12 months. These results were confirmed at subsequent controls at 48 and 60 months after implantation.

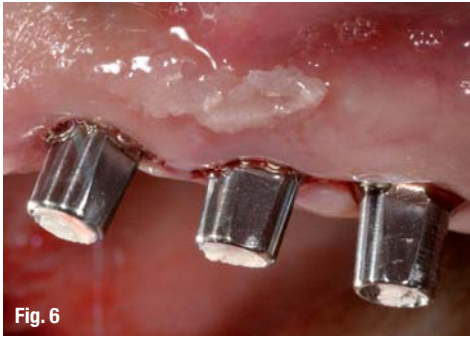## Technical complications

Resin-related technical complications occurred more often in control than in test patients. Six test bridges showed a loosening of the assembly screws of the abutments at the three-month check-up.

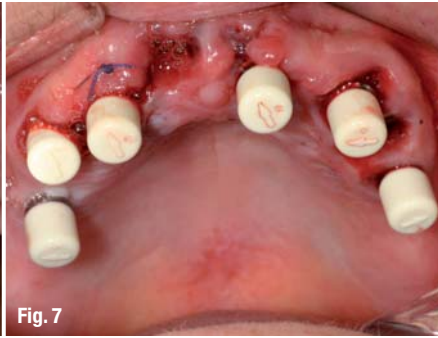**Fig. 3** Provisional bridge before final prosthetic steps.

**Fig. 4** Cemented provisional bridge in position at the time of surgery.

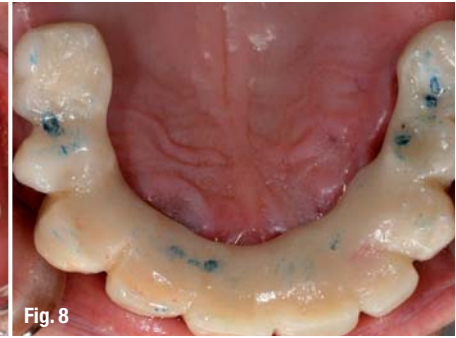**Fig. 5** Clinical appearance after three months of occlusal loading.



**Fig. 6** Three of the six implants after three months of occlusal loading with a cemented provisional bridge.



**Fig. 7** Six implants inserted in the maxilla and ready for cemented bridge.



**Fig. 8** Cemented bridge with occlusal loading at time of surgery.

## Discussion

Early loading has been made possible by using textured surfaces that promote osseointegration (Buser et al. 1991; Cochran et al. 1998; Trisi et al. 1999; Testori et al. 2002). However, immediate occlusal loading procedures can be successful only when the amount of micromotion at the bone–implant interface is kept below a certain threshold during the healing phase (Szmukler-Moncler et al. 1998). It is widely accepted that immediate loading is a desirable procedure if the outcome in terms of implant survival and success is comparable to that of conventional loading. Therefore, it has been the aim of the present study to demonstrate the different clinical outcomes and indications for cemented versus screwed immediately loaded prosthetic appliances, to assess the level of evidence and to discuss implant survival rates and the success rates of these two different protocols.

Varying experiences in the immediate occlusal loading of oral implants has led to different consensus papers (Aparicio et al. 2003; Cochran et al. 2004; Misch et al. 2004). In many of the studies on immediate loading, good bone quality is mentioned as an important prognostic factor for the success of the procedure (Chiapasco et al. 2001; Romeo et al. 2002). Although this conclusion appears reasonable, the level of evidence supporting the assumption is low. The same holds true for the implant lengths and diameters that should be used for immediate loading. In a controlled study, rough implant surfaces improved the survival rate of immediately loaded implants (Rocci et al. 2003); however, the influence of the rough as opposed to machined surfaces was not significant.

Several authors have addressed their interest on the biomechanical aspects of the occlusion in the immediate loading protocol (Szmukler-Moncler et al. 2000; Gapski et al. 2003; Chiapasco et al. 2004). It is commonly accepted, since the study of Cameron in 1971, that a micro motion limit of 150 microns should not be exceeded (Maniatopoulos et al. 1986; Pilliar et al. 1986; Szmukler-Moncler et al. 1998). It has been shown that this limit could be controlled using tex-

ured surface and immediate stability of the implants (Chaushu et al. 2001; Calandriello et al. 2003). The protocol of immediate loading linking the immediate stability with a metal reinforced provisional prosthesis screwed on multiunit abutments was successful and has been in previous reports (Nikellis et al. 2004; Van Steenberghe et al. 2004).

## Conclusion

All study patients received provisional prosthesis within four hours of surgery, and their final rehabilitation was completed six months later. The fact that patients could wear a fixed prosthesis since the first day of surgery has enhanced the compliance of the patients for the treatment period.

The marginal bone defects around immediately loaded implants were similar to delayed loading protocols (Albrektsson et al. 1986). However, several clinical studies on immediately loaded implants have clearly confirmed that the first six months of occlusal function are crucial (Babbush et al. 1986; Schnitman et al. 1990; Balshi & Wolfinger 1997; Schnitman et al. 1997; Ericsson et al. 2000; Jaffin et al. 2000; Szmukler-Moncler et al. 2000; Chaushu et al. 2001). We can conclude that immediate loading protocol using multi-unit abutments is a reliable technique.

### \_contact

### implants

#### Dr Luca Di Alberti

Department of Dental Sciences  
University of Foggia  
Via Colonneta 22-A  
66013 Chieti  
Italy

dialbertiluca@yahoo.it

<sup>1</sup> Department of Dental Sciences,  
University of Foggia, Italy

<sup>2</sup> Department of Oral and Maxillofacial Surgery,  
University of Verona, Italy

# FASCINATION OF LASER DENTISTRY

## FOR EXPERTS AND BEGINNERS

SEPTEMBER 7-8, 2012  
LEIPZIG  
HOTEL THE WESTIN  
LEIPZIG, GERMANY

16  
FORTBILDUNGSPUNKTE  
LEHRBILDUNGSPUNKTE

LASER  
START UP

7. UND 8. SEPTEMBER  
HOTEL THE WESTIN LEIPZIG

FASCINATION OF  
LASER DENTISTRY

21. JAHRESTAGUNG DER DGL e.V.

LASER START UP 2012



- 7./8. September 2012
- Hotel THE WESTIN LEIPZIG

HAUPTSPONSOR  
**BIOLASE**



### ORGANIZATION/ REGISTRATION

Deutsche Gesellschaft für Laserzahnheilkunde e.V.  
(German Society for Laserdentistry)

Klinik für Zahnerhaltung, Parodontologie und Präventive  
Zahnheilkunde Universitätsklinikum der RWTH Aachen,  
Pauwelsstraße 30, 52074 Aachen

Fon: +49 241 8088-164

Fax: +49 241 803388-164

sekretariat@dgl-online.de

www.dgl-online.de

### OEMUS MEDIA AG

Holbeinstraße 29

04229 Leipzig

Fon: +49 341 48474-308

Fax: +49 341 48474-390

event@oemus-media.de

www.oemus.com

www.dgl-jahrestagung.de

www.startup-laser.de

### MAIN SPONSOR

**BIOLASE**

### FURTHER INFORMATION



#### PLEASE FAX THIS FORM

+49 341 48474-390

Further information about:

- LASER START UP 2012       21st ANNUAL CONGRESS OF THE DGL e.V.

September 7-8, 2012, Leipzig, Germany

NAME/E-MAIL

OFFICE STAMP

implants 2/12