

The implant-retained bar overdenture: The SFI-Bar

Author_Dr Tussavir Tambra, United Kingdom




Fig. 2a

Fig. 1

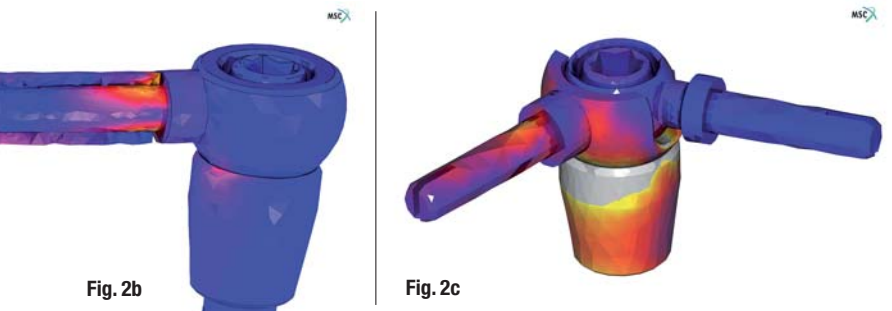


Fig. 2b

Fig. 2c

ous angulations (All-on-4, Nobel Biocare; Columbus Bridge, BIOMET 3i), has resulted in a significant uptake of treatment by edentulous patients and those with a failing dentition. This is mainly because a fixed bridge is provided and treatment times are reduced from months to hours, avoiding a conventional denture.

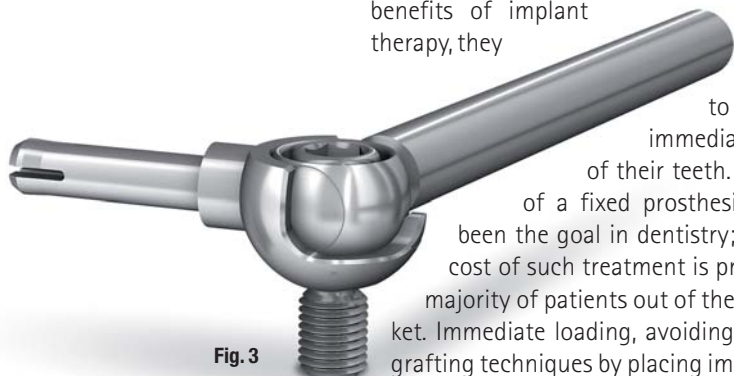
Most edentulous patients can tolerate a complete maxillary denture with few problems. The vast majority of problems arise in the mandible, where the underlying supporting tissues are not designed to function under this type of occlusal loading. Even a properly constructed complete lower denture can move as much as 10 mm in function. This continuous movement of the prosthesis results in loss of the supporting bone (or remodelling), further destabilising the denture. Poor ridge form increases denture instability and this produces more remodelling. Edentulism fulfils the WHO definition of a physical impairment.

Introduction

The advent of CAD/CAM technology and the more widespread utilisation of implants in modern dentistry have led to an explosion of treatment solutions designed to address any situation encountered by the general dentist. As patients have become more aware of the benefits of implant therapy, they

have begun to demand more immediate restoration of their teeth. The provision of a fixed prosthesis has always been the goal in dentistry; however, the cost of such treatment is pricing the vast majority of patients out of the implant market. Immediate loading, avoiding conventional grafting techniques by placing implants at vari-

Fig. 3



Treatment protocol

A simple treatment protocol was devised to treat this problem. According to this protocol, two dental implants are placed in the inter-foraminal area of the mandible, to which either a bar or stud attachments are connected to retain the lower



Fig. 4a

denture. This treatment greatly improves both masticatory efficiency and function in patients. Over the last two decades, attempts have been made to render the implant-retained overdenture the standard treatment for edentulism,¹ as demonstrated most recently by the McGill consensus.²

Prosthetic failure, usually loss of retention, and the technical difficulties encountered when relining or changing stud attachments proved to be major negative factors in dentists' attitudes towards this treatment modality. Several attempts were made to redesign and improve the attachments; however, owing to previous negative experiences, most dentists became reluctant to adopt implant-retained overdentures as a routine treatment option. The push to place more implants in an attempt to improve the situation led to the bar- and clip-retained overdenture scenario. This technique was more successful but still encountered similar issues to the stud-attachment overdentures.³

Poor stress transmission from the prosthesis to the supporting implants results in bone loss around the implants (especially the most distal implants in the multiple bar scenario), in addition to prosthetic and surgical complications.⁴ This resulted in implant companies and clinicians moving away from the two implant-retained overdenture treatment option in favour of fixed solutions, such as round-house bridges fixed on four or more implants. As a result, the vast majority of patients cannot access implant therapy owing to financial constraints. The McGill consensus brought the implant-retained overdenture back into the spotlight as a way of increasing access to implant dentistry and improving patients' quality of life. Improved component manufacturing techniques, and greater care and attention to both surgical and restorative treatment planning have significantly improved treatment outcomes using overdentures.⁵

Recently Cendres+Métaux introduced the Stress Free Implant Bar, or SFI-Bar, to the dental community. This unique, implant-platform-independent restorative bar overdenture solution allows the fabrication of a true passive-fit bar and clip system on two or more implants (Fig. 1). Finite element studies and clinical evaluation of the system have found minimal stress transmission from the prosthesis to the implants under loading (Figs. 2a-c), with most stresses being evenly distributed between the supporting implants. Vertical loads are transmitted effectively to the supporting implants, while undesirable lateral stresses are largely eliminated. More recent clinical studies have also shown it to be a viable immediate-loading treatment solution. The technique is in its infancy, so long-term (five years or more) data is not available. The SFI-Bar is a modular system that connects multiple dental implants with no soldered or laser-welded joints.

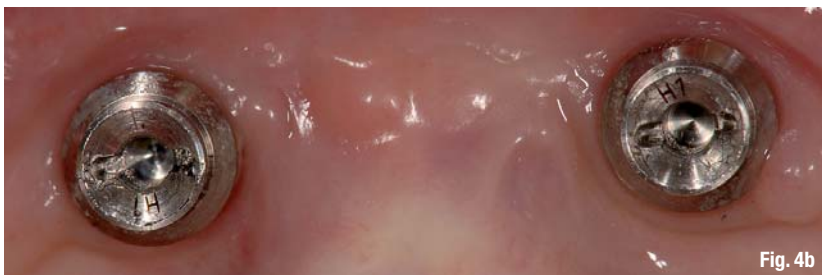

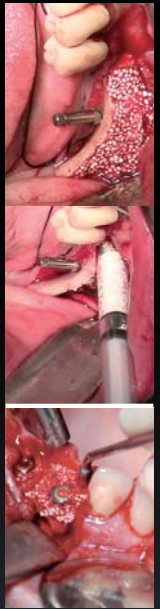Fig. 4b



Fig. 5

sticky granules

bionic



AD
easy-graft® CRYSTAL




easy-graft®
CRYSTAL

Ingenious: Simple handling and accelerated osteoconduction for long-term volume preservation.

SUNSTAR
GUIDOR®

Degradable Solutions AG
A Company of the Sunstar Group
Wagistrasse 23
CH-8952 Schlieren / Zurich
www.easy-graft.com

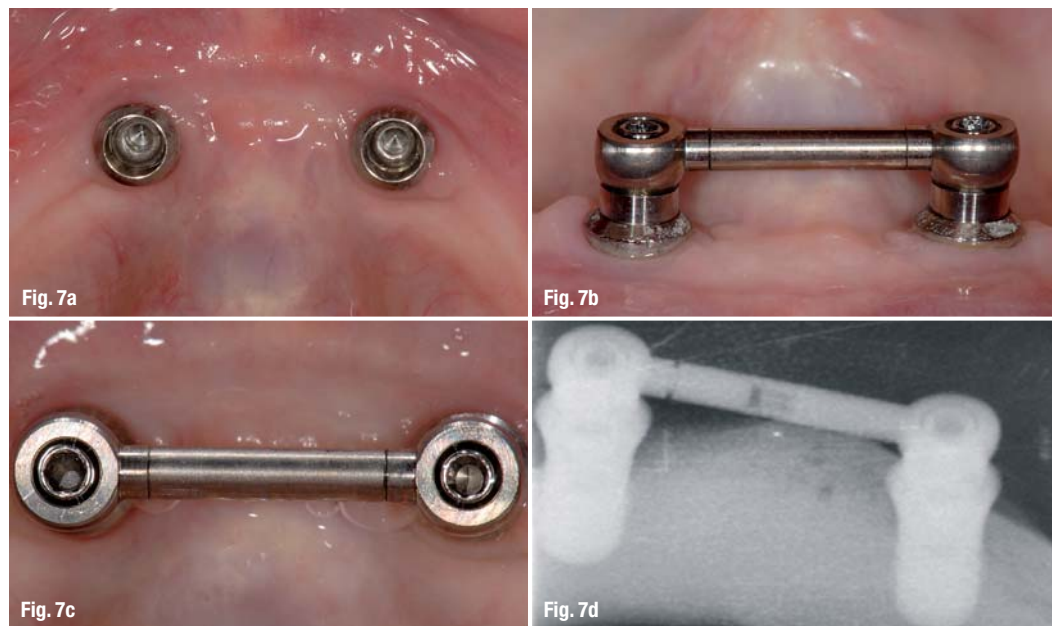


joint connection, ensuring a perfect section each time. The jig slides along the tube bar until it reaches the implant adapter, accurately sizing the bar. The tube bar is then locked in place and cut to size with a cutting disc (Fig. 6c). This process can be carried out either chair side (two-implant bar) or in the laboratory (four-implant bar or larger). An implant-level master cast will be required for cutting in the laboratory. The cutting of the tube bar must always be carried out extra-orally.

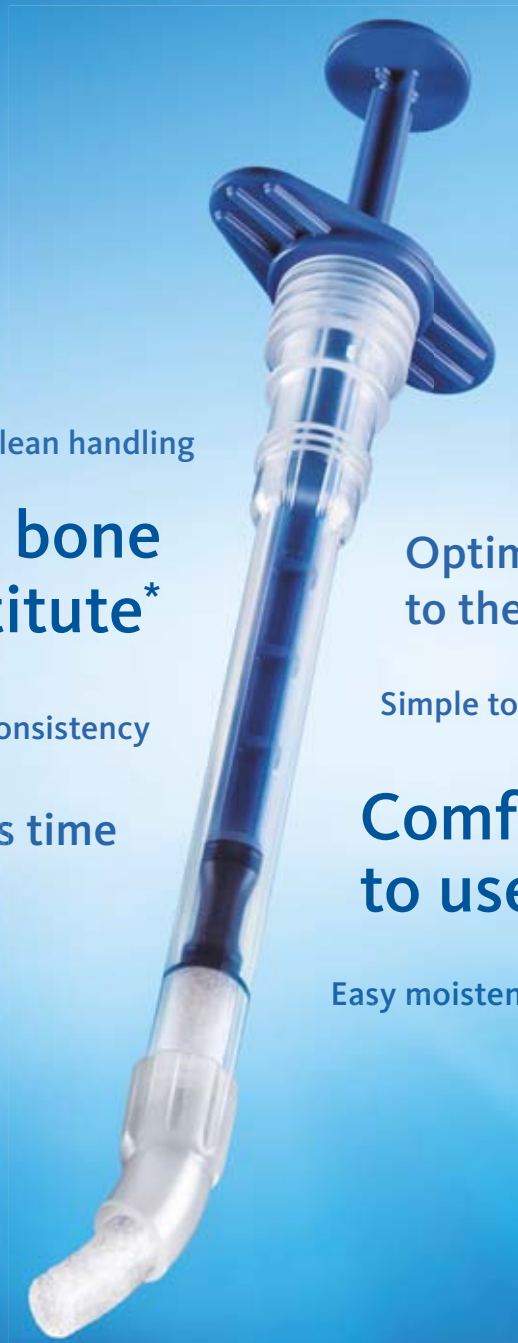Once the tube bar has been cut, the ball joints are inserted into each end of the tube bar prior to seating on the implant adapters (Figs. 7a–d) and torqued into place. The SFI-Bar is now complete and the patient is ready for the retentive element to be housed in the denture. The ball joints can accommodate non-parallel implant placement up to a maximum of 15° angulation correction. The absence of any soldered or welded joints means that a greater length of the bar can be engaged by the retentive clip. In conventional techniques, the presence of a weld increases the bar thickness, at that point preventing any retentive clip engaging that area. In the SFI-Bar, the clip engages the full length of the bar between the ball joints (Fig. 8). The bar assembly must be parallel with the occlusal plane; therefore, a selection of implant adapters of varying lengths should be available.

The minimum inter-implant distance is 8 mm and the maximum is 26 mm. This is an expandable bar system, in which add-on kits (Fig. 3) can be used to incorporate multiple implants to create a round-house bar. Implant adapter abutments are first torqued onto the implants (Figs. 4a & b). They form one half of a universal ball joint—the other half being incorporated into the bar element. The bar itself is formed by a hollow tube bar that fits onto the end of each ball joint (Fig. 5). This tube bar is cut to the correct length using a specialised jig and cutting disc (Figs. 6a–c). The jig is designed to mimic a ball

Most of the major implant companies offer CAD/CAM-fabricated bar and clip solutions. However, these bars are relatively expensive and are fabricated through a conventional impression and master cast technique. Studies have shown that 50% of all errors during impression making and cast fabrication result in non-passive fit of bars and



Nothing changed.
Just improved.



Clean handling

No. 1 bone substitute*

Optimal access to the defect

Very good consistency

Simple to use

Saves time

Comfortable to use

Easy moistening

New!

- ✓ Unwrap
- ✓ Moisten
- ✓ Use

* iData Research Inc., US Dental Bone Graft Substitutes and other Biomaterials Market, 2011.

iData Research Inc., European Dental Bone Graft Substitutes and other Biomaterials Market, 2010.

Please check for availability of this product with your country representative: www.geistlich-pharma.com

For more information visit:
www.bio-oss.com




Fig. 8

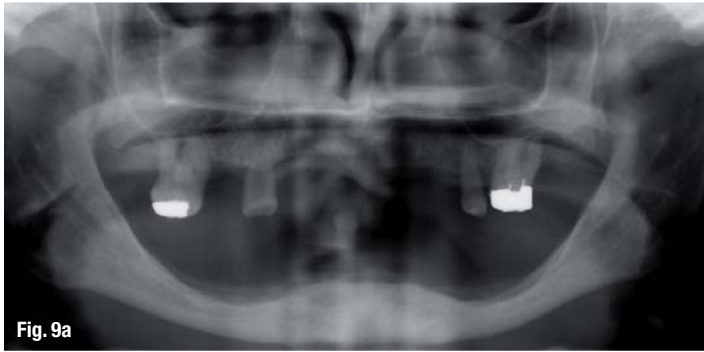


Fig. 9a

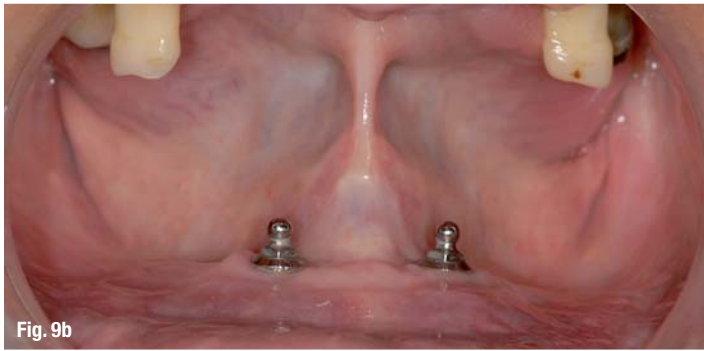

Fig. 9b

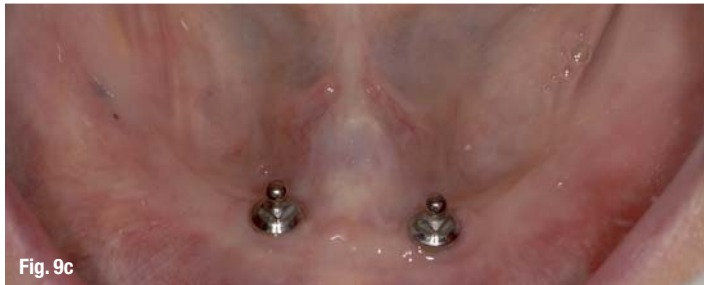

Fig. 9c




Fig. 10

frameworks. Thus, any bar fabricated through an impression or cast technique cannot be truly passive.⁶⁻⁸ A clinical case will be presented below in order to demonstrate the direct chair-side method and the use of the SFI-Bar on two implants to restore an edentulous mandible. In addition, the main points for use with the indirect method will be outlined.

Case presentation

In 2006, a 60-year-old female patient initially presented, complaining of an ill-fitting lower denture. The patient had worn a conventional complete mandibular denture for over 20 years, opposing a metal-based maxillary removable partial denture. The patient had visited a denturist on several occasions to try to improve the situation. After multiple relining procedures, the patient decided to seek expert help. An OPG radiograph revealed a severely resorbed mandible that clinically presented as a classic bowl-shaped deficiency (Figs. 9a–c). Radiographic examination revealed there was adequate bone volume in the anterior region for the placement of dental implants. However, a fixed solution would only have provided a shortened dental arch, as the mental foramen had become more mesial owing to bone resorption. Placing implants distal to the mental foramen was not an option, owing to the proximity of the inferior dental nerve and lack of bone height. The patient was not keen to have any nerve repositioning or complex bone grafting. Another important factor negating the fixed solution was the size of the volume defect. This would have been difficult both to correct and to maintain and would have produced a poor aesthetic result. The additional bulk of denture flanges allowed proper facial support.

After discussing all the relevant issues, the patient decided that the removable overdenture retained with two implants was the best and least complicated treatment option for her. The upper denture was not an issue for the patient, as it was retentive and stable. In order to limit costs, the upper denture was not replaced. A surgical guide was fabricated after the vertical dimension, aesthetic and phonetic parameters had been corrected in the wax denture try-in. Two 4.1 mm RN connection dental implants (Straumann), each 8 mm in length, were placed in sites #32 and #42 (Figs. 7a & 9b). These were allowed to integrate for three months prior to the provision of a ball-abutment-retained overdenture. This denture functioned without surgical or prosthetic issues for a five-year period. Unfortunately, the patient revisited her denturist and complications arose after an attempted intra-oral relining procedure. On examination, it was determined that the ball abutments were damaged and needed to be replaced. The female housings needed to be replaced, as they were no longer seated properly on the ball abutments.

The patient was then given the option of having either another ball-abutment-retained over-

denture or a bar- and clip-retained overdenture instead. The patient opted for the bar and clip overdenture. The first step was to remove the damaged ball abutments and seat the appropriate implant adapters on each implant (H1 adapters of 1 mm in length; Figs. 4a & b). The tube bar was then inserted into the cutting tool and cut to correct length using the cutting disc (Figs. 6a–c). The bar assembly was then connected to the implant adapters and torqued into place. The universal nature of the ball joint allows the tube bar to be located in the horizontal plane in a truly stress-free alignment (Figs. 2a–c & 7b–c).

The implant adapters were chosen so that when the bar is seated it is parallel to the occlusal plane, with at least 1.0 mm clearance between the underside of the bar and the mucosal tissues (Fig. 7b). This allows access for effective oral hygiene procedures around the dental implants and reduces the risk of tissue hyperplasia around the bar when the denture is seated. From a surgical perspective, ridge reduction procedures may be required firstly to aid ideal implant placement and secondly to ensure there is enough space to fabricate the final denture to be seated on the bar assembly. If multiple implants are used, adapters with a range of lengths should be used. Multiple implants are more difficult to place parallel to each other, but the ball joints can accommodate up to 15° of implant divergence. Surgical complications are seen more commonly in bar and clip overdentures than stud-attachment overdentures. Clinically, the whole procedure took six minutes, from removing the ball abutments to torquing the bar assembly into place.

The ball-abutment-retained denture was then hollowed out so that it could be seated over the bar assembly and used as a provisional while the new definitive denture was being fabricated. A custom tray was used to make a border-moulded final impression with Impregum (3M ESPE), after blocking out the bar assembly (Fig. 10). A wax occlusal rim was

then used to determine the vertical dimension of the occlusion and obtain a CR record. This was followed by a full wax try-in to ensure that all the aesthetic, phonetic and occlusal parameters were correct. At this point, the denture was ready to be processed. The denture is processed in one of two ways:

- In the laboratory technique, the female part T (made from pure Grade 4 titanium) is integrated into the denture and a complete prosthesis is returned to the clinic. Part T is contra-indicated for use on two implant bars (Figs. 11a & b).
- In the chairside technique, the denture is processed and a window is cut in the denture, through which the dentist can pick up the female part E (made from Elitor—68.6% gold alloy), using self-curing acrylic resin in the patient's mouth after seating the spacer and blocking out all undercuts (Fig. 10).




Fig. 11a

The total width of the bar with the E clip seated is 4.3 mm (Fig. 12) and 3.6 mm with the T clip seated (Fig. 11a). This is relevant for treatment planning, as ridge reduction may be indicated to provide space for the denture.

In the laboratory method, the denture is completed with the female part T integrated into the denture. The dentist then chooses the level of retention required by selecting the appropriate plastic inserts and seating them in part T (Fig. 11b). The plastic inserts are designed to compensate for transfer inaccuracies during the impression, master cast fabrication and post-processing stages. The presence of a laboratory technician is recommended for the chairside technique. A spacer is




Fig. 11b




Fig. 12

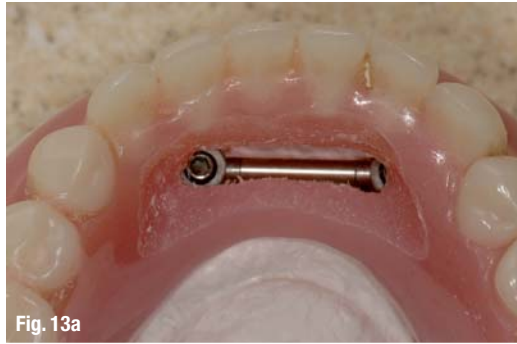

Fig. 13a

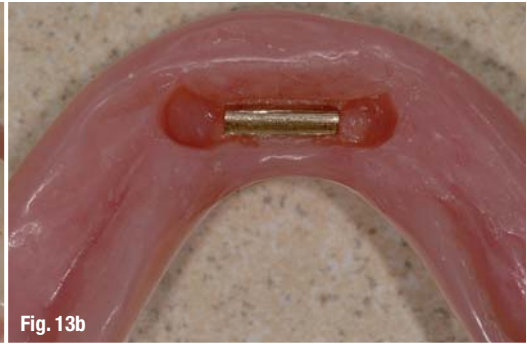

Fig. 13b

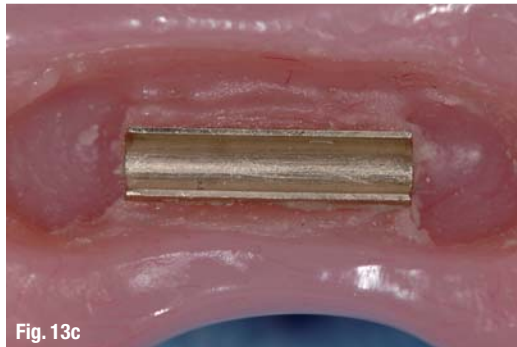


Fig. 13c

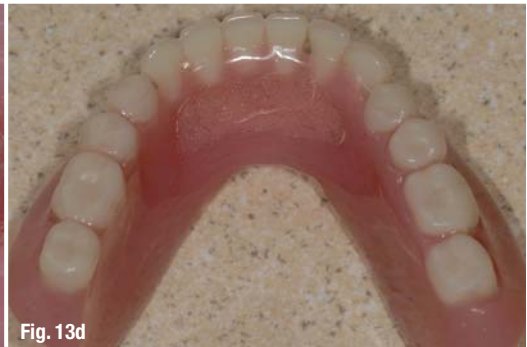

Fig. 13d

placed on the tube bar prior to seating the E clip to ensure vertical resilience. The spacer ensures a slight gap between the E clip and the tube bar so that when the patient bites down, the E clip does not overload or distort the bar as the denture beds into the supporting mucosa. All undercuts around the bar assembly, especially between the bar clip and tissues, were blocked out with a silicone material (Fig. 10). A window was then cut into the lingual aspect of the denture to expose the E clip (Fig. 13a). A small bead of cold-cure acrylic resin was then placed on the E clip, covering the retentive element of the clip. The E clip was then attached to the denture with small increments of resin (Fig. 13b). The resin was allowed to cure fully before the denture with the E clip was removed from the mouth. The remainder of the void was then filled with cold-cure resin and allowed to cure outside the mouth (Figs. 13c & d). Ideally, this process should take place in a pressure pot.

A transfer jig that fits into the E clip and is effectively a tube bar replica can be utilised if a large volume of acrylic has been used to house the E clip. The denture with the transfer jig seated in the E clip is bedded into a patty of fast-set plaster, similar to a denture-repair scenario. Once the stone has set, the denture is placed in a pressure pot with warm water and the self-curing resin is allowed to polymerise. Once the acrylic has fully cured, it is separated from the stone base and the transfer jig and all excess acrylic is trimmed.


At least 50% of the lamellae of the E clip must be clear of resin. Only the superior part of the E clip

with the attachment portion and shoulder section is locked into acrylic (Fig. 13c). The lamellae must be free to flex over the tube bar during insertion and removal of the denture. If the resin is in direct contact with the lamellae, the denture may not seat, as the E clip cannot flex. Finally, the definitive prosthesis was seated (Figs. 14a & b). The level of retention of the E clip was adjusted using the activation and deactivation tools provided in the restorative kit. The occlusion was checked and adjusted after verifying that the denture had been properly seated, using pressure-indicating paste. The bar assembly is required to retain the denture in the two-implant scenario. Support is derived from the conventional hard- and soft-tissue load, bearing areas like the residual ridge and the buccal shelf. The patient was then instructed on appropriate care of the implants and the prosthesis, and a routine recall and maintenance programme was instituted.

Discussion

It is imperative that the block-out procedure around the bar assembly is correct. Otherwise acrylic will enter an undercut area and cure, thus locking the denture to the bar assembly. As a consequence, there would be no option but to cut the denture from the bar to free it. This will not only ruin the denture, but may also damage the bar—a very costly and time-consuming mistake. The E clip is designed for use with the two-implant bar and should be picked up with a self-curing resin as explained. The T clip is for a laboratory-processed denture on four or more implants, as the plastic in-

Designed For Success, Packaged For Value



Cover Screw

ReActive™ Implant

All-in-One Packaging includes implant, abutment, transfer & cover screw for only €145

RePlant® Implant System Advantages:

Nobel Biocare-Compatible Internal Tri-Lobe
Prosthetic compatibility with Nobel Biocare's NobelReplace™ Implant

Surgical Compatibility with RePlant & NobelReplace™
No need to change surgical protocol or tools

Three Implant Designs & Packaging Options

Allows for selection based on price, packaging or thread design
RePlant®: €115 includes cover screw, temporary abutment/transfer
RePlus®: €130 includes cover screw & "snappy" abutment/transfer
ReActive™: €145 includes cover screw & preparable abutment/transfer

Micro-Threads

Reduce crestal stress for improved initial stability

Coronal Bevel on RePlus & ReActive

Allows for use of platform switching technology

Titanium Alloy

Offers superior strength to pure titanium

RePlant®

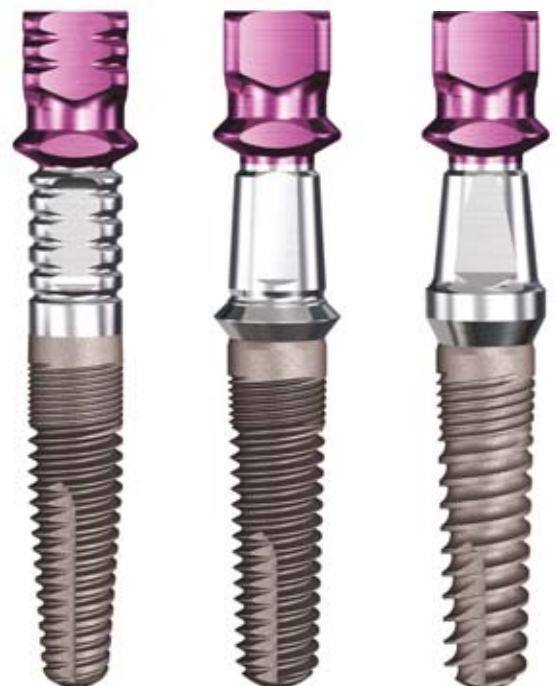Body Dimensions match NobelReplace™

RePlus®

Body Taper for Bone Expansion

ReActive™

Buttress Threads for Increased Surface



www.implantdirect.eu | 00800 4030 4030

All trademarks are property of their respective companies.
 †Implant Dent 2011; 20: 13-19 (n190); †PSN-EAO09PSI-346 (n373) Reports available at www.implantdirect.eu

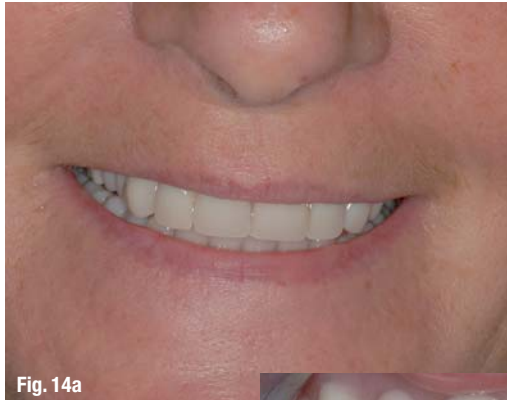

Fig. 14a

serts correct any processing errors. It must not be used in a two-implant situation.

Several studies have shown that conventional bar- and clip-retained overdentures transfer significant stress to the supporting peri-implant tissues (mainly bone).⁹⁻¹¹ The key to the SFI-Bar system is that the bar is assembled in the patient's mouth without the use of soldering, laser welding or conventional bonding techniques, thus reducing stress transmission to and bone loss around the implants. Studies have demonstrated that any laboratory-based technique that requires a master cast made from a dental impression will result in a bar that is not truly passive.^{8,9} As a result, several authors have suggested that the only way to achieve a passive fit would be to assemble the framework intra-orally and then bond the bridge pontic in place.^{12,13} This is the method employed with this system.

There is no casting, soldering, laser welding or bonding of components when fabricating the definitive bar. This, combined with the universal ball-joint nature of the components, ensures a true passive fit when the bar is assembled. The finite element analysis clearly shows the stress-free nature of the bar when being assembled and when the prosthesis experiences loading (Figs. 2a-c).

No laboratory time is required to fabricate the bar and there are no costly implant components or gold-alloy charges. Clinically, there is no need for the bar sections to be soldered in an attempt to achieve passive fit—a step that may need repeating—as with the conventional method.

There are no soldered or laser-welded joints, so the bar assembly has no inherent weak points that may fracture or corrode. The bar is assembled by the clinician, who also attaches the E clip intra-orally. The reduced number of clinical appointments, lab-

oratory time and component costs result in reduced treatment costs for the patient. In the case presented, for example, the bar assembly was completed in only six minutes. This is approximately the same time it takes for a polyether impression material (like Impregum) to set!

Conclusion

The SFI-Bar is relatively inexpensive compared with conventional gold castings and CAD/CAM options. The overall cost of the prosthesis and treatment time are significantly reduced compared with conventional and CAD/CAM techniques. Precision-milled components provide an improved quality of fit.

The physical and mechanical properties of the component materials can be controlled accurately, which is difficult to achieve with conventional casting methods. The SFI-Bar can be connected to two or more implants to create a full-arch bar if needed, while the SFI-Bar system produces a bar assembly that seats passively as demonstrated by finite element analysis. The passive-fit bar assembly can result in greatly reduced stress transmission to the supporting implants. Studies have demonstrated that this is also a viable treatment option for immediate-loading situations in the mandible, provided that the implants achieved insertion torques exceeding 50 Ncm approximately.

The finite element data and images were kindly provided by Dr Ludger Keilig, Endowed Chair of Oral Technologies, University of Bonn, Germany.

Disclaimer: The SFI-Bar, implant adapters and E clips were provided by Cendres+Métaux. The author did not receive any financial inducements to write this article or payment towards laboratory charges, nor was any other kind of payment given or received.

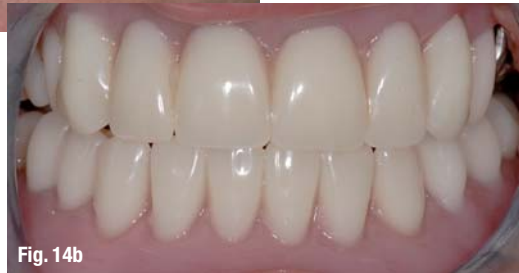
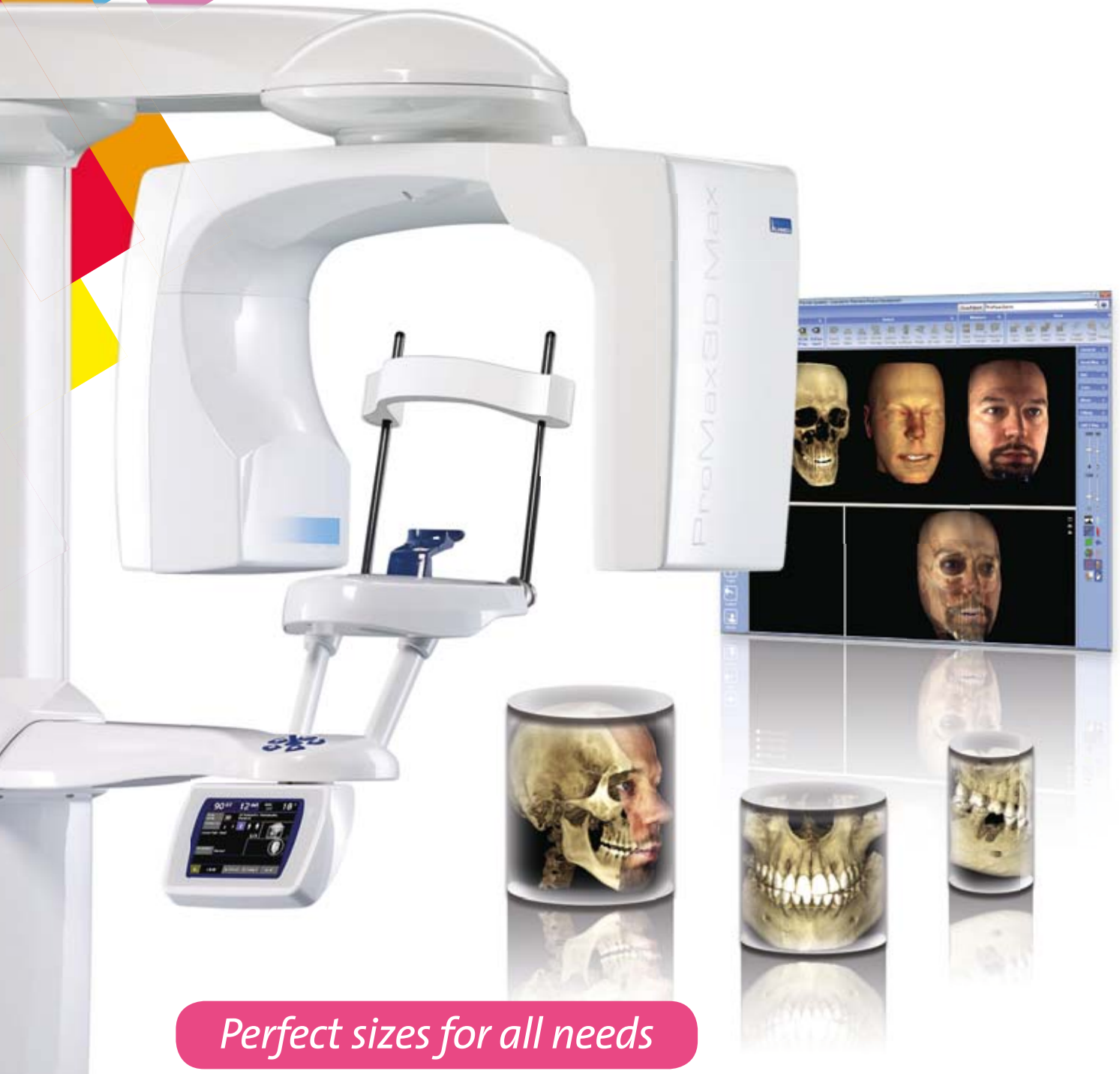
Fig. 14b

_contact	implants
<p>Dr Tussavir Tambra BDS, DDS, MS Prosthodontics (Michigan) Wolverhampton, United Kingdom</p> <p>dr.tambra@hotmail.co.uk</p>	

Planmeca ProMax[®] 3D

Unique product family



Perfect sizes for all needs

3D X-ray • 3D photo • panoramic • cephalometric

Romexis[®] software completes 3D perfection



Digital perfection™

More information

www.planmeca.com

Planmeca Oy
Asentajankatu 6, 00880 Helsinki, Finland
tel. +358 20 7795 500, fax +358 20 7795 555
sales@planmeca.com

PLANMECA