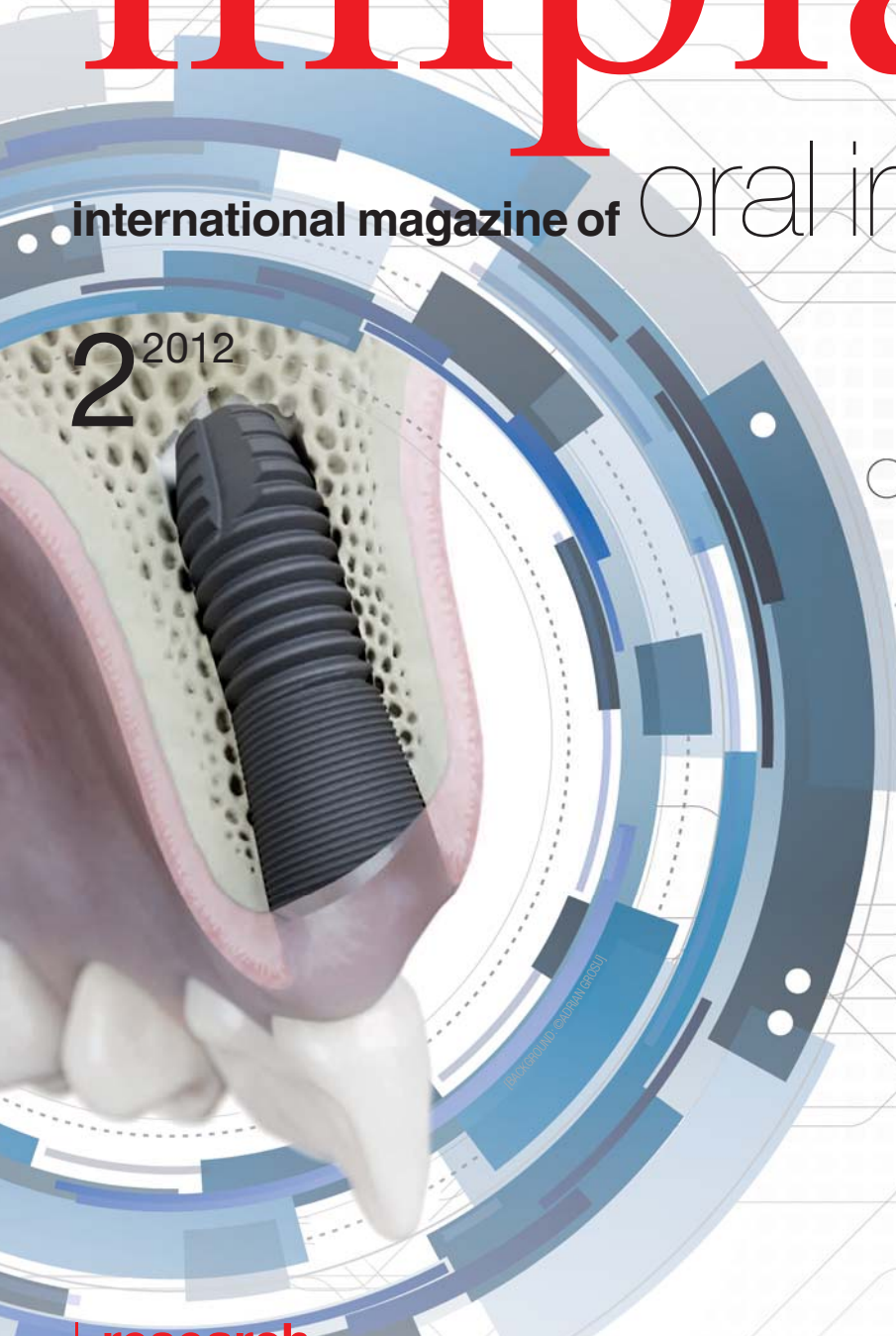

# implants

international magazine of oral implantology

2<sup>2012</sup>



| **research**

The implant-retained bar overdenture

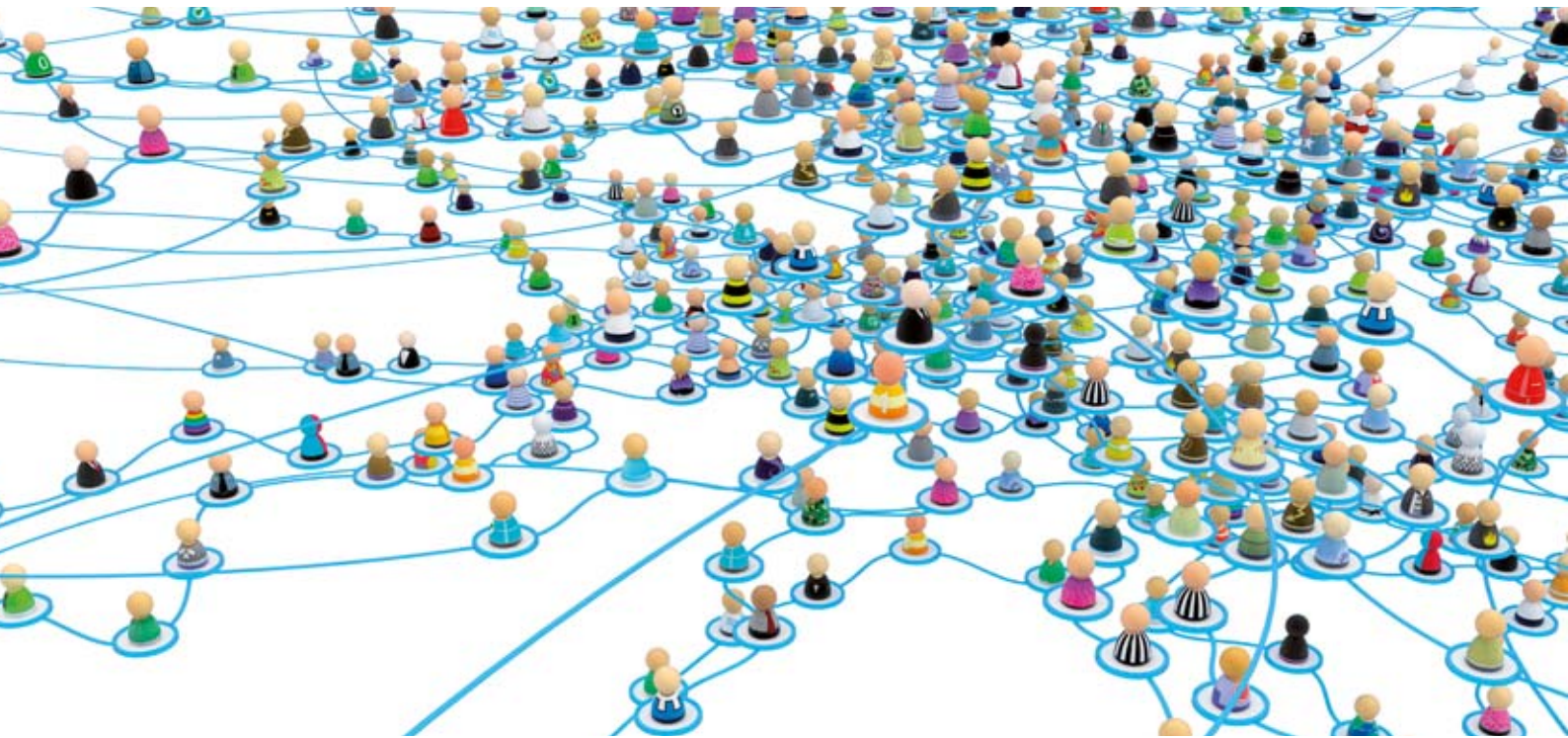| **case report**

Implantology in the atrophied alveolar ridge without augmentation

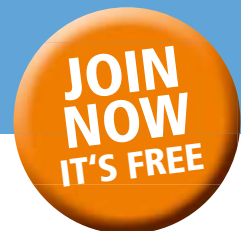| **meetings**

“Creating the future by going back to the roots”  
New findings at AstraTech World Congress





## CONNECTING THE CAMLOG COMMUNITY



**THE ONLINE PLATFORM FOR  
CAMLOG USERS WORLDWIDE!**

**CLINICAL CASES | VIDEOS | DISCUSSIONS | TUTORIALS | LEXICON**



Dr. Peter Hunt,  
Editor & Founder,  
Camlog Connect

This site is for you. Its slogan is "By Camlog Users: For Camlog Users", and we mean it. We want you to use it, to talk about it with your colleagues, to let us know what you want more of, to ask questions and to share your own cases, problems and solutions.

**TOGETHER WE CAN HELP EACH OTHER.**



# Laser (in)dispensable in implantology?



Dr Georg Bach

Have you been following the coverage of dental congresses in the past few weeks? If so, you might have felt just the same positive sensation as I have when I came across the fact that scientific contributions on laser applications in implantology have gained a high rank in the past congress season. By the way, the same holds true for scientific texts on implantology in dental specialist publications.

The growing impact of laser applications on both congresses and scientific literature does indeed pose a snapshot of the current status of laser in dental therapies and might even express a recent trend. This trend, in my view, bears various notable facets:

Many of the numerous implantological congresses and symposia intersecting with laser dentistry have included reports on the application of monochromatic light into their programs. Moreover, whole sessions are dedicated to laser in both implantological and periodontal congresses and symposia. On such occasions, the high value of atraumatic laser incisions with significantly reduced hemorrhage is highlighted, along with the lack of alternatives to laser surface decontamination in the treatment of periimplantitis.

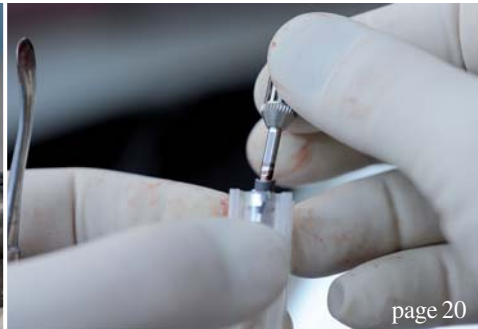As you can see, we are provided with a sufficient (and evidence-based) number of opportunities to pursue our passion for monochromatic light in implantology. It follows that our résumé be "No (more) implantology without laser"!\_

With best regards,

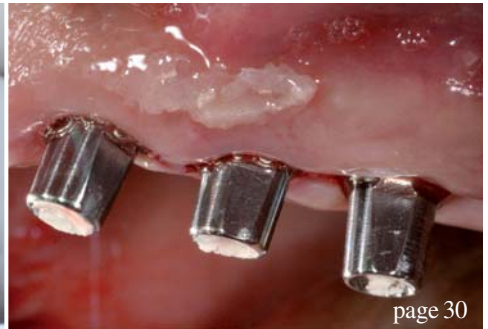Dr. Georg Bach



page 6



page 20



page 30

| editorial

- 03 **Laser (in)dispensable in implantology?**  
| Dr Georg Bach

| research

- 06 **The implant-retained bar overdenture: The SFI-Bar**  
| Dr Tussavir Tandra
- 16 **Restoration of implant supported crowns**  
| Dr Igor Cemavin

| case report

- 20 **Implantology in the atrophied alveolar ridge without augmentation**  
| Prof Dr Frank Liebaug *et al.*
- 26 **Bone expansion in one surgical step**  
| Prof Sergio Alexandre Gehrke *et al.*

| industry report

- 30 **Screwed versus cemented immediately functionally loaded implants**  
| Dr Luca Di Alberti *et al.*
- 34 **Immediate loading of the upper right lateral and central incisors**  
| Prof Alessandro Pozzi
- 36 **One straight maxillary bridge prosthesis on three implants**  
| Dr Eric Normand

| news

- 40 **Manufacturer News**
- 48 **News**

| education

- 43 **4<sup>th</sup> International CAMLOG Congress**  
| CAMLOG Foundation
- 44 **ITI Congresses in Switzerland and Spain make great debuts**  
| ITI Center

| meetings

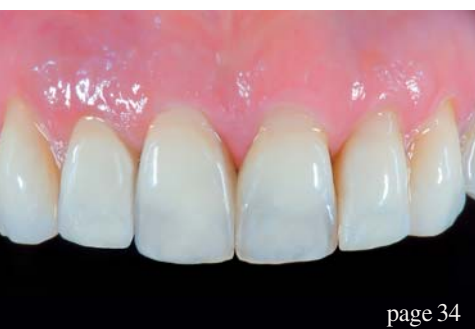- 46 **“Creating the future by going back to the roots”**  
| Dental Tribune, AstraTech

| about the publisher

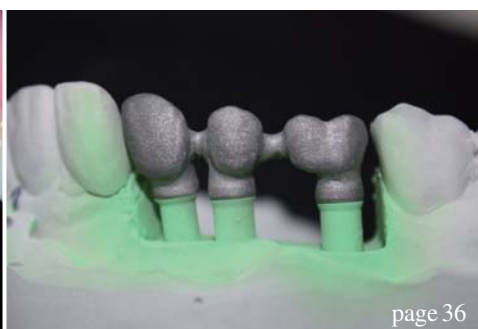- 50 | imprint



Cover image courtesy of Astra Tech GmbH, [www.astratech.de](http://www.astratech.de).  
Artwork by Sarah Fuhrmann, OEMUS MEDIA AG.



page 34



page 36



page 43



Behind every successful  
implantologist is an Implantmed



Scan the QR code with  
your mobile telephone  
for more information on  
Implantmed

With the new Implantmed you perform implant procedures with maximum precision. The unit is easy to operate and guarantees longer working without fatigue – thanks to the **lightweight**, yet **powerful motor** and the ergonomically-shaped contra-angle handpiece. And the integrated **thread cutter function** helps you with especially hard bone.

implantmed

# The implant-retained bar overdenture: The SFI-Bar

Author\_Dr Tussavir Tambra, United Kingdom

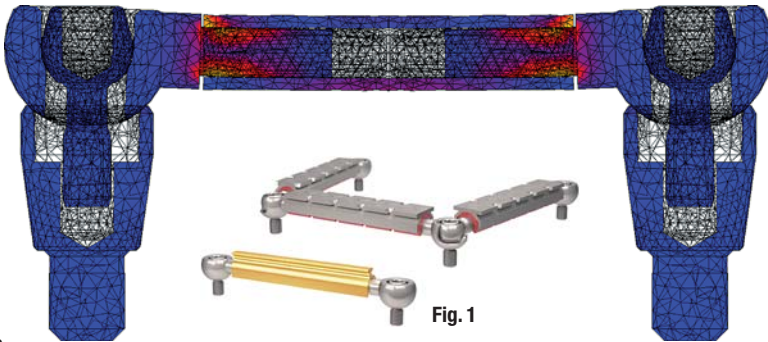


Fig. 2a

Fig. 1

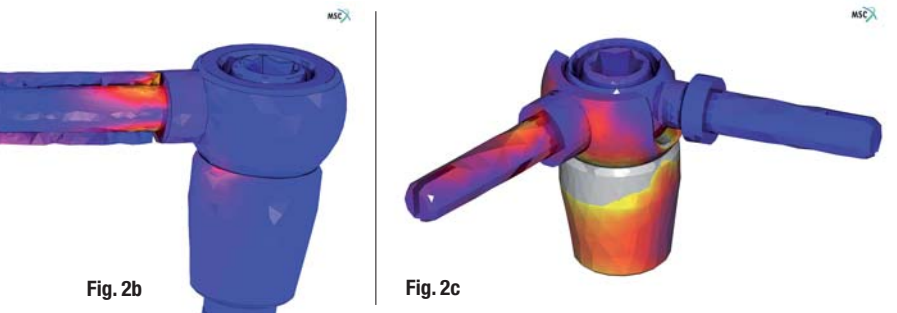


Fig. 2b

Fig. 2c

ous angulations (All-on-4, Nobel Biocare; Columbus Bridge, BIOMET 3i), has resulted in a significant uptake of treatment by edentulous patients and those with a failing dentition. This is mainly because a fixed bridge is provided and treatment times are reduced from months to hours, avoiding a conventional denture.

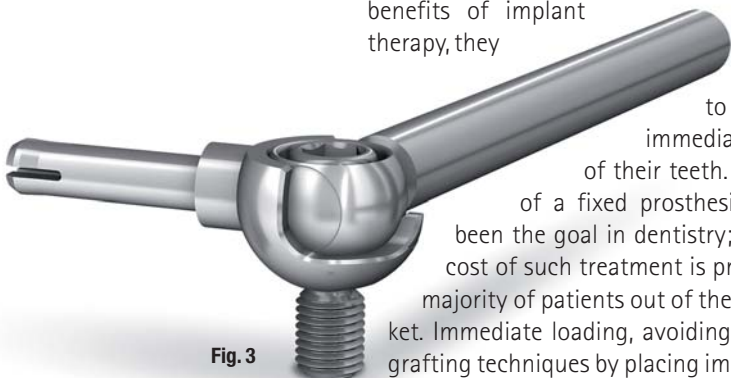
Most edentulous patients can tolerate a complete maxillary denture with few problems. The vast majority of problems arise in the mandible, where the underlying supporting tissues are not designed to function under this type of occlusal loading. Even a properly constructed complete lower denture can move as much as 10 mm in function. This continuous movement of the prosthesis results in loss of the supporting bone (or remodelling), further destabilising the denture. Poor ridge form increases denture instability and this produces more remodelling. Edentulism fulfils the WHO definition of a physical impairment.

## Introduction

The advent of CAD/CAM technology and the more widespread utilisation of implants in modern dentistry have led to an explosion of treatment solutions designed to address any situation encountered by the general dentist. As patients have become more aware of the benefits of implant therapy, they

have begun to demand more immediate restoration of their teeth. The provision of a fixed prosthesis has always been the goal in dentistry; however, the cost of such treatment is pricing the vast majority of patients out of the implant market. Immediate loading, avoiding conventional grafting techniques by placing implants at vari-

Fig. 3



## Treatment protocol

A simple treatment protocol was devised to treat this problem. According to this protocol, two dental implants are placed in the inter-foraminal area of the mandible, to which either a bar or stud attachments are connected to retain the lower



Fig. 4a

denture. This treatment greatly improves both masticatory efficiency and function in patients. Over the last two decades, attempts have been made to render the implant-retained overdenture the standard treatment for edentulism,<sup>1</sup> as demonstrated most recently by the McGill consensus.<sup>2</sup>

Prosthetic failure, usually loss of retention, and the technical difficulties encountered when relining or changing stud attachments proved to be major negative factors in dentists' attitudes towards this treatment modality. Several attempts were made to redesign and improve the attachments; however, owing to previous negative experiences, most dentists became reluctant to adopt implant-retained overdentures as a routine treatment option. The push to place more implants in an attempt to improve the situation led to the bar- and clip-retained overdenture scenario. This technique was more successful but still encountered similar issues to the stud-attachment overdentures.<sup>3</sup>

Poor stress transmission from the prosthesis to the supporting implants results in bone loss around the implants (especially the most distal implants in the multiple bar scenario), in addition to prosthetic and surgical complications.<sup>4</sup> This resulted in implant companies and clinicians moving away from the two implant-retained overdenture treatment option in favour of fixed solutions, such as round-house bridges fixed on four or more implants. As a result, the vast majority of patients cannot access implant therapy owing to financial constraints. The McGill consensus brought the implant-retained overdenture back into the spotlight as a way of increasing access to implant dentistry and improving patients' quality of life. Improved component manufacturing techniques, and greater care and attention to both surgical and restorative treatment planning have significantly improved treatment outcomes using overdentures.<sup>5</sup>

Recently Cendres+Métaux introduced the Stress Free Implant Bar, or SFI-Bar, to the dental community. This unique, implant-platform-independent restorative bar overdenture solution allows the fabrication of a true passive-fit bar and clip system on two or more implants (Fig. 1). Finite element studies and clinical evaluation of the system have found minimal stress transmission from the prosthesis to the implants under loading (Figs. 2a-c), with most stresses being evenly distributed between the supporting implants. Vertical loads are transmitted effectively to the supporting implants, while undesirable lateral stresses are largely eliminated. More recent clinical studies have also shown it to be a viable immediate-loading treatment solution. The technique is in its infancy, so long-term (five years or more) data is not available. The SFI-Bar is a modular system that connects multiple dental implants with no soldered or laser-welded joints.

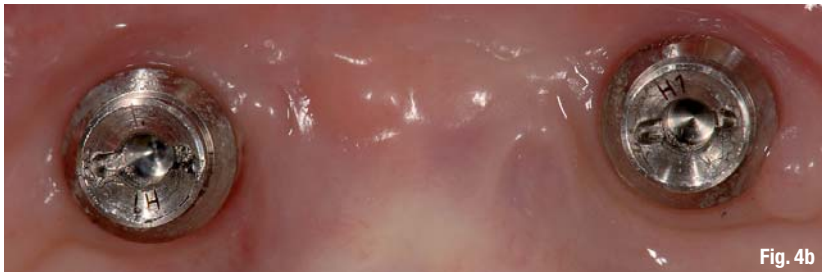
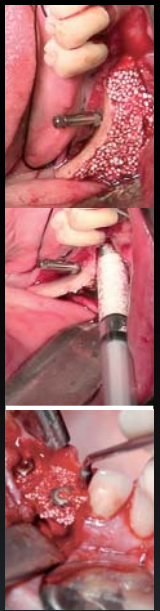
Fig. 4b



Fig. 5

sticky granules  
bionic




AD  
easy-graft®CRYSTAL

easy-graft®  
CRYSTAL

**Ingenious:** Simple handling and accelerated osteoconduction for long-term volume preservation.

SUNSTAR  
GUIDOR®

Degradable Solutions AG  
A Company of the Sunstar Group  
Wagistrasse 23  
CH-8952 Schlieren / Zurich  
www.easy-graft.com

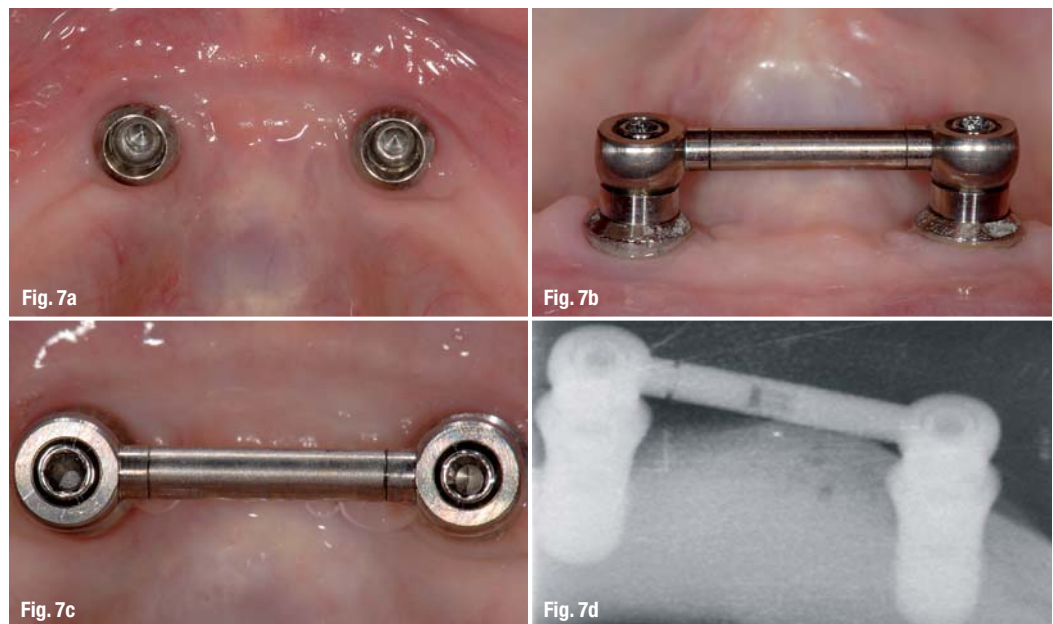


joint connection, ensuring a perfect section each time. The jig slides along the tube bar until it reaches the implant adapter, accurately sizing the bar. The tube bar is then locked in place and cut to size with a cutting disc (Fig. 6c). This process can be carried out either chair side (two-implant bar) or in the laboratory (four-implant bar or larger). An implant-level master cast will be required for cutting in the laboratory. The cutting of the tube bar must always be carried out extra-orally.

Once the tube bar has been cut, the ball joints are inserted into each end of the tube bar prior to seating on the implant adapters (Figs. 7a–d) and torqued into place. The SFI-Bar is now complete and the patient is ready for the retentive element to be housed in the denture. The ball joints can accommodate non-parallel implant placement up to a maximum of 15° angulation correction. The absence of any soldered or welded joints means that a greater length of the bar can be engaged by the retentive clip. In conventional techniques, the presence of a weld increases the bar thickness, at that point preventing any retentive clip engaging that area. In the SFI-Bar, the clip engages the full length of the bar between the ball joints (Fig. 8). The bar assembly must be parallel with the occlusal plane; therefore, a selection of implant adapters of varying lengths should be available.

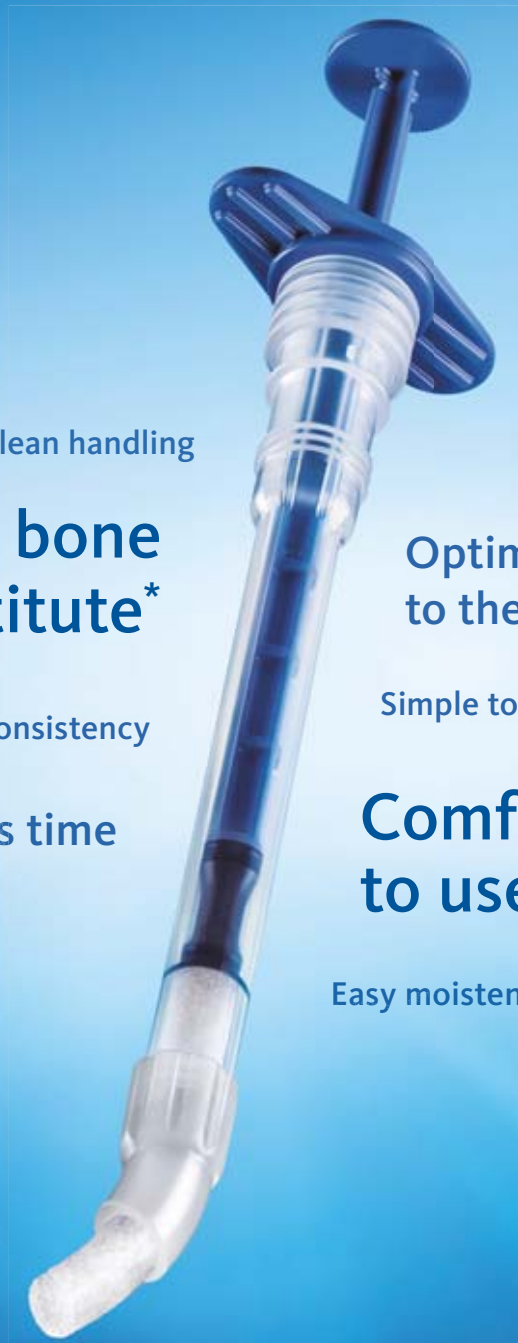The minimum inter-implant distance is 8 mm and the maximum is 26 mm. This is an expandable bar system, in which add-on kits (Fig. 3) can be used to incorporate multiple implants to create a round-house bar. Implant adapter abutments are first torqued onto the implants (Figs. 4a & b). They form one half of a universal ball joint—the other half being incorporated into the bar element. The bar itself is formed by a hollow tube bar that fits onto the end of each ball joint (Fig. 5). This tube bar is cut to the correct length using a specialised jig and cutting disc (Figs. 6a–c). The jig is designed to mimic a ball

Most of the major implant companies offer CAD/CAM-fabricated bar and clip solutions. However, these bars are relatively expensive and are fabricated through a conventional impression and master cast technique. Studies have shown that 50% of all errors during impression making and cast fabrication result in non-passive fit of bars and





Nothing changed.  
Just improved.



Clean handling

**No. 1 bone substitute\***

Optimal access to the defect

Very good consistency

Simple to use

Saves time

**Comfortable to use**

Easy moistening

**New!**

- ✓ Unwrap
- ✓ Moisten
- ✓ Use

\* iData Research Inc., US Dental Bone Graft Substitutes and other Biomaterials Market, 2011.

iData Research Inc., European Dental Bone Graft Substitutes and other Biomaterials Market, 2010.

Please check for availability of this product with your country representative: [www.geistlich-pharma.com](http://www.geistlich-pharma.com)

For more information visit:  
[www.bio-oss.com](http://www.bio-oss.com)




Fig. 8

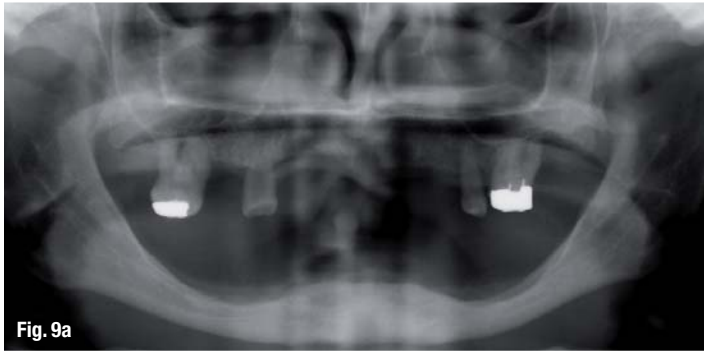


Fig. 9a

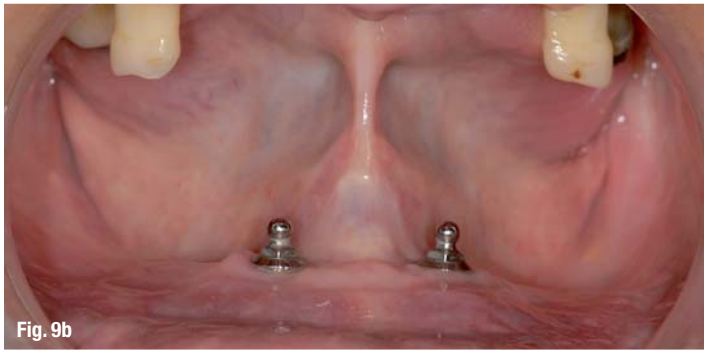

Fig. 9b

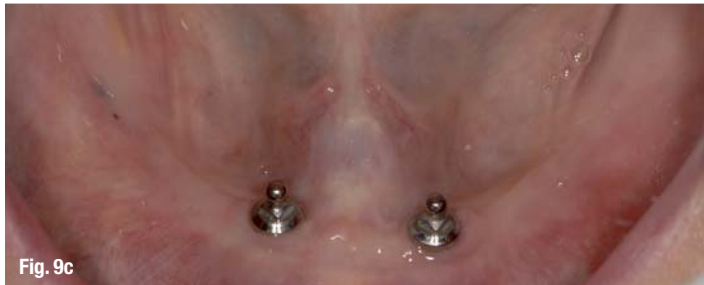

Fig. 9c




Fig. 10

frameworks. Thus, any bar fabricated through an impression or cast technique cannot be truly passive.<sup>6-8</sup> A clinical case will be presented below in order to demonstrate the direct chair-side method and the use of the SFI-Bar on two implants to restore an edentulous mandible. In addition, the main points for use with the indirect method will be outlined.

## Case presentation

In 2006, a 60-year-old female patient initially presented, complaining of an ill-fitting lower denture. The patient had worn a conventional complete mandibular denture for over 20 years, opposing a metal-based maxillary removable partial denture. The patient had visited a denturist on several occasions to try to improve the situation. After multiple relining procedures, the patient decided to seek expert help. An OPG radiograph revealed a severely resorbed mandible that clinically presented as a classic bowl-shaped deficiency (Figs. 9a–c). Radiographic examination revealed there was adequate bone volume in the anterior region for the placement of dental implants. However, a fixed solution would only have provided a shortened dental arch, as the mental foramen had become more mesial owing to bone resorption. Placing implants distal to the mental foramen was not an option, owing to the proximity of the inferior dental nerve and lack of bone height. The patient was not keen to have any nerve repositioning or complex bone grafting. Another important factor negating the fixed solution was the size of the volume defect. This would have been difficult both to correct and to maintain and would have produced a poor aesthetic result. The additional bulk of denture flanges allowed proper facial support.

After discussing all the relevant issues, the patient decided that the removable overdenture retained with two implants was the best and least complicated treatment option for her. The upper denture was not an issue for the patient, as it was retentive and stable. In order to limit costs, the upper denture was not replaced. A surgical guide was fabricated after the vertical dimension, aesthetic and phonetic parameters had been corrected in the wax denture try-in. Two 4.1 mm RN connection dental implants (Straumann), each 8 mm in length, were placed in sites #32 and #42 (Figs. 7a & 9b). These were allowed to integrate for three months prior to the provision of a ball-abutment-retained overdenture. This denture functioned without surgical or prosthetic issues for a five-year period. Unfortunately, the patient revisited her denturist and complications arose after an attempted intra-oral relining procedure. On examination, it was determined that the ball abutments were damaged and needed to be replaced. The female housings needed to be replaced, as they were no longer seated properly on the ball abutments.

The patient was then given the option of having either another ball-abutment-retained over-

denture or a bar- and clip-retained overdenture instead. The patient opted for the bar and clip overdenture. The first step was to remove the damaged ball abutments and seat the appropriate implant adapters on each implant (H1 adapters of 1 mm in length; Figs. 4a & b). The tube bar was then inserted into the cutting tool and cut to correct length using the cutting disc (Figs. 6a–c). The bar assembly was then connected to the implant adapters and torqued into place. The universal nature of the ball joint allows the tube bar to be located in the horizontal plane in a truly stress-free alignment (Figs. 2a–c & 7b–c).

The implant adapters were chosen so that when the bar is seated it is parallel to the occlusal plane, with at least 1.0 mm clearance between the underside of the bar and the mucosal tissues (Fig. 7b). This allows access for effective oral hygiene procedures around the dental implants and reduces the risk of tissue hyperplasia around the bar when the denture is seated. From a surgical perspective, ridge reduction procedures may be required firstly to aid ideal implant placement and secondly to ensure there is enough space to fabricate the final denture to be seated on the bar assembly. If multiple implants are used, adapters with a range of lengths should be used. Multiple implants are more difficult to place parallel to each other, but the ball joints can accommodate up to 15° of implant divergence. Surgical complications are seen more commonly in bar and clip overdentures than stud-attachment overdentures. Clinically, the whole procedure took six minutes, from removing the ball abutments to torquing the bar assembly into place.

The ball-abutment-retained denture was then hollowed out so that it could be seated over the bar assembly and used as a provisional while the new definitive denture was being fabricated. A custom tray was used to make a border-moulded final impression with Impregum (3M ESPE), after blocking out the bar assembly (Fig. 10). A wax occlusal rim was

then used to determine the vertical dimension of the occlusion and obtain a CR record. This was followed by a full wax try-in to ensure that all the aesthetic, phonetic and occlusal parameters were correct. At this point, the denture was ready to be processed. The denture is processed in one of two ways:

- In the laboratory technique, the female part T (made from pure Grade 4 titanium) is integrated into the denture and a complete prosthesis is returned to the clinic. Part T is contra-indicated for use on two implant bars (Figs. 11a & b).
- In the chairside technique, the denture is processed and a window is cut in the denture, through which the dentist can pick up the female part E (made from Elitor—68.6% gold alloy), using self-curing acrylic resin in the patient's mouth after seating the spacer and blocking out all undercuts (Fig. 10).




Fig. 11a

The total width of the bar with the E clip seated is 4.3 mm (Fig. 12) and 3.6 mm with the T clip seated (Fig. 11a). This is relevant for treatment planning, as ridge reduction may be indicated to provide space for the denture.

In the laboratory method, the denture is completed with the female part T integrated into the denture. The dentist then chooses the level of retention required by selecting the appropriate plastic inserts and seating them in part T (Fig. 11b). The plastic inserts are designed to compensate for transfer inaccuracies during the impression, master cast fabrication and post-processing stages. The presence of a laboratory technician is recommended for the chairside technique. A spacer is




Fig. 11b




Fig. 12

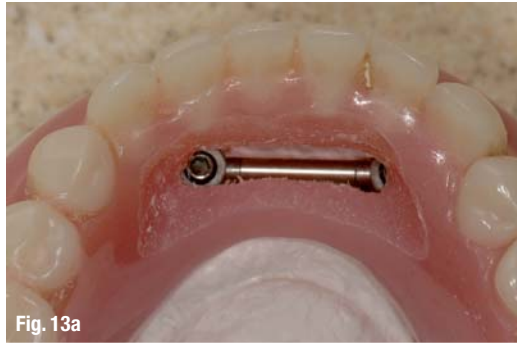

Fig. 13a

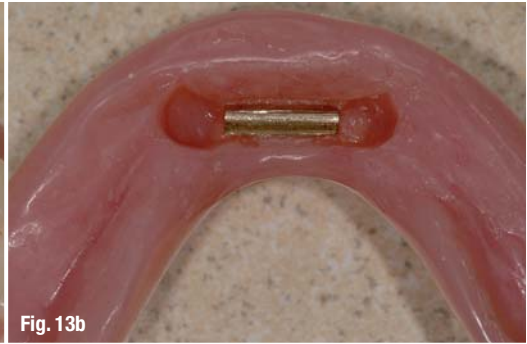

Fig. 13b

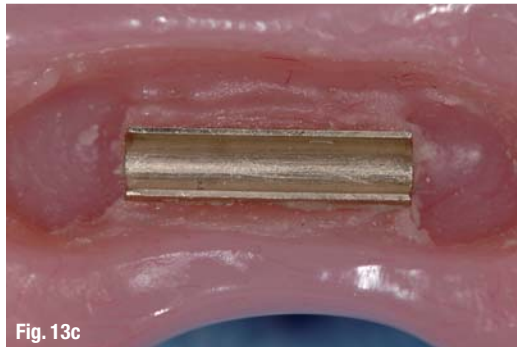


Fig. 13c

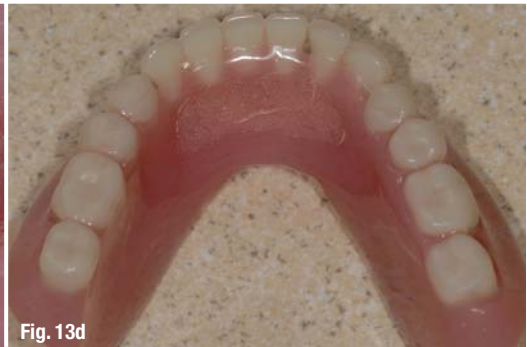

Fig. 13d

placed on the tube bar prior to seating the E clip to ensure vertical resilience. The spacer ensures a slight gap between the E clip and the tube bar so that when the patient bites down, the E clip does not overload or distort the bar as the denture beds into the supporting mucosa. All undercuts around the bar assembly, especially between the bar clip and tissues, were blocked out with a silicone material (Fig. 10). A window was then cut into the lingual aspect of the denture to expose the E clip (Fig. 13a). A small bead of cold-cure acrylic resin was then placed on the E clip, covering the retentive element of the clip. The E clip was then attached to the denture with small increments of resin (Fig. 13b). The resin was allowed to cure fully before the denture with the E clip was removed from the mouth. The remainder of the void was then filled with cold-cure resin and allowed to cure outside the mouth (Figs. 13c & d). Ideally, this process should take place in a pressure pot.

A transfer jig that fits into the E clip and is effectively a tube bar replica can be utilised if a large volume of acrylic has been used to house the E clip. The denture with the transfer jig seated in the E clip is bedded into a patty of fast-set plaster, similar to a denture-repair scenario. Once the stone has set, the denture is placed in a pressure pot with warm water and the self-curing resin is allowed to polymerise. Once the acrylic has fully cured, it is separated from the stone base and the transfer jig and all excess acrylic is trimmed.


At least 50% of the lamellae of the E clip must be clear of resin. Only the superior part of the E clip

with the attachment portion and shoulder section is locked into acrylic (Fig. 13c). The lamellae must be free to flex over the tube bar during insertion and removal of the denture. If the resin is in direct contact with the lamellae, the denture may not seat, as the E clip cannot flex. Finally, the definitive prosthesis was seated (Figs. 14a & b). The level of retention of the E clip was adjusted using the activation and deactivation tools provided in the restorative kit. The occlusion was checked and adjusted after verifying that the denture had been properly seated, using pressure-indicating paste. The bar assembly is required to retain the denture in the two-implant scenario. Support is derived from the conventional hard- and soft-tissue load, bearing areas like the residual ridge and the buccal shelf. The patient was then instructed on appropriate care of the implants and the prosthesis, and a routine recall and maintenance programme was instituted.

## Discussion

It is imperative that the block-out procedure around the bar assembly is correct. Otherwise acrylic will enter an undercut area and cure, thus locking the denture to the bar assembly. As a consequence, there would be no option but to cut the denture from the bar to free it. This will not only ruin the denture, but may also damage the bar—a very costly and time-consuming mistake. The E clip is designed for use with the two-implant bar and should be picked up with a self-curing resin as explained. The T clip is for a laboratory-processed denture on four or more implants, as the plastic in-

# Designed For Success, Packaged For Value



Cover Screw

## ReActive™ Implant

All-in-One Packaging includes implant, abutment, transfer & cover screw for only €145

## RePlant® Implant System Advantages:

**Nobel Biocare-Compatible Internal Tri-Lobe**  
Prosthetic compatibility with Nobel Biocare's NobelReplace™ Implant

**Surgical Compatibility with RePlant & NobelReplace™**  
No need to change surgical protocol or tools

### Three Implant Designs & Packaging Options

Allows for selection based on price, packaging or thread design  
**RePlant®:** €115 includes cover screw, temporary abutment/transfer  
**RePlus®:** €130 includes cover screw & "snappy" abutment/transfer  
**ReActive™:** €145 includes cover screw & preparable abutment/transfer

### Micro-Threads

Reduce crestal stress for improved initial stability

### Coronal Bevel on RePlus & ReActive

Allows for use of platform switching technology

### Titanium Alloy

Offers superior strength to pure titanium

## RePlant®

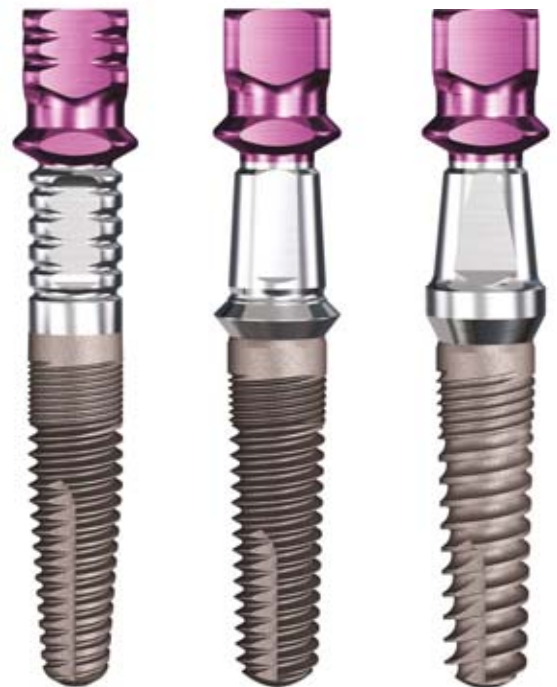Body Dimensions match NobelReplace™

## RePlus®

Body Taper for Bone Expansion

## ReActive™

Buttress Threads for Increased Surface



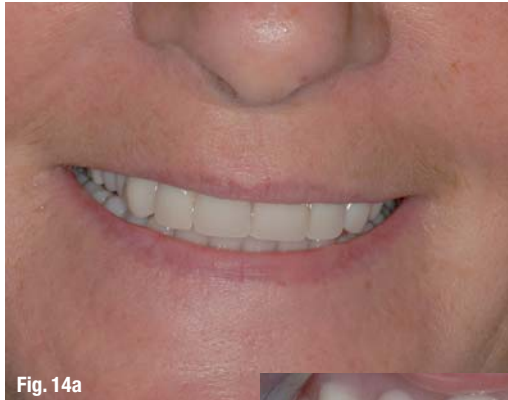

Fig. 14a

serts correct any processing errors. It must not be used in a two-implant situation.

Several studies have shown that conventional bar- and clip-retained overdentures transfer significant stress to the supporting peri-implant tissues (mainly bone).<sup>9-11</sup> The key to the SFI-Bar system is that the bar is assembled in the patient's mouth without the use of soldering, laser welding or conventional bonding techniques, thus reducing stress transmission to and bone loss around the implants. Studies have demonstrated that any laboratory-based technique that requires a master cast made from a dental impression will result in a bar that is not truly passive.<sup>8,9</sup> As a result, several authors have suggested that the only way to achieve a passive fit would be to assemble the framework intra-orally and then bond the bridge pontic in place.<sup>12,13</sup> This is the method employed with this system.

There is no casting, soldering, laser welding or bonding of components when fabricating the definitive bar. This, combined with the universal ball-joint nature of the components, ensures a true passive fit when the bar is assembled. The finite element analysis clearly shows the stress-free nature of the bar when being assembled and when the prosthesis experiences loading (Figs. 2a-c).

No laboratory time is required to fabricate the bar and there are no costly implant components or gold-alloy charges. Clinically, there is no need for the bar sections to be soldered in an attempt to achieve passive fit—a step that may need repeating—as with the conventional method.

There are no soldered or laser-welded joints, so the bar assembly has no inherent weak points that may fracture or corrode. The bar is assembled by the clinician, who also attaches the E clip intra-orally. The reduced number of clinical appointments, lab-

oratory time and component costs result in reduced treatment costs for the patient. In the case presented, for example, the bar assembly was completed in only six minutes. This is approximately the same time it takes for a polyether impression material (like Impregum) to set!

## Conclusion

The SFI-Bar is relatively inexpensive compared with conventional gold castings and CAD/CAM options. The overall cost of the prosthesis and treatment time are significantly reduced compared with conventional and CAD/CAM techniques. Precision-milled components provide an improved quality of fit.

The physical and mechanical properties of the component materials can be controlled accurately, which is difficult to achieve with conventional casting methods. The SFI-Bar can be connected to two or more implants to create a full-arch bar if needed, while the SFI-Bar system produces a bar assembly that seats passively as demonstrated by finite element analysis. The passive-fit bar assembly can result in greatly reduced stress transmission to the supporting implants. Studies have demonstrated that this is also a viable treatment option for immediate-loading situations in the mandible, provided that the implants achieved insertion torques exceeding 50 Ncm approximately.

*The finite element data and images were kindly provided by Dr Ludger Keilig, Endowed Chair of Oral Technologies, University of Bonn, Germany.*

*Disclaimer: The SFI-Bar, implant adapters and E clips were provided by Cendres+Métaux. The author did not receive any financial inducements to write this article or payment towards laboratory charges, nor was any other kind of payment given or received.*

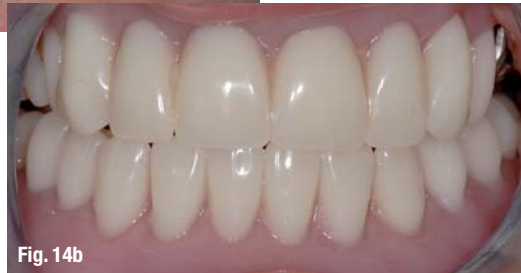

Fig. 14b

## contact

## implants

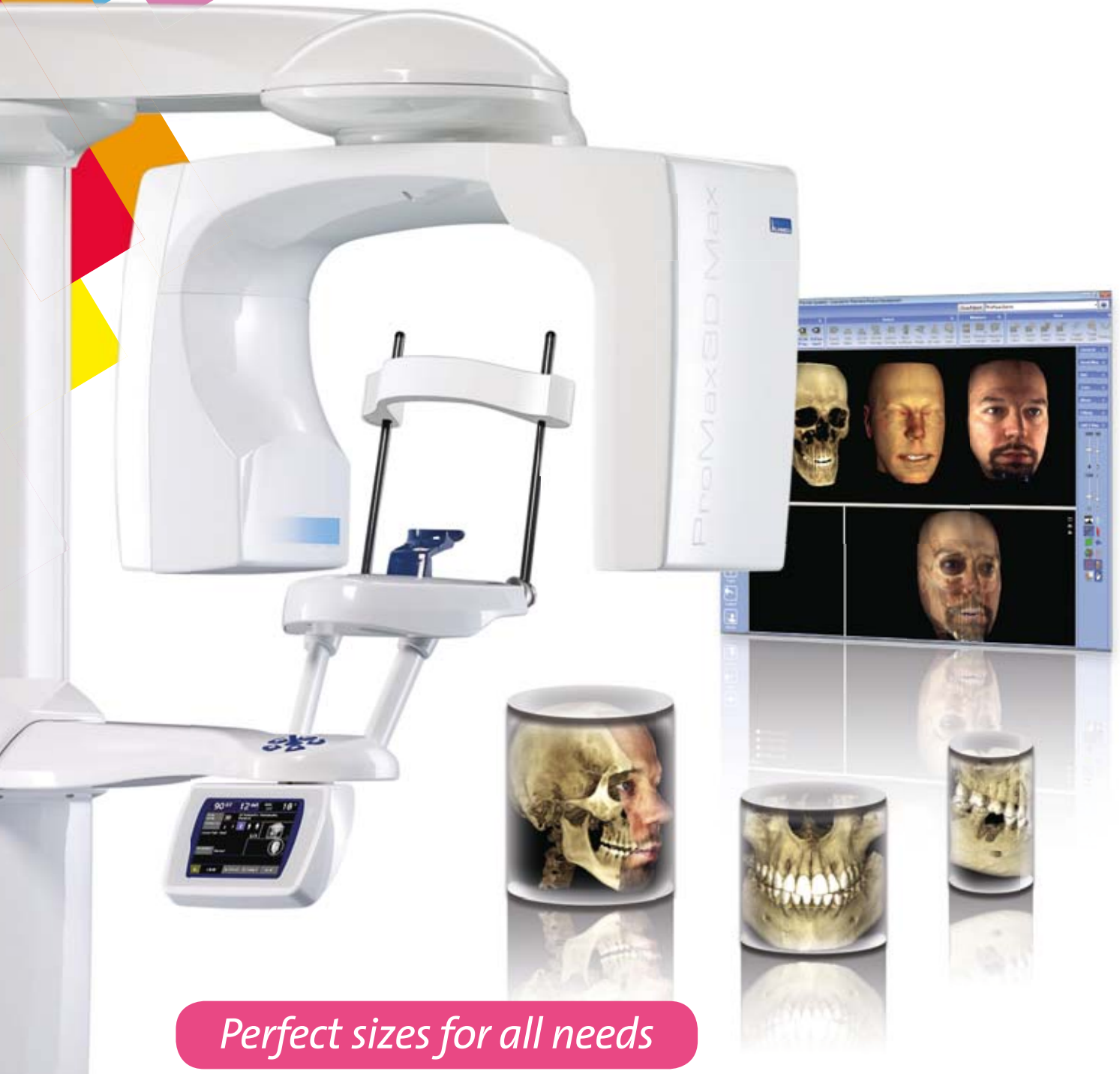### Dr Tussavir Tambra

BDS, DDS, MS Prosthodontics (Michigan)  
Wolverhampton, United Kingdom

dr.tambra@hotmail.co.uk

# Planmeca ProMax<sup>®</sup> 3D

*Unique product family*



*Perfect sizes for all needs*

*3D X-ray • 3D photo • panoramic • cephalometric*

*Romexis<sup>®</sup> software completes 3D perfection*



**Digital perfection™**

More information

[www.planmeca.com](http://www.planmeca.com)

Planmeca Oy  
Asentajankatu 6, 00880 Helsinki, Finland  
tel. +358 20 7795 500, fax +358 20 7795 555  
sales@planmeca.com

**PLANMECA**

# Restoration of **implant supported crowns**

## Uncommon problems and their solutions

Author\_Dr Igor Cernavin, Australia



[PICTURE: ©LEEDSN]

### Introduction

More than 40 years of experience have shown osseointegrated implants to be a highly predictable treatment modality, with unsuitable implant designs having been recognised and abandoned and risk factors for failure identified. Nevertheless, the author feels that in spite of having restored a significant number of implant-supported crowns, problems arise that are unexpected and not well recognised, often requiring considerable effort in arriving at a diagnosis and a solution. Below are a series of case reports presenting problems that the author has encountered over the years, among either his own patients or patients referred by general dental practitioners who

encountered such problems and were not able to solve them.

### Varying diameter of healing abutment and impression coping

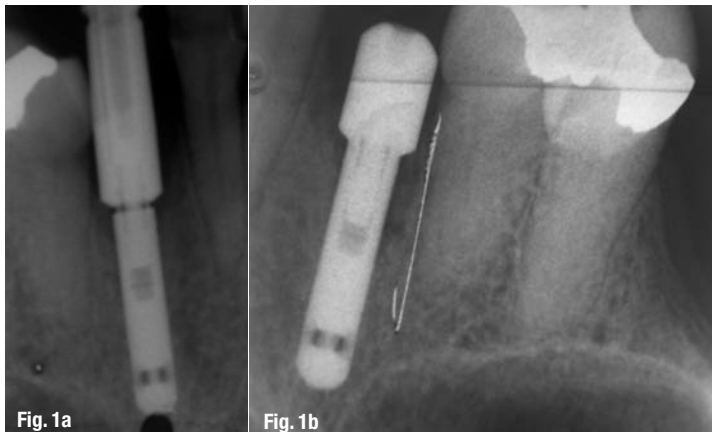
When this occurs and the impression coping is narrower than the healing abutment, there is no problem, but if the impression coping is wider than the healing abutment, bone may prevent the seating of the impression coping, and whilst clinically the impression coping may feel right, it is not and the subsequent crown/abutment will loosen (Fig. 1).

The author recommends that a radiograph always be taken to ensure that the impression coping is seated correctly. The radiograph should be taken using the bisecting technique, since if the beam does not pass through the joint between the impression coping and the implant, the coping may appear to be seated when in fact this may not be the case.

### Direct-to-fixture crowns

Direct-to-fixture crowns are a good way of restoring implants if the fixture is in an ideal position. However, in cases, especially in the molar region and for single units, in which the crown – fixture ratio is too great, the forces acting on the crown can lead to screw loosening. In such cases, it would be more prudent to use an

**Figs. 1a & b** Impression coping can impinge on bone.





abutment and then attach the crown to the abutment with a cross pin or in some other removable fashion. The abutment will alter the crown-root ratio significantly, thereby decreasing the forces on the abutment screw and decreasing the likelihood of the abutment screw loosening. Retrievability, using a cross pin or other method, will facilitate access to the abutment screw should it loosen.

Figure 2 shows such a case in which the crown-root ratio is too large for a direct-to-fixture crown. This case has the added problem of a regular-diameter implant with a wide-diameter crown, which would tend to increase the possibility of the screw loosening further. A wide-diameter implant would probably have been better here.

### Componentry mismatch?

The case presented in Figure 3 is very unusual. A radiograph was taken to verify seating of the impression coping and it was observed that the coping was seated halfway down the external hex and could be placed no farther (Fig. 3). It was clear from the radiograph that there was no bone or soft-tissue interference. Different impression copings were tried but the result was the same. The conclusion that the author finally reached

was that there must have been a mismatch between the diameter of the external hex on the fixture and the diameter of the impression coping. Once this concept was accepted, a laboratory impression coping was fabricated to allow for this and the coping seated correctly, with treatment proceeding uneventfully. The crowns have been in place for many years with no problems.

A mismatch in diameter between the external hex of the fixture and the diameter of the impression coping appears to be the only explanation for these cases. However, the author would be interested in other explanations.

### Implants and bisphosphonates

In the past, it was understood that there was a problem with the use of bisphosphonates and alveolar bone. A patient taking Fosamax was referred for implant replacement of the missing tooth #11. The fixture was placed by a periodontist, and after a suitable waiting period was restored by the author. All procedures were routine and uneventful, and the patient was pleased with the result. About one year after the crown had been placed, the patient rang, saying that the "implant had moved". This generally indicates that either the fixture has failed or the abutment or crown has loosened. The

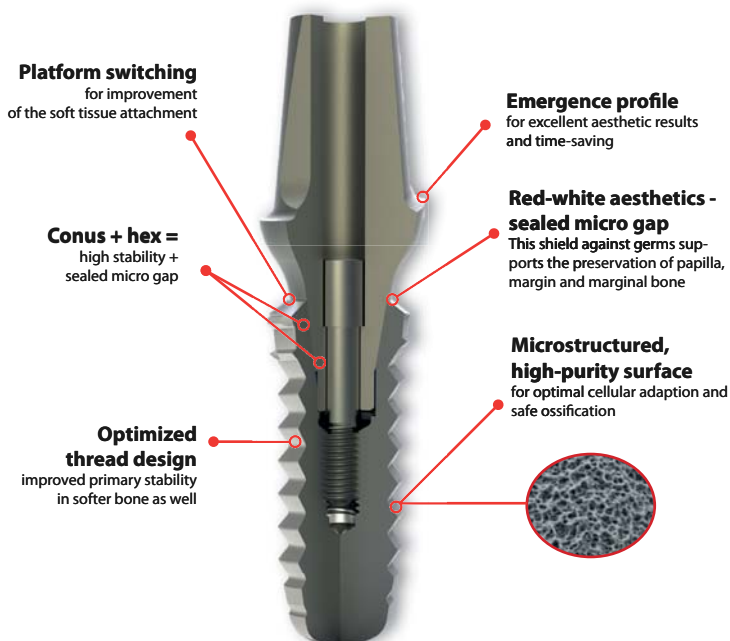
AD



**YOUR ADVANTAGE! THE 2 IN 1 CONCEPT:**  
Conical connection - with anti-rotation hex!

**DEALERS  
WANTED!**

#### The new IMPLA hybrid connection



### Special Promotion for your start into the IMPLA system:

**30 implants, abutments, gingiva formers, lab analogs, transfers and surgical kit!**

Promotion Code: P121154

#### Be ahead of your competition!

- » Wide range of trainings available for you and your team
- » Controlled German Quality
- » Great results + maximum security = satisfied customers

#### Call us today and become a partner.

For additional information visit our website:  
[www.schuetz-dental.com](http://www.schuetz-dental.com)

Scan me.



Sign up for the exclusive IMPLA Newsletter:  
<http://sdent.eu/newe>



**IMPLA**

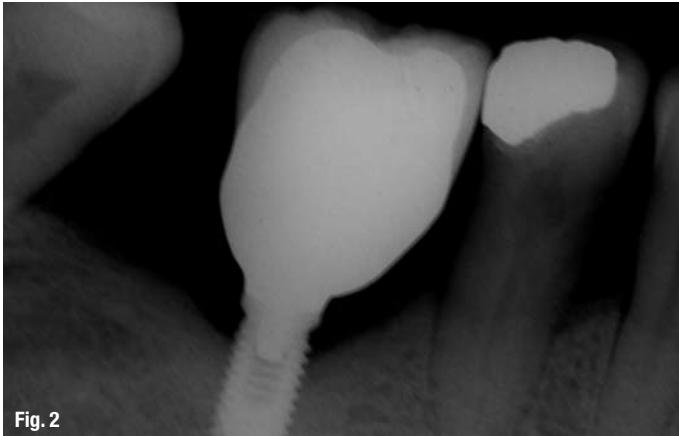


Fig. 2

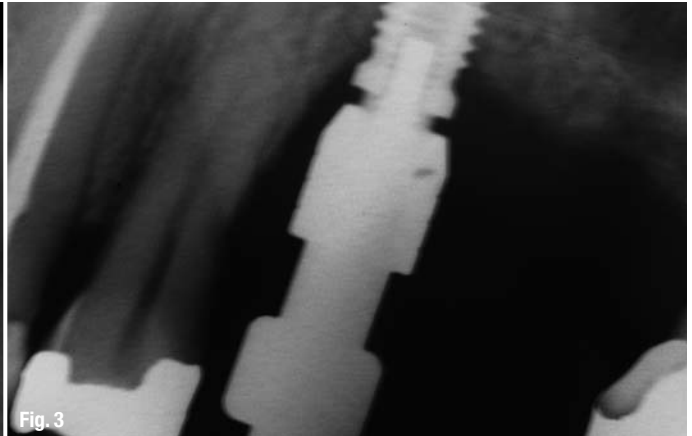


Fig. 3

**Fig. 2** Unfavourable crown root ratio for direct-to-fixture.

**Fig. 3** Mismatch in diameter between external hex of the fixture and the impression coping.

patient was examined and it was found that indeed the crown was now angled at approximately 30° labial to its original position (Fig. 4). Clinical and radiographic examination revealed that the fixture was sound, not tender to percussion and there was no probing depth. As the crown was retained with a cross pin, it was removed and it was found that the abutments screw was not loose. The crown was replaced and the patient agreed that she would leave things as they were to await further developments. The crown remained in place, symptom free, for a further six months, at which time the fixture exhibited clear clinical signs and symptoms of failure of integration, and was removed.

#### Fractured cross pins

Cross pins will rarely fracture, but when they do they usually fracture at the junction of the head and the body of the screw, thereby leaving the bulk of the screw holding the crown in place. Fortunately, the fracture mostly occurs after the cross pins have loosened and they can usually be unscrewed using a probe to catch the sharp edges, thereby removing the fractured portion of the screw and allowing removal of the crown and replacement of the screw with another. If the screw is not loose, carefully cutting the screw with a tungsten carbide bur, either cutting a slot and then unscrewing the screw or totally cutting the head of the screw until the crown can

be removed, is also possible but difficult to accomplish without damaging the crown.

#### Remarks

Implant-supported crowns and prostheses have been a tremendous boon to patients, allowing replacement of missing teeth without damaging adjacent teeth and placement of teeth in areas of the mouth where this would not otherwise have been possible; however, unusual and challenging situations are encountered that require considerable thought to obtain a solution.

**Fig. 4** Shifted implant retained crown.

**Fig. 5** Models comparing the original position of the fixture and the position of the implant retained crown after it had "shifted".

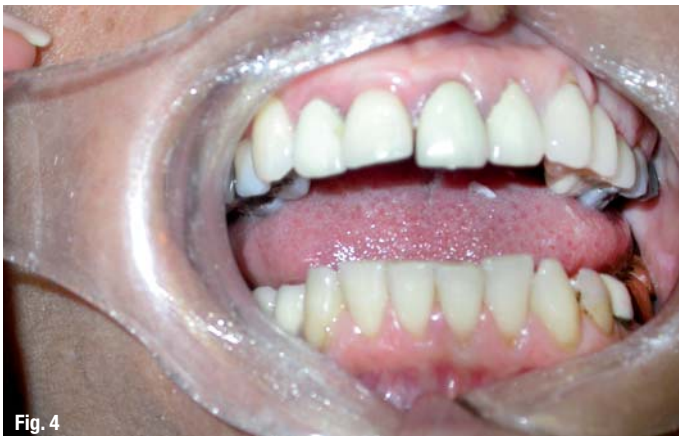

Fig. 4

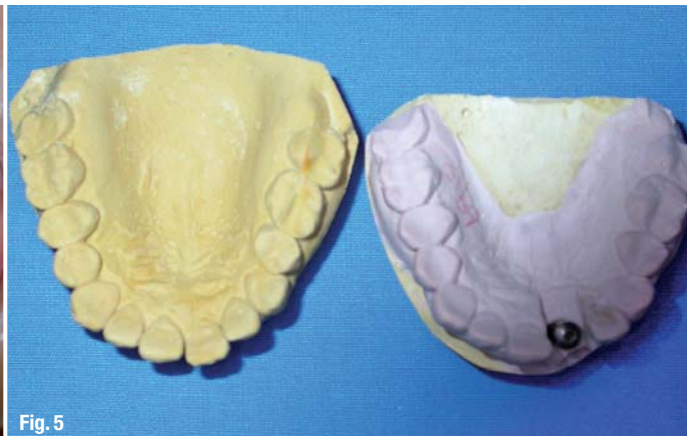

Fig. 5

<u>contact</u>	<b>implants</b>
<p><b>Dr Igor Cernavin</b>                  Prosthodontist, Honorary Senior Fellow                  Department of Restorative Dentistry, School of                  Dentistry, Faculty of Medicine, Dentistry and Health                  Sciences, University of Melbourne, Melbourne,                  Australia. Director of the Asia Pacific Institute of                  Dental Education and Research Pty Ltd.                  803 Malvern Road                  TOORAK, 3142, VIC, Australia</p> <p>Cernavin@unimelb.edu.au                  www.cernavin.com</p>	

# Celebrate the innovation of osseointegration with us.

Visit us at the Nobel Biocare Symposia 2012

March 21–23, Gothenburg

June 1–2, Avignon

June 9–11, Odessa

June 15–16, Hamburg

October 19–20, Rimini

October 19–20, Toronto

**SIGN UP NOW**

For more information and registration visit our website  
[nobelbiocare.com/symposia2012](http://nobelbiocare.com/symposia2012)

## **60 years since the discovery of osseointegration 30 years since the landmark conference in Toronto**

In 1952, Per-Ingvar Brånemark discovered the principles of osseointegration in Sweden. Thirty years later, in 1982, the discovery was acknowledged, and his subsequent findings confirmed at a landmark conference in Toronto. Yet another thirty years have passed, and Nobel Biocare will celebrate both these 60- and 30-year anniversaries in Sweden and Canada, as well as in France, Ukraine, Germany and Italy. Beginning in the hometown of osseointegration—Brånemark's Gothenburg—Nobel Biocare will gather some of the best-known names in the field to highlight how far Per-Ingvar Brånemark, together with Nobel Biocare and their supporters have brought the innovation of osseointegration. Scientific

and clinical experts from all over the world will exchange ideas and discuss promising areas for further exploration. The programs of all six Nobel Biocare Symposia 2012 will celebrate the origins and evolution of osseointegration as a practical and trusted treatment modality over the last six decades. Each program will also include lectures on recent advances in treatment, presented from surgical, prosthetic and laboratory perspectives. Speakers will look towards the future as well, presenting current trends and possible future developments for bone-anchored restorative dentistry.

**Join us and become a part of the next innovative chapter of osseointegration history.**

[nobelbiocare.com](http://nobelbiocare.com)



# Implantology in the atrophied alveolar ridge without augmentation

## Case study on the anterior maxilla

Author\_Prof Dr Frank Liebaug, Dr Ning Wu, Germany

### \_Introduction

In many cultures, a flawless set of teeth embodies vitality, health, youth and beauty. No wonder that, in all ages, ambitious dentists have strived for the provision of a perfect denture. Continuous research and the clinical monitoring of success rates have led to the triumph of modern implants. The possibility of a reliable and effective alloplastic root replacement opened up a variety of perspectives for a both functional and aesthetic rehabilitation after tooth loss (Esser 2010).

Implantological treatment concepts avoid the typical adverse effects of conventional prosthetic solutions. Due to their lack of bone resistance to pressure, mucosa-supported prosthetic solutions are often regarded as a compromise. Therefore, the risk of a profound atrophy of the Processus alveolaris and a consequential denture disability should be considered by any long-term therapy planning. This aspect

is of utmost importance in cases involving a premature loss of teeth.

However, implants are still rarely included in the prosthetic strategies of the general practice. Therefore, improved functionality and superior aesthetic rehabilitation are long-term possibilities yet not fully exploited. Instead, intact abutment teeth are often threatened by the reduction of the tooth structure and by overload.

As reported by numerous studies performed in the last two decades, implants have a certain protective effect which is based on the possibility of a physiological chewing force initiation in the bone, thus maintaining the alveolar bone. Today, these positive effects are important arguments for patients who are interested in implants. They can form a helpful support in the decision-making process when developing an individual prosthetic treatment plan. Moreover, implant procedures are now generally acknowledged

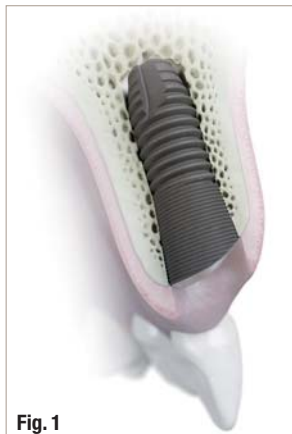

Fig. 1

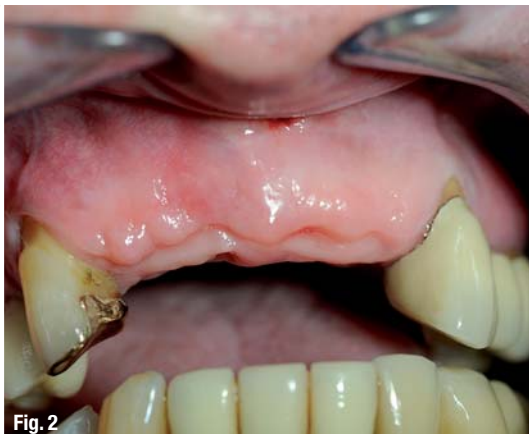

Fig. 2

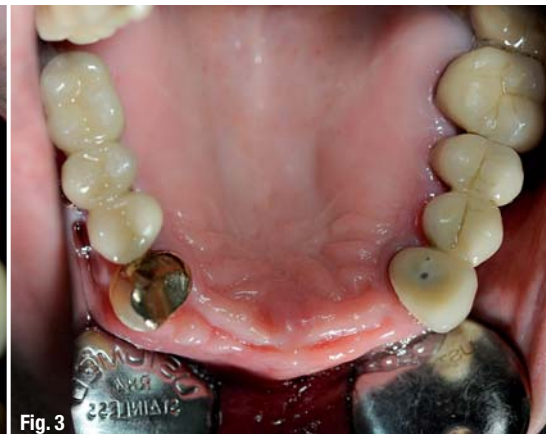

Fig. 3

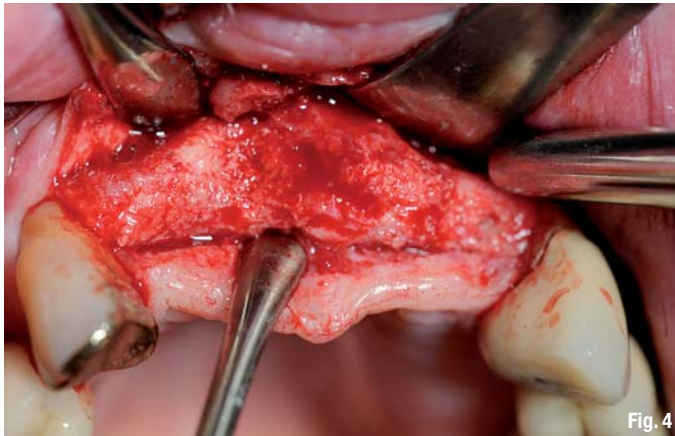


Fig. 4

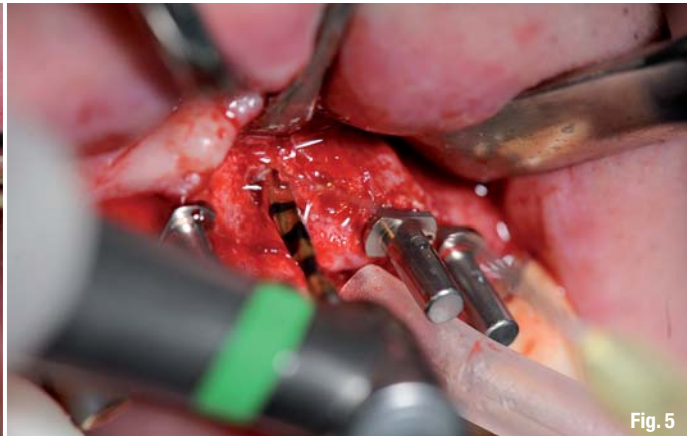


Fig. 5

as a safe treatment option. Nonetheless, researchers make great efforts to reduce the remaining deficits gathered from the data of long-term clinical studies.

### \_Tapered implants

Aesthetic restorations in the anterior maxilla require tapered implants with diameters designed as analogously to the teeth as possible, since the available apical space is often reduced. A sufficient diameter in the crestal region will permit a tooth-analogical profile. As a result, the existing bone material can be optimally exploited. However, dentists still come across the picture of a Processus alveolaris chamfered vestibularly, particularly in cases of pre-existing periodontal problems or tooth extractions performed a long time ago.

The retention of the peri-implant bone level is extremely important for an aesthetic, tooth-analogical reconstruction with implants. This measure is the only way for the peri-implant soft tissue to obtain sufficient osseous support and to avoid a collapse of the gingiva into the bone defect.

The newly-developed OsseoSpeed™ TX Profile Implant was modeled from nature. The resulting anatomically shaped and patented implant is de-

signed to maintain the marginal bone both vestibularly and orally, i.e. circularly around the implant, and especially in the case of a transversally atrophied alveolar ridge.

In order to ensure optimum treatment outcomes in this context, special attention was paid to features such as the MikroThread™ and OsseoSpeed™ surface, as well as the Conical Seal Design™ and the Connective Contour™, which have already proved their liability within the so-called AstraTech BioManagement Complex.

In order to achieve the best-possible treatment outcomes surgically, the surgical procedure must follow the standard protocol for implant placement. Only during the fine adjustment of the implant position is it mandatory that the vestibular chamfered edge of the implant ends precisely with the vestibular bone lamella. This can be ensured with the help of a specially marked insertion device (Fig. 1).

### \_Case report

The following case report illustrates the most important steps of the implant placement. The general medical and internal case histories of the 65-years-old patient were unremarkable. His tendency towards

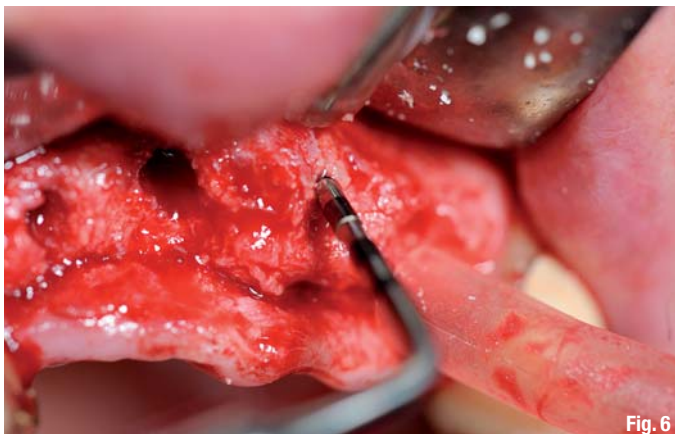


Fig. 6

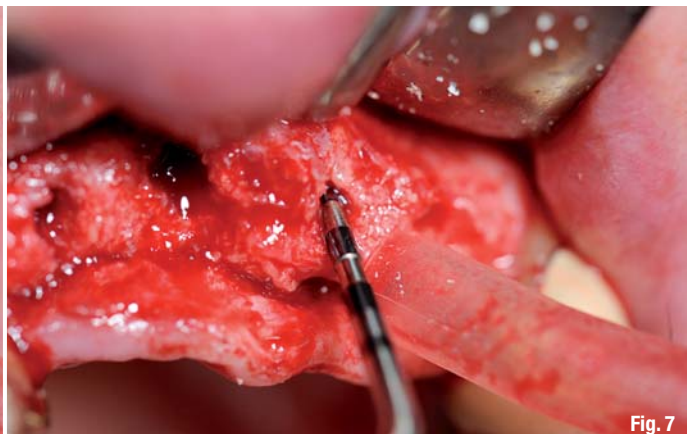
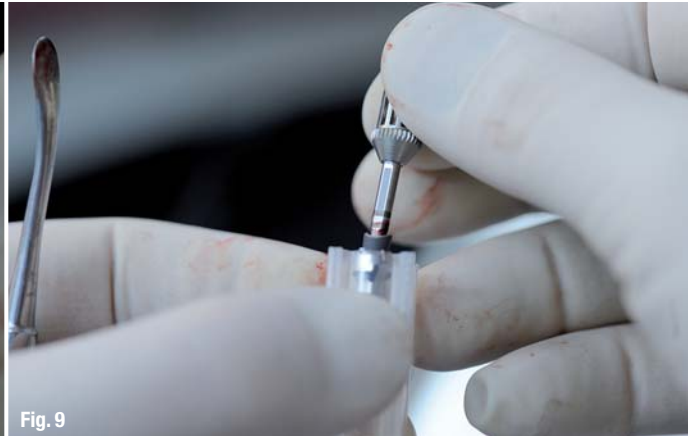
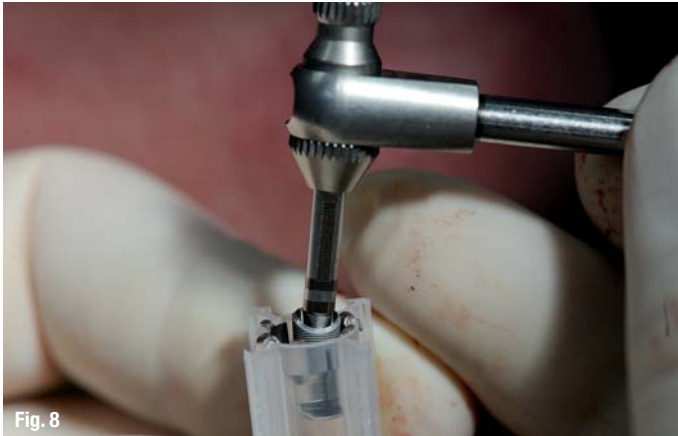
Fig. 7

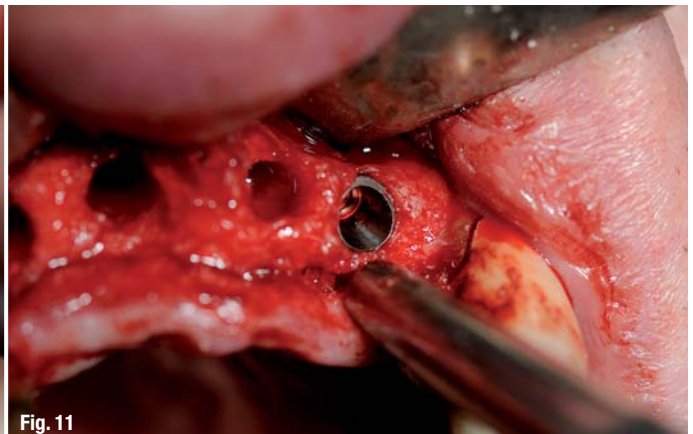
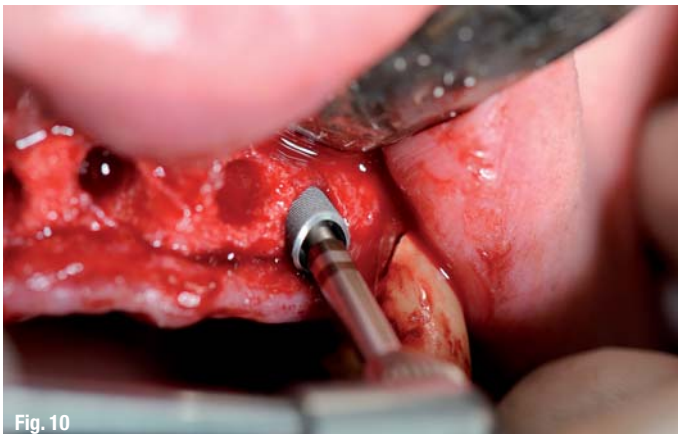

chronic marginal periodontitis was well controlled by a systematic periodontal treatment. Only the anterior teeth #12, 11, 21 and 22 had not been preserved prior to the medical intervention.

In principle, this procedure can be initially performed by machine and according to the dentist's individual preferences. However, the final position must by all means be adjusted manually.

Figures 2 and 3 illustrate the clinical situation prior to the implantological restoration of the edentulous space of teeth #12 to 22, approximately only four and a half months after the tooth extraction due to severe periodontal pre-damages. A transversally atrophied Processus alveolaris appeared after the formation of the mucoperiosteal flap and the opening of the surgical area, featuring an alveolar ridge width sufficient for implants of a diameter of 4.5 mm (Fig. 4). The verification and marking of the implant position are followed by the successive preparation of the cavities according to the well-known surgical protocol. Paralleling pins or paralleling tools can be applied to support the process already during pilot drilling in order to find an optimum axial direction and position (Fig. 5). Figures 6 and 7 demonstrate the problems of the transversally atrophied Processus alveolaris: The depth gauge in the implant cavity clearly depicts the measurable difference in the levels of the vestibular and the oral Pars compacta, amounting to approximately 1.5 mm. The implants are inserted as soon as the conditioning of the implant bed with regard to the diameter has been completed.

The OsseoSpeed™ TX Profile implant is removed from the sterile wrapping with the help of an implant driver. During the removal, a corresponding color marking must be adapted to the chamfered side of the implant (Figs. 8 & 9). Figure 10 shows how the fine adjustment of the implant position must be performed manually by means of a surgical ratchet wrench connected to handle. In this way, the dentist can determine the optimal final implant positioning accurately within a fraction of a millimeter (Fig. 11). The adjustment of the implant to a position most suitably adapted to the anatomical structures must therefore be realized by the application of light finger force. Visual control from the optimum position shows the flush transition of the inserted OsseoSpeed™ TX Profile implant to the adjacent bone of the slightly slanting alveolar process (Fig. 12). When this key position is achieved, the procedure can be continued according to the surgical standard protocol. Precisely configured closure screws were developed for this specific implant design. They are taken from a blister in a sterile manner (Fig. 13). Figure 14 depicts an implant shoulder adjusted to the anatomical structures with-



# ADVANCED TISSUE-MANAGEMENT

## The easy way to aesthetics.

PARASORB Sombrero®

RESODONT®

PARASORB® HD Cone

GENTA-COLL® HD Cone



### RESODONT®

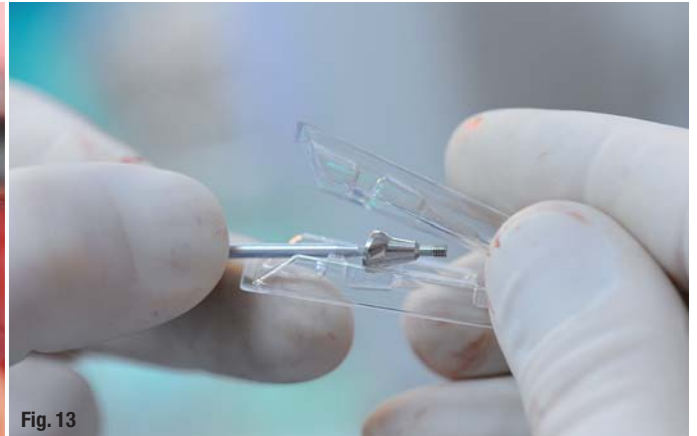
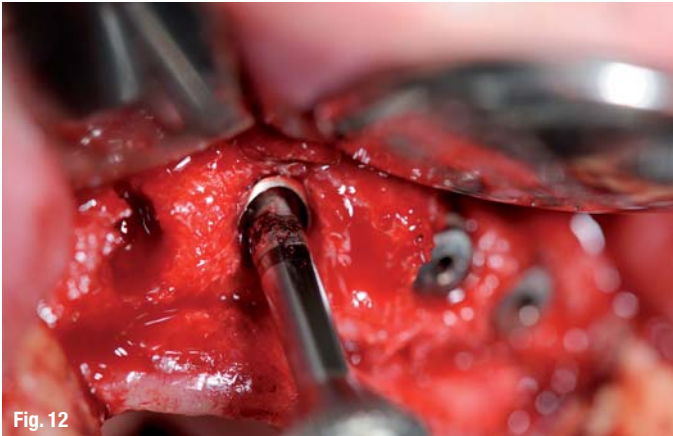
- ▶ naturally cross-linked, with no chemical additives
- ▶ quick and easy to cut to size and apply, both sides can be used
- ▶ rapid integration in the surrounding tissue
- ▶ highest degree of product safety and excellent biocompatibility

### PARASORB Sombrero®

- ▶ to cover and simultaneously fill the alveolus (socket preservation)
- ▶ offers a defined regeneration matrix
- ▶ formation of a stable bony implant bed after a relatively short time
- ▶ improved long-term aesthetic and functional results particularly in the anterior region

### PARASORB® HD Cone GENTA-COLL® HD Cone

- ▶ rapid and safe haemostasis
- ▶ reduction of alveolar ridge atrophy
- ▶ optionally comes with antibiotic protection for high-risk patients (e.g. diabetics, smokers, immune-suppressed patients)



outexposed implant surface. Thus, a complete circular support of the marginal bone after the insertion of the four anterior tooth implants regio 12, 11, 21 and 22 can be achieved. Augmentation is therefore not required after the insertion of the implants, but a primary wound closure is possible. In the present case, the provisional interim restoration was ensured by a removable denture. The subsequent healing process was clinically unremarkable and without any signs of irritation.

### Summary

This innovative implant design can be regarded as an indicator for future developments. It is particularly promising for an application in the transversally atrophied Processus alveolaris (vestibular). The tapered OsseoSpeed™ TX Profile implant has successfully closed a therapeutic gap, achieving valuable long-term outcomes without any need for additional augmentative procedures. This unique implant furthermore puts an end to the all too common compromise between the retention of the marginal bone level on the one hand and the achievement of attractive aesthetics in cases involving transversally atrophied alveolar ridges on the other. In addition, the implant's design makes it much easier to preserve the three-dimensional bony structure around the implant in ac-

cordance with the natural model. The retention of the marginal bone, both vestibularly and orally, also has positive effects on the approximal bone level and can support the natural aesthetics of the soft tissues. According to Prof Dr Dr Wagner, the implant design matches with the anatomy of the alveolar ridge rather than the Processus alveolaris adjusting to the implant. Therefore, the above-described implant is particularly suitable for an insertion into the aesthetic zone. However, due to the chamfered implant design, AstraTech recommends that this product initially only be utilized by dentists and surgeons who have extensive experience in the field of implant dentistry.

*Editorial note: A list of references is available from the author. First printed in DENT IMPLANTOL 15, 6, 382–387 (2011).*

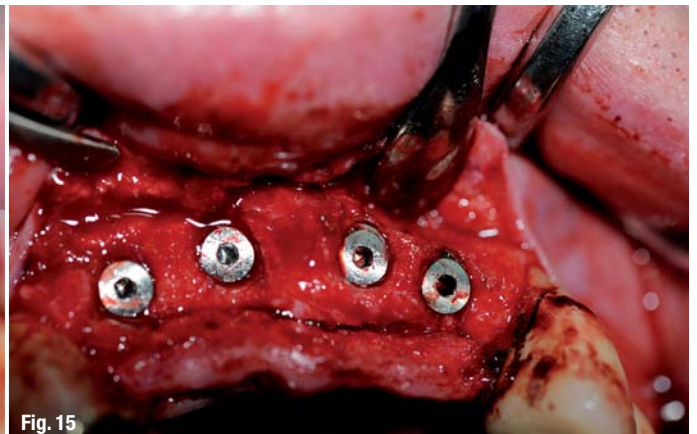
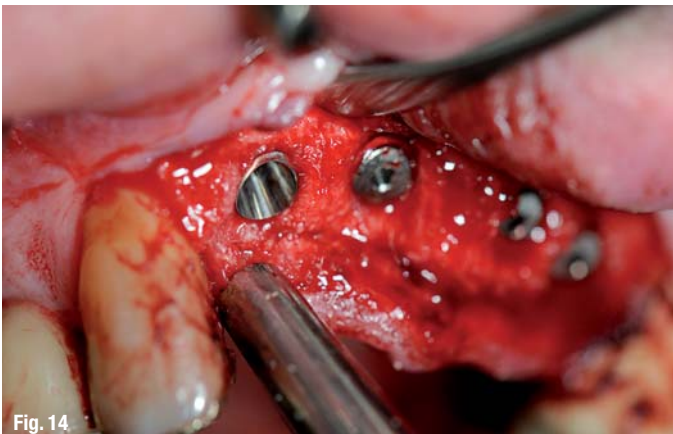
### contact

### implants

**Prof (Univ. Shandong) Dr med Frank Liebaug**

Arzbergstraße 30  
98587 Steinbach-Hallenberg, Germany  
Tel.: +49 36847 31788

frankliebaug@hotmail.com







## PERFECT FIT BY DESIGN

In combining Soft Tissue and Bone Level implants with a comprehensive prosthetic portfolio, Straumann has devised one system for all indications. The **Straumann® Dental Implant System** – excellent product quality designed for convincing, naturally esthetic outcomes.



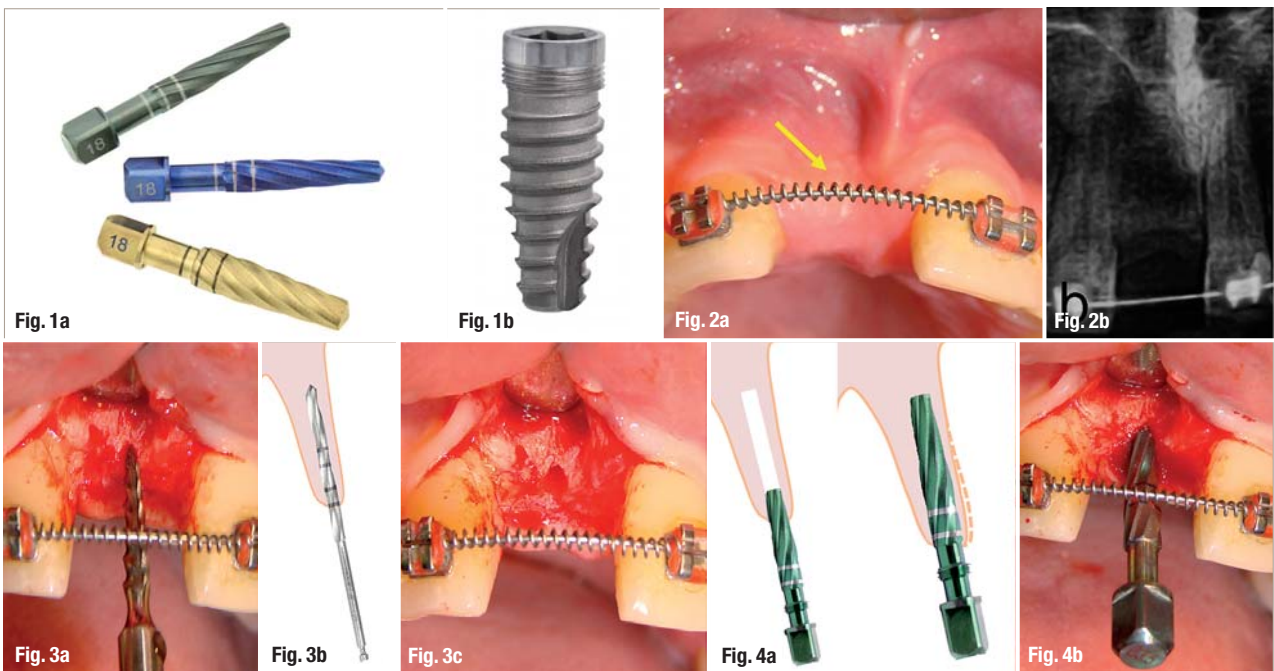
Featuring the  
SLActive® surface!

More information on [www.straumann.com](http://www.straumann.com)

COMMITTED TO  
**SIMPLY DOING MORE**  
FOR DENTAL PROFESSIONALS

# Bone expansion in one surgical step

Author\_Prof Sergio Alexandre Gehrke, Bruno Konig Jr., Brazil, & Giovanni Wiel Marin, Italy



**Figs. 1a & b\_** The countersinks (expanders) of the bone (a) and the conical implant (b).  
**Figs. 2a & b\_** Sinking of the bone (yellow arrow) before the surgery (a) and the radiograph thereof (b).  
**Fig. 3a-c\_** Bed preparation with a lance-shaped drill until planned depth was reached.  
**Fig. 4a & b\_** Sequence using the 3.5 mm expander.

## Introduction

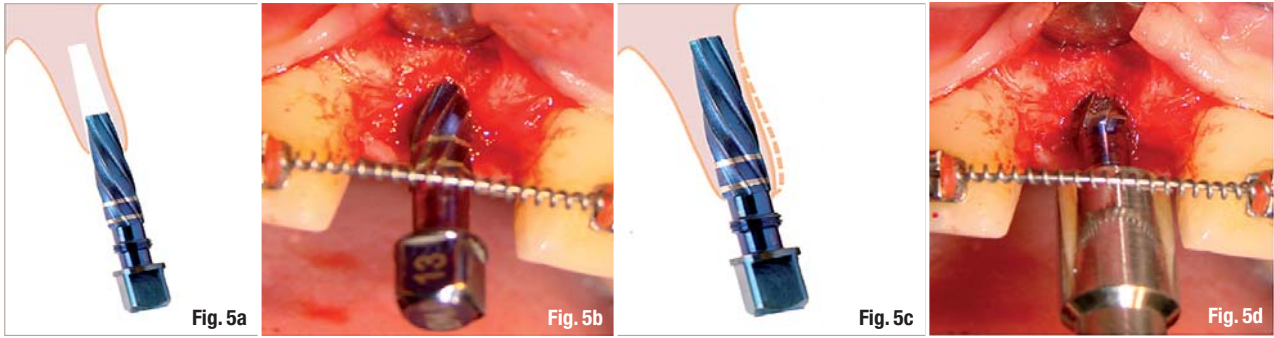
Tooth extraction changes the height and thickness of the alveolar bone significantly, especially when tooth loss is the result of dental trauma, periodontal involvement, or when the vestibular wall is lost during extraction.<sup>1</sup> Bone deficiencies may hamper or prevent the use of dental implants owing to insufficient bone volume for holding implants of an appropriate size<sup>2,3</sup> or in aesthetic areas, hampering an adequate treatment of the case.<sup>4</sup> To correct this situation, various surgical procedures have been proposed. Bone grafts,<sup>5</sup> membranes for guided bone regeneration<sup>6</sup> and a combination of both of these techniques<sup>7</sup> have been used to increase bone volume.

Even though there is ample documentation on the success of bone grafts and membranes in terms of the number of cases and follow-up after the placement of

implants in grafted areas, these procedures have some disadvantages, such as the need for extra-oral or intra-oral bone, increased morbidity, risk of exposure and infection of the graft or membrane, and an unpredictable rate of bone resorption after implant placement.<sup>8,9</sup> Thus, surgical alveolar ridge expansion was proposed as an alternative in order to allow the placement of implants.<sup>10</sup> With the aid of hand tools, a longitudinal fracture is performed in the atrophic ridge, dividing it into two parts and thereby increasing its thickness for implant placement. Through the presentation of clinical cases, this article aims to demonstrate and evaluate a simple technique for increasing the bone volume in narrowed areas with the use of conical implants and bone expanders.

## Materials and methods

Two patients with missing teeth in different regions of the maxilla were selected. These patients, besides



**Fig. 5a–d** Sequence using the 4.0 mm expander.

meeting all the requirements concerning their general health, also exhibited the conditions necessary for the technique of bone expansion. The materials selected were countersinks and conical implants (Implacil De Bortoli; Figs. 1a & b). The design of the countersink must be appropriate to expand the design of the implant.

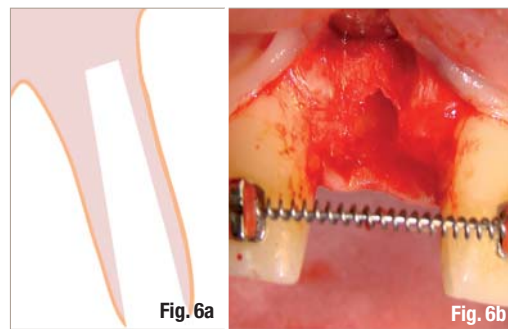
lowed in order to expand the vestibular wall of the alveolus. The green colour corresponds to the countersink for a 3.5 mm conical implant (Fig. 4) and the blue to a 4 mm conical implant (Fig. 5). After this sequence, the site was finished (Fig. 6), an internal conical implant of 4.0 x 11 mm was inserted in the place of tooth #11

### Case presentation

#### Case I

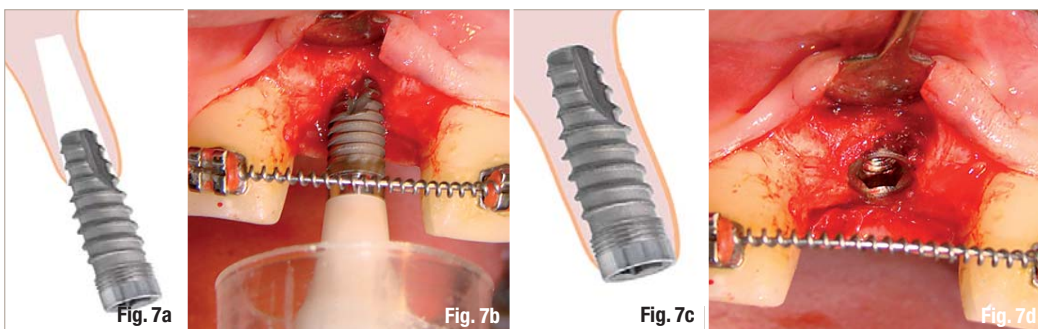
A 21-year-old male patient presented to the clinic (Bioface Cirurgia Oral e Maxilofacial) for the replacement of tooth #11 with an implant. After a detailed anamnesis, it was found that the patient had no systemic involvement. From the clinical and radiographic examinations, we were able to verify the necessary conditions for the realisation of the expansion technique, followed by the immediate placement of the implant (Figs. 2a & b).

After obtaining consent to the proposed treatment plan, treatment was begun. After the initial perforation with a 2 mm drill, establishing the position and depth of the implant (Fig. 3), the countersink sequence was fol-



**Fig. 6a & b** Prepared bed showing vestibular wall expansion.

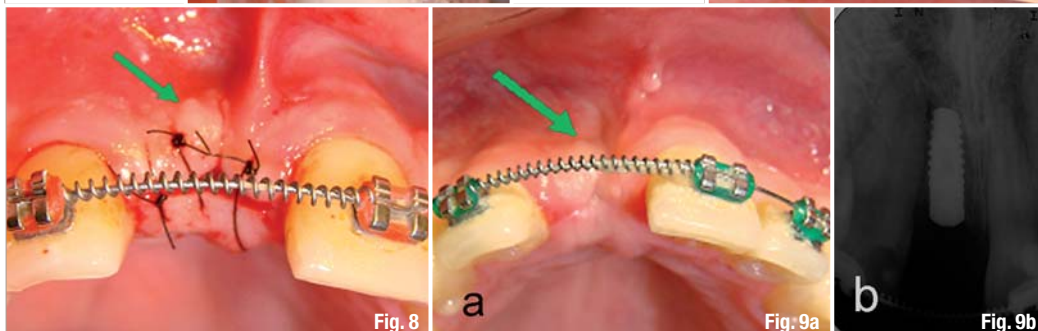
(Fig. 7) and the site was sutured (Fig. 8). A prescription of 875 mg amoxicillin to be taken two hours before the procedure was given to the patient as preventive medication. He was also instructed to take the same amount of amoxicillin twice a day for five days to prevent post-operative infection, as well as 100 mg of the anti-in-

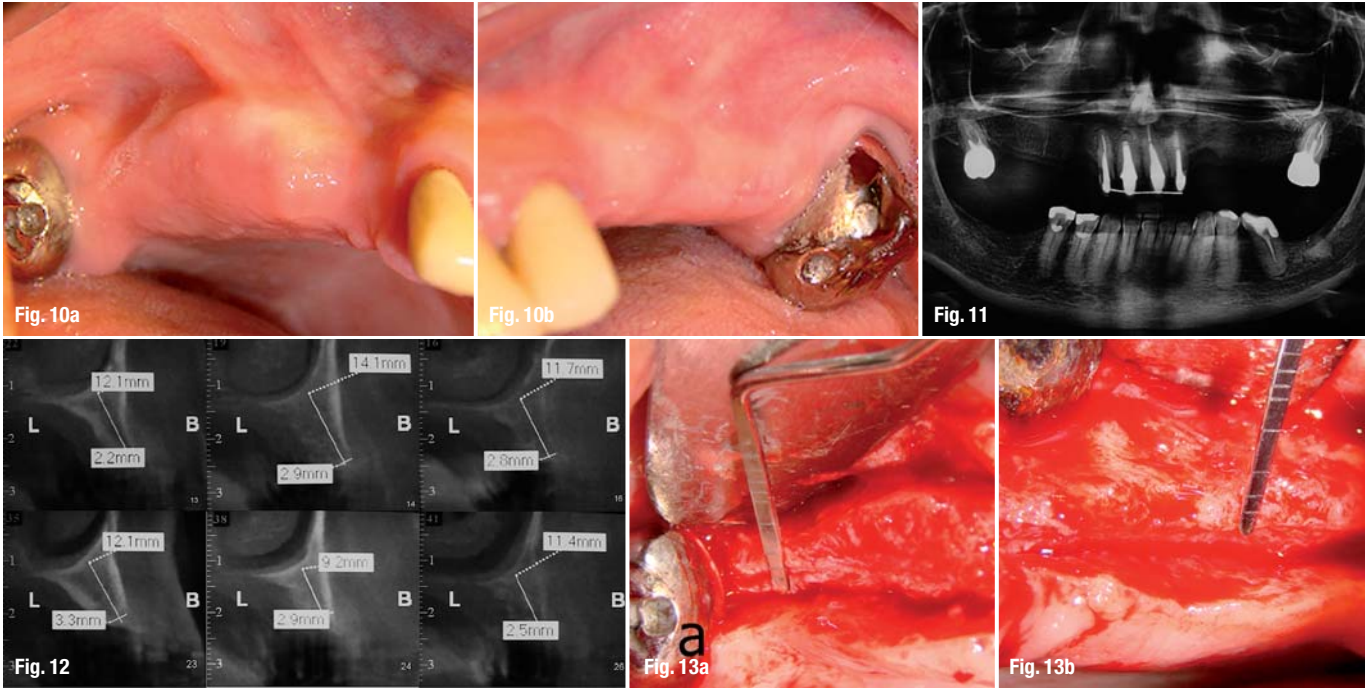


**Fig. 7a–d** Placement of the implant with the same conical form of the instrument.

**Fig. 8** After suturing, an increase in the volume of gingival mucosa was detected (green arrow).

**Figs. 9a & b** Clinical (a) and radiographic control (b) after ten days. An increase in the volume of gingival mucosa was detected (green arrow).





**Fig. 10a & b**\_Clinical bilateral view of initial situation.

**Fig. 11**\_Panoramic radiograph of initial situation.

**Fig. 12**\_Tomograph of initial situation at each site.

**Fig. 13a & b**\_Detachment of the mucosa and preparation of the implant bed, using countersinks to expand the bone area, resulting in an increase in volume.

**Fig. 14a & b**\_Appearance of the implants immediately post-placement.

**Figs. 15a & b**\_View of the mucosa (a) and radiographic control (b) three months after the surgery.

flamatory Profenid every 12 hours for three days post-operatively to control pain and prevent inflammation. In addition, rising twice a day with a 0.12% chlorhexidine mild mouthwash was recommended. Post-operatively, the implant was followed clinically and radiographically and no abnormality was detected after ten days (Figs. 9a & b).

*Case II*

A 61-year-old female patient presented to the clinic. Examination showed that bilateral tooth replacement was needed for teeth #13 to 16 and 23 to 26. After a detailed anamnesis, it was concluded that the patient had no systematic problems. After clinical (Fig. 10) and radiographic (Fig. 11 & 12) examination, the necessary conditions for the expansion technique and immediate

placement of the implants were established as with the previous case.

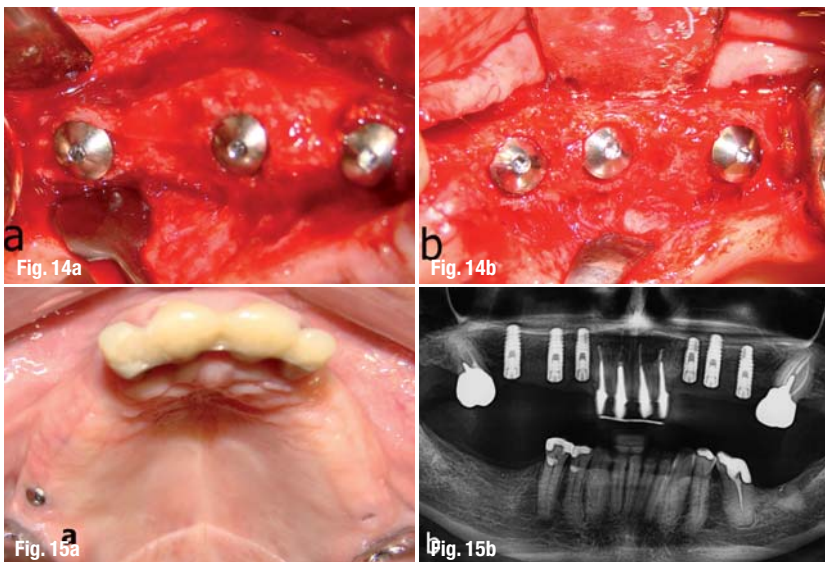
The small volume of bone was confirmed after the opening of the mucosal (Fig. 13). Six internal conical implants, measuring 4.0 mm in diameter and of different lengths, were inserted (Fig. 14) and sutured. Post-operative prescription and care were the same as with Case I. Clinical and radiographic control followed post-operatively and after one month (Figs. 15a & b), showing good results. In both cases, the tomographic measurements after placement of the implant were used to measure and evaluate the expansion volume during surgery.

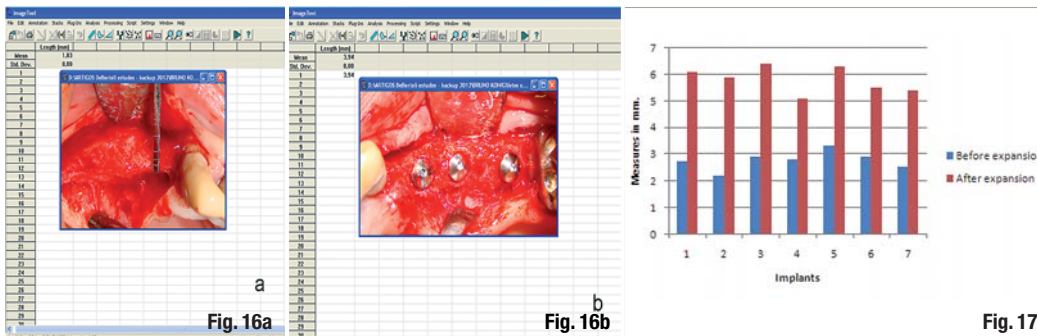
**\_Results**

The volume of the bone regions that received the implants was measured prior to the expansion. The probing depth in millimetres at the flange was used for calibration and measurement around the implantation area (Fig. 16a) and confirmed with the tomographic measurements. After implant placement, these were used for calibration before the final measurement (Fig. 16b). Measurements were done using the Image Tool (version 3.0) for Windows (Microsoft), and the results are shown in Table I and Figure 17.

**\_Discussion**

This paper presents a relatively simple technique for placing implants in regions with insufficient bone tissue, with the use of expanders to obtain an increase in bone volume. There have been fewer studies on the surgical expansion of the bed margin than studies on the





**Figs. 16a & b** Program, during calibration, used to measure the bone volume before (a) and after the expansion (b).  
**Fig. 17** Diagram comparing the measurements before and after the expansion.

use of surgical techniques for the same purpose.<sup>11-14</sup> Our technique offers some advantages over other techniques, such as being less invasive, requiring a shorter rehabilitation time and being of lower cost when compared with the costs of bone grafts and membranes. This technique should be applied only when the vestibular and lingual/palatal walls are separated by bone marrow<sup>2,15,16</sup> and when the base of the defect is greater than the bone crest at the border.<sup>17</sup>

Evaluation showed an average increase of  $113.3 \pm 29.6\%$  when compared with the volume of the bone before surgery. In the literature, there is no information regarding the amount of expansion needed to allow implant placement. There are also only a few studies that evaluate the increase in bone thickness after expansion of an atrophic alveolar ridge.<sup>2, 8, 16</sup> Thus, it is recommended that more studies be conducted to investigate these aspects more accurately. Most reports focus on the maxilla. A probable reason for this might be researchers' preference for examining bone of low density. The technique reported on in this article can be said to be safe and to furnish predictable results. Very few complications have been reported,<sup>17</sup> but care must be taken not to create excessive expansion, leading to a fracture of the vestibular wall. In this case, it would be impossible to stabilise the implant. In a histological study evaluating the new bone formed in expanded areas, high osteogenic activity was revealed.<sup>10</sup> The authors mention important details that determine these conditions: the space created undergoes spontaneous ossifi-

cation and the newly formed bone enables the consolidation of the palate and the vestibular wall. This procedure enables bone formation in an optimally expanded space.

### Conclusion

We conclude that the range of materials available on the market offers new alternatives with many advantages for the professional and the patient. The use of these materials can facilitate the placement of implants in areas of insufficient bone thickness, avoiding the need for regenerative procedures prior to and/or simultaneous with the implantation, and thereby reducing costs and treatment time. Further studies are necessary to assess these materials.

*Editorial note: A complete list of references is available from the publisher.*

\_contact
implants

**Prof Sergio Alexandre Gehrke**  
 Rua Bozano, 571  
 Santa Maria – RS  
 97015-001  
 Brazil

Tel.: +55 55 3222 7253  
 sergio.gehrke@hotmail.com

Case/Area	Volume	Final volume	Increase	Gain (%)
I/11	2.7	6.1	3.4	125.9%
II/13	2.2	5.9	3.7	168.1%
II/14	2.9	6.4	3.5	120.6%
II/16	2.8	5.1	2.3	82.1%
II/23	3.3	6.3	3.0	90.9%
II/24	2.9	5.5	2.6	89.6%
II/26	2.5	5.4	2.9	116.0%
Average/SD	$2.7 \pm 0.345$	$5.8 \pm 0.491$	$3.0 \pm 0.506$	$113.3 \pm 29.6\%$

**Table I** Values and averages obtained after measurement with Image Tool.

# Screwed versus cemented immediately functionally loaded implants

## A five-year prospective analysis

Author\_Dr Luca Di Alberti<sup>1</sup>, Prof Dario Bertossi<sup>2</sup>, Prof Lorenzo Lo Muzio<sup>1</sup> & Prof Pierfrancesco Nocini<sup>2</sup>, Italy

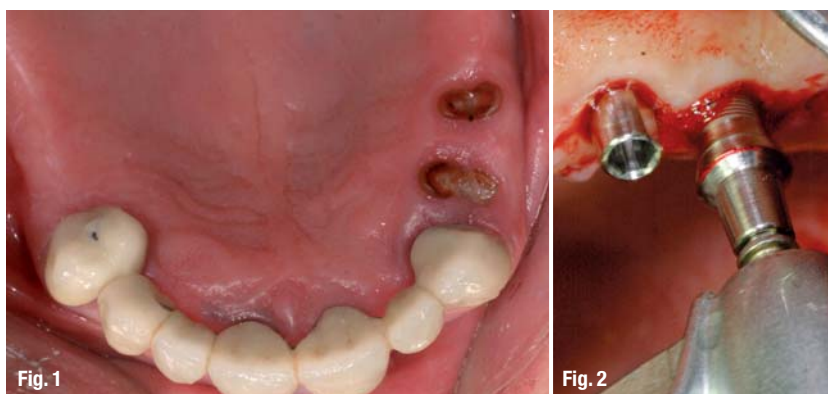


Fig. 1

Fig. 2

Fig. 1 Case before treatment.

Fig. 2 Implant insertion: SEVEN and Mistral implants are inserted flaplessly.

### \_Introduction

Immediate loading of oral implants has been defined as a situation in which the superstructure is attached to the implants no later than 72 hours after surgery (Aparicio et al. 2003; Cochran et al. 2004). The definition of immediate loading also includes occlusion with the teeth of the opposite jaw. Under these conditions, successful immediate loading of screw-type dental implants was reported as early as 1979 (Ledermann 1979).

The proposed exclusion criteria include insufficient bone volume, severe maxillo-mandibular skeletal discrepancy, drug and alcohol abuse, heavy smoking, local radiotherapy of the head and neck region for malignancies, uncontrolled diabetes, stroke, recent infarction, pregnancy at the time of evaluation, bleeding disorders or coumarin therapy, metabolic disorders, and general contra-indications for surgical procedures (Chiapasco et al. 2001; Chow et al. 2001; Hui et al. 2001; Proussaefs et al. 2002; Jaffin et al. 2004; Proussaefs & Lozada 2004; Ibanez et al. 2005).

The question of reducing the micro-movement has not yet been addressed in controlled studies dealing with the immediate loading of oral implants. Passive fit of provisional prostheses has been mentioned as an important factor in the osseointegration of immediately loaded implants. A prosthesis that is ill fitting may become loose, resulting in increased stress on the implants, which can lead to excessive micromotion and the loss of an implant (Jaffin et al. 2004). In this context, it has been hypothesised that screw-retained, passively fitting restorations may be superior to cement-retained ones with respect to this problem because they are less likely to become loose. If a cemented restoration is desired, the abutments should be long enough to provide adequate retention (Jaffin et al. 2004).

The ultimate goal of an immediate loading protocol is to reduce the number of surgical interventions and shorten the period between surgery and prosthetic delivery, without sacrificing implant success rates.

### \_Material and methods

The study was performed in two clinical centres by two investigators who followed the same clinical protocol for immediate occlusal loading of implants placed in the edentulous mandible or maxilla.

Thirty patients were enrolled in the study. Of these patients, ten maxillas and ten mandibles were treated with six implants and five implants, respectively, for a total of 110 implants as the test group for screwed implants, and ten patients (five maxillas and five mandibles) were the control group for cemented implants, with a total of 55 implants inserted. All of the patients were edentulous in the maxilla and/or

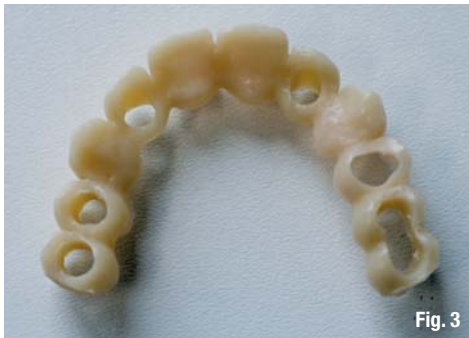

Fig. 3

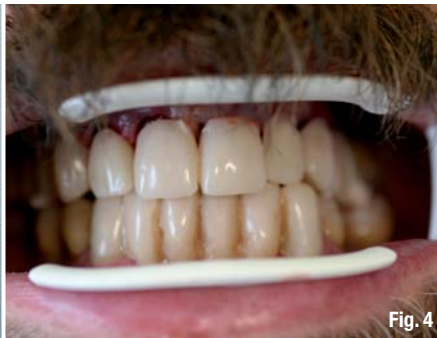

Fig. 4

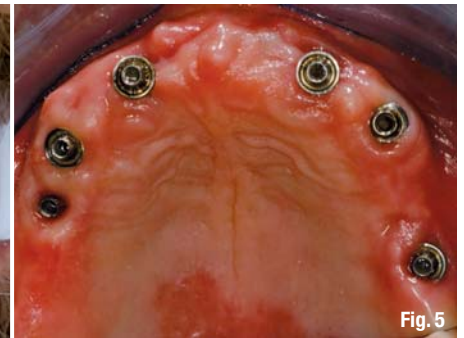

Fig. 5

mandible at the time of the surgery (Fig. 1). All of the patients were treated with SLA screw-shaped SEVEN and/or Mistral implants (MIS; Fig. 2). In addition, a provisional screwed embedded resin prosthetic appliance (Fig. 3) was fixed at the time of surgery for the test group and a provisional embedded resin prosthetic appliance (Fig. 4) was cemented at the time of surgery for the control group.

All clinicians followed the implant manufacturer's instructions for the implant site preparation and insertion procedure. The initial primary stability was assessed by setting the insertion torque of the surgical unit, and recorded according to the following modified classification: "tight" when torque was greater than 45 Ncm, "firm" between 30 and 44 Ncm, or "loose" when less than 30 Ncm (adapted from Testori et al. 2002). The length and the diameter of the individual implants can vary from subject to subject, depending upon bone quality and quantity at each surgical site. The treatment objective involved delivery of the provisional prosthesis within four hours of implant placement, by utilising the prosthetic procedure that best suited the clinical case. A reinforced acrylic provisional bridge was relined over provisional titanium multi-unit cylinders and immediately screwed onto the abutments for the test group. A provisional reinforced acrylic denture was then cemented over titanium abutments for the control group. The occlusion was carefully checked.

No specific diet was recommended to the patients. The patients were on a strict recall programme during the first six months: every week during the first month, and every two weeks between the second and third months, and every month until the sixth month. Orthopantomograms and periapical radiographs were obtained for image analysis at implant insertion. Periapical radiographs were also performed subsequently, after three, six, 12, 24, 48 and 60 months of occlusal loading (Figs. 5 & 6).

Peri-implant marginal bone change was evaluated utilising a computerised measuring technique applied to intra-oral periapical radiographs (RVG, Kodak). The evaluation of the marginal bone level around implants

was carried out using image analysis software (RVG). The bone loss at each follow-up visit was calculated for each implant by determining the difference between the baseline values.

## Results

Thirty patients were enrolled in the study. Of these, ten maxillas and ten mandibles were treated with six implants (Figs. 7 & 8) and five implants, respectively, in the test group (110 implants), and five maxillas and five mandibles in the control group (55 implants). Four implants were lost out of the 165 inserted. One implant belonged to the test group and three to the control group. The implants showed extensive marginal bone resorption and signs of peri-implantitis. The patients had a history of bruxism, smoking and/or poor oral hygiene and periodontitis. No patients enrolled in the study dropped out during the study period and all patients showed great satisfaction with the effectiveness of the treatment.

The RFA registrations showed higher values for mesial-distal measurements than for the buccal-palatal ones: 65.3 ISQ (SD 6) versus 55.8 ISQ (SD 6.9) for all implants. The marginal bone level was situated more coronally for the test implants at all stages of the trial. After six months, the marginal bone level was on average 0.9 mm (SD 1.1) below the implant shoulder for the test implants and 2.7 mm (SD 1.2) for the control implants. On average, 0.3 mm (SD 1) of bone loss was observed for the test implants and 0.8 mm (SD 1.2) for the control implants during the first 12 months ( $p = 0.05$ ). A similar proportion of patients showed one or more implants with bone loss. More patients and implants in the control group showed 2 to 3 mm of bone loss during these 12 months. These results were confirmed at subsequent controls at 48 and 60 months after implantation.

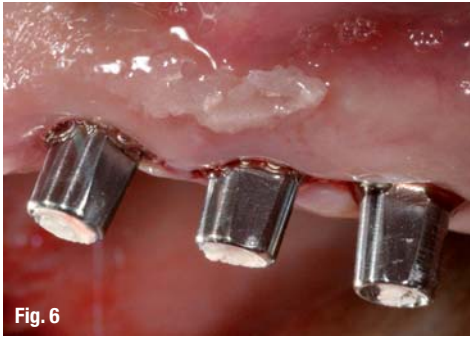## Technical complications

Resin-related technical complications occurred more often in control than in test patients. Six test bridges showed a loosening of the assembly screws of the abutments at the three-month check-up.

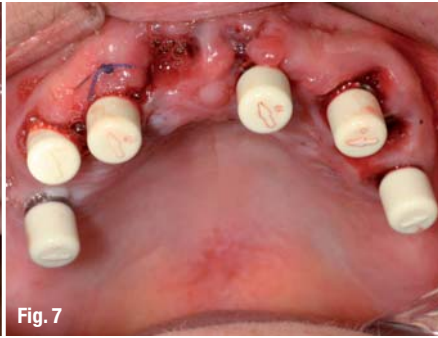**Fig. 3** Provisional bridge before final prosthetic steps.

**Fig. 4** Cemented provisional bridge in position at the time of surgery.

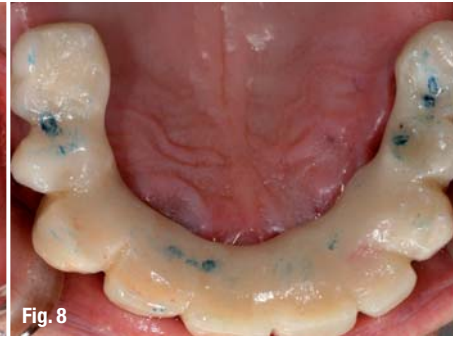**Fig. 5** Clinical appearance after three months of occlusal loading.



**Fig. 6\_** Three of the six implants after three months of occlusal loading with a cemented provisional bridge.



**Fig. 7\_** Six implants inserted in the maxilla and ready for cemented bridge.



**Fig. 8\_** Cemented bridge with occlusal loading at time of surgery.

## Discussion

Early loading has been made possible by using textured surfaces that promote osseointegration (Buser et al. 1991; Cochran et al. 1998; Trisi et al. 1999; Testori et al. 2002). However, immediate occlusal loading procedures can be successful only when the amount of micromotion at the bone–implant interface is kept below a certain threshold during the healing phase (Szmukler-Moncler et al. 1998). It is widely accepted that immediate loading is a desirable procedure if the outcome in terms of implant survival and success is comparable to that of conventional loading. Therefore, it has been the aim of the present study to demonstrate the different clinical outcomes and indications for cemented versus screwed immediately loaded prosthetic appliances, to assess the level of evidence and to discuss implant survival rates and the success rates of these two different protocols.

Varying experiences in the immediate occlusal loading of oral implants has led to different consensus papers (Aparicio et al. 2003; Cochran et al. 2004; Misch et al. 2004). In many of the studies on immediate loading, good bone quality is mentioned as an important prognostic factor for the success of the procedure (Chiapasco et al. 2001; Romeo et al. 2002). Although this conclusion appears reasonable, the level of evidence supporting the assumption is low. The same holds true for the implant lengths and diameters that should be used for immediate loading. In a controlled study, rough implant surfaces improved the survival rate of immediately loaded implants (Rocci et al. 2003); however, the influence of the rough as opposed to machined surfaces was not significant.

Several authors have addressed their interest on the biomechanical aspects of the occlusion in the immediate loading protocol (Szmukler-Moncler et al. 2000; Gapski et al. 2003; Chiapasco et al. 2004). It is commonly accepted, since the study of Cameron in 1971, that a micro motion limit of 150 microns should not be exceeded (Maniatopoulos et al. 1986; Pilliar et al. 1986; Szmukler-Moncler et al. 1998). It has been shown that this limit could be controlled using tex-

ured surface and immediate stability of the implants (Chaushu et al. 2001; Calandriello et al. 2003). The protocol of immediate loading linking the immediate stability with a metal reinforced provisional prosthesis screwed on multiunit abutments was successful and has been in previous reports (Nikellis et al. 2004; Van Steenberghe et al. 2004).

## Conclusion

All study patients received provisional prosthesis within four hours of surgery, and their final rehabilitation was completed six months later. The fact that patients could wear a fixed prosthesis since the first day of surgery has enhanced the compliance of the patients for the treatment period.

The marginal bone defects around immediately loaded implants were similar to delayed loading protocols (Albrektsson et al. 1986). However, several clinical studies on immediately loaded implants have clearly confirmed that the first six months of occlusal function are crucial (Babbush et al. 1986; Schnitman et al. 1990; Balshi & Wolfinger 1997; Schnitman et al. 1997; Ericsson et al. 2000; Jaffin et al. 2000; Szmukler-Moncler et al. 2000; Chaushu et al. 2001). We can conclude that immediate loading protocol using multi-unit abutments is a reliable technique.

### \_contact

### implants

#### Dr Luca Di Alberti

Department of Dental Sciences  
University of Foggia  
Via Colonneta 22-A  
66013 Chieti  
Italy

dialbertiluca@yahoo.it

<sup>1</sup> Department of Dental Sciences,  
University of Foggia, Italy

<sup>2</sup> Department of Oral and Maxillofacial Surgery,  
University of Verona, Italy



# FASCINATION OF LASER DENTISTRY

## FOR EXPERTS AND BEGINNERS

SEPTEMBER 7-8, 2012  
LEIPZIG  
HOTEL THE WESTIN  
LEIPZIG, GERMANY

16  
FORTBILDUNGSPUNKTE  
LEHRBILDUNGSPUNKTE

LASER  
START UP

7. UND 8. SEPTEMBER  
HOTEL THE WESTIN LEIPZIG

FASCINATION OF  
LASER DENTISTRY

21. JAHRESTAGUNG DER DGL e.V.

LASER START UP 2012



- 7./8. September 2012
- Hotel THE WESTIN LEIPZIG

HAUPTSPONSOR  
**BIOLASE**



### ORGANIZATION/ REGISTRATION

Deutsche Gesellschaft für Laserzahnheilkunde e.V.  
(German Society for Laserdentistry)

Klinik für Zahnerhaltung, Parodontologie und Präventive  
Zahnheilkunde Universitätsklinikum der RWTH Aachen,  
Pauwelsstraße 30, 52074 Aachen

Fon: +49 241 8088-164

Fax: +49 241 803388-164

sekretariat@dgl-online.de

www.dgl-online.de

### OEMUS MEDIA AG

Holbeinstraße 29

04229 Leipzig

Fon: +49 341 48474-308

Fax: +49 341 48474-390

event@oemus-media.de

www.oemus.com

www.dgl-jahrestagung.de

www.startup-laser.de

### MAIN SPONSOR

**BIOLASE**

### FURTHER INFORMATION



#### PLEASE FAX THIS FORM

+49 341 48474-390

Further information about:

LASER START UP 2012

21st ANNUAL CONGRESS OF THE DGL e.V.

September 7-8, 2012, Leipzig, Germany

NAME/E-MAIL

OFFICE STAMP

implants 2/12

# Immediate loading of the upper right lateral and central incisors

**Author**\_Prof Alessandro Pozzi, Italy

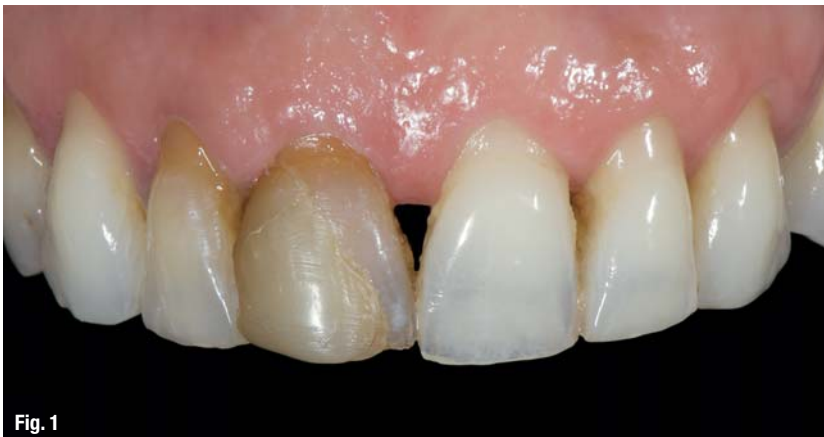

Fig. 1

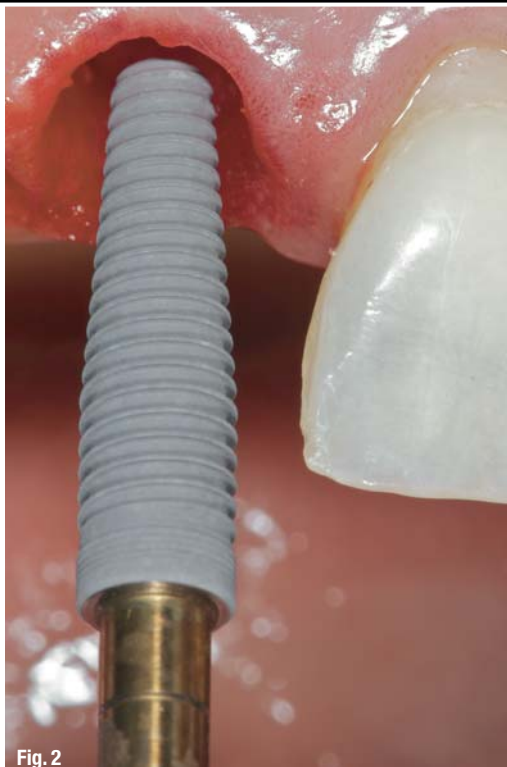

Fig. 2

## Introduction

In recent years, greater biomechanical demands have been placed on restorative solutions as the use of implants for single-tooth replacement in posterior regions of the mouth has become more widespread and new restorative designs based on axial and tilted implants have been introduced. These restorations require a stronger connection in order to withstand higher torque, lateral loading stress and to minimize forces on the retaining screw and prosthetic components.

## Internal connection components

In order to improve the biomechanical characteristics of the complete restoration, the internal connection concept was introduced to the world of implant design; but in its first iterations, the internal connection compromised the strength of both the connection and the implant itself.

Finite element analysis reveals that stresses resulting from functional loading are concentrated in the neck area of the implant. Up until now, internal connections have exacerbated this stress due to the weakness of implant walls and deficient load distribution to the bone, resulting from the designs themselves. The wall thickness of the implant in the critical stress zones has to be able to resist material fatigue and breakage under prolonged use while neither sacrificing "osseointegratable" threads at the neck nor reducing the diameter of the connecting screw.

## Case presentation

In the following commentary, I would like to share a case of anterior restoration in a 50-year-old

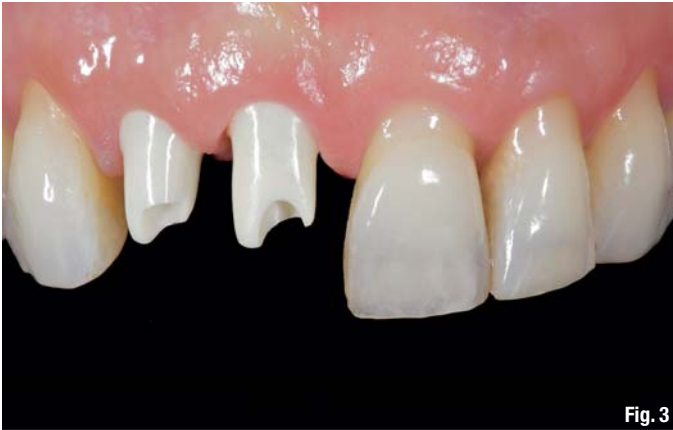

Fig. 3

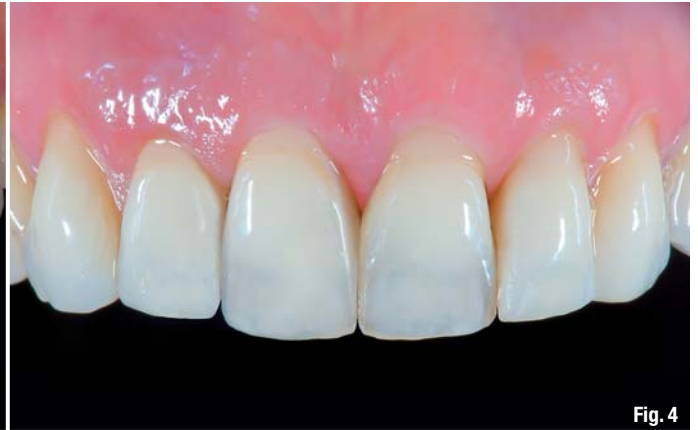

Fig. 4

woman, who had no parafunctional habits, but two inadequate root canal treatments and severely discolored teeth (Fig. 1). This is what she presented: vertical fracture of the upper right lateral and central incisors after an incident of trauma. The extraction of both of the damaged teeth was necessary.

I decided to place two NobelReplace Conical Connection implants (3.5 x 16 mm and 4.3 x 16 mm) immediately after tooth extraction 1 mm below the buccal crest level, in order to create mesial and distal bone peaks for papilla support (Fig. 2). We followed an immediate loading protocol including prefabricated abutments and provisional crowns for optimal shape and gingival architecture. The final abutments were placed four months after surgery. Depicted here, we used two customized NobelProcera Abutments in shaded zirconia (Fig. 3).

Directly afterwards, we cemented two IPS e.max® CAD Crowns by NobelProcera onto the NobelProcera Abutments. The CAD/CAM design of the individualized prosthetic restorations was done by A. Bonaca, and the veneering by P. Paglia and M. Moretti, all three of Rome, Italy. The final result shows excellent soft tissue development and bone formation (Fig. 4). The X-ray of the final restoration was taken one year after surgery (Fig. 5).

## Conclusion

The clinician can now produce a natural-looking restoration accompanied by healthy, soft tissue architecture, and do so with fewer soft tissue grafting procedures. It is, however, my conviction that modern bone-anchored treatment should be characterized by a minimally invasive surgical approach, high biocompatible prosthetic accuracy and unparalleled patient comfort.

The anti-rotational design of the conical connection minimizes torsion forces and allows the application of high insertion torques on the implant without

incurring distortion. By equipping the clinically well-proven implant body with platform shifting and a tight prosthetic connection, the clinician has a better chance to secure healthy soft tissue around the implant in a predictable way.

The tight conical connection and platform shifting both are intended to improve the volume and health of gingival tissue. The tight conical connection can preserve the marginal bone by minimizing micro-movements and eventual micro-leakage, leading to enhanced pink esthetics. The bottom line: quick and predictable implant treatment with long-term functional and esthetic stability. \_

*IPS e.max® is a registered trade-mark of Ivoclar Vivadent AG.*

*This article is a reprint from Nobel Biocare News Vol. 13, No. 1, 2011. © Nobel Biocare Services AG, 2011. All rights reserved. Nobel Biocare, the Nobel Biocare logo-type and all other trademarks are, if nothing else is stated or is evident from the context in a certain case, trademarks of Nobel Biocare. Product images are not necessarily to scale. Disclaimer: Some products may not be regulatory cleared/released for sale in all markets. Please contact the local Nobel Biocare sales office for current product assortment and availability.*

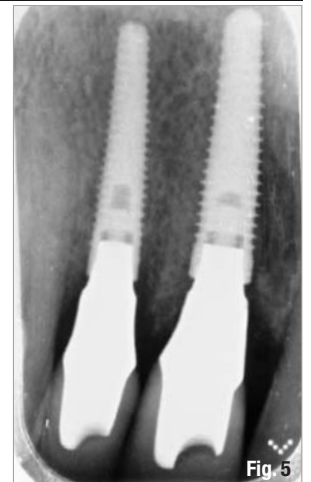

Fig. 5

## \_contact

## implants

### Prof Alessandro Pozzi DDS PhD

Department Oral Rehabilitation  
University of Rome "Tor Vergata"

Studio POZZI  
Excellence in Aesthetic & Implant Dentistry  
Viale Liegi 44  
00198 Rome, Italy

studiopozzi@me.com

# One straight maxillary bridge prosthesis on three implants

## A case report on Vario SR abutments

Author\_Dr Eric Normand, France

### \_Introduction

- Fig. 1\_Pre-op radiological exam: tomography.
- Fig. 2\_Post-op clinical view.
- Fig. 3\_Post-op radiological exam: periapical radiograph.
- Fig. 4\_Clinical view after healing.

This clinical case report presents the fabrication of a straight maxillary bridge prosthesis on three implants. The prosthesis is screw retained on Vario SR abutments. The techniques are detailed step-by-step with additional practical advice.

### \_Case presentation

The 50-year-old patient was in very good health and an athlete. He had been wearing a removable partial denture for more than five years to compensate for maxillary right tooth loss when he came to us for the first time. His request was clear, "I don't want to have an appliance anymore."

He had set his goal more for functional than for cosmetic reasons. The existing prosthesis covering the sectors adjacent to the missing teeth was fully satisfactory to him both cosmetically and functionally. The edentulous space was large, and a bridge on the teeth would have led to short-term failure. The treatment plan was therefore straightforward: replace teeth #13, 14, 15 and 16 with a fixed prosthesis on implants.

Clinical evaluation of the case showed sufficient inter arch space, good occlusion, and a significant amount of attached gingiva. The mucogingival junction was located far away enough from the middle of the crest. The mesiodistal distance was insufficient to replace the four missing teeth. We opted to replace three teeth: one canine, one premolar and one molar.

The cone-beam tomography scan showed significant residual bone volume, which gave us the best conditions for implant insertion (Fig. 1). It was therefore not necessary to perform pre-implant surgery to augment hard or soft tissue.

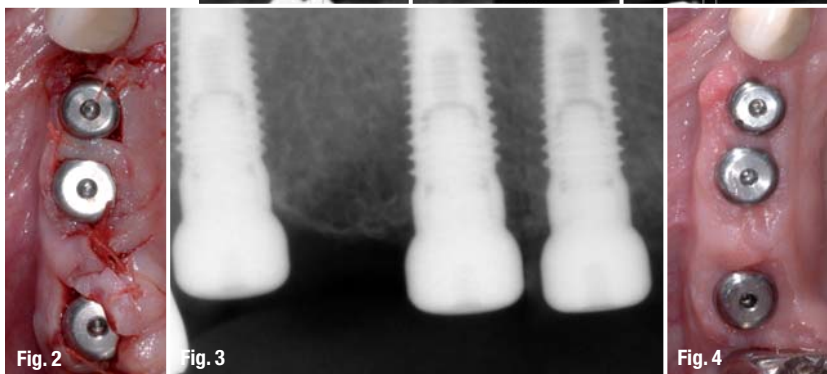
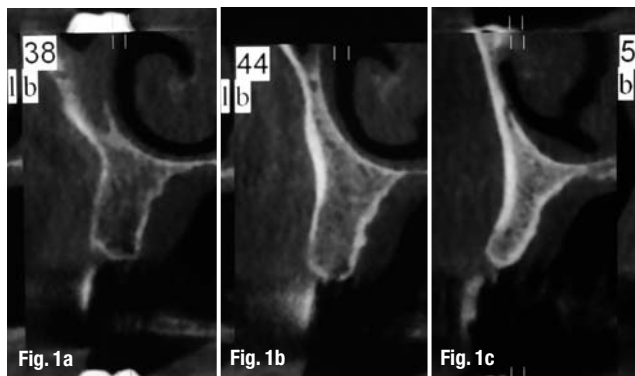
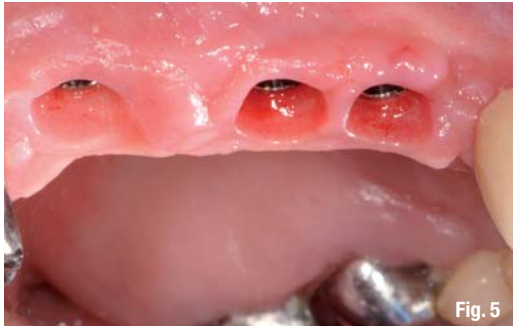



Fig. 5

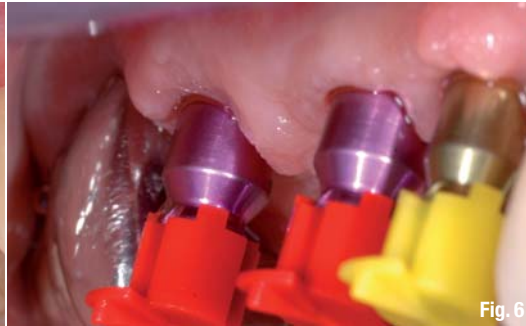

Fig. 6

**Fig. 5**\_Clinical view after eight weeks (at the time of impression taking).

**Fig. 6**\_Pop-in impression transfers in place.

## \_Treatment

The full-thickness flap with no incision for tension reduction was raised after placing the three implants (3.8 x 11 in position 13, 4.3 x 11 in positions 14 and 16) and their healing screws (wide body, 4 mm in length). The small pedicle flaps (using a technique derived from Palacci) provided for closure of the edges without tension, forming the future papillae (Figs. 2 & 3).

After the wounds had healed, irregular wounds were corrected by gingivoplasty with a cautery knife (Figs. 4 & 5). Closed-tray pop-in impression transfers were then applied, which are easier to use than open-tray transfers and are just as precise in the CAMLOG Implant System when the implants show little angulation towards each other (Fig. 6). With the impression transfers in place, the impression was taken (Fig. 7). Figure 8 shows the positive model

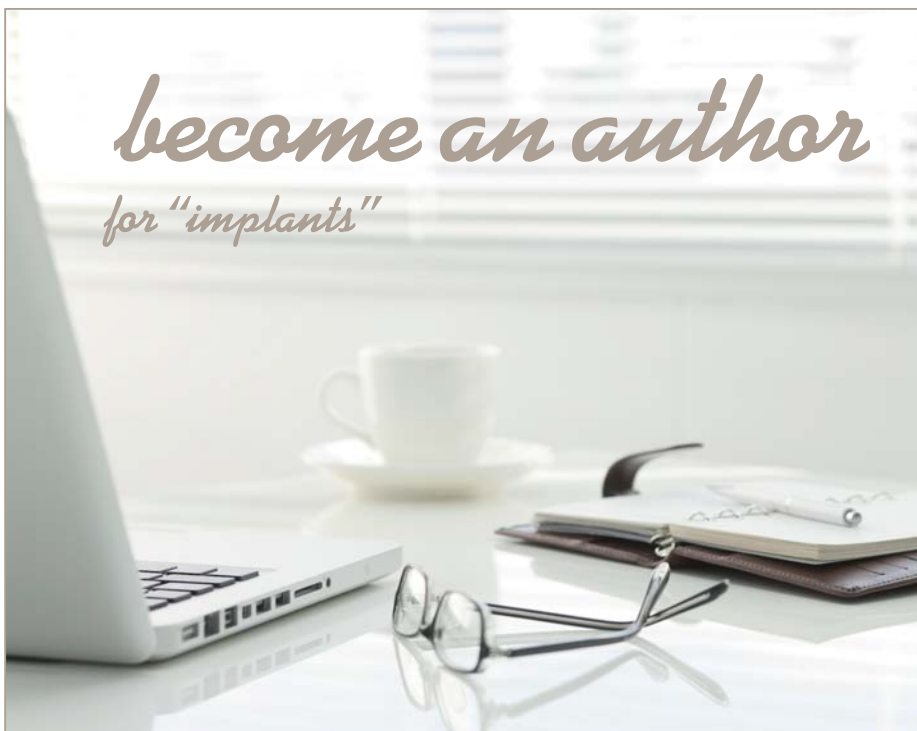with artificial gingiva and a view of the parts used by the laboratory for fabricating the bridge.

Since the implants showed little divergence, straight Vario SR abutments were placed in the model (Fig. 9). Burn-out copings with no anti-rotation plane were then placed (Fig. 10) and fitted (Fig. 11). The next step entailed the placement of the wax model teeth on the copings (Fig. 12). The cast framework was then produced (Fig. 13) and checked on the model (Fig. 14). Figure 15 shows the rough framework.

After reviewing the gingival wells formed by the healing caps (Fig. 16), Vario SR prosthetic abutments were placed (Fig. 17). The gingival quality at this point promoted overall stability (Fig. 18).

Several X-rays were taken during the insertion of the abutment screws to check for complete passiv-

AD



*become an author  
for "implants"*



Please contact Claudia Jahn  
✉ c.jahn@oemus-media.de

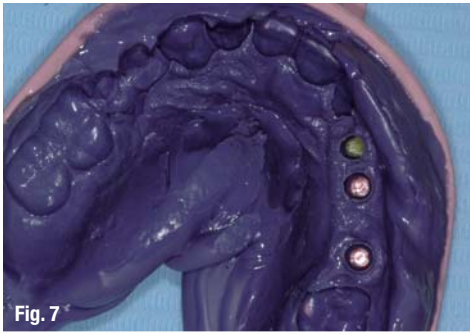


Fig. 7

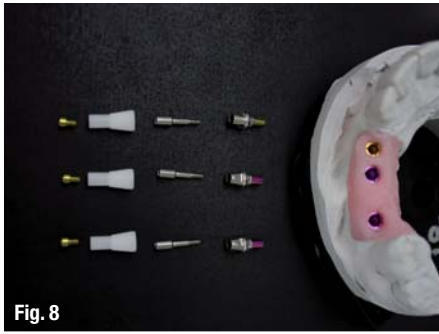


Fig. 8

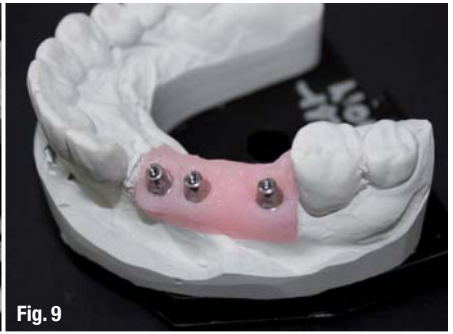

Fig. 9

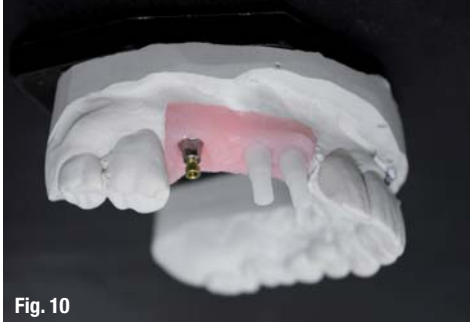


Fig. 10

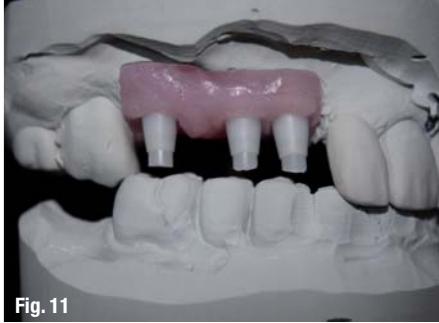

Fig. 11

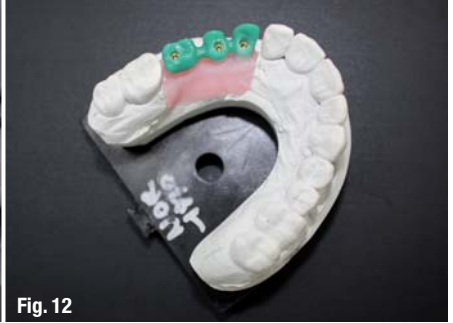

Fig. 12

**Fig. 7**\_Impression (note that the coloured caps have been removed).

**Fig. 8**\_Positive model.

**Fig. 9**\_Vario SR abutments in place.

**Fig. 10**\_Burn-out copings in place.

**Fig. 11**\_Fitting of copings.

**Fig. 12**\_Wax model.

**Fig. 13**\_Cast framework.

**Fig. 14**\_Checking the framework on the model.

**Fig. 15**\_Rough framework.

**Fig. 16**\_View of the gingival wells formed by the healing caps.

ity of the framework (Figs. 19 & 20). During the try-in of the bridge, there were slight gaps in the mesial implants (Fig. 21). These resulted from a contact point with tooth #13 that was too low. After some adjustments had been made, the gaps disappeared (Fig. 22). Figure 23 shows the occlusal view of the bridge during the try-in. The abutment screws were then tightened to 20 Ncm, and the prosthetic screws were tightened to 15 Ncm.

The occlusal access wells were filled with a cotton pellet and composite (Fig. 24). In spite of the resulting irregular and non-homogeneous appear-

ance, the patient was not bothered in the least by the cosmetic outcome. Figures 25a and b show the final result three months after the insertion of the prosthesis, with the cosmetic irregularities still visible from the palatal perspective. Note the final X-ray (Fig. 26).

### \_Discussion

The significant amount of attached gingiva and bone volume in this case allowed us to perform surgery with minimal detachment of soft tissue. With the raising of the flaps, we did not have to work



Fig. 13

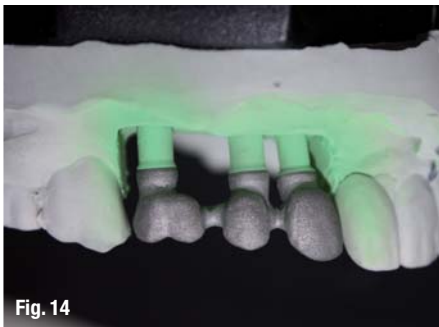


Fig. 14



Fig. 15

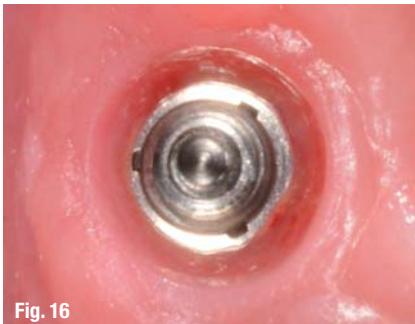

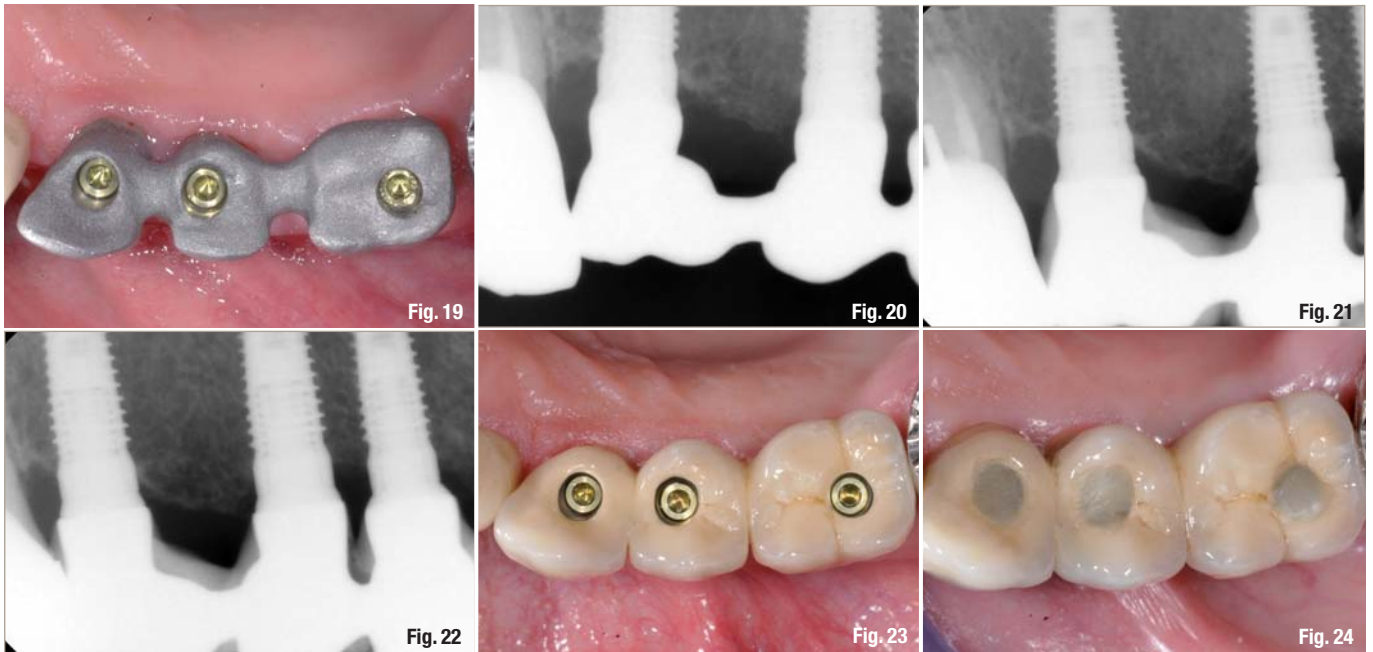
Fig. 16

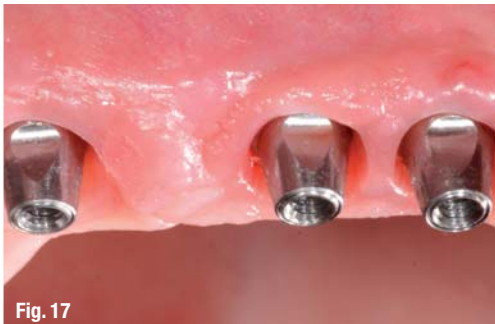

Fig. 17

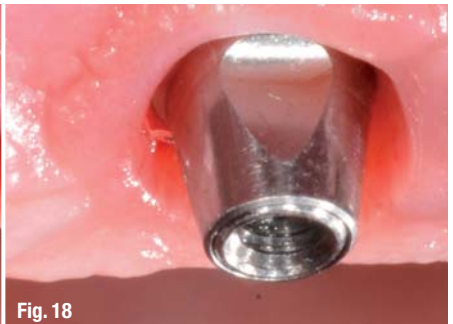

Fig. 18



blindly in the bone crest, and we were able to manage the inter-implant gingival volume optimally. It is important to adjust the temporary removable denture properly during the osseointegration phase. Moreover, the patient must be informed that any contact between the temporary prosthesis and the healing screw can result in the loss of the underlying implant. The impression with the pop-in system shows a precision similar to a pick-up impression in so far as the implants are not divergent. We use these transfers in over 99% of our cases.

### Conclusion

The one-stage surgical procedure enables us to take advantage of a longer period of mucosal and bone healing in cases in which burying the implant during the osseointegration phase can be avoided. There is also good primary stability, which can easily be obtained with the SCREW-LINE implant shape.

The Vario SR abutments allow us to make a screw-retained prosthesis on implants in a straightforward and precise manner. In addition, time is

saved—with no compromises on precision or quality—by using clinical protocols that are more straightforward and rational than traditional protocols. These include one-stage surgery, limited non-invasive flaps, impression taking with pop-in transfers, easy repositioning of abutments, use of only one screwdriver throughout the treatment and splinted crowns. The screw-retained prosthesis also avoids any risk of residual cement around the implant neck.

*Editorial note: This article was originally published in LE FIL DENTAIRE in October 2010.*

**Fig. 17**\_Vario SR prosthetic abutments in place.

**Fig. 18**\_Detail of the abutment in place.

**Fig. 19**\_Framework try-in.

**Fig. 20**\_X-ray check.

**Fig. 21**\_X-ray check of the bridge during the try-in (note the slight gaps in the mesial implants).

**Fig. 22**\_X-ray after adjustments.

**Fig. 23**\_Occlusal view of the bridge during the try-in.

**Fig. 24**\_Occlusal view after the occlusal access wells had been filled with a cotton pellet and composite.

\_contact

implants

**Dr Eric Normand**

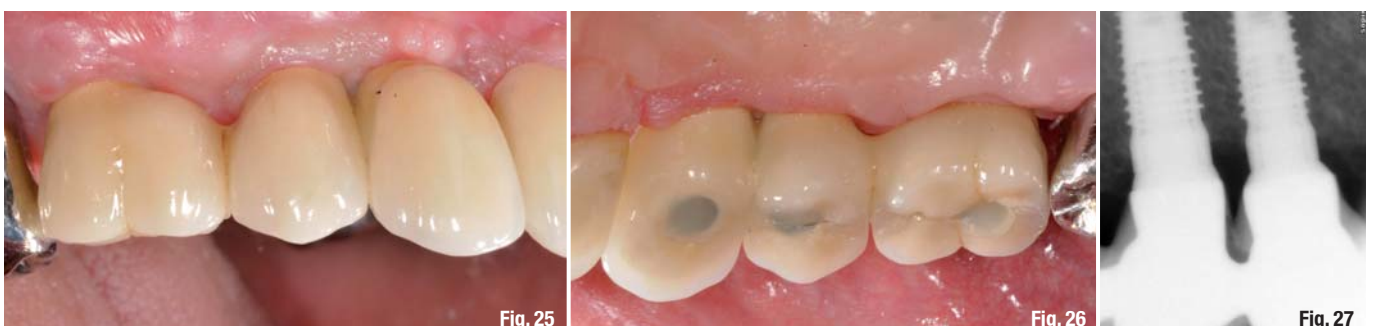124 rue Croix de Seguey  
33000 Bordeaux  
France

dr.eric.normand@gmail.com

**Figs. 25–26**\_Situation three months after insertion of the prosthesis:

buccal view (a) and palatal view (b).

**Fig. 27**\_Final X-ray.



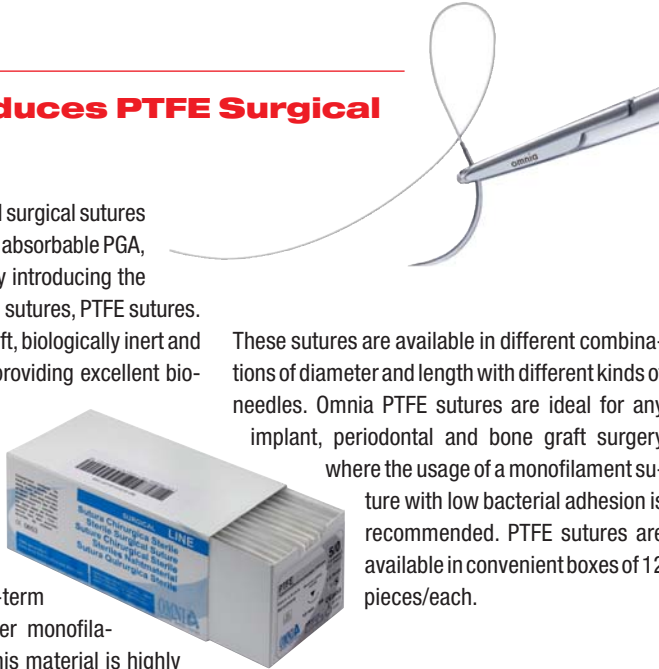
# Manufacturer News

## Omnia

### Omnia Introduces PTFE Surgical Sutures

In addition to the traditional surgical sutures made of silk, polyester and absorbable PGA, Omnia expands its offer by introducing the new generation of surgical sutures, PTFE sutures. Omnia PTFE sutures are soft, biologically inert and chemically non-reactive, providing excellent biocompatibility.

Main features of PTFE sutures are a great fluency of the thread along the tissues, strong knot holding, and a stable long-term quality. Compared to other monofilament synthetic sutures, this material is highly tolerated in the oral cavity. Further, PTFE sutures are ideal to limit inflammation, bleeding and other collateral effects which may occur during the soft tissue approximation. Albeit resistant, PTFE sutures are thus both comfortable and soft for the patient.



These sutures are available in different combinations of diameter and length with different kinds of needles. Omnia PTFE sutures are ideal for any implant, periodontal and bone graft surgery where the usage of a monofilament suture with low bacterial adhesion is recommended. PTFE sutures are available in convenient boxes of 12 pieces/each.

#### Omnia SpA

Via F. Delnevo, 190sx,  
43036 Fidenza (PR), Italy

info@omniaspa.eu  
www.omniaspa.eu

## Straumann

### Straumann CARES Visual 7.0: opening CAD/CAM

Straumann's CARES Visual 7.0 software was developed to enhance user friendliness and versatility. Using the application to design prosthetic elements, customers can route the design data to a milling process either in- or outside Straumann. The workflow inside Straumann is validated and seamless, offering one of the broadest ranges of materials and applications. Prosthetic restorations delivered through this process are covered by the Straumann guarantee.



Customers want state-of-the-art functional software that offers flexibility and full assurance of predictability and reliability. Straumann CARES Visual 7.0—developed on the Dental Wings Open Software platform—meets these criteria and ensures Straumann quality.

Labs can now invest in a CAD/CAM system without the fear of being locked in to a single manufacturer. Straumann CARES Digital Solutions provide dental professionals with a holistic, reliable and precise outcome. Digitalization of dental workflows is bringing about new and exciting possibilities for patients, surgeons and lab technicians. The Straumann CARES platform offers seamless connectivity to thousands of scanners worldwide and provides Straumann customers with access to future leading edge developments in digital dentistry.

#### Institut Straumann AG

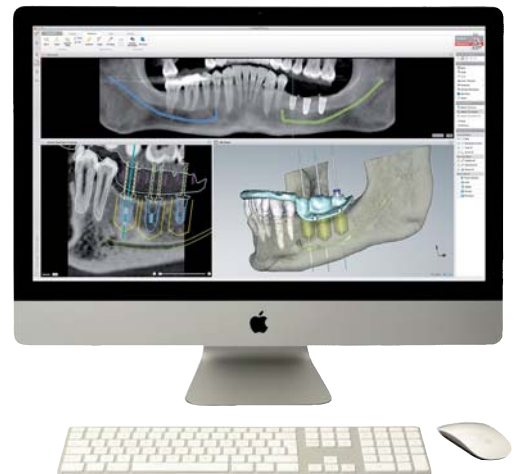Peter Merian-Weg 12  
4052 Basel, Switzerland

info@straumann.com  
www.straumann.com

## Nobel Biocare

### NobelClinician: Software now faster and easier to use

The new update to NobelClinician makes the first advanced diagnostics and treatment planning software for Mac OS® X and Windows® even easier to use and faster to work with in your daily practice. Additionally, NobelClinician is now open to other major implant systems. The latest version of NobelClinician software provides enhanced efficiency and safety with new visualization features. New features include a realistic 3-D visualization of the bone models with the artifact erasing function, visualization of the dental roots in 3-D, warning alerts if implants are



placed too close to roots or nerves and the ability to quickly generate clinical reports. The new update to NobelClinician also increases treatment flexibility by opening the software to other major implant systems. Users will now have the convenience of using one software to plan treatments that involve implants from various providers. In addition to Nobel Biocare's assortment, Straumann® implant systems are also available with other major implant systems to come.

#### Nobel Biocare Deutschland GmbH

Stolberger Straße 200  
50933 Köln, Germany

info.germany@nobelbiocare.com  
www.nobelbiocare.com

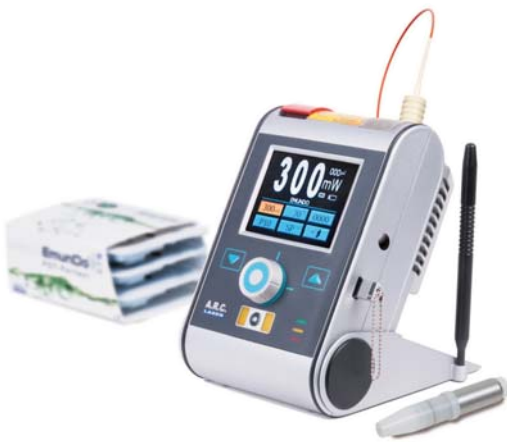

A.R.C. Laser

**Healthy teeth =  
Healthy patients**

Bacterial inflammation in periodontal pockets can lead to bleeding gums, pocket formation, reformation of gums with loosening and eventual loss of teeth. Furthermore, scientific evidence indicates that there is an increased risk of infections developing in the rest of the body, eventually resulting in vascular diseases in the heart and arteries.

EmunDo® PDT therapy is safe and effective for removing harmful bacteria, regardless of the Gram stain and including Gram-positive/-negative bacteria, as well as Gram-variable and Gram-undetermined species. By comparison, mechanical cleaning cannot reach and remove bacteria in all areas. Other laser-based therapies cannot be said to be clinically effective on all types of germs.



PDT has the ability to treat exposed areas without thermal effect. EmunDo® has a selective, localized effect because it accumulates only in the inflamed areas and can be irradiated immediately without waiting period. Furthermore, the bacteria contained in plaque or biofilm is less affected by antibiotics, because they are shielded by the organic matrix in the film and may be absorbed by or adhere to the tooth and epithel cells. While PDT has the advantage of achieving excellent cosmetic results with minimal risk of scarring, it is also a welcome alternative treatment for periimplantitis to save the implant by maintaining the protective function of the mucosa.

**A.R.C. Laser GmbH**  
Bessemersstraße 14  
90411 Nuremberg, Germany

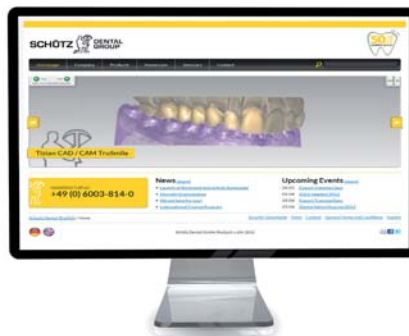
info@arclaser.de  
www.arclaser.de

Schütz Dental

**Relaunch of the brand new  
IMPLA homepage**

The brand new IMPLA homepage shows up with lots of exciting new features. Users can now participate in online trainings and save travelling expenses, or browse our newsroom for videos with tips and tricks or information on brand new products.


To stay up-to-date on the latest news, customers can register for the new IMPLA implant newsletter <http://sdent.eu/newe>. The newsletter also offers special deals and events. The new website furthermore brings an optimized research function. You can also find our complete product line with detailed information on implants, IMPLA 3D implant navigation and the Complete Digital Workflow. Out of the office? No problem — the new homepage was adjusted to be viewed on smartphones and tablets.



Stay up-to-date and follow us on Facebook. We are looking forward to your visit!

**Schütz Dental GmbH**  
Dieselstr. 5–6  
61191 Rosbach, Germany

export@schuetz-dental.de  
www.schuetz-dental.com



CAMLOG

**CamlogConnect**

The platform [www.camlogconnect.com](http://www.camlogconnect.com) offers dentists, students, technicians and academics a wide selection of education material and latest information on implantology, surgical techniques and CAMLOG products. The interactive platform is designed “by CAMLOG users—for CAMLOG users”. Registered members have free access



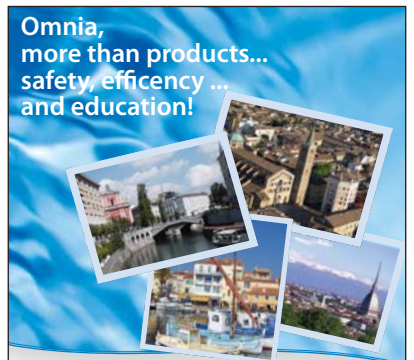to tutorial videos that help understand CAMLOG technology. They can also use videos and case reports from colleagues around the world. Tips & Tricks from experts further support CAMLOG users in their daily practice. Discussion forums invite to an exchange of knowledge. In addition, CamlogConnect offers a lexicon where terminology and techniques can be looked up. Members have the opportunity to upload their own case reports. The CamlogConnect team reviews the material and provides support for translation and editing. All services are free.

**CAMLOG**  
**Biotechnologies AG**  
Margarethenstrasse 38  
4053 Basel, Switzerland

info@camlog.com  
www.camlog.com



AD



**Omnia Education Program**

OMNIA presents a complete program of education that will be held throughout 2012. 2 days courses divided into 3 parts:

- Lectures
- Live surgery
- Hands-on

The courses are held in international locations (Italy, Slovenia, France) by internationally english speaking surgeons. The lecture session will be followed by a live surgery and a hands-on session on animal jaws.

Only a restricted number of participants is admitted (12-20) to offer the due attention and support to each of them. Time will be also devoted to teambuilding activities which will change according to the different locations.



Via F. Deliveo, 190 - 43036 Fidenza (PR) Italy  
Tel. +39 0524 527453 - Fax +39 0524 525230  
VAT. IT 01711860344 - R.E.A. PR 173685  
Company capital € 200.000,00

[www.omniaspa.eu](http://www.omniaspa.eu) - [oop@omniaspa.eu](mailto:oop@omniaspa.eu)

MIS Implants

**MIS Implants Minimises Stability Gap with C1**



As a result of an intensive research and development process, the implant specialist MIS is presenting C1, a screw implant minimising the time between primary and secondary stability. A combination of a specially developed drilling process and sophisticated implant design speeds up healing time and prolongs service life. In line with the MIS motto "Make it simple" the C1 is easy to handle and provided with an extensive range of accessories.

The unique Dual Stability Mechanism (DSM) of the new implant combines the benefits of high primary stability with accelerated osseointegration. The acrostructure and microstructure of C1 and its unique differential drilling method shorten the time between immediate mechanical primary stability and biological secondary stability.

For the C1 implant, MIS developed special instruments that facilitate rapid, reliable insertion. The unique 3-in-1 key system minimises the number of instruments and maximises the level of flexibility.

The combination pack of the C1 contains a single-use final drill, a cover screw, a healing cap with a height of 4 mm, and a temporary cylinder. The ergonomic, circular design of the innovative C1 surgical kit follows surgical procedure and drilling sequence. The kit contains a set of the mostly used pilot drills. Color-coded marks for implant diameter and restorative platforms are integrated.

**MIS Implants Technologies**

Simeons carré 2  
32423 Minden, Germany

service@mis-implants.de  
www.mis-customers.com

W&H

**For Daily Use:  
The New Implantmed by W&H**

Attractive and powerful are two words that perfectly describe the new W&H Implantmed. The new drive unit excels by virtue of its ease of operation, a powerful motor and a motorised thread-cutter function. It offers safety and maximum precision for oral surgery in the fields of implantology and also maxillofacial surgery.

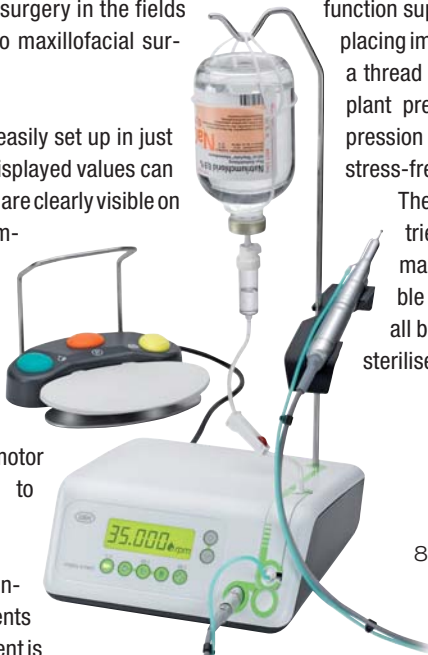All programmes can be easily set up in just one user level, and the displayed values can be modified. The settings are clearly visible on the large display. The implantologist can therefore concentrate on the essential factor: the patient. Implantmed is powerful enough for all operations with a motor torque of 5.5 Ncm and a motor speed range of 300 to 40,000 rpm.

The automatic torque control for rotary instruments ensures that the instrument is

safe. The lightweight motor and the ergonomically shaped W&H contra-angle handpieces are perfectly balanced in the user's hand.

The integrated automatic thread-cutting function supports the implantologist in placing implants in hard bone. Cutting a thread before screwing in the implant prevents an excessive compression of the bone and promotes stress-free healing of the implant.

The new Implantmed features tried and tested Austrian-made W&H quality. Motor, cable and handpiece holder can all be thermally disinfected and sterilised, of course.



**W&H Deutschland GmbH**

Raiffeisenstraße 4  
83410 Laufen, Germany

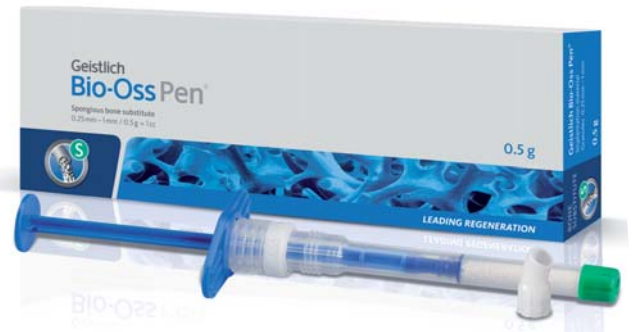office.de@wh.com  
www.wh.com

Geistlich Biomaterials

**Geistlich Bio-Oss Pen®:  
Nothing changed.  
Just improved.**

Geistlich Bio-Oss® granules are now available in the Geistlich Bio-Oss Pen®. Thanks to this applicator, the No. 1 bone substitute material<sup>1,2</sup> can now be applied faster and more precisely to the surgical site.

The Geistlich Bio-Oss Pen® combines the No. 1 bone substitute material with comfortable use and optimal access to the defect. The Geistlich Bio-Oss® granules are moistened with either sterile physiological saline or patient blood. This leads to an optimal consistency of the material. The curved applicator tip ensures fast and precise



application of the Geistlich Bio-Oss® granules to the surgical site. Especially in the posterior region and in the sinus the Geistlich Bio-Oss Pen® facilitates the placement of Geistlich Bio-Oss® and reduces surgery time. Due to the reduced spillage risk and minimal residuals in the Geistlich Bio-Oss Pen® after use the waste of bone substitute material can be minimised. Geistlich Bio-Oss Pen is available with large granules (0.5 g ~ 1.5 cc) and with small granules (0.5 g ~ 1.0 cc and 0.25 g ~ 0.5 cc). Large granules are ideal for sinus floor elevations and larger bony defects. For smaller defects the small granules are recommended, as they ensure closer contact with the surrounding bony walls.

<sup>1</sup>iData Research Inc., US Dental Bone Graft Substitutes and other Biomaterials Market, 2011  
<sup>2</sup>iData Research Inc., European Dental Bone Graft Substitutes and other Biomaterials Market, 2010

**Geistlich Pharma AG**

Bahnhofstrasse 4  
06110 Wolhusen, Switzerland

www.geistlich-pharma.com

# 4<sup>th</sup> International CAMLOG Congress

Author: CAMLOG Foundation

The CAMLOG Foundation is a foundation established by scientists under Swiss law. It engages in targeted support of gifted young scientists, promotion of basic and applied research, and continuing training and education to promote progress in implant dentistry and related fields to serve the patient. As part of its scientific mission, the CAMLOG Foundation has assumed patronage of the International CAMLOG Congresses, which take place every two years.

Under the motto "Feel the pulse of science in the heart of Switzerland", CAMLOG invited everyone to Lucerne, Switzerland, for the 4<sup>th</sup> International Congress—and they ALL came. More than 1,300 participants reached a new record attendance in the internal congress ranking of the CAMLOG Group, who again underscored its claim to place among international leaders in implant dentistry with this impressive success.

The starting shot for congress activities was given on Thursday, May 3, a day before the actual congress, with four German/English workshops that had been sold out well in advance. These theoretical and practical events on all aspects of soft-tissue management were held at 2,100 meters above sea level on Mount Pilatus, a unique location only accessible by cogwheel railway or aerial cableway with a fascinating view of an ensemble of more than 70 alpine peaks.

Then on May 4 and 5 at the Culture and Congress Center in Lucerne on Lake Lucerne, an internationally renowned panel of speakers presented the 'state of the art' of implant dentistry. The range of topics included: innovations in implant-abutment connections, long-term clinical experience with platform switching, the demographic shift and increasingly aging patients, current trends in digital dentistry, and "meet the experts" with complex cases and patients, including a lively panel discussion.

As the concluding participant survey showed, the connection between the scientific content of the first

morning of the congress and the practical topics of Friday afternoon and Saturday was viewed as particularly successful and instructive.

And not to miss out on the "social networking", CAMLOG invited to two raving parties. Both on Friday and Saturday evening, happy congress participants and



partygoers made certain that "Let's rock the Alps" was literally experienced by all invited by CAMLOG to the "Rigi", Lucerne's "exclusive" mountain.

Against the background of this resounding success, the CAMLOG Foundation disclosed immediately at the end of the Lucerne congress that the 5<sup>th</sup> International CAMLOG Congress, for which planning has already started, will be held in Spain in 2014.

[\\_contact](#)

[implants](#)

**CAMLOG Foundation**  
Margarethenstrasse 38  
4053 Basel, Switzerland

info@camlogfoundation.org  
www.camlogfoundation.org

SCAN ME



QR-Code: Impressions of the  
CAMLOG Congress. Scan  
QR-code with your smartphone.

# ITI Congresses Switzerland and Iberia a great success

Author\_ITI Center

Highly topical lectures, prominent speakers and lively discussions made up the first ITI Congress Switzerland. It was attended by more than 500 professionals and specialists in implant dentistry and took place in Biel against the magnificent backdrop of the lake and surrounding hills.

The congress dealt with the life cycle of an implant and covered aspects from treatment planning to possible complications. Speakers from universities, specialists from private practice and dental technicians took part in the program. Representatives from the Universities of Basel, Bern, Geneva and Zurich involved in peri-implantitis treatment elaborated their position and contributed to a spirited round table discussion. An industry exhibition rounded off the successful congress and provided participants with valuable information on current products and trends.

"This was the first time that an ITI national congress was held in Switzerland and we were very happy with the way it went", says Prof Dr Nicola Zitzmann, ITI Education Delegate Switzerland. "It provided an excellent opportunity for Swiss ITI Members and Fellows as well as other dental professionals to get up to date on the latest developments in implant dentistry."

Only a few days later, the ITI Congress Iberia took place. Well over 750 professionals in implant dentistry attended the congress which was held in Santiago de

Compostela. The congress dealt with evidence-based implant dentistry and offered a diverse program with parallel sessions for dental technicians and hygienists. It also included an industry exhibition, pre-congress courses and hands-on workshops, which were highly appreciated by the participants. "We received very positive feedback and were very happy with the smooth way the event took place", said Juan Blanco, Chair of the ITI Section Iberia, which is just about to pass the 450-mark for Fellows and Members.

Various top speakers from Iberia and abroad, among them Stephen Chen from Australia and German Gallucci from the US, contributed significantly to the overall success of the congress and provided the audience with valuable input. The Chancellor of the University of Santiago as well as the Dean of the School of Medicine and Dentistry also attended the congress, thus signaling the importance of the event for the region.

contact

implants

## ITI – International Team for Implantology

ITI Center, Peter Merian-Weg 10  
4052 Basel, Switzerland

iticenter@iticenter.ch  
www.iti.org



(PICTURE: ©PECCOLD)

# 42<sup>ND</sup>

October 5-6, 2012 // Hamburg, Germany // Elysee Hotel

Congress President // Prof. Dr. Dr. Frank Palm/DE  
Scientific Director // Dr. Roland Hille/DE

## INTERNATIONAL ANNUAL CONGRESS OF THE DGZI




Quality driven implantology –  
On the way to long term success

### Speakers

Prof. Dr. Dr. Kai-Olaf Henkel/DE  
Prof. Dr. Dr. George Khoury/DE  
Prof. Dr. Dr. Albert Mehl/CH  
Prof. Dr. Herbert Deppe/DE  
Prof. Dr. Werner Götz/DE  
Prof. Dr. Shoji Hayashi/JP  
Prof. Dr. Andrea Mombelli/CH  
Prof. Dr. Dr. Frank Palm/DE  
Prof. Dr. Suheil Boutros/US  
Prof. Dr. Peter Rammelsberg/DE  
Prof. Dr. Anton Sculean/CH  
Prof. Dr. Dr. Jörg R. Strub/DE

Prof. Dr. Hans-Peter Weber/US  
Prof. Dr. Thomas Weischer/DE  
Priv.-Doz. Dr. Andreas Bindl/CH  
Dr. Tomohiro Ezaki/JP  
Dr. Daniel Ferrari, MSc./DE  
Dr. Sami Jade/LB  
Dr. Ramy Fahmy Rezkallah/EG  
Dr. Osamu Yamashita/JP  
ZTM Andreas Kunz/DE  
ZTM Tom Lassen/DE  
ZTM Christian Müller/DE  
Mohamed Moataz M. Khamis  
B.D.S., M.S., Ph.D./EG

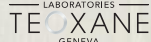Gold Sponsor:



Silver Sponsor:



Bronze Sponsor:



### FAX REPLY

**+49 341 48474-390**

Please send me further information on the  
42<sup>ND</sup> INTERNATIONAL ANNUAL CONGRESS  
OF THE DGZI October 5-6, 2012, in Hamburg, Germany.



Office Stamp

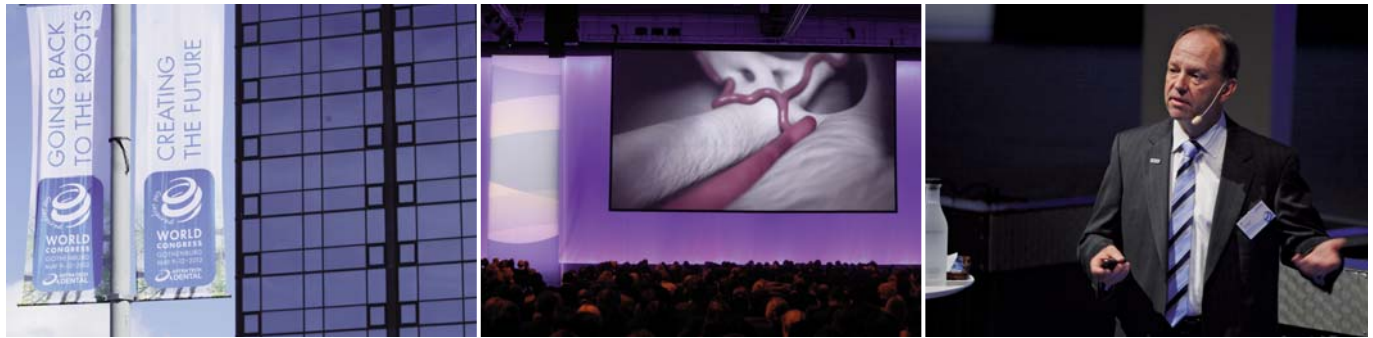# “Creating the future by going back to the roots”

## New findings at AstraTech World Congress

Author\_Dental Tribune, AstraTech



[BACKGROUND ©ARTCALINI]



On 11 May, 2012, Astra Tech presented new clinical data which confirmed the clinical effectiveness of its dental implant system at the Astra Tech World Congress. The results gathered through the company's global research programme demonstrate high survival rates for the company's OsseoSpeed implants in sites like the posterior mandible.

"We are very proud to present continuous positive data from our global clinical research program at the Astra Tech World Congress. For us it is of utmost importance that clinicians feel confident when using our implant system to care for their patients. Ninety per cent of all dental implant systems available today have

no clinical documentation" says AnnaKarin Lundgren, Head of Global Scientific Management.

Recent multicentre studies have also demonstrated the safety and predictability of OsseoSpeed 3 mm narrow implants and OsseoSpeed Profile implants, company officials said at the Astra Tech World Congress in Gothenburg.

Astra Tech's third and largest world congress, which was held from Wednesday, 9 March, 2012 to Saturday 12 March, 2012, has drawn international researchers and experts from the field of dental implantology to the company's headquarters in Sweden. With hundreds of





presentations on offer, more than 3,000 dental professionals from 50 countries participated in the annual event. Gothenburg's premier venues, such as the Swedish Exhibition and Congress Centre, the Göteborg Opera and the Scandinavium, formed the background to this outstanding international event. Well-known dental professionals and scientists discussed the future of osseointegration, among other topics.

"We have an outstanding scientific programme and look forward to an exciting congress with clients and speakers from all over the world," said Lars Henrikson, Senior Vice-President of Marketing and Business Development at Astra Tech.

"Gothenburg is not only the hometown of Astra Tech, it was here where it all began with Per-Ingvar Brånemark's discovery. Through his ground-breaking research, he discovered that titanium was able to integrate with human bone, he coined the term 'osseointegration' and his research was the birth of modern implant dentistry. It is therefore especially exciting to welcome our international attendees to Gothenburg," Henrikson continued.

The comprehensive scientific programme, based on the theme "Creating the future by going back to the roots", was aimed at enabling knowledge exchange between international researchers, clinicians and the dental team. More than 150 speakers from all over the world presented their latest research results, and members of the scientific committee's steering group included world-renowned scientists Jan Lindhe from

Sweden, Tomas Albrektsson from Sweden and Christoph Hämmerle from Switzerland.

During the congress, Astra Tech and WaterAid, an independent organisation that enables the world's poorest people to gain access to safe water and sanitation, strove to collect SEK 500,000 (€56,000). Astra Tech announced to match each Swedish krona donated, making a total of SEK 1,000,000 (€112,000).

"One million Swedish kronor will give 5,000 people access to clean, safe water and sanitation for life. This initiative is in line with our values and our corporate responsibility commitment," said Gunny Kron, Head of Global Marketing at Astra Tech. Astra Tech has been developing solutions to meet health-care needs based on its user and medical community's input since 1948.

Since 2011, Astra Tech has been part of DENTSPLY International Inc., a US dental company that manufactures and distributes the ANKYLOS and XIVE implant systems through its German-based subsidiary DENTSPLY Friudent. DENTSPLY's CEO, Bret Wise, who attended the meeting on Friday, said that these implants, together with its recently acquired Astra Tech OsseoSpeed implants, complement the company's portfolio, as they apply to different indications. Astra Tech Dental and DENTSPLY Friudent now unites into a new Global business—DENTSPLY Implants. Wise also confirmed that OsseoSpeed implants will be distributed and further developed in the future, the German online dental news portal ZWP online reported.



## Men's and women's

### Teeth do not differ significantly

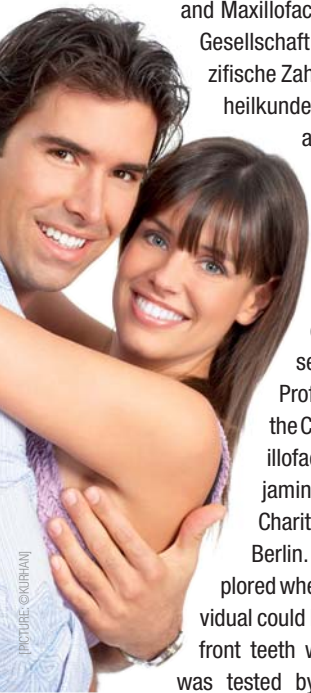Several morphometric studies have proven sexual dimorphisms in human teeth, for example that women's teeth are smaller than men's teeth.

The German Society for Sex-Specific Oral and Maxillofacial Surgery (Deutsche Gesellschaft für geschlechterspezifische Zahn-, Mund- und Kieferheilkunde) recently reported on a study that found no obvious differences between male and female teeth.

The study was conducted by a research group headed by Prof. Ralf J. Radlanski from the Centre for Oral and Maxillofacial Surgery at the Benjamin Franklin Campus of Charité Universitätsmedizin Berlin. The researchers explored whether the sex of an individual could be identified if only the front teeth were considered. This was tested by having participants

evaluate 50 images of the anterior oral region of men and women aged between 7 and 75. The lip area was not shown. The participants included dentists, dental technicians, dental students and dental professionals, as well as 50 people who had no professional dental background.

The results overall demonstrated that sex could be detected in only about 50 per cent of the images. Although there are anthropological studies that claim to prove measurable morphometric differences, the study proved that those are not even visible to experts' eyes. While some tooth positions were correctly assigned by 70 per cent of the participants, others were wrongly assigned by the same number of participants. The assumption that women tend to have rounded teeth and men rather angular ones could not be confirmed by the study. Furthermore, contrary to what was expected by many of the participants, shape, size and colour of the canines were not meaningful indicators of sex. "In everyday practice, it is relevant whether the restoration fits the patient's face but not whether the patient is male or female," Radlanski said. "Recognisable typical male teeth or female teeth do not exist."



## New massage method


### Quadruples protection against tooth decay

Researchers at the University of Gothenburg's Sahlgrenska Academy have developed a method to massage the buccal surfaces with the fingertips, using toothpaste as a kind of lotion. They found that brushing teeth twice a day with high-fluoride toothpaste and additionally rubbing toothpaste onto the teeth increases fluoride protection by 400 per cent. Eight years ago, Duraphat (Colgate), a high-fluoride toothpaste, containing more than three times as much fluoride as standard toothpaste, was launched in Sweden. Available without prescription, it is primarily aimed at people with a high caries risk. The researchers at Sahlgrenska Academy have now evaluated the effect of this toothpaste. At the same time, they developed a new method that quadruples the level of protection from fluoride. In the

study, 16 volunteers tested a variety of brushing techniques, using either high-fluoride or standard toothpaste, and brushing either two or three times a day.

The researchers also tested a new method that involves rubbing toothpaste onto the teeth with a finger. "This massage method proved to be at least as effective as a third brushing in increasing the amount of fluoride in the mouth", Anna Nordström explained. "Rubbing the front of your teeth with toothpaste can be an easy way of giving your teeth a third shot of fluoride during the day, after lunch for example. However, this does not replace brushing with a fluoride toothpaste in the morning and evening but it's an additional procedure."

The study "Effect of a third application of toothpaste, including a 'massage' method on fluoride retention and pH drop in plaque" was published online in February in the *Acta Odontologica Scandinavica* journal.



## Nobel Biocare celebrates

### Dual anniversaries of osseointegration



Professor Per-Ingvar Brånemark made a surprise entrance on March 22 at the first Nobel Biocare scientific symposium of 2012 in Gothenburg, Sweden. While his dramatic entry to the symposium was largely unexpected, his presence was warmly welcomed. Sixty years have now passed since Professor Brånemark's remarkable discovery that titanium could integrate with bone. Thirty years later, in 1982, the discovery was acknowledged and confirmed at an epoch-making meeting of dental authorities in Toronto, Canada. In acknowledgement, this year we revisit Toronto on the last stop of Nobel Biocare Symposia 2012.

The Nobel Biocare Symposia 2012 continue on the road from Sweden to Toronto, with stops along the way in France, Ukraine, Germany and Italy. From all over the world, many more participants are expected to make the pilgrimage to these symposia during the current year. As they do so they will be paying tribute to the discovery that astonished the dental community and sparked new treatment opportunities in such disparate fields as dentistry and orthopedics. An estimated 1,000 attendees descended upon the hometown of osseointegration — Brånemark's Gothenburg — from March 21–23 to celebrate the two anniversaries of osseointegration. For more information please visit <http://www.nobelbiocare.com/symposia2012>.



EAO revises guidelines for

## X-rays in implant dentistry

The European Association for Osseointegration (EAO) has updated its guidelines on the use of diagnostic imaging in implant dentistry by extending them to cone-beam computed tomography (CBCT). Their aim is to optimise both conventional radiography and new procedures and to address the As Low As is Reasonably Achievable principle (ALARA).

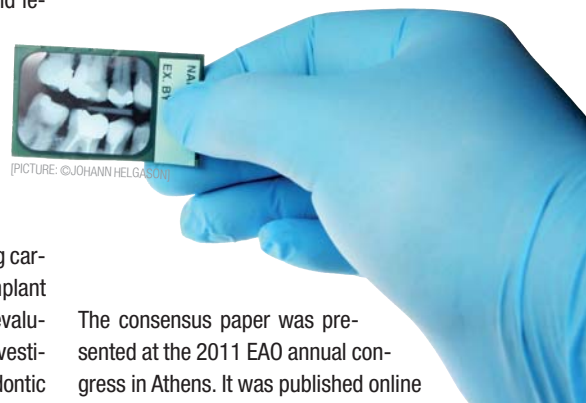The association approached the revision of its 2002 guidelines after SEDENTEXCT, a collaborative EU research project on the sound and scientifically based clinical use of CBCT in dental imaging, had recommended in 2009 that the EAO review its previous guidelines to take into account the increasing demand for CBCT in dental practice in recent years.

The new EAO guidelines primarily focus on patient welfare and safety with regard to minimising their exposure to ionising radiation. They were drawn up to support radiologists, as well as dentists and their assistants, in primary care.

“The field of diagnostic imaging is often both very technical and complex. I believe these EAO guidelines provide a very easily accessible, practical and authoritative approach to the area and offer useful guidance to dentists to help them fulfil their obligations, to act always in the best interests of their patients, as well as to be aware of their ethical and legal responsibilities,” said Prof. David Harris, lecturer at the Trinity College Dublin Dental School and Hospital and chair of the EAO panel of 14 radiologists and clinicians from all over Europe that convened at the Medical University of Warsaw in May 2011.

According to the panel, all diagnostic imaging carries a risk however small; nevertheless, in implant dentistry, it is considered essential to patient evaluation for proposed surgical treatment, the investigation of certain complications and prosthodontic planning. The experts therefore highlighted that it is necessary to reduce any radiation dose according

to the ALARA principle and to ensure that the examination of each patient is always justified and results in a net benefit to the patient. Available alternative techniques with the same objective but involving less or no exposure to ionising radiation must also be taken into account, they said.



(PICTURE: ©JOHANN HELGASON)

The consensus paper was presented at the 2011 EAO annual congress in Athens. It was published online on 20 March in the *Clinical Oral Implants Research* journal ahead of print.


The King's dental crown

## Purchased by Canadian dentist

A Canadian dentist has recently made the winning bid on a porcelain crown of Elvis Presley. The affectionately named “Kings Crown” sold for £5,200 (US\$8,150) and added to the dentist’s collection of celebrity dental memorabilia, in which he already had a tooth from John Lennon he bought last year from the same auction house. Dr Michael Zuk, a general dentist from Red Deer, Alberta (Canada), purchased the crown together with a model of Elvis Presley’s teeth made for the rock-and-roll star by his former dentist, Henry Weiss, in Memphis. The crown was accompanied by five documents confirming its authenticity, including a letter from Presley’s

tour manager Joe Esposito. The crown was sold on 25 February by Omega Auctions, a family-run business in south Manchester, offering rare items of music and film memorabilia, among others. Prior to the auction, the crown was expected to be sold for an estimated value of £6,000 to £10,000.

“Whilst it is not a real tooth, as was the case with the Lennon tooth, it is the only one in existence and we expected there to be considerable interest in this and were really pleased that it sold for £5,200,” said Paul Fairweather of Omega Auctions. According to Zuk’s blog, Presley used to have a gap between his teeth. He was so embarrassed by the space that he decided to have one of his front teeth crowned. Weiss practised dentistry in Memphis for 57 years until he died in December 1990. He was Presley’s dentist until 1971, and prepared the porcelain crown and always kept an extra copy of the crown. When Elvis cracked his crown on a microphone during a performance, Weiss’s son, S. Lewis Weiss, flew the replacement crown to Las Vegas. “John Lennon was a huge Elvis fan so to be the owner of dental memorabilia from both mega-stars is pretty amazing,” said Zuk.

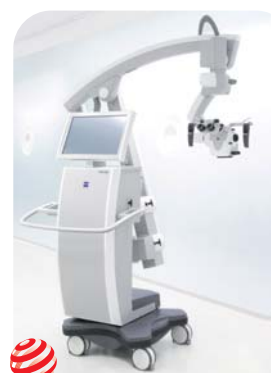

(PICTURE: ©AKVA)

Carl Zeiss receives

## Red Dot Award for OPMI PENTERO 900 Surgical Microscope

Medical technology provider Carl Zeiss Meditec announced that its OPMI PENTERO® 900 surgical microscope has won the highly-coveted Red Dot Award: product design 2012 in the Life Science and Medicine category. Only 62 of the 4,515 products entered this year were awarded “red dot: best of the best” in various categories. The 30-member international jury honored the industrial design of the surgical microscope for meeting the highest standards in nine strict adjudication criteria, including quality, innovation, ergonomics and functionality. The winning products will be honored at the awards ceremony to be held in Aalto Theater in Essen, Germany, on July 2, 2012.



reddot design award

**implants**  
international magazine of oral implantology



**Publisher**

Torsten R. Oemus  
[oemus@oemus-media.de](mailto:oemus@oemus-media.de)

**CEO**

Ingolf Döbbecke  
[doebbecke@oemus-media.de](mailto:doebbecke@oemus-media.de)

**Members of the Board**

Jürgen Isbaner  
[isbaner@oemus-media.de](mailto:isbaner@oemus-media.de)

Lutz V. Hiller

[hiller@oemus-media.de](mailto:hiller@oemus-media.de)

**Chief Editorial Manager**

Dr Torsten Hartmann (V. i. S. d. P.)  
[hartmann@dentalnet.de](mailto:hartmann@dentalnet.de)

**Editorial Council**

Prof Dr Dr Frank Palm  
[frank.palm@klinikum-konstanz.de](mailto:frank.palm@klinikum-konstanz.de)

Dr Roland Hille

[dr-hille@t-online.de](mailto:dr-hille@t-online.de)

Prof Dr Dr Kurt Vinzenz

[kurt.vinzenz@aon.at](mailto:kurt.vinzenz@aon.at)

Dr Torsten Hartmann

[hartmann@dentalnet.de](mailto:hartmann@dentalnet.de)

Dr Suheil Boutros

[SMBoutros@aol.com](mailto:SMBoutros@aol.com)

**Editorial Office**

Georg Isbaner  
[g.isbaner@oemus-media.de](mailto:g.isbaner@oemus-media.de)

Claudia Jahn

[c.jahn@oemus-media.de](mailto:c.jahn@oemus-media.de)

**Executive Producer**

Gernot Meyer  
[meyer@oemus-media.de](mailto:meyer@oemus-media.de)

**Designer**

Sarah Fuhrmann  
[s.fuhrmann@oemus-media.de](mailto:s.fuhrmann@oemus-media.de)

**Customer Service**

Marius Mezger  
[m.mezger@oemus-media.de](mailto:m.mezger@oemus-media.de)

**Published by**

OEMUS MEDIA AG  
Holbeinstraße 29  
04229 Leipzig, Germany  
Tel.: +49 341 48474-0  
Fax: +49 341 48474-290  
[kontakt@oemus-media.de](mailto:kontakt@oemus-media.de)

**Printed by**

Messedruck Leipzig GmbH  
An der Hebemärchte 6  
04316 Leipzig, Germany

**implants**

**international magazine of oral implantology**  
is published in cooperation with the German  
Association of Dental Implantology (DGZI).

**DGZI President**

Prof Dr Dr Frank Palm  
DGZI Central Office  
Feldstraße 80, 40479 Düsseldorf, Germany  
Tel.: +49 211 16970-77  
Fax: +49 211 16970-66  
[office@dgzi-info.de](mailto:office@dgzi-info.de)

[www.dgzi.de](http://www.dgzi.de)  
[www.oemus.com](http://www.oemus.com)

**Copyright Regulations**

**\_implants international magazine of oral implantology** is published by OEMUS MEDIA AG and will appear in 2012 with one issue every quarter. The magazine and all articles and illustrations therein are protected by copyright. Any utilization without the prior consent of editor and publisher is inadmissible and liable to prosecution. This applies in particular to duplicate copies, translations, microfilms, and storage and processing in electronic systems.

Reproductions, including extracts, may only be made with the permission of the publisher. Given no statement to the contrary, any submissions to the editorial department are understood to be in agreement with a full or partial publishing of said submission. The editorial department reserves the right to check all submitted articles for formal errors and factual authority, and to make amendments if necessary. No responsibility shall be taken for unsolicited books and manuscripts. Articles bearing symbols other than that of the editorial department, or which are distinguished by the name of the author, represent the opinion of the afore-mentioned, and do not have to comply with the views of OEMUS MEDIA AG. Responsibility for such articles shall be borne by the author. Responsibility for advertisements and other specially labeled items shall not be borne by the editorial department. Likewise, no responsibility shall be assumed for information published about associations, companies and commercial markets. All cases of consequential liability arising from inaccurate or faulty representation are excluded. General terms and conditions apply, legal venue is Leipzig, Germany.

# implants

international magazine of oral implantology



**Subscribe now!**

I would like to subscribe to **implants international magazine of oral implantology** (4 issues per year) for €44 including shipping and VAT for German customers, €46 including shipping and VAT for customers outside Germany, unless a written cancellation is sent within 14 days of the receipt of the trial subscription. The subscription will be renewed automatically every year until a written cancellation is sent to OEMUS MEDIA AG, Holbeinstr. 29, 04229 Leipzig, Germany, six weeks prior to the renewal date.

▶ **Reply** via Fax +49 341 48474-290 to OEMUS MEDIA AG or per E-mail to [grasse@oemus-media.de](mailto:grasse@oemus-media.de)

You can also subscribe via [www.oemus.com/abo](http://www.oemus.com/abo)

Last Name, First Name

Company

Street

ZIP/City/County

E-mail

Signature

Notice of revocation: I am able to revoke the subscription within 14 days after my order by sending a written cancellation to OEMUS MEDIA AG, Holbeinstr. 29, 04229 Leipzig, Germany.

Signature



# Adapting with nature

## OsseoSpeed™ TX Profile – anatomically designed implants for sloped ridges

Imagine being able to achieve 360° bone preservation around the implant, even in cases with sloped ridges. Now you can.

With OsseoSpeed™ TX Profile – a uniquely shaped, patented implant, specifically designed for sloped ridge situations – you no longer have to choose between buccal and lingual marginal bone preservation and esthetics, you can have it all – 360° around the implant.

As with all Astra Tech implants, OsseoSpeed™ TX Profile is based on the documented key features and benefits of the Astra Tech BioManagement Complex™. Used in combination with patient-specific Atlantis™ abutments, you and your patients can look forward to long-term function and esthetics.

For more information, please visit [www.astratechdental.com](http://www.astratechdental.com)

