

roots

international magazine of endodontology

2²⁰¹²

| case report

Cone-beam computed tomography
in endodontics — Overcoming limitations

| opinion

WaveOne—First experiences
of third-year students

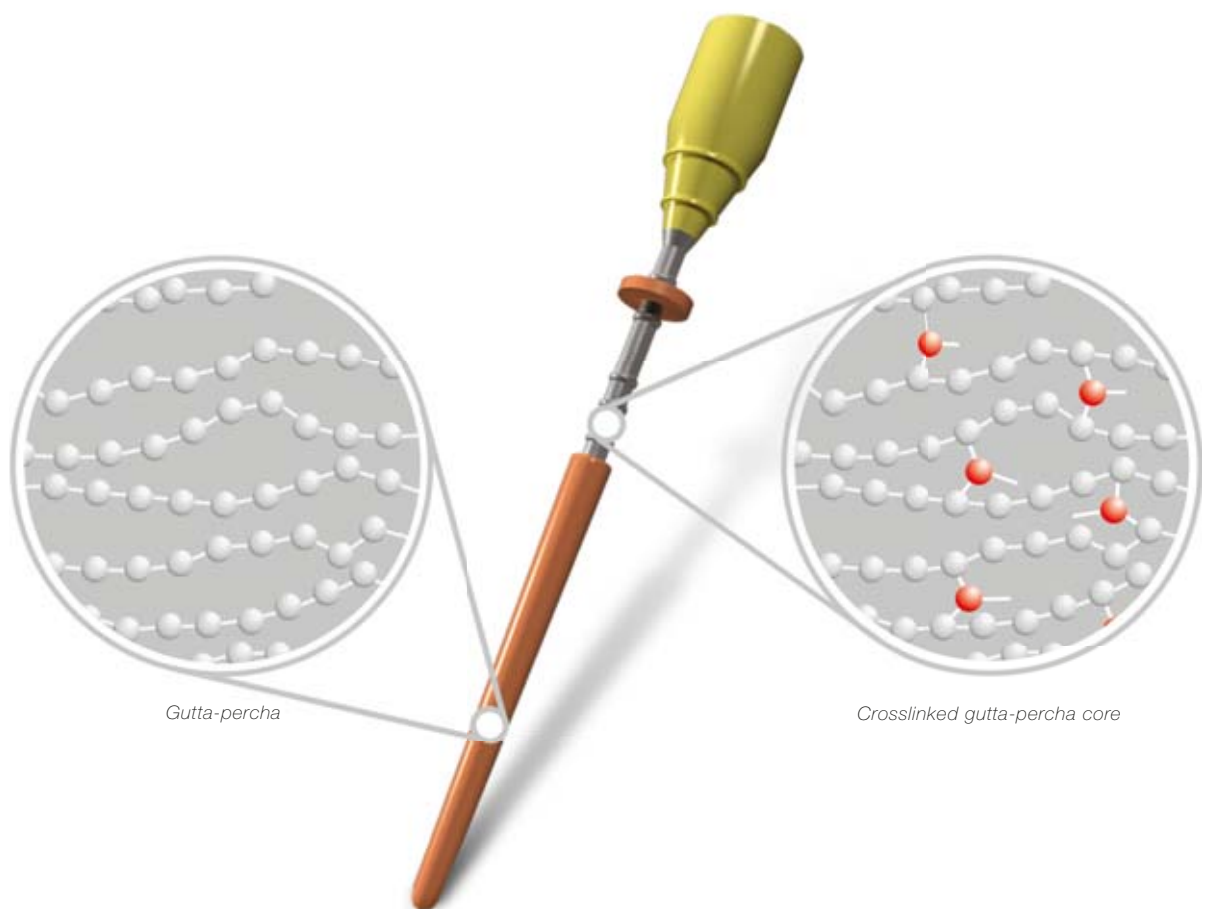
| industry report

Analysis of micro leakage using
a self-etching adhesive system
on casting and fiber glass posts

027113

gutta•core™

crosslinked gutta-percha core obturator



- superior 3D fills
- ease of retreatment
- post space simplified

Dear Reader,

Vince Lombardi so eloquently stated, "Practice does not make perfect. Only perfect practice makes perfect." In other words, we can perform a procedure repeatedly yet not obtain the expected outcome for success. We must continually advance in all disciplines of dentistry in order to provide our patients with the most predictable treatment regimens possible, understanding that the greatest variable that stands in our way is the human variable. Elevating the standards of endodontic care is inexorably tied to an important dynamic, our armamentaria.¹ The objective of endodontic treatment has remained a constant since root-canal treatment was first performed: the prevention and/or treatment of apical periodontitis such that there is complete healing and an absence of infection.² The most important advancements in clinical endodontics forever changed the endodontic landscape with the emergence and development of four technologies.^{3,4}

The *dental operating microscope*, not only provides us superior vision to diagnose cracks and track vertical fractures^{3,5}, but also to locate anatomy and then subsequently address that anatomy. *Sonic and ultrasonic instruments* have allowed us to be able to carry out refinement of access openings, locate calcified canals in a controlled and predictable manner, and eliminate the smear layer, and biofilm that has remained in the canal after instrumentation.^{3,6,7} *NiTi files* have allowed more predictable canal shapes,³ in reduced time compared to stainless-steel files, while maintaining the original canal anatomy and producing less extrusion of debris.^{8,9} *Mineral trioxide aggregate* is a remarkable and biocompatible restorative material that has become the standard for pulp capping and root perforation, and has salvaged countless teeth that previously had been considered hopeless. Perhaps the greatest international attention in recent years has focused on methods to improve endodontic disinfection in the root-canal system.³ Files shape; irrigants clean. We rely on our irrigants and irrigant delivery systems to penetrate into the complex anatomy that our instruments cannot shape, in order to eliminate the organic tissue and bacterial inoculum that exists within. The early works of Hess suggest this is ongoing to be challenging by virtue of its complexity.¹⁰

As I fly 32,000 feet over the Pacific Ocean after lecturing and running Essential Endo Clinical Skill set programmes in both Europe and Asia, it boggles my mind how, with all the modern technologies that exist today to provide predictable endodontics, the fundamentals are often ignored: *Vision, tooth isolation and irrigation*. An overwhelming number of general dentists and, surprisingly, endodontists worldwide do not use rubber dams and provide endodontic treatment through a matte of caries. Saliva is allowed to slop into the pulp chamber like the pungent backwater of a contaminated estuary. This is analogous to providing state-of-the-art building technology with the finest of materials but constructing the foundation on a bog-land. To take short-cuts during treatment to reduce costs, and to justify it to oneself, is to retreat into a mindset of persistent cognitive dissonance. In order to achieve endodontic nirvana and enjoy the successes that the recent technologies allow us to achieve, we must get back to fundamentals and provide grass roots education in a stepwise, systematic manner to those who will be providing the treatment."

"Science and research will elevate the specialty of endodontics to its rightful pinnacle."¹¹ "The cornerstone to our specialty's integrity and relevance must be built on a strong foundation of randomised clinical trials and evidenced-based endodontics."¹¹ The future of endodontics is bright and holds incredible promise as we continue to develop new techniques and technologies that will allow us to perform endodontic treatment painlessly and predictably, and continue to satisfy one of the main objectives in dentistry, that being to retain the natural dentition.¹²

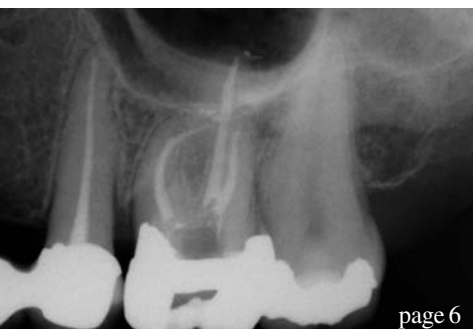

Dr Gary Glassman
Doctor of Dental Surgery
Fellow of Royal College of Dentists of Canada

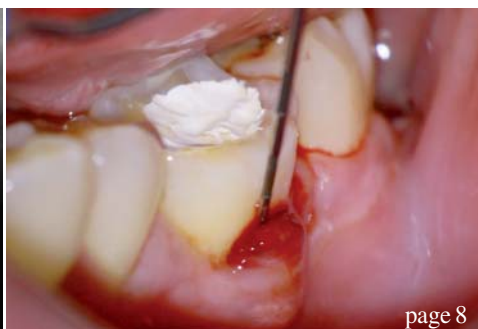

Dr Gary Glassman

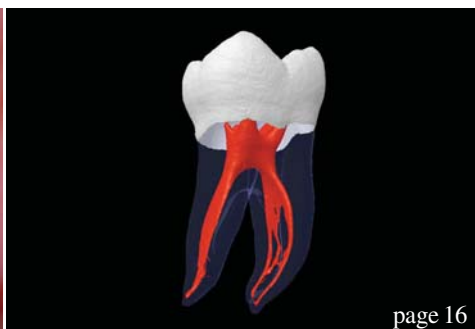Editorial note: A complete list of references is available from the publisher.



page 6



page 8



page 16

| editorial

03 Dear Reader
| Dr Gary Glassman

| case report

06 Cone-beam computed tomography in endodontics—
Overcoming limitations
| Dr Shanon Patel

08 **Diagnosis and management of a longitudinal fracture**
necrosis associated with an extensive periodontal defect
| Dr Antonis Chaniotis

| reviews

12 Dental occlusion/TMJ **and general body health**
| Dr Yong-Keun Lee et al.

| opinion

16 **Canal anatomy:** The ultimate directive in instrument
design and utilisation
| Dr Barry L. Musikant

20 **WaveOne**—First experiences of third-year students
| Prof Michael A. Baumann

24 **Scouting the root canal with dedicated NiTi files**
| Dr Gilberto Debelian et al.

| special

28 **Infection control**
| Dr Frank Y. W. Yung

| industry report

30 **Analysis of micro leakage** using a self-etching adhesive
system on casting and fiber glass posts
| Prof Alejandro Paz et al.

| industry news

34 **RECIPROC wins innovation prize 2011**
| VDW

34 **Everything you like about X-Smart**—with a Plus
| DENTSPLY

36 **Moisture-activated temporary filling** and sealing material
| Centrix

| meetings

38 **“History & Heritage—Forging the Future”**
AAE holds its annual session in Boston
| Fred Michmershuizen

40 **International Events**

| about the publisher

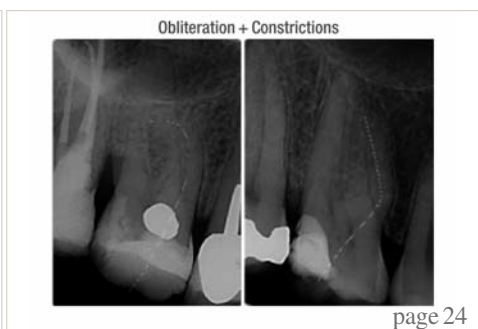41 | submission guidelines
42 | imprint



Cover image courtesy of Produits Dentaires SA
(www.pdsa.ch)



page 20



page 24



page 38

Touch Precision



High-tech apex locator for precise length determination

Sets new standards with respect to user-friendliness and design

- Unique 3-D style colour touch screen
- Smart user interface
- Foldable, pocket-sized design

VDW GmbH
P.O. Box 830954 • 81709 Munich • Germany
Tel. +49 89 62734-0 • Fax +49 89 62734-304
www.vdw-dental.com • info@vdw-dental.com



RAYPEX® 6

Apex locator

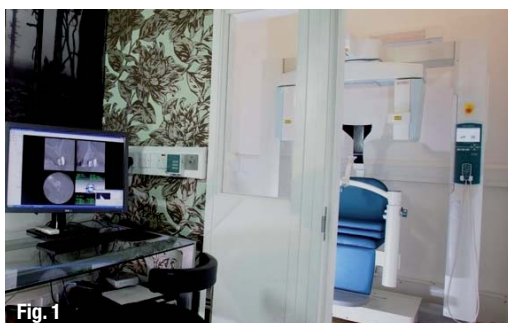


Endo Easy Efficient®

Cone-beam computed tomography in endodontics— Overcoming limitations

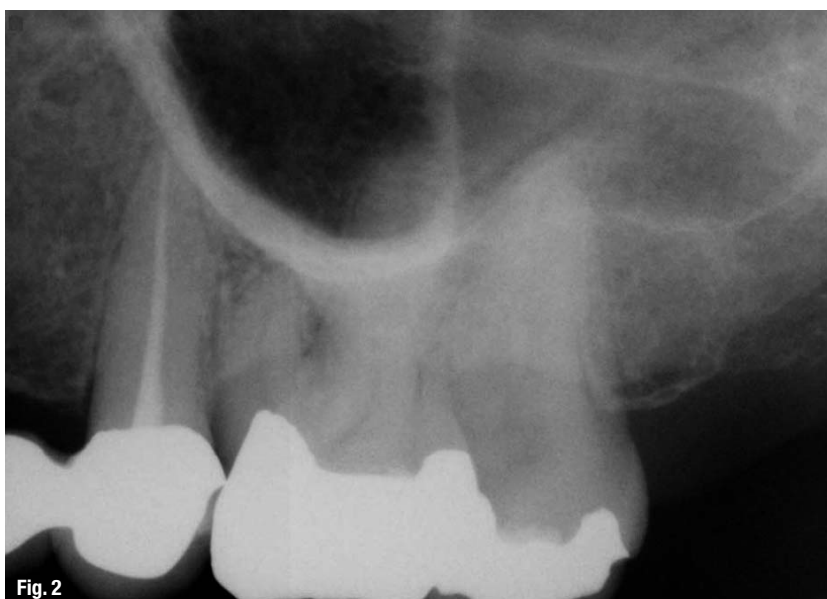
Author_ Dr Shanon Patel, UK

Fig. 1 The Accuitomo CBCT scanner (Morita) housed in a purpose-built acquisition room; the radiographer sits on the other side of the room, allowing her to programme the scanner.



_Introduction

Fig. 2 A periapical radiograph of the upper left quadrant does not show any signs of apical pathology. Note that the zygomatic buttress is obscuring the apices of teeth #26 and 27. Tooth #25 had been root treated to an acceptable standard.



In these situations, it is not uncommon for conventional radiographs (film or digital sensors), taken at several different views of the area of interest, not to reveal anything untoward. This is because conventional radiographs have several limitations. The image is the result of the complex (3-D) anatomy being radiographed being compressed into a 2-D “shadowgraph”; this inevitably results in loss of potentially useful information (for example, the axial plane that is not usually seen with radiographs). The images produced with radiographs, even when taken with a beam-aiming device, have a certain degree of geometric distortion, as it is often impossible to place the image receptor parallel to the long axis of the tooth. Finally, the anatomy overlying the area of interest (for example, zygomatic buttress, cortical bone) often masks the area of interest—this phenomenon is known as anatomical noise.

CBCT may be used to overcome the limitations of conventional radiographs. CBCT is an imaging system that has been specifically designed to produce 3-D images of the maxillo-facial skeleton (Fig. 1). These images are produced quickly and effortlessly, and assessed using relatively simple software on standard PCs.

Having access to CBCT imaging is a tremendous benefit in specialist endodontic practice. Most importantly, using a small field of view, the effective dose to the patient can be kept to a minimum.

The case described in this article demonstrates how CBCT may be used to manage a common diagnostic problem more effectively.

_Case report

A 45-year-old fit and healthy female patient was referred by her GDP for management of her pain, localised to the left side of her face. On presentation,

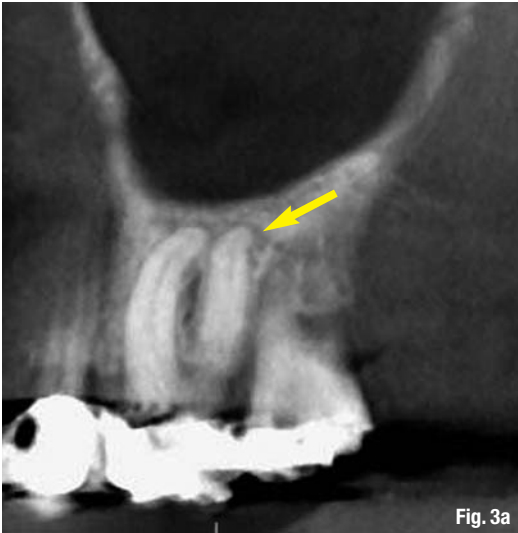

Fig. 3a

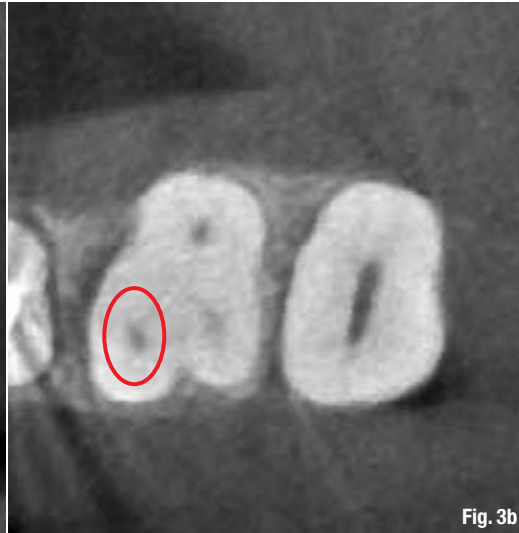


Fig. 3b

Figs. 3a & b Reconstructed sagittal (a) and axial (b) slices clearly show the presence of a periapical radiolucency (yellow arrow), and three canals.

the patient complained of poorly localised pain over the left side of her maxilla. The pain was spontaneous, woke her up at night, and was dull and throbbing in character. These symptoms had been present for five days and were steadily deteriorating.

She had seen her dentist when the symptoms first developed. He examined her and diagnosed tooth #25 as the cause of her symptoms and with her consent root treated this tooth. Unfortunately, the symptoms did not improve after this treatment.

Clinical examination revealed that the upper and lower left quadrants were heavily restored; however, none of these teeth was tender to percussion or palpation. None of the teeth was mobile and all responded positively to vitality testing.

Conventional radiographs did not reveal anything untoward: tooth #25 had undergone a well-executed root-canal treatment, and no periapical radiolucencies could be detected (Fig. 2). A small-volume CBCT scan was taken of the upper left quadrant. Reconstructed sagittal images clearly showed a periapical radiolucency associated with the distobuccal root of tooth #26, and the axial slices revealed the presence of three canals (mesiobuccal, distobuccal and palatal; Figs. 3a & b).

A diagnosis of chronic periapical periodontitis was made for this tooth, and with the patient's consent this tooth was root treated in a single visit under local anaesthetic (Fig. 4). The patient was contacted the following day and reported that she was completely asymptomatic.

Discussion

The key to effective management is accurate diagnosis. Invasive (and irreversible) treatment should not

be carried out until a definitive diagnosis has been made. In this case, a periapical radiolucency was readily detected with CBCT.

Perhaps not surprisingly, this same apical pathology could not be detected with conventional radiography, as the cortical plate and zygomatic buttress masked the pathological changes occurring in the cancellous bone. This case highlights the difficulties that even experienced endodontists commonly face in everyday practice, and demonstrates how CBCT may be used to help make an accurate diagnosis.

The reconstructed axial slices were also useful during examination. They confirmed the number and exact position of the root-canal entrances before treatment was commenced. This resulted in a conservative access-cavity preparation and swift identification of the root-canal entrances, thus allowing treatment to be carried out effectively and efficiently.

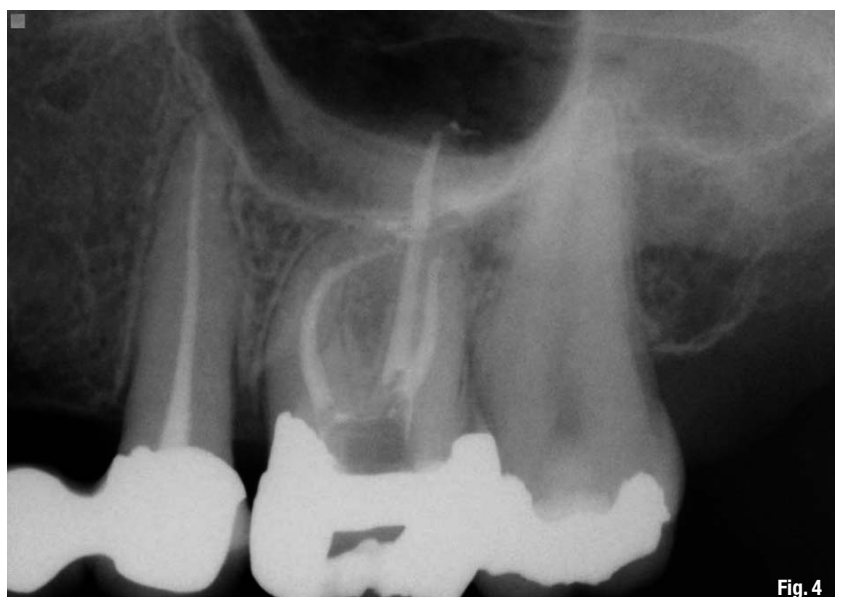

Fig. 4

Fig. 4 Completed root-canal treatment.

_author	roots
<p>Dr Shanon Patel (BDS, MSc, M.Clin.Dent., MFDS Royal College of Surgeons, MRD Royal College of Surgeons)</p> <p>Specialist endodontist</p>	

Diagnosis and management of a longitudinal fracture necrosis associated with an extensive periodontal defect

Author_ Dr Antonis Chaniotis, Greece

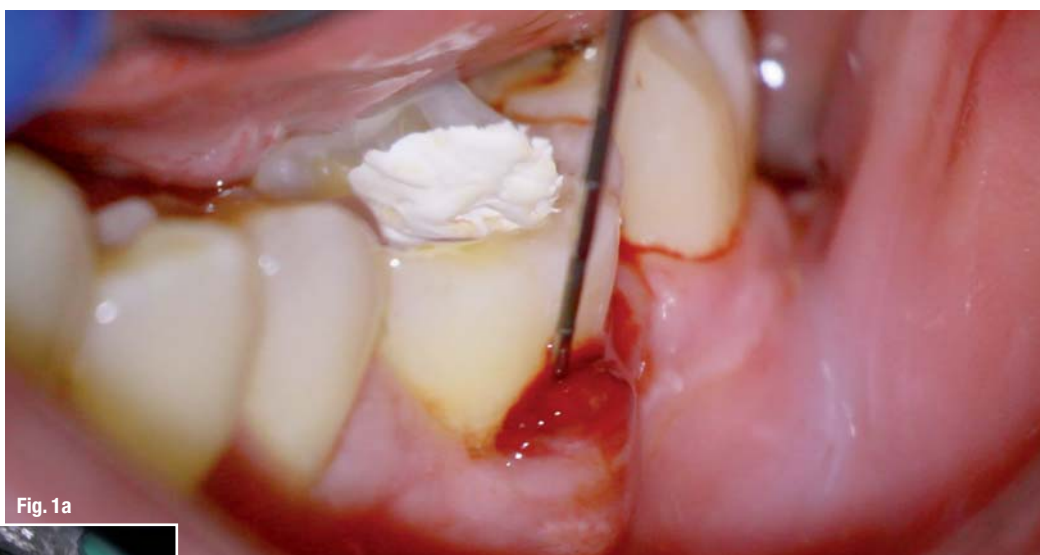

Fig. 1a

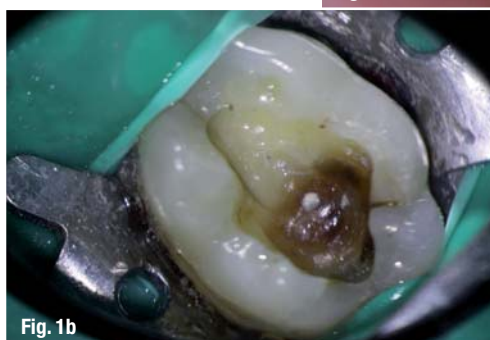

Fig. 1b

Introduction

The terminology and classification of incomplete tooth fractures have received significant attention in the scientific literature for many decades. Numerous terms and definitions have been proposed through the years,

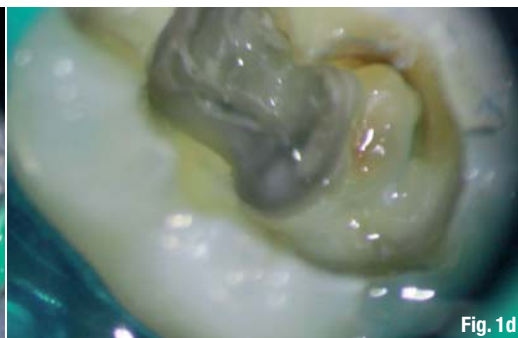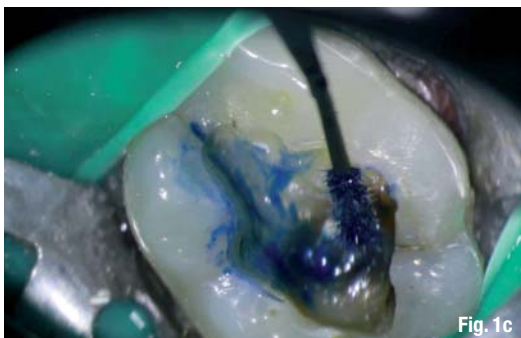
arising from the difficulties related to diagnosis, prognosis assessment and treatment planning. Cuspal fracture (Gibbs 1954), fissure fracture (Thoma 1954), fissural fracture (Down 1957), crack lines and greenstick fracture (Sutton 1961; 1962), cracked tooth syndrome (Cameron 1964), hairline fracture (Wiebusch 1972), split-root syndrome (Silvestri 1976), enamel infraction (Andreassen 1981), crack lines and craze lines (Abou-Rass 1983), and incomplete tooth

fracture (Luebke 1984) are some of the terms used through the years. Many of these terms were used by different authors to describe the same clinical entity.

Recently, the American Association of Endodontists categorised longitudinal tooth fractures into five major classes:

- _ craze line;
- _ fractured cusp;
- _ cracked tooth;
- _ split tooth; and
- _ vertical root fracture (VRF).

Craze lines affect only the enamel, originate on the occlusal surface, are typically from occlusal forces or thermo-cycling, and are asymptomatic.



A fractured cusp is defined as a complete or incomplete fracture initiated from the crown of the tooth and extending sub-gingivally, usually directed both mesiodistally and buccolingually.

A cracked tooth is defined as an incomplete fracture initiated from the crown and extending sub-gingivally, usually directed mesiodistally.

A split tooth is defined as a complete fracture initiated from the crown and extending sub-gingivally, usually directed mesiodistally through both of the marginal ridges and the proximal surfaces.

A true VRF is defined as a complete or incomplete fracture from the root at any level, usually directed buccolingually.

Cracked teeth are thought to occur as a result of para-functional habits or weakened tooth structure. The fractures are incomplete, tend to present in a mesial-to-distal orientation, and are generally centred on the occlusal table. The symptoms that develop subsequent to these cracks have been termed "cracked tooth syndrome". This has been described as acute pain that results during the mastication (or release) of small, hard food substances and is exacerbated by cold. However, the signs and symptoms of a cracked tooth may also be consistent with an irreversible *pulpitis* or *necrosis*.

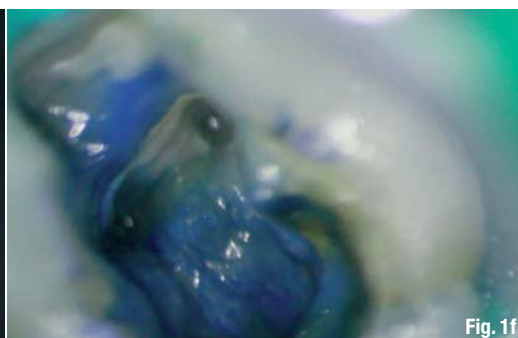Based on the available literature and investigations on root cracks and fractures, it has been suggested that the endodontic prognosis for teeth with

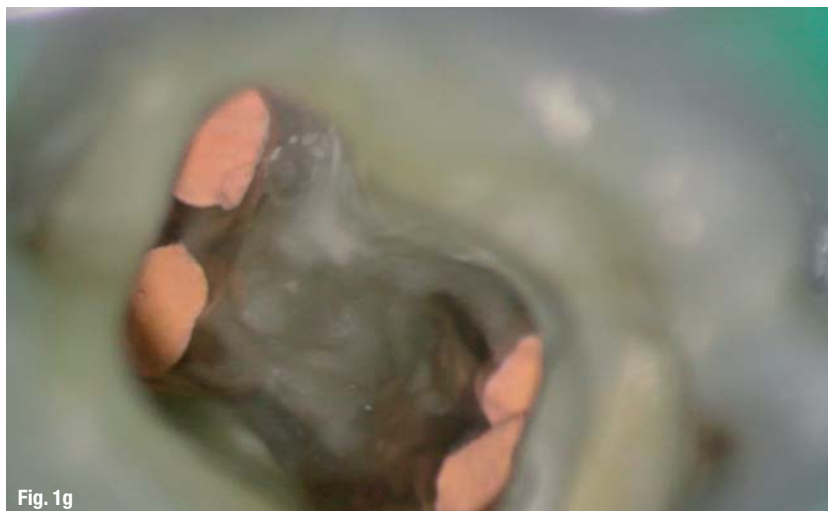these types of cracks is poor, with a high potential for unfavourable post-treatment sequelae. In their paper, Berman and Kuttler (2010) conclude that pulp necrosis, in the absence of extensive restorations, caries or luxation injuries, is likely caused by a longitudinal fracture extending from the occlusal surface and into the pulp. They suggest, based on the available literature, that these types of teeth may have a poor prognosis after endodontic treatment, with the potential ramification of extensive periodontal and/or periapical bone loss. They therefore suggest extraction as the primary treatment option.

Although this conclusion appears reasonable enough, it should be noted that the detection of the incomplete fracture line limits before proceeding to the extraction of a longitudinally fractured tooth is of utmost importance.

The detection of incomplete longitudinal fractures is a challenging task that is very often neglected. Generally, a combination of simple inspection, transillumination, staining with dyes, diagnostic surgery, microscopy and a cone-beam computerised tomography scan is necessary to identify and confirm the presence of cracks. The extraction of cracked teeth without identifying and documenting the fracture line limits is unjustifiable according to the author.

The aim of the present case report is to demonstrate the importance of the diagnostic procedures in the prognosis and treatment planning of incompletely longitudinally fractured teeth.





After administering infiltration anaesthetic, a rubber dam was placed. The temporary filling material was removed and the underlying dentine was stained with methylene blue dye (Figs. 1b & c). A fracture line was detected, extending from the mesial marginal ridge across the dentinal structure to the distal marginal ridge (Figs. 1c & d). The pulp chamber was accessed in order to determine the extent of the fracture line. Upon accessing the pulp chamber, the pulp floor calcifications were removed with ultrasonics under the microscope (Fig. 1e). The pulp floor and the axial dentinal walls were stained again with methylene blue dye and inspected under the microscope (Fig. 1f). No fracture lines or cracks were detected across the pulp floor, while the mesial and the distal fracture line appeared to end before entering the mesiobuccal and the distal root-canal orifices.

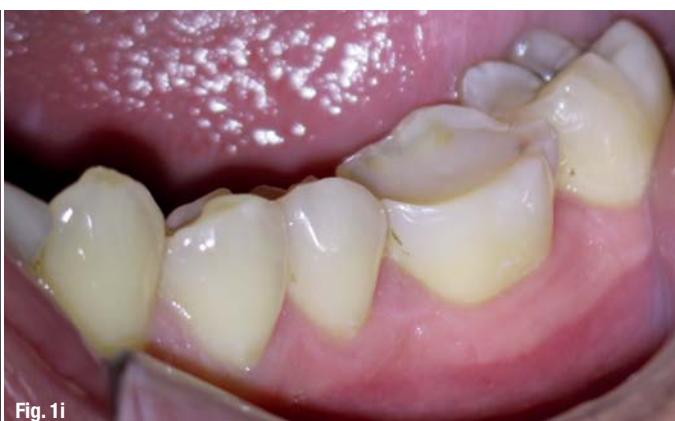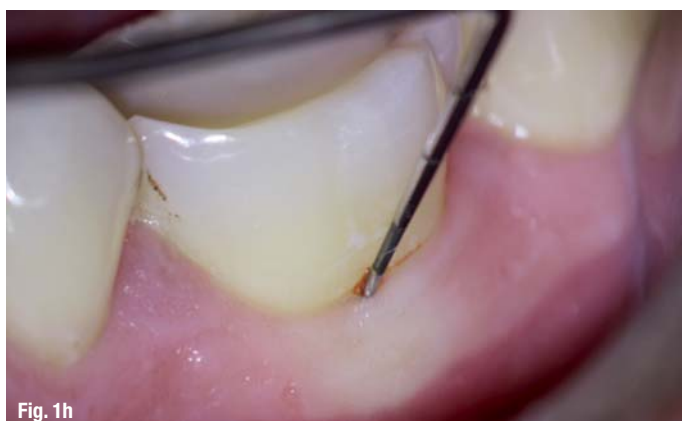_Case report

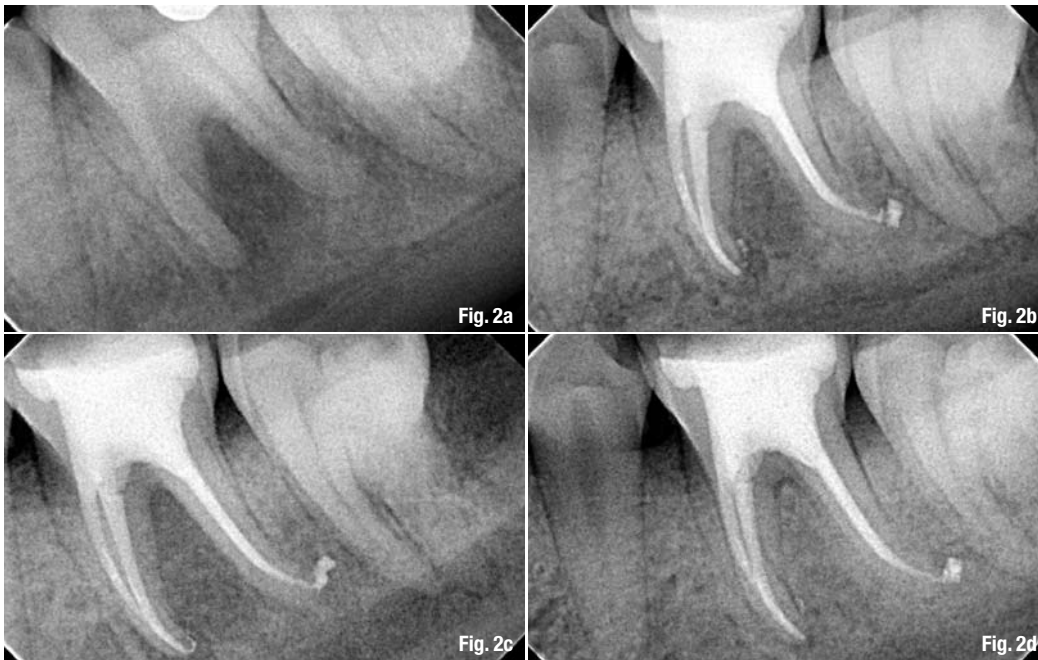A 30-year-old male patient was referred to our endodontics practice for the evaluation and possible treatment of his mandibular left first molar. The referral note mentioned a possible diagnosis of VRF and suggested the extraction of the tooth, followed by grafting and implant placement. The patient's medical history was non-contributory. There was no history of trauma and no para-functional habits were identified. There was a buccal swelling in the furcation area and the tooth was percussion sensitive. The referring dentist had removed the amalgam restoration and placed a temporary filling material. Cold and electric vitality tests were negative. There was a deep buccal periodontal probing defect. The clinical view of the mandibular left first molar can be seen in Figure 1a. The radiographic examination revealed an extensive periapical lesion extending through the furcation area (Fig. 2a).

The clinical and radiographic image indicated an incomplete longitudinal fracture necrosis with an associated extensive endodontic-periodontal defect. A decision was made to seek to identify the fracture line in order to assess the restorability of the tooth.

The fractured tooth was judged as treatable and restorable. Standard non-surgical root-canal treatment was accomplished under the microscope and the tooth was restored using a dual-cured composite resin build-up.

Shaping of the canals was accomplished using the HyFlex CM rotary files (Coltène/Whaledent) and cleaning of the canals was achieved according to a strict irrigation protocol. The irrigation protocol followed entailed syringe irrigation with a 6% NaOCl solution with surface modifiers (CanalPro, Coltène/Whaledent). The irrigation solution was activated with a #15 ultrasonic K-file (SATELEC) after the completion of the shaping procedures (3 x 20 seconds per canal). The canals were dried with paper points and flooded for five minutes with a 17% EDTA solution (CanalPro). The final rinse was achieved using sterile water. The canals were dried again and were flooded for another five minutes with a 2% chlorhexidine solution (Vista Dental). The canals were rinsed again with sterile water and were dried with sterile paper points (Roeko Cellpack, Coltène/Whaledent).





The obturation of the canals was achieved using the continuous wave of condensation technique plus injectable thermo-plasticised gutta-percha backfilling.

The pulp floor chamber was cleaned through sodium bicarbonate sand-blasting (Fig. 1g) and the orifices were covered with flowable dual-cured composite resin under the microscope. The build-up was accomplished using dual-cured composite resin and the occlusion was adjusted. The radiographic image of the tooth after the completion of the root-canal treatment and the build-up can be seen in Figures 2b and c.

The tooth was monitored for one year. The one-year follow-up radiograph revealed uneventful healing (Fig. 2d). The periodontal probing was within normal limits all around the tooth and the clinical view was favourable (Figs. 1h & i).

The patient was referred back to his prosthodontist for full-coverage crown protection. The prognosis of this case was judged as excellent.

_Discussion

The diagnosis, prognosis assessment and treatment planning of cases with incomplete longitudinal fractures can be really challenging. These fractures are very difficult, if not impossible, to identify in the 2-D periapical radiograph. The 3-D small field of view CBCT scan provides far more information. However, even with the CBCT scan, the incomplete fractures might remain undetectable. The clinical identification of the fracture lines and their extent throughout the tooth structure is generally a difficult task.

According to the author, the operating microscope is an indispensable aid for the detailed assessment and documentation of incomplete fractures. A combination of microscopic inspection, transillumination, staining with dyes and diagnostic surgery is what it takes to identify incomplete fractures properly.

The treatment planning of cases with incomplete fractures should not rely on hypothesis, but should always rely on microscopic diagnosis and documentation. Not every single case of a cracked tooth needs extraction. The extraction of incompletely fractured teeth without assessing and documenting the extent of the fracture line is unjustifiable.

_about the author

roots



Dr Antonis Chaniotis graduated from the University of Athens Dental School (Greece) in 1998. In 2003, he completed the three-year postgraduate programme in Endodontics at the dental school. He is a clinical instructor affiliated with the undergraduate and postgraduate programmes in the Endodontics department at the dental school. He has worked in a private practice in Athens limited to microscopic endodontics since 2003.

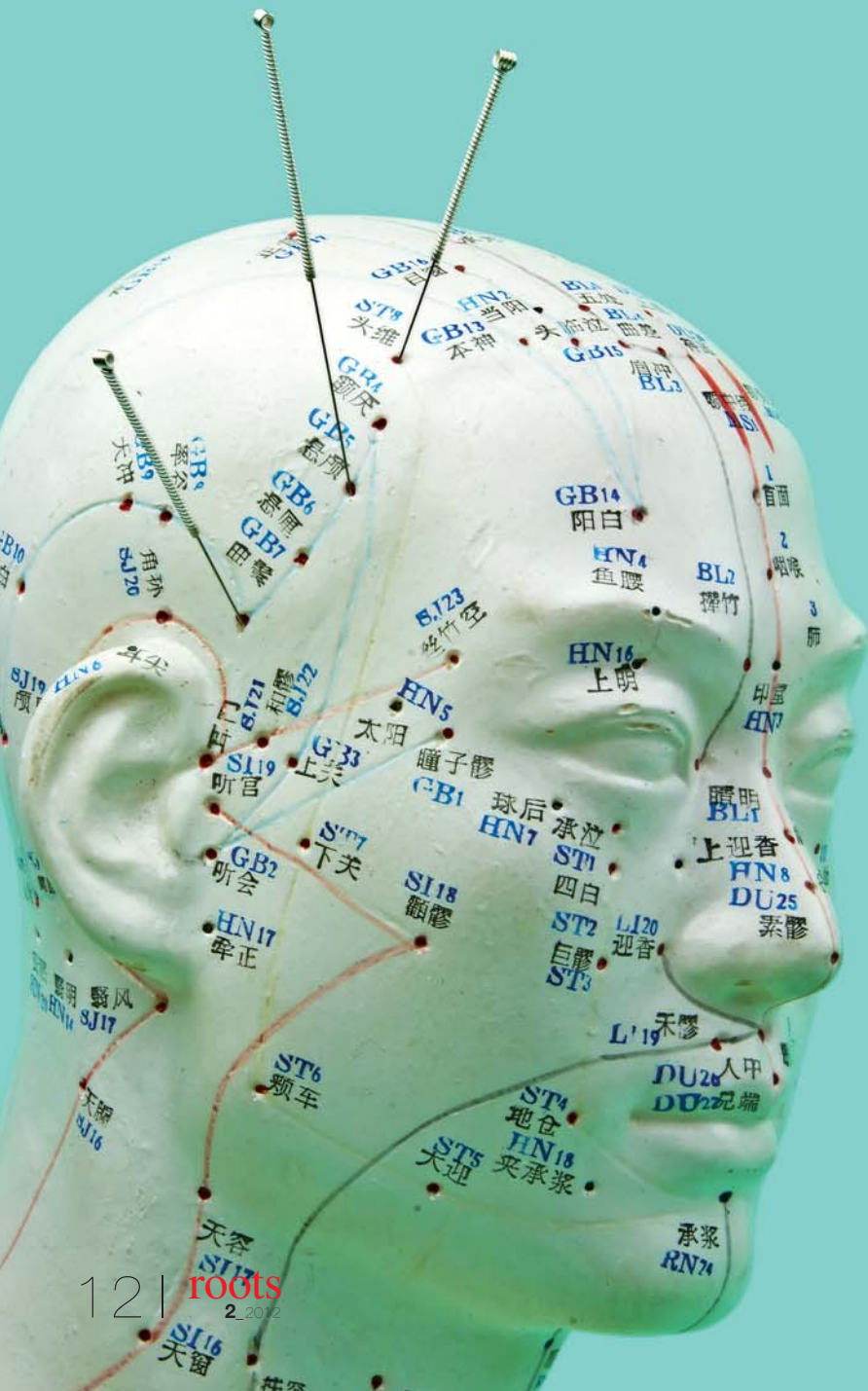He has published articles in local and international journals and he has lectured at over 40 local and international congresses. In 2010, he joined the Roots Forum and became well known for his clinical skills through his microscope-enhanced endodontic video case-management series. He has served as the administrator of the Endo-Implant-Algorithm video blog of the Dental Tribune Study Club since January 2011.

Dr Antonis Chaniotis can be contacted via his e-mail address at antch@otenet.gr or through his website, www.endotreatment.gr

Dental occlusion/TMJ and general body health

Clinical evidence and mechanism of an underestimated relationship

Author_ Dr Yong-Keun Lee & Dr Hyung-Joo Moon, South Korea



During the treatment of symptoms originating from disorders of the temporomandibular joint (TMJ) and occlusion, it was found that restoring the TMJ to its normal condition resulted in a change of general body health. In most cases, this change was improved general body health. Owing to similar reports, a connection between TMJ status and general body health was therefore hypothesised. However, the mechanism of this relationship remains unclear.

In this article, the relationships between dental occlusion/TMJ status and general body health are reviewed with reference to peer-reviewed papers. A conceptual theory is proposed that may explain this mechanism.

TMJ and myofascial pain

Dental occlusion is the relationship between the maxillary and mandibular teeth when they approach each other.¹ The TMJ is the joint of the jaw, which is unique in that it is the only bilateral joint that crosses the midline.² As the treatment of dental diseases aims to achieve harmony within the entire stomatognathic system, teeth could be literally considered to be a set of gears anchored in bone, while the upper and lower jaws are attached to each other by the TMJ.³

The causes of TMJ disorders can be divided into five categories: dental, trauma, lifestyle habits, stressful social situations and emotional factors.⁴ Trauma can be in the form of whiplash, traction appliances and blows to the head, face or jaw.⁴ Evidence of significant trauma to the TMJ has also been found following hyperextension of the cervical spine.⁵ With regard to habits, bad posture, bad ergonomics at work, oral and

FDI World Dental Federation

Leading the World to Optimal Oral Health

2012 Hong Kong

FDI Annual World Dental Congress

29 August - 1 September 2012

10 reasons to join FDI in Hong Kong, World Oral Health Capital 2012

- 1. Celebrate** the uniqueness of FDI at its 100th Annual World Dental Congress;
- 2. Learn** about the latest developments from international and regional experts;
- 3. Discover** the newest technology, equipment, products and materials;
- 4. Interact** with renowned world specialists;
- 5. Empower** yourself through FDI sessions on policy and public and oral health;
- 6. Enjoy** exclusive face-to-face encounters with your peers worldwide;
- 7. Develop** your knowledge and skills through a new and innovative programme;
- 8. Sample** some of the best cuisine in Asia: one restaurant for every 600 inhabitants!
- 9. Marvel** at the breathtaking views of Hong Kong and Macau;
- 10. Uncover** the riches and mysteries of mainland China.



Leading the world into a new century of oral health

ADA CERP® | Continuing Education Recognition Program

www.fdicongress.org

congress@fdiworldental.org

childhood habits, as well as poor diet and strenuous activities such as heavy lifting, have been cited.⁴

Myofascial pain, deriving from the hyperalgesic trigger points located in skeletal muscle and fascia, is commonly characterised by persistent regional pain.⁶ The myofascial component has generally been considered to be part of pain syndromes that involve TMJ. Trigger points in masticatory muscles are presumably caused by malocclusion, misalignment and habitual para-function of the jaws, abnormal head and neck postures, or trauma.⁶

Relationship between TMJ and general body health

There have been several studies on the relationship between occlusion/TMJ and general body health. Among other findings, it has been found that lesions in the masticatory muscles or dento-alveolar ligaments can perturb visual stability and thus generate postural imbalance.⁷ The position and functioning of the mandible also have an effect on the centre of gravity.^{8,9}

“...lesions in the masticatory muscles or dento-alveolar ligaments can perturb visual stability.”

Dental occlusion is associated with reduced lower extremity strength, agility and balance in elderly people.¹⁰ The proper functional occlusion of natural or artificial teeth has been shown to play an important role in generating an adequate postural reflex.¹¹ The subgroups of general body conditions associated with TMJ may be divided into the following three categories:

Synchronisation of the head and jaw muscles with other muscles

There is a necessary systematic synchronisation of the head and jaw muscles with the other muscles of the body to maintain proper body posture. The functional coupling of the stomatognathic system with the neck muscles is well known. Patients suffering from occlusal or TMJ disorders have frequently reported dysfunction and pain in their neck muscles.^{12,13} An imbalance of sternocleidomastoid muscle activity, often leading to neck pain, can be induced by a unilateral loss of occlusal support.¹⁴

The biomechanical impact on cervical vertebrae during mastication has been calculated, which confirmed that vertical occlusal alteration can influence stress distribution in the cervical column.¹⁵ Possible associations between trunk and cervical asymmetry and facial symmetry have been reported.¹⁶ For example, it has been found that visual perception control is most important in orienting the head in the frontal plane.¹⁶ A relationship between dental occlusion and postural control has also been postulated.¹⁷

TMJ and body stability

Dental occlusion/TMJ condition exerts an influence on body stability. Human beings assume a relatively unstable postural state when in the standing position; therefore, the maintenance of a standing position is related to fluctuation in the centre of gravity, which is controlled by information from the ocular region, the three semicircular canals and anti-gravity muscles.¹⁸

It has been suggested that occlusion and head position affect the centre of gravity, resulting in an increased risk of falling when abnormal.¹⁹ Poor or absent dental occlusion may decrease proprioception in this area, interfering with the proper stability of the head posture.⁷ It is thought that tooth loss is a risk factor for postural instability.²⁰ Physiologically, mechanical receptors in the periodontal membrane control mandibular movements and coordinate masticatory function,²¹ and this is related to the motor activity of the neck muscles.²²

Fluctuation in the centre of gravity caused by altering the occlusal contact area experimentally was examined experimentally, and the results confirmed that occlusal contact affects gravity fluctuation and that appropriate occlusion attained by maintaining even occlusal contact in the posterior region is crucial for gravity fluctuation.²³

TMJ and physical performance

TMJ conditions can influence physical performance. Trainers often advise athletes to wear occlusal splints or mouth guards during competitions in order to increase motor performance.²⁴ It has also been reported that proper teeth clenching plays an effective role in the enhancement of physical performance.²⁵

The relationship between the presence of occlusal support in edentulous subjects and their capacity for physical exercise has been investigated, and it was concluded that reconstruction of occlusal support holds significance not only for the restoration of masticatory function but also for the maintenance of physical exercise.²⁶

_Mechanism of relationship between the TMJ and general body health based on the myofascial aspect

It is the first hypothesis of this article that TMJ and other parts of the body are connected through fasciae, which is a connective element between various anatomical structures,²⁷ very similar to a three-dimensional network extending throughout the whole body.^{28,29} This network can be stretched by the contraction of underlying muscles and transmit tension over a distance.^{30,31}

The fascial tissues are arranged vertically, from head to toe, and four interconnected transverse fascial planes criss-cross the body. Therefore, should an injury occur in one part of the body, pain and dysfunction may occur throughout the body.³²

_Mechanism based on qi and the meridian aspect

The second hypothesis is that the TMJ and other parts of the body are connected through the meridian system, which is constituted of the fasciae. Traditionally, acupuncture meridians are believed to form a network throughout the body, connecting peripheral tissues to each other.³³ Studies that seek to understand the acupuncture point/meridian systems from a Western perspective have mainly focused on identifying distinct histological features that differentiate acupuncture points from surrounding tissue.³⁴ One of the histological and anatomical associations with the meridians is intermuscular or intramuscular loose connective tissue (fascia).

Ancient acupuncture texts contain several references to "fat, greasy membranes, fasciae and systems of connecting membranes" through which the qi is believed to flow.³⁵ In terms of connective tissue associations, several authors have suggested that a connection may exist between the acupuncture meridians, which tend to be located along the fascial planes between muscles or between a muscle and bone or tendon, and the connective tissue.^{34,35}

In view of experimental evidence, it has been hypothesised that the network of the meridians can be viewed as a representation of a network of interstitial connective tissues. These findings are supported by ultrasound images showing connective tissue cleavage planes at the acupuncture points in human beings.³⁴ Rather than viewing acupuncture points as discrete entities, it has been proposed that these points might correspond to sites of convergence in a network of connective tissue permeating the entire body, similar to highway intersections in a network of primary and secondary roads.³⁴

_Correlation between trigger points and acupuncture points

Although separated by two millennia, the traditions of acupuncture and myofascial pain therapies share fundamental similarities in the treatment of pain disorders.³⁶ Recent reports have suggested substantial anatomic, clinical and physiological overlap of the myofascial trigger points and acupuncture points.³⁶ The analogy between the trigger points and acupuncture points has been discussed since 1977,³⁷ when 100% anatomic and 71% clinical pain correspondences for the myofascial trigger points and acupuncture points in the treatment of pain disorders were reported.

A number of similarities between them were also suggested. The two structures have similar locations and needles are used at either point to treat pain. The pain associated with the local twitch response at trigger points is similar to the de qi sensation, and the referred pain generated by needling trigger points is similar to the propagated sensation along the meridians.

“...the traditions of acupuncture and myofascial pain therapies share fundamental similarities...”

It was pointed out, however, that the acupuncture points located at the trigger points are not frequently used by acupuncturists, and do not share the same clinical indications as the trigger point therapy.³⁸ It was further argued that the claim of 71% correspondence between the acupuncture points and the trigger points³⁷ is conceptually impossible. Furthermore, even putting this conceptual problem aside, no more than 40% of the acupuncture points correlated with the treatment for pain and, more likely, only approximately 18 to 19% of the points are actually correlated.³⁹ The correlation between the trigger points and the acupuncture points clearly need to be further investigated in the future.

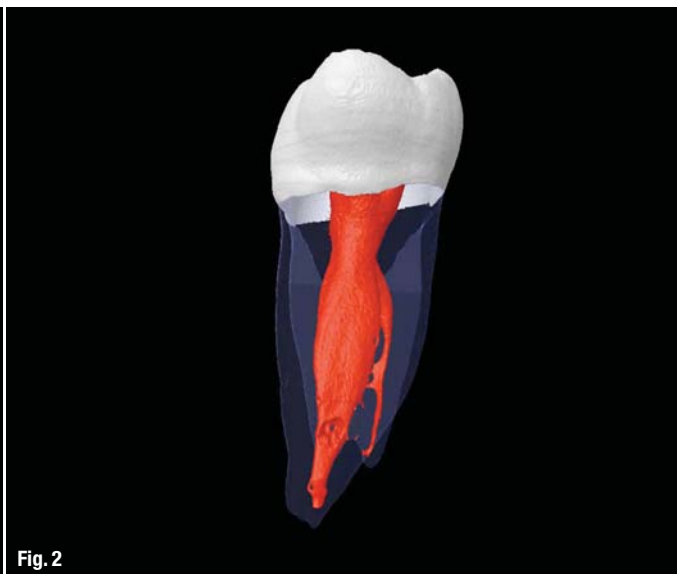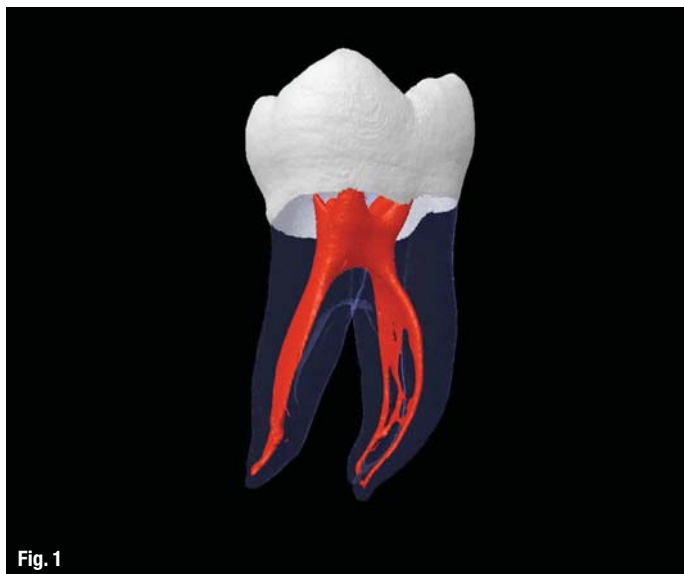The fascial connection theory we propose can explain the functional connection between dental occlusion/TMJ and other parts of the body based on either myofascial release or the qi and meridian system, or a combination of the two. Therefore, dental occlusion should be built up and maintained in a normal natural condition, while causes for deterioration of the TMJ status should be treated in an effort to restore the natural condition.

Editorial note: This article is a summary of two review papers recently published in the Journal of Alternative and Complementary Medicine 17 (2011): 995–1000 & 1119–24. A complete list of references is available from the authors.

_contact

roots

Dr Yong-Keun Lee and **Dr Hyung-Joo Moon** are practicing dentistry at the Moon Dental Hospital and ICPB in Seoul in South Korea. They can be contacted at ykleeedm@gmail.com



Canal anatomy: The ultimate directive in instrument design and utilisation

Author_ Dr Barry L. Musikant, USA

Fig. 1_Mandibular first molar (mesiodistal).

Fig. 2_Mandibular first molar (buccolingual).

It may sound so basic that one would not even think to ask the question, but what constitutes an endodontic education? After teaching thousands of dentists over many years, I believe that the mechanical aspect of endodontic education is a rote exercise. The students are presented with a set of instruments and told how to use them. In the case of K-files, they may be told that the instrument must first engage dentine by rotating the instrument clockwise for the flutes to engage the dentine followed by a pull stroke that cleaves off the engaged dentine, or they may be taught to use these instruments with a watch-winding motion combined with an up-and-down stroke that randomly engages and cleaves small amounts of dentine away. That the K-file also impacts debris and distorts curved canals to the outside wall are considered side-effects that will not occur once the dentist learns how to use these instruments properly. Under any circumstances, any negative side-effects are not considered to be due to deficiency of design so much as the dentist's lack of skill. This mindset solidifies the

continued use of K-files, even as the introduction of rotary NiTi has taken increasing hold.

The course of endodontic instrument development might take a different turn if the choice of instrument design and implementation were based on critical analysis. As it is, the increased adoption of rotary NiTi is confirmation that the pre-existing use of K-files as the sole instruments to shape and cleanse canals is inadequate. What is ironic is that while the adoption of rotary NiTi has been most dramatic, drastically reducing the usage of K-files, this clearly discernible trend has not led to a re-examination of why K-files, now used a good deal less, are still being used at all. The irony is doubly compounded by the fact that as the vulnerabilities, namely instrument separation, of rotary NiTi have become more pronounced, it has led to a rebound in the increased usage of K-files to further shape the glide path so the fracture-prone NiTi instruments are subject to less stress.

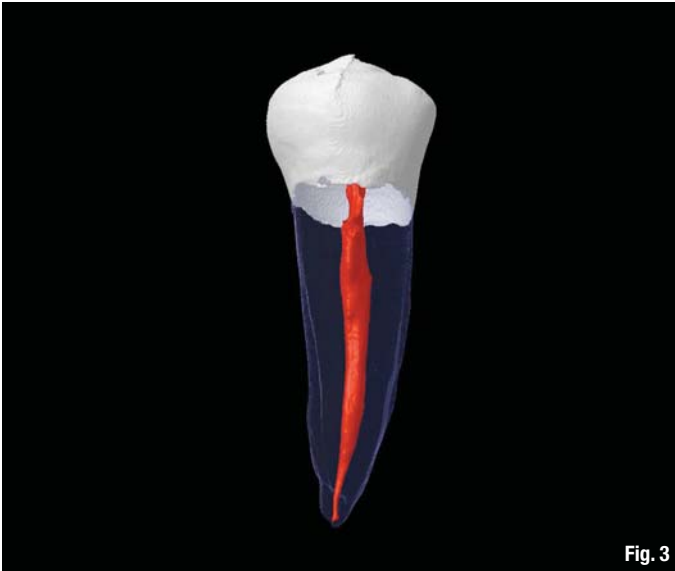


Fig. 3

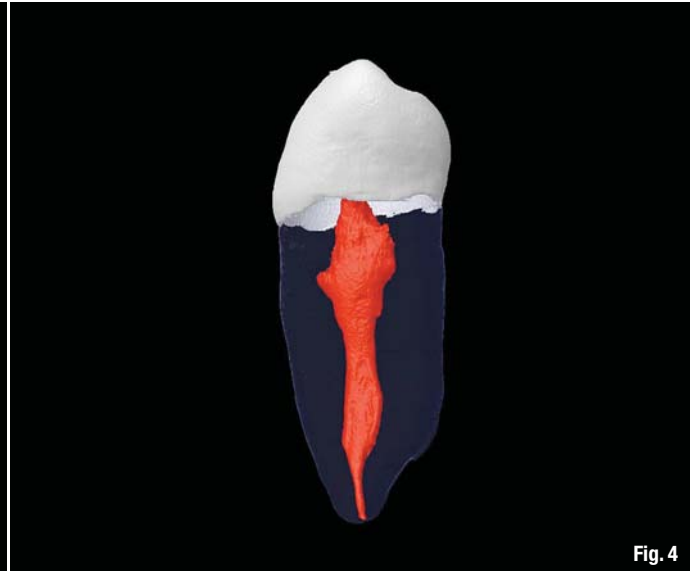

Fig. 4

Increasing the reliance on K-files, a system that demands a substitute in the form of rotary NiTi, represents a dichotomy in that neither system is workable by itself, with the weaknesses of both still present when combined. The result is a balancing act in which each tooth presents its own unique conditions for an ever-changing combination of these two shaping systems, a balancing act that is inherently unstable and leads to a reduced rate of successful outcomes. The most obvious shortcomings of K-files include the impaction of debris and the distortion of curved canals to the outer wall—something already attributed to the lack of operator skill. Rotary NiTi's greatest shortcoming is unpredictable separation, a problem intimately associated with the torsional stress¹ and cyclic fatigue² generated by this form of motion and compounded in canals of increasing curvature. The solution to this weakness is the use of these instruments in reciprocation rather than rotation. The form of reciprocation cho-

sen for these instruments is a hybrid one that still produces 200 full rotations per minute, reducing but not eliminating cyclic fatigue,³ while a 30-degree clockwise stroke compensates for a 150-degree counter-clockwise arc of motion, significantly reducing the torsional stress formerly generated by full rotation.

The introduction of a hybrid reciprocating system without question leads to less instrument separation. Yet, the manufacturer of this system also understood that marketing benefits would be derived if the system were less expensive with fewer instruments being the most direct way to reduce costs. They evidently determined that the increased costs for the one recommended instrument would be acceptable because the overall cost to the dentist for the procedure would be reduced. All that was necessary for this new system to be successful was to convince the dentist that the canal preparations done with one

Fig. 3 Mandibular second premolar (mesiodistal).

Fig. 4 Mandibular second premolar (buccolingual).

Fig. 5 Mandibular incisor (mesiodistal).

Fig. 6 Mandibular incisor (buccolingual).

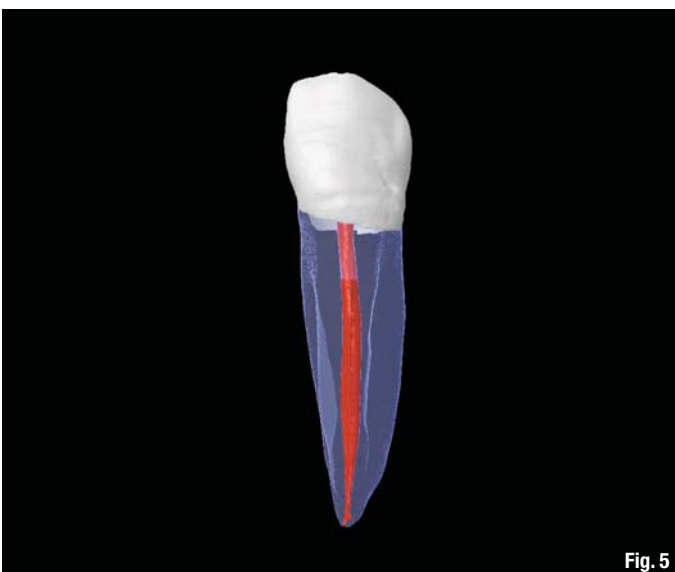


Fig. 5



Fig. 6

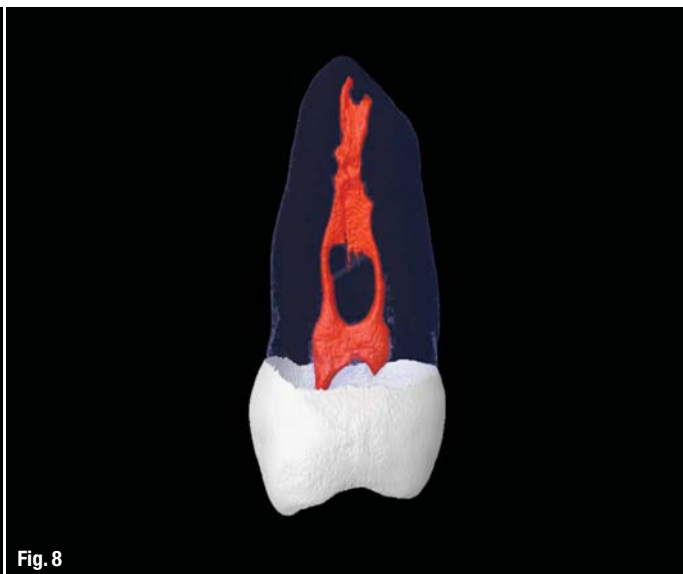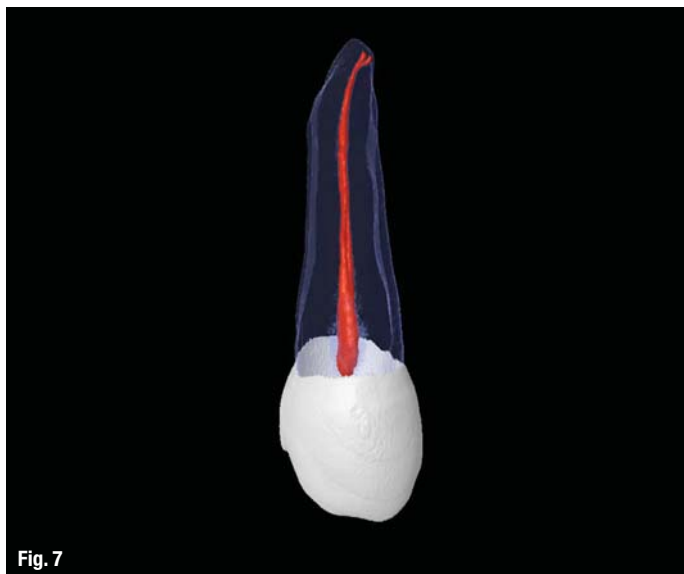


Fig. 7 Maxillary second premolar (mesiodistal).

Fig. 8 Maxillary second premolar (buccolingual).

instrument produce results that are adequate for predictable success.

The greater our understanding of pulpal anatomy as it is, rather than an idealistic rendition that makes for a comfortable fit between results and perception, the better our judgement of what constitutes proper design and utilisation as it relates to the task at hand. The several micro-CT scans shown in this article, generated by Drs Versiani, Pecora and Neto, clearly demonstrate the typical anatomy of various teeth (Figs. 1–8). In addition to anastomoses, divergent branching and cul-de-sacs, the most common feature of pulp tissue is its asymmetric anatomy.⁴ Far from displaying a uniform conical shape, it is most often far wider in the buccolingual plane than the mesiodistal. Thin sheaths of tissue rather than well-defined canals are often present. These anatomical variations present challenges to K-files, mostly because of their high level of canal engagement as they attempt to work themselves apically. They must be used with repetitive vertical strokes to cleanse the buccolingual extensions of these tissue sheaths, a motion that increases the chances of debris impaction blocking further access to the apex. Both hybrid reciprocating NiTi and full rotary NiTi systems

tend to stay centred within the canal and, as many studies point out, the wider extensions of oval canals are not cleansed. If the canal is prepared to a maximum of 25.08, it may look adequate in the mesiodistal dimension, but be totally inadequate in the buccolingual plane, where the canal diameter is often five to six times greater. A canal may look very much like our ideal preconception in one plane and totally invalidate that perception when seen after 90 degrees of rotation.

If the cleansing of highly asymmetric canal anatomy is the goal that drives instrument design, then what we have at present is too often not up to the task. What we need are more rational designs based on a critical analysis of the interaction between design utilisation and results. Let's consider the use of relieved reamers designed with a flat (Fig. 9) along their entire working length used in a watch-winding motion that may be generated both manually and in a 30-degree reciprocating handpiece. All the instruments, including a thin 0.06 mm tipped reamer, have vertical flutes that when used with a horizontal watch-winding motion will immediately shave dentine away. The vertical pull stroke is simply employed for carrying the debris occupying the flutes in order

Fig. 9 A relieved reamer with a flat side. Note the decreased number of vertically oriented flutes.

Fig. 10 A K-file. Note the increased number of horizontal flutes.



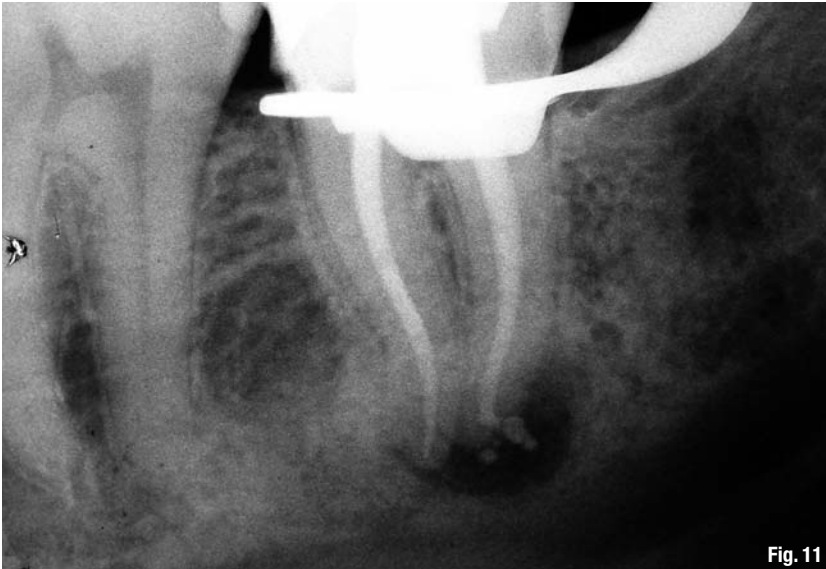


Fig. 11

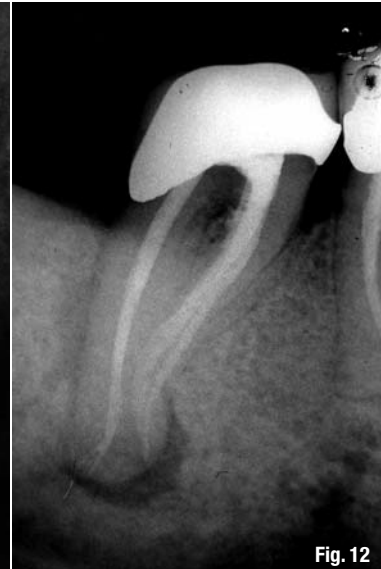

Fig. 12

to be brought coronally and wiped away. The vertical orientation of the flutes tends to sweep through any debris that may be present in the canal when the reamers are directed apically, rather than impacting debris apically the way the horizontal flutes on a K-file (Fig. 10) tend to do.⁵ With full depth far more easily attained with a relieved reamer than a K-file, leaning the vertically oriented blades against a broad sheath of tissue is more likely to remove that tissue than if the main function of the blades is to engage and disengage until the pull stroke is employed, an action that occurs with K-files.

Unbeknownst to most dentists, NiTi instruments are predominantly shaped like reamers even though they are still called files. They recognise the inherent advantages of an instrument that shaves dentine away rather than first embedding into it. Yet, NiTi instruments must stay centred, lest they encounter anatomy that may lock and bind anywhere along length.⁶ Locking and binding is good for neither NiTi nor stainless steel, but where there is a large gap between deformation and fracture for stainless steel, NiTi has little room between the two, effectively allowing for safe usage within very narrow margins. These narrow safety margins empirically appreciated by dentists are major incentives for conservative NiTi canal preparation, which in light of the real anatomy that must be instrumented can lead to inadequate shaping and cleansing.

What I am attempting to show here are the possible consequences that occur simply because the instruments that have been traditionally employed are not designed to treat the canal anatomy as it is. It may provide pleasing results when viewed in the mesiodistal plane, but micro-CT scans clearly tell us there is far more to the story that must be addressed. Graduating dentists will be far more able to make

sensible, rational decisions if they are taught instrument design as it relates to function, which in turn will produce results that are consistent with the stated goals. That is far better than using instruments that meet our ideal preconception of a canal anatomy that often exists nowhere but in our minds.

Editorial note: A complete list of references is available from the publisher.

Images by Prof. Marco A. Versiani, courtesy of The Root Canal Anatomy Project (original images can be found at rootcanalanatomy.blogspot.com)

Figs. 11 & 12—These radiographs show the ability of flat-sided reamers (SafeSiders) used in a reciprocating handpiece (Endo-Express) to shape, irrigate and clean irregular-shaped canals effectively. They were used without the fear of binding or breakage.

Figs. 1–12 (Courtesy of Dr Barry Musikant)

_about the author

roots



Dr Barry Lee Musikant is a member of the American Dental Association, American Association of Endodontists, Academy of General Dentistry, Dental Society of New York, First District Dental Society, Academy of Oral Medicine, Alpha Omega International Dental Fraternity and the American Society for Dental Aesthetics. He is also a Fellow of the American College of Dentistry. His 35-plus years of practice experience as a partner in the largest endodontic practice in Manhattan has established him as one of the top authorities in endodontics.

To obtain more information about Dr Musikant, please visit www.essentialseminars.org, e-mail info@essentialseminars.org or call +1 888 542 6376.

_contact

Dr Barry Lee Musikant
Essential Dental Systems, Inc.
89 Leuning Street
S. Hackensack, NJ 07606
USA

info@edsdental.com

WaveOne— First experiences of third-year students

Author_ Prof Michael A. Baumann, Germany

Rotary root-canal instrumentation with NiTi files has been very successful over the last 20 years. Starting with ProFile (DENTSPLY Maillefer) in 1994, the time-consuming and complicated hand instrumentation of root canals, which had dominated endodontic procedures for more than a century, was replaced with a totally new approach.

In the beginning, that is the 1990s, there was a debate about the advantages and disadvantages of the new NiTi files and about an initially high fracture rate. Before long, knowledge about the behaviour of the new material, correct handling, auxiliary support of specific endodontic motors with torque-control mechanisms and the understanding of cyclic versus torsional fatigue, the advantage of a crown-down approach and many, many more details led to a breakthrough in this new area. The initial fears—that a rotary instrument would screw into the root dentine too deeply and become stuck or fractured—led to a radial land design.

Table I Results of the study by Roane and Sybala (1984), showing that most fractured K-files in daily practice result from use in CW motion.

	Number	Percentage
Complete separation CCW	29	5.9
Complete separation CW	37	7.5
Partial separation CCW	0	0
Partial separation CW	21	4.3
Distortions of the flutes CCW	13	2.6
Distortions of the flutes CW	393	79.7
Fractures CW	451	91.5
Fractures CCW	42	8.5
Total	493	100

Table I

At the turn of the millennium, the first files with sharp edges, such as FlexMaster (VDW) and ProTaper (DENTSPLY Maillefer), were introduced to the market and the triangle cross-section was diversified, ranging from two sharp edges to three (which still is the most frequently used type), four or five. In addition, a variety of sizes and tapers were introduced.

In 2008, Ghassan Yared published his idea of using only one file from the ProTaper system, the F2 (#25 at the tip and 0.08 taper in the first 3 mm), in the ATR motor, which enabled the user to programme the file movement in a reciprocating file motion at self-defined angles and time. This idea goes back to Roane, who discussed clockwise (CW) and counter-clockwise (CCW) movement of K-files¹ and introduced the balanced force technique in the early 1980s.²

In 1984, Roane and Sybala evaluated 493 used K-files from an endodontic practice. In a preliminary test, new K-files were rotated CW and CCW until they broke and exhibited a special, totally different and characteristic fracture pattern for each movement. This pattern had been delineated by Chernick et al.³ Roane and Sybala concluded that file damage predominantly occurred when the K-files were used in a CW motion (91.5%), whereas the CCW motion caused distortion or separation in less than 10% of cases (Table I).

“This observation is explained by the fact that counterclockwise rotation unthreads the instrument, decreasing its load and releasing its cutting edge. Clockwise rotation threads the instrument into the canal and increases its load until its cutting edges cease to rotate. At that point, the instrument shaft must either distort or separate unless the operator terminates the rotation.”¹



Fig. 1 WaveOne files: Small, primary and large.

With these facts in mind, Roane et al. published another article in the following year, describing the 'balanced force' concept for instrumentation of curved canals, in which they state: "Its concepts use force magnitudes in order to create control over undesirable cutting associated with canal curvature. Rotation is promoted as the means for maintaining magnitude as a control and CCW direction of rotation provides finite operator control."² They thus suggested combining CW and CCW motion in root-canal instrumentation to prevent breakage of K-files and preserve curved canals much better than before. To obtain this result, they introduced a new K-type file with a parabolic tip, expecting that the load would be distributed and reduced to below the regular cutting magnitude.

Today, the balanced force concept is taught in many dental schools and is well known all over the world. When the new NiTi instruments appeared in the early 1990s, the constant rotation of files at a speed of 250 to 350 min⁻¹ appeared to be the gold standard over the next few decades. With Yared's idea⁴—combining CW and CCW when using NiTi files, namely the ProTaper F2—both ideas were unified.

Yared suggested the use of a #8 stainless-steel hand file to negotiate the canal to working length using an apex locator and #10 or 15 files only in severely curved canals. This is followed by the 25.08 ProTaper F2. The CW rotation is greater than the CCW rotation. In this manner, a CW motion screws the file into the canal and a CCW motion unscrews it. As CW is greater than CCW, the file automatically passes more deeply into the canal and the user is warned to avoid apical pressure that will force the instrument deeper still.

Yared's idea triggered the design of a new instrument and motor that would fulfil the requirements

of a reciprocating technique, the WaveOne system. WaveOne is available in three sizes—21.06, 25.08 and 40.08 (Fig. 1)—and comes with the WaveOne motor, which is programmed to move the file in the special reciprocating motion. The main advantages of WaveOne are:

WaveOne enables the realisation of the one-file concept

Only one file is needed for a single tooth. In some cases, molars demand two WaveOne files, namely the small or primary for the buccal and the large for the palatal canals. This replaces the use of numerous files necessary in the past. The files may be used as disposable instruments because of a lower price, which may be accepted more easily by the patient than the higher prices of a complete set of files used with other systems.

WaveOne lowers the fracture risk

The fracture risk of NiTi files is low, with a deformation rate of 0.75% for ProFile and 2.9% for ProTaper. Instrument separation occurs in 0.26% for ProTaper and 0% for ProFile.⁵ Nevertheless, practitioners still fear file breakage. The reciprocating motion respects the fatigue threshold of NiTi alloys (Fig. 2) far better than a constant rotary motion, which leads to a lower fracture risk than with conventional NiTi files.

WaveOne reduces the risk of prion transmission

"The risk of vCJD transmission through endodontic procedure compares with other health care risks of current concern, such as death after liver biopsy or during general anaesthesia. These results show that

Fig. 2 Relationship between torque (gcm) and angle of rotation (degrees). A NiTi file tolerates about three to four complete rotations before it fractures. When used in a reciprocating motion, the angle of rotation always stays within a rotation of no more than 360°.

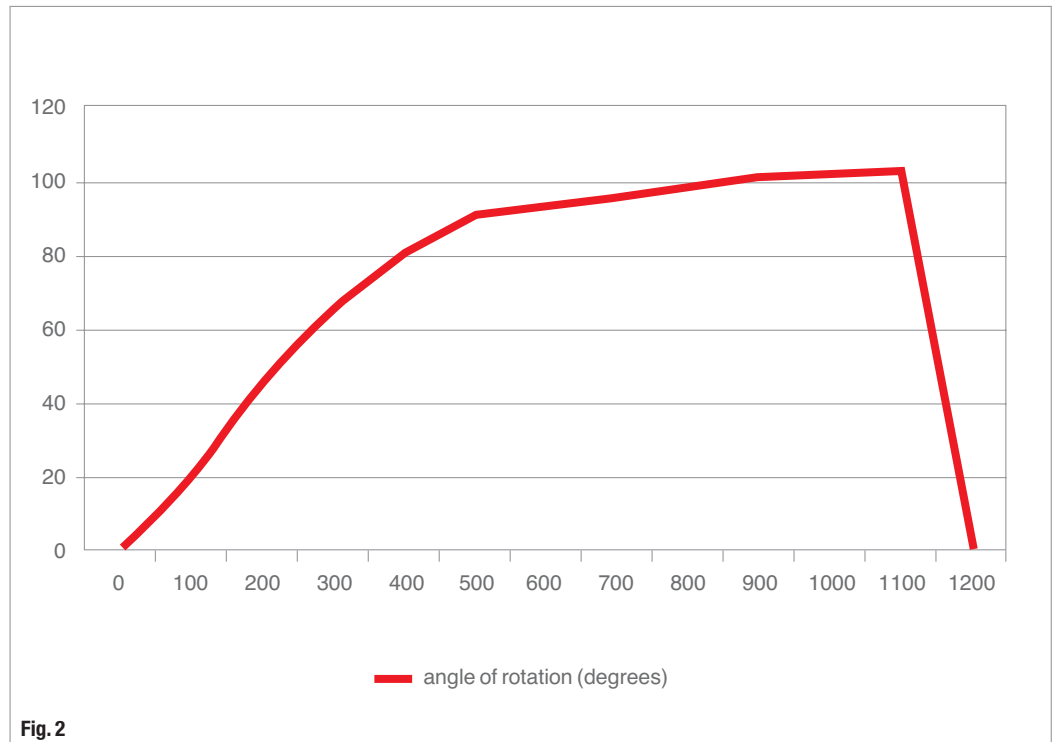


Fig. 2

single instrument use or adequate prion-decontamination procedures like those recently implemented in dental practice must be rigorously enforced.”⁶ The prion decontamination of endodontic instruments appears to be an extremely difficult procedure. Instruments cannot be cleaned through NaOH, NaOCl or guanidine thiocyanate immersion for 24 hours or through steam sterilisation. “Uniformly, debris could not be completely removed. [...] Based on these findings, single use of nickel-titanium rotaries appears to be beneficial.”⁷ This finding led to the recommendation by the Department of Health in the UK in 2007 and some manufacturers of dental instruments to use disposable (single-use) instruments:

“The transmission of vCJD via dentistry is considered to be low risk! However, the Department of Health (DoH) has recently advised dentists to ensure that as a precautionary measure endodontic reamers and files are treated as single-use in order to further reduce any risk of vCJD transmission.”⁸

In contrast, Julian Webber, the editor of *Endodontic Practice*, sent a letter to the editor of the *British Dental Journal* published in June 2007, requesting less “draconian advice.”⁹ Webber stated that no prions had been found in the dental pulp^{10,11} and that there was no proof for the iatrogenic transmission of CJD in dentistry.¹²

Schneider et al.¹³ conducted a study with knockout mice and human teeth using three methods: immunohistochemistry, cell culture and SEM. They state, “In human teeth, cementoblasts and odontoblasts showed prominent staining for PrP (Prion Protein) at levels comparable to those of nerve fibers. [...] Periodontal and pulpal tissue exposed by disease or trauma might represent a clinically relevant entry point for prions incorporated orally and thus a possible mode of infection.” This means they did not find prions in teeth but a staining of pulpal cells in several tissues, which indicates that prion-like proteins can be found physiologically in the dental pulp.

In an initial trial with the aim of collecting information about the routine use of WaveOne files, third-year dental students at the University of Cologne,

Table II Instrumentation time using WaveOne and hand files.

	WaveOne (time in s)	Hand files (time in s)
	30	251
	25	210
	38	223
	41	129
	22	299
	14	346
	12	163
	17	328
	34	224
Total time	233	2,173
Mean	23.3	217.3

Table II



Fig. 3a, b A plastic block instrumented with WaveOne (#020) and another after hand instrumentation (#023). In the middle, the dark/black area indicates the original canal and the surrounding grey silhouette shows the root-canal geometry after shaping. With WaveOne, a sharp, continuous and smooth shape was created. In contrast, a canal instrumented with a hand file is disrupted and has a more transported shape with zipping and ledging.

Germany, were given the opportunity to work with the WaveOne primary file (25.08). These students have little experience with root-canal treatment because they only work on six teeth (two incisors, two bicuspid and two molars) and a plastic block during their sixth term. Instrumentation is taught through the initial use of hand files up to #15 for creating a glide path and using ProTaper or FlexMaster in a constant rotary motion with the ATR motor.

At the end of this course, ten students were selected to participate in a pilot study. The students were introduced to the handling of WaveOne files and the balanced force technique. The students then instrumented endodontic plastic blocks with WaveOne files and other blocks with hand instruments (K-files) using the balanced force technique with the #30 AMF and with step-back to #50 to reach comparable sizes with the 25.08 WaveOne file (Fig. 3).

The results show that the mean instrumentation time (without file exchange and rinsing) for WaveOne with 23,3s was much more shorter than for hand instrumentation with 217,3s (Table II). The students were nearly ten times faster with WaveOne than with hand instrumentation (between 129 to 346 seconds). No instruments were fractured, which suggests that even inexperienced students were able to instrument plastic blocks easily and quickly (between 12 and 41 seconds). In addition, the resulting shape with WaveOne was much better, smoother and without zip, elbow or ledge formation.

In summary, upon initial observation, WaveOne is a promising system that is easy to learn for first-time users, results in less breakage and allows the use of one single-use instrument.

Editorial note: A complete list of references is available from the publisher.

_about the author

roots



Prof Michael A. Baumann is Head of the Division of Endodontics at the Department of Operative Dentistry and Periodontology at the University of Cologne's Dental School. He was one of the founders of the German Society of Endodontology (DGEndo) in 2002 and held positions as vice-president and president. He has written seven books mainly on endodontic topics, the most well-known being the *Color Atlas of Endodontology* (2009), which originally appeared in German (in 2007) and has been translated into English, Spanish, Italian and Portuguese. His *Pocket Atlas of Endodontology* has been translated into English, French, Portuguese, Turkish, Russian, Taiwanese, Chinese, Russian and Ukrainian.

Prof Michael A. Baumann

Department of Operative Dentistry and Periodontology
Dental School
University of Cologne
Kerpener Straße 32
50931 Köln
Germany

Scouting the root canal with dedicated NiTi files

Authors_ Dr Gilberto Debelian, Norway, & Dr Martin Trope, USA

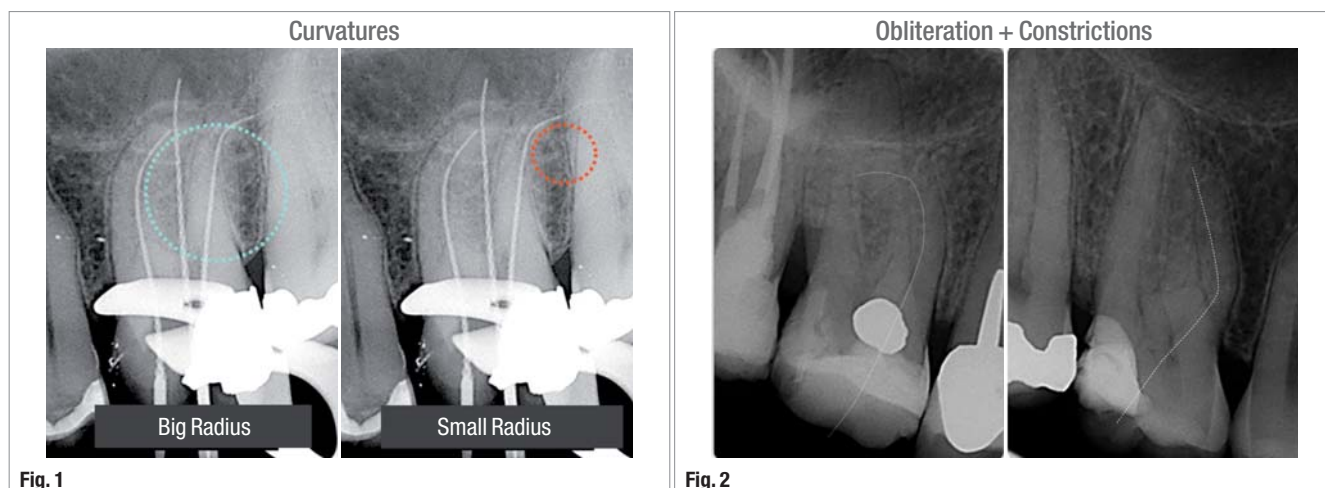


Fig. 1 A large curvature radius is noted (blue) in the mesiobuccal (MB) canal and a small curvature radius (red) in the distobuccal canal. Metal fatigue of NiTi files will increase with small radius curvatures.

Fig. 2 Obliteration (Case I) and abrupt coronal curvatures and/or coronal constrictions (Case II) can contribute to metal fatigue of NiTi files.

The introduction of nickel-titanium (NiTi) rotary instrumentation has made endodontics easier and faster than with hand instrumentation. In addition, root canal preparation is more consistent and predictable. However, fracture of NiTi files remains a major risk. Fracture results from either cyclic or torsional fatigue.¹⁻⁸

In clinical practice, cyclic fatigue will increase in curved canals (the smaller the curvature radius or double curvature the higher the risk) and torsional fatigue in small and obliterated canals (tip lock; Figs. 1-3). The type of NiTi files (design, taper, size) and the instrumentation technique (crown-down or step-back, brushing or pecking motions) may overcome these anatomic challenges and prevent file separation. Another major clinical technique for reducing the risk of NiTi file separation is to perform coronal enlargement and manual pre-flaring to create a glide path before using NiTi rotary instruments (Fig. 4).⁹⁻¹¹ It has been shown in the literature that establishing a glide path

by coronal pre-flaring and manual canal scouting is a fundamental clinical step for safer use of NiTi rotary files. Berutti et al.¹² have shown that creating a manual glide path with a #20.02 manual stainless steel (SS) file decreases the frequency of NiTi rotary file separation by six times. However, creating a glide path and coronal pre-flare with small SS files (#06-08) in curved, constricted or obliterated canals will result in several clinical complications, such as file deformation, buckling, separation and the need to use several instruments (Fig. 5). This is because SS small-diameter files are highly flexible, often leading to torsional fatigue and flute deformation. In addition, straightening of the original canal can occur with the use of even these small files in severely or double-curved canals.

Recently, FKG Dentaire introduced its Scout-RaCe and RaCe ISO 10 files, NiTi rotary file systems for mechanical pre-flaring and creating a glide path to replace SS hand filing at this phase of canal preparation. It has been demonstrated that the use of these NiTi

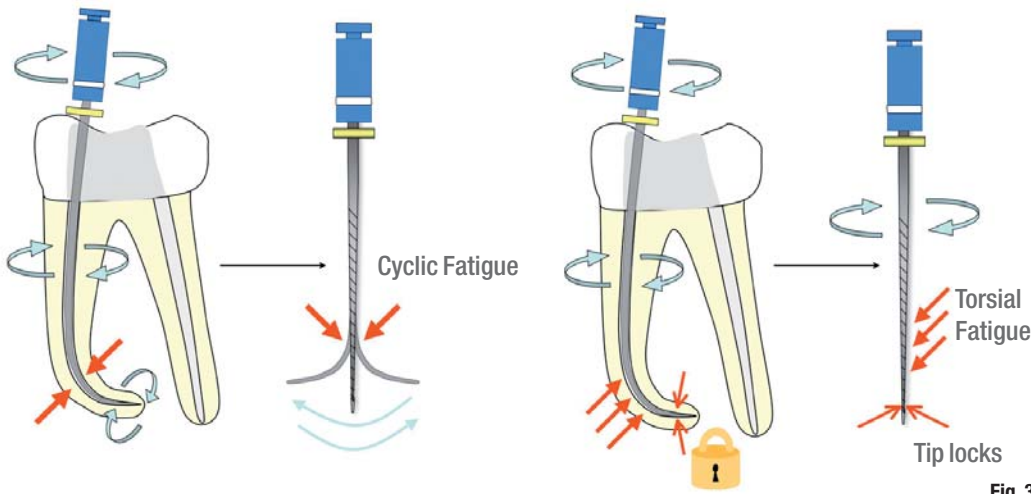


Fig. 3 Cyclic fatigue of NiTi files will increase as a result of a small curvature radius, which is further exacerbated by keeping the file in the same position while rotating or inflexible files. Torsional fatigue will increase as a result of canal constriction and obliteration, exacerbated by flexible files (unwinding), and excessive vertical pressure.

Fig. 3

instruments prior to the main NiTi rotary files better retains the original canal anatomy, with less modification of canal curvature and fewer canal deviations compared with manual pre-flaring performed with SS K-files.^{8,12} In addition, challenging canals that would take a considerable amount of time to initiate with SS files can be completed quickly with this new technology.

In this case report, we will present the indications and protocols for the use of Scout-RaCe and RaCe ISO 10 files (Fig. 6).

Scout-RaCe files

This system consists of three NiTi files with a RaCe flute design (alternating cutting edges), which is considered to be a non threading design owing to its alternating pitch from parallel to spiralled zones.¹⁴⁻¹⁷ The surface of these files is electropolished in order to remove all irregularities produced during grinding. The tips are non-cutting and rounded. They are produced in lengths of 21 and 25 mm with a 0.02 taper. They have a triangular cross-section and come in sizes #10 (purple), 15 (white) and 20 (yellow). These files have two silicon stoppers, one called SMD (safe memory disc), which lies close to the handle and is

yellow, indicating the taper of the files (0.02), and a smaller stopper that indicates the length of the files (red = 21 mm and blue = 25 mm). These files are used in severe single or double-curved canals and they will primarily scout the canals with minimal coronal flare (Fig. 7).

Clinical protocol for Scout-RaCe files (severe single and double curvatures):

1. If possible, use a #06 or 08 K-file file to reach the estimated working length (WL). Confirm the length with an electronic apex locator (EAL).
2. Irrigate with NaOCl.
3. With gentle strokes at 600rpm, widen the canals with the #10, 15 and 20 Scout-RaCe instruments to full length. Since these files are very flexible, avoid excessive pressure to prevent buckling. Irrigate the canals with NaOCl between files and clean the files if used for more than four strokes. Use a #15 K-file to obtain a smooth glide path and confirm the WL with an EAL.
4. Continue with the main NiTi sequence (BioRaCe, Sequence files, etc.; Figs. 8 & 9).

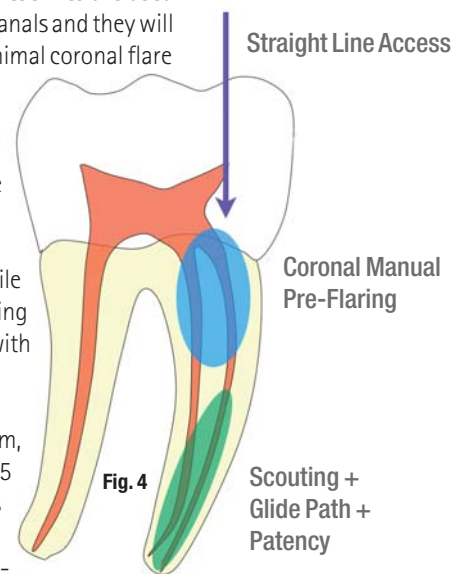


Fig. 4 The risk of NiTi separation is reduced by straight-line access, coronal pre-flaring and the establishment of a glide path.

Fig. 4

Manual Scouting




Complications

- Deformation
- Buckling
- Separation
- Several instruments
- High cost

Small diameter and taper

- High flexibility
- Lack of rigidity
- High torsional fatigue

Fig. 5

Fig. 5 Manual scouting with SS files.

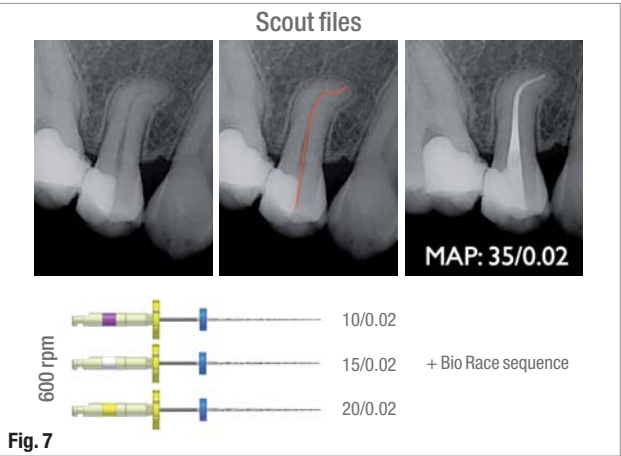
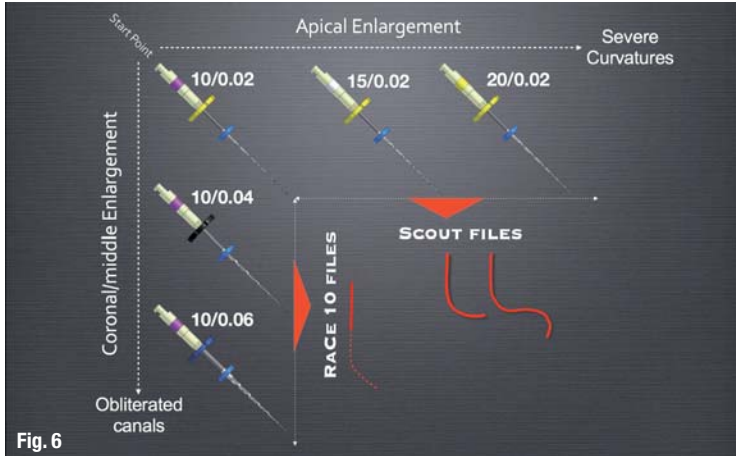


Fig. 6 Scout-RaCe and RaCe ISO 10 clinical applications and protocol.

The Scout-RaCe files are used in severely and double-curved canals, whereas the RaCe ISO 10 files are used in obliterated and calcified canals.

Fig. 7 Clinical case of a maxillary premolar with an S-shaped curvature. The glide path created by Scout-RaCe files allowed the NiTi sequence to be followed without straightening the canal or file separation.

RaCe ISO 10

This system consists of three NiTi files with the same RaCe flute design as described above. They are produced in lengths of 21 and 25 mm. The difference between Scout-RaCe and RaCe ISO 10 is that these files progressively increase in taper but maintain the same apical diameter of 0.10 mm. These three files come in size #10 and tapers of 0.02, 0.04 and 0.06 (Fig. 6).

The SMD silicon stopper is yellow for the 0.02 taper files, black for the 0.04 taper and blue for the 0.06 taper. The colour of the small silicon stopper indicates length as with the Scout-RaCe files. These files are meant to be used in constricted and obliterated canals, as well as in abrupt coronal curva-

tures. These files, like the Scout-RaCe files, will also scout the canals but because of the progressive increase in taper will primarily perform coronal flaring (Fig. 10). The #10.04 and 10.06 RaCe ISO 10 files are more rigid than the #15 and 20 Scout-RaCe files, and that is why they are for use with vertical pressure for constricted or obliterated and curved canals (will not buckle as easily as Scout-RaCe files) and are not ideal for double and severe curvatures.

Clinical protocol for RaCe ISO 10 files (constricted or obliterated canals):

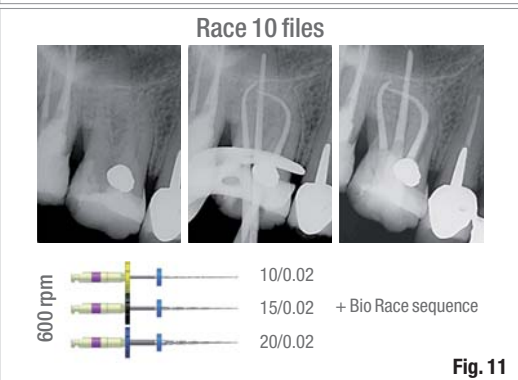
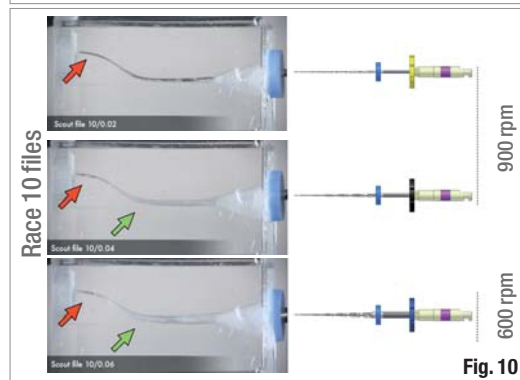
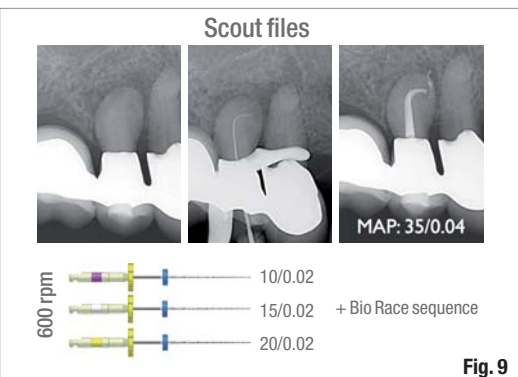
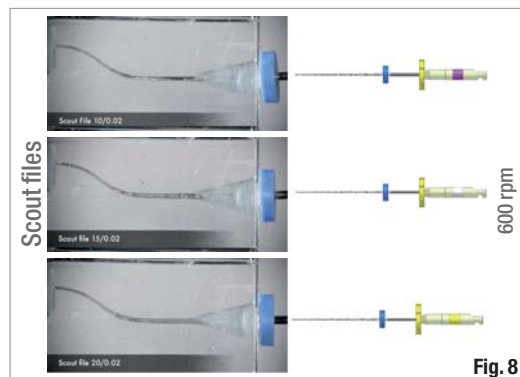
1. Use a #06 or 08 K-file to reach the estimated WL. Confirm the length with an EAL. Remove the file and verify that the curvature is not severe by inspecting the file's surface.

Fig. 8 Scout-RaCe files are extremely flexible because of their small 0.02 taper. Note that these files will not remove dentine from the coronal part of the canal and will mostly create apical enlargement.

Fig. 9 Clinical case of a maxillary premolar with a severe curvature.

Fig. 10 RaCe ISO 10 files will remove mostly the coronal and middle part of the canal (green arrows). The tip for the #10.04 and 10.06 files will work freely (red arrows) after the #10.02 has reached the WL.

Fig. 11 Clinical case of a maxillary molar with a severe curvature and obliterated MB canals. The RaCe ISO 10 files have enough rigidity to move through the obliteration while retaining the curvature of the canal. Coronal space is produced because of the increasing taper of the files.



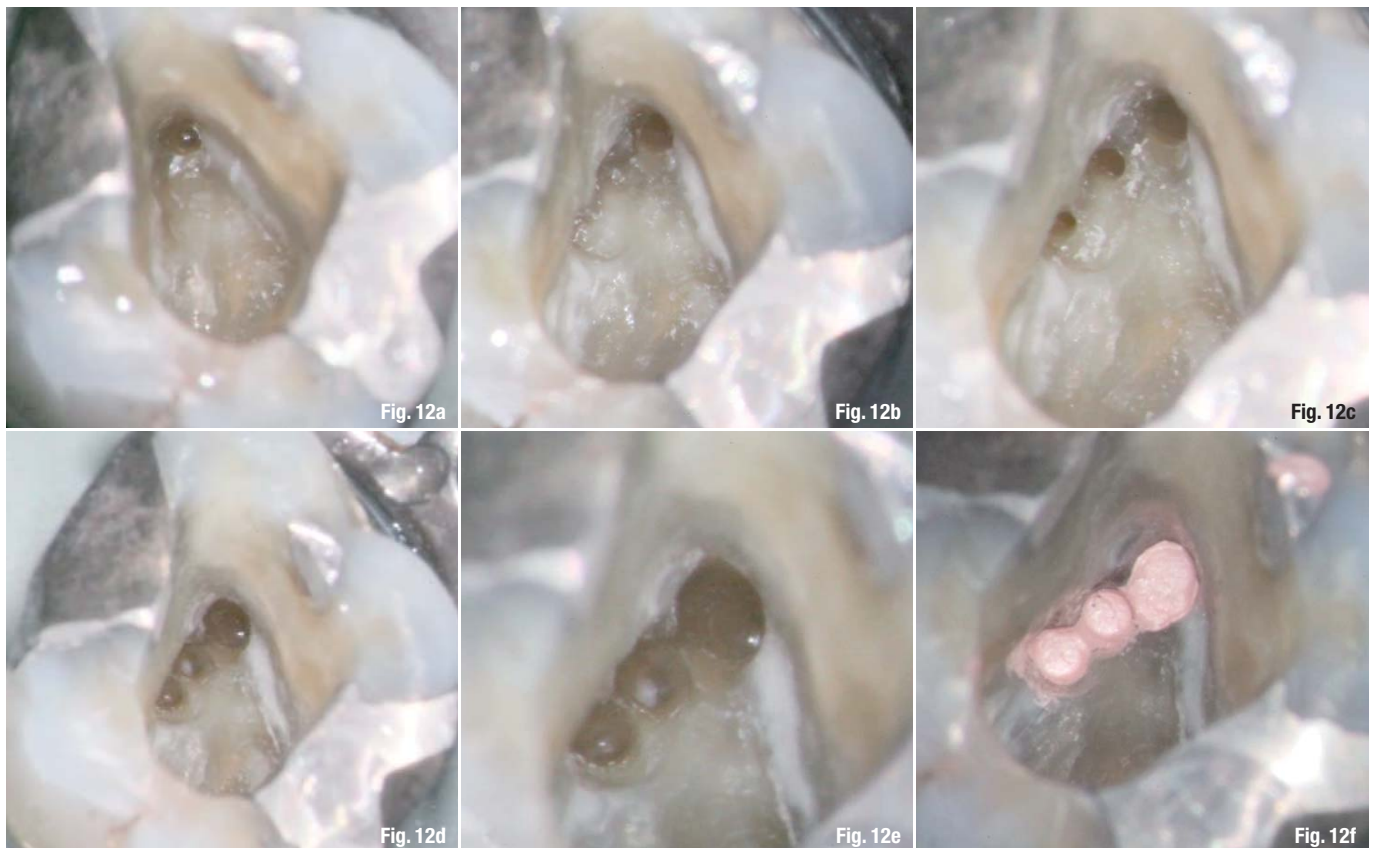


Fig. 12 Clinical images of the access cavity of the case presented in Figure 11, taken through an operating microscope. All three MB canals were obliterated. Pre-op preparation, only the MB1 canal is visible (a). Initial preparation of the MB1 canal with *RaCe* ISO 10 files and after having troughed with ultrasonics over the other MB canals (b). Following preparation of all three MB canals with all *RaCe* ISO 10 files (c). Following preparation of all canals with *BioRaCe* NiTi files to #40.04 (BR5; d). Close-up following complete preparation (e). All three MB canals obturated (f). The final X-ray is shown in Figure 11.

2. Irrigate with NaOCl.
3. With gentle strokes at 900 to 1,000 rpm, widen the canal to WL with the #10.02 and 10.04 instruments. If necessary, continue with the #10.06 file at 600 rpm.
4. Irrigate the canals with NaOCl between files and clean the files if used for more than four strokes. Use the #15 K-file to obtain a smooth glide path and confirm the WL with an EAL.
5. Continue with the main NiTi sequence (*BioRaCe*, Sequence files, etc.; Fig. 9).

Conclusion

Scout-*RaCe* and *RaCe* ISO 10 NiTi rotary files offer the following advantages over SS files for attaining initial flaring and glide path:

- improved speed and efficiency;
- less initial canal transportation in both experienced and non-experienced hands;
- predictable patency;
- limits the need for the initial use of multiple SS files in constricted and severely curved canals;
- makes severely and double-curved canals predictable for the traditional NiTi instruments that follow.

Editorial note: A complete list of references is available from the publisher.

about the authors

roots



Dr Gilberto Debelian (Oslo, Norway)

Dr Debelian received his DMD degree from the University of São Paulo, Brazil, in 1987. He completed his specialisation in Endodontics at the University of Pennsylvania, Philadelphia, USA, in 1991. He completed his PhD studies at the University of Oslo in 1997. He is an adjunct visiting professor in the postgraduate programmes in Endodontics at the University of North Carolina at Chapel Hill and the University of Pennsylvania. Dr Debelian maintains a private specialist endodontics practice in Bekkestua, Norway.



Dr Martin Trope (Philadelphia, USA)

Dr Trope received his BDS degree in dentistry from University in Johannesburg, South Africa, in 1976. In 1980 he moved to Philadelphia to specialize in Endodontics at the University of Pennsylvania. After graduating as an Endodontist he continued at the University of Pennsylvania as a faculty member until 1989 when he became Chair of Endodontology at Temple University, School of Dentistry.

Dr Trope is now Clinical Professor, Department of Endodontics, School of Dental Medicine, University of Pennsylvania. He is also in private practice in Philadelphia, USA.

Infection control

Author_Dr Frank Y. W. Yung, Canada

More than 20 years ago, a dental patient named Kimberly Bergalis was diagnosed with Aids. The source of her HIV infection was her dentist. Even though the exact path of transmission is still not known, this first proven transmission of HIV from dentist to patient—and the subsequent intense coverage by the media—set off tremendous confusion and panic amongst dental patients. It was her unfortunate death in 1991 that changed the dental profession almost overnight, prompting all sorts of new regulations and guidelines, including the sterilisation of dental instruments. The document *Guidelines for Infection Control in Dental Health-care Settings* was published by the US Centers for Disease Control and Prevention (CDC) on 19 December 2003, providing some of the current and available scientific rationale for infection-control practices, for which recommendations were made.¹ These suggestions were followed closely by various governing dental health organisations, including the US Occupational Safety and Health Administration (OSHA) and Health Canada.

In dentistry, we see patients from different walks of life every day and they bring all kinds of pathogens to our dental offices. It is our responsibility to arrest the path of these pathogens and attempt to prevent them from infecting others and spreading beyond our practices. Following the CDC recommended infection-control guidelines and procedures can help stop and prevent transmission of infectious organisms through blood, oral and respiratory secretions and contaminated equipment during the course of dental treatment. One factor to consider in assessing the risk of contamination is the type of bodily substances to which dental health-care personnel (DHCP) are exposed. It is generally understood that human blood has a high infectious potential.² In addition to bacteria and fungi, human saliva has been found to be capable of harbouring many kinds of infectious viruses.^{3,4} Without the benefits of a quick and reliable reference, DHCP have to assume that everyone is a potential carrier. This is the fundamental reason that dental practices should have a universal infection prevention protocol.

Fig. 1 An example of a high-filtration protective mask, which is recommended for use with dental lasers.

Fig. 2 An example of the submission of indicators to a testing service for assessment of office sterilisation equipment's effectiveness.

Fig. 3 An example of sterilised optical fibres and handpieces.

Fig. 4 An example of sterilised rigid glass tips and handpieces.

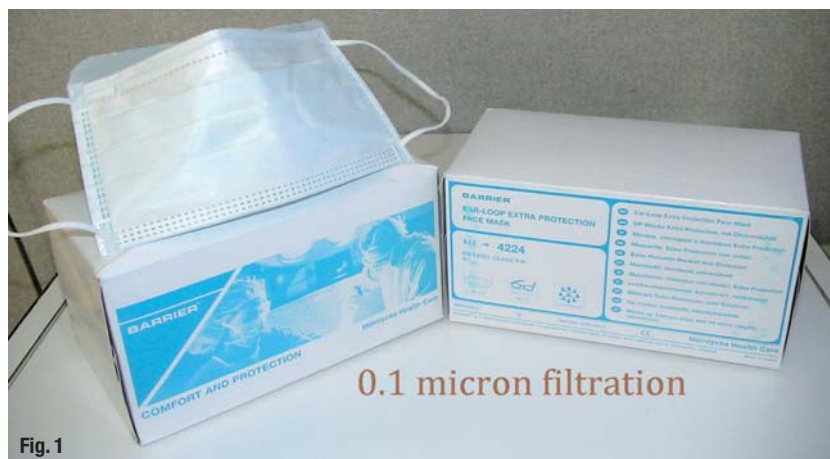

Fig. 1

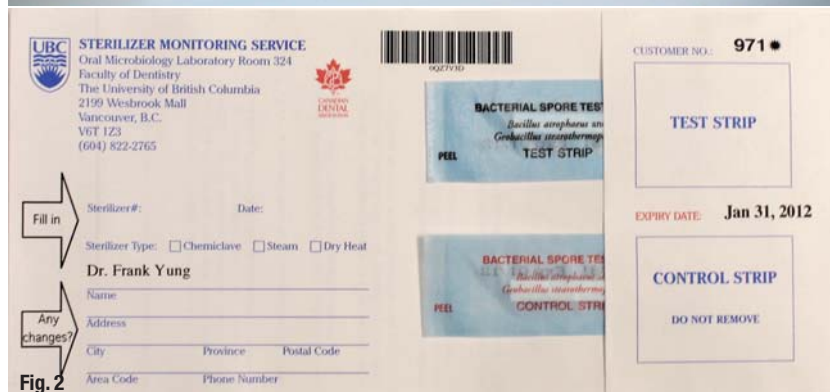


Fig. 2

Amongst many other related issues, the CDC guidelines explain the manner in which to wear surgical gloves properly and implement a glove protocol. These recommendations will help properly prevent contamination from our patients' oral tissues and fluids. Regarding surgical masks, laser ablation of human tissue or dental restorations can cause thermal destruction and can create smoke by-products containing dead and live cellular material (including blood fragments), viruses, and possible toxic gases and vapours. One concern is that aerosolised infectious material in the laser plume, such as the herpes simplex virus and human papillomavirus may come into contact with the nasal mucosa of the laser operator and nearby DHCP. Although no evidence exists that HIV or the hepatitis B virus (HBV) has been transmitted via aerosolisation and inhalation, there are scientific studies that confirm the risk of this possible route of contamination.^{5,6} The risk to DHCP from exposure to laser plumes and smoke is real, and, along with other measures such as strong high-volume suction, the use of a high-filtration mask is strongly recommended (Fig. 1).

Sterilisation is a multistep procedure that must be performed carefully and correctly by the DHCP to help

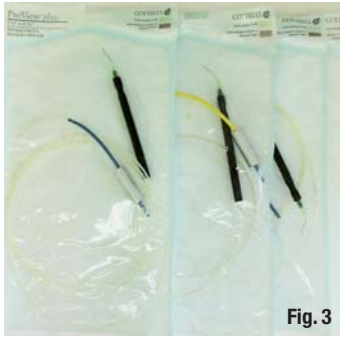

Fig. 3

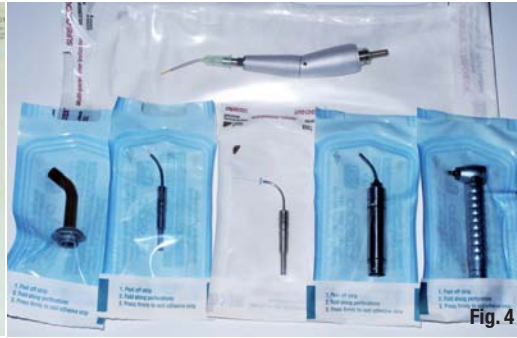

Fig. 4

ensure that all instruments are uniformly sterilised and safe for patient use. Cleaning, which is the first basic step in all decontamination and sterilisation processes, involves the physical removal of debris and reduces the number of micro-organisms on an instrument or device. If visible debris or organic matter is not removed, it can interfere with the disinfection or sterilisation process. Proper monitoring of sterilisation procedures should include a combination of process indicators and biological indicators, and should be assessed at least once a week (Fig. 2). Patient-care items are generally divided into three groups, depending on their intended use and the potential risk of disease transmission. Critical items are those that penetrate soft tissue, touch bone or contact the bloodstream. They pose the highest risk of transmitting infection and should be heat sterilised between patient uses. Examples of critical items are surgical instruments, periodontal scalers, surgical dental burs, optical fibres (Fig. 3) and contact tips (Fig. 4). Therefore, it is extremely important to examine, cleave, polish and sterilise optical fibres and contact tips after each use. Alternatively, sterile, single-use, disposable devices can be used. Semi-critical items are those that come into contact with only mucous membranes and do not penetrate soft tissues. As such, they have a lower risk of transmission. Examples of semi-critical instruments are dental mouth mirrors, amalgam condensers and impression trays. Most of the equipment in this category is heat tolerant, and should therefore be heat sterilised between patient uses. For heat-sensitive instruments, high-level disinfection is appropriate. Non-critical items are instruments and devices that come into contact only with intact (unbroken) skin, which serves as an effective barrier to micro-organisms. These items carry such a low risk of transmitting infections that they usually only require cleaning and low-level

disinfection. Examples of instruments in this category include X-ray head/cones, blood pressure cuffs, low-level laser emission devices and laser safety glasses. For low-level laser therapy, the use of a transparent barrier similar to disposable sleeves for curing lights is acceptable. For safety glasses, the use of a low-level disinfectant is suitable as long as it has a label claim approved by OSHA for removing HIV and HBV. The disposal of used instruments and excised biological tissues should be managed separately. A cleaved optical fibre, broken contact tips, or disposable fibres should be disposed of properly in a sharps container. Harvested biological waste should be placed in a container labelled with a biohazard symbol. In order to protect the individuals handling and transporting biopsy specimens, each specimen must be placed in a sturdy, leak-proof container with a secure lid to prevent leakage during transport. By following these guidelines, the spread of pathogens amongst dental patients, DHCP and their families can be prevented, and the passing of Kimberly Bergalis will not have been in vain.

Disclosure

Dr Yung has no commercial or financial interest regarding this article.

This article was first published in the Journal of Laser Dentistry, 18/2 (2010): 68-70.

Editorial note: A list of references is available from the publisher.

[_contact](#)

[roots](#)

Dr Frank Y. W. Yung
Toronto, Ontario, Canada

frankyung@rogers.com
www.drfrankyung.com

**Complete canal shaping
with only one single file
in continuous rotation!**

**One
Shape®**



- New design.
- No need to buy an additional motor.
- Sterile instrument.

Simplifying your endodontic procedures with complete safety and effectiveness is our primary concern. MICRO-MEGA® now offers you **One Shape®**, the one and only NiTi instrument in continuous rotation for quality root canal preparations.

One Shape® allows for curved canal negotiation with an instrumental and easy dynamic. Its instrument design and non-working (safety) tip ensure an effective apical progression which will consistently produce high-quality results.

**Another new innovation
from MICRO-MEGA®...**



For further information about One Shape®, flash the code with your Smartphone.

MICRO-MEGA®
Tel.: +33 (0)3 81 54 42 34
mmb@micro-mega.com
www.micro-mega.com



Your Endo Specialist™

Analysis of micro leakage using a self-etching adhesive system on casting and fiber glass posts

Authors_ Prof Alejandro Paz, Silvia Arias, Abel Vilma, España Candelaria & Lucas Condomi, Argentina

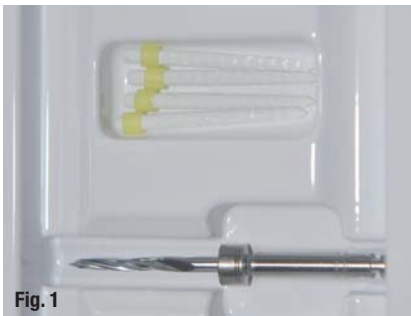


Fig. 1

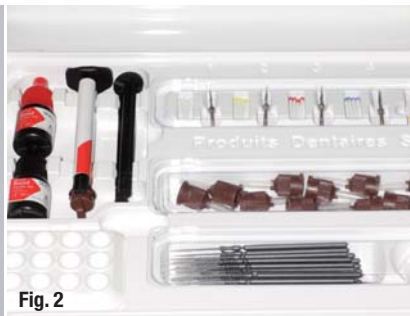

Fig. 2

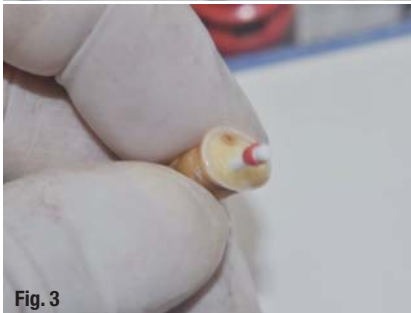

Fig. 3

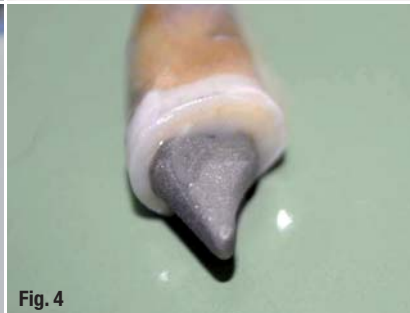

Fig. 4

not cause any clinically significant changes. We can say that the structure loses a significant percentage of its hardness.² These points revalidate theories that state that there is an important relationship between the properties of the dentine and the remaining tooth structure. Preformed posts do not truly reinforce the tooth's root, but rather uniformly distribute the load and serve as anchors for the tooth reconstruction material.^{3,4}

There are various procedures and materials for cementing preformed posts and reconstructing the tooth. Resin cements can be a valid alternative even if their properties are not very similar to the missing dental tissue. These cements can be self-adhesive, self-etching or use an adhesive system. Possible materials for cementing fibreglass posts are self-etch resin cement and conventional resin cements with self-etch adhesives. From these, we can determine the most appropriate combination for the best marginal seal. The conventional etching technique produces strong adhesion to prevent marginal leakage. However, along with the benefits that this brings, this also causes excessive decalcification.⁵

Self-etch adhesive systems arose from the need to avoid unnecessary dental decalcification. These systems are based on the fixation of dental compos-

_Introduction

One of the misconceptions surrounding endodontically treated teeth is that the use of posts reinforces the remaining tooth structure. Baldissara et al.,¹ for example, showed that an endodontically treated tooth loses 9% of its moisture, which does

Fig. 5_ Fibreglass post and dentine.
Fig. 6_ Magnification of 400x.



Fig. 5





Fig. 6



ite after interaction with the dentine the subsequent formation of the hybrid layer. Its adhesive values may be somewhat lower than those obtained with the total-etch technique,⁶ but the decalcification is substantially lower. It is necessary to discuss whether adhesive systems with lower adhesive value and better biocompatibility are sufficient to prevent bacterial infiltration within a root canal. Self-etch dental adhesives can be effective in setting prosthetic structures such as posts, both preformed and cast.⁷

In an adhesive system, both the adhesive and the solid substrates must be analysed. Fibreglass posts are sealed through the binding of the adhesive to the

organic matrix of the post and through micro-mechanical fixation.⁸ Cast posts generally present irregularities on their surface, which can serve to anchor the fixation system.⁹

We must take into account that the solid adherent, the post, can produce movements during the polymerisation of the cement that can detach the adhesive. In these cases, gaps¹⁰ are formed between the material and substrate tooth. These spaces allow bacterial infection. The entry of micro-organisms is known as micro-leakage.¹¹ To prevent this, slight pressure must be maintained during the cement's hardening time.

Fig. 7 Magnification of 800 x.

Fig. 8 Metal post.

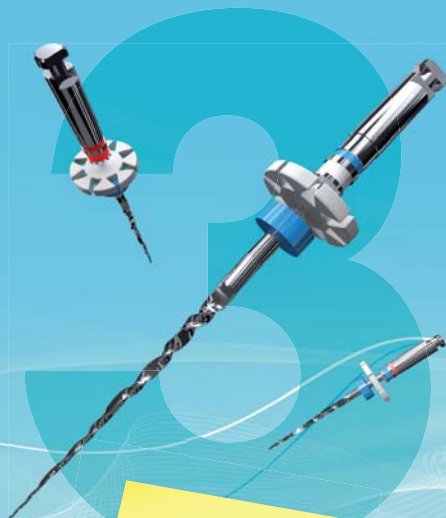Fig. 9 Metal, cement and dentine.

AD

iRaCe

QUICK, EFFECTIVE and SAFE

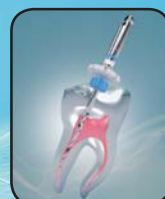Only 3 instruments for most cases
Single-length technique



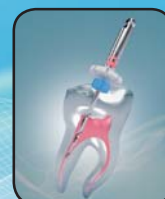R1 - 15/.06

R2 - 25/.04

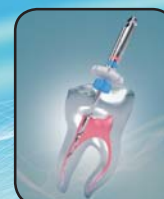R3 - 30/.04



up to WL



up to WL



up to WL

COSAE 2012
Argentina
22 - 25 Aug 2012



www.iRaCe.ch






Fig. 10

Fig. 11

Fig. 10_Fibreglass post (Fibrapost).
Fig. 11_Metal post.

The aim of this study was to analyse the marginal leakage in preformed and cast posts cemented with self-etch systems based on the visualization of the interfaces using SEM technique.

Materials and methods

Endodontic treatment was performed on ten single-rooted teeth. They were mechanically unsealed with Gate drills, provided by the manufacturer (Fig. 1), according to the diameter of the fibreglass post. The coronal portion was removed for later reconstruction. We used the Sealacore self-etch dual-cure resin cement system and the Fibrapost fibreglass post (both Produits Dentaires; Fig. 2).

The root canal preparations were all of the same length. The cement was distributed inside the root canal with a lentulo-spiral and the post was placed (Figs. 3 & 4). The tooth stump was reconstructed with the same bonding resin, concluding with the construction of a provisional element. An impression of the cast post was taken with silicone and the casting was done with a non-noble alloy.

This was followed by 300 thermo-cycles at temperatures of between 5 and 55°C. The samples were soaked in methylene blue for a week. Once dry, the teeth were separated from the provisional part by a cut at the neck of the tooth. In the root and coronary part, the presence or absence of micro leakage was analysed (Philips 505 SEM), as was dye penetration in the third cervical root. Analysis of micro leakage was performed using the image with the highest optical magnification.

Results and microscopic analysis

Fibreglass post

Figure 5 shows the dentine system, cement and post with no micro leakage (at 45x magnification). Figures 6 & 7 show excellent bonding with no micro leakage between the adhesive system, dentine and fibreglass post (400x–800x magnification). The thin layer of the Sealacore cement was noticeable.

Cast post

For this type of post, a marginal closure similar to that produced for the fibreglass posts was observed. Micro leakage were not seen at a magnification of 600x (Figs. 8 & 9).

Penetration of the dye

Completing the cut at the cervix showed no penetration of the dye in all the specimens analysed for both fibreglass and cast posts (Figs. 10 & 11).

Conclusion

The Sealacore self-etch adhesive showed excellent performance for fibreglass and cast posts. This adhesive system produced an appropriate marginal closure. For achieving marginal closure, we recommend this type of adhesive system, as it causes less decalcification.

Editorial note: A complete list of references is available from the publisher.

author
roots



Prof Alejandro Paz
 JF Kennedy University
 Buenos Aires, Argentina
 E-Mail:
 alepaz63@ciudad.com.ar

RECIPROC wins innovation prize 2011



_RECIPROC is probably the most significant new development since nickel-titanium instruments were first introduced to rotary preparation of root canals. RECIPROC completely prepares and shapes the root canal with one single instrument. The system was developed to simplify the procedure of preparing root canals while ensuring maximum security during the process. Hence, since its launch in March 2011, the RECIPROC® system has been adopted in numerous dental offices and clinics replacing manual instrumentation as well as rotary NiTi systems.

At six German dental trade shows, dentists voted for RECIPROC one-file endo to be awarded first prize in the materials and instruments for dental treatment

category of DZW and pluradent's German INNOVATIONSPREIS 2011.

During the ADF congress in Paris (November 2011), out of 56 entries Réciprocité (reciprocation technique) won the Dental Profession's Special Innovation Award.

It is the simplicity of working without instrument changes and only one motor setting, combined with safety and economic single use, that has dentists convinced.

_contact	roots
<p>VDW Fax: +49 89 62734-304 info@vdw-dental.com www.reciproc.com</p>	

Everything you like about X-Smart— with a Plus

_The new generation of the popular X-Smart endo motor from DENTSPLY Maillefer, the X-Smart Plus, will allow you to discover the WaveOne reciprocating single-file technique advocated by leading endodontists. The X-Smart user interface has been further improved by a large, bright colour screen, with a colour-coded file library for file selection at a single glance, making it the endo motor of choice for all ProTaper Universal users. The X-Smart Plus retains the familiar X-Smart features such as the miniature contra-angle head and the on/off button on the motor hand-piece.

as well as eight free programmes for individual settings. It is operated by a rechargeable battery and in continuous rotation provides a speed range of between 250 and 1,200 rpm and a torque range of between 0.6 and 4 Ncm. A warning sound helps you keep track of the file stress and the auto-reverse rotation at the torque limit reduces the risk of file breakage.

The X-Smart Plus endo motor from DENTSPLY Maillefer comes with a three-year warranty.

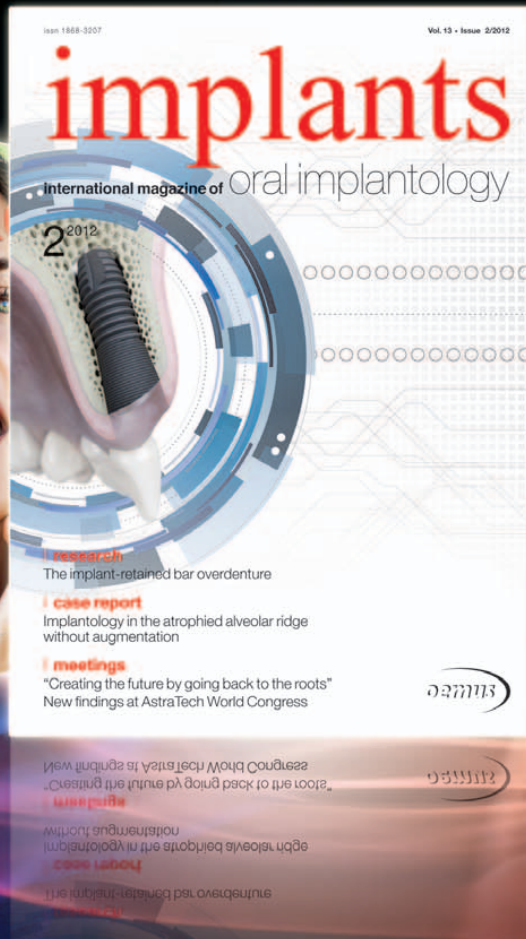

The motor works in both reciprocating motion and continuous rotation. The file library contains preprogrammed settings for WaveOne, ProTaper Universal, PathFile, Gates and RECIPROC,

_contact	roots
<p>DENTSPLY Maillefer www.dentsplymaillefer.com</p>	

implants

international magazine of oral implantology



You can also subscribe via
www.oemus.com/abo

 **Subscribe now!**

I hereby agree to receive a free trial subscription of **implants international magazine of oral implantology** (4 issues per year).

I would like to subscribe to **implants** for € 44 including shipping and VAT for German customers, € 46 including shipping and VAT for customers outside of Germany, unless a written cancellation is sent within 14 days of the receipt of the trial subscription. The subscription will be renewed automatically every year until a written cancellation is sent to OEMUS MEDIA AG, Holbeinstr. 29, 04229 Leipzig, Germany, six weeks prior to the renewal date.

▶ **Reply** via Fax +49 341 48474-290 to OEMUS MEDIA AG or via E-mail to grasse@oemus-media.de

One issue free of charge!

Last Name, First Name

Company

Street

ZIP/City/County

E-mail

Signature

Notice of revocation: I am able to revoke the subscription within 14 days after my order by sending a written cancellation to OEMUS MEDIA AG, Holbeinstr. 29, 04229 Leipzig, Germany.

Signature

Holbeinstr. 29, 04229 Leipzig, Germany, Tel.: +49 341 48474-0, Fax: +49 341 48474-290, E-Mail: grasse@oemus-media.de

OEMUS MEDIA AG

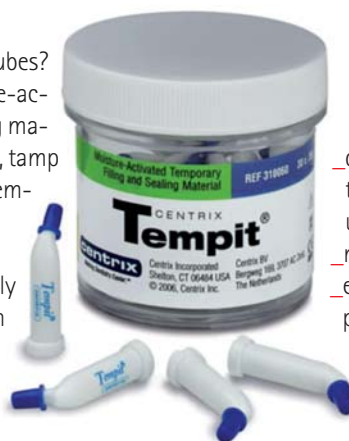

Moisture-activated temporary filling and sealing material

Tempit is packaged in 30 tips of 0.35g each in a jar.

_Still squeezing those messy tubes? With Tempit, our unit-dose, moisture-activated temporary filling and sealing material, simply inject into a moist prep, tamp down and then dismiss the patient. Tempit sets in five minutes or less.

Tempit was developed specifically for sealing access cavities between root-canal treatments. It seals medicaments in and contaminants out between root-canal treatments.



Pre-filled, it eliminates set-up time. Unique delivery provides:

- _direct injection** without worrying that the material will harden before use;
- _no clean-up;** and
- _eliminates the voids** you get when placing other materials.

No more spatulas! No more tubes or jars!_

_contact	roots
<p>Centrix Tel.: +49 221 530978-0 koeln@centrixdental.com www.centrixdental.com</p>	

AD

cosmetic dentistry _ beauty & science

One issue free of charge!

 **Subscribe now!**

You can also subscribe via www.oemus.com/abo

I hereby agree to receive a free trial subscription of **cosmetic dentistry** (4 issues per year). I would like to subscribe to **cosmetic dentistry** for € 44 including shipping and VAT for German customers, € 46 including shipping and VAT for customers outside of Germany, unless a written cancellation is sent within 14 days of the receipt of the trial subscription. The subscription will be renewed automatically every year until a written cancellation is sent to OEMUS MEDIA AG, Holbeinstr. 29, 04229 Leipzig, Germany, six weeks prior to the renewal date.

Reply via Fax +49 341 48474-290 to OEMUS MEDIA AG or per E-mail to grasse@oemus-media.de

Last Name, First Name	
Company	
Street	
ZIP/City/Country	
E-mail	Signature

Notice of revocation: I am able to revoke the subscription within 14 days after my order by sending a written cancellation to OEMUS MEDIA AG, Holbeinstr. 29, 04229 Leipzig, Germany.

Signature

roots 2/12





RECIPROC wins innovation prize 2011



RECIPROC is probably the most significant new development since nickel-titanium instruments were first introduced to rotary preparation of root canals. RECIPROC completely prepares and shapes the root canal with one single instrument. The system was developed to simplify the procedure of preparing root canals while ensuring maximum security during the process. Hence, since its launch in March 2011, the RECIPROC® system has been adopted in numerous dental offices and clinics replacing manual instrumentation as well as rotary NiTi systems.

At six German dental trade shows, dentists voted for RECIPROC one-file endo to be awarded first prize in the materials and instruments for dental treatment category of DZW and pluradent's German INNOVATIONSPREIS 2011.

During the ADF congress in Paris (November 2011), out of 56 entries Réciprocité (reciprocation tech-

nique) won the Dental Profession's Special Innovation Award.

It is the simplicity of working without instrument changes and only one motor setting, combined with safety and economic single use, that has dentists convinced.

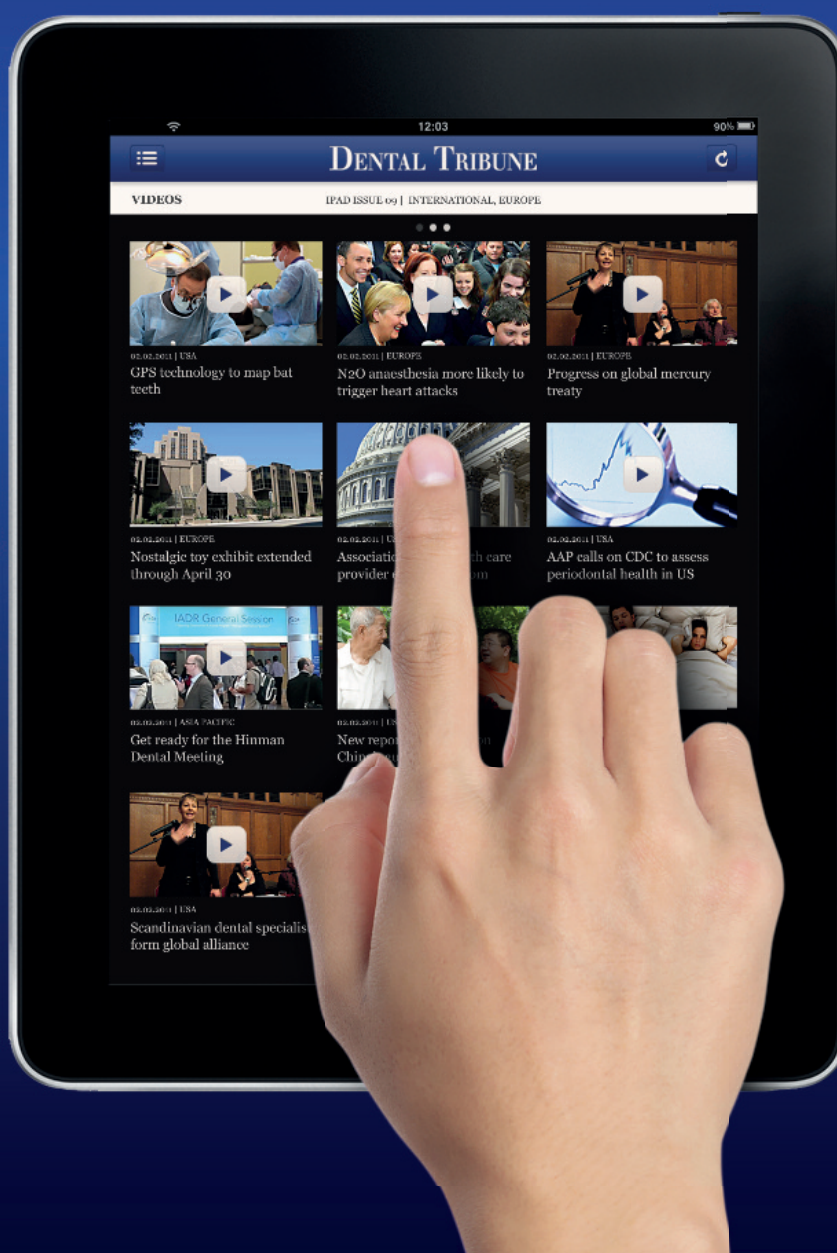_contact	roots
<p>VDW Fax: +49 89 6273 4304 info@vdw-dental.com www.reciproc.com</p>	

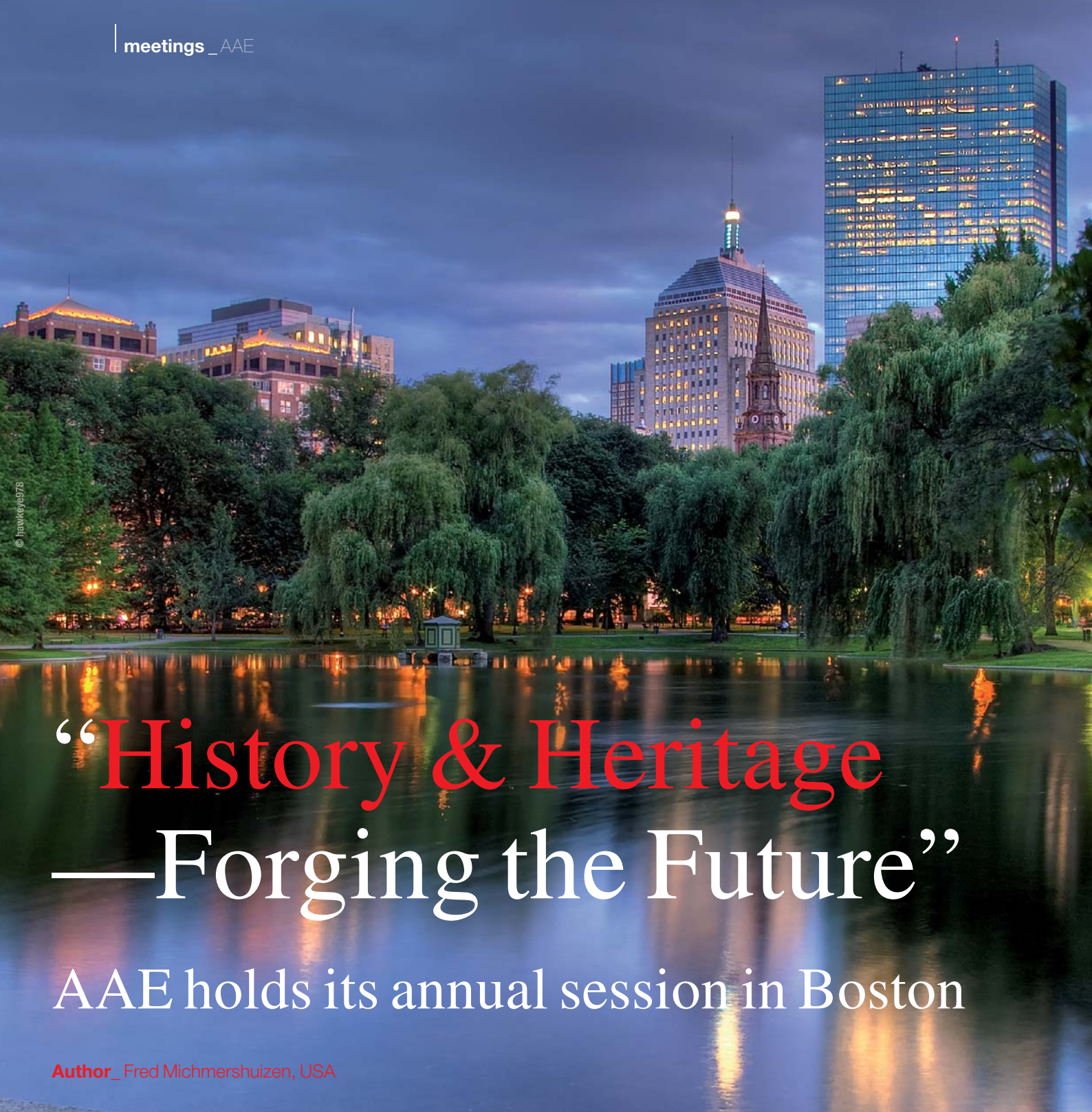Dental Tribune pour iPad – Votre sélection de nouvelles hebdomadaires

Chaque semaine, nos éditeurs choisissent les meilleurs articles et vidéos des différentes éditions des Dental Tribune dans le monde.

Créez votre édition personnelle, dans la langue de votre choix, en sélectionnant uniquement les publications et vidéos qui vous intéressent.

ipad.dental-tribune.com





© ianweye/978

“History & Heritage —Forging the Future”

AAE holds its annual session in Boston

Author_ Fred Michmershuizen, USA

The American Association of Endodontists held its 2012 Annual Session April 18–21 at the Hynes Convention Center in Boston. The meeting offered endodontists, general dentists and other specialists the opportunity to participate in a large selection of endodontic courses as well as learn about the rich history of the specialty in the United States.

During the four-day event, meeting attendees could receive continuing education credit from eight different educational tracks, three of which were new this year: Exploring the Future, Evidence Based-En-

dodontics and Orofacial Pain, Oral Pathology and Trauma. The sessions were offered in a variety of learning formats.

The popular Master Clinician Series showcased live, state-of-the-art surgeries, including implant placement, regenerative endodontic therapy, molar endodontic microsurgery, the use of cone beam computed tomography and more.

This year's master clinicians included Dr Paul D. Eleazer, Dr Shepard S. Goldstein, Dr Mani Moulazadeh,



Fig. 1



Fig. 2

Dr Richard A. Rubinstein, Dr Wyatt D. Simons and Dr John D. West.

On the exhibit hall floor, companies showcased their products and services.

Roydent Dental Products offered its popular C-Files in new sizes—12.5, 15 and assorted packs 06-10, all in 21 mm and 25 mm lengths. The new 12.5 is an exclusive size to Roydent and allows doctors to make a half step when instrumentation between sizes 10 and 15.

Nancy Connor, Roydent's sales and marketing manager, said the C-Files provide an ideal and extremely effective way to instrument calcified canals. They are also ideal for locating canals and instrumenting narrow canals. Their non-cutting tip allows doctors to break through calcification safely and efficiently.

SS White, which had an expanded booth presence this year, introduced a full line of endodontic products driven around the company's passion toward conservation and efficiency. The offerings included the re-development of the V Taper file and many other instruments.

"The V Taper really is unique because it has a patented variable taper that at the top of the file is

much more conservative and allows for the preservation of cervical dentin to a higher degree than any other file system on the market," said Tom Gallop, CEO of SS White. "As we are starting to learn, and as the endodontic and restorative community is starting to see, the value of that cervical dentin in terms of the long life creation of successful restorations is a vital element, so we feel that with that patented feature in V Taper files and a lot of the research pointing to the need to preserve that cervical dentin as much as possible that we are on the path to creating longer lasting endodontic procedures and restorative procedures."

Other product highlights included the introduction of SafeSiders instruments from EDS in a new 31 mm size; a new, high-density foam for cleaning instruments, available from Jordco; new X-treme endodontic instruments from JS Dental Mfg.; a new Marwan Abou-Rass (MAR) microsurgical endodontic instrument line from Hu-Friedy; the Impact Air 45 high-speed, air-powered handpiece from Palisades Dental; and the introduction of a new Plasma light source for Seiler microscopes.

The theme of the 2012 meeting was "History & Heritage—Forging the Future." Next year's AAE Annual Session is scheduled for April 17–20 in Honolulu.

Fig. 1_Dr. Richard A. Rubinstein performs atypical molar microsurgery during a theater-in-the-round educational presentation at the 2012. AAE Annual Session in Boston.

Fig. 2_Companies offer their products and services in the exhibit hall.

Fig. 3_Brant Miles of SS White.

Fig. 4_James Johnson of Jordco.

Fig. 5_Dane Carlson of Seiler Precision Microscopes.

Photos: Fred Michmershuizen, Dental Tribune America.



Fig. 3



Fig. 4



Fig. 5

International Events

2012

IADR General Session & Exhibition

20–23 June 2012
Iguaçu Falls, Brazil
www.iadr.org

Trans-Tasman Endodontic Conference

21–23 June 2012
Queensland, Australia
www.tteconference.com

Skand Endo

23–25 August 2012
Oslo, Norway
nina.gerner@c2i.net

FDI Annual World Dental Congress

29 August–1 September 2012
Hong Kong, China
www.fdiworldental.org

ESMD Annual Meeting

4–6 October 2012
Berlin, Germany
www.esmd.info

ROOTS Summit

18–20 October 2012
Foz do Iguaçu, Brazil

DGET Annual Meeting

1–3 November 2012
Leipzig, Germany
www.dget.de

ÖGEndo International Congress

9 & 10 November 2012
Vienna, Austria
www.oegendo.at

AMED Annual Meeting

16 & 17 November 2012
San Diego, CA, USA
www.microscopedentistry.com

Greater New York Dental Meeting

23–28 November 2012
New York, NY, USA
www.gnydm.com

2013

International Dental Show

12–16 March 2013
Cologne, Germany
www.ids-cologne.de

IFEA World Endodontic Congress

23–26 May 2013
Tokyo, Japan
www2.convention.co.jp/ifea2013

ESE Biennial Congress

12–14 September 2013
Lisbon, Portugal
www.e-s-e.eu



© Morten Normann Almeland

submission guidelines:

Please note that all the textual components of your submission must be combined into one MS Word document. Please do not submit multiple files for each of these items:

- _ the complete article;
- _ all the image (tables, charts, photographs, etc.) captions;
- _ the complete list of sources consulted; and
- _ the author or contact information (biographical sketch, mailing address, e-mail address, etc.).

In addition, images must not be embedded into the MS Word document. All images must be submitted separately, and details about such submission follow below under image requirements.

Text length

Article lengths can vary greatly—from 1,500 to 5,500 words—depending on the subject matter. Our approach is that if you need more or less words to do the topic justice, then please make the article as long or as short as necessary.

We can run an unusually long article in multiple parts, but this usually entails a topic for which each part can stand alone because it contains so much information.

In short, we do not want to limit you in terms of article length, so please use the word count above as a general guideline and if you have specific questions, please do not hesitate to contact us.

Text formatting

We also ask that you forego any special formatting beyond the use of italics and boldface. If you would like to emphasise certain words within the text, please only use italics (do not use underlining or a larger font size). Boldface is reserved for article headers. Please do not use underlining.

Please use single spacing and make sure that the text is left justified. Please do not centre text on the page. Do not indent paragraphs, rather place a blank line between paragraphs. Please do not add tab stops.

Should you require a special layout, please let the word processing programme you are using help you do this formatting automatically. Similarly, should you need to make a list, or add footnotes or endnotes, please let the word processing programme do it for you automatically. There are menus in every programme that will enable you to do so. The fact is that no matter how carefully done, errors can creep in when you try to number footnotes yourself.

Any formatting contrary to stated above will require us to remove such formatting before layout, which is very time-consuming. Please consider this when formatting your document.

Image requirements

Please number images consecutively throughout the article by using a new number for each image. If it is imperative that certain images are grouped together, then use lowercase letters to designate these in a group (for example, 2a, 2b, 2c).

Please place image references in your article wherever they are appropriate, whether in the middle or at the end of a sentence. If you do not directly refer to the image, place the reference at the end of the sentence to which it relates enclosed within brackets and before the period.

In addition, please note:

- _ We require images in TIF or JPEG format.
- _ These images must be no smaller than 6x6 cm in size at 300 DPI.
- _ These image files must be no smaller than 80 KB in size (or they will print the size of a postage stamp!).

Larger image files are always better, and those approximately the size of 1 MB are best. Thus, do not size large image files down to meet our requirements but send us the largest files available. (The larger the starting image is in terms of bytes, the more leeway the designer has for resizing the image in order to fill up more space should there be room available.)

Also, please remember that images must not be embedded into the body of the article submitted. Images must be submitted separately to the textual submission.

You may submit images via e-mail, via our FTP server or post a CD containing your images directly to us (please contact us for the mailing address, as this will depend upon the country from which you will be mailing).

Please also send us a head shot of yourself that is in accordance with the requirements stated above so that it can be printed with your article.

Abstracts

An abstract of your article is not required.

Author or contact information

The author's contact information and a head shot of the author are included at the end of every article. Please note the exact information you would like to appear in this section and format it according to the requirements stated above. A short biographical sketch may precede the contact information if you provide us with the necessary information (60 words or less).

Questions?

Magda Wojtkiewicz (Managing Editor)
m.wojtkiewicz@oemus-media.de

roots

international magazine of endodontology

Publisher

Torsten R. Oemus
oemus@oemus-media.de

CEO

Ingolf Döbbecke
doebbecke@oemus-media.de

Members of the Board

Jürgen Isbaner
isbaner@oemus-media.de

Lutz V. Hiller

hiller@oemus-media.de

Managing Editor

Magda Wojtkiewicz
m.wojtkiewicz@oemus-media.de

Executive Producer

Gernot Meyer
meyer@oemus-media.de

Designer

Josephine Ritter
j.ritter@oemus-media.de

Copy Editors

Sabrina Raaff
Hans Motschmann

Published by

Oemus Media AG
Holbeinstraße 29
04229 Leipzig, Germany
Tel.: +49 341 48474-0
Fax: +49 341 48474-290
kontakt@oemus-media.de
www.oemus.com

Printed by

Löhnert Druck
Handelsstraße 12
04420 Markranstädt, Germany

Editorial Board

Fernando Goldberg, Argentina
Markus Haapasalo, Canada
Ken Serota, Canada
Clemens Bargholz, Germany
Michael Baumann, Germany
Benjamin Briseno, Germany
Asgeir Sigurdsson, Iceland
Adam Stabholz, Israel
Heike Steffen, Germany
Gary Cheung, Hong Kong
Unni Endal, Norway
Roman Borczyk, Poland
Bartosz Cerkaski, Poland
Esteban Brau, Spain
José Pumarola, Spain
Kishor Gulabivala, United Kingdom
William P. Saunders, United Kingdom
Fred Barnett, USA
L. Stephan Buchanan, USA
Jo Dovgan, USA
Vladimir Gorokhovskiy, USA
James Gutmann, USA
Ben Johnson, USA
Kenneth Koch, USA
Sergio Kuttler, USA
John Nusstein, USA
Ove Peters, USA
Jorge Vera, Mexico



Magda Wojtkiewicz, Managing Editor

A stylized logo for the magazine 'roots'. The word 'roots' is written in a red, serif font. To the right of the text is a grey, curved graphic element that resembles a stylized 'S' or a swoosh.

Copyright Regulations

_roots international magazine of endodontology is published by Oemus Media AG and will appear in 2012 with one issue every quarter. The magazine and all articles and illustrations therein are protected by copyright. Any utilisation without the prior consent of editor and publisher is inadmissible and liable to prosecution. This applies in particular to duplicate copies, translations, microfilms, and storage and processing in electronic systems.

Reproductions, including extracts, may only be made with the permission of the publisher. Given no statement to the contrary, any submissions to the editorial department are understood to be in agreement with a full or partial publishing of said submission. The editorial department reserves the right to check all submitted articles for formal errors and factual authority, and to make amendments if necessary. No responsibility shall be taken for unsolicited books and manuscripts. Articles bearing symbols other than that of the editorial department, or which are distinguished by the name of the author, represent the opinion of the afore-mentioned, and do not have to comply with the views of Oemus Media AG. Responsibility for such articles shall be borne by the author. Responsibility for advertisements and other specially labeled items shall not be borne by the editorial department. Likewise, no responsibility shall be assumed for information published about associations, companies and commercial markets. All cases of consequential liability arising from inaccurate or faulty representation are excluded. General terms and conditions apply, legal venue is Leipzig, Germany.



Cordless with an extra-small head



An extra-small head. No cord. And full power. The Entran cordless handpiece provides complete freedom of movement and, thanks to its extra-small head, also gives optimum access to the treatment site. The torque-controlled automatic direction change and the five torque levels set new safety standards in cordless endodontics.

wh.com

en.tran

Endodontics. Cordless!

FIBRAPOST PLUS & SEALACORE DC

ALL-IN-ONE BUILD UP KIT

All you need
for a safe
and complete
core build-up

