

Fixed full arch metal-free prosthesis on four SHORT[®] implants

Authors_Dr Mauro Marincola, Italy, Dr Vincent J. Morgan, USA, Angelo Perpetuini & Stefano Lapucci, Italy

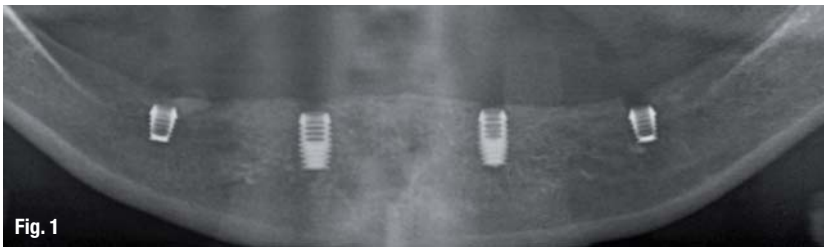


Fig. 1

Introduction

The concept of having only four SHORT[®] implants for the support of a fixed full arch non-metallic prosthesis (Trinia[™]), a CAD/CAM fiber reinforced resin, was first executed in 2010. The clinically based results performed in three different implant dentistry centers are showing clinical success because of Trinia's inherent mechanical and clinical properties. Another factor were the 360 degrees of universal abutment positioning provided by the Implants Locking Taper connection (Bicon[®]), which gives the opportunity to use the Trinia[™] prosthesis to orient and seat the abutments in the well of the implants. The Trinia framework may be covered with either customized poly-ceramic indirect composite material or by conventional denture teeth and resin.

In the following case presentation, we want to show how short implants have been successfully used to restore severely atrophic mandibles without the use of difficult bone augmentation procedures and complicated prosthetic suprastructures in the past decade.

Material and methods

Bicon Dental implants (Bicon LLC, Boston, MA, USA) were used for the reconstruction of the case, combined with a CAD/CAM fiber reinforced resin framework (Trinia[™]) and conventional denture teeth and resin prosthesis. Bicon implants can be characterized by their special macro-structure, including a root-shaped design with wide fins called plateaus, by a sloping shoulder and by a well which holds the abutment post by means of a Locking Taper connection.¹

The plateaus are of particular importance for the biomechanical performance, allowing SHORT[®] implants with a wide diameter to be used in any position in the oral cavity. Their insertion into the osteotomy, which has been prepared using atraumatic drills rotating at 50 rpm, is executed by using mechanical pressure. The countless micro-retentions created on

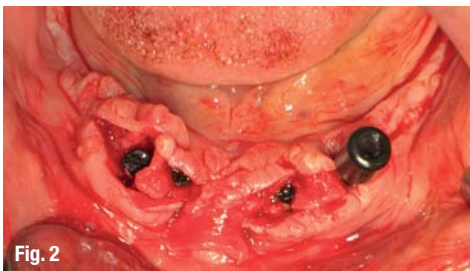


Fig. 2

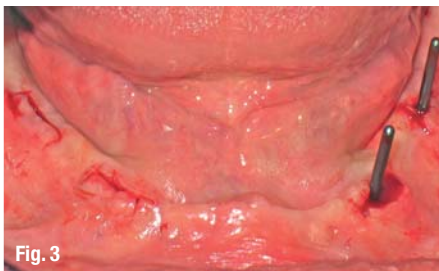

Fig. 3

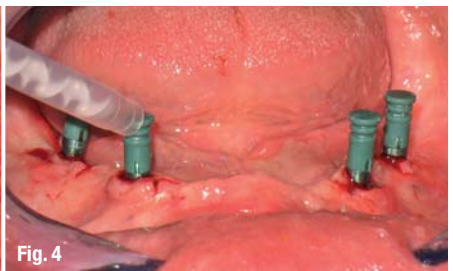

Fig. 4



Fig. 5

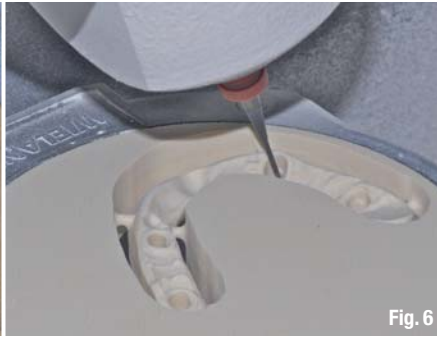

Fig. 6

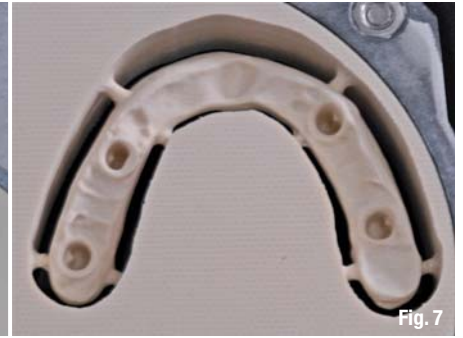

Fig. 7

the surface of the fin edges with the walls of the osteotomy ensure primary stability of the implant in the implant site. Furthermore, the wide spaces between the plateaus avoid vertical compression on the bone walls and rapidly collect the clotted blood, allowing rapid bone formation without the classic macrophagic and osteoclastic processes of bone resorption taking place. Thus well defined bone is formed, with haversian canals and blood vessels which enable continuous bone remodelling around the implant/bone contact surface. This ensures stability of the implant in any situation involving biomechanical stimulus.²

The sloping shoulder is vitally important for the preservation of crestal bone after implant osseointegration and for implant function. The Bicon implant design offers platform switching with a neck which converges from the widest diameter of the first plateau, to 2 or 3 mm towards the crestal zone (converting crest module). In our patient, we used implants 5 mm in diameter, but the space taken up at crestal level is only 3 mm. This ensures bone augmentation above the neck, also because the implant is seated at least 1 mm below the crest during the first surgical stage. This allows the above structures, such as the crestal bone, periosteum and epithelium, to grow around the hemispherical base of the abutment and to give sufficient space for maintenance and the growth of the papillae.

Another important factor for obtaining long-term crestal bone stability is the bacterial seal within the connection between implant and abutment. If crestal

bone maintenance and the formation of papillae can only be achieved when the implant is placed in a sub-crestal position and by platform switching at the level of the implant neck, it is also true that this situation can only be accomplished if the connection is hermetically sealed from bacterial infiltration. Without this feature, the placement of a sub-crestal implant without a bacterial seal would result in the rapid spread of pathogens around vital structures, crestal bone, periosteum and epithelium. The result would be bone resorption well below the original crestal bone level.

Bicon's locking taper is a design feature ensuring crestal bone level maintenance around an implant with a convergent sloping shoulder placed sub-crestally.³ The Locking Taper is a precise connection formed by cold welding out of two surfaces of the same material which are brought into close contact with pressure. In this way, the oxidation layers—formed both on the abutment post and on the surface of the implant well—are detached.^{4,5} The prosthetic components (one-piece titanium abutments made from the same surgical grade titanium alloy as the implants) ensure maximum mechanical resistance and optimum biocompatibility. The subgingival hemispheric base geometry is ideal for the stability of peri-implant connective tissues.

The abutments are connected to the implant well by means of a post, which is 2 mm, 2.5 mm or 3 mm in diameter. Implants which are 3.0 mm and 3.5 mm in diameter are suitable for 2 mm posts, while implants of a diameter of 4.5 mm, 5 mm or 6 mm match with

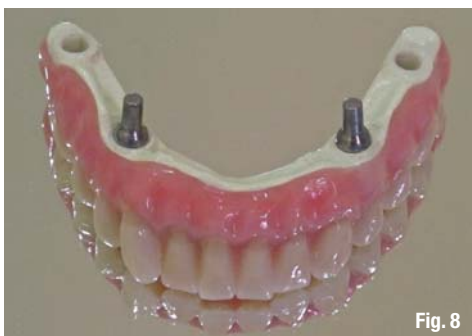

Fig. 8

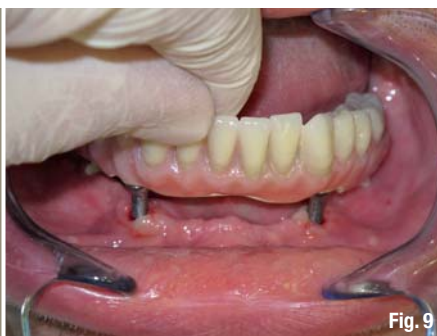

Fig. 9

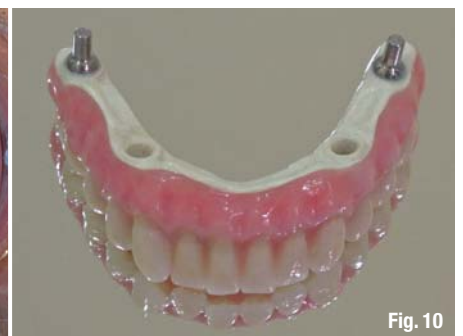

Fig. 10

abutments with a 3 mm post. All of the abutment posts have diameters or emergence profiles of 3.5, 4.0, 5.0 or 6.5 mm, suitable for allowing a natural anatomical shape of the soft tissues. Abutment diameters are therefore independent of implant diameters, which means that any implant may host the four different abutment emergence profiles. The different emergence profiles start from the 2 mm, 2.5 mm or 3 mm posts, placed at crestal bone level. The geometry of the abutments provides for platform switching even at a prosthetic level, which is of vital importance in the organization of the connecting tissue and the epithelial layer.

The suprapariosteal space involved in the shift from the connecting post diameter (2–3 mm) to the diameter of the abutment hemisphere (3–6.5 mm), allows a thicker and denser connecting tissue to form, resulting in the optimal preservation of the papilla. In the following case, all the selected abutments have a 3 mm post, as they must connect to the 3 mm wells of the 5.0 x 6.0 mm implants. Abutment post heights, inclinations and diameters are selected in the laboratory in accordance with the position of the implants relative to the anatomy of the alveolar ridge.

Trinia is a CAD/CAM multidirectional fiber reinforced resin material, which despite its light weight is capable of withstanding occlusal forces.

Case report

A 52-year-old male patient, presenting a severely compromised mandibular bone, was treated with the placement of four short implants. Two SHORT® implants (4.5x8 mm) were placed bilaterally at the canine region and two ULTRA SHORT® implants (4 x 5 mm) were bilaterally located at the first molar region (Fig. 1). The implants were placed in a two-stage surgery and they were uncovered after a healing period of three months (Figs. 2 and 3).

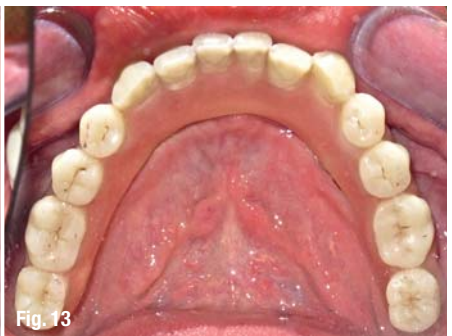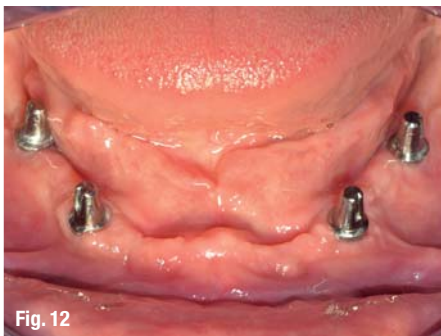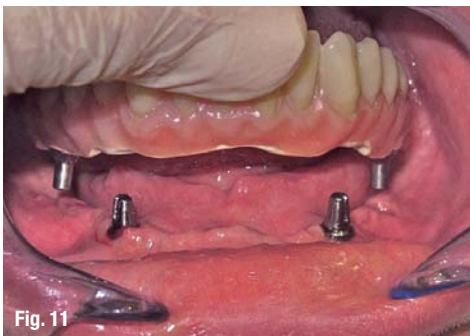Clinically, the prosthetic treatment began with an implant level transfer impression by inserting with only finger pressure a green impression post with its corresponding acrylic sleeve into the 3.0 mm implant well,

prior to recording their position by making an implant level impression with any conventional impression material (Fig 4). Upon the removal of the full arch impression, green impression posts were removed from the implant wells and inserted into an implant analog of the same color before inserting them into their corresponding acrylic sleeves within the impression.

Prior to the pouring of a stone model, a resilient acrylic was applied around the impression posts to simulate a soft tissue contour in the stone model. The stone model was used for the fabrication of a wax bite rim to record the occlusal registrations. After articulation of the models, appropriate abutments with the largest practical hemispherical base were selected and inserted into their corresponding implant analogs within the stone model. Their prosthetic posts were then milled parallel to one another (Fig. 5).

The model with the milled abutments was used to fabricate a light cured resin bar and denture tooth set up for an intra-oral confirmation of the arranged teeth. Once the denture set-up had been clinically approved, a facial occlusal silicone mask was initially formed over the denture wax set up. Prior to forming the lingual silicone mask, indexing or alignment grooves were placed in the facial occlusal mask. After fabrication of the lingual mask, grooves were cut into the stone model to prevent the subsequent entrapment of air, when acrylic was poured into the silicone flask through an anterior cut-away or aperture in the lingual mask. Prior to the removal of the wax denture tooth set up from the stone model, the facial lingual extent of the wax denture tooth set up on the alveolar ridge was marked on the stone model with a pencil.

After the removal of the denture teeth and wax from the resin bar, the teeth were cleaned and lingually roughened or modified prior to being facially glued to the facial occlusal silicone mask with cyanoacrylate glue. An uneven thin application of clear resin was then applied to the cervical area of the teeth on the mask to achieve an aesthetic stratification of the gingival denture resin. The facial occlusal mask and the resin bar were then repositioned on the model to confirm the appropriateness of their contours relative to each other



and particularly to the cervical gingival area of the intended teeth. If necessary, the resin bar may be modified by adding wax or by reducing it with a bur. Prior to its being sprayed and digitally scanned, the space between the resin bar and the ridge area between the pencil lines on the model is filled with a putty material, so that the milled framework can be in contact with the soft tissue of the edentulous ridge (Fig. 6).

After the model with the milled abutments and the resin bar were separately sprayed and scanned, the Trinia fiber resin bar was digitally designed on the computer with a minimum thickness of 7.0 mm throughout, an abutment clearance of 30 microns for cement and with a maximum cantilever extension of 21.0 mm. If necessary, the milled Trinia framework may have been judiciously reduced manually.

After cleaning the milled Trinia framework with alcohol, it was placed onto the milled abutments to evaluate and, if necessary, modify the marginal adaptation of the framework to the abutments and to the alveolar ridge of the model. The ridge side of the framework should be convex without any concavities. Additionally, the Trinia framework was used to confirm both the path of insertion of the prosthesis and the sequence of insertion of the milled abutments on the model. After the sequence and path of insertion were confirmed, the facial, occlusal and lingual masks were repositioned on the model and attached together with cyanoacrylate glue (Fig. 7).

A thin mix of denture resin was poured into the silicone flask through the anterior cutaway or aperture in the lingual mask. Final polymerization was achieved while the silicone flask and models were under hot water, with an air pressure of 3 bars. After polymerization, the Trinia prosthesis was removed from its silicone flask, then finished and polished in a conventional manner. Clinically, after the removal of the temporary abutments from the implant wells, at least two milled abutments were incompletely inserted into the prosthesis. If necessary, they were stabilized with an application of Vaseline, prior to their being transported to the mouth and inserted into the well of their implant (Fig. 8). The loosely fitting abutment facilitated its insertion into the well of the implant (Fig. 9). Once the abutment was initially seated, the prosthesis was removed for the definitive seating by tapping directly onto the titanium abutment. This seating process was continued until all of the abutments were definitively seated (Figs. 10 to 12).

Alternatively, an abutment could have been initially be loosely seated in the well of the implant, prior to the prosthesis being used to orient and seat the abutment in the well of the implant. Final or temporary cementation was achieved by first applying Vaseline over the

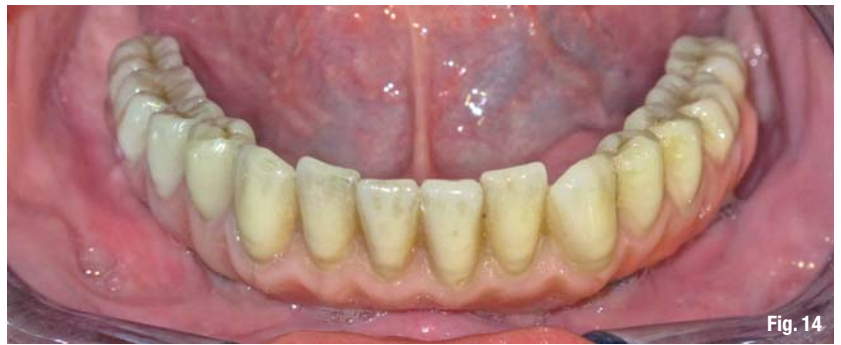

Fig. 14

ridge area of the prosthesis to facilitate the removal of any extraneous cement. Only a minimum of cement was applied to the bores in the Trinia framework before inserting the prosthesis in the mouth. The extraneous cement was blown away with an application of air under the prosthesis. The occlusion was evaluated and adjusted (Figs. 13 & 14).

Conclusion

Regardless of which type of material will ultimately be used to cover the Trinia framework, it was essential to have an anterior diagnostic positioning, wax rim, or arrangement of the intended teeth prior to the fabrication of the Trinia CAD/CAM framework.

In our clinical case, Meyor composite denture teeth were used for the final prosthetic to assure a good bio-mechanical force distribution around the four SHORT® implants. The follow-ups of our patients treated with the described technique was showing a good gingival response and no marginal bone loss around the platform switched implant neck of the SHORT® or ULTRA SHORT® implants (Bicon Dental Implants) used in our case presentation and in 60 other cases treated in three different Implant Dentistry Centers.

This technique of a fixed prosthesis on only four short implants deserves a clinical, long term, evidence-based study because of its low costs and reduced treatment time with minimum morbidity and good patient response.

Editorial note: A complete list of references is available from the publisher.

contact

implants

Prof Dr Mauro Marincola

Via dei Gracchi, 285
I-00192 Roma, Italy

mmarincola@gmail.com