

CAD/CAM-based restoration of an edentulous maxilla

Author_Arnd Lohmann, Germany

_Introduction

There is probably no other treatment method that turns our patients' quality of life for the better so critically and predictably as the restoration of the edentulous jaw using implant-supported dental replacements (Alfadda et al., 2009). An implant-based, telescopic bridge should be viewed as the treatment of choice for the rehabilitation of an edentulous mandible (Abd El-Dayem et al., 2009). This is the conclusion drawn from the results of an investigation by Eitner and his colleagues in 2008, especially in anatomically difficult situations, in which an implant-supported superstructure guarantees an adequate prosthetic rehabilitation. Visser et al. showed in 2009 that the implant-supported restoration of the edentulous maxilla also represents a proven and effective treatment method with predictable success.

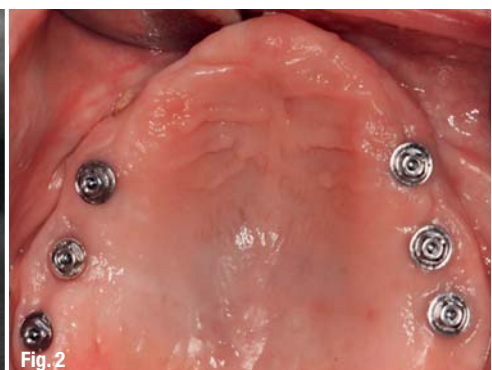
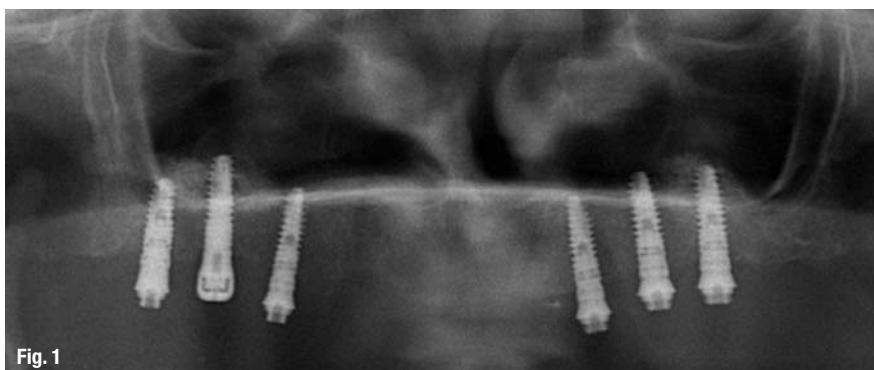
2008). A bar connection and telescopic crowns are favored for the edentulous maxilla, since, in contrast to flexible connections, these can prevent the denture from tilting. Which of these two connection types is to be preferred, however, seems unclear. Implants supporting telescopic crowns exhibit a reduced sulcus fluid rate, which is interpreted as a sign of a slight inflammation of the periimplant tissues. This, however, as Eitner and his colleagues showed, does not lead to a reduced rate of implant loss in comparison with implant-supported bars, even over a longer period. Bar-retained, implant-supported superstructures, on the other hand, are significantly less prone to repair, with the result that, according to the working party under Eitner, no alternative restoration can be identified as to be preferred. In each case, following extensive treatment, the patient treated expects—for him, from a financial and, above all, an emotional point of view—a substantially uncomplicated, mechanically “maintenance-free” rehabilitation. In this respect, restoration using a bar-retained, removable superstructure resembling a bridge is, for us, the first choice. As a matter of principle, we include two interlocking mechanisms to improve the wearing comfort. This prevents a reduction in the retention of the removable


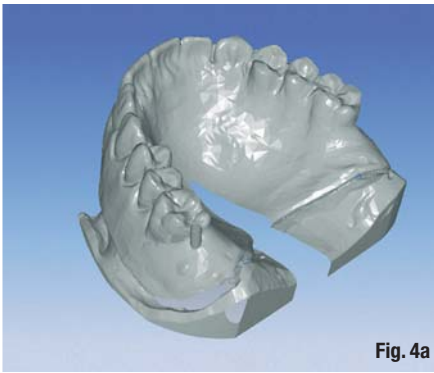
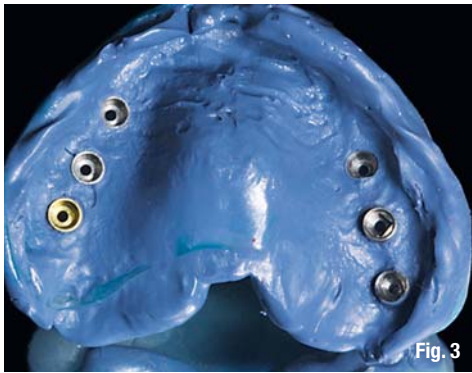
_Connection elements

Various anchoring elements such as bars, double crowns and a variety of prefabricated connection elements for the replacement of teeth have been discussed in the past (Alfadda et al., 2009; Eitner et al.,

Fig. 1_Orthopantomogram post insertion of the XIVE TG implant.

Fig. 2_The Friadent MP abutments transfer the working level from the edge of the bone to a supragingival level.





unit caused by abrasion. Furthermore, the interlocking gives the patient the important feeling of confidence, since unwanted loosening of the restoration is precluded.

Materials

Individually milled bars are usually cast in a chrome-cobalt or gold alloy. A recent option is the central CAD/CAM fabrication of virtually designed bar constructions in accordance to a model scan. This fabrication variant has numerous advantages: on the one hand, the tension-free fit of the bar on the implants is not affected by the shrinkage of the metal caused by cooling. On the other hand, it is possible to manufacture the bar from titanium, which may result in a reduction in gingival inflammation (Abd El-Dayem et al., 2009), since there is a better attachment of the tissues here. The team under Abd El-Dayem further concludes that both advantages together, the absolutely tension-free fit of the bar and the material itself, could lead to even less peri-implant bone resorption, which further improves the long-term prognosis.

Case presentation

A 73-year-old woman, a non-smoker with an unremarkable medical history, was given six implants with two milled bars as anchoring elements. Five XIVE S plus implants were inserted during a simultaneous sinus floor elevation and were allowed to heal submerged over six months. When the implant was

uncovered, a vestibular graft was performed with an apical transposition flap. Due to the less favorable bone volume in region 16, an additional XIVE TG plus implant was inserted subsequently for the purposes of the procedure and was immediately loaded (Fig. 1). The impression for the fabrication of the CAD/CAM bars was made four weeks later on the MP abutments inserted during this consultation (Figs. 2 & 3).

The advantage of the Friadent MP abutments is the transfer of the working level from the implant shoulder—that is, the crestal edge of the bone—to a supracrestal plane. Hence, the apposition of the marginal tissues on the abutment components is not affected by try-ins and other treatment steps. Furthermore, a simple visual check of the bar seating can be made. Figure 2 shows the patient's condition prior to impression making, with inserted Friadent MP abutments. The model fabricated using the MP analogs and a XIVE TG implant analog was sent to the DENTSPLY Scan Center with the temporary construction. The option of displaying and masking various structures, such as the soft tissues, the dental arrangement, the implants and the bar construction, allows a simplified check of the construction proposal (Figs. 4a–4d). This is adjusted to the practitioner's preferences as required. Galvanic bar latches are manufactured on the titanium CAD/CAM-fabricated bars, embedded in the openings for the slide axles. The tertiary structure is cast from a chrome-cobalt alloy. In order to guarantee a tension-free fit for the supported metal base, this was cemented to the bar

Fig. 3 Functional impression with FRIADENT MP impression abutments
Figs. 4 a–d Screenshots of the virtual bar construction with various overlays.

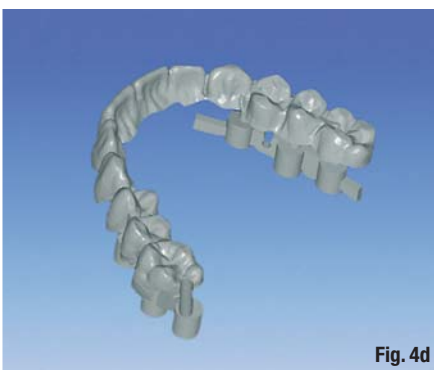



Fig. 5 Working model with bars, bar slides, tertiary structure and inserted slides.

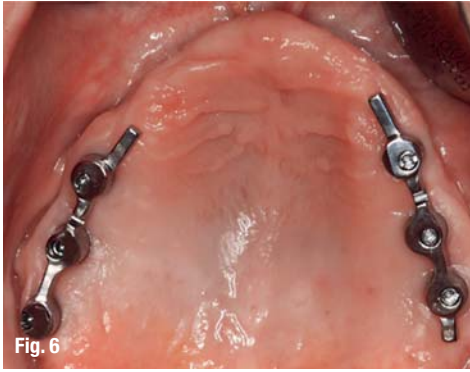


Fig. 6

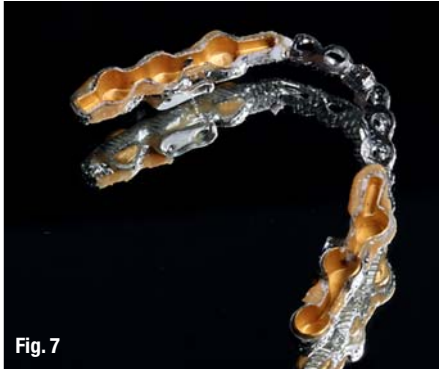

Fig. 7

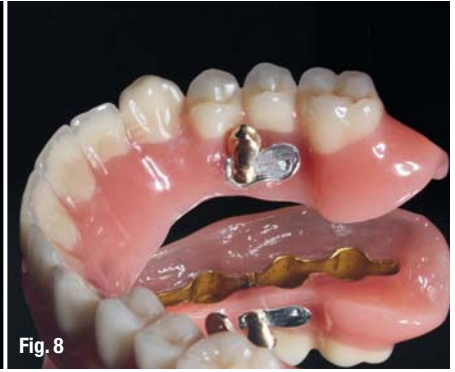

Fig. 8

Fig. 6_Titanium bars in situ.

Fig. 7_The metal base was cemented intraorally.

Fig. 8_The finished tertiary structure with open slides.

latches in the patient's mouth. The Genios dentition (DENTSPLY DeTrey) was transferred to the manufactured framework (Figs. 5–8). The final restoration was adjusted to the patient's mouth and inserted (Figs. 9 & 10). The dentition showed excellent translucency. On follow-ups 27 months after the implant insertion and 21 months after the incorporation, the tissue conditions were stable (Fig. 11). The crestal bone level was still located on the implant shoulder. No resorption was observed.

who has used this new technique will immediately recognize. Together with the use of titanium as the component material, the tension reduction represents a further advance in the reproducible retention of marginal bone. Furthermore, the bar construction with latches restores the desired level of security and hence vitality to the patient.

Editorial note: A complete list of references is available from the author.

Conclusion

Because of its good primary stability, even in marginal situations, the XIVE implant system is applicable in an augmentation of the maxillary sinus with simultaneous implant placement. Where there is little remaining bone volume, the prerequisite for this is a classic, submerged healing phase without pressure. The option of relocating the connection level to an epigingival level following uncovering reduces the risk of a deterioration of the bone in the region of the implant shoulder due to manipulation. CAD/CAM fabrication of the bar constructions markedly improves the fit of these constructions, which a practitioner

Fig. 9_Frontal view of the finished superstructure.

Fig. 10_The incorporated restoration in the patient's mouth; excellent translucence of the selected dentition (Genios, DENTSPLY DeTrey).

Fig. 11_OPG for the follow-up; stable conditions almost two years after incorporation of the prosthetic restoration.

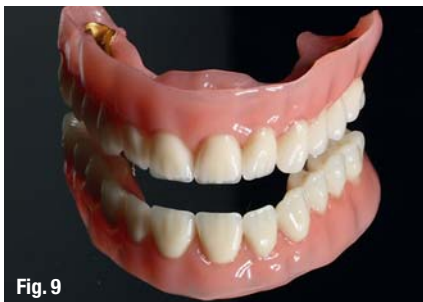

Fig. 9

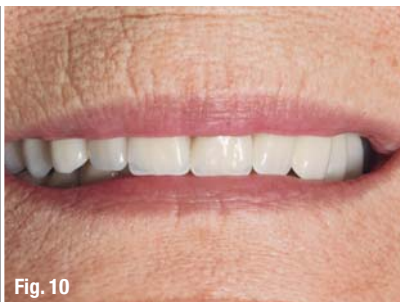

Fig. 10

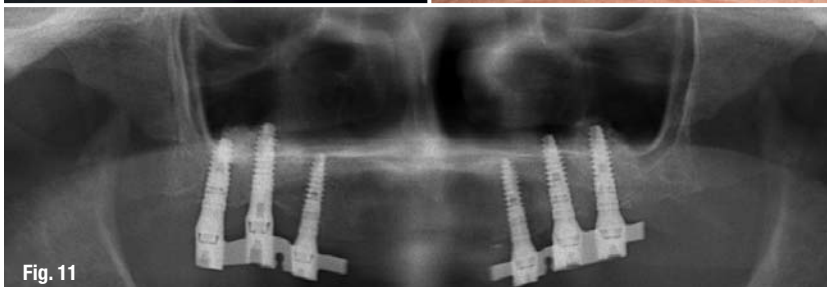


Fig. 11

_about the author implants



Dr Arnd Lohmann got his Licensure in Hamburg, Germany, in 2002 and worked as assistant doctor in Oral and Maxillofacial Surgery from 2002 to 2003. In 2003 he completed his dissertation. He has focused on Oral Implantology since 2003

and completed his Master of Science in Oral Implantology in 2007. He is a member of the German Society of Oral Implantology (Deutsche Gesellschaft fuer Orale Implantologie, DGO), the German Association of Dental Implantology (Deutsche Gesellschaft fuer Zahnärztliche Implantologie, DGZI) and the German Association of Oral Implantology (Deutsche Gesellschaft fuer Implantologie, DGI). He works in a partnership and medical practice with Dr Rainer Lohmann in Bremen, Germany

_contact implants

Dr Arnd Lohmann, MSc
Ostpreußische Str. 9
28211 Bremen, Germany

Tel.: +49 421 443868

mail@zahnarztpraxis-dr-lohmann.de
www.zahnarzt-dr-lohmann.de