

The use of direct FRC posts in the restoration of endodontically treated anterior and premolar teeth—A clinical perspective

Author | Dr Ian Kerr, UK

The restoration of endodontically treated teeth has long been a challenge to the dental profession and the success of endodontics is directly affected by the quality and integrity of the coronal seal created by the final restoration.¹ Recent advances in restorative dentistry have led to a bewildering array of treatment options for patients and it is essential that dentists present these options so that patients can make informed choices that are right for them. When we present these choices, we need to bear in mind that

Fig. 1 | Ideal properties of a retentive post.

THE IDEAL CHARACTERISTICS OF A POST

- good retention;
- good biocompatibility;
- good aesthetics;
- good retrievability;
- modulus of elasticity (to dentine);
- compressive strength (to dentine);
- co-efficient of thermal expansion (to dentine);
- minimal capacity for moisture absorption; and
- anti-cariogenic properties.

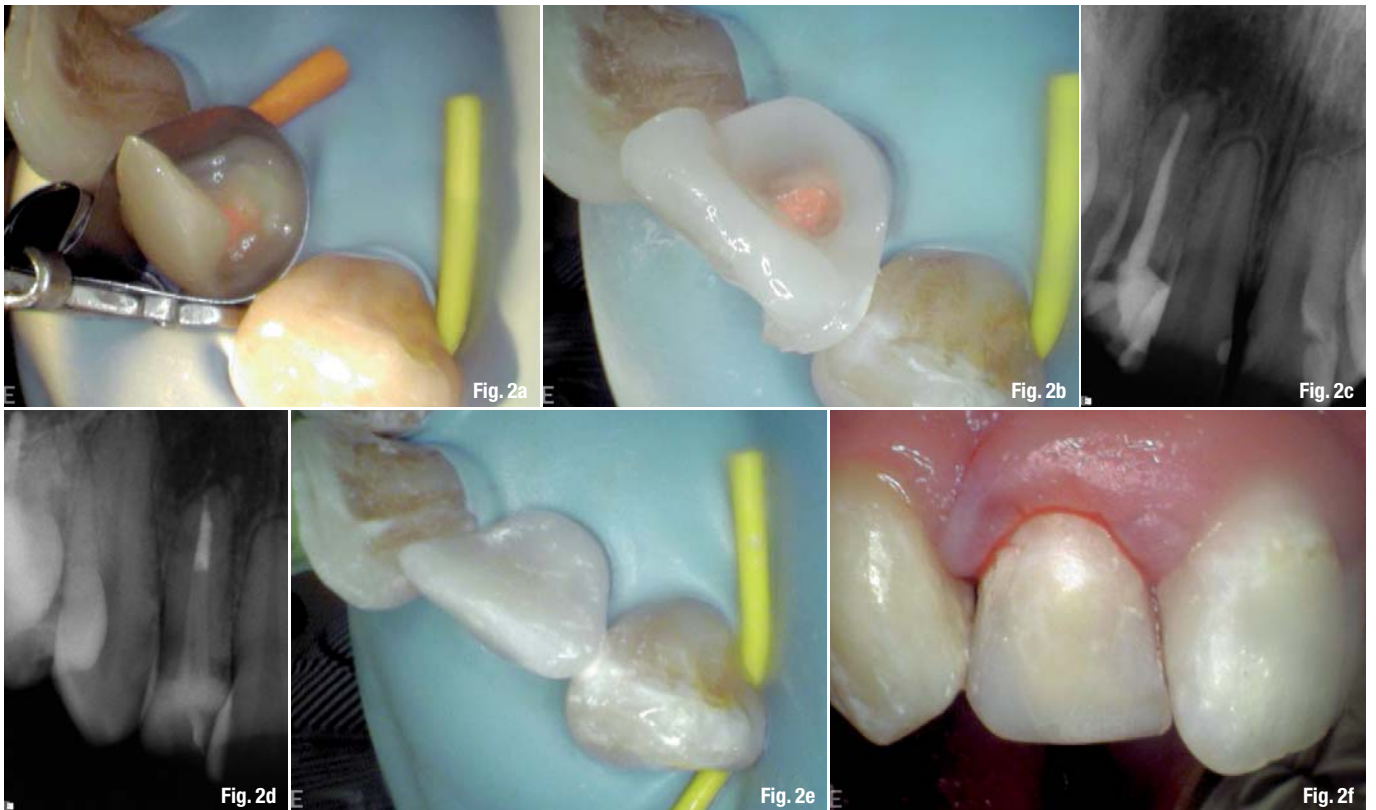
Fig. 1

the financial implications of restorative dentistry are increasingly important to patients, so we need to look at both the financial and the biological costs that we are asking our patients to pay and must advise them clearly on these matters before treatment begins.

When discussing fibre-reinforced composite (FRC) dentistry with colleagues, there is often a discussion along the lines of, wouldn't an implant be better? For me, this is a flawed question, as there is no single

treatment option that can guarantee a lifetime result for our patients. Rather than looking at which is best, we should look at what is most appropriate for the patient right now. A survey conducted by Taloustutkimus in Finland in 2002 sampled 300 dentists and looked at the uptake of treatment to replace or restore one damaged or missing tooth before and after the introduction of FRCs. The survey revealed that once FRC options became readily available the number of patients taking up no treatment dropped from 47 to 17%, indicating that FRC often represents an acceptable treatment option to patients who would otherwise have rejected conventional crowns, bridges, implant-retained crowns, etc. By delivering minimally invasive options that are easily repaired, we can delay the loss of the tooth for many years. This dynamic lifetime therapy leaves all other options available for later in the patient's life when his or her circumstances and dental techniques may have changed.

When we are presented with a restoratively compromised tooth in need of root-canal treatment, we need to be able to follow a simple pretreatment protocol to establish the answer to two simple questions: can we restore the tooth and should we restore the tooth? The first question relates to both our own clinical abilities as a dentist and the clinical parameters of the case. If we feel that the case lies within our skill range (by this I mean something that we are *proficient* at rather than merely *competent* at), then we need to consider the clinical parameters. A full discussion of the pre-endodontic assessment of a tooth is beyond the scope of this article, but if we are going to ask our patients to part with their hard-earned money, then I think we should have a high degree of confidence that we will be able to fully isolate the tooth, locate all the canals using adequate magnification and illumination, negotiate the canals to full working length, prepare them fully to allow adequate

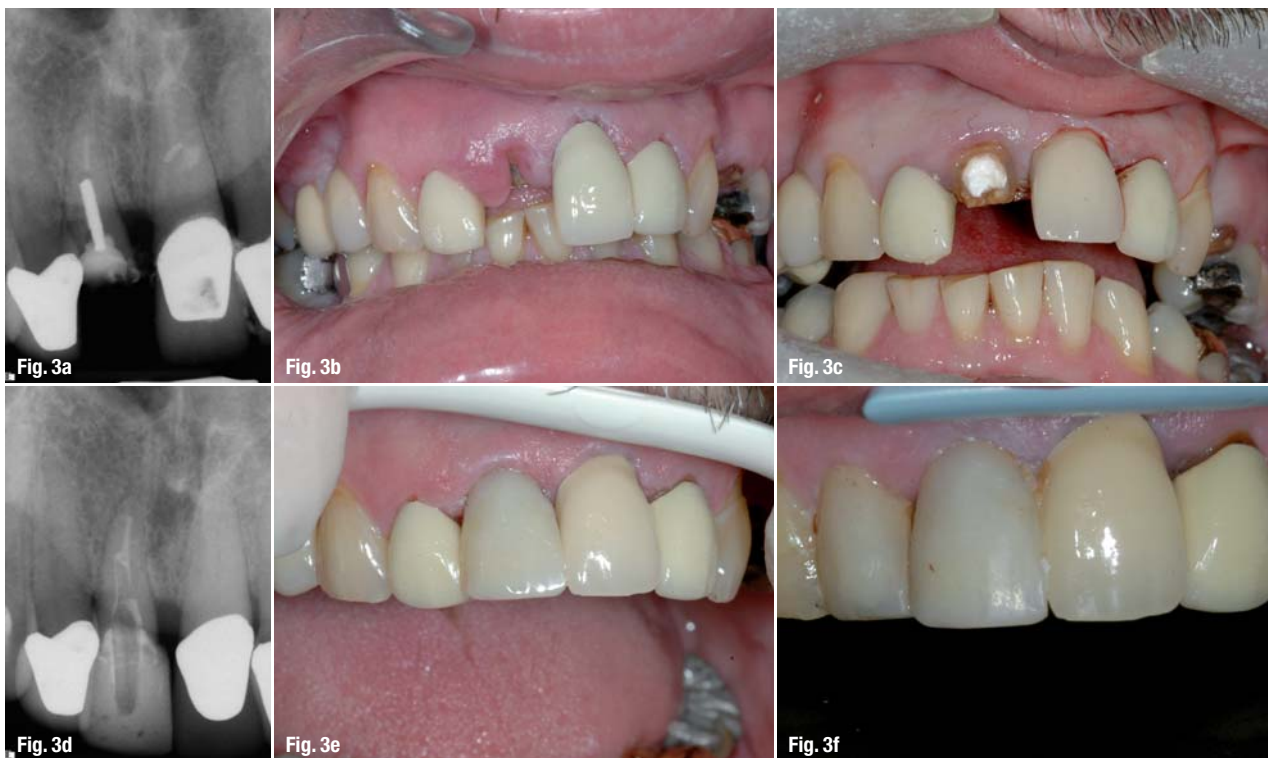

irrigation and disinfection of the canal structure and then be able to place an appropriate restoration under ideal conditions. If we can do all of this, then the answer to the first question is yes. We must then consider the second question, *should* we restore the tooth? Just because I am technically able to provide an ideal root filling and restoration does not mean that I should if we are working in a very disease-active mouth or in a tooth that has such an unreasonably high vertical or lateral load on it that it is unlikely to survive beyond the short term. Also, just because we, as clinicians, place a very high value on tooth preservation, this does not mean that all our patients do. They may take the view that taking the tooth out and adding it to an existing denture or just accepting the gap may be a perfectly reasonable alternative; ultimately, this is their decision and one that we have to respect. Excellent fixed prosthetic alternatives exist today, from direct FRC bridges, to minimally invasive resin-bonded bridges to implant-retained crowns. The relative values of each of these options need to be weighed against the preservation and restoration of the existing tooth.

If after a lengthy discussion and pretreatment planning session we agree that a tooth should be treated endodontically, then we need to look at how we are going to restore it at the same time.

Concerning anterior teeth, it has long been the view that the provision of cast full-coverage restora-

tion does not enhance longevity² and more recent evidence has begun to cast doubt on the need for cast restorations for root-treated premolar teeth,³ at least in the first five years. What the research is much less clear on is whether we should use a cast post or fibre post and, indeed, whether a post is still indicated. Certainly, we have known for a long time that we should not increase post dimensions at the expense of dentine removal,⁴ and for even longer that the primary purpose of a post is to retain a core,⁵ but more recent research has shown that fibre posts in conjunction with resin cements can strengthen roots⁶ and can help provide single-visit, direct aesthetic restorations. Fibre posts were originally sold as preformed posts, which are certainly easy to use but can show limitations in bonding to core pastes and cements⁷ and require greater adjustment to the canal shape to fit, compared with the newer anatomical fibre posts. In the case of the Stick Tech range of anatomical posts, they also show greater bonding capacity to cores and pastes⁸ and allow for intimate adaption to the existing canal shape. It remains unclear in the literature as to the desired length of a fibre post and all the firmly held beliefs regarding post length and shape predominately come from earlier literature (such as Sorrenson & Martinoff, 1984), and relate to cast metal posts and often predate predictable resin bonding. Recent studies^{9,10} have considered short (5 mm) anatomical fibre posts and found these to have greater strength and favourable fracture patterns compared with longer posts, whilst retaining similar retention



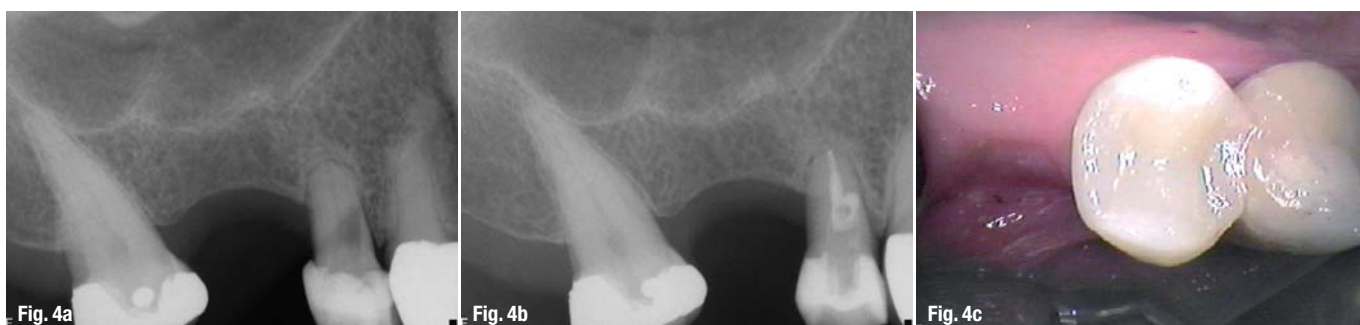strengths. Research on bonding within canals to root dentine reveals that it becomes increasingly more difficult to maintain ideal conditions the farther into the canal we progress¹¹ and that the quality of the dentine available for bonding reduces as well.¹² Bouillaquet et al. reported their findings in 2003¹⁰ and demonstrated that even the simplest of bonding techniques, such as Fuji PLUS cement (GC), show a reduction in bond strength the farther into the canal we progress, suggesting that dentine quality has a significant role to play in the bond strength achieved.

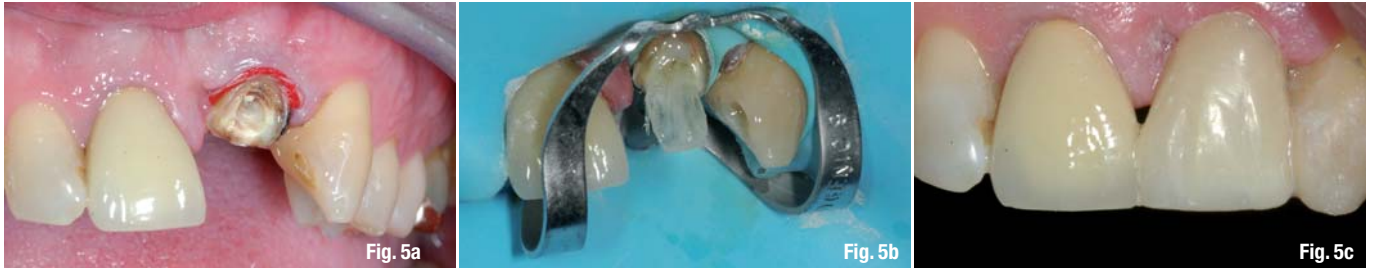If we look at the ideal characteristics of a post, then it is clear that no such post exists (Fig. 1). The best we can hope for is one that allows close adaptation to the wall with the least amount of tissue reduction, whilst providing strength to the root and retention to the core or restoration. At the same time, it should show excellent bonding to the cement and core pastes that it is used in conjunction with and minimise any stresses to the tooth tissue that supports it.

Case studies

The following cases represent everyday uses for direct anatomical FRC posts in anterior and premolar teeth. In my experience over the past five years, these techniques have shown themselves to be reliable, predictable and endlessly adaptable when used in ideal restorative conditions.

I completed each of the following cases and they were carried out under rubber dam isolation and microscopic illumination. In my opinion, the ability to isolate a tooth fully is the main factor in achieving successful bonding. The use of a rubber dam is mandatory for this work, as it allows excellent vision and isolation over an extended working time, which allows the clinician to perform the necessary bonding steps without fear of contamination. As a rule of thumb, "if the tooth cannot be isolated in its current state then bonding cannot take place"—the ability to isolate the tooth with a rubber dam is a great way of testing this rule.





Case 1: Endodontic retreatment of an upper lateral incisor and restoration with direct FRC post and core (time in mouth since completion: 22 months)

- Fig. 2a Pre-endodontic build-up required owing to extensive tooth loss.
- Fig. 2b Pre-endodontic build-up in place.
- Fig. 2c Pre-op radiograph showing extensive coronal restoration.
- Fig. 2d Post-op radiograph showing FRC post and endodontic retreatment.
- Fig. 2e Incisal view of the coronal restoration.
- Fig. 2f Buccal view of the finished direct restoration.

Case 2: Restoration of an extremely damaged upper central incisor with direct FRC (time in mouth since completion: 60 months)

- Fig. 3a Pre-op view of the decoronated incisor due for extraction.
- Fig. 3b Clinical view of gingival overgrowth preventing isolation.
- Fig. 3c Root face exposed after electrocautery.
- Fig. 3d Radiographic view of direct FRC post and crown.
- Fig. 3e Clinical view of direct FRC post and crown.
- Fig. 3f The 5 year follow up.

Case 3: Root treatment and MTA repair of perforation and direct FRC for an extremely compromised upper premolar (time in mouth since completion: 36 months)

- Fig. 4a Pre-op radiograph showing lateral perforation.
- Fig. 4b Post-op restoration showing lateral repair with MTA and glass ionomer cement and direct anatomical FRC post and restoration.
- Fig. 4c Intra-oral view of direct FRC restoration.

Case 4: Complete crown build-up with horizontal supporting fibre from adjacent tooth

- Fig. 5a Decoronated sclerotic root with insufficient tooth tissue for full ferrule preparation.
- Fig. 5b Vertical post fibres placed in access cavity. Horizontal fibre placed from the canine later in the restorative process.
- Fig. 5c Final direct restoration (G-aenial composite, GC; everStickC&tBridge fibres, Stick Tech).

Conclusion

From a restorative perspective:

- there is no true perfect system for restoring endodontically treated teeth; that is why we have hundreds of systems from which to choose;
- the literature cannot provide a clear winner in treatment choice;
- the key to tooth survival is retention of sound tooth tissue—all techniques should be aimed at this;
- a restoration is only as good as the root filling it sits upon;
- FRC post and cores represent a clinically acceptable treatment regime compared with cast and direct metal posts;
- bonding posts with composite resin cements compensate for reduced post length;
- bond strengths to root dentine reduce as we extend down the root;
- short (5 mm) anatomical posts cemented and cured simultaneously with core paste provide optimal root strength.

In my opinion, providing direct FRC posts, cores and complete build-ups is one of the most enjoyable aspects of dentistry and yet represents only a small part of the role FRCs can play. In future articles, I will look at their role in restoring posterior teeth, replacing missing teeth and supporting periodontally involved teeth.

Editorial note: A complete list of references is available from the publisher.

about the author

roots



Dr Ian Kerr is in full time private practice where he is the co founder of the StoneRock Dental Care Group that comprises 4 separate dental practices and a post graduate training site. He is passionate about sharing his knowledge and experience with his fellow colleagues and enjoys the hands on environment where people can gain the most experience with these techniques.

info@stonerock.co.uk