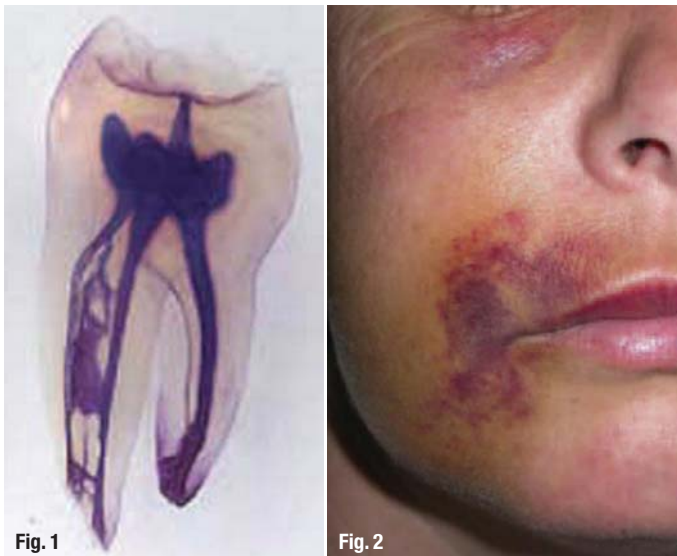

# Positive versus negative pressure irrigation

Author\_ Dr Gregori M. Kurtzman, USA



requires careful attention to all three to provide long-term clinical success.

Teeth have a very complex pulpal anatomy, and instrumentation alone cannot prepare the canal system for obturation adequately. The intricacies of the canal anatomy with its fins, lateral canals and apical deltas make it impossible for endodontic instruments to reach all aspects of the anatomy (Fig. 1). Thus, irrigation is critical for removal of residual tissue and microbiota that cannot be reached by instrumentation of the main canals.

Regardless of the file system used for instrumentation, files cannot reach all of the pulpal anatomy, and therefore disinfection is key to augmenting the cleaning process prior to obturation. What is meant by disinfection of the canal system? Disinfection entails removal of the residual tissue in the canal system and the associated bacteria through flushing the canal system with irrigation solution.

The objective is to remove as much residual tissue as possible through thorough irrigation, as the less residual tissue, the less bacteria and the more successful the clinical outcome of the endodontic treatment.

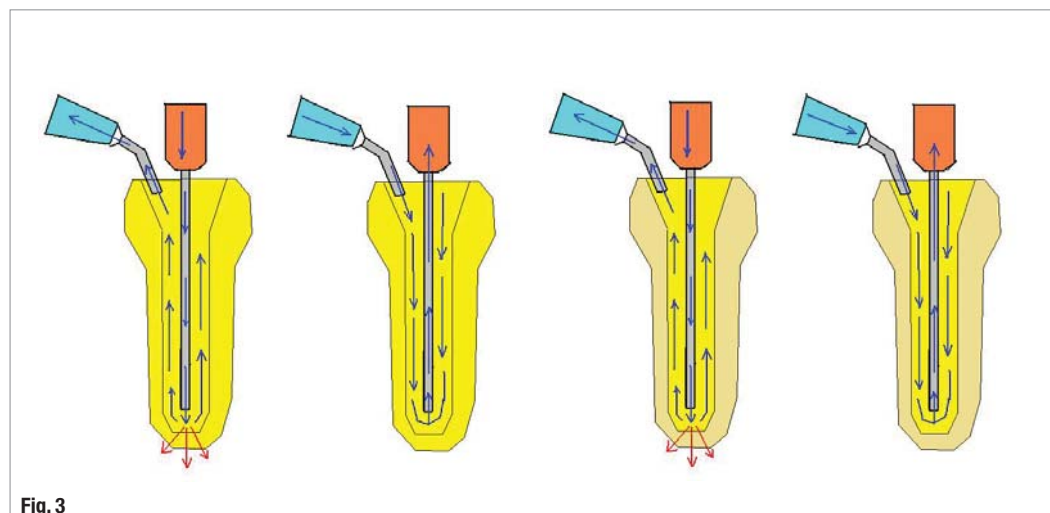
## The endodontic triad

Long-term endodontic success is not due to a single factor but is dependent upon three critical aspects of treatment called the "endodontic triad": instrumentation, disinfection and obturation. These three components of the triad are interwoven, and success

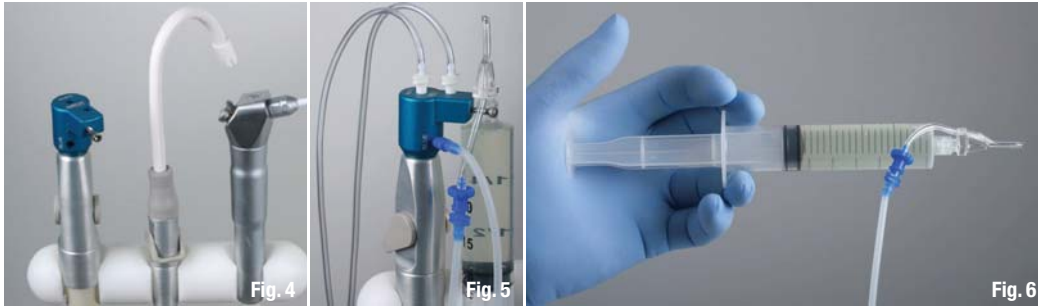**Fig. 1** \_ Cleaned molar with dye within the canal system, illustrating the complex anatomy normally found in teeth.

**Fig. 2** \_ Result of NaOCl being extruded periapically into the facial spaces from forceful irrigation with positive pressure during endodontic treatment.

**Fig. 3** \_ Comparison of positive (left) and negative (right) pressure with regard to endodontic irrigation.



**Fig. 3**



**Fig. 4** EndoVac MPA (left) on HVE connector and line.  
**Fig. 5** EndoVac (blue) connected to HVE suction line and to the Master Delivery Tip syringe. A separate line connects to the MacroCannula or MicroCannula suction tip.  
**Fig. 6** EndoVac Master Delivery Tip syringe with suction line connected to MPA.

## Cleaning the canal

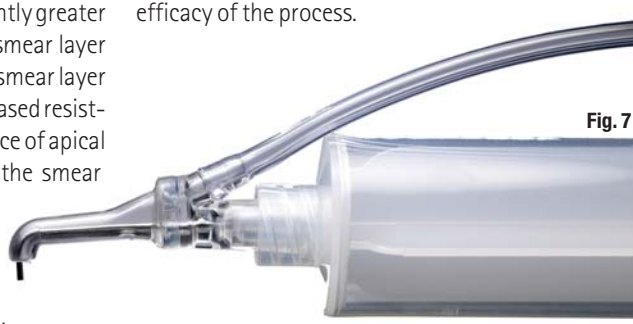No matter what obturation material is used, how well the sealer adheres to the canal walls is important. The smear layer may prevent sealer penetration into the dentinal tubules. In past studies, the frequency of bacterial penetration through teeth obturated with the smear layer intact (70%) was significantly greater than that through teeth from which the smear layer had been removed (30%). Removal of the smear layer enhanced sealability as evidenced by increased resistance to bacterial penetration.<sup>1</sup> The incidence of apical leakage was reduced in the absence of the smear layer, and the adaptation of gutta-percha was improved no matter what obturation method was used later.<sup>2-4</sup>

What is used to obturate the canals is important; however, the manner in which the canal is prepared prior to obturation also determines how well the canal will be sealed. Rotary instrumentation with NiTi files has shown less micro-leakage than hand-instrumented canals, irrespective of what was used to obturate the canal.<sup>5</sup> Compared with stainless-steel hand filing, the machining of the canal walls with NiTi rotary instruments provides smoother canal walls and shapes that are easier to obturate. The better the adaptation of the obturation material to the instrumented dentinal walls, the less leakage is to be expected along the entire root length. The better the canal walls are prepared and cleaned, the greater the amount of smear layer and organic debris removed will be, which is beneficial to root-canal sealing.

Smear layer removal is best achieved by irrigating the canals with NaOCl, followed by 17% EDTA.<sup>6</sup> NaOCl dissolves the organic component of the smear layer, exposing the dentinal tubules lining the canal walls, whereas EDTA, a chelating agent, dissolves the inorganic portion of the dentine, opening the dentinal tubules. Alternating between the two irrigants during instrumentation will permit removal of more organic debris farther into the tubules, increasing resistance to bacterial penetration once the canal has been obturated.<sup>7,8</sup>

Studies suggest that the regular exchange and use of large amounts of irrigant should maintain the

antibacterial effectiveness of the NaOCl solution, compensating for the effects of concentration.<sup>9</sup> Volume is more critical to canal disinfection during treatment than the concentration of the irrigant.<sup>10</sup> Flushing of the irrigant also serves to remove the debris, exposing the dentine around the anatomy in the canal system to further action of the irrigant, improving the efficacy of the process.

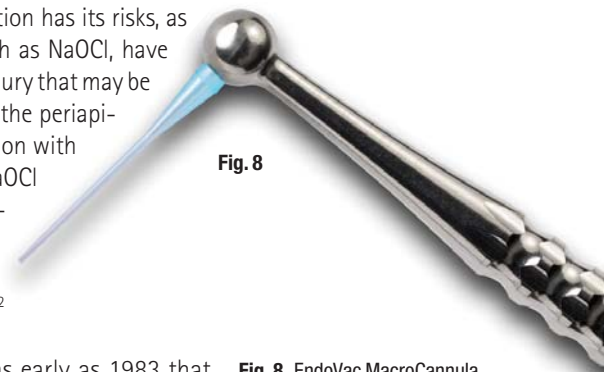


**Fig. 7** EndoVac Master Delivery Tip (irrigation and suction) on a disposable syringe.

## Positive versus negative pressure

Irrigation as it relates to endodontic treatment involves placement of an irrigation solution into the canal system and its evacuation from the tooth. Traditionally, this involved placement of the irrigant with an end-port or side-port needle into the apical canal and expressing solution out of the needle to be suctioned coronally. This creates a positive pressure system, with force created at the end of the needle, which may lead to solution being forced into the periapical tissue. Positive pressure irrigation has its risks, as some irrigation solutions, such as NaOCl, have the potential to cause tissue injury that may be extensive when encountering the periapical tissue and its communication with tissue spaces (Fig. 2). These NaOCl accidents can lead to permanent physical injury or disability, with facial deformation and neurological complications.<sup>11,12</sup>

Chow was able to show as early as 1983 that positive pressure irrigation has little or no effect apical to the needle's orifice.<sup>13</sup> This is highlighted in his paradigm on endodontic irrigation, "For the solution to be mechanically effective in removing all the particles, it has to: (a) reach the apex, (b) create a current force and (c) carry the particles away."



**Fig. 8** EndoVac MacroCannula on the handpiece.



Fig. 9

**Fig. 9**\_EndoVac MicroCannula in the finger piece and close-up showing the rounded end with multiple lateral micro-holes.

The inability to eliminate intra-radicular micro-organisms from the canal system, especially in the apical portion of the root, increases the risk of clinical failure.<sup>14</sup>

A negative pressure irrigation system however does not create positive pressure at the needle's tip, so potential accidents are essentially eliminated. In a negative pressure irrigation system, the irrigation solution is expressed coronally, and suction at the tip of the irrigation needle at the apex creates a current flow down the canal towards the apex and drawn up the needle. True apical negative pressure only occurs when the needle (cannula) is utilised to aspirate irrigants from the apical constriction of

the root canal. The apical suction pulls irrigation solution down the canal walls towards the apex, creating a rapid, turbulent current force towards the terminus of the needle (Fig. 3).

Haas and Edson found that "The teeth irrigated with negative apical pressure had no apical leakage. While the teeth irrigated with positive pressure leaked an average of 2.41 ml out of 3 ml."<sup>15</sup> Fukumoto found that when using negative pressure there was less extrusion of irrigant than when using needle irrigation (positive pressure) when both were placed 2 mm from working length.<sup>16</sup>

What other sequelae can occur with minute amounts of NaOCl leaking from the apex during the irrigation process? Gondim et al. in a study of post-operative pain comparing positive and negative pressure irrigation systems report, "The outcome of this investigation indicates that the use of a negative pressure irrigation device can result in a significant reduction in postoperative pain levels in comparison to conventional needle irrigation."<sup>17</sup> So although we may not see NaOCl accidents frequently, it is possible to see the effects of positive pressure irrigation allowing some minute extrusion apically in our normal, day-to-day endodontic treatment. They further state that "the use of the EndoVac system did not result in apical extrusion of irrigant, hence chemical irritation of the periapical tissues leading to postoperative pain may not be likely." They conclude that "It is safe to use a negative pressure irrigation protocol for antimicrobial debridement up to the full working length."

**Fig. 10**\_Obturation of apical anatomy following irrigation with the EndoVac system, demonstrating apical deltas. (Image courtesy of Dr Richard Rubinstein, Farmington Hills, Michigan.)

**Fig. 11**\_Obturation of apical anatomy following irrigation with the EndoVac system, demonstrating lateral anatomy. (Image courtesy of Dr Richard Rubinstein)

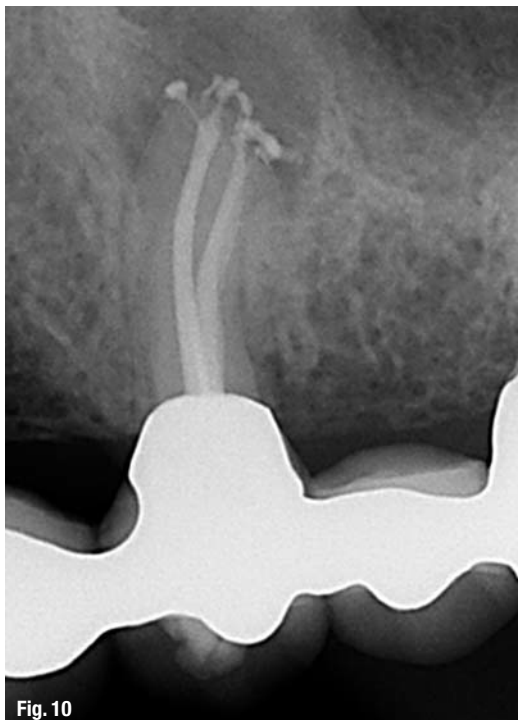
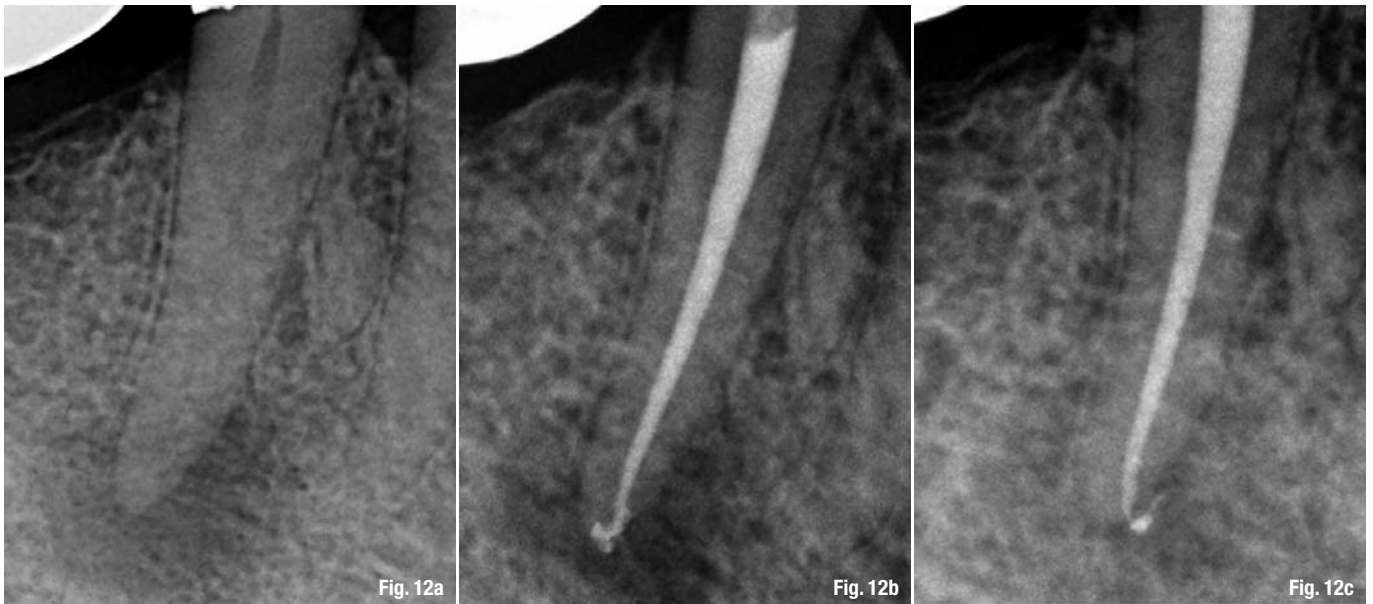


Fig. 10

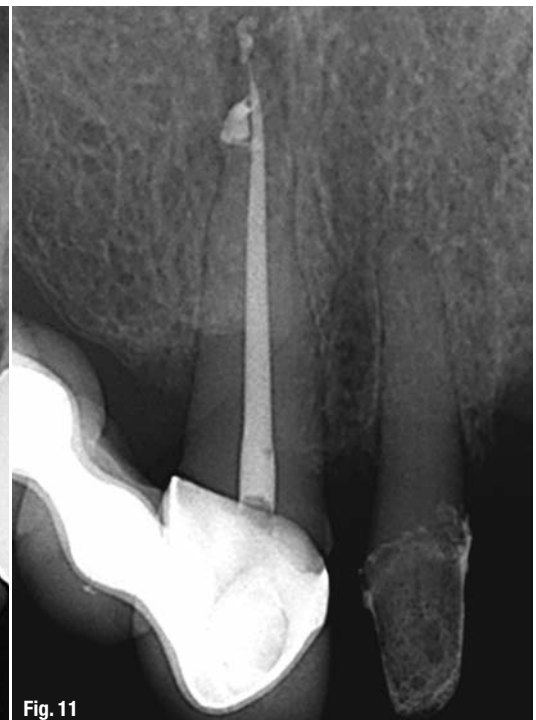

Fig. 11



### EndoVac endodontic irrigation system

Designed by Dr G. John Schoeffel after over a decade of research, the EndoVac irrigation system (SybronEndo) was developed as a means to irrigate and remove debris to the apical constriction without forcing solution out of the apex into the periapical tissue. The system utilises negative pressure through the high-volume evacuation system, permitting thorough irrigation with high volumes of irrigation solution.

The EndoVac system consists of a multi-port adapter (MPA) assembly that connects to the high-volume evacuation hose (HVE) in the dental operatory (Figs. 4 & 5). To this, connects the Master Delivery Tip (irrigation and suction together) with a disposable syringe filled with irrigation solution (Figs. 6 & 7). Either the MacroCannula (Fig. 8) or MicroCannula (Fig. 9) is attached and used simultaneously with the Master Delivery Tip during treatment. The plastic MacroCannula is placed on a handpiece attached to tubing that connects to the MPA via a separate line. This is used for coarse debris removal. The MicroCannula is a metal suction tip available in either 21, 25 or 31 mm lengths with 12 micro-holes in the terminal 0.7 mm of the tip, permitting removal of particles that are 100 $\mu$  or smaller to the apical constriction. This tip fits into a metal finger piece and is connected to the MPA (Fig. 5) in the HVE via tubing. The turbulent current force generated in the MicroCannula rapidly flows to the micro-holes at the terminus, which can reach within 0.2 mm of full working length. Quite simply, the vacuum formed at the tip of the MicroCannula is able to achieve each of the objectives in Chow's irrigation paradigm.

Nielsen and Baumgartner found that the volume of irrigant delivered with the EndoVac system was significantly greater than the volume delivered with

needle irrigation over the same amount of time.<sup>18</sup> Furthermore, they reported significantly better debridement 1 mm from working length for the EndoVac system compared with needle irrigation.

Since one of the laws of physics states, "only one object can occupy a space at a time," if the tissue remnant can be removed from the lateral canals, apical deltas and fins within the canal system, these areas can be filled with obturation material, providing a better seal and limiting bacteria in the canal system. The EndoVac irrigation system, as Nielsen and Baumgartner demonstrated, is able to clean at the apex more thoroughly than other irrigation methods and systems have been able to do (Figs. 10–12).

### EndoVac technique

Following removal of the chamber roof and exposure of the pulp, the Master Delivery Tip is used to provide frequent and abundant irrigation as the orifices are identified and explored. The Master Delivery Tip may be used to deliver irrigant into the pulp chamber while also suctioning debris brought coronal during the instrumentation process (Fig. 13). Care must be taken to deliver the irrigant passively into the pulp chamber and to avoid delivering irrigant directly into the orifice, as this will create positive apical pressure. The benefit of the Master Delivery Tip is that, with a single tip at the tooth's access, visibility is not blocked and large volumes of irrigation solution can be utilised. As the canals are being instrumented to a size #30 with a 0.04 taper, the MacroCannula is introduced between changes in file size. The MacroCannula is utilised to remove coarse debris during instrumentation and is used in combination with the Master Delivery Tip, which delivers the irrigation solution. Negative pressure is created as irrigation solution is

**Figs. 12a–c** Negative pressure irrigation using the EndoVac system, allowing thorough debridement of the canal system, and the apical lesion demonstrating significant healing apically, as well as sealer in the lateral canal at mid-root. Initial (a), following completion of endodontic treatment (b) and six months post-treatment (c).



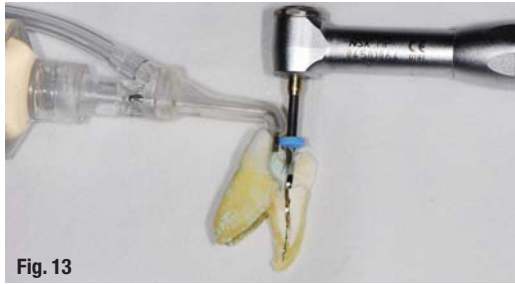

Fig. 13

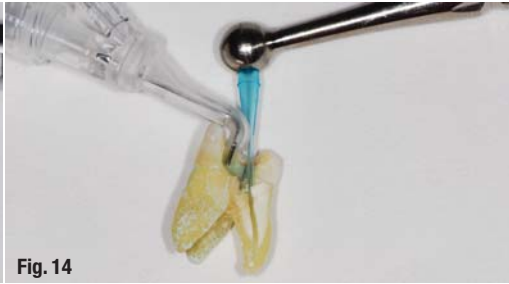

Fig. 14

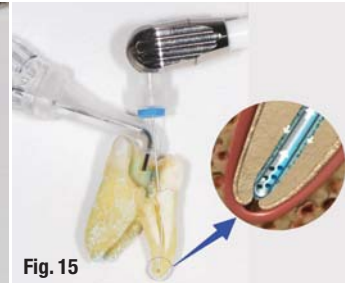


Fig. 15

**Fig. 13** Master Delivery Tip being used to provide constant irrigation as the canal is instrumented.

**Fig. 14** Use of the MacroCannula and Master Delivery Tip.

**Fig. 15** Use of the MicroCannula, showing placement of the tip in the apical root end.

drawn down the canal towards the apex as it is expressed from the Master Delivery Tip and then drawn up the MacroCannula (Fig. 14). It is suggested that the MacroCannula be used with a slight pumping motion as each canal is flushed. Irrigation should continue with the MacroCannula until clear fluid is observed being withdrawn through the tubing connected to the handpiece before proceeding to the next file.

When the canal has been enlarged to the desired size, the MacroCannula is again used until clear solution is observed in the tubing. This will ensure that all coarse debris has been removed from the canal. Next, the metal MicroCannula is placed in the finger piece and attached to the MPA connector line (white connection) and used upon completion of canal instrumentation to remove fine debris to the apical constriction under negative pressure once the canal has been instrumented to a size #35 with a 0.04 taper or greater (Fig. 15). To prevent plugging of the fine holes in the apical constriction, the MicroCannula must not be used until thorough irrigation has been accomplished with the MacroCannula and all instrumentation has been completed.

## \_Conclusion

Instrumentation, disinfection and obturation are important aspects of rendering quality endodontic care. Yet, the instruments we use to prepare the canal, whether hand or mechanised, are unable to reach all aspects of the canal system. Irrigation is key to cleaning and disinfecting those areas that cannot be reached by instrumentation alone.

The EndoVac irrigation system with its negative pressure is able to move much larger volumes of irrigant through the canal system, safely, resulting in more thorough removal of the fine debris at the apical constriction, thereby providing a better environment for sealing. Accordingly, negative pressure irrigation not only greatly improves both the flow and safety of irrigation with NaOCl, but has also been shown to minimise post-operative sensitivity following treatment, compared with traditional positive pressure irrigation protocols.

*Editorial note: A complete list of references is available from the publisher.*

## \_about the author

roots



**Dr Gregori M. Kurtzman** is in private general practice in Silver Spring, Maryland, and is a former assistant clinical professor at the University of Maryland. He has lectured internationally on the topics of restorative dentistry, endodontics, implant surgery and prosthetics, removable and fixed prostheses, and periodontics, and he has over 260 published articles. He is a fellow of the Academy of General Dentistry, American Academy of Implant Prosthodontics, American College of Dentists, International Congress of Oral Implantologists, Pierre Fauchard Academy, Academy of Dentistry International; master of the Academy of General Dentistry and International Congress of Oral Implantologists; and diplomate of the International Congress of Oral Implantologists and American Dental Implant Association.

## \_contact

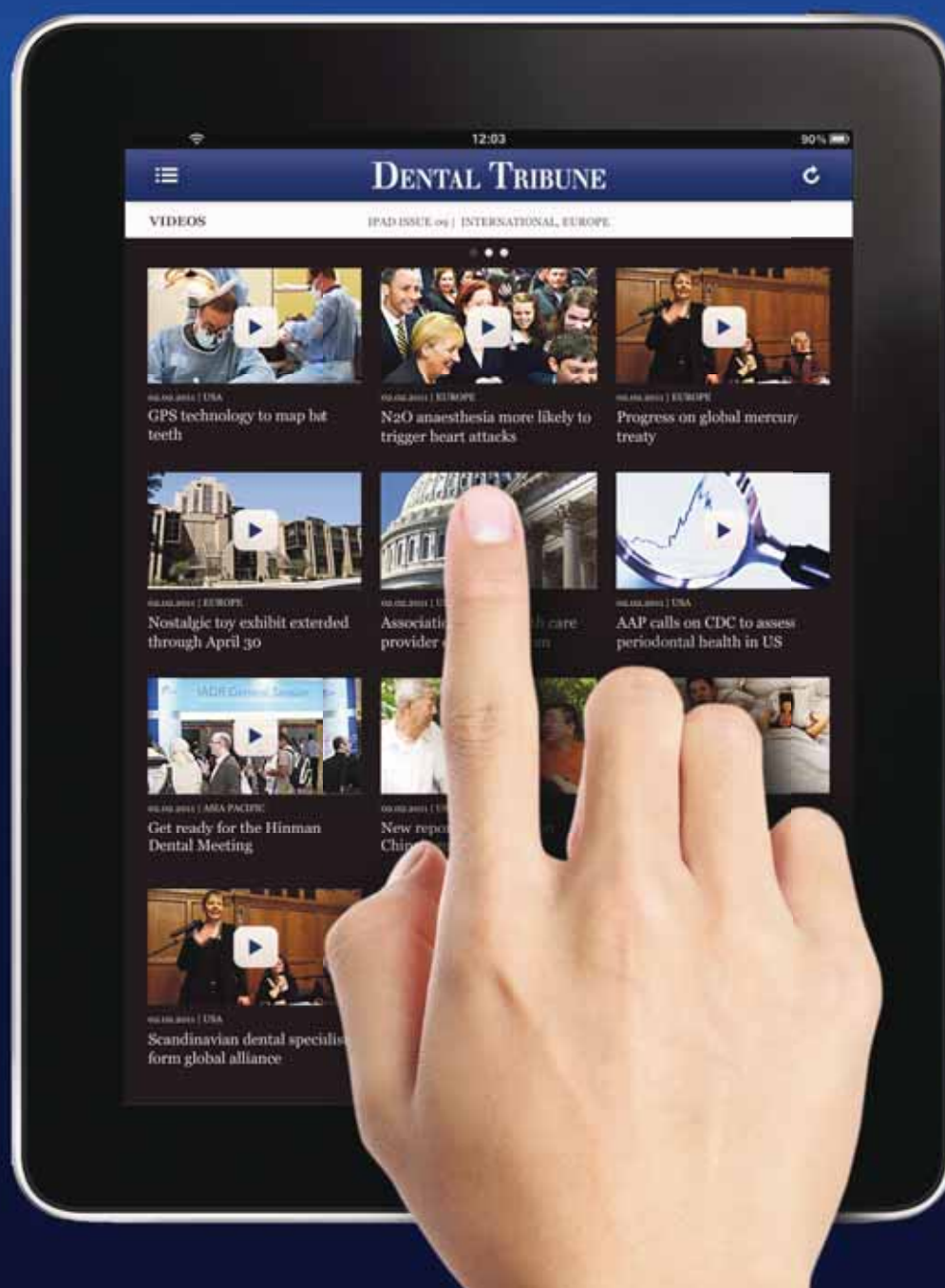Leisure World Plaza Professional Building  
3801 International Drive, Suite 102  
Silver Spring, MD 20906  
USA

drimplants@aol.com  
www.maryland-implants.com

# Dental Tribune for iPad – Your weekly news selection

Our editors select the best articles and videos from around the world for you every week. Create your personal edition in your preferred language.

[ipad.dental-tribune.com](http://ipad.dental-tribune.com)



# DENTAL TRIBUNE

— The World's Dental Newspaper —