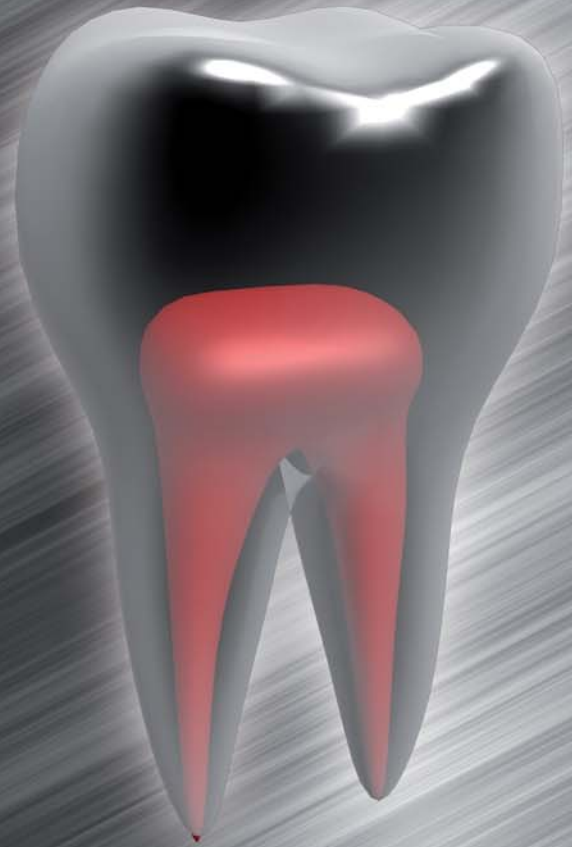

# roots

international magazine of endodontology

3<sup>2012</sup>



| **special**

Endodontic retreatment:  
Achieving success the second time around

| **technique**

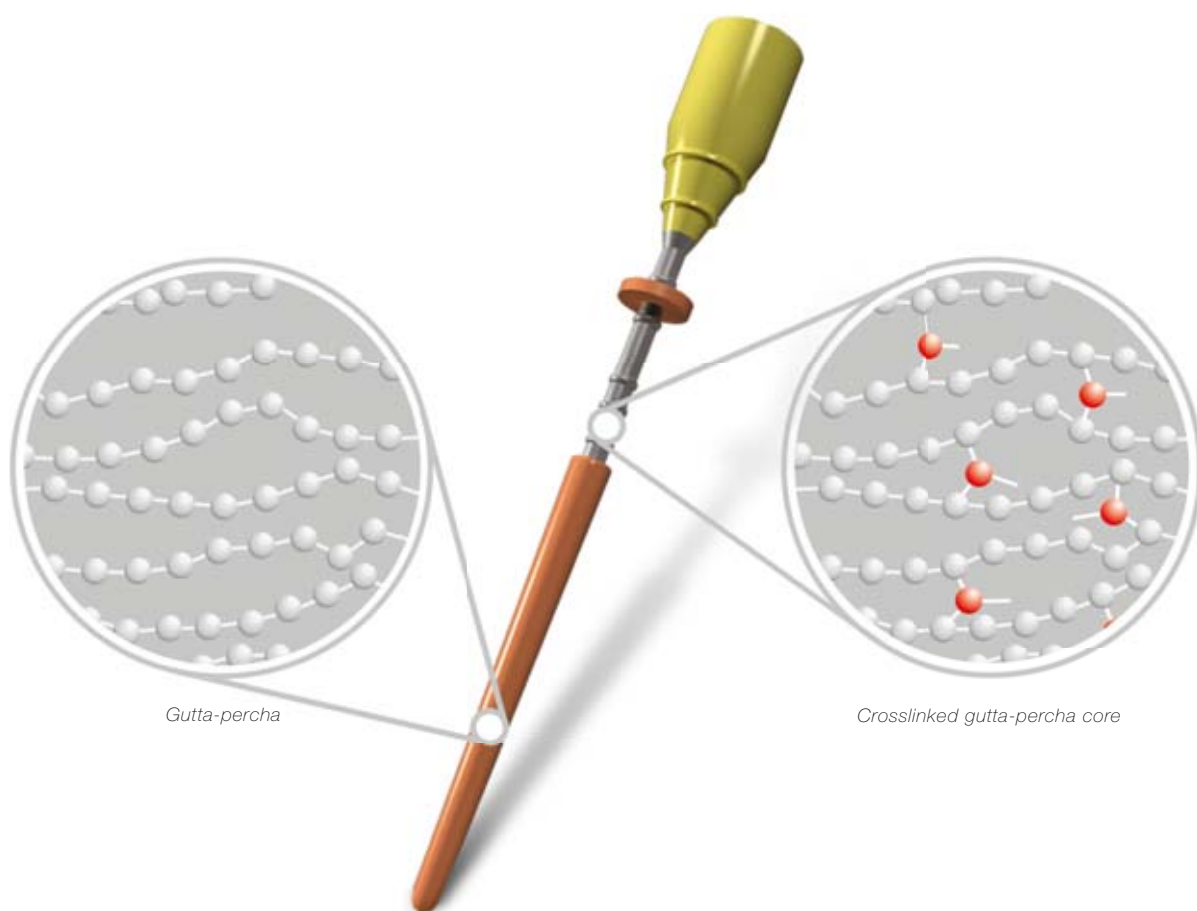
Positive versus negative pressure irrigation

| **research**

Dentine thickness in buccal roots  
of maxillary first premolars following  
preparation with three techniques

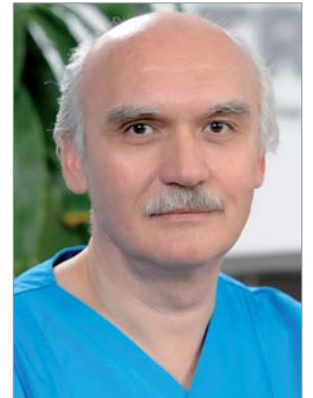
# gutta•core™

crosslinked gutta-percha core obturator



- superior 3D fills
- ease of retreatment
- post space simplified

# Dear Reader,



Bogdan Dimitriu, DDS, PhD

**As a professor and international speaker**, every year I meet hundreds of young people full of enthusiasm, pursuing their goal to conquer the endodontic world. This is beautiful, but even more beautiful is when I meet my former students, after ten or 15 years, and they still have the same passion as before. Unfortunately, it rarely happens. Why is that? What happened to their enthusiasm all these years later? Why do recent developments and trends in endodontics no longer appear to fascinate them?

On the one hand, industry is overwhelming dentists with innovative materials and technologies, which have developed rapidly in recent years. On the other hand, there is a lack of information and evidence-based literature on when and how to use them correctly. It is confusing; thus, many dentists prefer to follow traditional procedures instead of pursuing new solutions and knowledge. This leads to a routine which is very well known to kill any previous passion that could have existed.

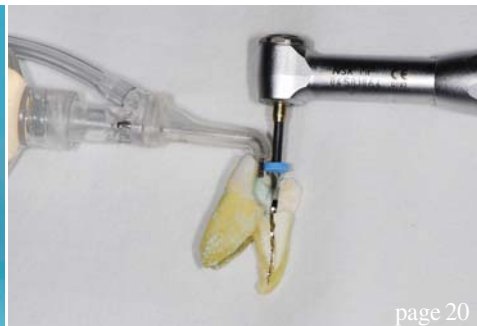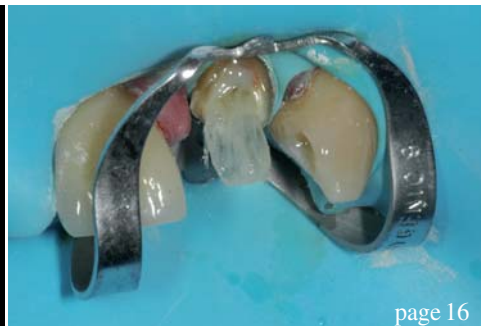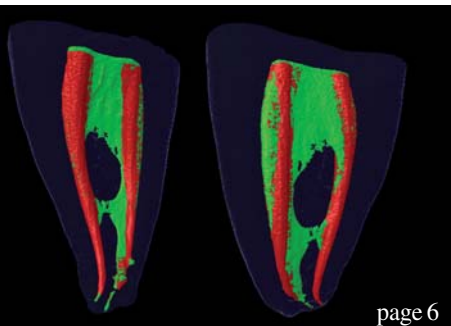
I therefore consider to be of paramount importance to undertake continuing professional development by attending congresses, following courses and reading literature. It is only in this way that you will remain up to date and as enthusiastic as before, I hope.

One year from now, in September 2013, a beautiful Lisbon will host the largest endodontics meeting in Europe: the 16<sup>th</sup> Biennial Congress of the European Society of Endodontology, organised in collaboration with the Portuguese Society of Endodontology. I encourage you to put this event in your schedule today already, as there will be a lot to learn at the congress.

Continuing professional education together with the exchange of experiences will keep us moving forward with passion that both, us and our patients really need.

Yours faithfully,

Bogdan Dimitriu, DDS, PhD  
 Professor and Chair, Department of Endodontics  
 Deputy Dean, Faculty of Dental Medicine „Carol Davila“ University  
 Bucharest, Romania



| editorial

03 Dear Reader  
| Prof Bogdan Dimitriu

| special

06 Endodontic retreatment: Achieving success the second time around  
| Dr Brett E. Gilbert

10 Non-surgical retreatment following failed apicoectomy with re-use of intra-radicular restoration  
| Dr Imran Cassim

| case report

16 The use of direct FRC posts in the restoration of endodontically treated anterior and premolar teeth  
| Dr Ian Kerr

| technique

20 Positive versus negative pressure irrigation  
| Dr Gregori M. Kurtzman

26 Determining working length  
| Dr Chris J. Lampert

| feature

28 The right to be pain free  
| Dr Michael Sultan

| research

30 Dentine thickness in buccal roots of maxillary first premolars following preparation with three techniques  
| Dr Paola Adriana Lammertyn et al.

| industry news

36 Moisture-activated temporary filling and sealing material  
| Centrix

RAYPEX 6—State-of-the-art technology  
| VDW

| meetings

38 IDS 2013: Organisers expect successful exhibition

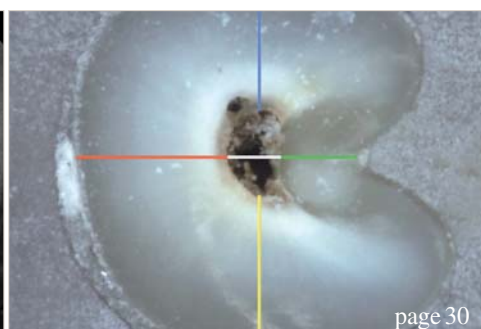
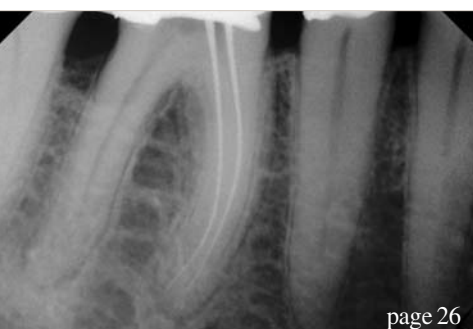40 International Events

| about the publisher

41 | submission guidelines  
42 | imprint



Cover image courtesy of © Sgame (image) and © Gilmanshin (background).





**No Pre-Registration Fee**

**The Largest  
Dental Meeting/  
Exhibition/Congress  
in the United States**

**MARK YOUR CALENDAR**

**Scientific Meeting:  
Friday - Wednesday,  
November 23 - 28**

**Exhibit Dates:  
Sunday - Wednesday,  
November 25 - 28**

**ATTEND AT NO COST**  
Never a pre-registration fee at the  
Greater New York Dental Meeting

**MORE THAN 600 EXHIBITORS**  
Jacob K. Javits Convention Center 11th Ave.  
between 34-39th Streets (Manhattan)

**HEADQUARTERS HOTEL**  
New York Marriott Marquis Hotel

**LIVE DENTISTRY ARENA - NO TUITION**

**LATEST DENTAL TECHNOLOGY  
& SCIENTIFIC ADVANCES**

**MORE THAN 350 SCIENTIFIC PROGRAMS**  
Seminars, Hands-on Workshops, Essays  
& Scientific Poster Sessions as well as  
Specialty and Auxiliary Programs

**EDUCATIONAL PROGRAMS  
IN VARIOUS LANGUAGES**

**SOCIAL PROGRAMS FOR THE ENTIRE FAMILY**

**ENJOY NEW YORK CITY AT ITS BEST  
DURING THE MOST FESTIVE TIME  
OF THE YEAR!**

**FOR MORE INFORMATION:**  
Greater New York Dental Meeting®  
570 Seventh Avenue - Suite 800  
New York, NY 10018 USA  
Tel: (212) 398-6922 / Fax: (212) 398-6934  
E-mail: victoria@gnydm.com

**GREATER  
N.Y.**

**DENTAL MEETING**

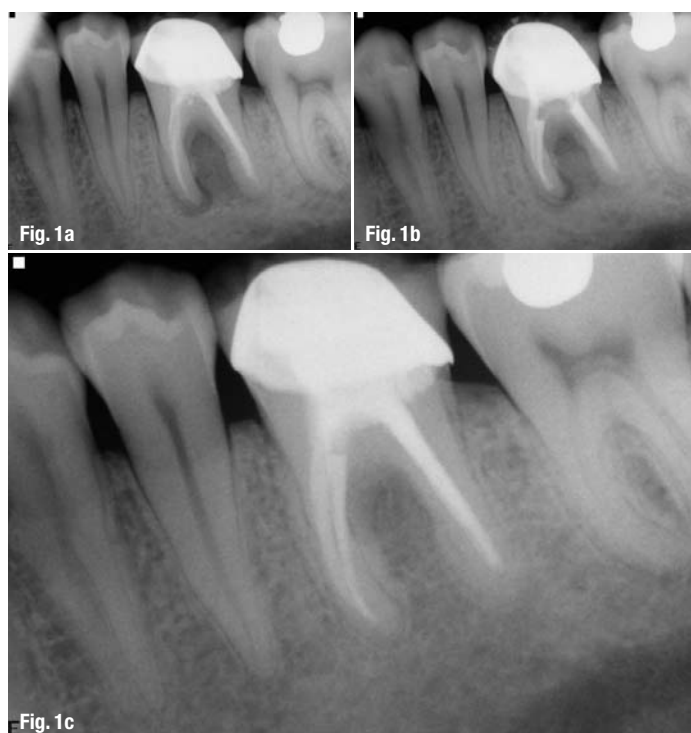
**WWW.GNYDM.COM**

Sponsored by the New York County Dental Society and the Second District Dental Society

**2 0 1 2**

# Endodontic retreatment: Achieving success the second time around

Author\_ Dr Brett E. Gilbert, USA



strictest of criteria for determining that a tooth has healed, and includes many studies that were completed prior to the clinical use of dental operating microscopes and other advanced armamentaria.

When considering treatment for a tooth that has not healed successfully with root-canal therapy, there are significant challenges to address to be able to attain complete healing of the diseased tooth. The armamentarium and techniques available today allow us the ability to disinfect the root-canal system properly after initial treatment has led to post-treatment disease.

The success rate of retreatment has been shown to be in the range of 80% healing. Phases III and IV of the Toronto Study showed such a healing rate four to six years after non-surgical retreatment.<sup>3</sup> In a systematic review by Torabinejad et al. comparing non-surgical retreatment to endodontic surgery, it was demonstrated that non-surgical retreatment had a success rate of 83% versus 71.8% for endodontic surgery after four to six years.<sup>4</sup>

The presence of pretreatment apical periodontitis is one factor that has been shown to decrease the success rate. Without apical periodontitis, a ten-year success rate of 92 to 98% has been shown for both initial and retreatment root-canal therapy. With the preoperative presence of apical periodontitis, there is a decrease in the success rate to 74 to 86% over the ten years.<sup>5</sup> From this, it is evident that endodontic healing is attainable through retreatment procedures, allowing us to maintain our patients' natural teeth (Figs. 1a-c). Although the alternative clinical treatment option of implant placement can provide an effective method for replacing a missing tooth, healthy maintenance of the natural tooth should remain the overall goal.

**\_Root-canal treatment** has been shown to have a success rate of 92%.<sup>1</sup> However, as research methodologies move towards higher levels of substantiation, clinicians must rely on the best current evidence available to gain insight into the expected outcomes of their treatment. The highest level and best current evidence we have on the clinical success of endodontic treatment comes from a meta-analysis of the literature.

A meta-analysis done in 2007 by Ng et al. provides a thorough review of endodontic success rates from a variety of classical outcome studies. They found a weighted pooled success rate of 68 to 85%, with at least one year of follow-up.<sup>2</sup> This review considers the

**Fig. 1a**\_Pre-operative image.  
**Fig. 1b**\_Post-operative image.  
**Fig. 1c**\_12 month follow-up image.  
(Case by Dr. Brett Gilbert)

Post-treatment disease is, inevitably, a result of bacteria and the host response of the patient to the bacteria. These micro-organisms are the most critical aetiology of post-treatment disease, as they are present within the root-canal system of a previously endodontically treated tooth owing to a combination of substandard endodontic techniques, iatrogenic treatment issues and restorative failure.

Intra-radicular bacteria are the primary aetiology of post-treatment disease<sup>6</sup> and eradication of these bacteria is the primary goal of retreatment procedures. The intra-radicular bacteria present in the previously treated tooth are persistent and resist removal methods. Bacteria are able to hide and survive in canal ramifications, deltas, irregularities (fins) and dentinal tubules.<sup>7</sup>

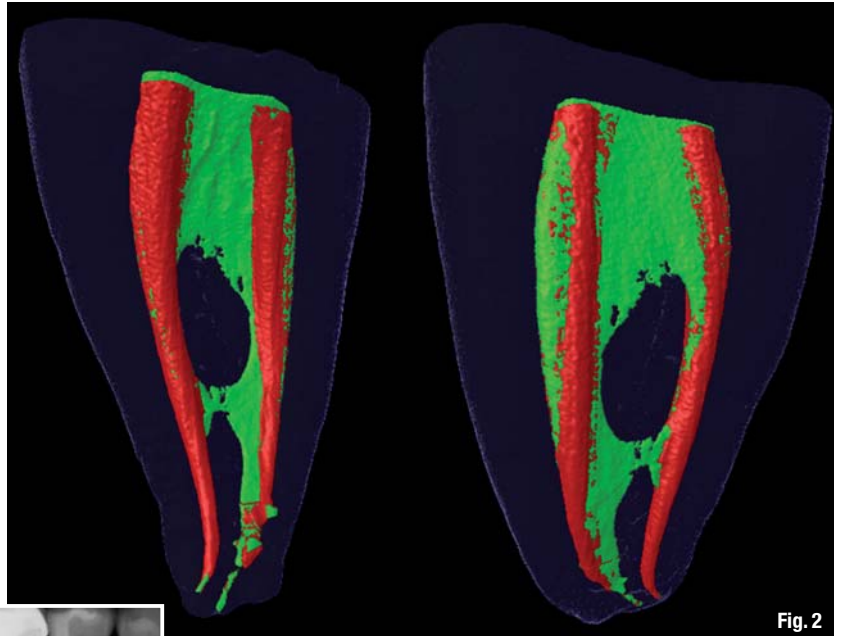


Fig. 2

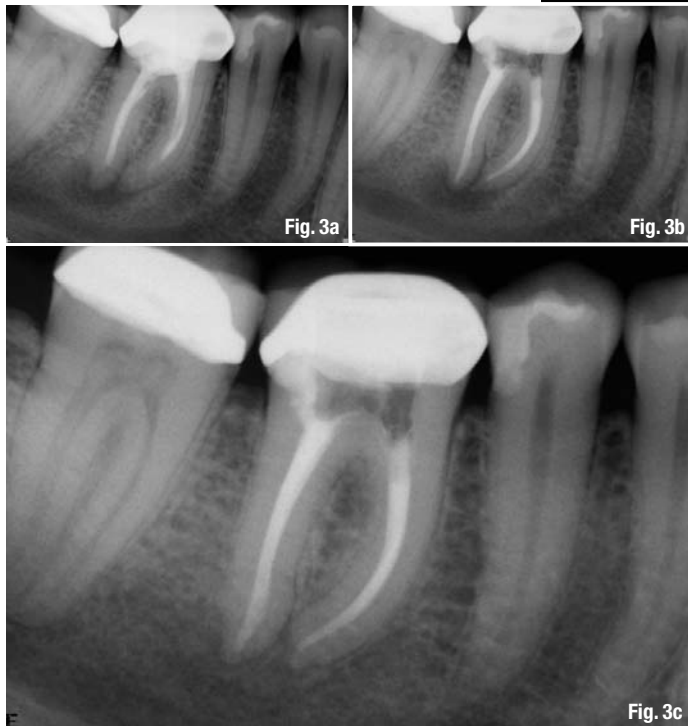

Fig. 3a

Fig. 3b

Fig. 3c

The bacteria present in the initial infection of a root canal differ markedly from the bacteria infecting a previously treated tooth. Pre-treatment flora is polymicrobial with equal numbers of Gram-negative and -positive bacteria. Post-treatment bacteria are predominantly Gram-positive<sup>10</sup> and they have been shown to be able to survive in harsh environments and to be resistant to many treatment methods.

**Fig. 2** Image displays the unprepared pulpal tissue (in green) and the post-operative prepared or instrumented areas (in red), which is evidence of the complexity of root canal anatomy. (Image courtesy of <http://rootcanalanatomy.blogspot.com>.)

**Fig. 3a** Pre-operative image.  
**Fig. 3b** Post-operative image.  
**Fig. 3c** 13-month follow-up image. (Case by Dr. Brett Gilbert)

There are high numbers of *Enterococcus* species.<sup>11</sup> *Enterococcus faecalis*, for example, has been shown to be a common isolate in 27 to 77% of teeth with post-treatment disease.<sup>12</sup> A contaminated canal space may result from incomplete cleansing initially or

subsequent leakage into root-canal spaces following root-canal treatment. Once present inside the canals, *E. faecalis* has a variety of characteristics that allow it to evade our best efforts to eradicate it from the root-canal system, including the ability to invade dentinal tubules and adhere to collagen.<sup>13</sup> It is also resistant to calcium hydroxide application inside the canal system, which is an inter-appointment treatment technique used to help remove micro-organisms and their by-products, such as lipopolysaccharides, from the canal space.<sup>14,15</sup> *E. faecalis*'s resistance of calcium hydroxide action arises from its ability to pump hydrogen ions from a proton pump. The hydrogen combines with the hydroxyl ions of calcium hydroxide and neutralises the high pH value.<sup>16</sup>

subsequent leakage into root-canal spaces following root-canal treatment. Once present inside the canals, *E. faecalis* has a variety of characteristics that allow it to evade our best efforts to eradicate it from the root-canal system, including the ability to invade dentinal tubules and adhere to collagen.<sup>13</sup> It is also resistant to calcium hydroxide application inside the canal system, which is an inter-appointment treatment technique used to help remove micro-organisms and their by-products, such as lipopolysaccharides, from the canal space.<sup>14,15</sup> *E. faecalis*'s resistance of calcium hydroxide action arises from its ability to pump hydrogen ions from a proton pump. The hydrogen combines with the hydroxyl ions of calcium hydroxide and neutralises the high pH value.<sup>16</sup>

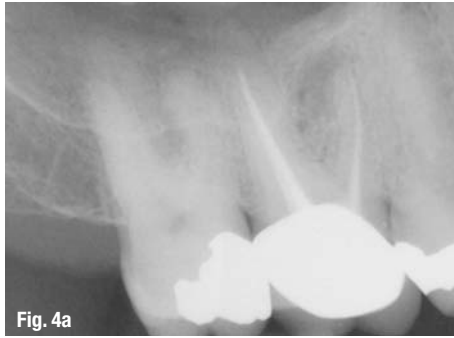

Fig. 4a

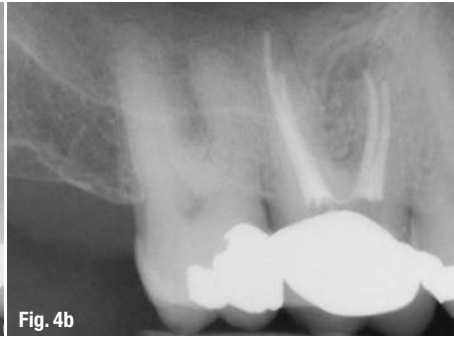


Fig. 4b

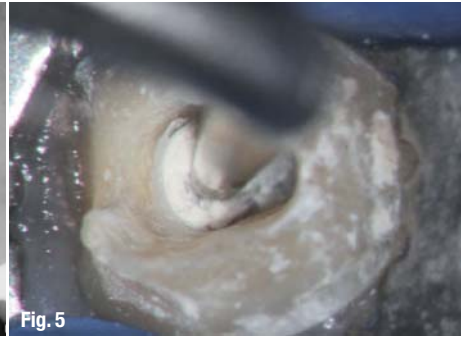


Fig. 5

**Fig. 4a**\_Tooth #3 with a radiolucent periapical lesion on the MB root apex.

**Fig. 4b**\_Post-operative image showing treatment of MB2 and appropriate lengths on retreatment of DB and P canals. (Case by Dr. Brett Gilbert)

**Fig. 5**\_Photograph displays excellent visibility and magnification of the pulp chamber with use of an ultrasonic tip. (Photograph courtesy of Dr. Scott Bentkover)

*E. faecalis* also able to resist calcium hydroxide by being part of a biofilm. The protection of bacteria within a biofilm matrix prevents the contact of the bacteria with irrigants and medicaments, and allows communication between bacteria to aid in survival capabilities.<sup>17,18</sup> The presence of *E. faecalis* is well documented; however, its role in post-treatment disease has yet to be proven definitively.<sup>19</sup> Its survival mechanisms, however, shine a light on the persistent capabilities of these bacteria, and our clinical techniques must be focused on the challenge of eliminating them.

Iatrogenic issues encountered during the initial root-canal treatment may be the cause of intra-canal bacterial infection. These issues may include perforation, incomplete cleansing and shaping, inadequate canal enlargement, missed canals, ledging, canal transportation, over-instrumentation, as well as obstruction of the canal by debris or separation of instruments. Failure to use or using too small a volume of an appropriate irrigant solution, such as sodium hypochlorite, is an iatrogenic error.

Full-strength 6% sodium hypochlorite been shown to be highly antimicrobial and able to dissolve tissue and disrupt bacterial biofilm.<sup>20,21</sup> These qualities in an irrigant are ideal for the debridement of residual bacteria and tissue debris. The use of a rubber dam to isolate the treatment field is the standard of care for endodontic treatment. Failure to use a rubber dam may be a fundamental contributor to post-treatment disease. The following case illustrates the ability to overcome prior incomplete treatment to achieve successful healing (Figs. 3a-c).

## \_Clinical example

Restorative failure is a common cause of post-treatment disease. Failure to place an effective permanent access restoration in a timely manner can allow for bacterial entry into the root-canal system by coronal leakage. Submarginal leakage on a crowned tooth can also allow bacterial entry to occur.

Decay in a previously treated tooth is another source of bacterial contamination. Structural damage to a tooth by trauma, cracking or fracture may provide an entry point for bacterial contamination of the canals. Our patients are responsible for their own oral health and must commit to effective oral hygiene techniques. Failure of the patient to perform effective oral hygiene can result in the failure of even the most well executed root-canal and restorative treatments.

With the bacterial challenges clinicians have to face, retreatment techniques must be capable of effective elimination of bacteria and their substrates. The use of a dental operating microscope and ultrasonic instruments allows clinicians to uncover all existing canal anatomy properly to ensure that they are able to cleanse the root-canal system completely. The following clinical case (Figs. 4a & b) illustrates the extent of the canal space left untreated in the initial root-canal therapy by not opening the mesiobuccal canal adequately and not locating and cleansing the hidden second mesiobuccal canal.

Endodontic ultrasonic tips are highly efficient at removing core build-up material, paste fills, posts and

**Fig. 6a**\_Pre-operative image.

**Fig. 6b**\_Post-operative image.

**Fig. 6c**\_13-month follow up image.

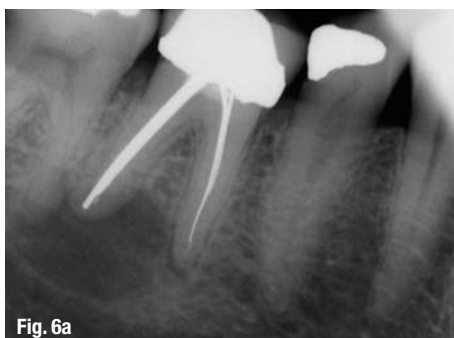

Fig. 6a

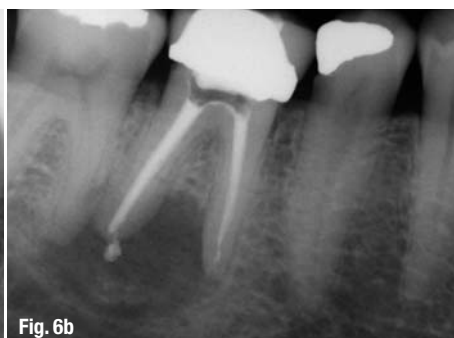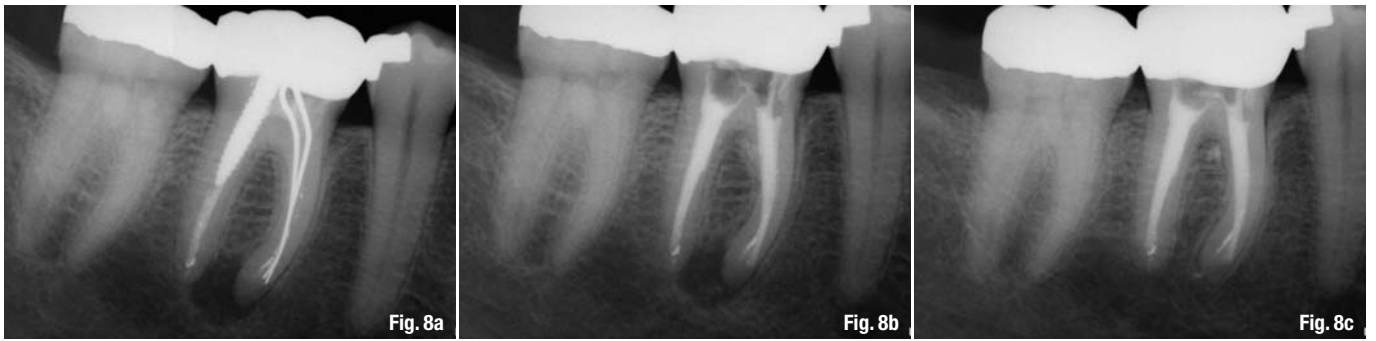


Fig. 6b

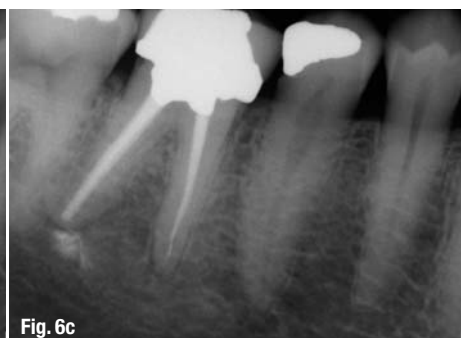

Fig. 6c





silver-point fillings, as demonstrated in Figure 5. These instruments allow clinicians to conserve root dentine by providing excellent visibility under a dental operating microscope, thereby greatly improving the ability to retreat canals (Figs. 6a–c). A heat source such as a System B tip (Axis, SybronEndo) is efficient for the removal of gutta-percha and resin materials from the coronal third. Hand and rotary files can remove root fillings and shape canals to appropriate working lengths. Current NiTi rotary files are highly flexible and resistant to separation and allow us to mechanically enlarge the apical third of root canals safely and efficiently without alteration of the natural canal morphology, which allows effective irrigation to reach the complex apical root-canal anatomy where bacteria are able to hide and resist debridement.

Once the canals have been located and instrumented, the ability to irrigate becomes essential to successful treatment. The irrigant solutions target the bacteria we are trying to eliminate. While sodium hypochlorite is a potent and proven antimicrobial and tissue dissolver,<sup>22</sup> 2% chlorhexidine has been shown to prevent the adhesion of *E. faecalis* to dentine.<sup>23</sup> EDTA 17% is often used as an effective smear-layer removal agent.<sup>24</sup> Therefore, mechanical debridement and canal instrumentation provide a pathway for copious chemical irrigation deep into the canal.

Passive ultrasonic irrigation allows clinicians to place an irrigant solution into the pulp chamber and activate it as it is carried down to the apical end of the root canal. The IrriSafe tip (Acteon Group; Fig. 7) is a non-cutting ultrasonic file that is placed into each canal and is moved up and down in the canal for three cycles of 20 seconds. Passive ultrasonic irrigation has been shown to irrigate lateral canals better at 4.5 and 2 mm from the working length of canals as compared with needle irrigation alone.<sup>25</sup> It has been demonstrated that passive ultrasonic irrigation can remove dentine debris in a canal up to 3 mm in front of where the tip extends apically in straight or curved canals.<sup>26</sup> This evidence shows that an effective flow of irrigation can assist in the cleansing of teeth in which canal alteration occurred during the initial root-canal treatment.

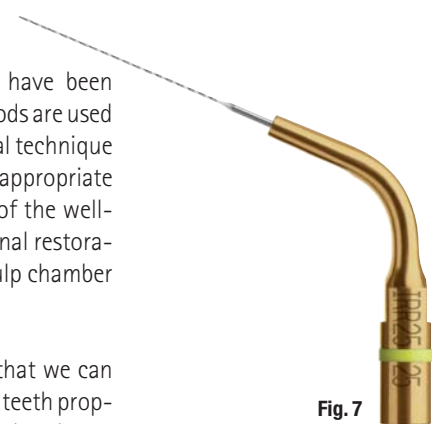
The following silver-point case (Figs. 8a–c), with a large distal post and apical transportation in the mesial root, demonstrates the successful healing of post-treatment disease when proper disinfection has been accomplished. This case illustrates the reason that retreatment is the primary treatment option for post-treatment disease.

Once debridement and disinfection have been completed, appropriate obturation methods are used to seal the canal spaces. The warm vertical technique using gutta-percha or resin with an appropriate sealing agent provides a thorough seal of the well-cleansed and shaped canal spaces. The final restoration must provide a proper seal of the pulp chamber to prevent coronal micro-leakage.

Current evidence has demonstrated that we can retreat previously endodontically treated teeth properly and successfully. The literature has also shown that specific bacteria, such as *E. faecalis*, are able to survive inside a previously filled canal. The use of a dental operating microscope, ultrasonic instruments, irrigants, rotary NiTi files and appropriate obturation materials increases our ability to attain healing after retreatment. As we continue to strive to maintain healthy natural teeth for our patients, endodontic retreatments should be the primary option for patients with post-treatment disease.

*Editorial note: A complete list of references is available from the publisher.*

**Fig. 8a**\_Pre-operative image.  
**Fig. 8b**\_Post-operative image.  
**Fig. 8c**\_15-month follow up image.  
(Case by Dr. Brett Gilbert)



**Fig. 7**\_IrriSafe tip by Satelec/Acteon.

## \_about the author

roots



**Dr Brett Gilbert** received his D.D.S. and Certificate of Endodontics from the University of Maryland. Dr. Gilbert has a private practice limited to Endodontics in Niles, Illinois. He is currently on faculty in the Department of Endodontics at the University of Illinois at Chicago, College of Dentistry and on staff at Resurrection Medical Center in Chicago. Dr. Gilbert is a Diplomate of the American Board of Endodontics and lectures nationally and internationally on clinical endodontics.

# Non-surgical retreatment following failed apicoectomy with re-use of intra-radicular restoration—A case report

Author\_ Dr Imran Cassim, South Africa

The aim of this article is to highlight the possibility of the successful outcome of non-surgical retreatment involving disassembly of a cast restoration then orthograde MTA obturation, following failed surgical retreatment of a maxillary central incisor.

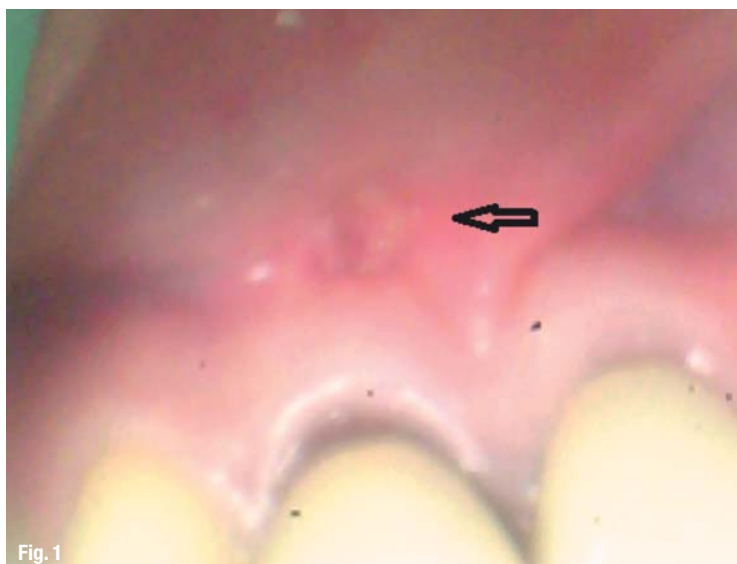## Introduction

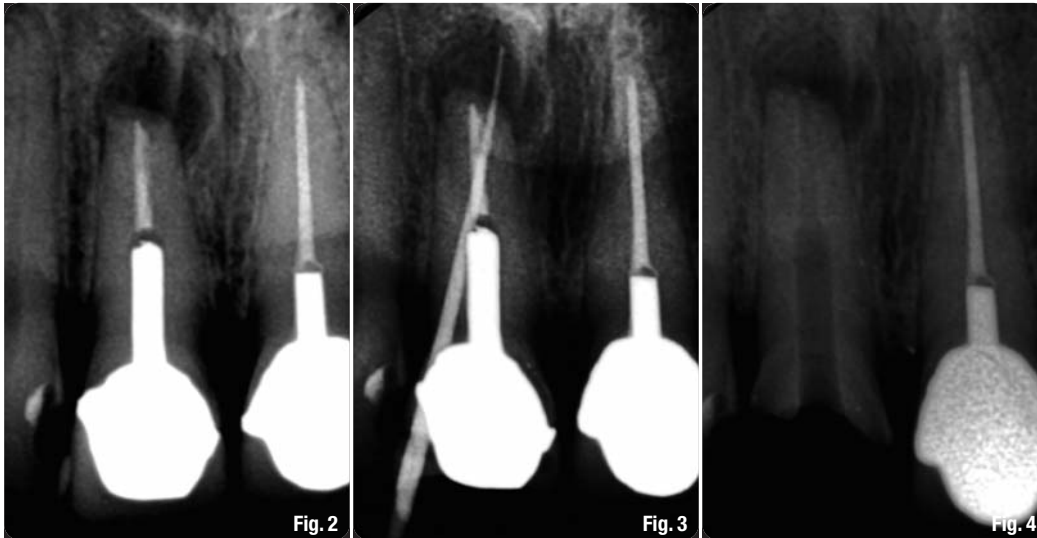
Several studies have documented that bacterial infection of the root canal is the primary cause of apical periodontitis;<sup>1-4</sup> therefore, eradication of micro-organisms from the infected tooth is essential for healing.<sup>5-7</sup> Schilder outlined the principles of 3-D cleaning, shaping and obturation of the root-canal system, which are the foundations for predictable endodontic success.<sup>8,9</sup> Some of the reasons for failure of primary endodontic therapy are persistent intra-radicular infection owing to incomplete debridement

and obturation of the root-canal system, which can occur as a result of missed anatomy,<sup>10</sup> ledges, blockage,<sup>11</sup> canal transportation,<sup>12</sup> fractured instruments,<sup>13</sup> strip perforation<sup>14</sup> and damage to the apical foramen.<sup>15</sup> Other causes of apical periodontitis following root-canal therapy are a lack of coronal seal, secondary caries, vertical root fractures and coronal cracks, trauma, and periodontal disease, which can allow the ingress of bacteria into the root-canal system.<sup>16</sup> Other extra-radicular causes of periapical infection include cellulose-containing materials from paper points or cotton pellets, which are known to cause a chronic inflammatory reaction if present in the periapical tissue,<sup>17</sup> periapical actinomycosis,<sup>18</sup> an unresolved cystic lesion<sup>19</sup> or the accumulation of cholesterol crystals in the periapical area.<sup>20</sup>

The treatment modalities for teeth that have symptoms of apical periodontitis after endodontic treatment are endodontic surgery or non-surgical retreatment if the tooth is to be saved. Non-surgical retreatment is an attempt to remove the micro-organisms from within the canal system and isolate micro-organisms from extra-radicular areas, whereas endodontic surgery is an attempt to confine the micro-organisms within the root-canal system and remove micro-organisms from the extra-radicular areas.<sup>21</sup> Endodontic surgery shows a more favourable initial success but non-surgical retreatment shows a better long-term success.<sup>22</sup> Extraction of teeth with failed root-canal treatment and replacement with implants has increasingly become more popular than surgical and non-surgical endodontic retreatment.<sup>23,24</sup> Technological advances, such as the use of magnification and ultrasonics, and the development of new materials promise greater efficiency and improved treatment outcomes. The decision of whether to ex-

Fig. 1\_Draining sinus in gingiva above tooth #11 and recession of gingiva.





**Fig. 2** Pre-op X-ray showing periapical radiolucency and post crowns on teeth #11 and 21.

**Fig. 3** A gutta-percha point tracking the draining sinus to the periapical radiolucency.

**Fig. 4** X-ray showing removal of intra-canal contents.

tract or retain a tooth should be based on its suitability for further restoration after retreatment, as long as it is periodontally sound.<sup>16,25</sup> It is important that in patients with high aesthetic expectations and a thin mucosal biotype that greater efforts be made to save a questionable anterior tooth in order to ensure preservation of the soft-tissue architecture.<sup>26,27</sup>

In non-surgical retreatment, the presence of cast restorations and posts may pose technical difficulty in accessing the root-canal space. Cast and prefabricated metal posts can be removed with ultrasonics and post-pulling devices; fibre posts can be drilled out.<sup>28</sup> The simplest means of removing a screw post is to use the corresponding wrench—if the head of the post has been damaged, a piece of cotton wool can be placed in the wrench to provide a tighter fit.<sup>28</sup> Ultrasonic vibration applied to posts reduces the force needed to remove the post. It is important to use a water spray to prevent overheating the tooth during ultrasonic vibration of the post. The risk of root fracture during post removal has been reported to be less than 1%.<sup>29</sup> Traditionally, teeth with failed apicoectomies without retrograde fillings were retreated surgically or a combination of non-surgical and surgical procedures was employed.<sup>30</sup> Retreatment of teeth with previously apically resected roots was first reported by Stewart in 1975.<sup>31</sup> In these cases, the existing root filling should be removed carefully in order to avoid extruding the filling into the periapical area when a retrograde filling is absent. Pannkuk<sup>32</sup> demonstrated a method for removal of amalgam root-end fillings during retreatment. Once the previous filling material has been removed, further treatment proceeds as in the treatment of immature teeth with open apices. MTA has been proposed as the material of choice for apical barrier formation in teeth with open apices and necrotic pulps.<sup>33</sup> It is biocompatible, osteoinductive, cementogenic and has antifungal and antibacterial properties.<sup>34</sup>

## Case report

A 61-year-old female patient was referred for treatment of a symptomatic maxillary right incisor. Her chief complaint was that she had had an apicoectomy done by a maxillofacial surgeon on her anterior tooth (#11) one year previously and three months after the procedure she kept getting a swelling in the gum above the tooth and recently the swelling had become painful and the tooth was painful when biting. She had seen her dentist two days previously and he had prescribed clindamycin 150mg. Her other concern was the dark cervical margin exposed above her crown on the tooth owing to the receding gum line.

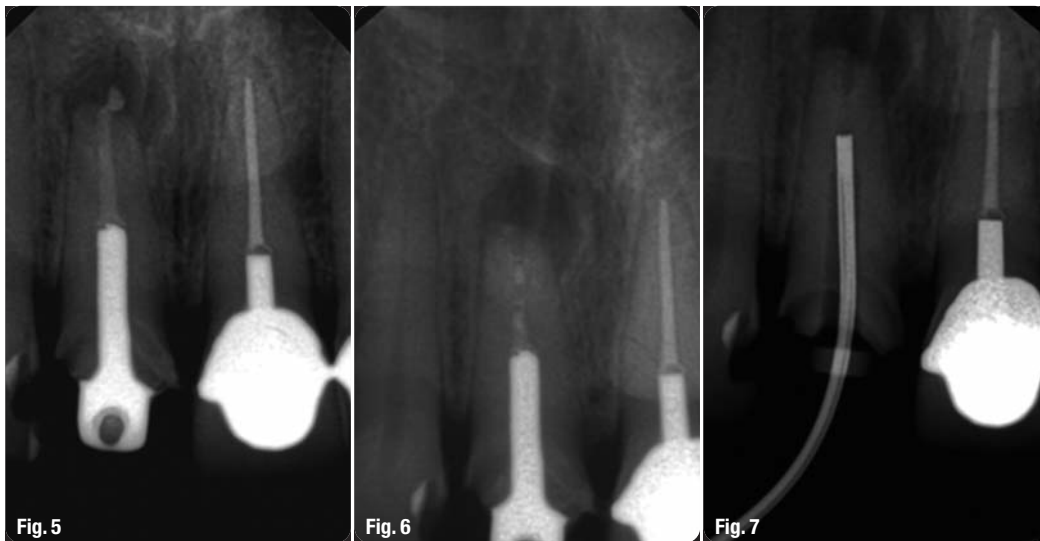
On clinical examination, the gingiva above tooth #11 was inflamed and a draining sinus was noted in the gingiva 10mm above the cervical margin of the incisor. There was recession of the gingiva above the cervical margin of the crown of tooth #11 and a PFM crown on tooth #21 (Fig. 1). Thermal tests were negative. Tooth #11 was tender to percussion and palpation. Periodontal probing showed 2mm pockets around teeth #11, 12 and 21. No pathological mobility of tooth #11 was detected. Radiographic examination demonstrated that there was a post crown on tooth #11, periapical radiolucency and no retrograde filling placed at the apex (Fig. 2). The crown-root ratio was approximately 50:50. The draining sinus was at the apical level of the post, and a root fracture was suspected. A gutta-percha point was inserted into the draining sinus and a periapical radiograph showed the gutta-percha point tracking the sinus to the periapical radiolucency (Fig. 3).

Treatment options were discussed with the patient. The following options were suggested: non-surgical retreatment, surgical retreatment, extraction followed by implant placement, denture or bridge. She was

**Fig. 5** X-ray taken at end of first visit showing placement of calcium hydroxide and post core recemented and temporary crown. Note slight extrusion of calcium hydroxide, hole in core and presence of adequate ferrule.

**Fig. 6** X-ray after six weeks of calcium hydroxide dressing showing dissolution of the calcium hydroxide.

**Fig. 7** Gauging placement of MTA Gun and confirming removal of intra-canal medicament.



motivated to keep her tooth, refused another apicoectomy procedure and could not afford an implant and bone augmentation and the possible replacement of the neighbouring crown because of gingival recession following extraction. A decision was made to attempt non-surgical retreatment and the patient was warned that there was a possibility of fracture.

The patient was scheduled for a two-hour appointment. Following anaesthesia, a polyvinyl siloxane impression (PRESIDENT, Coltène/Whaledent) was taken of the maxillary arch. The crown was sectioned off using a tapered crown preparation diamond bur (Komet) and a tungsten carbide bur (Tri Hawk). A minimum 2 mm ferrule was observed around the cast post core. A rubber dam was placed and secured with wedges placed between teeth #12 and 13, and between #21 and 22.

Post-core removal was initiated using the Start-X #4 ultrasonic tip (DENTSPLY Maillefer) in a piezoelectric scaler handpiece (NSK), moving the tip anti-clockwise along the longitudinal axis of the post core. The Start-X tip has a lumen for water spray, which prevents overheating of the post and surrounding periodontal ligament. After 15 minutes of ultrasonic vibration, the post core had not completely loosened. A hole was drilled through the core bucco-palatally using a Great White #2 tungsten carbide bur (SS White). A double-layered dental floss ligature (Satin Tape, Oral-B) was looped into the hole in the core. The cable attachment of the Safe Relax automatic crown and bridge remover (Anthogyr) was looped through the dental floss ligature. The purpose of this is that the dental floss ligature acts as a stress breaker, thereby preventing excessive force on the root and minimising the risk of root fracture or inadvertent extraction of the tooth. The post core was removed without any damage to the root following 30 seconds of low intensity force application with the Safe Relax.

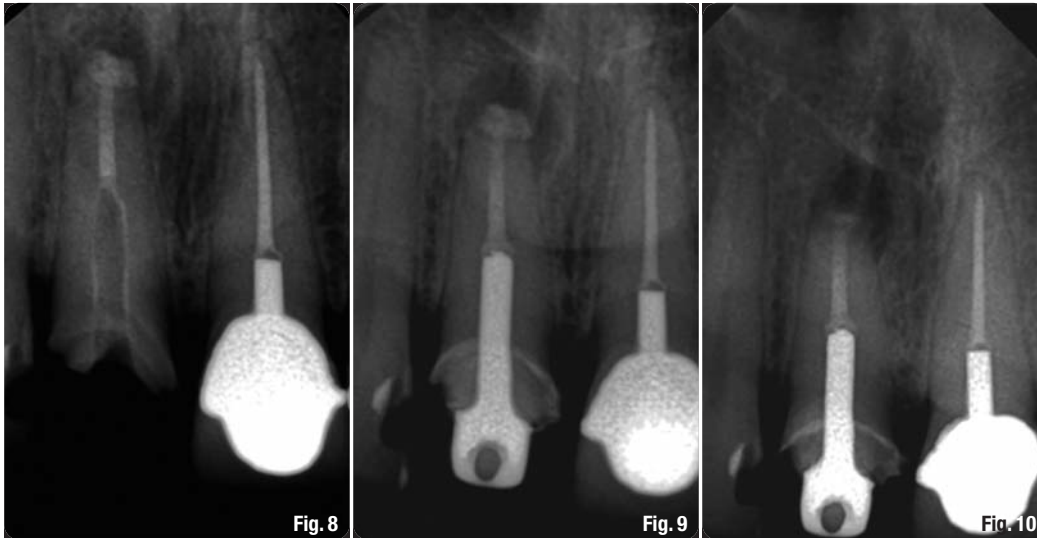
The Safe Relax was used because the post was not serrated.

The residual cement in the canal was removed with a #3 Start-X ultrasonic tip (DENTSPLY Maillefer). The gutta-percha was removed using a few drops of chloroform (Allied Drug Company) and a #40 Hedstrom file (DENTSPLY Maillefer). A radiograph was taken to confirm removal of the gutta-percha (Fig. 4). Working length was determined using the iPex digital apex locator (NSK) and the apex was gauged to a size #100 using a K-file (DENTSPLY Maillefer).

The canal was irrigated with 3% sodium hypochlorite (Vista Dental) and agitated with the Endo-Activator (DENTSPLY Tulsa) for one minute and this was repeated ten times with fresh irrigant each time. The canal was dried with paper points and then flooded with 17% EDTA and agitated with the Endo-Activator for one minute and then dried and rinsed with distilled water. A 2% chlorhexidine solution was left to soak in the canal while the post core was being prepared for temporary recementation.

The post core was air abraded using the RONDOflex (KaVo) with 27 $\mu$  aluminium oxide powder. The post core was then soaked in 2% chlorhexidine (Vista Dental) for two minutes. The hole in the core was etched with 37% phosphoric acid (Ultradent), rinsed and air-dried. Then Monobond Plus primer (Ivoclar Vivadent) was applied to the surface and air-dried after 60 seconds. The XenoV (DENTSPLY) bonding agent was applied to the core and light cured for 20 seconds using the SmartLite (DENTSPLY) ultraviolet curing light. The QuiXfil (DENTSPLY) resin composite was used to fill the hole in the core and light cured for ten seconds.

The buccal margin of the crown preparation was extended to the gingival margin using a #018 tapered diamond bur (Komet). The canal was air-dried and



**Fig. 8** Placement of apical MTA barrier and slight apical extrusion of MTA.

**Fig. 9** Immediate post-op X-ray.

**Fig. 10** Follow-up X-ray at five months showing some dissolution of extruded MTA.

UltraCal XS (Ultradent), a radiopaque calcium hydroxide paste, was syringed into the canal using a NaviTip needle (Ultradent). The post core was recemented with NexTemp temporary cement (Premier Dental) and the rubber dam removed. A temporary crown was fabricated by placing Protemp 4 (3M ESPE) in the polyvinyl siloxane impression and reseating it. The temporary crown was polished and cemented using Meron glass ionomer luting cement (VOCO). A post-operative periapical radiograph was taken (Fig. 5). The patient was scheduled to return for evaluation and further treatment after six weeks.

#### Second visit

The patient reported that her symptoms had disappeared within the first week after the first visit. On clinical examination, it was noted that the inflammation and draining sinus in the gingiva above tooth #11 had healed. A periapical radiograph showed some dissolution of the calcium hydroxide dressing apically (Fig. 6).

Following anaesthesia and isolation, a horizontal slot was cut on the buccal cervical aspect of the temporary crown and it was levered off along with the post core using a flat plastic instrument. The canal was irrigated with 17% EDTA, which was agitated using the EndoActivator for one minute to help remove the remaining calcium hydroxide dressing. Then distilled water was used to flush the canal and 2% chlorhexidine was left in the canal for two minutes. Thereafter, the canal was irrigated with distilled water and dried with paper points. A periapical radiograph was taken to determine the placement of the MTA Gun System (DENTSPLY Maillefer) and confirm removal of residual calcium hydroxide (Fig. 7).

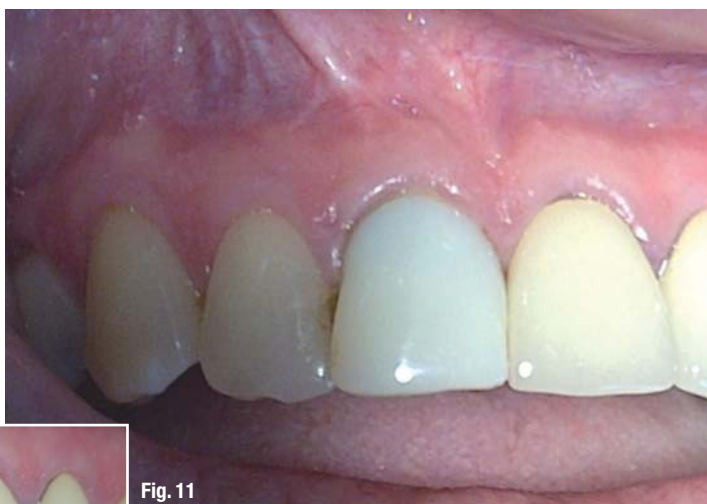White MTA-Angelus (Angelus) was mixed according to the manufacturer's instructions and placed

into the canal using the MTA carrier gun. After the placement of three aliquots of MTA, a #5 Dr Machtou Plugger (DENTSPLY Maillefer) was used to condense the MTA, with ultrasonic vibration applied to the plugger for 20 seconds to aid in condensing the MTA mass apically. A further three aliquots of MTA were placed and the condensation procedure repeated. The post was used to condense the final two aliquots of MTA. A periapical radiograph was taken to assess the MTA placement (Fig. 8). A post brush (DiaDent) was used to remove excess MTA in the post space, and a cotton pellet soaked in distilled water was placed in the canal for 15 minutes.

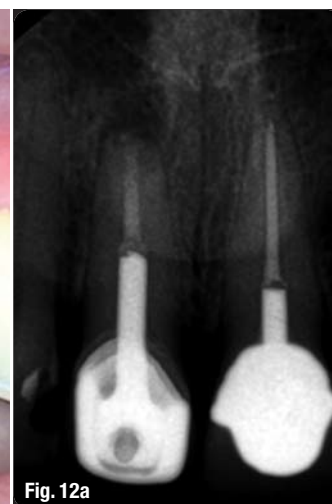
The RONDOflex was used to lightly air abrade the post surface to remove the remnant of the temporary cement, and the post was soaked in 2% chlorhexidine for two minutes. The post was then etched with 37% phosphoric acid for 20 seconds, rinsed and air-dried, and then Monobond Plus was applied and air-dried after 30 seconds. After 30 minutes the initial set of the MTA was confirmed by inserting a #60 K-file (DENTSPLY Maillefer) into the canal against the MTA mass. The post space was dried using paper points. The post-core crown was recemented using the RelyX Unicem resin-modified glass ionomer cement (3M ESPE) and a periapical radiograph was taken (Fig. 9).

The preparation of the permanent crown was postponed to monitor healing and symptoms, to assess the gingival response to the new crown margin and to spread the cost. A five-month post-operative radiograph (Fig. 10) showed some dissolution of the extruded MTA, and the tooth was asymptomatic and the gingiva above tooth #11 showed no further recession (Fig. 11). An 18-month follow-up radiograph showed a decrease in periapical radiolucency (Fig. 12a) and the patient was happy with the new crown (Fig. 12b).

**Fig. 11** Gingiva is healthy and no further recession at the cervical margin at five months with temporary crown in place.



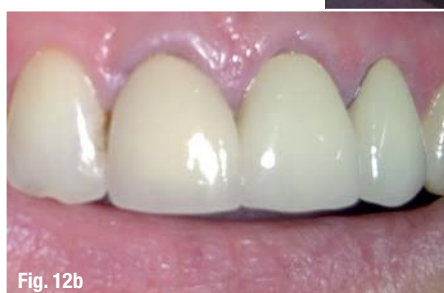**Fig. 11**



**Fig. 12a**

**Fig. 12a** Follow-up X-ray at 18 months showing decrease in size of periapical radiolucency and the permanent crown placed.

**Fig. 12b** Patient is happy with the new crown and gingival margin six months after permanent crown placement.



**Fig. 12b**

## \_Discussion

It is important to discuss treatment alternatives, risk factors and costs with patients before proceeding with treatment.<sup>21</sup> The approach to cleaning and shaping in teeth with open apices requires an adaption of strategies and the biological objectives described by Schilder<sup>9</sup> take precedence. Particular attention should be given to working length control to reduce the possibility of extrusion of irrigants. Sub-sonic agitation was used for the irrigants to minimise extrusion<sup>35</sup> and improve the efficacy of chemical debridement.<sup>36</sup> The combined use of EDTA and sodium hypochlorite has been shown to have better antibacterial efficacy than sodium hypochlorite alone.<sup>37</sup> Chlorhexidine exhibits substantivity and dentine medicated with a 2% solution for ten minutes can exhibit substantivity for up to 12 weeks. Furthermore, chlorhexidine is antifungal, which is beneficial because fungi may be involved in cases with persistent or secondary endodontic infection.<sup>38</sup> Premedication

with calcium hydroxide improves the marginal adaptation of the apical MTA plug<sup>39</sup> and it appears to be the only medicament that is effective against endotoxin.<sup>40</sup> White MTA-Angelus was used because of its short setting time. (MTA-Angelus is available in both grey and white forms.) It is composed of 80% Portland cement and 20% bismuth oxide. The absence of calcium sulphate allows a quicker initial setting time of approximately 15 minutes.<sup>41</sup> In teeth with open apices, apical control is difficult during obturation, but MTA extrusion is well tolerated.<sup>32</sup>

In the present case, the cast post core was reused because there was no unnecessary mechanical enlargement of the post space, the well-fitting post core was removed largely intact, its reuse minimised the cost to the patient and there was an adequate ferrule around on sound tooth structure.

A second surgery in teeth that have undergone apicoectomy results in further scarring, shortening of the root and decreased localised blood supply.<sup>32</sup> The present case report shows healing in progress and the absence of symptoms 18 months after non-surgical retreatment. Further follow-up is necessary to assess the long-term outcome.

Non-surgical retreatment with an MTA apical barrier after root resection is considered an empirical treatment modality, as no data exists on success rates.<sup>31</sup> This warrants further research of this approach, as it may provide comparable healing and less morbidity compared with conventional retreatment combined with apical surgery.

*Editorial note: A complete list of references is available from the publisher.*

*Acknowledgement: I would like to thank Prof. J. L. Gutmann for his encouragement and help in writing this case report and Dr K. Serota and the roots community.*

## \_about the author

### roots



**Dr Imran Cassim** obtained his BDS degree in 1999 from the University of Witwatersrand. He obtained a Postgraduate Diploma in Endodontics with distinction from the University of Pretoria in 2009. He is currently completing an MSc in Endodontics at the University of Pretoria and is in practice in Durban, South Africa. Along with Dr Hussein Seedat, he is the co-founder of the KZN Endodontic Study Group.

P.O. Box 2295  
New Germany  
3610 KwaZulu-Natal  
South Africa

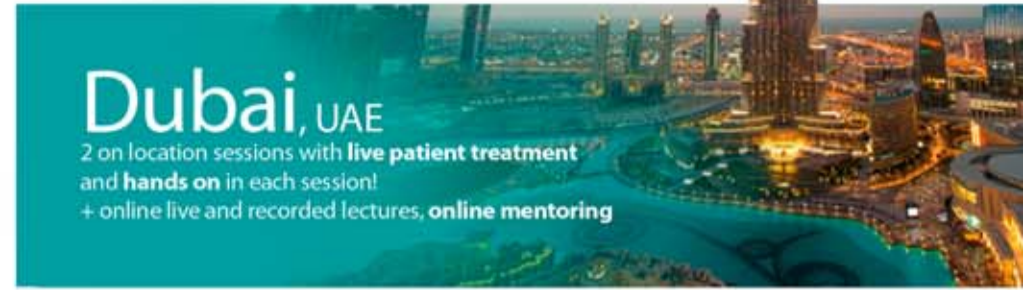ijcassim@worldonline.co.za



Tribune CME

# Clinical Masters Program in Aesthetic and Restorative Dentistry

10-14 January 2013 and 24-27 April 2013 in Dubai, for a total 9 days



## Dubai, UAE

2 on location sessions with **live patient treatment**  
and **hands on** in each session!  
+ online live and recorded lectures, **online mentoring**



Didier Dietschi



Francesco Mangani



Panos Bazos

### Session I: 10 - 14 January 2013 (5 days)

- Direct/Indirect composite Artistry in the Anterior Segment
- Direct/Indirect composite Artistry in the Posterior Segment
- Photography and shade analysis

#### Clinical Masters:

Didier Dietschi, Francesco Mangani, Panos Bazos



Mauro Fradeani



Urs Brodbeck

### Session II: 24 - 27 April 2013 (4 days)

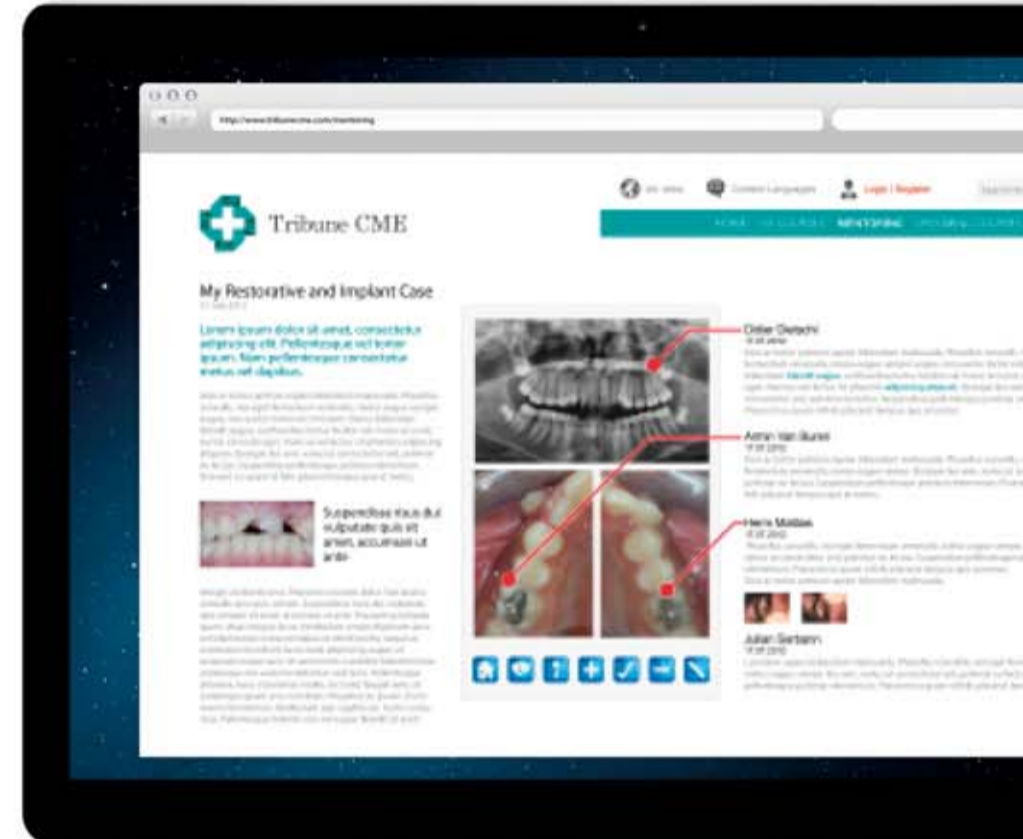
- Full coverage Anterior/Posterior Restoration
- Partial coverage Anterior/Posterior Restoration, Ceramic Restoration

#### Clinical Masters:

Mauro Fradeani, Urs Brodbeck

**ADA CER-P**® | Continuing Education  
Recognition Program

Tribune America LLC is the ADA CER-P provider.  
ADA CER-P is a service of the American Dental Association to assist dental professionals in identifying quality providers of continuing dental education. ADA CER-P does not approve or endorse individual courses or instructors, nor does it imply acceptance of credit hours by boards of dentistry.



Full access to our online learning platform:  
hours of premium video training and live webinars  
collaborate with peers and faculty on **your cases**

### Registration info

## Course fee: € 8,900

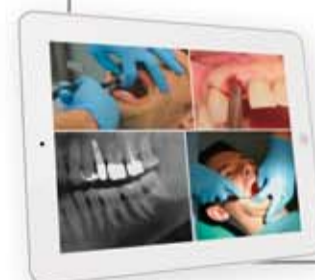Register by the end of October and you  
will receive a complimentary iPad  
preloaded with premium dental courses

Tribune CME

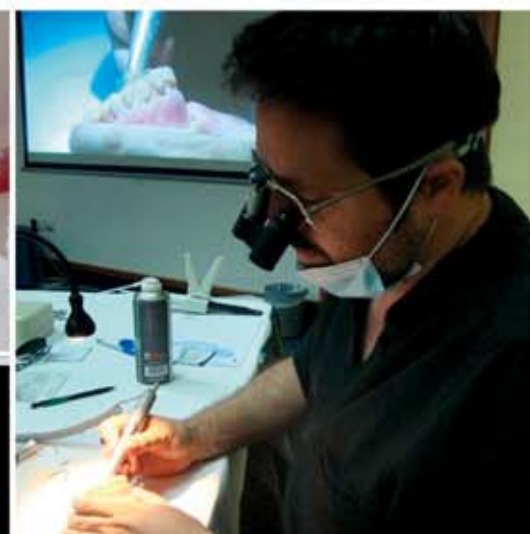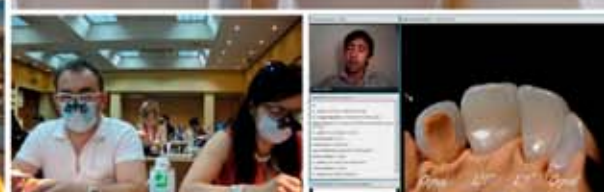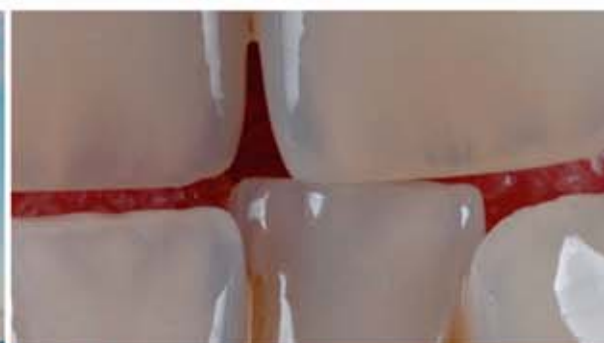Tel.: +49-341-48474-302

email: [info@tribunecme.com](mailto:info@tribunecme.com)

[www.TribuneCME.com](http://www.TribuneCME.com)



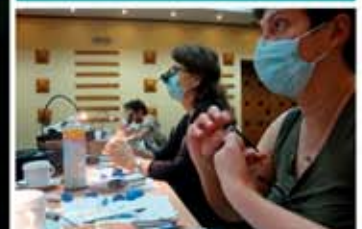*Discover the Master's secrets and Dubai's superlatives*



# 100

## C.E. CREDITS

ADA CER-P®



# The use of direct FRC posts in the restoration of endodontically treated anterior and premolar teeth—A clinical perspective

Author\_ Dr Ian Kerr, UK

The restoration of endodontically treated teeth has long been a challenge to the dental profession and the success of endodontics is directly affected by the quality and integrity of the coronal seal created by the final restoration.<sup>1</sup> Recent advances in restorative dentistry have led to a bewildering array of treatment options for patients and it is essential that dentists present these options so that patients can make informed choices that are right for them. When we present these choices, we need to bear in mind that

treatment option that can guarantee a lifetime result for our patients. Rather than looking at which is best, we should look at what is most appropriate for the patient right now. A survey conducted by Taloustutkimus in Finland in 2002 sampled 300 dentists and looked at the uptake of treatment to replace or restore one damaged or missing tooth before and after the introduction of FRCs. The survey revealed that once FRC options became readily available the number of patients taking up no treatment dropped from 47 to 17%, indicating that FRC often represents an acceptable treatment option to patients who would otherwise have rejected conventional crowns, bridges, implant-retained crowns, etc. By delivering minimally invasive options that are easily repaired, we can delay the loss of the tooth for many years. This dynamic lifetime therapy leaves all other options available for later in the patient's life when his or her circumstances and dental techniques may have changed.

Fig. 1 \_ Ideal properties of a retentive post.

**THE IDEAL CHARACTERISTICS OF A POST**

- \_ good retention;
- \_ good biocompatibility;
- \_ good aesthetics;
- \_ good retrievability;
- \_ modulus of elasticity (to dentine);
- \_ compressive strength (to dentine);
- \_ co-efficient of thermal expansion (to dentine);
- \_ minimal capacity for moisture absorption; and
- \_ anti-cariogenic properties.

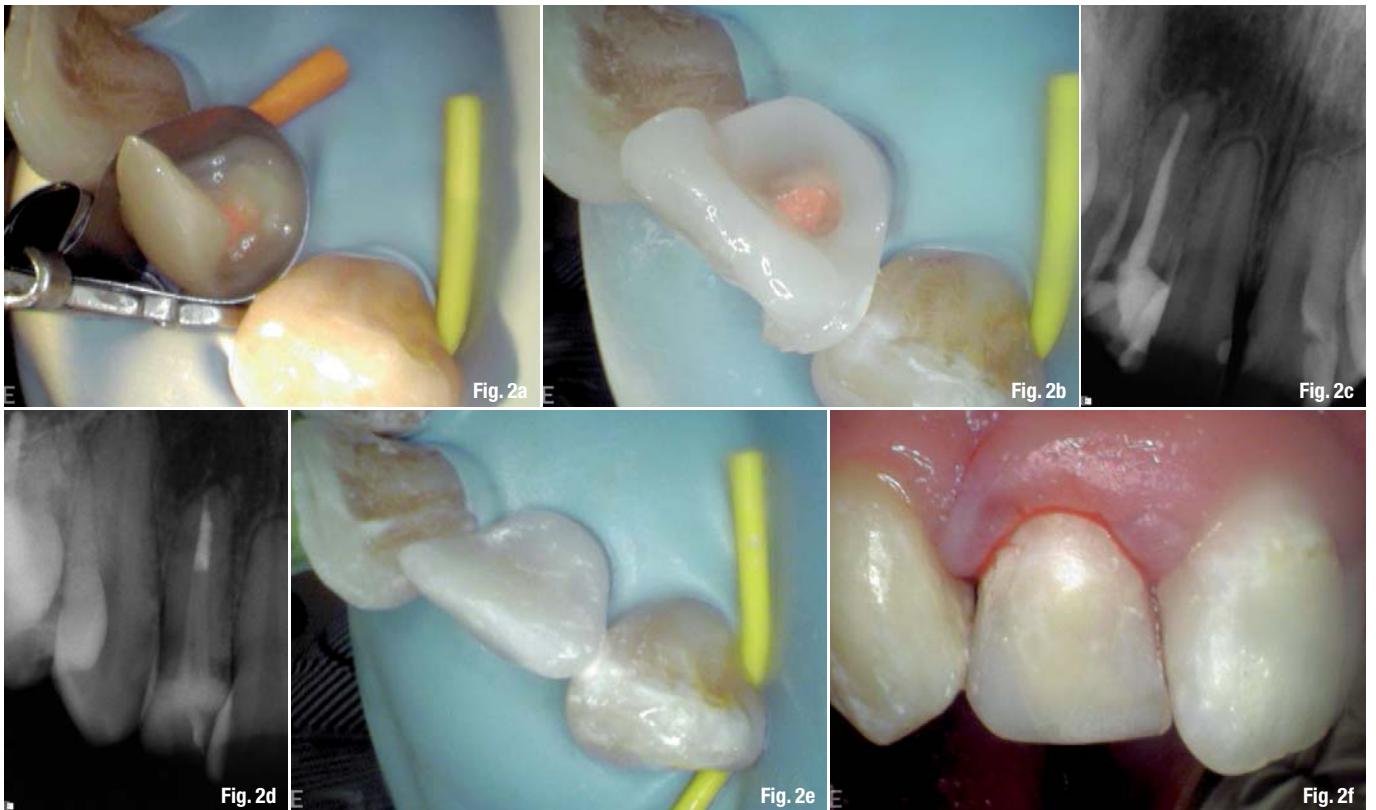
Fig. 1

the financial implications of restorative dentistry are increasingly important to patients, so we need to look at both the financial and the biological costs that we are ask our patients to pay and must advise them clearly on these matters before treatment begins.

When discussing fibre-reinforced composite (FRC) dentistry with colleagues, there is often a discussion along the lines of, wouldn't an implant be better? For me, this is a flawed question, as there is no single

When we are presented with a restoratively compromised tooth in need of root-canal treatment, we need to be able to follow a simple pretreatment protocol to establish the answer to two simple questions: can we restore the tooth and should we restore the tooth? The first question relates to both our own clinical abilities as a dentist and the clinical parameters of the case. If we feel that the case lies within our skill range (by this I mean something that we are *proficient* at rather than merely *competent* at), then we need to consider the clinical parameters. A full discussion of the pre-endodontic assessment of a tooth is beyond the scope of this article, but if we are going to ask our patients to part with their hard-earned money, then I think we should have a high degree of confidence that we will be able to fully isolate the tooth, locate all the canals using adequate magnification and illumination, negotiate the canals to full working length, prepare them fully to allow adequate



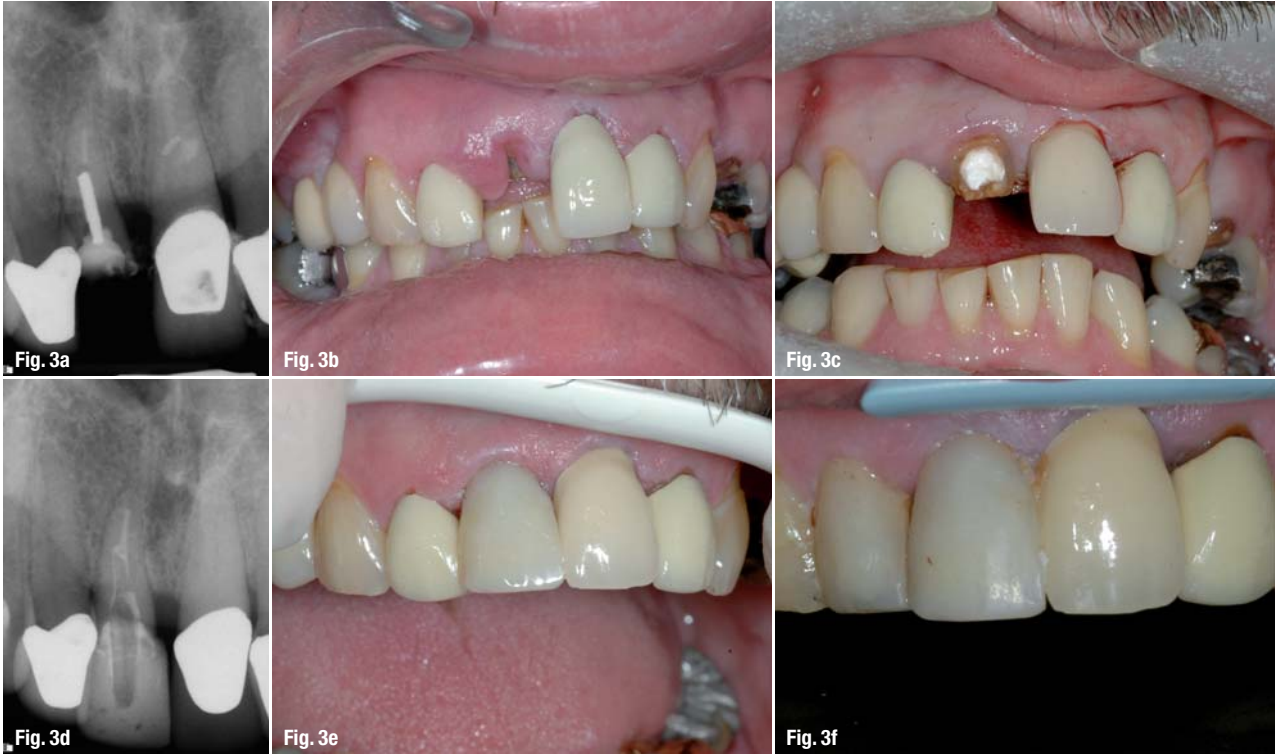

irrigation and disinfection of the canal structure and then be able to place an appropriate restoration under ideal conditions. If we can do all of this, then the answer to the first question is yes. We must then consider the second question, *should* we restore the tooth? Just because I am technically able to provide an ideal root filling and restoration does not mean that I should if we are working in a very disease-active mouth or in a tooth that has such an unreasonably high vertical or lateral load on it that it is unlikely to survive beyond the short term. Also, just because we, as clinicians, place a very high value on tooth preservation, this does not mean that all our patients do. They may take the view that taking the tooth out and adding it to an existing denture or just accepting the gap may be a perfectly reasonable alternative; ultimately, this is their decision and one that we have to respect. Excellent fixed prosthetic alternatives exist today, from direct FRC bridges, to minimally invasive resin-bonded bridges to implant-retained crowns. The relative values of each of these options need to be weighed against the preservation and restoration of the existing tooth.

If after a lengthy discussion and pretreatment planning session we agree that a tooth should be treated endodontically, then we need to look at how we are going to restore it at the same time.

Concerning anterior teeth, it has long been the view that the provision of cast full-coverage restora-

tion does not enhance longevity<sup>2</sup> and more recent evidence has begun to cast doubt on the need for cast restorations for root-treated premolar teeth,<sup>3</sup> at least in the first five years. What the research is much less clear on is whether we should use a cast post or fibre post and, indeed, whether a post is still indicated. Certainly, we have known for a long time that we should not increase post dimensions at the expense of dentine removal,<sup>4</sup> and for even longer that the primary purpose of a post is to retain a core,<sup>5</sup> but more recent research has shown that fibre posts in conjunction with resin cements can strengthen roots<sup>6</sup> and can help provide single-visit, direct aesthetic restorations. Fibre posts were originally sold as preformed posts, which are certainly easy to use but can show limitations in bonding to core pastes and cements<sup>7</sup> and require greater adjustment to the canal shape to fit, compared with the newer anatomical fibre posts. In the case of the Stick Tech range of anatomical posts, they also show greater bonding capacity to cores and pastes<sup>8</sup> and allow for intimate adaption to the existing canal shape. It remains unclear in the literature as to the desired length of a fibre post and all the firmly held beliefs regarding post length and shape predominately come from earlier literature (such as Sorrenson & Martinoff, 1984), and relate to cast metal posts and often predate predictable resin bonding. Recent studies<sup>9,10</sup> have considered short (5 mm) anatomical fibre posts and found these to have greater strength and favourable fracture patterns compared with longer posts, whilst retaining similar retention



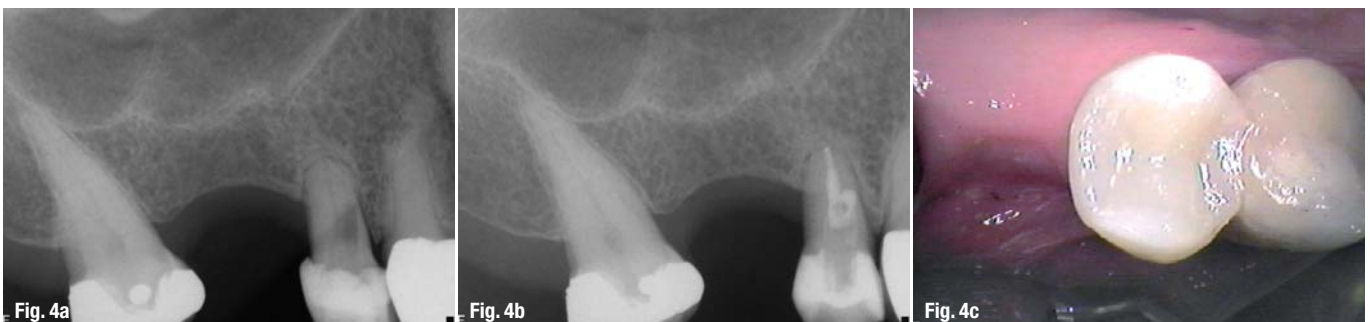strengths. Research on bonding within canals to root dentine reveals that it becomes increasingly more difficult to maintain ideal conditions the farther into the canal we progress<sup>11</sup> and that the quality of the dentine available for bonding reduces as well.<sup>12</sup> Bouillaquet et al. reported their findings in 2003<sup>10</sup> and demonstrated that even the simplest of bonding techniques, such as Fuji PLUS cement (GC), show a reduction in bond strength the farther into the canal we progress, suggesting that dentine quality has a significant role to play in the bond strength achieved.

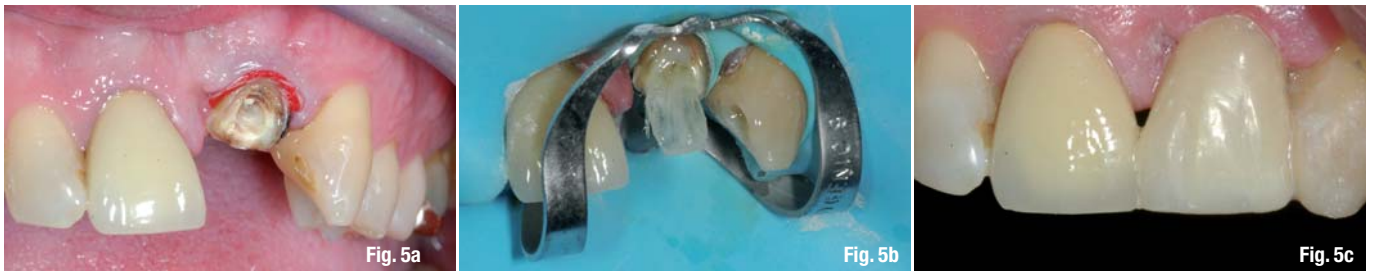If we look at the ideal characteristics of a post, then it is clear that no such post exists (Fig. 1). The best we can hope for is one that allows close adaptation to the wall with the least amount of tissue reduction, whilst providing strength to the root and retention to the core or restoration. At the same time, it should show excellent bonding to the cement and core pastes that it is used in conjunction with and minimise any stresses to the tooth tissue that supports it.

### Case studies

The following cases represent everyday uses for direct anatomical FRC posts in anterior and premolar teeth. In my experience over the past five years, these techniques have shown themselves to be reliable, predictable and endlessly adaptable when used in ideal restorative conditions.

I completed each of the following cases and they were carried out under rubber dam isolation and microscopic illumination. In my opinion, the ability to isolate a tooth fully is the main factor in achieving successful bonding. The use of a rubber dam is mandatory for this work, as it allows excellent vision and isolation over an extended working time, which allows the clinician to perform the necessary bonding steps without fear of contamination. As a rule of thumb, "if the tooth cannot be isolated in its current state then bonding cannot take place"—the ability to isolate the tooth with a rubber dam is a great way of testing this rule.





**Case 1:** Endodontic retreatment of an upper lateral incisor and restoration with direct FRC post and core (time in mouth since completion: 22 months)

- Fig. 2a Pre-endodontic build-up required owing to extensive tooth loss.
- Fig. 2b Pre-endodontic build-up in place.
- Fig. 2c Pre-op radiograph showing extensive coronal restoration.
- Fig. 2d Post-op radiograph showing FRC post and endodontic retreatment.
- Fig. 2e Incisal view of the coronal restoration.
- Fig. 2f Buccal view of the finished direct restoration.

**Case 2:** Restoration of an extremely damaged upper central incisor with direct FRC (time in mouth since completion: 60 months)

- Fig. 3a Pre-op view of the decoronated incisor due for extraction.
- Fig. 3b Clinical view of gingival overgrowth preventing isolation.
- Fig. 3c Root face exposed after electrocautery.
- Fig. 3d Radiographic view of direct FRC post and crown.
- Fig. 3e Clinical view of direct FRC post and crown.
- Fig. 3f The 5 year follow up.

**Case 3:** Root treatment and MTA repair of perforation and direct FRC for an extremely compromised upper premolar (time in mouth since completion: 36 months)

- Fig. 4a Pre-op radiograph showing lateral perforation.
- Fig. 4b Post-op restoration showing lateral repair with MTA and glass ionomer cement and direct anatomical FRC post and restoration.
- Fig. 4c Intra-oral view of direct FRC restoration.

**Case 4:** Complete crown build-up with horizontal supporting fibre from adjacent tooth

- Fig. 5a Decoronated sclerotic root with insufficient tooth tissue for full ferrule preparation.
- Fig. 5b Vertical post fibres placed in access cavity. Horizontal fibre placed from the canine later in the restorative process.
- Fig. 5c Final direct restoration (G-ænial composite, GC; everStickC&tBridge fibres, Stick Tech).

## Conclusion

From a restorative perspective:

- there is no true perfect system for restoring endodontically treated teeth; that is why we have hundreds of systems from which to choose;
- the literature cannot provide a clear winner in treatment choice;
- the key to tooth survival is retention of sound tooth tissue—all techniques should be aimed at this;
- a restoration is only as good as the root filling it sits upon;
- FRC post and cores represent a clinically acceptable treatment regime compared with cast and direct metal posts;
- bonding posts with composite resin cements compensate for reduced post length;
- bond strengths to root dentine reduce as we extend down the root;
- short (5 mm) anatomical posts cemented and cured simultaneously with core paste provide optimal root strength.

In my opinion, providing direct FRC posts, cores and complete build-ups is one of the most enjoyable aspects of dentistry and yet represents only a small part of the role FRCs can play. In future articles, I will look at their role in restoring posterior teeth, replacing missing teeth and supporting periodontally involved teeth.

*Editorial note: A complete list of references is available from the publisher.*

## about the author

roots

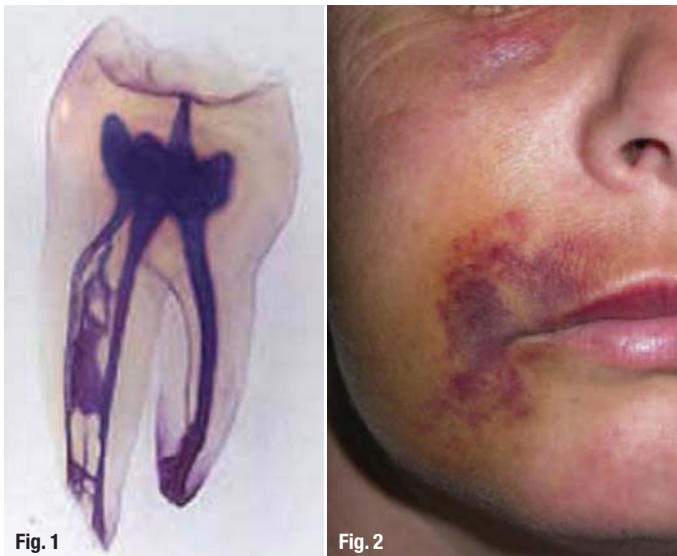

**Dr Ian Kerr** is in full time private practice where he is the co founder of the StoneRock Dental Care Group that comprises 4 separate dental practices and a post graduate training site. He is passionate about sharing his knowledge and experience with his fellow colleagues and enjoys the hands on environment where people can gain the most experience with these techniques.

info@stonerock.co.uk

# Positive versus negative pressure irrigation

Author\_ Dr Gregori M. Kurtzman, USA



requires careful attention to all three to provide long-term clinical success.

Teeth have a very complex pulpal anatomy, and instrumentation alone cannot prepare the canal system for obturation adequately. The intricacies of the canal anatomy with its fins, lateral canals and apical deltas make it impossible for endodontic instruments to reach all aspects of the anatomy (Fig. 1). Thus, irrigation is critical for removal of residual tissue and microbiota that cannot be reached by instrumentation of the main canals.

Regardless of the file system used for instrumentation, files cannot reach all of the pulpal anatomy, and therefore disinfection is key to augmenting the cleaning process prior to obturation. What is meant by disinfection of the canal system? Disinfection entails removal of the residual tissue in the canal system and the associated bacteria through flushing the canal system with irrigation solution.

The objective is to remove as much residual tissue as possible through thorough irrigation, as the less residual tissue, the less bacteria and the more successful the clinical outcome of the endodontic treatment.

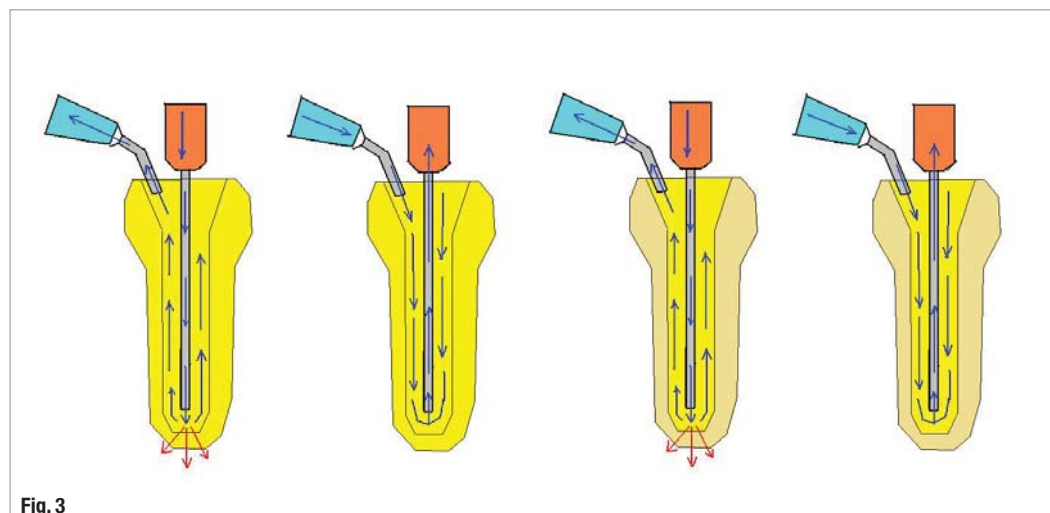
## The endodontic triad

Long-term endodontic success is not due to a single factor but is dependent upon three critical aspects of treatment called the "endodontic triad": instrumentation, disinfection and obturation. These three components of the triad are interwoven, and success

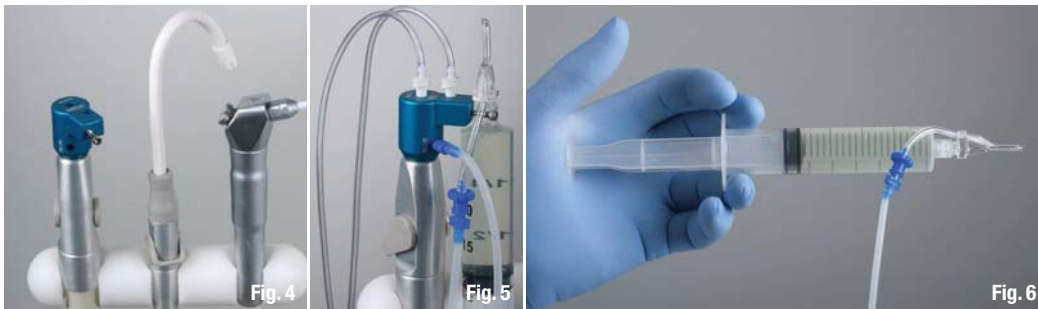**Fig. 1** \_ Cleaned molar with dye within the canal system, illustrating the complex anatomy normally found in teeth.

**Fig. 2** \_ Result of NaOCl being extruded periapically into the facial spaces from forceful irrigation with positive pressure during endodontic treatment.

**Fig. 3** \_ Comparison of positive (left) and negative (right) pressure with regard to endodontic irrigation.



**Fig. 3**



**Fig. 4** EndoVac MPA (left) on HVE connector and line.  
**Fig. 5** EndoVac (blue) connected to HVE suction line and to the Master Delivery Tip syringe. A separate line connects to the MacroCannula or MicroCannula suction tip.  
**Fig. 6** EndoVac Master Delivery Tip syringe with suction line connected to MPA.

## Cleaning the canal

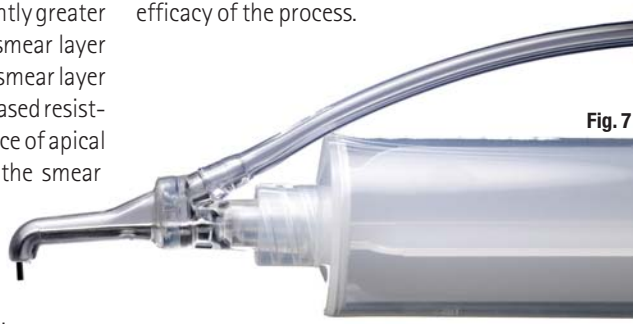No matter what obturation material is used, how well the sealer adheres to the canal walls is important. The smear layer may prevent sealer penetration into the dentinal tubules. In past studies, the frequency of bacterial penetration through teeth obturated with the smear layer intact (70%) was significantly greater than that through teeth from which the smear layer had been removed (30%). Removal of the smear layer enhanced sealability as evidenced by increased resistance to bacterial penetration.<sup>1</sup> The incidence of apical leakage was reduced in the absence of the smear layer, and the adaptation of gutta-percha was improved no matter what obturation method was used later.<sup>2-4</sup>

What is used to obturate the canals is important; however, the manner in which the canal is prepared prior to obturation also determines how well the canal will be sealed. Rotary instrumentation with NiTi files has shown less micro-leakage than hand-instrumented canals, irrespective of what was used to obturate the canal.<sup>5</sup> Compared with stainless-steel hand filing, the machining of the canal walls with NiTi rotary instruments provides smoother canal walls and shapes that are easier to obturate. The better the adaptation of the obturation material to the instrumented dentinal walls, the less leakage is to be expected along the entire root length. The better the canal walls are prepared and cleaned, the greater the amount of smear layer and organic debris removed will be, which is beneficial to root-canal sealing.

Smear layer removal is best achieved by irrigating the canals with NaOCl, followed by 17% EDTA.<sup>6</sup> NaOCl dissolves the organic component of the smear layer, exposing the dentinal tubules lining the canal walls, whereas EDTA, a chelating agent, dissolves the inorganic portion of the dentine, opening the dentinal tubules. Alternating between the two irrigants during instrumentation will permit removal of more organic debris farther into the tubules, increasing resistance to bacterial penetration once the canal has been obturated.<sup>7,8</sup>

Studies suggest that the regular exchange and use of large amounts of irrigant should maintain the

antibacterial effectiveness of the NaOCl solution, compensating for the effects of concentration.<sup>9</sup> Volume is more critical to canal disinfection during treatment than the concentration of the irrigant.<sup>10</sup> Flushing of the irrigant also serves to remove the debris, exposing the dentine around the anatomy in the canal system to further action of the irrigant, improving the efficacy of the process.

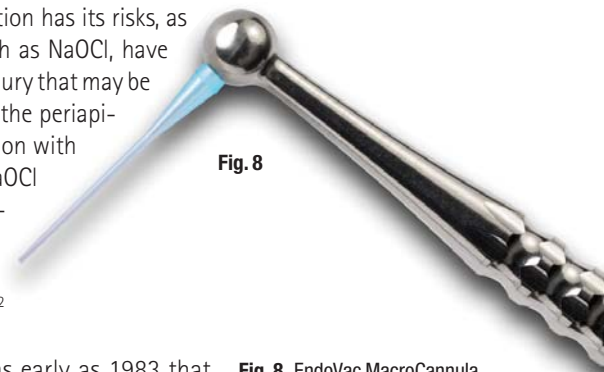


**Fig. 7** EndoVac Master Delivery Tip (irrigation and suction) on a disposable syringe.

## Positive versus negative pressure

Irrigation as it relates to endodontic treatment involves placement of an irrigation solution into the canal system and its evacuation from the tooth. Traditionally, this involved placement of the irrigant with an end-port or side-port needle into the apical canal and expressing solution out of the needle to be suctioned coronally. This creates a positive pressure system, with force created at the end of the needle, which may lead to solution being forced into the periapical tissue. Positive pressure irrigation has its risks, as some irrigation solutions, such as NaOCl, have the potential to cause tissue injury that may be extensive when encountering the periapical tissue and its communication with tissue spaces (Fig. 2). These NaOCl accidents can lead to permanent physical injury or disability, with facial deformation and neurological complications.<sup>11,12</sup>

Chow was able to show as early as 1983 that positive pressure irrigation has little or no effect apical to the needle's orifice.<sup>13</sup> This is highlighted in his paradigm on endodontic irrigation, "For the solution to be mechanically effective in removing all the particles, it has to: (a) reach the apex, (b) create a current force and (c) carry the particles away."



**Fig. 8** EndoVac MacroCannula on the handpiece.




Fig. 9

**Fig. 9**\_EndoVac MicroCannula in the finger piece and close-up showing the rounded end with multiple lateral micro-holes.

The inability to eliminate intra-radicular micro-organisms from the canal system, especially in the apical portion of the root, increases the risk of clinical failure.<sup>14</sup>

A negative pressure irrigation system however does not create positive pressure at the needle's tip, so potential accidents are essentially eliminated. In a negative pressure irrigation system, the irrigation solution is expressed coronally, and suction at the tip of the irrigation needle at the apex creates a current flow down the canal towards the apex and drawn up the needle. True apical negative pressure only occurs when the needle (cannula) is utilised to aspirate irrigants from the apical constriction of

the root canal. The apical suction pulls irrigation solution down the canal walls towards the apex, creating a rapid, turbulent current force towards the terminus of the needle (Fig. 3).

Haas and Edson found that "The teeth irrigated with negative apical pressure had no apical leakage. While the teeth irrigated with positive pressure leaked an average of 2.41 ml out of 3 ml."<sup>15</sup> Fukumoto found that when using negative pressure there was less extrusion of irrigant than when using needle irrigation (positive pressure) when both were placed 2 mm from working length.<sup>16</sup>

What other sequelae can occur with minute amounts of NaOCl leaking from the apex during the irrigation process? Gondim et al. in a study of post-operative pain comparing positive and negative pressure irrigation systems report, "The outcome of this investigation indicates that the use of a negative pressure irrigation device can result in a significant reduction in postoperative pain levels in comparison to conventional needle irrigation."<sup>17</sup> So although we may not see NaOCl accidents frequently, it is possible to see the effects of positive pressure irrigation allowing some minute extrusion apically in our normal, day-to-day endodontic treatment. They further state that "the use of the EndoVac system did not result in apical extrusion of irrigant, hence chemical irritation of the periapical tissues leading to postoperative pain may not be likely." They conclude that "It is safe to use a negative pressure irrigation protocol for antimicrobial debridement up to the full working length."

**Fig. 10**\_Obturation of apical anatomy following irrigation with the EndoVac system, demonstrating apical deltas. (Image courtesy of Dr Richard Rubinstein, Farmington Hills, Michigan.)

**Fig. 11**\_Obturation of apical anatomy following irrigation with the EndoVac system, demonstrating lateral anatomy. (Image courtesy of Dr Richard Rubinstein)

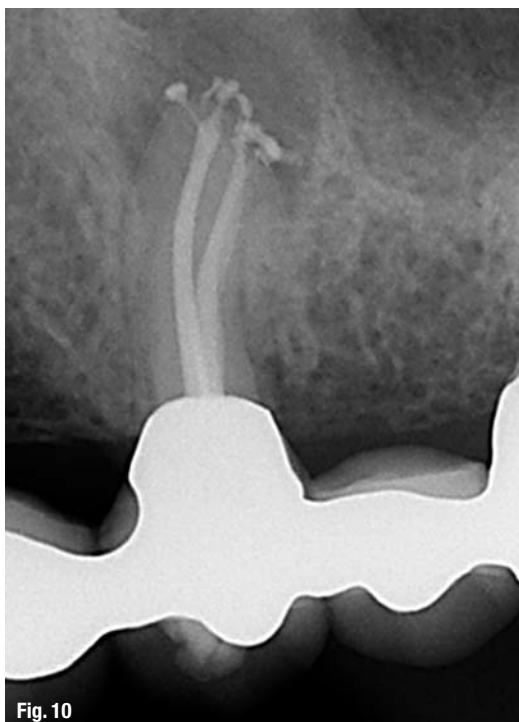
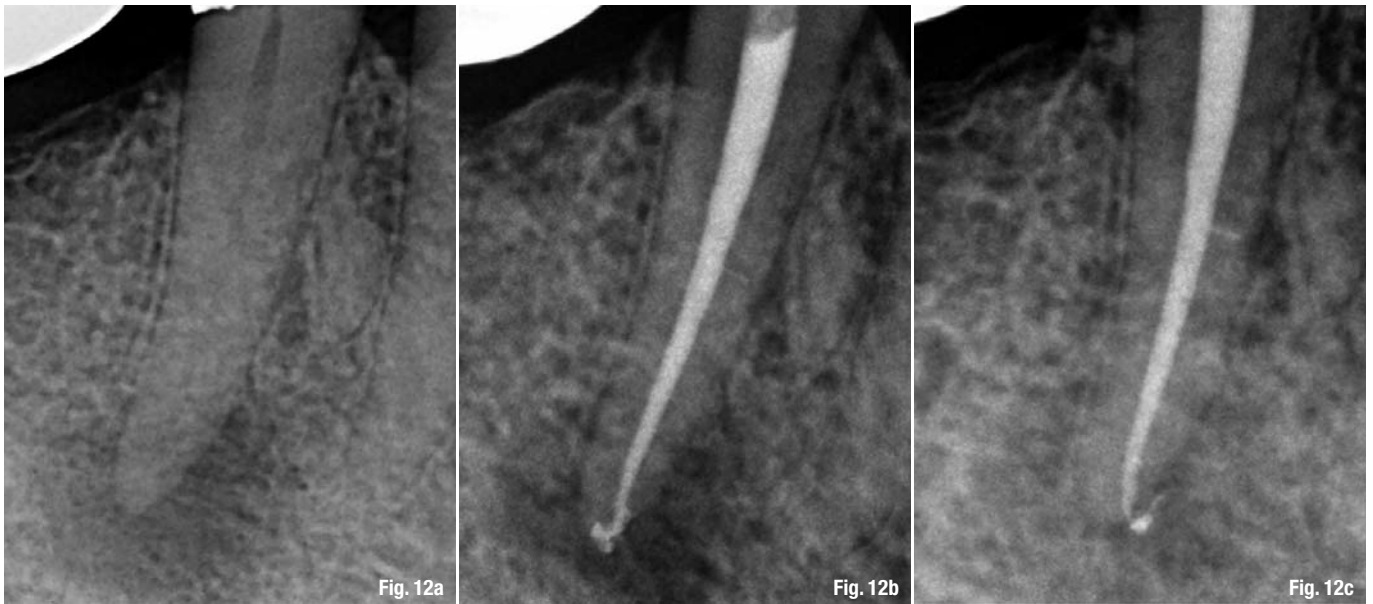


Fig. 10

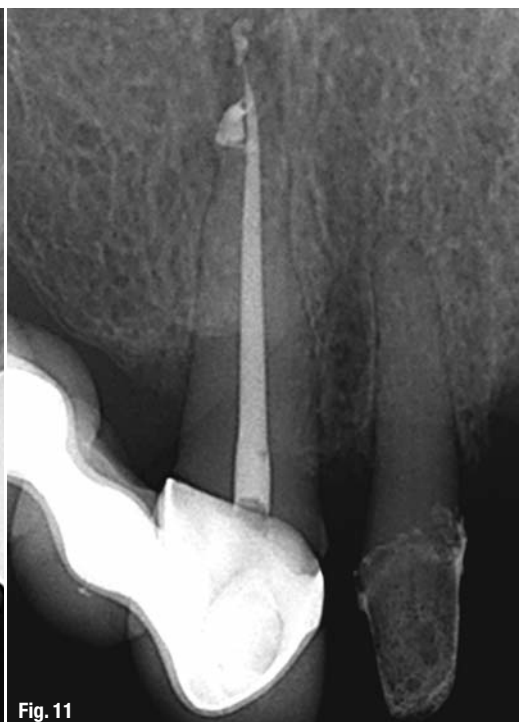

Fig. 11



### EndoVac endodontic irrigation system

Designed by Dr G. John Schoeffel after over a decade of research, the EndoVac irrigation system (SybronEndo) was developed as a means to irrigate and remove debris to the apical constriction without forcing solution out of the apex into the periapical tissue. The system utilises negative pressure through the high-volume evacuation system, permitting thorough irrigation with high volumes of irrigation solution.

The EndoVac system consists of a multi-port adapter (MPA) assembly that connects to the high-volume evacuation hose (HVE) in the dental operatory (Figs. 4 & 5). To this, connects the Master Delivery Tip (irrigation and suction together) with a disposable syringe filled with irrigation solution (Figs. 6 & 7). Either the MacroCannula (Fig. 8) or MicroCannula (Fig. 9) is attached and used simultaneously with the Master Delivery Tip during treatment. The plastic MacroCannula is placed on a handpiece attached to tubing that connects to the MPA via a separate line. This is used for coarse debris removal. The MicroCannula is a metal suction tip available in either 21, 25 or 31 mm lengths with 12 micro-holes in the terminal 0.7 mm of the tip, permitting removal of particles that are 100 $\mu$  or smaller to the apical constriction. This tip fits into a metal finger piece and is connected to the MPA (Fig. 5) in the HVE via tubing. The turbulent current force generated in the MicroCannula rapidly flows to the micro-holes at the terminus, which can reach within 0.2 mm of full working length. Quite simply, the vacuum formed at the tip of the MicroCannula is able to achieve each of the objectives in Chow's irrigation paradigm.

Nielsen and Baumgartner found that the volume of irrigant delivered with the EndoVac system was significantly greater than the volume delivered with

needle irrigation over the same amount of time.<sup>18</sup> Furthermore, they reported significantly better debridement 1 mm from working length for the EndoVac system compared with needle irrigation.

Since one of the laws of physics states, "only one object can occupy a space at a time," if the tissue remnant can be removed from the lateral canals, apical deltas and fins within the canal system, these areas can be filled with obturation material, providing a better seal and limiting bacteria in the canal system. The EndoVac irrigation system, as Nielsen and Baumgartner demonstrated, is able to clean at the apex more thoroughly than other irrigation methods and systems have been able to do (Figs. 10–12).

### EndoVac technique

Following removal of the chamber roof and exposure of the pulp, the Master Delivery Tip is used to provide frequent and abundant irrigation as the orifices are identified and explored. The Master Delivery Tip may be used to deliver irrigant into the pulp chamber while also suctioning debris brought coronal during the instrumentation process (Fig. 13). Care must be taken to deliver the irrigant passively into the pulp chamber and to avoid delivering irrigant directly into the orifice, as this will create positive apical pressure. The benefit of the Master Delivery Tip is that, with a single tip at the tooth's access, visibility is not blocked and large volumes of irrigation solution can be utilised. As the canals are being instrumented to a size #30 with a 0.04 taper, the MacroCannula is introduced between changes in file size. The MacroCannula is utilised to remove coarse debris during instrumentation and is used in combination with the Master Delivery Tip, which delivers the irrigation solution. Negative pressure is created as irrigation solution is

**Figs. 12a–c** Negative pressure irrigation using the EndoVac system, allowing thorough debridement of the canal system, and the apical lesion demonstrating significant healing apically, as well as sealer in the lateral canal at mid-root. Initial (a), following completion of endodontic treatment (b) and six months post-treatment (c).

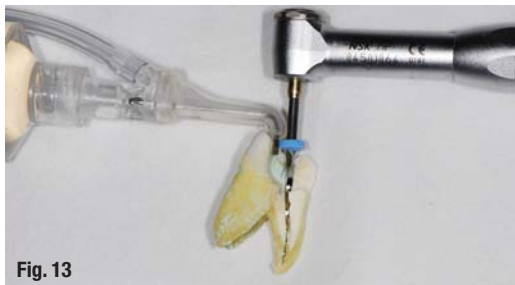

Fig. 13

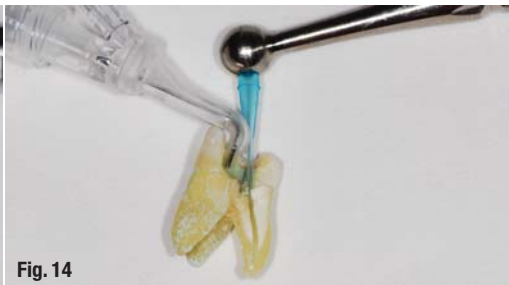

Fig. 14

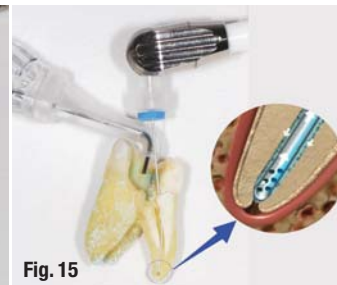


Fig. 15

**Fig. 13** Master Delivery Tip being used to provide constant irrigation as the canal is instrumented.

**Fig. 14** Use of the MacroCannula and Master Delivery Tip.

**Fig. 15** Use of the MicroCannula, showing placement of the tip in the apical root end.

drawn down the canal towards the apex as it is expressed from the Master Delivery Tip and then drawn up the MacroCannula (Fig. 14). It is suggested that the MacroCannula be used with a slight pumping motion as each canal is flushed. Irrigation should continue with the MacroCannula until clear fluid is observed being withdrawn through the tubing connected to the handpiece before proceeding to the next file.

When the canal has been enlarged to the desired size, the MacroCannula is again used until clear solution is observed in the tubing. This will ensure that all coarse debris has been removed from the canal. Next, the metal MicroCannula is placed in the finger piece and attached to the MPA connector line (white connection) and used upon completion of canal instrumentation to remove fine debris to the apical constriction under negative pressure once the canal has been instrumented to a size #35 with a 0.04 taper or greater (Fig. 15). To prevent plugging of the fine holes in the apical constriction, the MicroCannula must not be used until thorough irrigation has been accomplished with the MacroCannula and all instrumentation has been completed.

## \_Conclusion

Instrumentation, disinfection and obturation are important aspects of rendering quality endodontic care. Yet, the instruments we use to prepare the canal, whether hand or mechanised, are unable to reach all aspects of the canal system. Irrigation is key to cleaning and disinfecting those areas that cannot be reached by instrumentation alone.

The EndoVac irrigation system with its negative pressure is able to move much larger volumes of irrigant through the canal system, safely, resulting in more thorough removal of the fine debris at the apical constriction, thereby providing a better environment for sealing. Accordingly, negative pressure irrigation not only greatly improves both the flow and safety of irrigation with NaOCl, but has also been shown to minimise post-operative sensitivity following treatment, compared with traditional positive pressure irrigation protocols.

*Editorial note: A complete list of references is available from the publisher.*

## \_about the author

roots



**Dr Gregori M. Kurtzman** is in private general practice in Silver Spring, Maryland, and is a former assistant clinical professor at the University of Maryland. He has lectured internationally on the topics of restorative dentistry, endodontics, implant surgery and prosthetics, removable and fixed prostheses, and periodontics, and he has over 260 published articles. He is a fellow of the Academy of General Dentistry, American Academy of Implant Prosthodontics, American College of Dentists, International Congress of Oral Implantologists, Pierre Fauchard Academy, Academy of Dentistry International; master of the Academy of General Dentistry and International Congress of Oral Implantologists; and diplomate of the International Congress of Oral Implantologists and American Dental Implant Association.

## \_contact

Leisure World Plaza Professional Building  
3801 International Drive, Suite 102  
Silver Spring, MD 20906  
USA

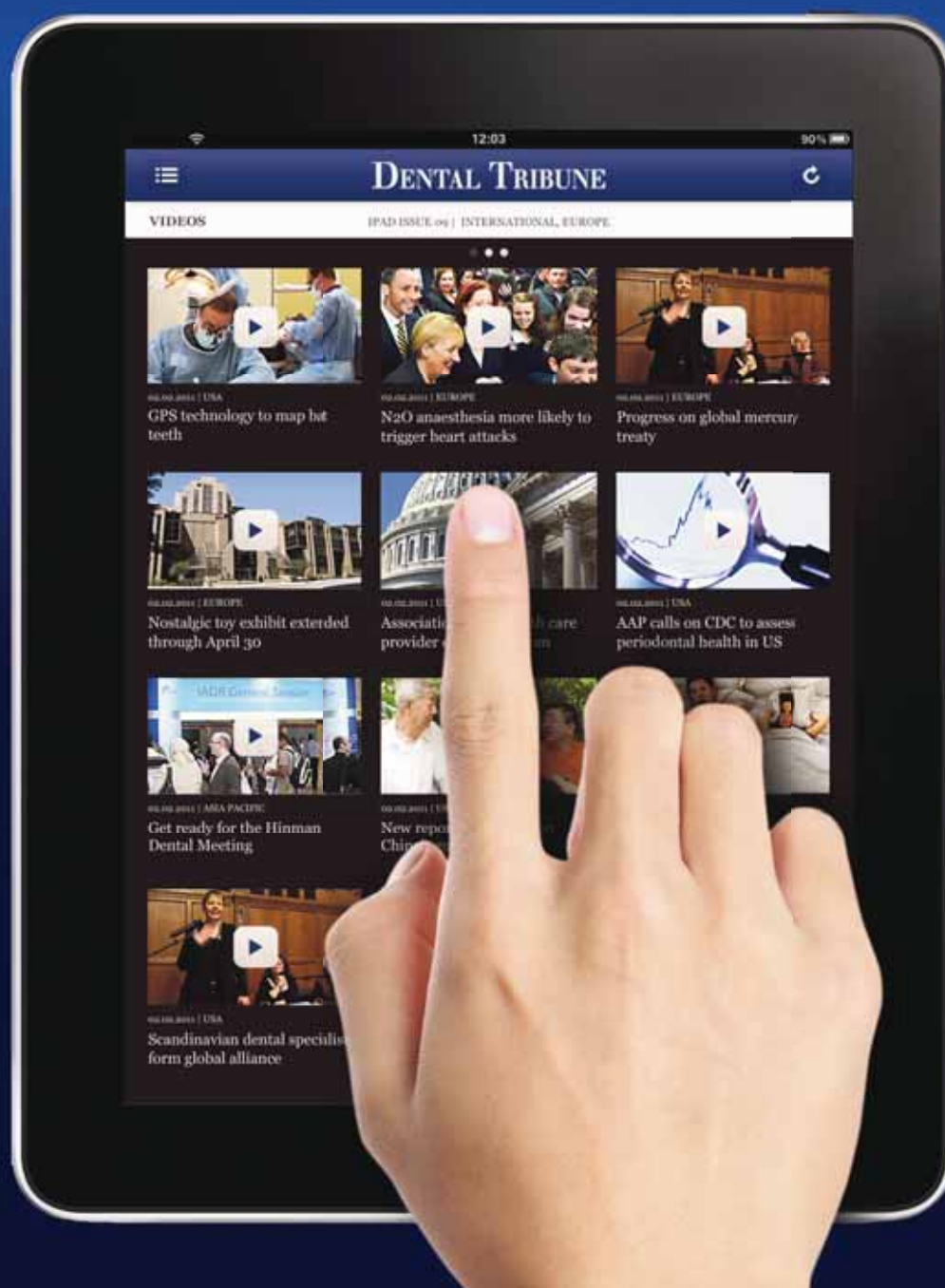drimplants@aol.com  
www.maryland-implants.com



# Dental Tribune for iPad – Your weekly news selection

Our editors select the best articles and videos from around the world for you every week. Create your personal edition in your preferred language.

[ipad.dental-tribune.com](http://ipad.dental-tribune.com)



# DENTAL TRIBUNE

— The World's Dental Newspaper —

# Determining working length

Author\_ Dr Chris J. Lampert, USA

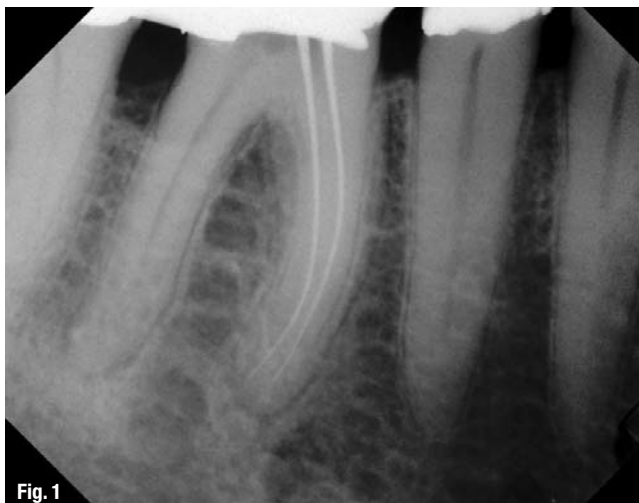


Fig. 1

Fig. 1\_Radiograph.

**An accurate working length** is one of the most important criteria for achieving successful endodontic results and minimising post-operative discomfort. An erroneous working length, either long or short, can compromise the outcome of the case from the beginning. An erroneously short working length leaves uncleaned and unfilled canal space in the apical region. An erroneously long working length will lead to over-instrumentation and overextended obturation, causing significant post-operative discomfort. That being said, in my opinion, it is better to be slightly long than slightly short.

There are different opinions throughout endodontics on where the canal terminus is. There is also debate on how close to the canal terminus you should clean and shape. Do you work short of the canal terminus at the expense of leaving pulp tissue and debris in the canal? Do you achieve patency and clean the entire canal? I am definitely a proponent of achieving patency and cleaning the entire canal. Leaving tissue in the apical region is setting the case up for failure later.

Currently, the three accepted methods for determining working length are

- \_radiographs,
- \_electronic apex locators, and
- \_the paper point method.

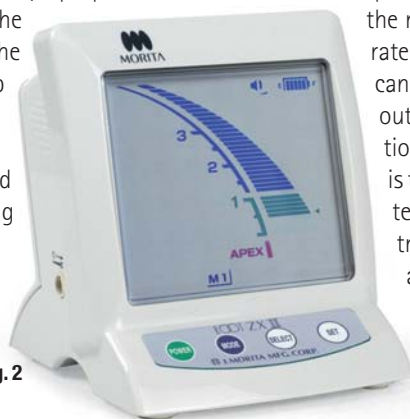


Fig. 2

Fig. 2\_Electronic apex locator (Root ZX).

## \_Radiographic working length

Radiographs are probably the most common method used for determining working length. Although radiographs (Fig. 1) are important in endodontic treatment, primarily for assessing canal curvature and root form, they have limitations regarding length determination. This is because the radiographic apex (the end of the root on the radiograph) and canal terminus (where the canal exits the root) often do not coincide. One absolute that can be proven by a radiograph is when a file is out of the apex. At that point, there is no doubt you are patent. If the file is right at the radiographic apex, you are usually patent. If the file is short of the apex on a radiograph, you still might be patent. This is the reason that radiographs can be used to confirm patency, but are not the most accurate method for determining working length.

## \_Electronic apex locators

Aside from the surgical microscope, the electronic apex locator (Root ZX, J. Morita; Fig. 2) is the most valuable piece of endodontic equipment in my office. When used correctly, an electronic apex locator is the most accurate and efficient method for determining endodontic working length. When used incorrectly, it can be an unreliable source of frustration. Obtaining a consistent, reliable apex locator reading is necessary for developing confidence in its use.

In order to better understand apex locator use, the attributes and limitations of the device must first be understood. Apex locators should be thought of as "patency locators" because patency is what they detect. Apex locators measure the change in electrical impedance at the canal terminus. This is the reason that they are most accurate at showing when a file is in the canal (not patent) and when a file is out of the canal (patent). The location at which these two points meet is the point of patency, or the canal terminus. This measurement is the true canal length. Apex locators are less accurate at showing how close the file is to the canal terminus. This is the reason that most apex loca-

tor manufacturers suggest passing the file tip out of the canal terminus (going patent) then pulling the file tip back into the canal terminus to find the exact point of patency for the best results. If you have not achieved patency then the only information you get from the apex locator is confirmation that you are not patent. Achieving patency is an absolute requirement for using an apex locator to determine working length.

The following tips will help you achieve a consistent and smooth apex locator reading and improve your apex locator experience:

1. For teeth with multiple canals, the chamber and preferably the canals should be dry. Manufacturers claim that their units work in moist environments (wet canals) but this is primarily true for teeth with one canal. In teeth with multiple canals, fluid will bridge from one canal to another, allowing electrical current to flow down multiple canals. The apex locator will not know which canal is being measured and produce an inaccurate reading.
2. Remember the file must maintain good electrical contact with the canal wall and not contact metallic restorations.
3. Use a thin layer of viscous lubricant such as RC-Prep (Premier Dental) to coat the file and improve electrical contact between the file and the canal wall.
4. Placing a curve in the file will also increase the electrical contact between the file and the canal wall.
5. The most stable reading is achieved when the file size approaches the natural size of the canal. The file must fit snugly within the canal and have good electrical contact with the canal wall. When an erratic reading occurs, change to a larger file size until the reading becomes stable and reproducible.
6. Always advance the file until the file tip is patent (the apex locator reads "apex"), then slowly pull the file back into the constriction of the foramen to find the exact point of patency; this is the true canal length. Achieving patency is an absolute requirement for accurately using an apex locator.
7. Apex locators are accurate at showing when the file is in the canal (not patent) and when the file is out of the canal (patent). The location at which these two points meet is the point of patency, or the end of the canal. This is the true canal length. Apex locators are less accurate at showing how close you are to the canal terminus.

When you are completely confident in your apex locator reading, working length determination takes only a few seconds and is the most reliable method for length determination.




Fig. 3

### \_\_Paper point method

The paper point method is most accurate for determining the final canal length prior to obturation. This technique requires a shaped canal; therefore, it is used following instrumentation. In this method, a feather-tipped paper point (Fig. 3) is placed through the terminus of a dry patent canal. The tip of the paper point becomes moist where it exits the canal and the moisture spot is the true working length for obturation. The moist tip of the paper point bends easily, as shown in Figure 3. This method is very good for post-shaping measurement, but it is also technique sensitive and requires much practice to master. The paper point method requires a patent canal terminus and great care must be taken to prevent over-instrumentation and apical bleeding.

Often use this method to compare the pre-shaping working length from an electronic apex locator to the post-shaping working length. In curved canals, the degree of curvature is usually less following instrumentation. This reduction in curvature means there is a straighter and shorter distance to the canal terminus, resulting in a shortening of the true working length.

### \_\_Conclusion

I rely on and trust the electronic apex locator over all other length-determining methods. Once you develop confidence in your electronic apex locator, it will shorten your treatment time and increase your accuracy. Ultimately, it will produce better end-results with less post-operative discomfort for your patients.

Fig. 3\_Paper point.

\_\_author

roots



#### Dr Chris Lampert

completed his specialty training in endodontics at Boston University in 2003. He currently maintains a private practice limited to endodontics in Portland, Oregon. Dr Lampert is also the Founder and President of Specialized Endo, an endodontic instrument company that designs, manufactures, and distributes endodontic instruments to dentists and endodontists. Learn more at [www.specializedendo.com](http://www.specializedendo.com)



# The right to be pain free

**Author\_** Dr Michael Sultan, UK

**\_Pain is defined by** the World Health Organization (WHO) as "an unpleasant sensory or emotional experience associated with actual or potential tissue damage, or described in terms of such damage".

While recognising its existence, what the WHO doesn't mention is that pain is, of course, entirely subjective, which is one of the reasons that it is such a challenge and a major global public health issue. We probably know far more about pain and its treatment than ever before, yet there is a disconnect between having that knowledge and using it to treat and manage pain.

I believe passionately that dental professionals in general, and endodontists in particular, should commit to the right of every patient to be free of pain and, through our work as compassionate professionals, to understanding acute pain management, if we are to provide real health and emotional benefits for our patients.

During the 2010-11 "Global Year Against Acute Pain", the International Association for the Study of Pain published a paper that points to inadequate education of health-care practitioners as one of the

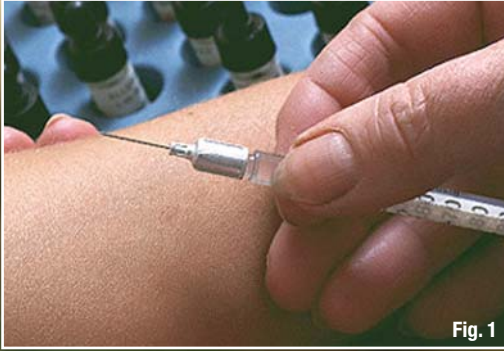


Fig. 1



Fig. 2

different pain thresholds and, indeed, vastly different capacity to deal with it. Interestingly, the Australian and New Zealand College of Anaesthetists puts at the very top of its list in a statement on Patients' Rights to Pain Management: "The right to be believed, recognising that pain is a personal experience and that there is a great variability among people in their response to different situations causing pain."

Acute pain is the awareness of noxious signals from damaged tissue and is complicated not only by sensitisation in the periphery but also by changes in the central nervous system. A person's emotional state can often have a significant influence on pain and increase the level of distress and impact on quality of life. Pain is hugely debilitating and makes life extremely miserable for millions of people every day, and there are many underlying cultural, economic and social reasons that should also be taken into consideration.

I firmly believe that the dental profession must work with the government, policymakers and campaigners to ensure that every patient has access to pain-free dentistry. In some cases, this will mean that NHS patients will receive treatment from private dental specialists, an issue raised by the Steele report, which suggests that poorer patients are forced to settle for extractions and dentures rather than tooth preservation, with root-canal treatments the preserve of the rich.

While there is no legally enshrined right to be pain free, there are those who believe that the internationally established and recognised rights to health include that by implication and inference. We can at least encourage greater awareness, better education and knowledge sharing, as well as raising patient expectations to be pain free.

main reasons for underestimating the seriousness of, and failing to recognise treatment options for, acute pain.

It is clear therefore that, despite huge advances in a vast array of sophisticated medical and non-clinical treatment options, we are part of the problem so we must become part of the solution.

By increasing our own awareness and understanding of the issues surrounding the assessment and treatment of acute pain, we can, in turn, help educate our colleagues in the use of anaesthetics and analgesics so they are better placed to offer information and help to their patients, many of whom are reluctant to use painkillers for fear of unpleasant side-effects or even, addiction.

Pain is both physical and emotional, which is the reason that it is fundamentally important to recognise that it is subjective and that different people will have

**Fig. 1** By understanding the use of anaesthetics and analgesics, dental staff are better placed to offer information and help to their patients.

**Fig. 2** Every patient has the right to be pain free.

## about the author

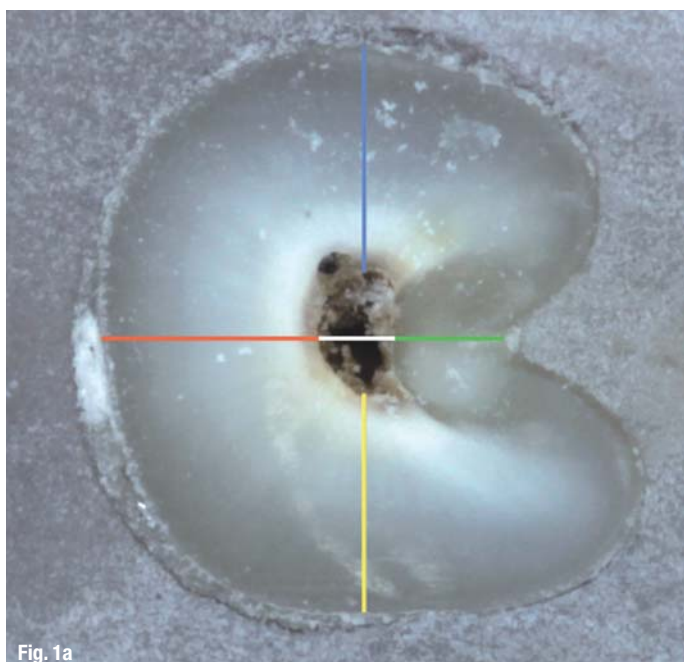
roots



**Dr Michael Sultan** (BDS, MSc, DFO, FICD) is a specialist in endodontics and the Clinical Director of EndoCare, a group of specialist practices. Michael qualified at University of Bristol in 1986. He worked as a general dental practitioner for five years before commencing specialist studies at Guy's Hospital, London. He completed his MSc in Endodontics in 1993 and worked as an in-house endodontist in various practices before setting up in Harley St., London, in 2000. He was admitted to the specialist register in endodontics in 1999 and has lectured extensively to postgraduate dental groups, as well as presented endodontic courses at the Eastman Dental Institute's CPD department, University of London. He has been involved in numerous dental groups and has been chairperson of the Alpha Omega International Dental Fraternity. In 2008, he became clinical director of EndoCare.

# Dentine thickness in buccal roots of maxillary first premolars following preparation with three techniques

**Authors\_ Drs Paola Adriana Lammertyn & Liliana Gloria Sierra, Argentina**



**Figs. 1a & b** Image of the transversal cut of a MFP buccal root prepared with K3 G-Pack. Pre-preparation showing the measurements taken: lingual dentine thickness (green line), buccal dentine thickness (red line), proximal a and b (blue and yellow lines), bucco lingual canal diameter (white line; a). Same image after preparation (b).

## Introduction

Coronal and root fractures in teeth are the third major cause of dental loss after caries and periodontal disease.<sup>1</sup> Of these, maxillary premolars account for more than half of the fractured teeth.<sup>2,3</sup> Some etiological factors reported are dentine dehydration due to endodontic treatment, unique anatomic features, loss of dentine structure due to caries, access preparation and excessive canal preparation. Although some studies have demonstrated that neither dehydration nor endodontic treatment altered the mechanical properties of dentine, it is worth mentioning that the loss of structural integrity owing to caries, previous restorative work or access preparation can predispose teeth that have been endodontically treated

to fracturing at a greater frequency than teeth with vital pulps.<sup>4-6</sup> Moreover, this predisposition increases proportionally with the amount of dentine removed.<sup>7</sup>

The type of tooth, canal-wall thickness, root-canal diameter and cross-canal shape may be associated with an increased risk of root fracture following endodontic treatment. In addition, the instruments selected and preparation technique, as well as the size of the master apical file, may also be responsible for possible fracture either during or after endodontic treatment.<sup>8</sup> Finally, irregularities within the internal or external root morphology or sites with small dentine thickness are able to produce areas of strength concentration, which could be critical factors contributing to the initiation and propagation of root fractures.<sup>9,10</sup>

Maxillary first premolars (MFPs) have ovoid roots with a mesiodistal diameter narrower than that of the buccolingual and display variable radicular configuration and external grooves. Among these grooves is the furcation of the buccal root, which is referred to as a developmental depression, and extends longitudinally over the lingual aspect from the furcation towards the apex. Previous studies on dentine thickness in the buccal root of MFPs demonstrated that the smallest dentine thicknesses were found in the lingual wall and had average values of 0.81 to 1.31 mm, depending on the study.<sup>11–13</sup>

The anatomical factors and operative procedures used are particularly important, given that MFPs are the most prone to fracture.<sup>3,4</sup> Even though these fractures can be caused by many factors, they are often the result of inappropriate preparation owing to a lack of knowledge regarding dentine thickness, as well as to poor file selection.

One of the main objectives of root-canal preparation is to shape and clean the root-canal system effectively whilst maintaining the original configuration; however, traditional stainless-steel instruments often fail to achieve the tapered root-canal shapes needed for adequate cleaning and filling. Therefore, NiTi rotary instruments were introduced to improve root-canal instrumentation, create continuously tapered preparations and shorten working time. These entailed the development of features such as non-cutting tips, radial lands, different cross-sections and superior resistance to torsional fracture with varying tapers.<sup>14</sup> In an earlier study, it was observed that the taper of the preparation and the files chosen could be contributing factors to the generation of craze lines and dentinal defects. It was also demonstrated that these defects could increase the risk of future fracture.<sup>10</sup>

Morphometric studies have shown that the thickness of the lingual wall in buccal roots of MFPs is less than 1 mm on average in instrumented canals.<sup>15</sup> This confirms our previous findings and should be taken into account.<sup>13</sup> Related to this, it is important to note that in prosthetic and endodontic procedures, it is generally agreed that a dentine thickness greater than 1 mm should always

remain.<sup>16</sup> The purpose of this study was to evaluate dentine thickness in the buccal root of MFPs both pre- and post-preparation using three different rotary canal instrumentation techniques.

### Materials and methods

The sample consisted of 24 MFPs with two well-formed roots and mature apices without visible apical resorption. The teeth were carefully selected to have a length of between 20 and 22 mm and the furcation located not more than 8 mm from the cemento-enamel junction. The teeth were obtained from the Department of Endodontics, Faculty of Dentistry, University of Buenos Aires. These were treated according to safety protocols established by the University of Buenos Aires, and were kept in solution with equal parts of alcohol and glycerine until use. The teeth were divided into three groups according to the instrumentation technique utilised: (a) K3 G-Pack (SybronEndo) was used for group 1 (n = 8); (b) ProTaper (DENTSPLY Maillefer) for group 2 (n = 8); and (c) RaCe (FKG) for group 3 (n = 8). The teeth were embedded in acrylic resin in a similar way to that previously used for the Bramante muffle.<sup>17</sup>

A vacuum-forming machine was used to create a clamp of plastic resin, which allowed the tooth to be moved back to its original position once sectioned. The blocks were sectioned perpendicular to the larger axis of the tooth using a precision saw (IsoMet Plus) at approximately 2 mm apical to the furcation. Each cut was photographed (Canon; macro 100 mm, 1:1, 3,000 x 4,000 pixels) pre- and post-canal instrumentation.

All buccal root-canal preparations were performed in a crown-down fashion in the following sequence for each group:

— K3 G-Pack: 25.12, 25.10, 25.08, 25.06 and 25.04;

— ProTaper: S1, S2, F1, F2 and F3;

— Easy RaCe: 40.10, 35.08, 25.06 and 25.04.

All samples were frequently irrigated with 2.5% sodium hypochlorite. Canals were dried with paper points.

The pre- and post-preparation photographs were analysed with the ImageJ pro-



## One issue free of charge!

✂ **Subscribe now!**

You can also subscribe via  
[www.oemus.com/abo](http://www.oemus.com/abo)

I hereby agree to receive a free trial subscription of **cosmetic dentistry** (4 issues per year). I would like to subscribe to **cosmetic dentistry** for € 44 including shipping and VAT for German customers, € 46 including shipping and VAT for customers outside Germany, unless a written cancellation is sent within 14 days of the receipt of the trial subscription. The subscription will be renewed automatically every year until a written cancellation is sent to OEMUS MEDIA AG, Holbeinstr. 29, 04229 Leipzig, Germany, six weeks prior to the renewal date.

▶ Reply per Fax +49 341 48474-290 to OEMUS MEDIA AG or per E-mail to [grasse@oemus-media.de](mailto:grasse@oemus-media.de)

Last Name
First Name
Company
Street
ZIP/City/County
E-Mail
Signature

Notice of revocation: I am able to revoke the subscription within 14 days after my order by sending a written cancellation to OEMUS MEDIA AG, Holbeinstr. 29, 04229 Leipzig, Germany.

Signature
-----------

OEMUS MEDIA AG  
Holbeinstr. 29, 04229 Leipzig  
Tel.: +49 341 48474-0  
Fax: +49 341 48474-290  
E-Mail: [grasse@oemus-media.de](mailto:grasse@oemus-media.de)



**Table 1** Mean values and SE of each of the measured groups pre- and post-preparation.

(LDT: Lingual dentine thickness;  
BDT: Buccal dentine thickness;  
BLCD: Buccolingual canal diameter.)

Preparation technique	Variable	Pre-preparation		Post-preparation		Variation	Probability
		Mean	SE	Mean	SE		
K3 G-Pack	LDT (mm)	1.09	0.10	0.96	0.11	-13 %	0.0490
	BDT (mm)	1.25	0.10	1.14	0.12	-9 %	0.0323
	BLCD (mm)	0.34	0.04	0.52	0.06	+52 %	0.0003
	Proximal a (mm)	1.51	0.11	1.45	0.12	-4 %	0.3504
	Proximal b (mm)	1.58	0.12	1.51	0.10	-4 %	0.1374
	Area (mm <sup>2</sup> )	0.16	0.04	0.25	0.04	+56 %	0.0010
Pro Taper	LDT (mm)	1.02	0.06	0.94	0.04	-8.5 %	0.0192
	BDT (mm)	1.17	0.02	1.10	0.03	-6.3 %	0.0057
	BLCD (mm)	0.36	0.05	0.53	0.03	+47 %	0.0004
	Proximal a (mm)	1.40	0.05	1.31	0.05	-6.8 %	0.0153
	Proximal b (mm)	1.32	0.07	1.24	0.06	-6.4 %	0.0076
	Area (mm <sup>2</sup> )	0.15	0.03	0.24	0.03	+60 %	< 0.0001
RaCe	LDT (mm)	1.07	0.07	0.98	0.08	-9.2 %	0.0119
	BDT (mm)	1.19	0.06	1.10	0.07	-8 %	0.0282
	BLCD (mm)	0.37	0.05	0.52	0.05	+40%	0.0012
	Proximal a (mm)	1.29	0.04	1.24	0.04	-4 %	0.0444
	Proximal b (mm)	1.38	0.06	1.31	0.06	-5 %	0.0319
	Area (mm <sup>2</sup> )	0.21	0.07	0.30	0.08	+42 %	0.0003

gram (<http://rsbweb.nih.gov/ij>), and measurements of the following variables were taken:

- a) lingual dentine thickness (LDT);
- b) buccal dentine thickness (BDT);
- c) proximal dentine thickness a;
- d) proximal dentine thickness b;
- e) buccolingual diameter of the canal (BLCD);
- f) canal area.

The mesial and distal aspects were grouped together for the purpose of this study and named proximal dentine thickness a and b (Figs. 1a & b).

### Statistical analysis

Statistical analysis was carried out using InfoStat Professional 2010 (FCA-UNC). The Student's t-test was used for comparisons of paired samples between pre- and post-preparation images, and the Kruskal-Wallis non-parametric test was utilised for unpaired samples. P < 0.05 was considered to be statistically significant.

### Results

#### Comparison between paired samples

Mean values and the standard error (SE) were taken pre- and post-preparation for each group and

instrumentation technique. Then, the pre- and post-preparation variation was calculated for each value found (Table 1).

**K3 G-Pack group:** Significant differences between pre- and post-preparation values were observed in LDT (P = 0.0490) and BDT (P = 0.0323), as well as in the BLCD (P = 0.0010).

**ProTaper group:** Significant differences between pre- and post-preparation values were observed in all the variables examined. These were LDT (P = 0.0192), BDT (P = 0.0057), BLCD (P = 0.0004), proximal dentine thickness a (P = 0.0153), proximal dentine thickness b (P = 0.0076) and canal area (P < 0.0001).

**RaCe group:** Significant differences between pre- and post-preparation values were observed in all the variables examined. These were LDT (P = 0.0119), BDT (P = 0.0282), BLCD (P = 0.0012), proximal dentine thickness a (P = 0.0444), proximal dentine thickness b (P = 0.0319) and canal area (P = 0.0003).

#### Comparison between independent groups

It was noted that the three preparation techniques had similar effects, inasmuch as they all provoked a thinning of the dentine walls and an increase in the canal diameter after preparation.



## Discussion

Owing to its anatomical complexity, the endodontic treatment of pathologies affecting MFPs remains a challenge for the clinician. Knowledge of the internal anatomical relationships is fundamental for canal preparation. In addition, several external anatomical characteristics must be taken into account, such as the sulcus and furcation grooves and cracks, and in particular the relationship that exists between them and the variations in dentine thickness. It has already been established that the more grooves there are on the surface of the root and the deeper and more extensive they are, the greater the variations observed in the internal anatomy of the root canals will be.<sup>18</sup>

In a previous study on dentine thickness in MFPs, it was demonstrated that dentine became thinner in the area corresponding to the presence of external grooves.<sup>19</sup> In addition, a high-resolution computed tomography analysis showed that the changes that occur in the canal configuration after preparation depend more on the original canal anatomy than on the instrumentation technique chosen.<sup>20</sup> Therefore, it is fundamental for the clinician to be aware of anatomical variations.

The reported dentine thickness of buccal roots in unprepared teeth varies among authors. Tamse et al.<sup>11</sup> and Katz et al.<sup>15</sup> found mean values of less than 1 mm in the lingual wall, whereas Bellucci's mean values were more than 1 mm, with the latter study coincid-

ing with our findings.<sup>12,21</sup> In agreement with earlier studies, the mean values we found in the buccal wall were larger than 1 mm and greater than in the lingual wall on average.<sup>12,22</sup> However, it should be noted that although the dentine thickness was greater than 1 mm on average, in 11 samples this value was less than 1 mm (Table 1).

All three groups revealed a mean dentine thickness in the lingual wall of the buccal root of 0.96 mm after instrumentation, with 15 of 24 samples showing a wall thickness of less than 1 mm after canal preparation. In an earlier investigation on mandibular molars in which rotary instrumentation and a similar method of assessment was used, it was demonstrated that pre-instrumentation dentine thickness was the major factor in determining post-instrumentation dentine thickness.<sup>23</sup> As seen in our studies, the smallest dentine thicknesses were found in the furcal wall.

Li et al.<sup>24</sup> analysed changes in the configuration of MFPs with five classes of canal configuration, including the one used in our study (Weine Type III). They used the F3 ProTaper file as the master apical file, and found an increased canal volume and surface and canal straightening towards the inner aspects of the curved parts. Although these authors reported a good instrumentation effect, 40.7% of walls were untouched.

Pilo et al.<sup>22</sup> reported a mean of 0.82 mm for furcation wall thickness after instrumentation. However, the difference with our study may be attributed to the use of different instrumentation techniques.

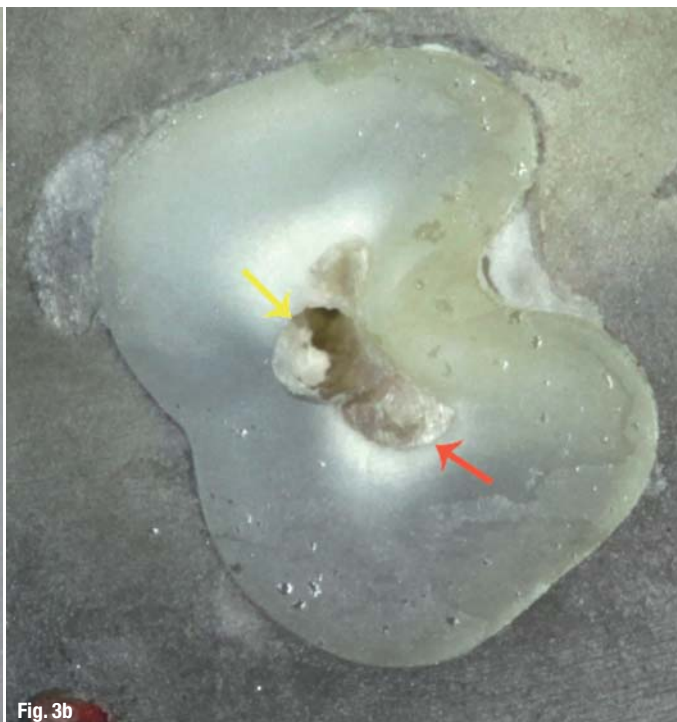
**Figs. 2a & b** Photomicrograph of buccal root prepared with ProTaper. Pre-preparation (a). Same image post-preparation (b). It can be observed that the instrument tends to lean against the furcation wall (yellow arrow).

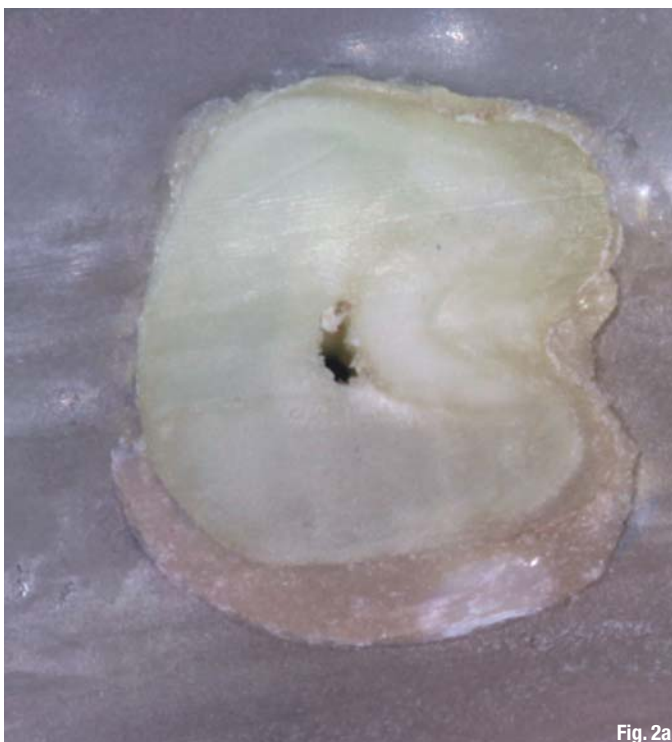

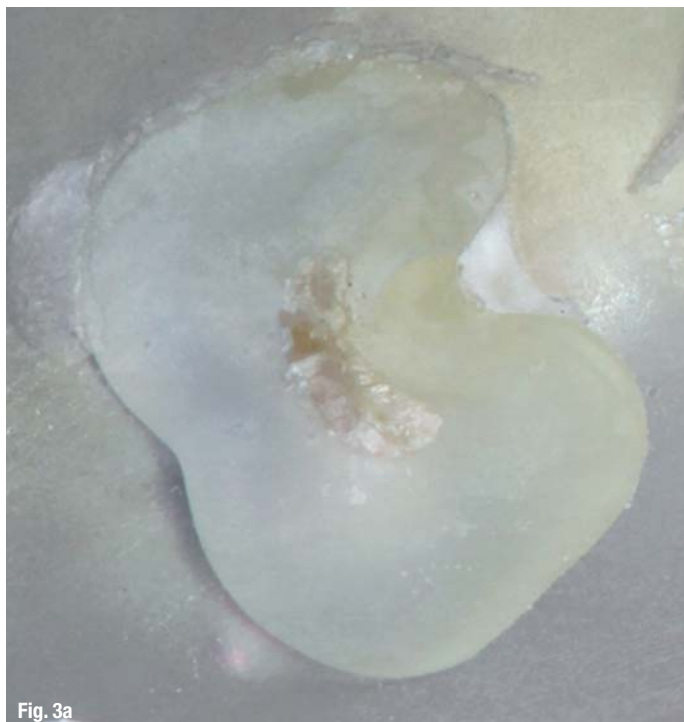Fig. 2a



Fig. 2b



**Figs. 3a & b** Photomicrograph of buccal root prepared with RaCe. Pre-preparation (a). Same image post-preparation (b). The yellow arrow clearly shows the canal area prepared by the instrument, leaving other areas untouched (red arrow).

The preparation of the coronal third of the canal is fundamental to access of the apical third. This allows for optimal debris removal and overall better irrigation, preparation and obturation. However, the thickness of dentine walls must be preserved, as any thinning will predispose the roots to perforation and radicular fracture. It should be born in mind that during any type of preparation, especially rotary instrumentation, the instruments tend to wear down the thinnest walls that correspond to the furcation groove in the MFPs (Figs. 2a & b).<sup>15</sup> In the present study, we measured dentine thickness 2mm apical to the

furcation, as this corresponds to the critical area where fissures commence after root-canal treatments. Although the three instrumentation systems used in this study are not consistent in taper, they were chosen for being in current use in clinical practice.

The present results were similar for all three systems used in this study, with dentine thickness decreasing as canal area increased significantly (Table 1). On analysing the slices after surgical preparation, it was noted that all instruments tended to produce rounded preparations, while leaving some areas of the walls untouched (Figs. 3a & b).

The thickness of the dentine walls decreased by 4 to 13% and the most important changes were found in the furcation wall, thus confirming earlier studies that indicated that instruments tend to lean on this wall and thereby cause greater thinning of the area in question (Table 1).<sup>13,25,26</sup> This may be attributed to the corono-radicular axis and the divergence of the canal, which leads to the instrument leaning on top of the furcation wall. It is therefore very important to record the measurements of the lingual wall after preparation. We obtained mean values smaller than 1 mm for all the groups, as previously seen in other studies.<sup>15</sup> Thus, owing to the presence of the furcation groove, these values were smaller than the recommended 1 mm dentine thickness.<sup>27</sup> Related to this, previous studies have shown that the risk of fracture increases as more dentine is removed.<sup>8</sup>

We agree with Robbins that, ideally, the canals of MFPs should not be enlarged after endodontic obtu-

**\_about the authors** **roots**

**Dr Paola Adriana Lammertyn** has a PhD in Dentistry and is a specialist in endodontics.

Dr Paola Adriana Lammertyn  
Franchini 108  
X5186IWD – Alta Gracia, Córdoba  
Argentina  
Tel./Fax: +54 354 742 1187

paolammertyn@hotmail.com

**Dr Liliana Gloria Sierra**

Head Professor  
Department of Endodontics  
University of Buenos Aires  
Marcelo T. de Alvear 2142  
C1122AAH – Buenos Aires  
Argentina

ration.<sup>28</sup> If the use of posts is required, they must be modified to fit the canal.<sup>29</sup> Indeed, excessive post-space preparation weakens root strength and increases the risk of root perforation, especially with premolars and mandibular incisors.<sup>9</sup> In our study, the BLCD and its area revealed increases of greater than 40%, as seen in earlier studies (Table 1).<sup>30,31</sup>

Anatomy and topography studies are necessary, since the data obtained will facilitate the determination of which instruments and techniques to use in any given case. Some authors maintain that endodontic preparation should respect the anatomy of the canal. However, this may be very difficult to carry out if the practitioner does not have the appropriate technology to adapt his or her clinical reality to the anatomical and topographical needs. In fact, the clinician must generate a new anatomy after canal preparation, which means that he or she has to assess the limits, thickness and shape of the new contours. Consequently, the measurements of this new dental piece will be critical for any future restorative treatment and for its return to mandibular function. Future studies involving strength patterns should follow anatomy and topography studies, and as a result lead to new lines of investigation.

## \_ Conclusion

In the present study, we chose three instrumentation systems used in clinical practice. In the case of an MFP, the clinician should be aware of the original anatomy in order to obtain cleanliness and proper obturation with fewer instruments. Dentine thickness in the buccal roots of MFPs decreases significantly after preparation, with the furcation wall being the most affected area. The three preparation techniques had similar results. The BLCD increased significantly after preparation.

## \_ Clinical recommendations

Owing to the particular anatomical characteristics of MFPs, their treatment remains a real therapeutic challenge. Anatomical aspects such as the furcation groove in buccal roots, proximal grooves and dentine thickness have to be taken into account when planning endodontic and prosthetic procedures. Ideally, the canals should not be additionally enlarged after endodontic preparation.

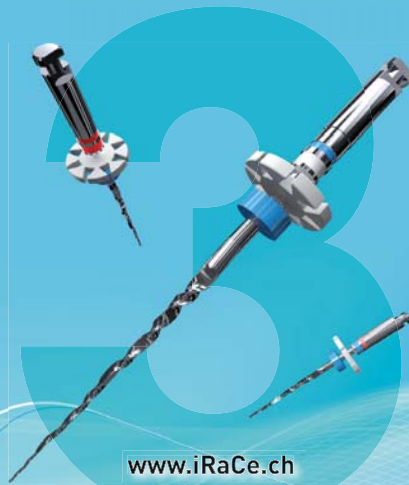*Editorial note: A complete list of references is available from the publisher.*

AD



# iRaCe

Only 3 instruments...



[www.iRaCe.ch](http://www.iRaCe.ch)

... for most cases

*Roots Summit*  
Foz de Iguaçu, Brazil  
18 - 20 Oct 2012  
SYNERGY C.P.D. S.A.

**AWARD-WINNING**



Swiss Venture Club



[www.fkg.ch](http://www.fkg.ch)

prix de l'entreprise  
suisse romande

More info on [fkg.ch](http://fkg.ch)



# Moisture-activated temporary filling and sealing material

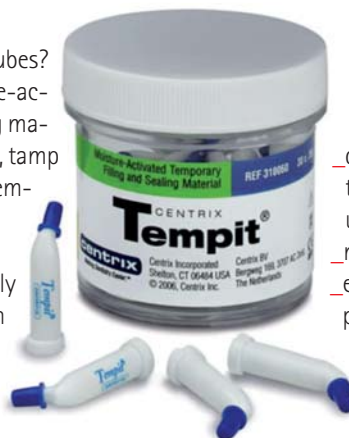Tempit is packaged in 30 tips of 0.35g each in a jar.

**\_contact roots**

**Centrix**  
Tel.: +49 221 530978-0  
koeln@centrixdental.com  
www.centrixdental.com

**\_Still squeezing** those messy tubes? With Tempit, our unit-dose, moisture-activated temporary filling and sealing material, simply inject into a moist prep, tamp down and then dismiss the patient. Tempit sets in five minutes or less.

Tempit was developed specifically for sealing access cavities between root-canal treatments. It seals medicaments in and contaminants out between root-canal treatments.



Pre-filled, it eliminates set-up time. Unique delivery provides:

- \_direct** injection without worrying that the material will harden before use;
- \_no** clean-up; and
- \_eliminates** the voids you get when placing other materials.

No more spatulas! No more tubes or jars! **\_**

# RAYPEX 6— State-of-the-art technology

**\_For the precise location** of the apical constriction, electronic means have been proven to be superior to using radiographs. RAYPEX devices ensure precise measurement and feature a unique zoom-in function, which significantly aids endodontic treatment. The latest model, RAYPEX 6, redefines user-friendliness and design standards.

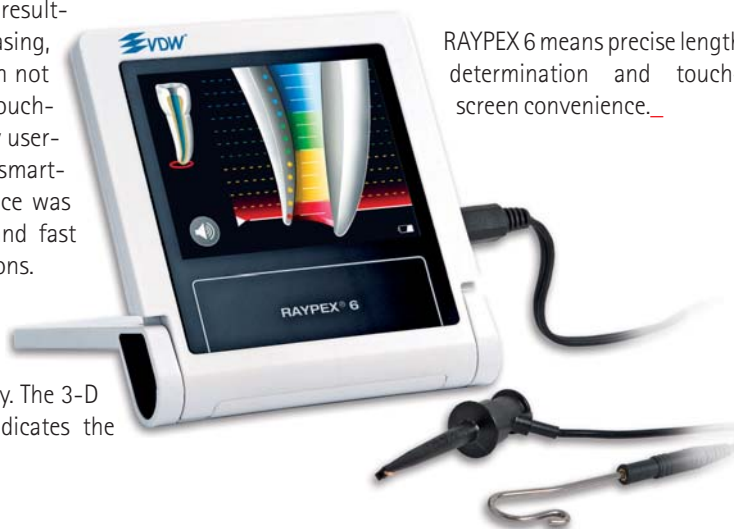Its design, operation and user-friendliness were developed to a high standard, resulting in a stylish and handy casing, which can be folded flat when not in use. The high-resolution touch-screen with a self-explanatory user-interface is comparable with a smartphone, and the menu guidance was designed to ensure precise and fast navigation through the functions.

For precise length determination, RAYPEX 6 uses the latest multi-frequency technology. The 3-D graphic display constantly indicates the

position of the tip of the file, while the automatic zoom-in function in the region of the apical constriction enhances safety in the critical section just before reaching the working length. Acoustic signals allow for a "blind" localisation of the apex.

RAYPEX 6 is ready for use—simply plug-in and start. Any personalisation of display colour and tones, for instance, can be done quickly.

RAYPEX 6 means precise length determination and touch-screen convenience. **\_**



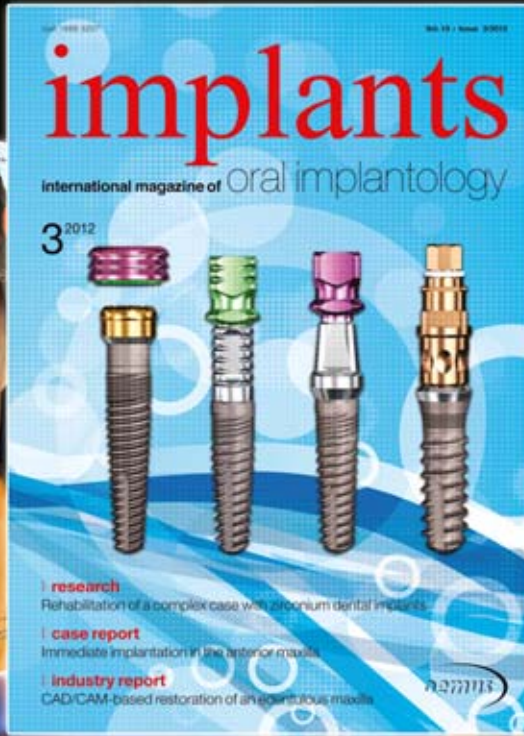**\_contact roots**

**VDW GmbH**  
Bayerwaldstr. 15  
81737 Munich  
Germany

info@vdw-dental.com  
www.vdw-dental.com

# implants

international magazine of oral implantology



You can also subscribe via  
[www.oemus.com/abo](http://www.oemus.com/abo)

 **Subscribe now!**

I hereby agree to receive a free trial subscription of **implants international magazine of oral implantology** (4 issues per year).

I would like to subscribe to **implants** for € 44 including shipping and VAT for German customers, € 46 including shipping and VAT for customers outside of Germany, unless a written cancellation is sent within 14 days of the receipt of the trial subscription. The subscription will be renewed automatically every year until a written cancellation is sent to OEMUS MEDIA AG, Holbeinstr. 29, 04229 Leipzig, Germany, six weeks prior to the renewal date.

▶ **Reply** via Fax +49 341 48474-290 to OEMUS MEDIA AG or via E-mail to [grasse@oemus-media.de](mailto:grasse@oemus-media.de)

## One issue free of charge!

Last Name, First Name	
Company	
Street	
ZIP/City/County	
E-mail	Signature

Notice of revocation: I am able to revoke the subscription within 14 days after my order by sending a written cancellation to OEMUS MEDIA AG, Holbeinstr. 29, 04229 Leipzig, Germany.

Signature
-----------



# IDS 2013: Organisers expect successful exhibition


Preparations for the 35<sup>th</sup> International Dental Show (IDS), which will be hosted in Cologne in March 2013, are already gathering pace. For the 2013 show, the organisers of the world's largest fair for dental medicine and technology are expecting a repeat of last year's interest from the dental world, when nearly 2,000 suppliers and 118,000 trade visitors made IDS 2011 the most successful ever.

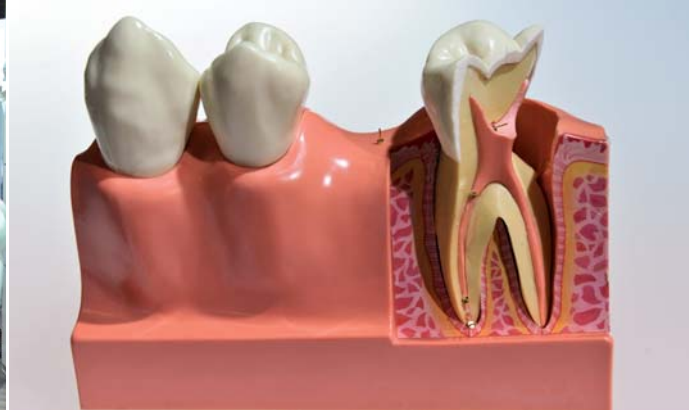The Society for the Promotion of the Dental Industry (Gesellschaft zur Förderung der Dental-Industrie—GFDI), IDS organiser and the commercial enterprise of the Association of German Dental Manufacturers (Verband der Deutschen Dental-Industrie—VDDI), and global company Koelnmesse, who is staging the event, have mailed the regis-

tration forms to potential exhibitors, kicking off preparations for next year.

Koelnmesse has already received numerous enquiries for stand space. Following the record results of IDS 2011, with 1,954 suppliers from 58 countries and around 118,000 trade visitors from 149 countries, the organisers are expecting similar interest next year. "According to a representative survey, around 90 per cent of the exhibitors of IDS 2011 are planning their participation at IDS 2013," said Dr. Martin Rickert, VDDI CEO. "This shows that the IDS is a not-to-be-missed event for all those who wish to successfully operate in the dental industry."

As with previous shows, the first day of the fair will be Dealers' Day, which concentrates on the





specialist dental trade and importers, thus offering the opportunity of uninterrupted sales negotiations at the exhibitors' stands.

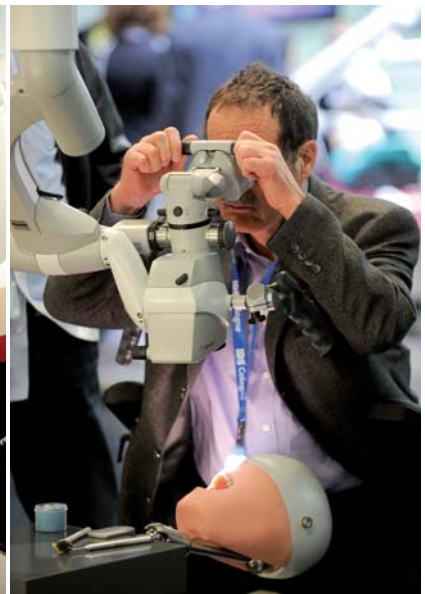Also, 81 per cent of the German and 99 per cent of the foreign suppliers acquired new international contacts.

As in 2011, the IDS will occupy exhibition space of 145,000 m<sup>2</sup>. The organisers expect the dental trade show to attract more than 1,900 national and international exhibitors. Even at this stage, many exhibition enquiries have been received from potential first-time exhibitors from abroad. Additionally, 12 foreign group presentations are expected so far.

According to the survey, the majority of visitors were satisfied with last year's IDS. Moreover, 78 per cent of the German and 81 per cent of the foreign trade visitors rated the product range as good to very good.

*All images courtesy of Koelnmesse GmbH.*

According to the organisers, the undisputed status of the IDS as the world's leading fair for the dental industry was also impressively underlined by the results of an independent exhibitor and visitor survey of IDS 2011. The event brought together decision-makers from the dental profession, dental technicians trade, specialist dental trade and dental industry from all over the world, which ensured great satisfaction among the IDS exhibitors. In addition, 97 per cent of the German suppliers reached their key customers in the domestic market and 83 per cent reached their key accounts from abroad.



Of the foreign exhibitors, as many as 98 per cent networked with their international customers and 95 per cent with their German customers, according to the survey. Furthermore, 95 per cent of the German and 98 per cent of the international exhibitors made new contacts with interested German parties.

# International Events

## 2012

**ESMD Annual Meeting**  
4–6 October 2012  
Berlin, Germany  
[www.esmd.info](http://www.esmd.info)

**ROOTS Summit**  
18–20 October 2012  
Foz do Iguaçu, Brazil

**DGET Annual Meeting**  
1–3 November 2012  
Leipzig, Germany  
[www.dget.de](http://www.dget.de)

**ÖGEndo International Congress**  
9 & 10 November 2012  
Vienna, Austria  
[www.oegendo.at](http://www.oegendo.at)

**AMED Annual Meeting**  
16 & 17 November 2012  
San Diego, CA, USA  
[www.microscopdentistry.com](http://www.microscopdentistry.com)

**ENDO BALTIC 2012**  
23 & 24 November 2012  
Vilnius, Lithuania  
[www.endodontologija.lt](http://www.endodontologija.lt)

**Greater New York Dental Meeting**  
23–28 November 2012  
New York, NY, USA  
[www.gnydm.com](http://www.gnydm.com)

## 2013

**DGET Spring Meeting**  
1 & 2 March 2013  
Hanover, Germany  
[www.dget.de](http://www.dget.de)

**International Dental Show**  
12–16 March 2013  
Cologne, Germany  
[www.ids-cologne.de](http://www.ids-cologne.de)

**IFEA World Endodontic Congress**  
23–26 May 2013  
Tokyo, Japan  
[www2.convention.co.jp/ifea2013](http://www2.convention.co.jp/ifea2013)

**FDI Annual World Dental Congress**  
28–31 August 2013  
Istanbul, Turkey  
[www.fdiworldental.org](http://www.fdiworldental.org)

**ESE Biennial Congress**  
12–14 September 2013  
Lisbon, Portugal  
[www.e-s-e.eu](http://www.e-s-e.eu)



© Andriy Ivanov



## submission guidelines:

Please note that all the textual components of your submission must be combined into one MS Word document. Please do not submit multiple files for each of these items:

- \_ the complete article;
- \_ all the image (tables, charts, photographs, etc.) captions;
- \_ the complete list of sources consulted; and
- \_ the author or contact information (biographical sketch, mailing address, e-mail address, etc.).

In addition, images must not be embedded into the MS Word document. All images must be submitted separately, and details about such submission follow below under image requirements.

### Text length

Article lengths can vary greatly—from 1,500 to 5,500 words—depending on the subject matter. Our approach is that if you need more or less words to do the topic justice, then please make the article as long or as short as necessary.

We can run an unusually long article in multiple parts, but this usually entails a topic for which each part can stand alone because it contains so much information.

In short, we do not want to limit you in terms of article length, so please use the word count above as a general guideline and if you have specific questions, please do not hesitate to contact us.

### Text formatting

We also ask that you forego any special formatting beyond the use of italics and boldface. If you would like to emphasise certain words within the text, please only use italics (do not use underlining or a larger font size). Boldface is reserved for article headers. Please do not use underlining.

Please use single spacing and make sure that the text is left justified. Please do not centre text on the page. Do not indent paragraphs, rather place a blank line between paragraphs. Please do not add tab stops.

Should you require a special layout, please let the word processing programme you are using help you do this formatting automatically. Similarly, should you need to make a list, or add footnotes or endnotes, please let the word processing programme do it for you automatically. There are menus in every programme that will enable you to do so. The fact is that no matter how carefully done, errors can creep in when you try to number footnotes yourself.

Any formatting contrary to stated above will require us to remove such formatting before layout, which is very time-consuming. Please consider this when formatting your document.

### Image requirements

Please number images consecutively throughout the article by using a new number for each image. If it is imperative that certain images are grouped together, then use lowercase letters to designate these in a group (for example, 2a, 2b, 2c).

Please place image references in your article wherever they are appropriate, whether in the middle or at the end of a sentence. If you do not directly refer to the image, place the reference at the end of the sentence to which it relates enclosed within brackets and before the period.

In addition, please note:

- \_ We require images in TIF or JPEG format.
- \_ These images must be no smaller than 6x6 cm in size at 300 DPI.
- \_ These image files must be no smaller than 80 KB in size (or they will print the size of a postage stamp!).

Larger image files are always better, and those approximately the size of 1 MB are best. Thus, do not size large image files down to meet our requirements but send us the largest files available. (The larger the starting image is in terms of bytes, the more leeway the designer has for resizing the image in order to fill up more space should there be room available.)

Also, please remember that images must not be embedded into the body of the article submitted. Images must be submitted separately to the textual submission.

You may submit images via e-mail, via our FTP server or post a CD containing your images directly to us (please contact us for the mailing address, as this will depend upon the country from which you will be mailing).

Please also send us a head shot of yourself that is in accordance with the requirements stated above so that it can be printed with your article.

### Abstracts

An abstract of your article is not required.

### Author or contact information

The author's contact information and a head shot of the author are included at the end of every article. Please note the exact information you would like to appear in this section and format it according to the requirements stated above. A short biographical sketch may precede the contact information if you provide us with the necessary information (60 words or less).

### Questions?

Magda Wojtkiewicz (Managing Editor)  
*m.wojtkiewicz@oemus-media.de*

# roots

international magazine of endodontology

## Publisher

Torsten R. Oemus  
[oemus@oemus-media.de](mailto:oemus@oemus-media.de)

## CEO

Ingolf Döbbecke  
[doebbecke@oemus-media.de](mailto:doebbecke@oemus-media.de)

## Members of the Board

Jürgen Isbaner  
[isbaner@oemus-media.de](mailto:isbaner@oemus-media.de)

Lutz V. Hiller

[hiller@oemus-media.de](mailto:hiller@oemus-media.de)

## Managing Editor

Magda Wojtkiewicz  
[m.wojtkiewicz@oemus-media.de](mailto:m.wojtkiewicz@oemus-media.de)

## Executive Producer

Gernot Meyer  
[meyer@oemus-media.de](mailto:meyer@oemus-media.de)

## Designer

Josephine Ritter  
[j.ritter@oemus-media.de](mailto:j.ritter@oemus-media.de)

## Copy Editors

Sabrina Raaff  
Hans Motschmann

## Published by

Oemus Media AG  
Holbeinstraße 29  
04229 Leipzig, Germany  
Tel.: +49 341 48474-0  
Fax: +49 341 48474-290  
[kontakt@oemus-media.de](mailto:kontakt@oemus-media.de)  
[www.oemus.com](http://www.oemus.com)

## Printed by

Löhnert Druck  
Handelsstraße 12  
04420 Markranstädt, Germany

## Editorial Board

Fernando Goldberg, Argentina  
Markus Haapasalo, Canada  
Ken Serota, Canada  
Clemens Bargholz, Germany  
Michael Baumann, Germany  
Benjamin Briseno, Germany  
Asgeir Sigurdsson, Iceland  
Adam Stabholz, Israel  
Heike Steffen, Germany  
Gary Cheung, Hong Kong  
Unni Endal, Norway  
Roman Borczyk, Poland  
Bartosz Cerkaski, Poland  
Esteban Brau, Spain  
José Pumarola, Spain  
Kishor Gulabivala, United Kingdom  
William P. Saunders, United Kingdom  
Fred Barnett, USA  
L. Stephan Buchanan, USA  
Jo Dovgan, USA  
Vladimir Gorokhovskiy, USA  
James Gutmann, USA  
Ben Johnson, USA  
Kenneth Koch, USA  
Sergio Kuttler, USA  
John Nusstein, USA  
Ove Peters, USA  
Jorge Vera, Mexico



Magda Wojtkiewicz, Managing Editor

A stylized logo for the magazine 'roots'. The word 'roots' is written in a red, serif font. To the right of the text is a grey, curved graphic element that resembles a stylized 'S' or a swoosh.

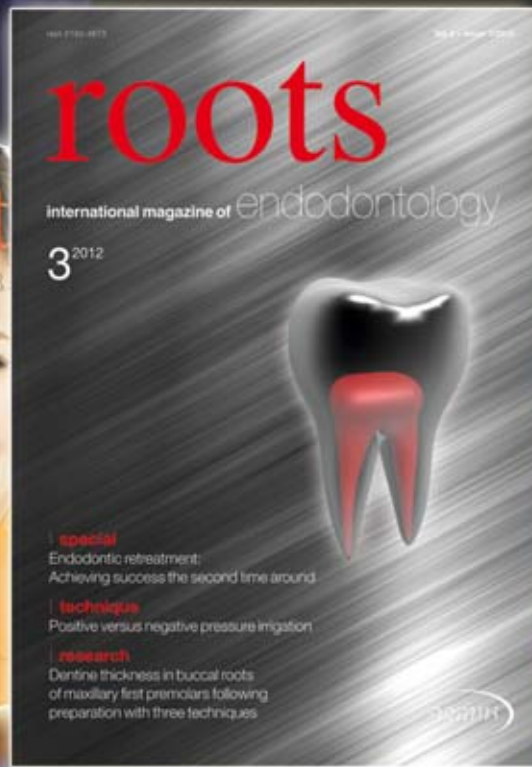
## Copyright Regulations

\_roots international magazine of endodontology is published by Oemus Media AG and will appear in 2012 with one issue every quarter. The magazine and all articles and illustrations therein are protected by copyright. Any utilisation without the prior consent of editor and publisher is inadmissible and liable to prosecution. This applies in particular to duplicate copies, translations, microfilms, and storage and processing in electronic systems.

Reproductions, including extracts, may only be made with the permission of the publisher. Given no statement to the contrary, any submissions to the editorial department are understood to be in agreement with a full or partial publishing of said submission. The editorial department reserves the right to check all submitted articles for formal errors and factual authority, and to make amendments if necessary. No responsibility shall be taken for unsolicited books and manuscripts. Articles bearing symbols other than that of the editorial department, or which are distinguished by the name of the author, represent the opinion of the afore-mentioned, and do not have to comply with the views of Oemus Media AG. Responsibility for such articles shall be borne by the author. Responsibility for advertisements and other specially labeled items shall not be borne by the editorial department. Likewise, no responsibility shall be assumed for information published about associations, companies and commercial markets. All cases of consequential liability arising from inaccurate or faulty representation are excluded. General terms and conditions apply, legal venue is Leipzig, Germany.

# roots

international magazine of endodontology



You can also subscribe via  
[www.oemus.com/abo](http://www.oemus.com/abo)

 **Subscribe now!**

I would like to subscribe to **roots** for € 44 including shipping and VAT for German customers, € 46 including shipping and VAT for customers outside Germany, unless a written cancellation is sent within 14 days of the receipt of the trial subscription. The subscription will be renewed automatically every year until a written cancellation is sent to OEMUS MEDIA AG, Holbeinstr. 29, 04229 Leipzig, Germany, six weeks prior to the renewal date.

▶ **Reply** via Fax to +49 341 48474-290 to OEMUS MEDIA AG or via E-mail to [grasse@oemus-media.de](mailto:grasse@oemus-media.de)

Last Name, First Name	
Company	
Street	
ZIP/City/Country	
E-mail	Signature

Notice of revocation: I am able to revoke the subscription within 14 days after my order by sending a written cancellation to OEMUS MEDIA AG, Holbeinstr. 29, 04229 Leipzig, Germany.

Signature
-----------

# RECIPROC®

*one file endo*

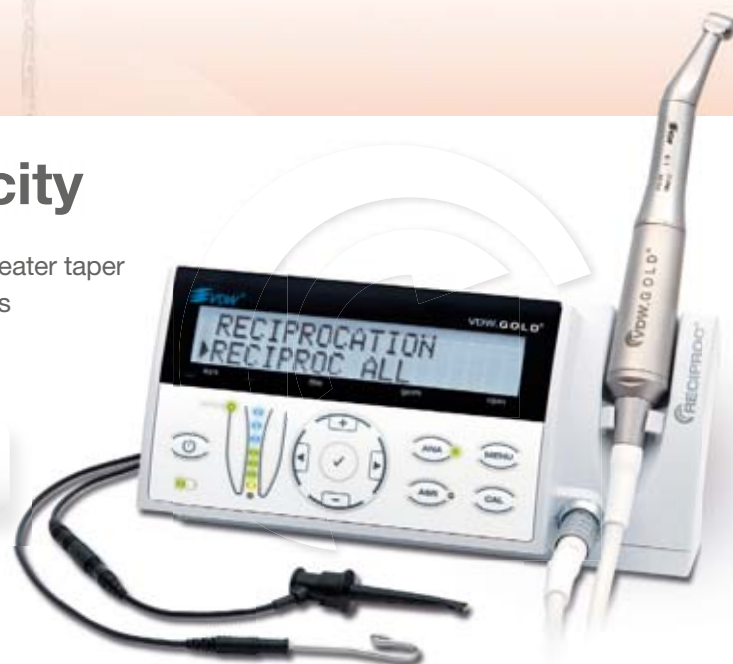

## Proficiency through Simplicity

- **Less work steps** ▶ one instrument prepares a root canal to a greater taper
- **Safe use** ▶ prepares even severely curved and narrow canals
- **Single use convenience** ▶ no cleaning and sterilising

Find more information about the RECIPROC® system on  
▶ [www.RECIPROC.com](http://www.RECIPROC.com)

VDW GmbH  
P.O.Box 830954 • 81709 Munich • Germany  
Tel. +49 89 62734-0 • Fax +49 89 62734-304  
[www.vdw-dental.com](http://www.vdw-dental.com) • [info@vdw-dental.com](mailto:info@vdw-dental.com)



**VDW.GOLD® RECIPROC®**

**Endo Easy Efficient®**

