

Simple layering technique with direct composite restorations

Author_Dr Valdas Vilkinis, Lithuania

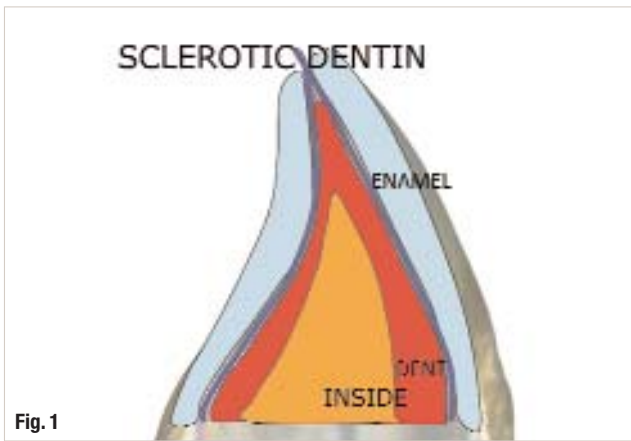


Fig. 1

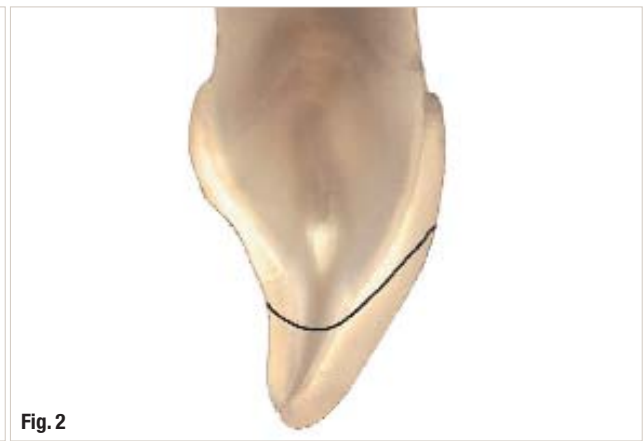

Fig. 2

For many years, the trend in restorative dentistry has been to place only one- or two-shade composite restorations in daily practice. However, with this approach, it is difficult to achieve a satisfactory aesthetic result in anterior teeth. There are great variations in colour value (lightness or darkness), depending on the patient's age and enamel thickness, which affect the overall tooth colour. It has been proven that aesthetic restorations can only be achieved if the different values of natural enamel are recreated with composite material of a similar translucency.

In recent years, anatomic layering techniques have been advocated by various clinicians aiming to achieve a more natural-looking restoration. The essence of these techniques is similar: recreate lost tooth structure layer by layer using composite materials of different opacities. Some of the techniques are rather complex, using numerous shades and layers, making them difficult to learn and use in daily practice.

In this article, a simple and predictable restorative technique will be described that concentrates

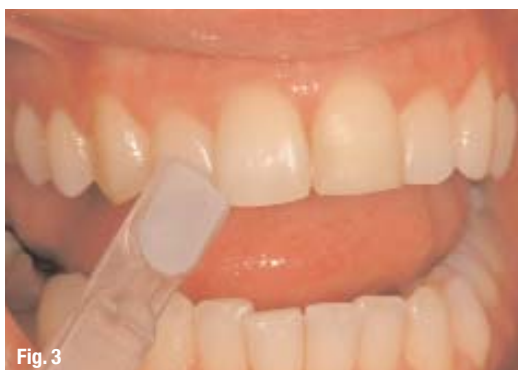

Fig. 3

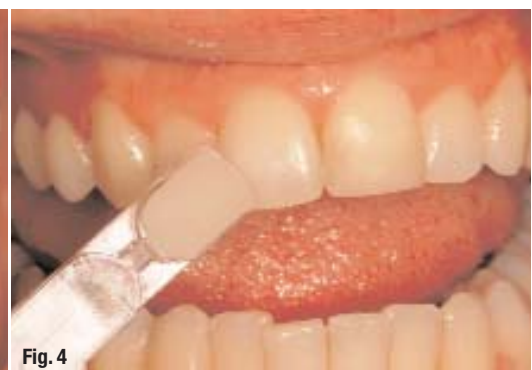
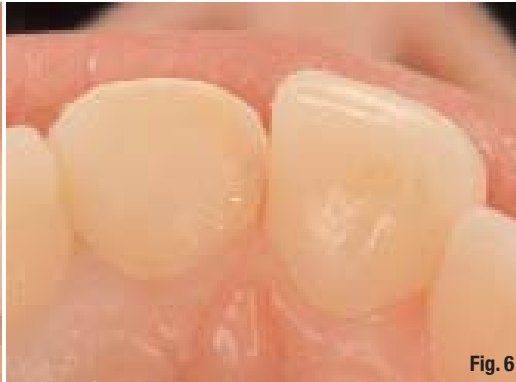
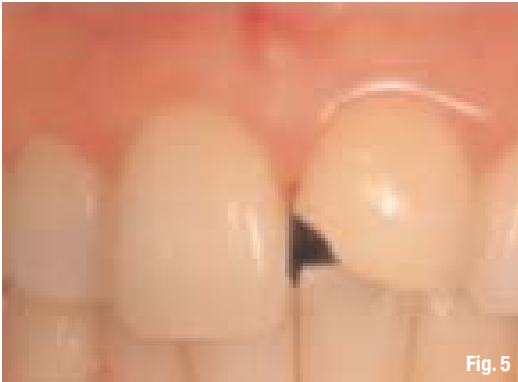Fig. 4



on the recreation of dental tissues of natural thickness, layer by layer. We believe that special attention has to be paid to restoring the enamel layer. The image below, with a cross-section of a natural incisor, demonstrates why it is so important to concentrate on recreation of this outermost layer (Figs. 1 & 2).

If you prepare the tooth with wide bevels on the labial and palatal surfaces (black imaginary preparation line) around two thirds of the restoration volume would be constituted of enamel. Enamel determines the value of the dental shade, being lighter (higher value) or darker (lower value), while the dentine determines the hue and chroma of the dental shade. Enamel becomes darker as individuals age, so it is necessary to have several translucent composite shades that can mimic the ageing enamel.

For a natural-looking anterior restoration, the most important step is the recreation of the enamel and therefore we recommend that you start by determining the value. The entire clinical procedure for this restorative technique is described step by step in the following example. Suppose the tooth #21 exhibits an inaesthetic restoration of the incisal edge, which would be replaced as follows:

_Step 1

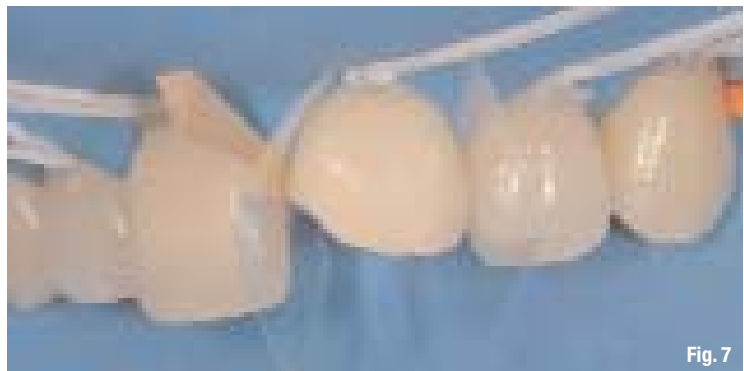When determining the value, decreasing the ambient lighting in the operatory room is advised in order to concentrate on the incisal edge and middle part of the neighbouring tooth, where the enamel is thick, allowing you to determine its colour (Fig. 3).

_Step 2

The hue and the chroma are determined from the cervical area of the crown, where the enamel is thin and the colour of the dentine shines through (Fig. 4).

_Step 3

The old restoration is removed and a wide bevel preparation has been made on the labial and palatal surfaces (flame shaped burs) (Figs. 5 & 6).

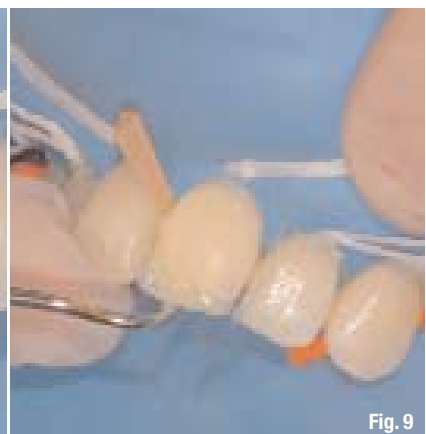
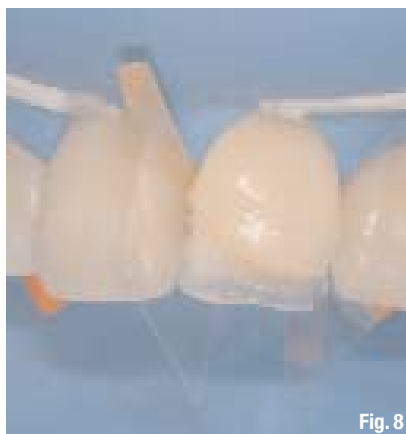

_Step 4

A rubber dam and transparent matrix strips are placed (Fig. 7).

_Step 5

Firstly, the palatal layer of a translucent composite material, G-aenial IE (GC), can be positioned by means of a silicon index or by bending the transparent matrix band strips and sculpting the palatal



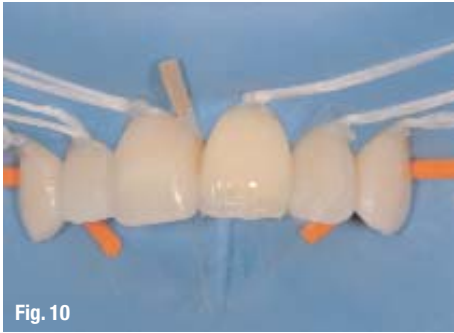


Fig. 10

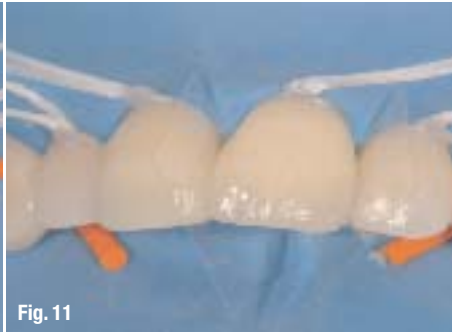

Fig. 11

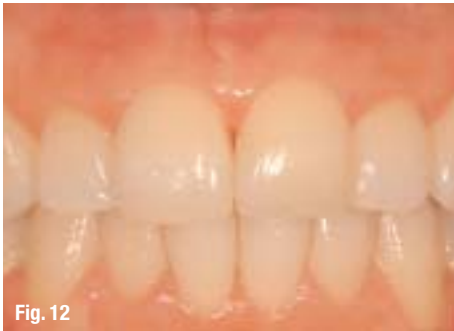

Fig. 12

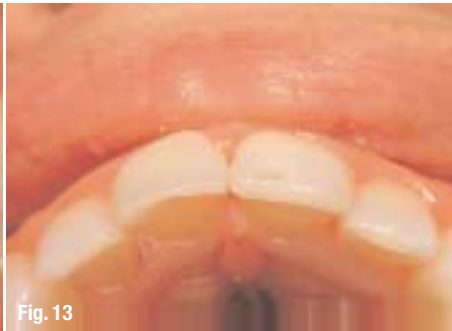

Fig. 13

surface morphology of the tooth. The final gloss was achieved by means of a Gradia Diapolisher (GC). The final image of the restoration reveals good translucency and a lifelike incisal edge (Figs. 12 & 13).

_ Conclusion

This technique uses only four or five different layers of a composite material in three or four opacities, and yields a predictable result. For this reason, it can be used in daily practice for every Class IV or broken incisal edge restoration.

The composite material blends with the natural tooth structure so well that the preparation line is invisible and the restorations are well integrated. The extent of the

anatomical layering depends on the class and size of the lesion. With small Class III and Class V restorations, it is easier to achieve good aesthetics with one or two layers of the composite material. However, with large Class IV restorations, use of this technique should be routine, along with a composite material featuring a wide range of translucent shades, natural opalescence and fluorescence to recreate a natural appearance.

surface by hand. In order to hide the transition line between the tooth and the translucent composite material, a thin band of the opaque G-aenial in special shade A02 is applied inside. This layer should not be extended too far to the end of the incisal edge or the gingival preparation line to avoid the opaque material shining through (Fig. 8).

_ Step 6

The rest of the dentine layers and mamelon structure are created with G-aenial in shade A2. This layer should also be thin and even more thinned out in the area of the incisal edge, so as not to block the natural translucency (Fig. 9).

_ Step 7

On top of this, a thin layer of very translucent G-aenial TE extending to the end of the incisal edge is placed to mimic the sclerotic dentine layer (Fig. 10). This layer helps to create a depth effect and therefore the incisal edge looks more natural. Note that, at this stage, sufficient space has been left for the thick outermost translucent layer.

_ Step 8

The outermost translucent layer is created in the same external special shade used to form the first palatal layer, G-aenial IE (Fig. 11).

_ Step 9

The restoration is polished with diamond and Sof-Lex discs (3M ESPE) to recreate the natural

_ about the author

cosmetic
dentistry



Dr Valdas Vilkinis was born in 1965 in Kaunas, Lithuania. He obtained his dentistry degree at the Kaunas University of Medicine in 1991. After graduating, he served as a clinical instructor at the Faculty of Dentistry at the

Kaunas University of Medicine until 2000. From 1993 to 1994, he undertook a postgraduate course on cariology, preventive and operative dentistry, and endodontics at the Royal Dental College of Aarhus at Aarhus University in Denmark. He defended his doctoral thesis in 2000.

He has worked in private practice in Kaunas since 1999. Dr Vilkinis has served on the editorial board of the *Journal of Oral and Maxillofacial Research* since 2010. He has held a consultancy agreement with GC Europe since 2000. He also lectures and offers hands-on courses on restorative techniques in Lithuania, Latvia, Estonia and Finland.

Cyprus
28-29/09/12

INTERNATIONAL CONGRESS IN IMPLANTOLOGY AND ESTHETIC DENTISTRY

LECTURERS

OLIVER BRIX

Germany

DANIEL EDELHOFF

Germany

EGON EUWE

Italy

VASILI KAITAS

Italy

ANGELO PUTIGNANO

Italy

ISTVAN URBAN

Hungary

PANOS BAZOS

Greece

GEORGE GOUMENOS

Greece

STAVROS PELEKANOS

Greece

ILIA ROUSSOU

Greece

Hilton Park Nicosia

Griva Dighenis Avenue,
Nicosia, Cyprus 1507

Web: nicosia.hilton.com

Information & Registration for Greece:

Omnipress

Tel: +30 210 222 2637 +30 210 213 2084

info@omnicongresses.gr

www.omnicongresses.gr www.omnipress.gr

ORGANIZED BY

FIDENTALMED Ltd

SPONSORS

**ivoclar
vivadent**

DENSPLY
FRIADENT

Hu-Friedy
How the best perform

W&H

MEDIA SPONSORS

dti Dental
Tribune
International

Smile
Dental
Magazine