

MiCD customised case-finishing concept and clinical protocol

Author_Dr Sushil Koirala, Nepal

The sooner the better: Follow early diagnosis and intervention approach.

Smile Design Wheel approach: Understand psychology, establish health, restore function and enhance aesthetics (PHFA sequences of the Smile Design Wheel—Fig. 2).

Do no harm: Minimise the possible biological cost.

Evidence-based selection: Select materials, tools, techniques and protocols based on scientific evidence.

Keep in touch: Encourage regular follow-up and maintenance.

Fig. 1

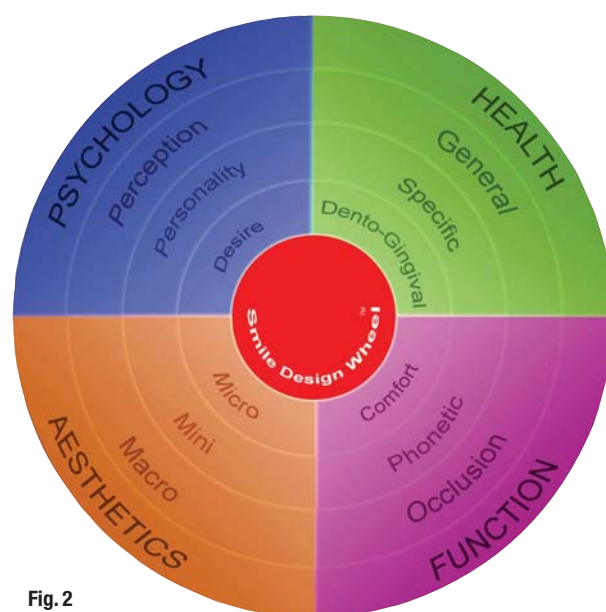


Fig. 2

Fig. 1_MiCD core principles.¹

Abstract

Fig. 2_Smile Design Wheel.

Case finishing is one of the important clinical steps in dentistry. Aesthetics, functional forces and oral health are the three fundamental components that need to be considered during case finishing. Aesthetic components are clinically visible and guided by the subjective analysis (perception) of the patient and the clinician. However, the force components are invisible,

and their adverse effects are not easily appreciated clinically until the effects become chronic. Moreover, the force components require special tools and clinical techniques to demonstrate

- I. Molar relationship: The distal surface of the distobuccal cusp of the maxillary first molar occludes with the mesial surface of the mesiobuccal cusp of the mandibular second molar.
- II. Crown angulation (mesiodistal tip): The gingival portion of each crown is distal to the incisal portion and varies with each tooth type.
- III. Crown inclination (labiolingual, buccolingual):
 - _Anterior teeth (incisors) are at a sufficient angulation to prevent overeruption.
 - _Maxillary posterior teeth: The lingual tip is constant and similar from the canine to second premolar and increased in the molars.
 - _Mandibular posterior teeth: The lingual tip increases progressively from the canines to the molar.
- IV. No rotations.
- V. No spaces.
- VI. Flat occlusal planes.

Fig. 3

Fig. 3_Andrews' six keys to occlusion.²

and measure them clinically. Therefore, the force is the most neglected component in cosmetic dentistry during case finishing.

When the force components are not addressed properly during the treatment, clinicians may encounter various clinical problems, such as damaged restorations (veneers, onlays, crowns and bridges); fractured teeth; tooth mobility; abnormal tooth wear and sensitivity; pain in the teeth, muscles and jaw joints; and increased neck pain, ear pain and headache.

In cosmetic dentistry, forces are finished based on articulating paper mark interpretation and the patient's proprioception feedback. It has been documented in the literature that articulating paper is a poor indicator of occlusal disharmony and cannot measure occlusal load and the timing of tooth contacts. The proper tools and techniques can measure precisely and objectively the necessary occlusal parameters required for finishing the force components in cosmetic dentistry.

Minimally invasive cosmetic dentistry customised case finishing integrates the concept of force finishing into the conventional case-finishing protocol of dentistry, in the hope that it will help practitioners to achieve long-term optimum results in terms of health, function and aesthetics, and high patient satisfaction with minimal biological cost.

_Introduction

The treatment modalities and protocol of health care should be aimed at the establishment of health and the preservation of the human body with its natural function and aesthetics. The comprehensive concept of minimally invasive cosmetic dentistry (MiCD) and its treatment protocol were introduced in 2009 with the basic aim of a clinician effecting optimum clinical therapeutic improvements in smile enhancement, while performing corrective procedures that require as little clinical intervention as possible.¹

The intervention level of the treatment in MiCD depends on the type of smile defects and the aesthetic needs of the patient.¹ The five core principles (Fig. 1) of the MiCD concept help to guide the clinician in achieving the desired smile enhancement with minimal clinical intervention. However, the core principles must be adapted from case selection to the final case-finishing stages. Proper case finishing is not possible without understanding its two com-

1. Centric relation theory (Schuyler):⁸ The occlusion is determined by the manner in which the ligaments brace the components of the jaw joint, particularly the rearmost hinge axis. There are various clinical techniques proposed to record centric relation (CR). The bimanual manipulation technique of Dawson,⁹ the Lucia jig and the leaf-gauge technique, as reported by Long,¹⁰ are popular techniques for positioning the mandible in CR. Prior to this, chin-point guidance and swallowing techniques were used to locate and record CR.

2. Neuromuscular theory (Jankelson):¹¹ The occlusion is determined by gravity and based on the position in which the jaw muscles are most relaxed. Trans Electric Nerve Stimulation (TENS) is employed to relax the muscles.

3. Intercuspal theory: The occlusion is determined by the habitual fit with the most tooth contact.

4. Anterior protrusive position theory (Gelb 4/7 position):¹² The occlusion is determined by the manner in which the muscles brace the components of the jaw joint. The Gelb 4/7 jaw position is found by using appliances to open the occlusion and reposition the mandible forwards and downwards of the true centre of the glenoid fossa.

Fig. 4

ponents, namely the micro-aesthetics and the occlusal forces. **Fig. 4_Jaw-position theories.**

It is, however, the force component that is often neglected, or improperly considered, in cosmetic dentistry. This article describes an MiCD customised case-finishing (MCCF) concept and protocol that respect both force and aesthetic components.

_MiCD customised case-finishing concept

Case finishing is one of the most important steps in any clinical treatment in dentistry. It has three major components that need to be considered: aesthetics, overall health and occlusal function. It is interesting to note that case finishing is viewed differently in different disciplines of dental medicine. In orthodontics,

Fig. 5_Mechanism of occlusion-force alteration.¹⁵

Clinicians can affect the occlusal forces by altering the following five areas during occlusal scheme preparation:¹⁵

1. Intercuspal position (ICP) contacts: Restorative dentists can control which teeth come into contact and the number of tooth contacts during closure in the ICP.

2. Excursive contacts: By altering the number and type of tooth contacts in eccentric excursions, restorative dentists have the ability to change muscular contraction and the distribution of forces.

3. Angle of tooth contacts: It is well known that the depth of the overbite or steepness of the angle of guidance of the teeth will have an impact on the manner in which forces are distributed.^{37,38} The angle of impact will affect not only the distribution of the force but also the ability of the muscle to contract.

4. Condylar position: The condylar position chosen will have a dramatic impact on the ability to control which teeth contact each other and when they contact.

5. Vertical dimension of occlusion: The vertical dimension of occlusion can be opened or closed when restoring at least one arch. Decreased vertical dimension increases the occlusal forces.

Fig. 5

case finishing fundamentally focuses on six keys to occlusion (Fig. 3) described by Andrews,² whereas in cosmetic dentistry, it is considered the last step of the clinical procedure and entails

Fig. 6_Force-finishing clinical facts.

1. Unilateral tooth contacts increase force in the opposite joint.
2. Bilateral even tooth contacts during ICP give more stability to the teeth, muscles and joints.
3. When the number of occluding teeth increases, the total percentage of forces to each tooth decreases.
4. The vertical forces created by tooth contacts are well accepted by the periodontal ligament, but horizontal forces cannot be effectively dissipated.³⁹ These forces may create pathological bone responses or elicit neuromuscular reflex activity in an attempt to avoid or guard against the incline plane contacts.⁴⁰ Hence, directing the occlusal force through the long axis of the tooth (axial loading) should be a goal of force finishing in the posterior teeth. Axial loading can be accomplished by cusp tip to flat surface contacts or by creating reciprocal incline contacts (also known as tripodisation).
5. The amount of the force that can be generated between teeth depends on the distance of the teeth from the temporomandibular joint, combined with applied muscular force vectors (fulcrum principle). Greater force can be applied to the posterior teeth than to the anterior teeth.⁴¹⁻⁴³ The posterior teeth function effectively when accepting the axial forces (axial loading) applied during closure of the mouth. They accept these forces well, primarily owing to their position in the arches because the force can be directed through the long axes and thus dissipated effectively.¹⁶
6. The anterior teeth are not positioned well in the arches to accept heavy axial force. They are normally positioned at a labial angle to the direction of closure, so loading them axially is nearly impossible.⁴⁴
7. The anterior teeth, unlike the posterior teeth, are in proper position to accept horizontal forces of eccentric mandibular movements.^{43,45,46}
8. The anterior teeth should immediately disclude the posterior teeth during excursive movements,^{13,14,16} resulting in friction-free excursive movements that limit wear on teeth and activate low levels of excursive muscle function.⁴⁷
9. The canines are best suited to accepting the horizontal forces that occur during eccentric movements.^{40,45,48} This is because:
 - a) They have the longest and the largest roots and therefore the best crown/root ratio.^{44,49}
 - b) They are surrounded by dense compact bone, which tolerates the forces better than the medullary bone found around the posterior teeth.⁵⁰
 - c) The canines are centred on sensory input and the resultant effect on the muscles of mastication. Apparently, fewer muscles are active when the canines contact during eccentric movements than when posterior teeth contact.^{51,52}
 - d) Lower levels of muscular activity would decrease forces to the dental and joint structures, minimising pathosis. It is therefore suggested that during force finishing of left or right laterotrusive excursive movements, canine guidance is the preferred excursive control in order to best dissipate any damaging horizontal forces. When canine guidance cannot be achieved during case finishing, the most favourable alternative to canine guidance is group function. The most desirable group function consists of the canines, premolars and sometimes the mesiobuccal cusp of the first molar. Any laterotrusive contacts other than the mesial portion of the first molar are not desirable because of the increased amount of muscle force that can be created as the contact nears the fulcrum (temporomandibular joint).¹⁶

Fig. 6

refining the micro-aesthetic components of the smile. Cosmetic dentists spend their clinical time and effort rather on the aesthetics of the final result. This is because, aesthetic components are visible to both the clinician and patient, and the outcome can thus be appreciated immediately.

However, the force components are invisible, and their negative effects are not easily appreciated clinically until the effects become chronic. Another reason that force finishing may be overlooked is that it requires special tools and clinical techniques to demonstrate and measure the force factors clinically. Therefore, force is the most neglected component in cosmetic dentistry during case finishing.

In cosmetic dentistry, forces are finished based on articulating paper mark interpretation and the patient's proprioception feedback. It has been documented in the literature that articulating paper is a poor indicator of occlusal disharmony,³⁻⁵ and studies have shown that mark size varies with the same applied load, with differing thickness of paper, surface texture of tooth and restorations, and that mark interpretation is an operator-based subjective procedure. Moreover, paper cannot measure the timing of occlusal forces.³⁻⁶

A proper case-finishing protocol must be based on both subjective and objective analysis. In order to measure the occlusal load and timing of occlusal forces, it is necessary to use proper tools, which can measure precisely and objectively the necessary occlusal parameters required in cosmetic case finishing. Computerised instrumentation to analyse occlusal forces was introduced by Tekscan Inc in 1984 as T-Scan I.⁷ Over the past 27 years, it has evolved to become a very precise diagnostic and treatment tool that is used to manage the force components in any conventional case-finishing approach to dentistry.

Every clinical case is different, as it is related to the patient's state of health, his or her functional requirements, and his or her aesthetic needs and desires. Function is directly related to the forces that a patient generates within his or her stomatognathic system. There are four different theories of occlusion. Each of these theories has their value, and treatments that are founded on each have been successful. These theories of occlusion differ in their consideration of the positioning of the jaw or temporomandibular joint during treatment, which are known as jaw-position theories (Fig. 4).

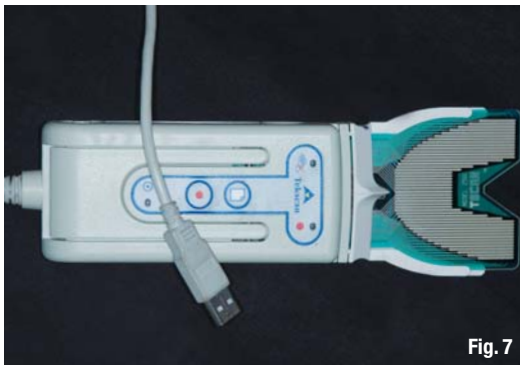

Fig. 7




Fig. 8

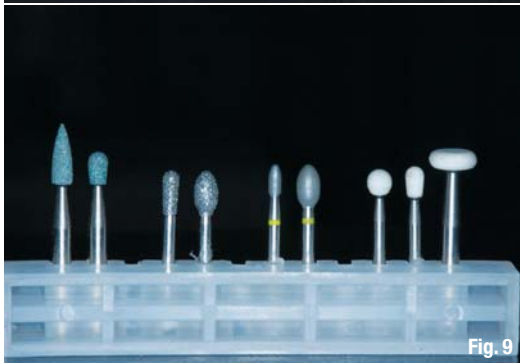


Fig. 9




Fig. 10

Fig. 7_T-Scan III: Digital occlusal analysis tool used to measure occlusal force percentage and tooth-contact timing.

Fig. 8_Articulating paper with holder, a necessary item for locating the tooth-contact point and surface area during force finishing.

Fig. 9_Dura-Green stones, Diamond points and Dura-White stones (all Shofu) can be used to contour the pressure spots selectively during force finishing.

Fig. 10_Diamond-impregnated silicone points to finish and polish the contoured tooth and restoration surfaces.

However, all of these theories agree on the following issues:

1. Teeth during mandibular closure: All teeth should occlude simultaneously in mandibular closure movement.¹³⁻¹⁶
2. Occlusal load distribution on arch: An equal percentage of occlusal force should be shared between the right and left arch halves.

3. Occlusal load on tooth: An equal percentage of occlusal force should be distributed on each tooth counterpart.

4. Excursive contacts: The anterior teeth should immediately disclude the posterior teeth during excursive movements.¹³⁻¹⁶

Based on the laterotrusive movements from centric occlusion, various concepts of functional

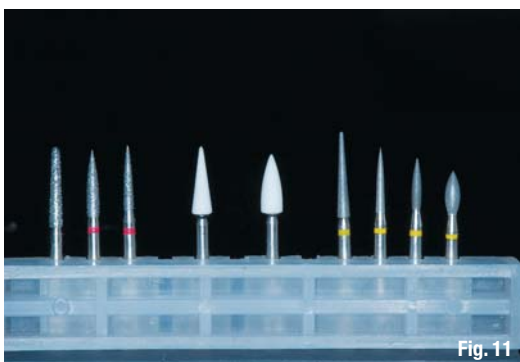


Fig. 11

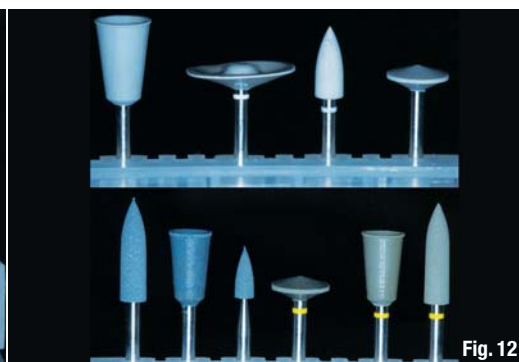

Fig. 12

Fig. 11_Diamond points and Dura-White stones to contour and texture the tooth and restoration surfaces.

Fig. 12_Diamond-impregnated silicone points to finish and polish the contoured tooth and restoration surfaces.



Fig. 13

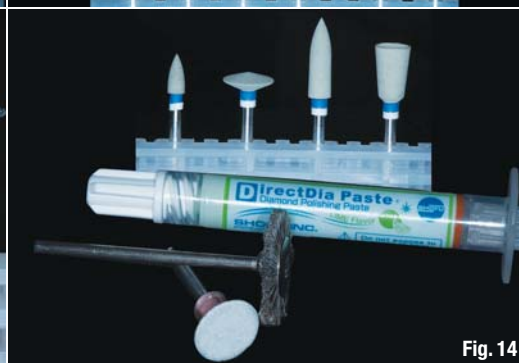

Fig. 14

Fig. 13_Super Snap disk and strips (Shofu): For labial and interdental surface finishing and polishing.

Fig. 14_Diamond paste, diamond-impregnated silicone points and a Robinson brush are used to achieve super polishing or enamel-like lustre of the restoration and tooth surfaces.

Fig. 15_Aesthetic-finishing clinical facts.

1. A rough restoration surface allows dental plaque to adhere, which can promote secondary caries and periodontal diseases.⁵⁴ As the free surface energy of uneven surfaces is lower than that of smooth surfaces, micro-organisms can easily adhere and colonise.^{55,56} As a result, susceptibility to soft-tissue infection and caries can increase.^{57,58}
2. The rough surface of the final restoration promotes marginal restoration discoloration,⁵⁹⁻⁶¹ which can decrease the aesthetic quality of the restorations.⁶²
3. Surface gloss plays an important role in the appearance of tooth-coloured restorative resins⁶³ and is a desirable characteristic that allows restorative materials to better mimic the appearance of the enamel.^{64,65}
4. A smooth and well-polished surface improves the flexural strength of the restorations and decreases abrasion of the opposing teeth.^{66,67}
5. The quality of intra-oral aesthetic finishing depends on the restorative materials used, finishing techniques, finishing tools and materials selected, and skill of the operator.
6. The quality of polishing of the restoration surfaces is vital for long-term health, function and aesthetics of the oral tissue.

Fig. 15

occlusion have been recognised and advocated: balanced occlusion,^{17,18} canine-protected occlusion,¹⁹⁻²⁶ group-function occlusion,²⁷⁻³¹ mixed canine-protected and group function,³² flat-plane (attrition) occlusion,^{33,34} biological (multi-varied, physiological) occlusion.³⁵ However, no single type of functional occlusion has been found to predominate in nature and there appears to be no scientific evidence to support one occlusal scheme over other.³⁶

Therefore, the literature and research findings, along with individual clinical experiences and accepted parameters of care, should always be considered in selecting the occlusal scheme during cosmetic dental treatment. Case-finishing procedures should not be based on a one-size-fits-all concept, and must be customised and designed according to the patient's aesthetic desires, functional requirements and physiological limits.

Fig. 16a-d_A dental loupe, T-Scan III, BioJVA (jaw vibration analysis), BioEMG (electromyography) and digital SLR camera are used as the guiding tools to evaluate the force-finishing quality.



Fig. 16a

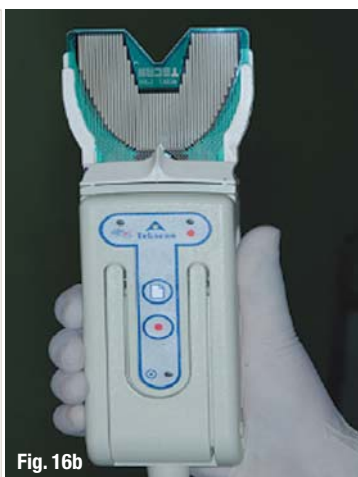

Fig. 16b



Fig. 16c



Fig. 16d

MCCF integrates the concept of force finishing into the conventional case-finishing protocol in the hope that it will help practitioners to achieve long-term optimum results in terms of health, function, aesthetics and patient satisfaction with minimal biological cost. MCCF consists of three clinical components:

- _force finishing;
- _aesthetic finishing; and
- _finishing evaluation.

_Force finishing

The concept of force finishing is new in cosmetic dentistry and should not be confused with the conventional occlusal equilibration or occlusal adjustment process. The concept of force finishing is based on the universal principles of force balance and force loading timing during dynamic occlusion. In order to achieve precise force finishing in restorative dentistry, clinicians need to plan the occlusal goals. This is required because the force-finishing steps alone cannot refine the major occlusal discrepancies of the patient.

Hence, proper jaw positioning, angulation and establishment of tooth form (natural anatomy) must be completed before proceeding to

MCCF. There are five areas of the occlusal scheme in which clinicians can affect the force components (Fig. 5).

The force-finishing component of MCCF requires the use of digital occlusal technology that can measure precisely and objectively clinical occlusal force data, while displaying the findings for clinical interpretation and treatment.

The objective and precise clinical data helps clinicians to achieve tooth-contact forces and tooth-contact timing sequences that are preservational, rather than destructive, regarding the final case result. However, in cosmetic dentistry, the role of force finishing is generally overlooked, minimised or ignored.

The following are some of the clinical problems that clinicians encounter when they ignore or are unable to harmonise occlusal forces after treatment:

- _ damaged restorations (veneers, onlays, crowns, bridges);
- _ fractured teeth;
- _ tooth mobility;
- _ abnormal tooth wear and sensitivity;
- _ pain in the teeth, muscles and jaw joints; and
- _ increased neck pain, ear pain and headache.

In order to achieve the quality force-finishing results in dentistry, the following clinical conditions must be fulfilled during the force-finishing process:

- _ even and simultaneous contacts of all teeth during mandibular closure;
- _ distribution of nearly equal force percentage between the right and left arch halves;
- _ distribution of more tooth-contact forces on posterior teeth, less on premolar teeth, with only light anterior contacts;
- _ the centre of force (COF) should be in the middle of the distribution of all contacting teeth;
- _ the anterior teeth should immediately disclude the posterior teeth during excursive movements.¹³⁻¹⁶

Optimally, after proper force finishing, all teeth should come into contact with one another at about the same time and with harmonised occlusal forces and measurably short disclusion timing. When this does not occur, the clinical case is considered to be unbalanced and poorly force finished. Force-finishing clinical facts are shown in Figure 6.

Clinical steps	Finishing tools	Guiding tools
<p>Step I: Aesthetic finishing</p> <p>Aesthetic contouring:</p> <ol style="list-style-type: none"> 1. Reproduce natural size, shape and other details of the tooth form. 2. Re-establish normal and functional contact with adjacent and opposing teeth. <p>Finishing:</p> <ol style="list-style-type: none"> 1. Establish an even, well-adapted junction between the tooth surface and the restorations. <p>Aesthetic touch-up:</p> <ol style="list-style-type: none"> 1. Achieve natural surface details through texture, grooves, pits and other special surface effects. <p>Polishing:</p> <ol style="list-style-type: none"> 1. Pre-polishing: Remove the remaining surface scratches after the aesthetic touch-up process. 2. Polishing: Establish a blemish-free and smooth surface with no visible scratches on the restoration. 3. Super polishing: Polish restoration to enamel-like lustre. 	<p>Aesthetic-finishing kit</p>	<p>_ Dental loupe _ Digital images _ Digital X-ray (to check restoration marginal fit, finishing and overhangs)</p>
<p>Step II: Finishing evaluation</p> <ol style="list-style-type: none"> 1. Evaluate aesthetics, health (dental and gingival) and comfort status. 2. Document the final case-finishing results digitally. 	<p>Aesthetic-finishing kit</p>	<p>_ Dental loupe _ Digital images</p>

Table I

_ Aesthetic finishing

The aesthetic outcome is one of the major concerns of all patients seeking cosmetic dental treatment. The aesthetic-finishing process in cosmetic dentistry involves establishing high surface gloss and creating proper micro-smile aesthetic characteristics. These include proper tooth-size ratio, axial inclination, open incisal embrasures, proper connector location, proper contact-point progression, surface micro-texture, surface gloss or lustre, inciso-gingival shade progression, and special surface effects on the facial surfaces.

Additionally, gingival aesthetic characteristics to incorporate during case finishing are the control of tissue contour, embrasure heights, gingival zenith, and the establishment of uniform height (position or level) of the tissue around all the restorations.

In order to improve the practicality of clinical aesthetic case-finishing procedures, the procedures are divided into four clinical steps:

_ Aesthetic contouring: The restoration is grossly reduced for the reproduction of the natural size, shape and other details of the tooth form.⁵³ Re-establishing the contact with ad-

Table I_Type I MiCD case-finishing protocol.

Clinical steps	Finishing tools	Guiding tools
<p>Step I: Force finishing</p> <p>During centric closure movement:</p> <ol style="list-style-type: none"> 1. Bring all the teeth into occlusal contact by selective contouring. 2. Measure tooth-contact forces and timing sequences on the restorations. 3. Adjust early contacts to delay them from contact, which improves contact simultaneity. 4. Adjust high contact forces on the restoration. 5. Adjust tooth-contact forces on restoration selectively until force equality is established throughout. <p>During excursive movements:</p> <ol style="list-style-type: none"> 1. Check for prolonged frictional contacts on the restorations during right, left and protrusive movements. 2. Remove all prolonged frictional contacts on the restorations. 	Force-finishing kit	<ul style="list-style-type: none"> _ T-Scan III _ Articulating paper
<p>Step II: Aesthetic finishing</p> <p>Aesthetic touch-up:</p> <ol style="list-style-type: none"> 1. Achieve natural surface details through texture, grooves, pits and other special surface effects. <p>Polishing:</p> <ol style="list-style-type: none"> 1. Pre-polishing: Remove the remaining surface scratches after the aesthetic touch-up process. 2. Polishing: Establish a blemish-free and smooth surface with no visible scratches on the restoration. 3. Super polishing: Polish restoration to enamel-like lustre. 	Aesthetic-finishing kit	<ul style="list-style-type: none"> _ Dental loupe _ Digital images _ Digital X-ray (to check restoration marginal fit, finishing and overhangs)
<p>Step III: Finishing evaluation</p> <ol style="list-style-type: none"> 1. Evaluate aesthetics, health (dental and gingival) and comfort status. 2. Confirm force-finishing end-results. 3. Document the final case-finishing results digitally. 		<ul style="list-style-type: none"> _ Dental loupe _ Digital images _ T-Scan III

Table II

Table II_Type II MiCD case-finishing protocol.

adjacent opposing teeth to a normal and functional form is achieved in this step.⁵³

_Finishing: This is a finishing process to establish an even, well-adapted junction between the tooth surface and the restorations.

_Aesthetic touch-up: Necessary minor adjustments to achieve natural surface details through texture, grooves, pits and other special surface effects.

_Polishing: This step entails smoothing restorations to an enamel-like lustre. For clinical convenience, this process can be further divided into three steps:

- a) pre-polishing: removing the remaining surface scratches from the aesthetic touch-up process;
- b) polishing: achieving blemish-free and smooth surfaces with no visible scratches;
- c) super polishing: creating enamel-like lustre or gloss.

Aesthetic-finishing clinical facts are shown in Figure 15.

_Finishing evaluation

Post-operative clinical evaluation is one of the fundamental requirements of the keep in touch principle of the MiCD treatment protocol.¹ Generally one week after the case finishing, the case should be re-evaluated in terms of health, comfort and aesthetics through clinical examination, digital images and other necessary guiding tools. The end-result of force finishing should be re-confirmed before final case documentation.

_MiCD customised case-finishing protocol

Based on the patient's aesthetic wishes and level of sensitivity towards the occlusal force components (tooth-contact forces and timing sequences), MCCF can be divided into three clinical types:

_Type I: In cases in which forces are not part of creating the aesthetic case changes, as well as cases of non-load-bearing anterior and posterior restorations, tooth-whitening procedures, reductive and additive contouring (both the teeth and gingival tissues) if correction does not alter the existing occlusal scheme, these cases are generally finished according to the type I MCCF protocol (Table I).

_Type II: When aesthetic cases are sensitive to tooth-contact forces because a major restoration is being fabricated on the load-bearing areas of the anterior or posterior teeth (as when utilising inlays, onlays, overlays, crowns and bridges, veneers, dentures, or performing a re-restoration of frequently fractured restorations), force-finishing procedures should precede aesthetic case finishing. This will improve the long-term clinical success of the restoration and create effective functional health. Force finishing in type II cases requires the use of digital technology (T-Scan III) that can measure and display the underlying tooth-contact forces precisely and objectively. The type II MCCF finishing protocol is shown in Table II.

_Type III: Complex aesthetic cases (full-mouth restoration, orthodontic treatment, implant restoration, cases with para-functional habits, restorations that alter the anterior guidance, cases with a known history of TMD symptoms) require significant tooth-contact force and

timing management. In these complex restorative cases, force finishing is performed before aesthetic finishing is accomplished in order to achieve enhanced occlusal function and ideal aesthetics, combined with teeth, muscle and joint harmony. The type III MCCF protocol is shown in Table III.

All three types of force finishing should always be in harmony with the aesthetic results. After force finishing, the micro-aesthetic elements should be re-examined, and cases should be completed with the necessary aesthetic touch-ups, and super polishing of all restorations. It should be remembered that the force-finishing process should be followed by aesthetic finishing to complete the case successfully.

Conclusion

In the performance of cosmetic dentistry, the force components are frequently neglected or misunderstood. Therefore, the physical strength of the tooth-coloured restorative materials is still an important topic in cosmetic dentistry. The restorative materials chosen are often much stronger than the natural teeth because the clinician hopes the materials selected will overcome potential fracture of the restorations.

However, it is necessary to understand that the highly concentrated occlusal force locations within the occlusal scheme may not always fracture the restorations, but will create other problems with the teeth, muscles and/or joints in some patients. Therefore, if the clinician overcomes fracture of the restorations through material choice, he or she may actually be ignoring the underlying force factors.⁶⁸

It is to be noted that whatever the theory or concept of occlusal scheme selected during the treatment procedure, the role of MCCF is paramount to achieving long-term optimum results in terms of health, function, aesthetics and high patient satisfaction with minimal biological cost.

Editorial notes: A complete list of references is available from the publisher.

The author does not have any conflict of interest regarding the products mentioned in this article. This article originally appeared in the MiCD Clinical Journal, 2011 Dec-Mar;01(1):32-42.

Reprinted with permission from Vedic Institute of smile Aesthetics (VISA)

Clinical steps	Finishing tools	Guiding tools
<p>Step I: Force finishing</p> <p>During centric closure movement:</p> <ol style="list-style-type: none"> 1. Bring all the teeth into occlusal contact by selective contouring. 2. Measure tooth-contact forces and timing sequences. 3. Adjust early high-pressure points, one by one. 4. Equalise right and left arch-half force percentage. 5. Distribute nearly equal force percentage on each posterior tooth counterpart, one by one (i.e. left first molar region should nearly equal right first molar region force percentage). 6. Keep light tooth contacts (lower force percentage) in the anterior region. 7. Check the location of COF and bring it down the midline and to the centre of the distribution of all contacting teeth. 8. Achieve simultaneous contacts of all teeth during mandibular closure. 9. Adjust tooth-contact timing of implant restorations selectively to delay them from making initial occlusal contact until after the nearby (to the implants) natural teeth make moderate occlusal contact. <p>During excursive movements:</p> <ol style="list-style-type: none"> 1. Check for prolonged frictional contacts on the restorations during right, left and protrusive movements. 2. Remove all prolonged frictional contacts on the restorations so that the disclusion time is reduced. 3. Achieve canine-protected guidance whenever possible. 	Force-finishing kit	<p>_ T-Scan III</p> <p>_ Articulating paper</p>
<p>Step II: Aesthetic finishing</p> <p>Aesthetic touch-up:</p> <ol style="list-style-type: none"> 1. Achieve natural surface details through texture, grooves, pits and other special surface effects. <p>Polishing:</p> <ol style="list-style-type: none"> 1. Pre-polishing: Remove the remaining surface scratches after the aesthetic touch-up process. 2. Polishing: Establish a blemish-free and smooth surface with no visible scratches on the restoration. 3. Super polishing: Polish restoration to enamel-like lustre. 	Aesthetic-finishing kit	<p>_ Dental loupe</p> <p>_ Digital images</p> <p>_ Digital X-ray (to check restoration marginal fit, finishing and overhangs)</p>
<p>Step III: Finishing evaluation</p> <ol style="list-style-type: none"> 1. Evaluate aesthetics, health (dental and gingival) and comfort status. 2. Confirm force-finishing end-results. 3. Document the final case-finishing results digitally. 		<p>_ Dental loupe</p> <p>_ Digital images</p> <p>_ T-Scan III</p> <p>_ JVA</p> <p>_ EMG</p>

Table III

_ about the author



Dr Sushil Koirala is the Chairman of and chief instructor at the Vedic Institute of Smile Aesthetics. He maintains a successful private practice in Kathmandu, Nepal. He can be contacted at skoirala@vedicsmile.com.

Table III_Type III MiCD case-finishing protocol.