

Lithium disilicate— An effective solution for aesthetically demanding indications

Author_Dr Igor Ristić, Serbia

Fig. 1 _Pre-op view of patient's smile.

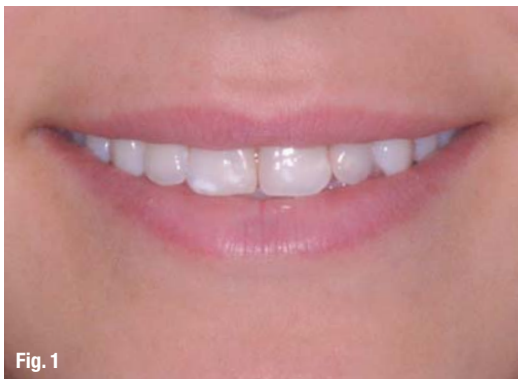
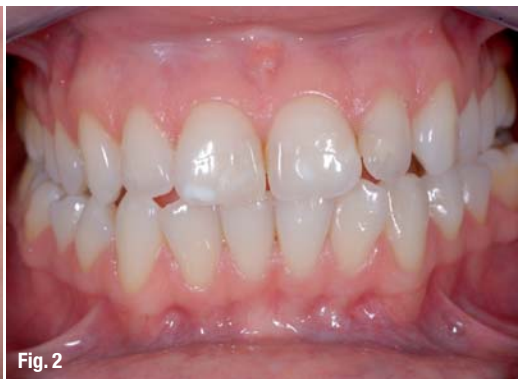
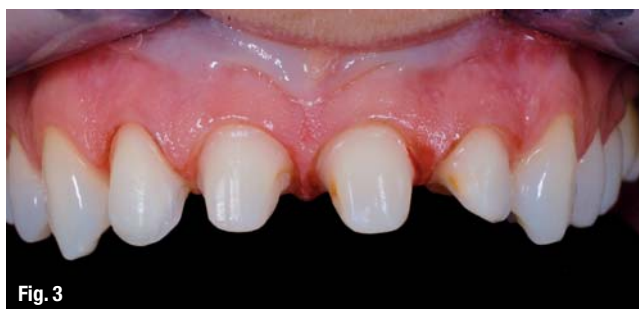Fig. 2 _Stained teeth, old composite fillings and rotated teeth were the patient's major complaints.



At a time when dentists and patients are both seeking more conservative restoration, as well as maximum transformation regarding individual teeth and whole-mouth restoration, lithium disilicate ceramic material represents a truly unique material and is almost certainly the next big thing in aesthetic dentistry!

Owing to its high resistance to fracture (400 MPa), optical properties similar to natural tooth structure and the ability to be pressed very thinly in particular, such material has a unique potential for the manufacture of minimally invasive restorations like ultra-thin crowns and veneers.

Fig. 3 _Prepared teeth for two crowns and two veneers.



Now, skilled dental technicians can press lithium disilicate restorations as thin as 0.3 mm with excellent aesthetic results. If we add to that experience and knowledge of the material, such restorations could be considered perfect in terms of appearance, durability and ability to blend with the existing intact teeth.

Unfortunately, when the press ceramic was launched it caused some scepticism and reluctance within the profession, primarily owing to the high biological cost of such restorations, since healthy tooth structure was reduced by up to 2 mm, which eventually led to overly aggressive preparation. Preparation of the lower incisors according to the manufacturer's instructions was often on the verge of devitalising the tooth.

Owing to its special properties, Lithium Disilicate (IPS e.max Press, Ivoclar Vivadent) has completely changed the concept of use for pressed ceramics and allows for extremely conservative preparation. IPS e.max Press is an aesthetic ceramic system based on lithium disilicate, with a high resistance to fracture, that can be cemented with adhesive technique

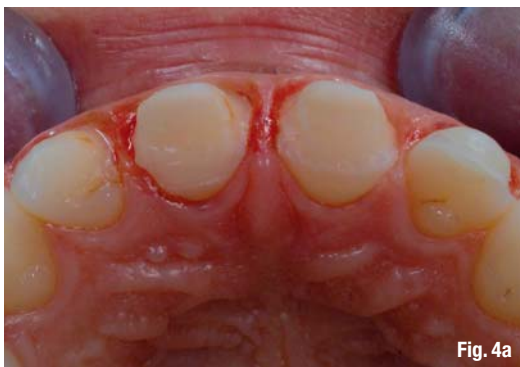

Fig. 4a

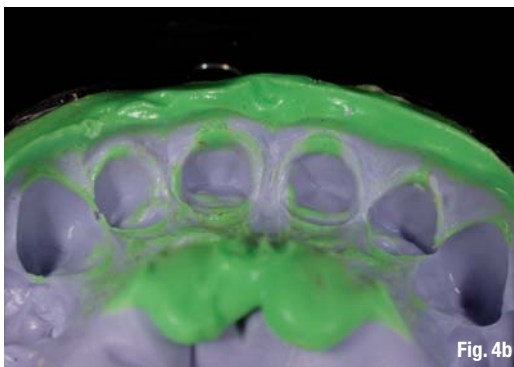


Fig. 4b

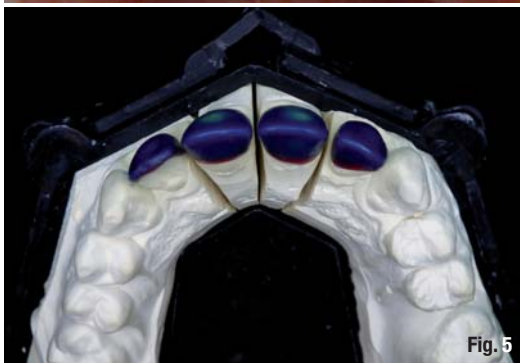


Fig. 5

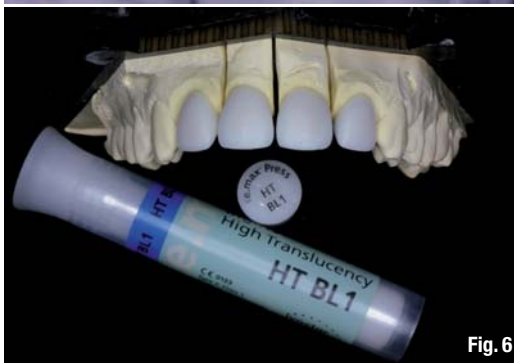

Fig. 6

Fig. 4a_ Conservative preparation on palatal side for pressed crowns.
Fig. 4b_ Impression with A-silicone (Flexitime Putty and Flexitime Correct Flow).
Fig. 5_ Ceramic cores for the restorations were made of wax patterns created on stone model in full volume.
Fig. 6_ Lithium disilicate cores were pressed from HT BL1 ingot.

or self-etch composite cements—such techniques are better known in the literature as "conventional". Full-contour restorations can be created and characterised with staining or layered with IPS e.max Ceram ceramic.

_ Case report

The patient presented to our practice with a simple request: "I don't like the stains on my teeth and I would like to correct the rotated tooth #22 to look like #12".

The examination established that teeth #11 and 21 had stains most likely caused by fluorosis, visible under a partially delaminated composite layer, which was previously added by another dentist in an attempt to mask the discoloration. Tooth #22 was rotated with a huge mesial composite filling (Figs. 1 & 2). A seemingly nice and relatively harmonious smile, upon further inspection, revealed a number of composite fillings on the proximal palatal side of the central incisors, which limited the possibility of restoration with veneers on these teeth.

After consultation with the laboratory and ceramist, we decided to use IPS e.max Press to produce crowns for teeth #11 and 21, with preparation as conservative as possible, and a thin, V-shaped vestibular palatal veneer on tooth #22, which was to simultaneously be rotated to correct and compensate for the missing natural tooth structure restored with composite. There was a need for

preparation only on the labio-distal tooth surface after removing the mesial composite fillings. A veneer was made for tooth #12.

After reviewing the composite fillings on the centrals, the teeth were prepared palatally with a supra-gingival finish line and minimal removal of the tooth structure. Teeth #12 and 22 were very conservatively prepared, owing to the characteristics of e.max Press materials the advantages and characteristics of e.max Press materials.

Temporary restorations were fabricated from composite material and cemented with the spot-etch technique, in order to allow the fit of the definitive restoration. Impression taking was done with one stage putty/wash technique using highly accurate Flexitime Putty and Flexitime Correct Flow materials (both Heraeus; Fig. 4b).

The surface of the prepared teeth was healthy, with natural colour and no discoloration, which allowed us to use the highly translucent IPS e.max Press HT BL1 ingot (Fig. 6). The copings were pressed from lithium disilicate material and fired in a special furnace.

Fig. 7_ Superb nature-like optical performance of lithium disilicate e.max system.

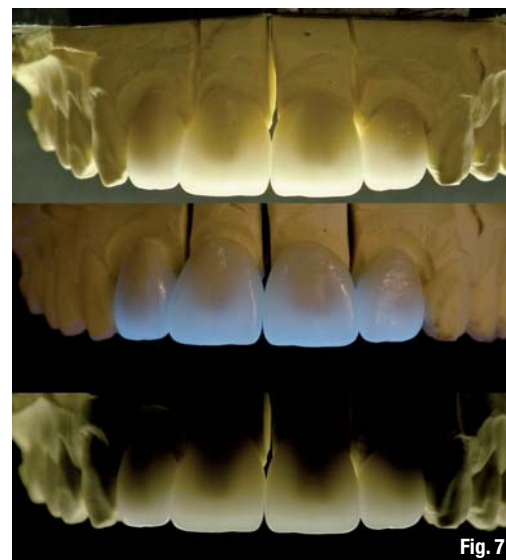

Fig. 7

Fig. 8_E.max pressed core veneered with e.max Ceram.

Fig. 9_Restorations could be as thin as 0.4 mm.

Fig. 10_Restorations immediately after cementation.

Fig. 11_The restorations blended perfectly into the natural dentition.

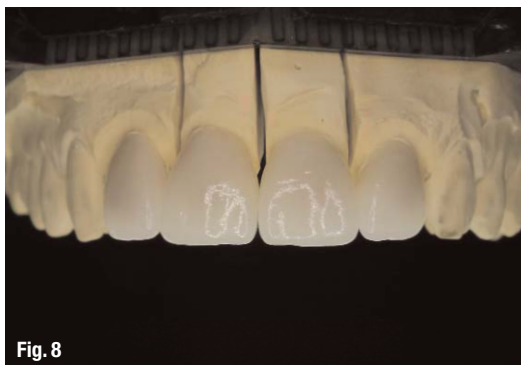

Fig. 8

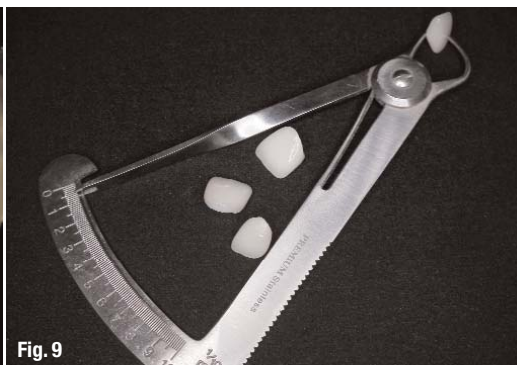

Fig. 9

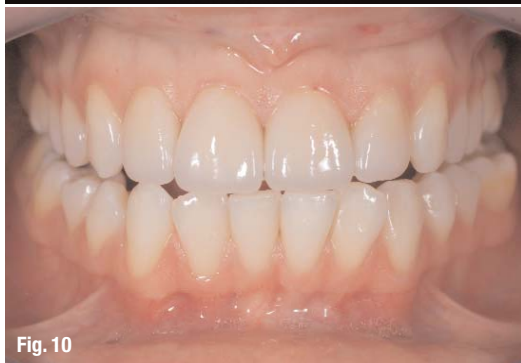

Fig. 10

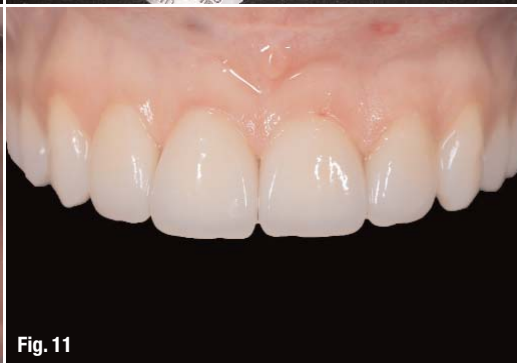

Fig. 11

Given that there was a demand for the highest level of aesthetics in this case, the ceramist decided that all four restorations were to be made using the cut-back technique on pressed copings and veneers in order to achieve a high degree of individualisation using the Incisal materials of the IPS e.max Ceram range.

Once received from the laboratory, the restorations were treated with hydrofluoric acid gel and a silane agent. The restorations were tried in before glazing and then cemented after the final check (Fig. 10). For adhesion, we used the resin cement Variolink II (Ivoclar Vivadent) in a transparent colour without a catalyst, taking advantage of light only polymerisation.

The perfectly fitting crowns and veneers, even prior to cementation, indicated that we had met all the preconditions for a successful future adaptation of the restorations to the soft tissue (Fig. 11).

_Conclusion

The aesthetic result and the optical properties of the overall restoration have demonstrated that when it is necessary to combine veneers and crowns at a minimal cost to the natural tooth structure, the best choice is the IPS e.max Press system, owing to its superb clinical performance, physical properties and reliability. With that knowledge, the treatment team is relieved of the dilemma of whether different thicknesses of the final restorations will yield a different aesthetic result.

The whole system has a much broader philosophy, that no matter what the base is (zirconia, metal substructure, pressed core), it does not affect the final result—a predictable aesthetic reconstruction of different core materials in a single arch.

_Acknowledgement

I would like to acknowledge Andreja Protic for the fabrication of the ceramic restorations, laboratory photographs and material for this article.

_about the author	cosmetic dentistry
	<p>Dr Igor Ristić, after graduating in 1996, searched for the new frontiers and emerging trends in aesthetic dentistry and implantology. In 2001, he established his private practice, the Centre for Aesthetic Dentistry and Implantology in Belgrade, Serbia. He loves teaching treatment planning and various clinical procedures nationally and internationally, through lectures, hands-on training and workshops with a focus on all-ceramic and implant restorative procedures. He is a certified member of the European Society of Cosmetic Dentistry board and an affiliate member of the International Academy for Dental-Facial Esthetics. He can be contacted at igor@iristic.com.</p>



1st ASIA - PACIFIC EDITION 7th CAD/CAM & Computerized Dentistry International Conference

06 - 07 October 2012, Marina Bay Sands Hotel, SINGAPORE



THE STARS IN COMPUTERIZED DENTISTRY

NEW

Theatre Presentation

One-visit chairside dentistry:
How to make CAD/CAM
Restorations Esthetic
and Durable in Clinical Practice



*Dr. Michael Dieter,
Germany*



*Joerg Voegt,
Germany*



*Dr. Andreas Kurbad,
Germany*

- Computer Navigated Implantology
- Esthetic Engineering



*Dr. Simon Smyth,
UK*

- Everyday CAD/CAM Usage: Preparation, Practicality & Possibilities, What Benefits You and Your Practice
- Further Possibilities of CAD/CAM: One Visit Smile Makeovers and Permanent Bridges Chairside



*Dr. med. dent. Peter Gehrke,
Germany*

- Two-Piece CAD/CAM Zirconia Implant Abutments
- Optimizing Implant Function & Esthetics at the Perio-Prosthetic Interface: The Role of the Superstructure

PLATINUM SPONSOR



GOLD SPONSOR



OFFICIAL SPONSORS



ORGANIZED BY



PROUD SUPPORTER



HELD IN



SUPPORTED BY



OTHER INDUSTRY PLAYERS



www.capp-asia.com

www.facebook.com/cappasiapacific