

cosmetic dentistry

— beauty & science

2²⁰¹²

| **special topic**

Clinician's guide
for porcelain laminate veneers

| **research**

Dentine hypersensitivity: Simplified

| **case report**

Aesthetics and function:
Orthodontic–surgical collaboration
as a key to success

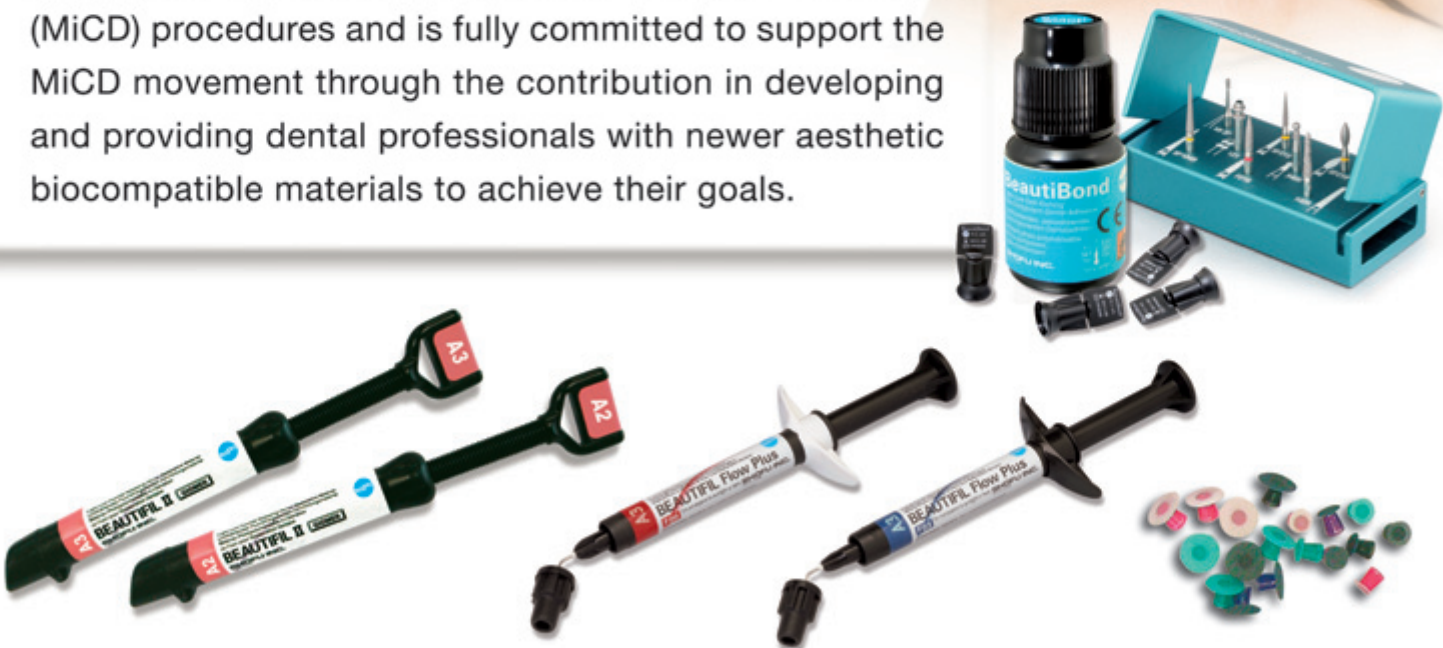

Adopt the trend...



Minimally Invasive
Cosmetic Dentistry

SHOFU recognizes the development of new clinical techniques in minimally invasive cosmetic dentistry (MiCD) procedures and is fully committed to support the MiCD movement through the contribution in developing and providing dental professionals with newer aesthetic biocompatible materials to achieve their goals.



For more information, simply contact your nearest **SHOFU** dealer.



SHOFU INC. SINGAPORE BRANCH

Tel (65) 6377 2722 Fax (65) 6377 1121 eMail mailbx@shofu.com.sg website www.shofu.com.sg

Dear Reader,

_Welcome to this year's second edition of **cosmetic dentistry**!

As the Co-Editor-in-Chief of the official journal of the Asian Academy of Aesthetic Dentistry (AAAD), I am excited to invite you to the 12th AAAD and 23rd Japan Academy of Esthetic Dentistry (JAED) joint meeting in Sapporo, Japan, from 20 to 22 July 2012. We are expecting another wonderful meeting that will bring all our academy members together in sharing precious knowledge, expertise and friendship.

The JAED, which has nearly 4,000 members, has set a beautiful location for the meeting: Sapporo, which attracts many tourists for the Sapporo Summer Festival, a cheerful event that takes place in the heart of the city. The organising committee has put great effort into the scientific programme, with an emphasis on integrating aesthetic dentistry to meet the patient's needs and desires. Among the invited speakers, Dr Marcos Vargas, professor at the University of Iowa, will present on anterior composite restorations; Dr Mark Latta, professor and Dean of the Creighton University School of Dentistry, on posterior composite restorations; Dr Wynn Okuda, past President of the American Academy of Cosmetic Dentistry (AACD), on contemporary cosmetic dentistry in the daily practice; and me, on how to maximise aesthetic success with tooth whitening.

A new introduction to the conventional joint meeting this year is the academy presidents' lecture section, with Dr Hisashi Hisamitsu representing the AAAD, Dr Akira Senda the JAED, and Dr Ronald Goodlin the AACD.

One of the major highlights will be the special lectures by country representatives of our AAAD. We are all anticipating a great meeting with considerable active participation by all of our academy members!

Our second edition of **cosmetic dentistry** is a continuum of the first edition, which focused on the minimally invasive cosmetic dentistry concept. The clinical articles and case reports beautifully illustrate how to formulate a smile design and provide step-by-step procedures for successful porcelain laminate veneers.

I would like to thank our readers, authors, supporting companies and the **cosmetic dentistry** team for their continuous support in making this magazine extraordinary, and I am confident that you will enjoy this issue!

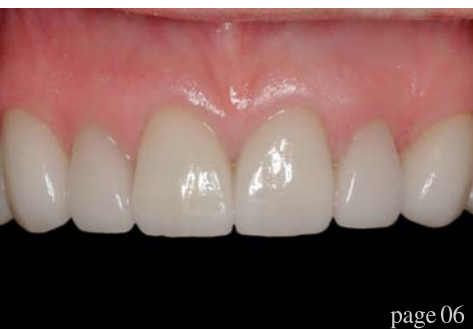Yours faithfully,



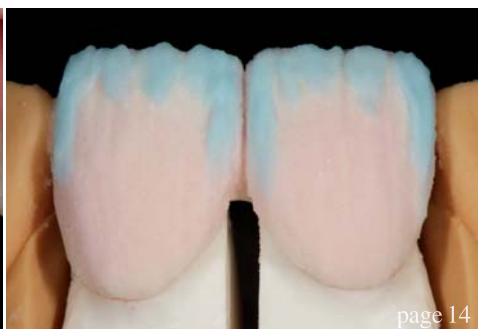Dr So Ran Kwon
Co-Editor-in-Chief
President, Korean Bleaching Society
Seoul, Korea



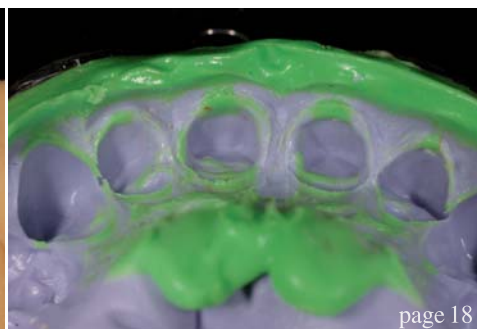
Dr So Ran Kwon
Co-Editor-in-Chief



page 06



page 14



page 18

| editorial

03 Dear Reader

| Dr So Ran Kwon, Co-Editor-in-Chief

| special topic

06 The five-phase key to the Pros GPS:
Clinician's guide for porcelain laminate veneers

| Dr Seok-Hwan Cho

14 On smile design: Conservatively placed
IPS d.SIGN veneers to correct a diastema

| Harald Heindl & Dr Stephen Phelan

18 Lithium disilicate—An effective solution
for aesthetically demanding indications

| Dr Igor Ristić

| research

22 Dentine hypersensitivity: Simplified

| Dr Fay Goldstep

| case report

26 Aesthetics and function: Orthodontic–surgical
collaboration as a key to success

| Drs Martin Jaroch & Friedrich Bunz

32 Ethical smile design with the Inman Aligner—
A case study

| Dr Andrew Wallace

| industry news

36 CLEARFIL S³ BOND PLUS:
High-tech and high speed for high performance

| Kuraray

| news

38 Mission: Passion, ethics and professionalism

| Letter from Dr Luca L. Dalloca, new President of ESCD

| meetings

40 International Events

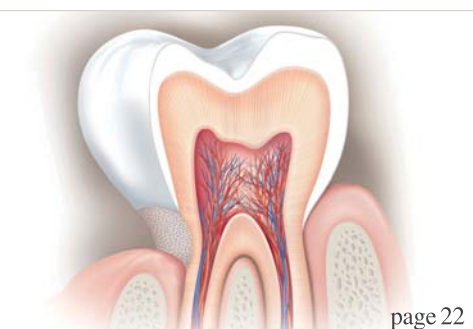
| about the publisher

41 | submission guidelines

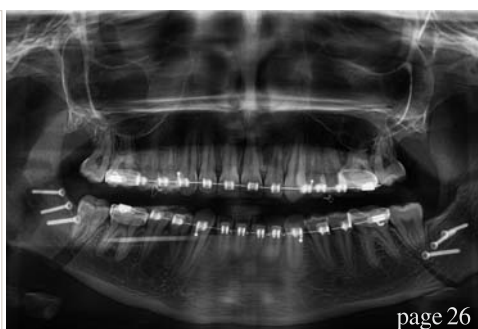42 | imprint



Cover image courtesy of BestPhotoStudio.



page 22



page 26

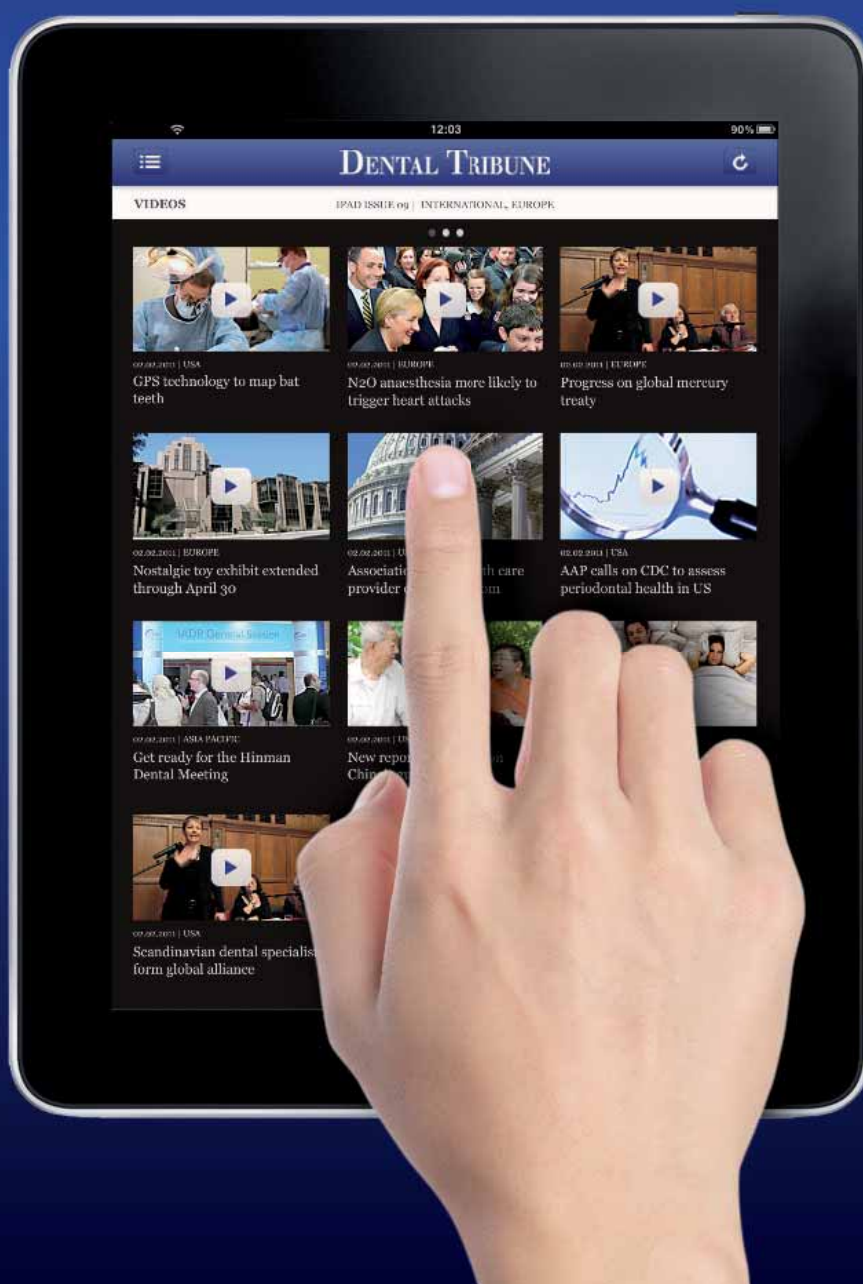

page 40

Dental Tribune for iPad – Your weekly news selection

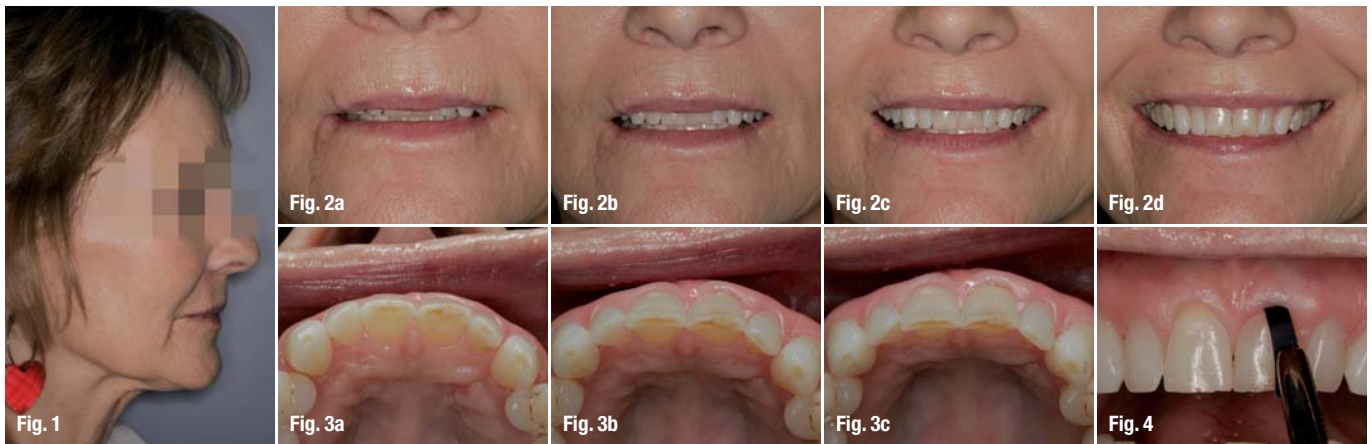Our editors select the best articles and videos from around the world for you every week. Create your personal edition in your preferred language.

ipad.dental-tribune.com



The five-phase key to the Pros GPS: Clinician's guide for porcelain laminate veneers

Author_Dr Seok-Hwan Cho, USA

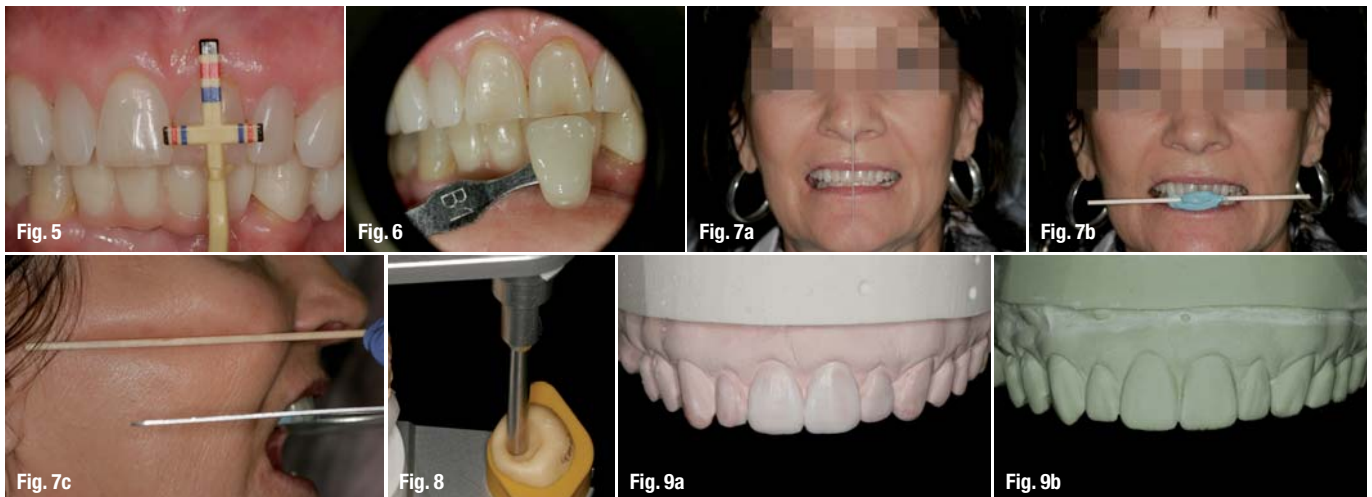

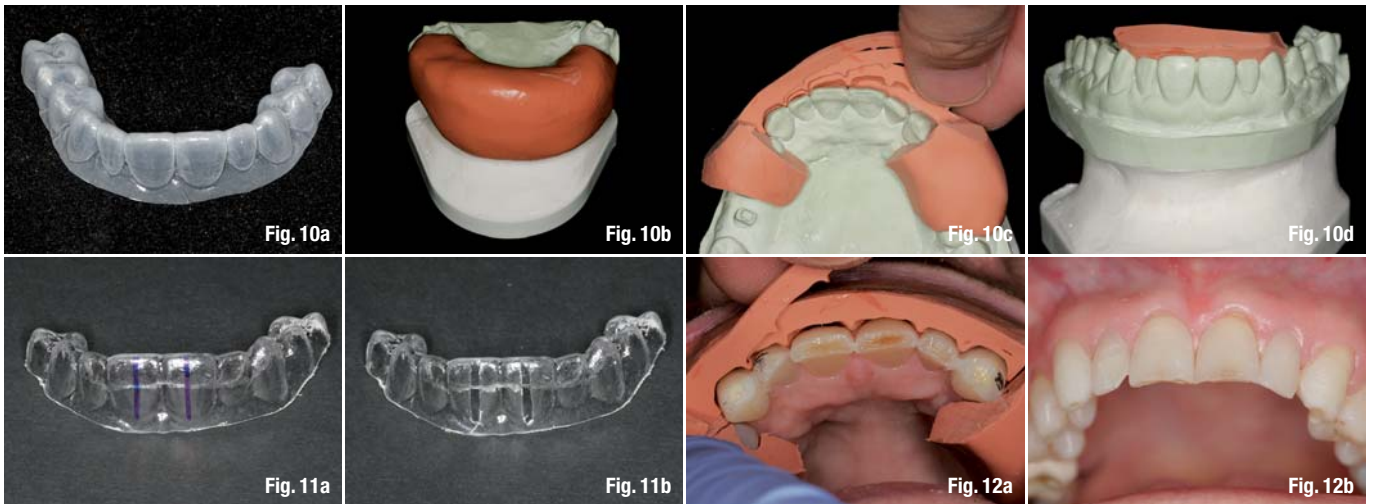
_Introduction

Porcelain laminate veneers (PLVs) have become a reliable treatment option because of recent advances in resin cements and ceramic materials. The advantages of PLVs include minimal reduction of enamel, superior aesthetic properties, great colour stability, and reliable bonding to the enamel. However, failures of PLV treatment, such as the patient's dissatisfaction with the aesthetic appearance and

ceramic fracture, continue to trouble both clinicians and patients. They stem from incorrect diagnosis, improper material selection, and defective tooth preparation. Therefore, the success of PLV treatments depends on the systematic and comprehensive assessment of patients and the scientific selection of dental materials.¹

Therefore, before a clinician starts to prepare teeth for veneers, it is critical that a comprehensive





and detailed treatment plan first be completed. It is equally critical that the treatment plan be discussed with the patient. Based on the author's experience and recommendations from other prominent authorities in aesthetic dentistry, a dentist must obtain the big picture, from the initial patient evaluation all the way to maintenance of the completed PLVs.

The purpose of this article is to introduce a step-by-step guide for PLVs. We could title it "the Pros GPS", since it is intended to guide readers to successful veneer restoration outcomes, both aesthetic and functional, by helping them avoid some of the pitfalls encountered by many dentists during PLV treatment. There are five phases to the Prosthodontic GPS: diagnosis, preparation design, provisionalisation, material selection and cementation.

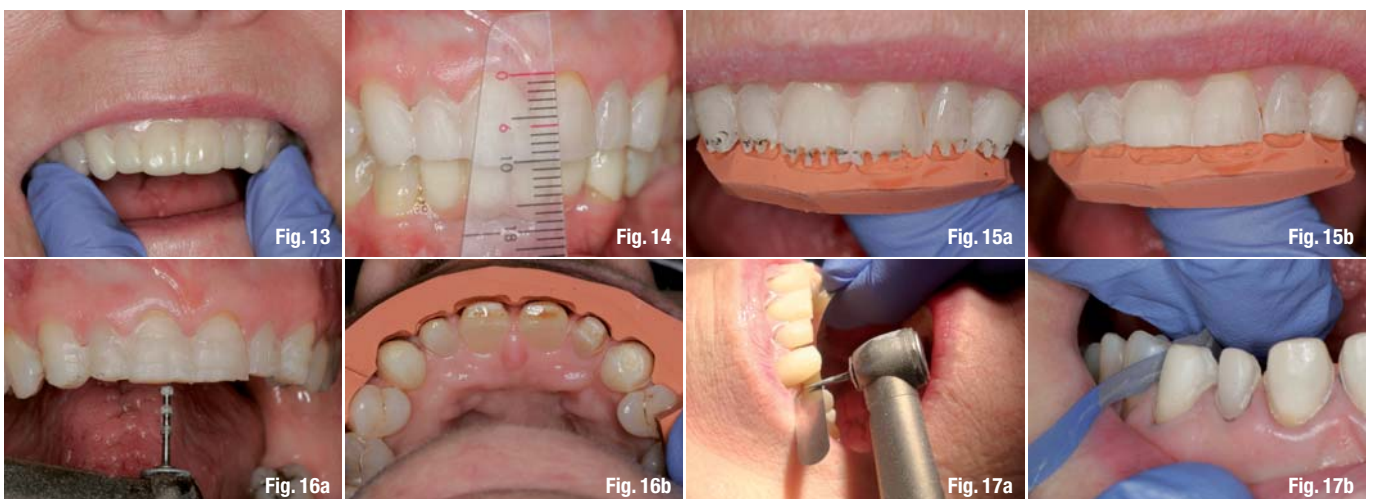
Diagnosis

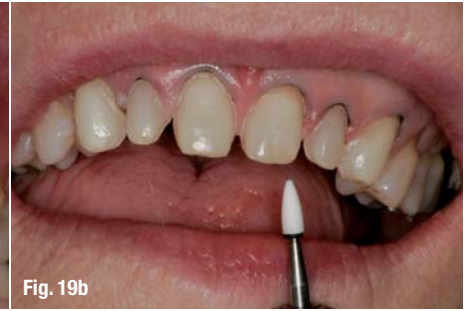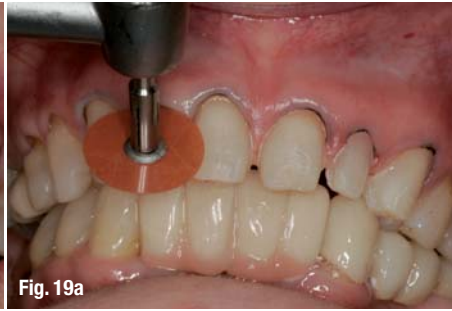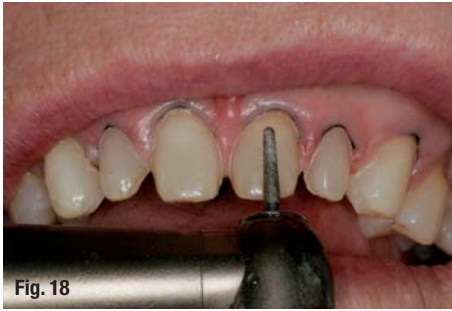A 61-year-old Caucasian female patient with minimal medical history presents for correction of her maxillary anterior teeth. She wants you to make

her teeth more rounded in order to enhance her feminine and youthful smile. How would you proceed?

First, start with facial and smile analysis. If you do not need to change the vertical dimension of occlusion, a profile evaluation such as E-line or the nasolabial angle is more important than a facial proportion evaluation (Fig. 1). The E-line profile evaluation is based on the maxillary anterior tooth position (sagittal angulation). If there is a large discrepancy between the average (anatomic) value and the patient's value, you may need to consider orthodontic treatment prior to PLV treatment. In addition, the symmetry and shape (such as ovoid or square) of the patient's face must be evaluated.

For smile analysis, record the patient's gradual smile change from a rest (repose) position to a dynamic and full-smile position (Figs. 2a-d). This series of photographs will enable you to evaluate the patient's lip mobility and the smile line, which is an imaginary line drawn along the incisal edges of the maxillary anterior teeth. Based on the rest posi-





tion photograph, you can evaluate how much of the maxillary anterior teeth is displayed below the patient's upper lip. This incisal display depends on the age and sex of the patient.² The full-smile photograph will enable you to evaluate a high lip line and the buccal corridor. The tooth-surface photographs can be taken in three planes: incisal third, middle third and cervical third (Figs. 3a–c).

Second, perform an intra-oral examination. Evaluate the symmetry of gingival level and dental caries. Then evaluate the biotype with articulating paper (Fig. 4). A thin biotype may decrease long-term stability because it tends to be less resistant to trauma during restoration procedures (such as retraction-cord insertion) and has a higher prevalence of gingival recession after cementation. Tooth proportion is evaluated with Chu's Aesthetic Gauge (Hu-Friedy; Fig. 5).

Third, evaluate tooth shade with the Rite-Lite (AdDent). It is a shade-matching light that supplies a constant colour temperature of 5,500 K (Fig. 6).

Fourth, evaluate the dental radiographs. Check for the apex lesion and root proximity.

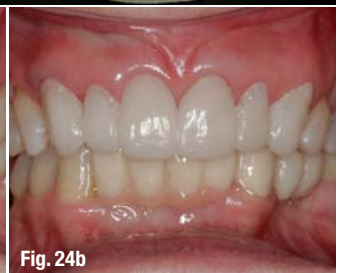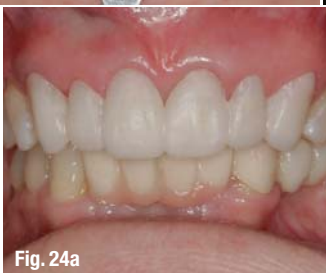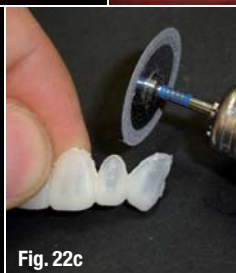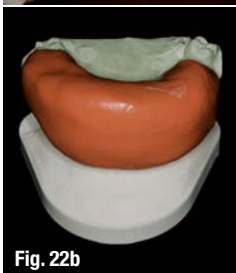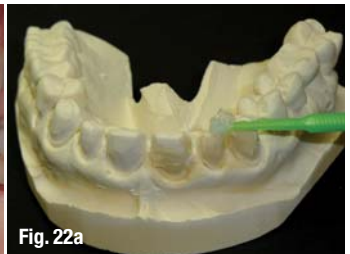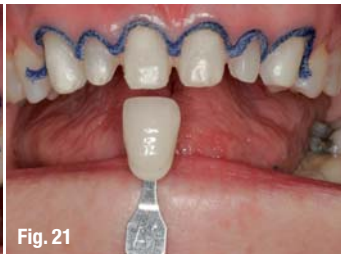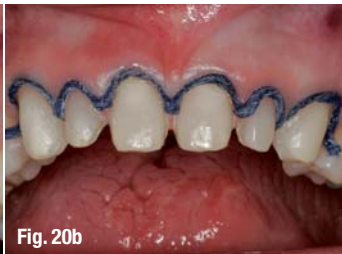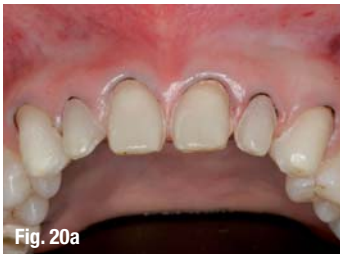Fifth, evaluate and transfer the midline, interpupillary line, and Camper's lines as illustrated in Figures 7a to c.

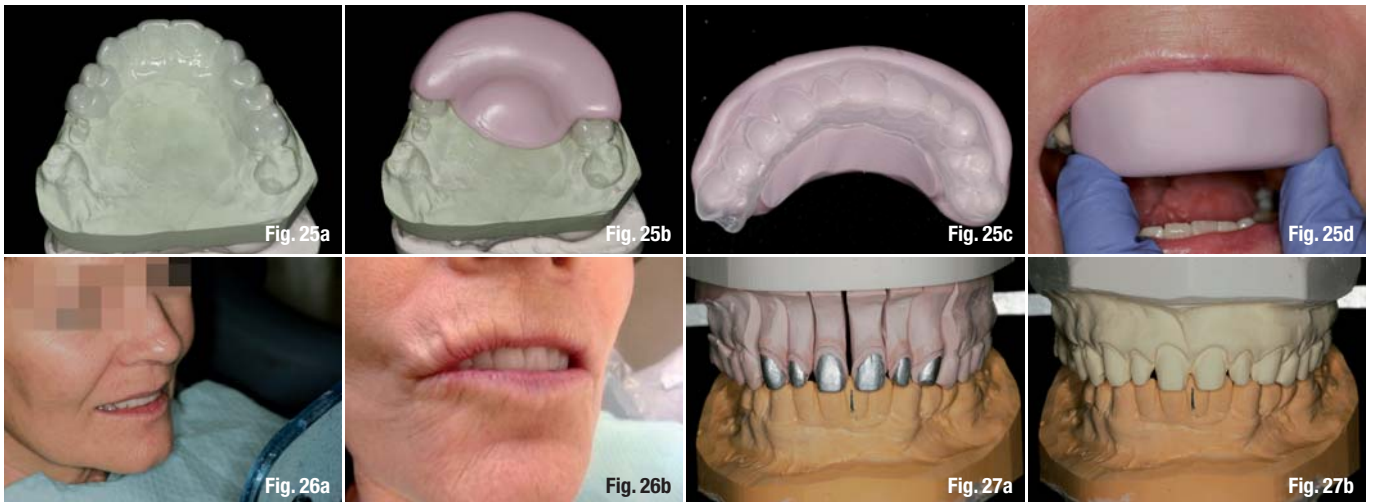
Sixth, perform the mounted cast evaluation on an articulator. Assess horizontal and vertical overlap (overjet and overbite) between maxillary and mandibular incisors. In order to preserve anterior guidance (maxillary anterior lingual surfaces), a custom incisal table needs to be made with auto-cure resin (Fig. 8).

Seventh, make a diagnostic wax-up on the mounted cast. Do not forget to duplicate the wax-up (Figs. 9a & b).

Preparation design

This section discusses veneer preparation design. I recommend incisal wrapping with either a butt margin or a mini-chamfer finish line. This finish line will assist dental ceramists in making a determination with respect to form and shape, and will assist clinicians in making a positive seating during cementation. However, you should avoid placing the finish line on the concave lingual fossa to prevent high tensile stress of the porcelain. In addition, avoid placing the finish line on the occlusal contact points. Opening interproximal contacts is recommended. Closed proximal contacts will interfere with improvement of the shape and translucency, since it is very difficult to separate the dies.





First, before a veneer preparation is initiated, make a thermoplastic matrix for a resin mock-up and a silicone matrix on the duplicated wax-up cast (Fig. 10). You can cut this silicone matrix into two depth-reduction guides: one for incisal reduction and the other for labial reduction (which is notebook-shaped with incisal third, middle third, and cervical third layers). Alternately, you can also use a thermoplastic matrix for the depth reduction (Fig. 11).

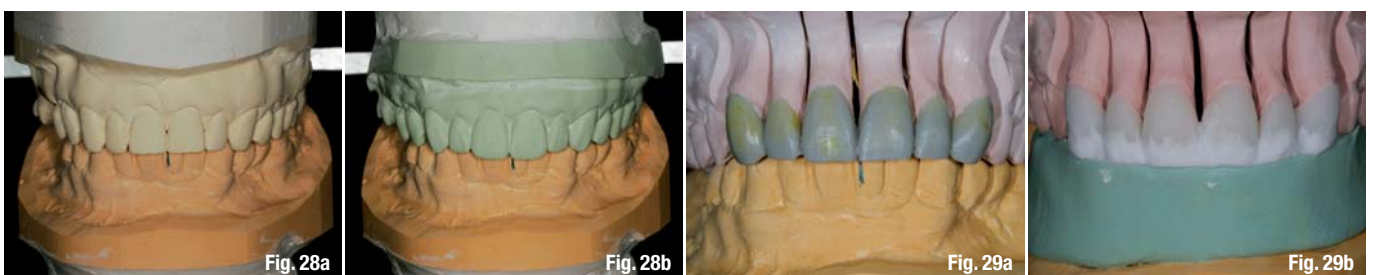
Second, have the patient return to make a resin mock-up on the patient's teeth. This is a great communication tool with the patient and will enhance the patient's acceptance of the proposed treatment plan. Before making the resin mock-up, with the silicone labial-reduction guide from the previous step (Fig. 10c), mark with a pencil any over-contoured area (Fig. 12a) and then reduce that area in order to achieve a better adaptation of the silicone matrix or the thermoplastic sheet (Fig. 12b). After that, you can make the mock-up resin with a flowable composite resin, carried in the thermoplastic sheet with no dental bonding agent (Fig. 13). Once the patient agrees to the proposed treatment plan for PLVs, use this resin mock-up during the following tooth-preparation steps. You should verify the mock-up resin with a ruler (Fig. 14).

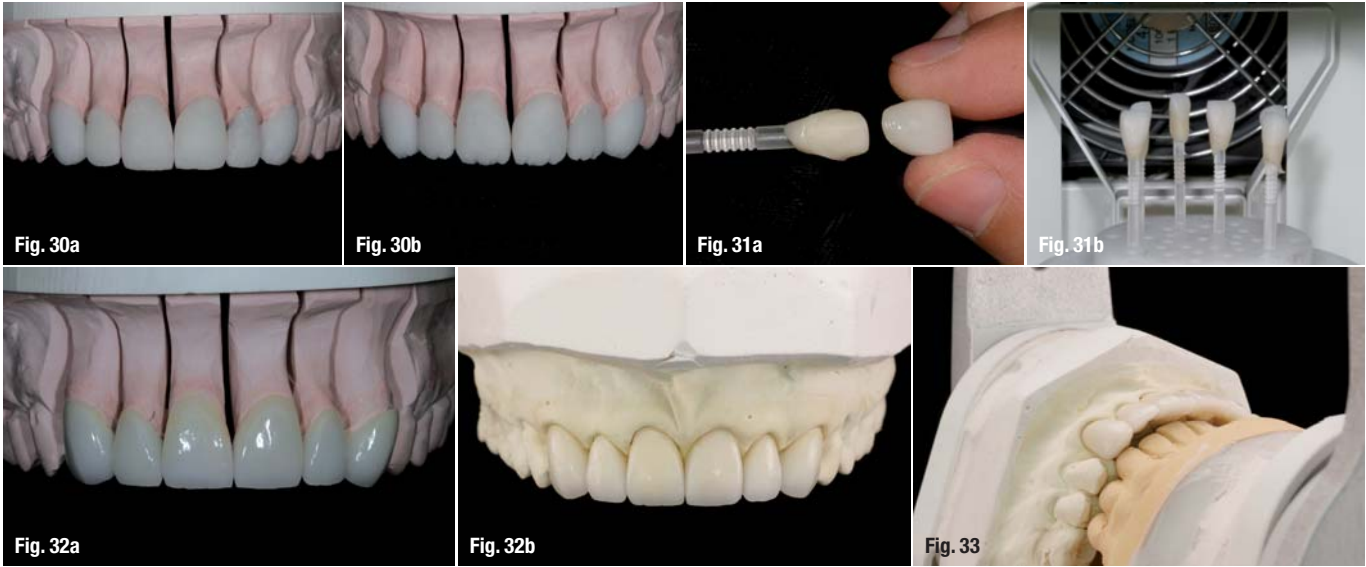
Third, over the mock-up resin, complete the incisal reduction with a #330 bur to achieve an

even 2 mm reduction and verify the reduction with a silicone incisal-reduction guide (Figs. 15a & b). Then, make the labial reduction with 3 mm (834.314.016, Komet Dental) and 5 mm (834.314.021, Komet Dental) depth cutter burs in the cervical and middle areas, respectively (see Fig. 16a). Verify your veneer preparation with a notebook-shaped labial silicone matrix (0.3 mm to ~0.7 mm; Fig. 16b). It is important to achieve even amounts of preparation with depth cutting burs over the resin mock-up and to avoid over-reduction of the tooth structure, thus preserving the enamel for predictable cementation.

Fourth, do the interproximal reduction. Use a metal matrix to avoid damaging adjacent teeth. Polish the interproximal areas with polishing strips to create smooth and even surfaces (Figs. 17a & b).

Fifth, create the cervical finish line. I prefer a slight sub-gingival position when I intend to change the shade of the tooth. A chamfer cervical finish line is created along the free gingival margin without placing a retraction cord. Then, with a thin retraction cord (Ultrapak Cord #00, Ultradent Products) placed in the sulcus, make another equi-gingival chamfer finish line following the displaced free gingival level (Fig. 18). When the retraction cord is removed later, you will see a 0.5 mm sub-gingival margin placement. However, do not remove the





retraction cord at this time. Finish the prepared tooth surfaces with a polishing disc and a white stone bur (Figs. 19a & b).

discussions with the patient, a change may be made in the laboratory procedure for the final restorations.

Sixth, prepare for the impression by placing a second (thicker) retraction cord (Ultrapak Cord #1, Ultradent Products) and wait for five minutes. This second cord can be a single, continuous cord for easy removal. Right before the impression material is applied to the tissue, remove the second retraction cord (Figs. 20a & b). I recommend using heavy and light body VPS material. The stump shade can be taken at this point (Fig. 21). You should make sure that all retraction cords are removed before the patient is released.

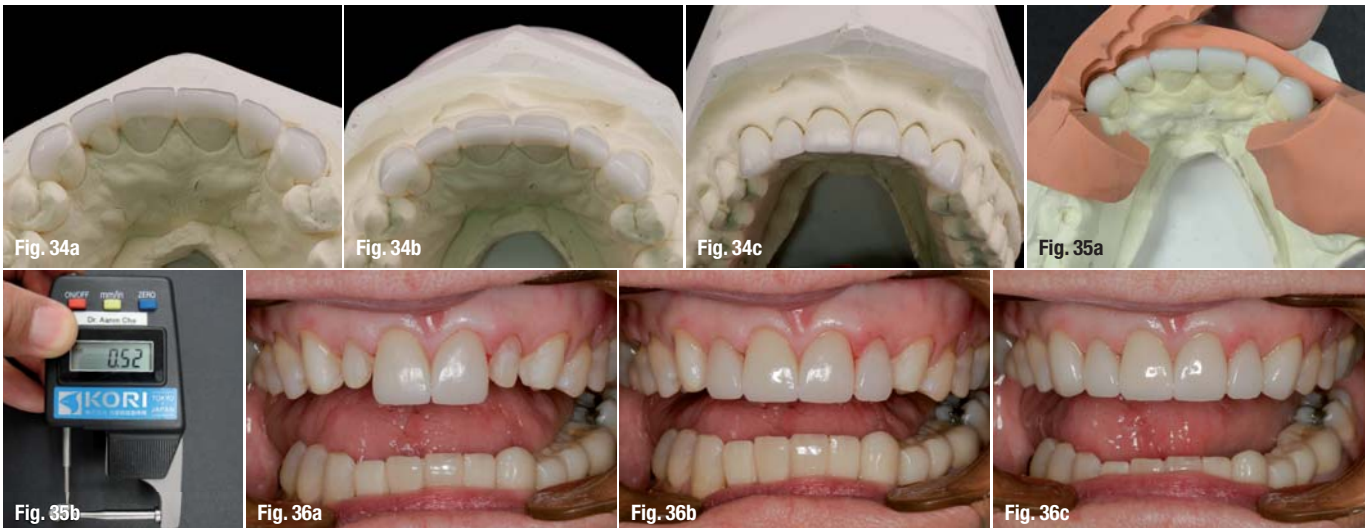
There are many materials for provisionalisation. I often use a direct method with bis-acryl or flowable resin to make interim veneers. For the case illustrated here, I used an indirect method because it has several advantages, such as verification of the amount of tooth preparation and better control of interim veneer forms.

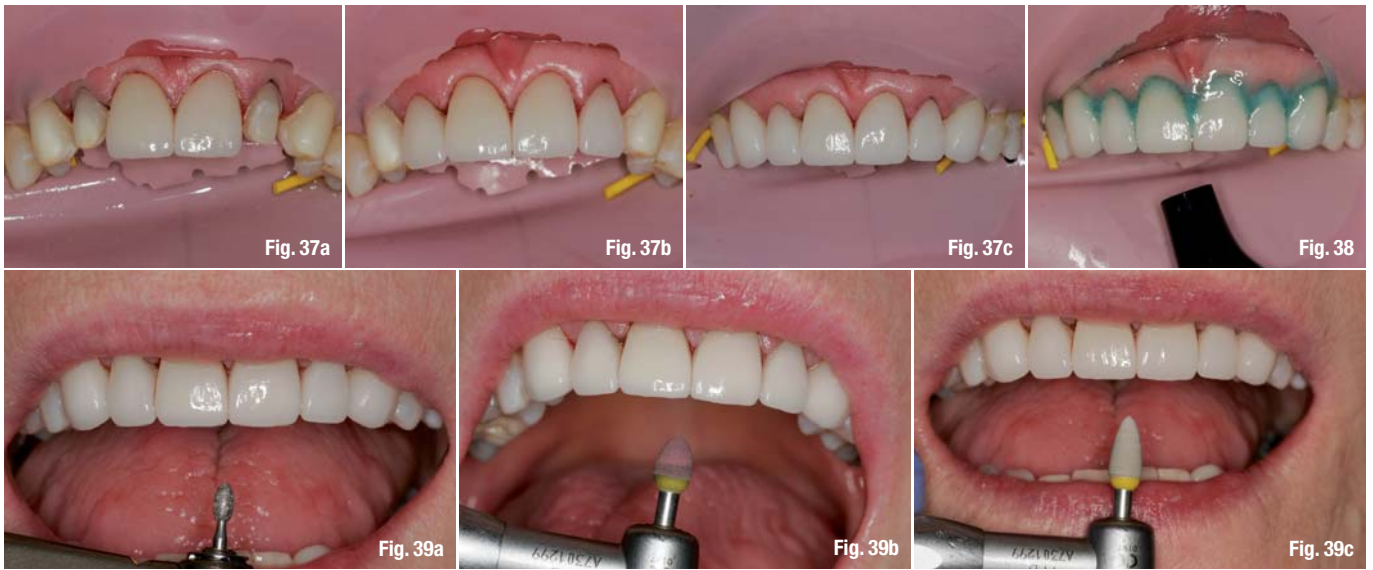
Provisionalisation

First, make an alginate impression of the prepared teeth. You can use the silicone matrix and a PMMA resin to make acrylic interim veneers (Figs. 22a-c). After trimming, verify the thickness with a digital calliper (Fig. 23).

Interim veneers play significant roles, serving as a communication tool and a phonetic evaluation tool (Figs. 26a & b). Through these evaluations and

Second, make a spot etching for retention of the interim veneers. Then apply a glazing resin coating (G-Coat Plus, GC) to the interim veneers for the





glazing effect (Figs. 24a & b). If you want to make interim veneers using a direct method, I recommend placing the silicone matrix over the thermoplastic sheet during fabrication in the mouth because the thickness of an interim veneer is too thin to control with a thermoplastic sheet only (Figs. 25a–d).

Material selection

Once the dental laboratory receives the final impression, two stone casts will be made—a master cast and a solid cast. The master cast will be used for individual die fabrication, wax-ups, internal fit, margin fit and occlusal contact checks. The solid cast will be used mainly for proximal contact check and labial surface contour, which needs to be harmonised with the soft tissue (Figs. 27a & b). In addition, for diagnostic casts, a duplicate cast of the diagnostic wax-up and intra-oral photographs for shade selection must be shipped to the laboratory for the final veneer fabrication (Figs. 28a & b).

Pressable ceramic material is recommended because of its enhanced aesthetic property in layering technique, and for its strength and stability with resin bonding cements. When you select a lost-wax method, a laboratory technician creates a full-contour wax-up on the master cast, guided by the duplicate diagnostic cast and the doctor's instructions (Fig. 29).

After the initial pressing, a cut-back is made on the incisal area of the ceramic veneers in order to create room for additional porcelain to be added. This layering technique is used to create lifelike translucency in the incisal third of the veneers (Figs. 30a–c).

For external staining and glazing, use the stump-shade resin dies to create an accurate matching of shade (Figs. 31a & b). The effect of multiple firings on the marginal integrity of the pressable veneers is minimal.³

Final veneers are evaluated on both the master cast and the solid cast (Figs. 32a & b). Occlusal contacts during eccentric movement are then evaluated and adjusted (Fig. 33). The intaglio (inner) surfaces of the veneers need to be treated with hydrofluoric acid in the laboratory.

Cementation

If thickness and opacity of veneers are important factors, I recommend using dual-cure resin cements for pressable ceramic veneers. However, light-cure resin cements also have some advantages, such as extended working time and colour stability due to the fact there is no amine degradation.

First, after receiving the veneers from the laboratory, you should evaluate facial veneer surfaces on the three different planes: incisal third, middle third and cervical third (Figs. 34a–c), as you did during the diagnostic phase (Figs. 3a–c). You can easily verify whether the veneer surfaces have been built to a harmonised contour with adjacent teeth. Look for over-contouring. Evaluate the form and thickness with a silicone matrix and a digital calliper (Figs. 35a & b).

Second, on the try-in date, remove the interim veneers gently and try in the veneers with a recommended try-in resin paste in this order: central incisor, lateral incisor and canine. Clinically evaluate the shade, form and margin (Figs. 36a–c), and then

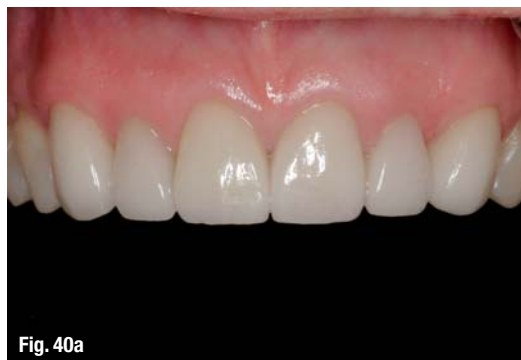

Fig. 40a

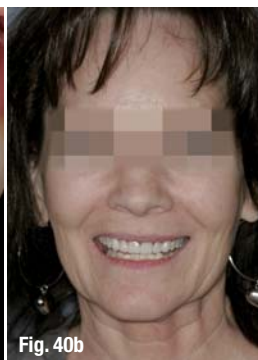

Fig. 40b

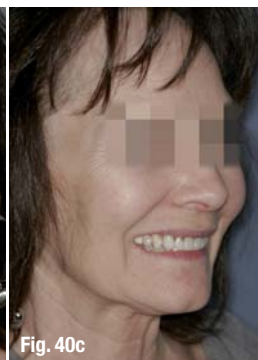

Fig. 40c

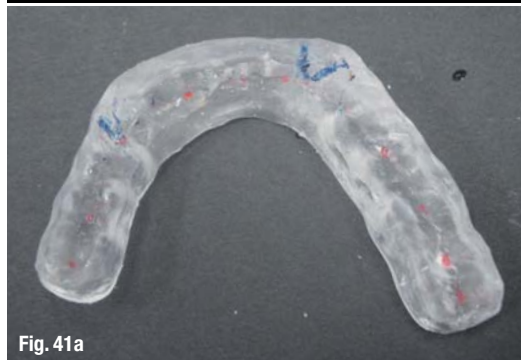

Fig. 41a

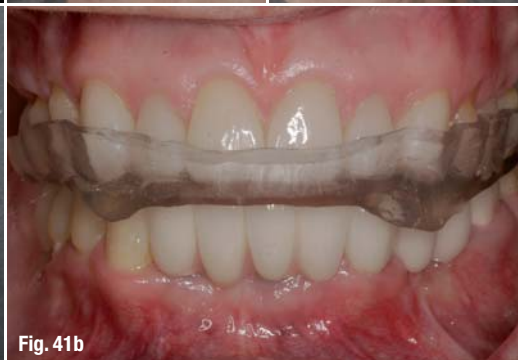

Fig. 41b

request feedback from the patient to have him or her approve the veneers.

Third, after obtaining the patient's approval, etch the inner surfaces of the veneers with 37 % phosphoric acid for 15 seconds. Cleanse the acid from the veneers in an ultrasonic cleaner with a 95 % alcohol solution for four minutes. Apply silane two or three times, followed by a heat treatment carried out with a hair dryer.⁴

Fourth, apply and rinse etchant. Then apply bonding agents to the teeth surfaces.

Fifth, place veneers with resin cements on the teeth, and make sure that the cementation steps are done individually in the following order: central incisor, lateral incisor and canine (Figs. 37a–c). After the initial light curing (two seconds), remove the excess cement, then finalise the light curing with an oxygen blocker (Oxyguard II, Kuraray) on the marginal area to achieve complete polymerisation (Fig. 38).

Sixth, after cleaning, adjust occlusal contacts with a diamond bur and ceramic polishing burs (Figs. 39a–c). The final PLVs produce a natural smile with an enhanced aesthetic contour and texture (Figs. 40a–c). Make an alginate impression to fabricate a night guard for the veneers.

On the follow-up appointment, deliver the night guard to protect the newly placed veneers (Figs. 41a & b).

Conclusion

With this easy-to-use, step-by-step guide, you can create predictably aesthetic and reliable ceramic veneer restorations, but this requires a firm understanding of all five phases: diagnosis, preparation design, provisionalisation, material selection and cementation.

Acknowledgement

Special thanks to Dr. Young S. Kang for the editing of the manuscript.

Editorial note: A complete list of references is available from the publisher.

contact

cosmetic
dentistry



Dr Seok-Hwan Cho

Assistant Professor
and Prosthodontist,
Department of General
Dental Sciences

School of Dentistry
Marquette University
Room 004
1801 W Wisconsin Ave
Milwaukee, WI 53233
USA

FDI World Dental Federation

Leading the World to Optimal Oral Health

2012 Hong Kong

FDI Annual World Dental Congress

29 August - 1 September 2012

10 reasons to join FDI in Hong Kong, World Oral Health Capital 2012

- 1. Celebrate** the uniqueness of FDI at its 100th Annual World Dental Congress;
- 2. Learn** about the latest developments from international and regional experts;
- 3. Discover** the newest technology, equipment, products and materials;
- 4. Interact** with renowned world specialists;
- 5. Empower** yourself through FDI sessions on policy and public and oral health;
- 6. Enjoy** exclusive face-to-face encounters with your peers worldwide;
- 7. Develop** your knowledge and skills through a new and innovative programme;
- 8. Sample** some of the best cuisine in Asia: one restaurant for every 600 inhabitants!
- 9. Marvel** at the breathtaking views of Hong Kong and Macau;
- 10. Uncover** the riches and mysteries of mainland China.



Leading the world into a new century of oral health

ADA CERP® | Continuing Education
Recognition Program

www.fdicongress.org

congress@fdiworldental.org

On smile design: Conservatively placed IPS d.SIGN veneers to correct a diastema

Authors_Harald Heindl, USA, & Dr Stephen Phelan, Canada

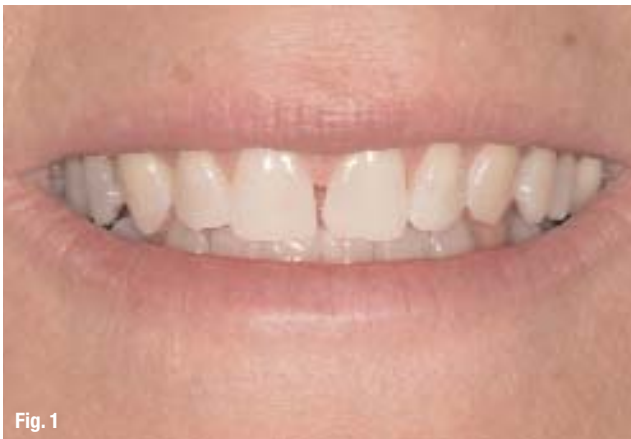

Fig. 1

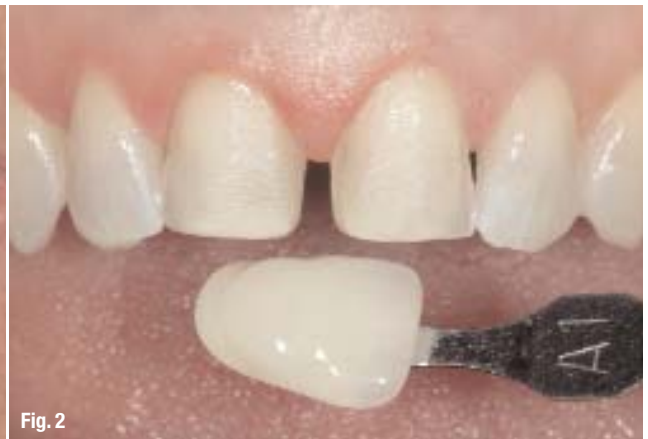

Fig. 2

Fig. 1 _Initial situation: what some people see as a sign of beauty, others may see as a flaw; the patient disliked her diastema between teeth #11 and 21.

Fig. 2 _After conservative preparation, the shade was determined (A1).

_Today's patients expect restorations that not only function properly, but are also highly aesthetic. Unlike some years ago, different media outlets today afford patients greater knowledge and insight into the possibilities and the potential of modern materials and treatment. They expect us to achieve optimum outcomes when designing their smile, and rightly so. The most significant goal, however, is still the

restoration of oral health in the most conservative way.

When choosing a treatment option, dentists and technicians must satisfy not only the clinical requirements, but also the expectations and goals of the patients. In cases in which patients decline orthodontic treatment, adhesively bonded porcelain veneers are a viable treatment

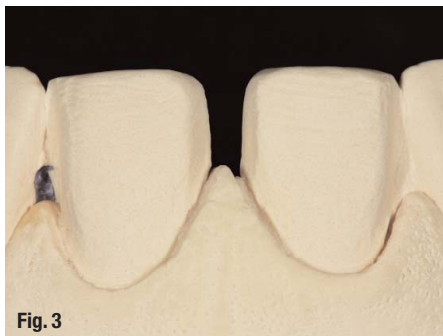

Fig. 3

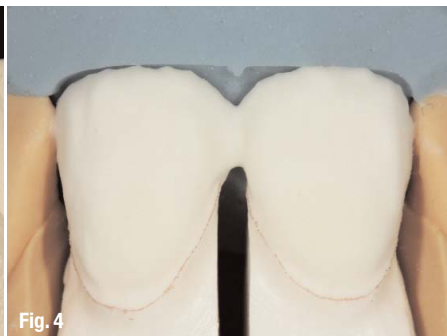

Fig. 4

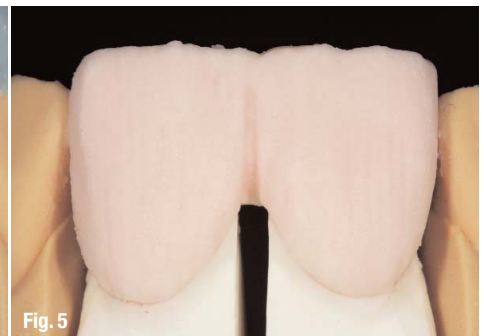

Fig. 5

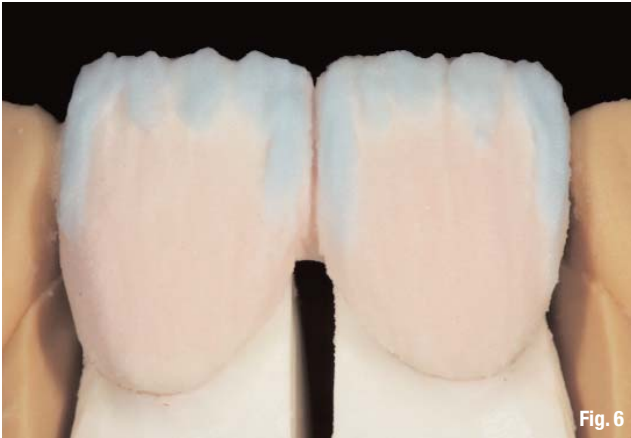

Fig. 6

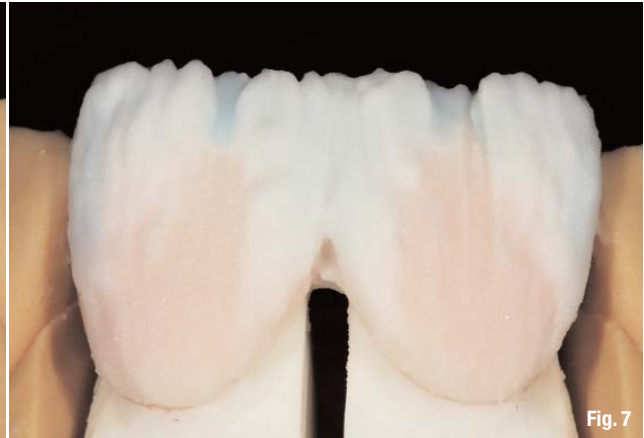


Fig. 7

option to modify the appearance of tooth position and form, to close diastemas or cervical embrasures or to change the tooth shade. Porcelain veneers are one of the best restorative treatment options available from biological, functional, mechanical and aesthetic perspectives. Preservation of enamel is one of the main concerns if such a treatment is envisaged.

The conventional laminate veneer techniques often require aggressive removal of dental tissue, which goes against the principles of conservative dentistry. New techniques and materials allow aesthetically pleasing and functionally long-lasting restorations to be produced while limiting tooth preparation. By using diagnostic guides, such as a wax-up, and a fluorapatite glass-ceramic material (IPS d.SIGN, Ivoclar Vivadent), dentists and dental technicians can fabricate minimally invasive ceramic veneers and thus provide their patients with lifelike, aesthetic restorations that also meet the functional criteria.

_Case presentation

A 52-year-old female patient presented with complaints about the shape and size of her max-

illary centrals, and she wanted the midline diastema closed (Fig. 1). After discussion with the patient, it was decided that porcelain veneers (IPS d.SIGN) would be placed on teeth # 11 and 21. We wanted to apply a conservative protocol to fulfil the patient's wishes.

Leucite-reinforced fluorapatite layering ceramic (IPS d.SIGN, for instance) is ideal for bonded ceramic restorations such as veneers. The material's special qualities include outstanding optical properties and wear behaviour. The physical properties are very close to those found in natural teeth. As a result, IPS d.SIGN is the material of choice for treatments requiring conservative veneers.

By using a direct layering technique on refractory dies, laboratory ceramists can provide their customers and patients with restorations that display the vitality and fluorescence required to make them indistinguishable from natural dentition. With increased brightness, higher shade consistency, natural opalescence and a wide range of characterisation options, this glass-ceramic material enables professional creativity in addressing a variety of restorative cases. Additionally, the IPS d.SIGN porcelain

Fig. 3 The working stone model for the creation of the veneers.

Fig. 4 The material was layered on refractory dies. The silicone matrix fabricated on the basis of the wax-up was used as a guide.

Fig. 5 Quality dentine materials together with excellent technical and manual skills are required to create tooth-like veneers made up of many individual layers.

Fig. 6 The stratification was created by applying various brightness and translucency levels.

Fig. 7 The dental lobes were created in the incisal area with custom-mixed ivory- and cream-coloured materials, which were applied in thin layers.

Fig. 8 The baked veneers.

Fig. 9 The entire porcelain surface was coated with silver powder to better assess symmetry and surface morphology.

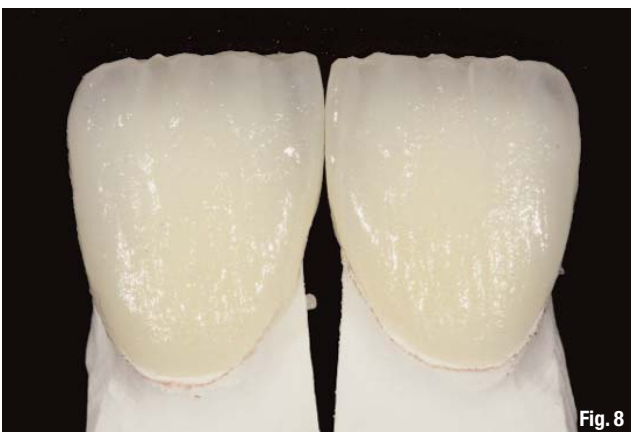

Fig. 8

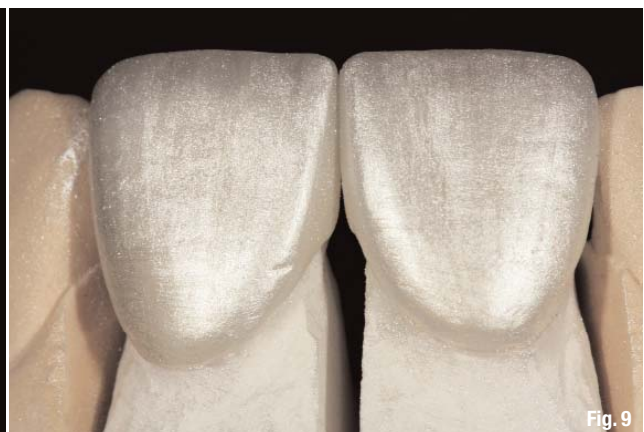

Fig. 9

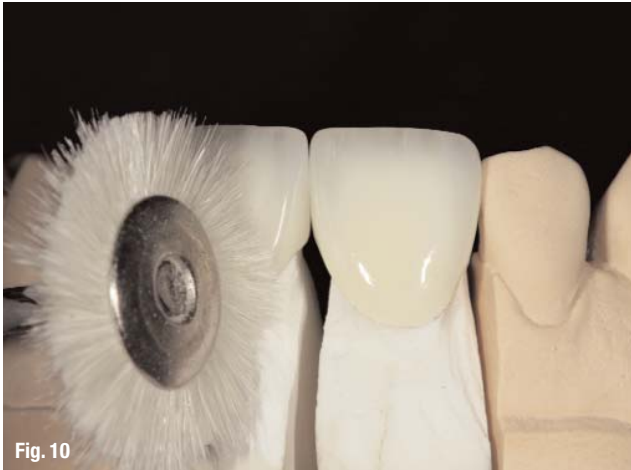

Fig. 10

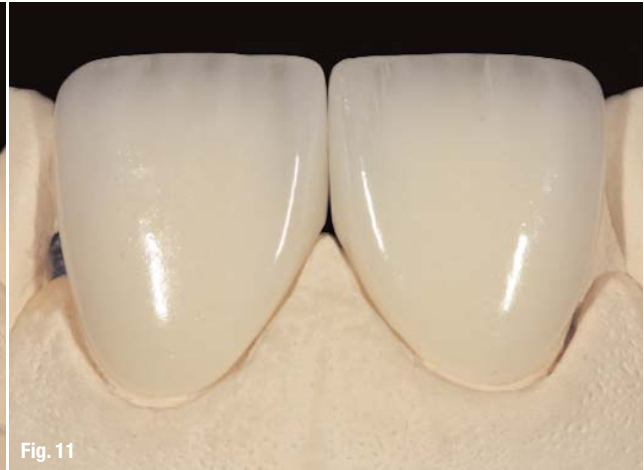

Fig. 11

Fig. 10_ After thermal glazing, the restorations were mechanically polished.

Fig. 11_ The delicate ceramic veneers already looked impressive on the model.

enables dentists to limit much of the veneer preparation to enamel, thereby reducing the risk of overexposing dentine.

Clinical preparation

After the patient had accepted the treatment plan, the dental technician created a diagnostic wax-up. In order to observe the principles of conservative preparation, a purely additive technique was used. Wax was added to the model to build up the new tooth forms. A resin matrix (mock-up) was then created from the diagnostic wax-up to allow the patient to preview the restorations prior to tooth preparation.

After patient approval, the mock-up was used as a blueprint for enamel reduction. The patient was anesthetised and depth cuts were placed in the incisal and cervical third of the matrix. Proper depth cuts were made with a diamond bur, using the matrix as a guide. The cuts were marked with a pencil for easy identification. The mock-up was removed and the necessary dental enamel for the veneer preparations was

removed using large round-ended diamond burs (Fig. 2).

Finally, the preparations were checked with vertical and palatal putty stents. These stents had been created previously from the diagnostic wax-up to ensure that the preparations were compatible with the veneer shape. The provisional restorations were inserted and checked. Particular emphasis was given to the embrasure form, where a space was left to allow the gingival tissue to recover fully after placement. The provisionals were spot-etched with phosphoric acid solution and luted with resin cement. The patient returned after a few days, a facebow was created, and the case was sent to the dental ceramist (Fig. 3).

Laboratory procedure

The veneers were built up on the refractory dies using the IPS d.SIGN porcelain (Fig. 4). Prior to the actual layering procedure, margin material was applied in a thin layer as far as the margins and baked.

Figs. 12 & 13_ The seated restorations.

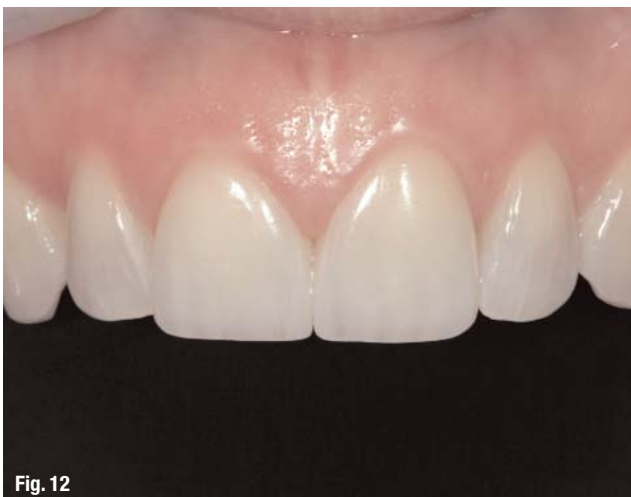

Fig. 12

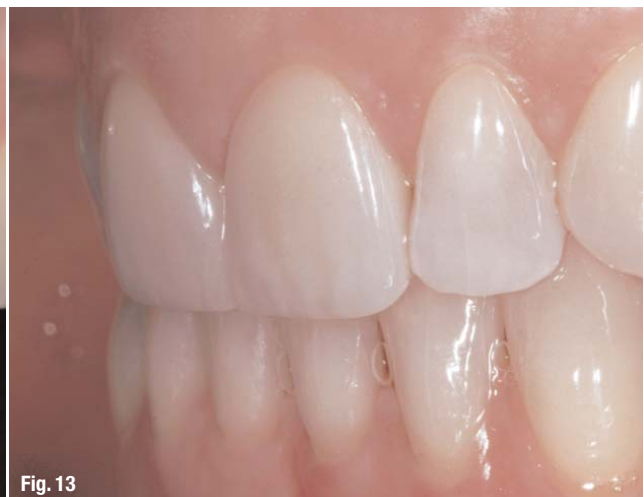

Fig. 13

Porcelain stratification was initiated by placing a layer of deep dentine on the facial, interproximal and incisal areas. For the subsequent layering steps, the resin matrix from the wax-up served as a guide. The veneers were then built up using dentine layers of different values and translucencies with the appropriate dentine materials and manual skills (Figs. 5 & 6).

Finally, the dental lobes were characterised by applying thin layers of custom-mixed ivory- and cream-coloured intensive materials (Fig. 7). A combination of translucent and opalescent enamel powders was used to cover the entire facial aspect of the veneers (Fig. 8).

After the initial bake, the veneers were checked on the master dies. The contours and shape were finalised and the veneers were baked for a second time (Fig. 9).

Final contouring and surface texturing were completed with diamond burs and green stones (Fig. 10). After the final polish, the internal aspects of the veneers were etched with 9.5 % hydrofluoric acid for 60 seconds. The thin veneers were then ready for seating and delivered to the dentist (Fig. 11).

Final seating

Once the provisionals had been removed, it was important to polish the preparations with pumice and to thoroughly clean them subsequently.

The veneers were tried in individually to inspect the fit and then collectively to evaluate the contact areas optimally. The veneers were placed using a try-in gel in order to give the patient a preview of the final outcome. The result was outstanding, and thus the veneers were definitively luted into place according to standard bonding protocol with a resin cement. After final polishing, the occlusion was adjusted and checked.

The patient's expectations had been met: the restorations closed the diastema, the newly designed anterior teeth fulfilled the aesthetic expectations of the patient, and her smile was more relaxed and she looked more confident (Figs. 12 & 13).

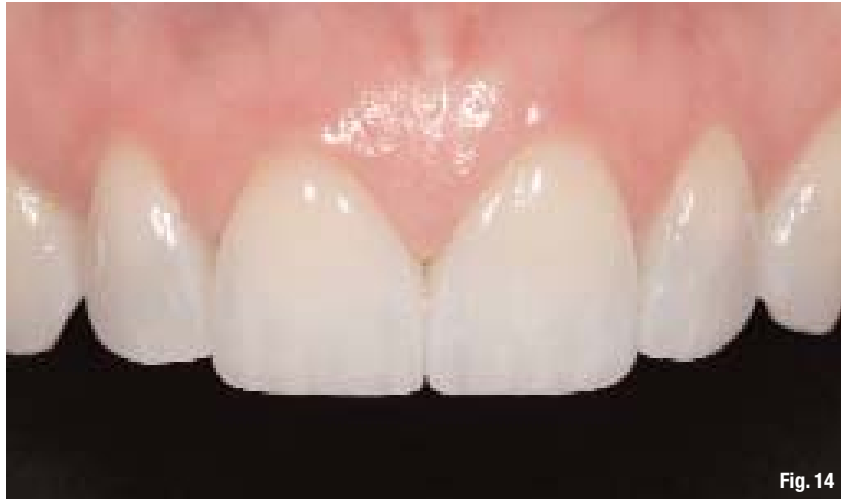

Fig. 14

Conclusion

Bonded veneers can represent a minimally invasive treatment option. If the appearance of the anterior teeth is to be improved or modified, they are an attractive alternative to orthodontic treatment.

The IPS d.SIGN fluorapatite material features properties that come very close to the optical and physical characteristics, as well as the wear resistance of natural teeth. With this material, veneers can be fabricated that are virtually indistinguishable from natural dentition.

The procedure discussed in this case allowed a conservative and highly aesthetic veneer restoration to be fabricated. Both the patient's aesthetic goals and the dentist's functional requirements were met (Fig. 14).

Fig. 14 Two years after treatment: the gingiva is healthy and the patient still happy.

contact

cosmetic
dentistry



Harald Heindl, MDT
Aesthetic Dental Creations
Mill Creek, WA 98012
USA

aedecr@comcast.net



Dr Stephen Phelan
1500 Heritage Way
Oakville, ON L6M 4M7
Canada

dr.sphelan@cogeco.ca

Lithium disilicate— An effective solution for aesthetically demanding indications

Author_Dr Igor Ristić, Serbia

Fig. 1 _Pre-op view of patient's smile.

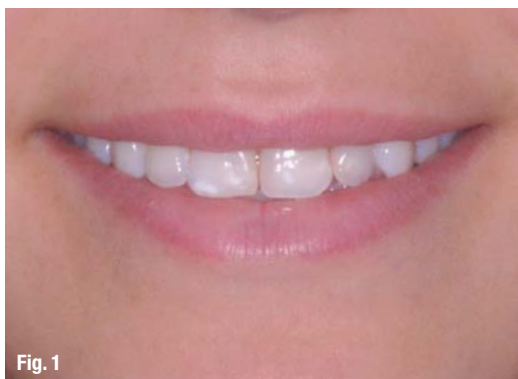
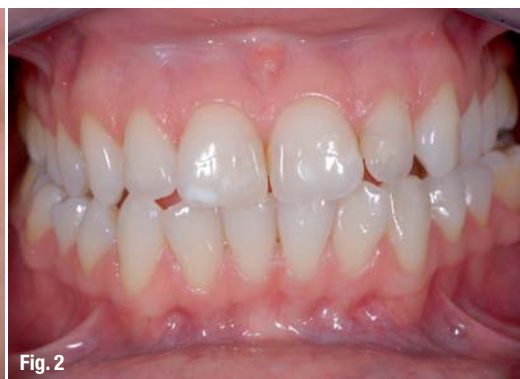
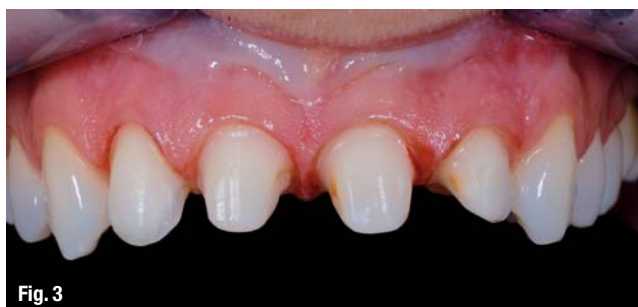Fig. 2 _Stained teeth, old composite fillings and rotated teeth were the patient's major complaints.



At a time when dentists and patients are both seeking more conservative restoration, as well as maximum transformation regarding individual teeth and whole-mouth restoration, lithium disilicate ceramic material represents a truly unique material and is almost certainly the next big thing in aesthetic dentistry!

Owing to its high resistance to fracture (400 MPa), optical properties similar to natural tooth structure and the ability to be pressed very thinly in particular, such material has a unique potential for the manufacture of minimally invasive restorations like ultra-thin crowns and veneers.

Fig. 3 _Prepared teeth for two crowns and two veneers.



Now, skilled dental technicians can press lithium disilicate restorations as thin as 0.3 mm with excellent aesthetic results. If we add to that experience and knowledge of the material, such restorations could be considered perfect in terms of appearance, durability and ability to blend with the existing intact teeth.

Unfortunately, when the press ceramic was launched it caused some scepticism and reluctance within the profession, primarily owing to the high biological cost of such restorations, since healthy tooth structure was reduced by up to 2 mm, which eventually led to overly aggressive preparation. Preparation of the lower incisors according to the manufacturer's instructions was often on the verge of devitalising the tooth.

Owing to its special properties, Lithium Disilicate (IPS e.max Press, Ivoclar Vivadent) has completely changed the concept of use for pressed ceramics and allows for extremely conservative preparation. IPS e.max Press is an aesthetic ceramic system based on lithium disilicate, with a high resistance to fracture, that can be cemented with adhesive technique

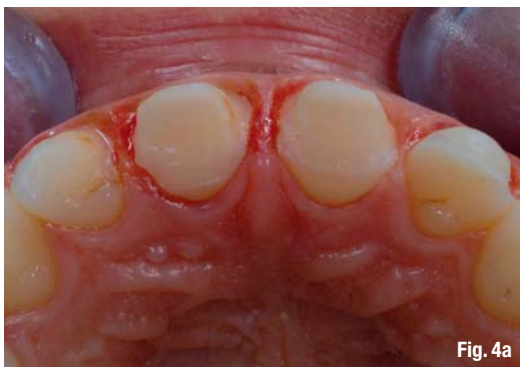

Fig. 4a

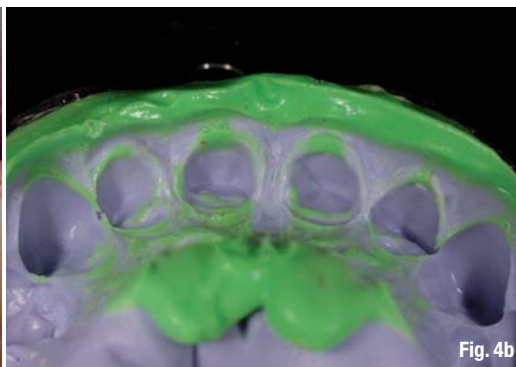


Fig. 4b

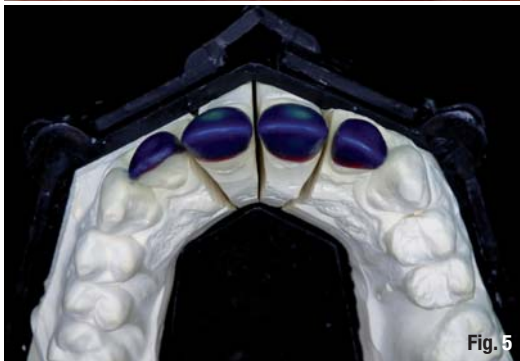

Fig. 5

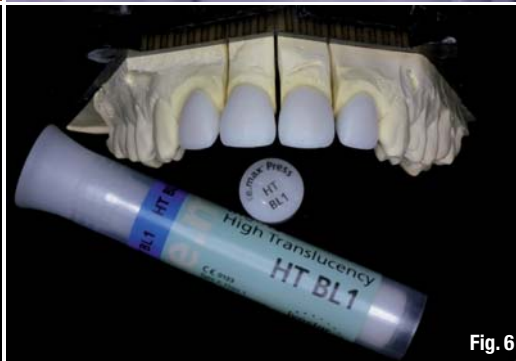

Fig. 6

Fig. 4a_ Conservative preparation on palatal side for pressed crowns.
Fig. 4b_ Impression with A-silicone (Flexitime Putty and Flexitime Correct Flow).
Fig. 5_ Ceramic cores for the restorations were made of wax patterns created on stone model in full volume.
Fig. 6_ Lithium disilicate cores were pressed from HT BL1 ingot.

or self-etch composite cements—such techniques are better known in the literature as "conventional". Full-contour restorations can be created and characterised with staining or layered with IPS e.max Ceram ceramic.

_ Case report

The patient presented to our practice with a simple request: "I don't like the stains on my teeth and I would like to correct the rotated tooth #22 to look like #12".

The examination established that teeth #11 and 21 had stains most likely caused by fluorosis, visible under a partially delaminated composite layer, which was previously added by another dentist in an attempt to mask the discoloration. Tooth #22 was rotated with a huge mesial composite filling (Figs. 1 & 2). A seemingly nice and relatively harmonious smile, upon further inspection, revealed a number of composite fillings on the proximal palatal side of the central incisors, which limited the possibility of restoration with veneers on these teeth.

After consultation with the laboratory and ceramist, we decided to use IPS e.max Press to produce crowns for teeth #11 and 21, with preparation as conservative as possible, and a thin, V-shaped vestibular palatal veneer on tooth #22, which was to simultaneously be rotated to correct and compensate for the missing natural tooth structure restored with composite. There was a need for

preparation only on the labio-distal tooth surface after removing the mesial composite fillings. A veneer was made for tooth #12.

After reviewing the composite fillings on the centrals, the teeth were prepared palatally with a supra-gingival finish line and minimal removal of the tooth structure. Teeth #12 and 22 were very conservatively prepared, owing to the characteristics of e.max Press materials the advantages and characteristics of e.max Press materials.

Temporary restorations were fabricated from composite material and cemented with the spot-etch technique, in order to allow the fit of the definitive restoration. Impression taking was done with one stage putty/wash technique using highly accurate Flexitime Putty and Flexitime Correct Flow materials (both Heraeus; Fig. 4b).

The surface of the prepared teeth was healthy, with natural colour and no discoloration, which allowed us to use the highly translucent IPS e.max Press HT BL1 ingot (Fig. 6). The copings were pressed from lithium disilicate material and fired in a special furnace.

Fig. 7_ Superb nature-like optical performance of lithium disilicate e.max system.

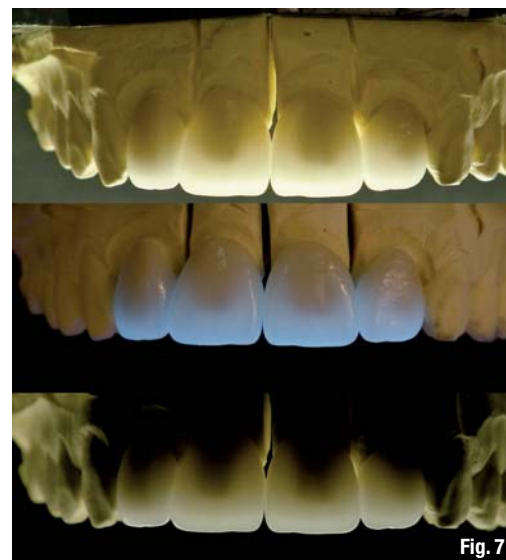

Fig. 7

Fig. 8_E.max pressed core veneered with e.max Ceram.

Fig. 9_Restorations could be as thin as 0.4 mm.

Fig. 10_Restorations immediately after cementation.

Fig. 11_The restorations blended perfectly into the natural dentition.

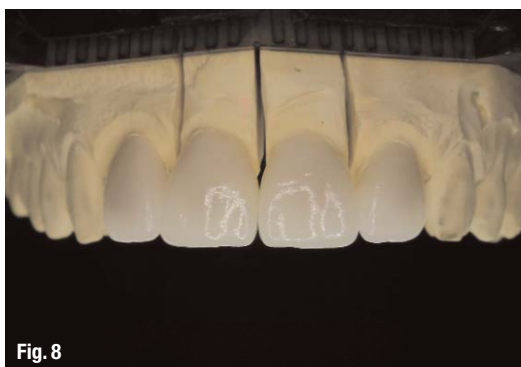

Fig. 8

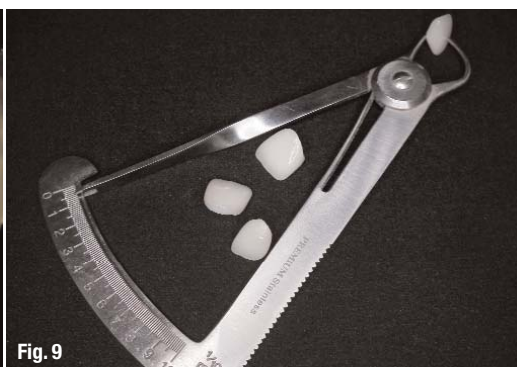

Fig. 9

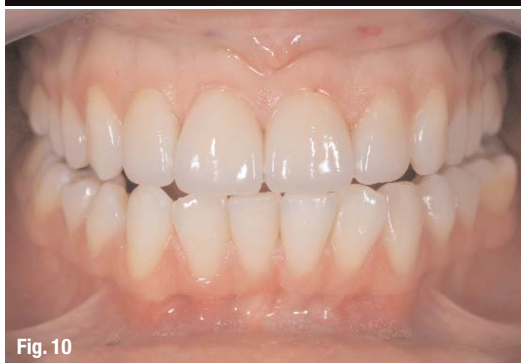

Fig. 10

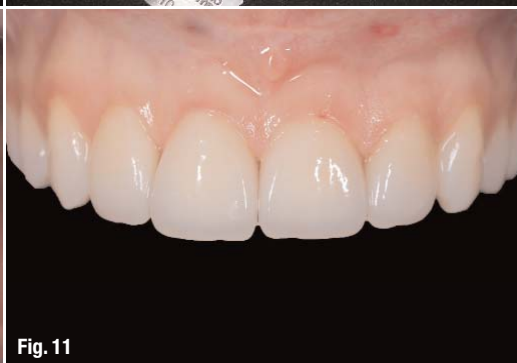

Fig. 11

Given that there was a demand for the highest level of aesthetics in this case, the ceramist decided that all four restorations were to be made using the cut-back technique on pressed copings and veneers in order to achieve a high degree of individualisation using the Incisal materials of the IPS e.max Ceram range.

Once received from the laboratory, the restorations were treated with hydrofluoric acid gel and a silane agent. The restorations were tried in before glazing and then cemented after the final check (Fig. 10). For adhesion, we used the resin cement Variolink II (Ivoclar Vivadent) in a transparent colour without a catalyst, taking advantage of light only polymerisation.

The perfectly fitting crowns and veneers, even prior to cementation, indicated that we had met all the preconditions for a successful future adaptation of the restorations to the soft tissue (Fig. 11).


Conclusion

The aesthetic result and the optical properties of the overall restoration have demonstrated that when it is necessary to combine veneers and crowns at a minimal cost to the natural tooth structure, the best choice is the IPS e.max Press system, owing to its superb clinical performance, physical properties and reliability. With that knowledge, the treatment team is relieved of the dilemma of whether different thicknesses of the final restorations will yield a different aesthetic result.

The whole system has a much broader philosophy, that no matter what the base is (zirconia, metal substructure, pressed core), it does not affect the final result—a predictable aesthetic reconstruction of different core materials in a single arch.

Acknowledgement

I would like to acknowledge Andreja Protic for the fabrication of the ceramic restorations, laboratory photographs and material for this article.

_about the author	cosmetic dentistry
	<p>Dr Igor Ristić, after graduating in 1996, searched for the new frontiers and emerging trends in aesthetic dentistry and implantology. In 2001, he established his private practice, the Centre for Aesthetic Dentistry and Implantology in Belgrade, Serbia. He loves teaching treatment planning and various clinical procedures nationally and internationally, through lectures, hands-on training and workshops with a focus on all-ceramic and implant restorative procedures. He is a certified member of the European Society of Cosmetic Dentistry board and an affiliate member of the International Academy for Dental-Facial Esthetics. He can be contacted at igor@iristic.com.</p>



1st ASIA - PACIFIC EDITION 7th CAD/CAM & Computerized Dentistry International Conference

06 - 07 October 2012, Marina Bay Sands Hotel, SINGAPORE



THE STARS IN COMPUTERIZED DENTISTRY

NEW

Theatre Presentation

One-visit chairside dentistry:
How to make CAD/CAM
Restorations Esthetic
and Durable in Clinical Practice



*Dr. Michael Dieter,
Germany*



*Joerg Voegt,
Germany*



*Dr. Andreas Kurbad,
Germany*

- Computer Navigated Implantology
- Esthetic Engineering



*Dr. Simon Smyth,
UK*

- Everyday CAD/CAM Usage: Preparation, Practicality & Possibilities, What Benefits You and Your Practice
- Further Possibilities of CAD/CAM: One Visit Smile Makeovers and Permanent Bridges Chairside



*Dr. med. dent. Peter Gehrke,
Germany*

- Two-Piece CAD/CAM Zirconia Implant Abutments
- Optimizing Implant Function & Esthetics at the Perio-Prosthetic Interface: The Role of the Superstructure

PLATINUM SPONSOR



GOLD SPONSOR



OFFICIAL SPONSORS



ORGANIZED BY



PROUD SUPPORTER



HELD IN



SUPPORTED BY



OTHER INDUSTRY PLAYERS



www.capp-asia.com

www.facebook.com/cappasiapacific

Dentine hypersensitivity: Simplified

Author_Dr Fay Goldstep, Canada

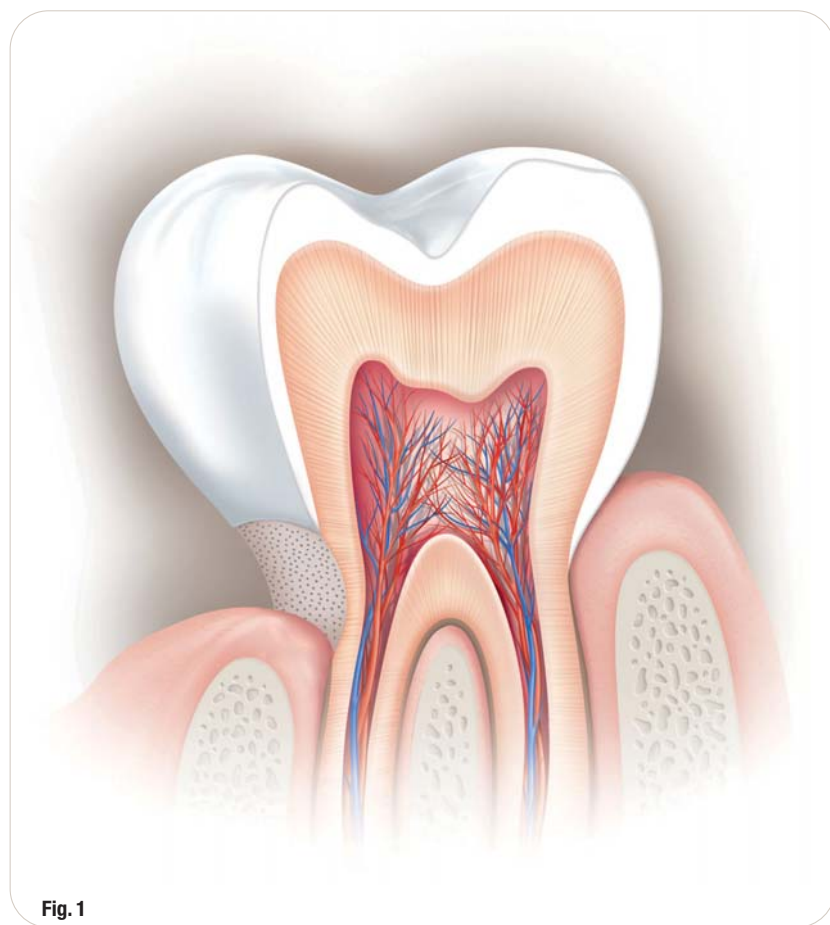

Fig. 1

Fig. 1 The essential components of dentine hypersensitivity are exposed dentine surfaces with open patent tubules leading to a vital pulp. (Image courtesy of GSK)

All dental practices have patients with dentine hypersensitivity. Many patients avoid dental treatment because of their hypersensitivity. Surprisingly, most practices do not have a systematic approach for diagnosing and treating this condition. This is simply because it seems too complicated. There is a multitude of products. What works? Why does it work? Many practitioners have had poor success in the past with sensitivity treatments and are reluctant to try again. Today's products are effective and easy to use. The following discussion will attempt to bring simplicity and clarity to the subject of diagnosis and treatment of dentine hypersensitivity.

Definition

Dentine hypersensitivity is defined as a short sharp pain arising from exposed dentine in response to:

- _ thermal change,
- _ evaporation of air,
- _ tactile stimulus,
- _ osmotic pressure or
- _ chemical stimulus

and cannot be ascribed to any defect or pathology.¹

The three essential components of dentine hypersensitivity are (Fig. 1)²:

1. exposed dentine surfaces;
2. open tubule orifices on the exposed dentine surfaces;
3. patent tubules leading to vital pulp.

Dentine hypersensitivity has been reported to affect up to 57 % of the general population.³⁻¹⁰ It occurs most frequently in patients of 30 to 40 years of age.¹¹ All teeth are susceptible but canines and premolars are the most affected.^{12,13}

A 2002 international survey of 11,000 adults revealed that only half of the affected individuals had talked to their dentist about their sensitivity and only half of this group actually received treatment recommendations.¹⁴ Many patients do not wish to burden the dentist with this problem, or they may feel that it may not be taken seriously.

Mechanism of action

The most widely accepted theory for the mechanism that causes dentine hypersensitivity is the hydrodynamic theory first proposed by Brännström in 1963.¹⁵ When dentinal tubules in vital teeth are exposed and open, the fluid in the tubules flows in an inward or outward direction, depending on pres-

Active ingredient	Benefits and indications	Delivery	Product examples
Fluorides	Some efficacy. Stannous fluoride best. For mild sensitivity where patient also has gingivitis.	Toothpaste/at home	Crest Pro-Health (Procter & Gamble)
Fluoride varnishes	Some efficacy. For mild sensitivity where patient also requires anti-caries effect.	Varnish/in office	Vanish XT Extended Contact Varnish Vanish 5 % Sodium Fluoride White Varnish (all 3M ESPE) X-PUR White Varnish (Oral Science)
Tissue fixatives (glutaraldehyde or HEMA)	Strong efficacy. Place away from gingiva.	Liquid/in office	GLUMA Desensitizer (Heraeus)
Oxalates	Strong efficacy. Fast onset. Lasting.	Liquid/in office	Super Seal (Phoenix Dental)
Novamin	Strong efficacy. Cumulative onset. Remineraliser.	Toothpaste/at home	X-PUR (Oral Science) Sensodyne Repair and Protect (GlaxoSmithKline)
Recaldent	Strong efficacy. Cumulative onset. Remineraliser.	Extra paste/at home	MI Paste MI Paste Plus (GC Europe)
Pro-Argin Technology	Strong efficacy. Fast onset. Lasting.	Paste/in office Toothpaste/at home	Sensitive Pro-Relief (Colgate)
5 % potassium nitrate	Strong efficacy. Cumulative onset. Best treatment for whitening sensitivity.	Toothpaste/at home Toothpaste/in tray/at home Gel/at home	Sensodyne (GlaxoSmithKline) Crest Sensitivity Protection (Procter & Gamble) Sensodyne (GlaxoSmithKline) Crest Sensitivity Protection (Procter & Gamble) Soothe desensitizer (SDI) Ultra EZ (Ultradent) Relief ACP (Discus Dental)

sure differences in the surrounding tissue. This fluid shift activates pain receptors in the intra-tubular nerves or superficial pulp and the patient feels pain (Fig. 2).²

Diagnosis

Prior to establishing the diagnosis of dentine hypersensitivity, one must first rule out other conditions that exhibit similar symptoms²:

- _caries;
- _pulpitis;
- _marginal leakage;
- _restoration fracture;
- _cracked tooth;
- _polymerisation shrinkage.

It is important to use specific clinical descriptors with the patient (like brief, sharp, localised) to differentiate dentine hypersensitivity from pulpal pain (which is prolonged, dull, aching, poorly localised and longer lasting).²

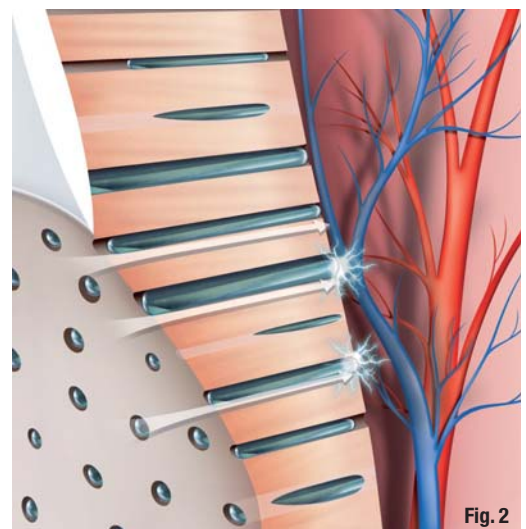
Risk factors for dentine hypersensitivity include¹⁶:

- _periodontal disease;
- _gingival recession;
- _para-function (abfractions);
- _acidic diet;
- _xerostomia;
- _bleaching.

These factors predispose the patient to the essential components of dentine hypersensitivity: exposed, open and patent dentinal tubules leading to vital pulp. There may also be passage of fluids through the enamel. The enamel may be thought of as a semi-permeable membrane that allows passage of fluids and small molecules through the organic defects between the enamel crystals. With time, the organic channels

Table 1 Treatment of dentine hypersensitivity.

Fig. 2 Fluid shifts in the dentinal tubules activate pain receptors to cause pain. (Courtesy of GSK)



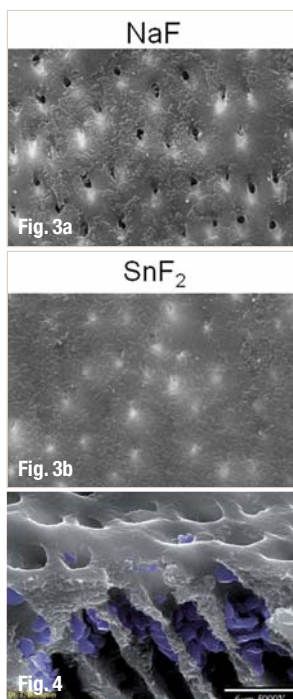


Fig. 3a & b In the concentrations used for toothpastes, stannous fluoride is more effective than sodium fluoride in occluding dentinal tubules.

(Courtesy of Procter & Gamble)

Fig. 4 Super Seal forms a complex with the calcium of the peri-tubular dentine to create a crystal plug across the dentine tubules.

(Courtesy of Tammy Bonstein)

become plugged owing to the formation of organic biofilm. When this occurs, the bidirectional flow of fluids stops and so does the pain. During bleaching, the organic plugs may be dissolved, reopening the enamel channels and causing sensitivity.¹⁷

Treatment

The first line of treatment for dentine hypersensitivity is of course prevention. All of the predisposing factors must be dealt with first. This may not be an easy task. Periodontal disease, recession, occlusal forces and diet present many challenges. The treatment of sensitivity is much simpler in comparison.

If we review the mechanism of action of dentine hypersensitivity, it is easy to understand the wide range of products available for treatment. The product must either block the movement of fluid in the tubules or stop the transmission of the pain response to the pulp. For added simplification, it is important to focus on the active ingredient, and not on the multitude of products (Table I).

Products are available for in-office or at-home application. Treatment should not be restricted to one option only. This is not a one-size-fits-all solution. Different treatments may be tried and modified based on the patient's response.

The first group of products works by occluding the open tubules and decreasing pulpal fluid flow. This group includes fluorides, fluoride varnishes, tissue fixatives, oxalates, remineralising agents and Pro-Argin Technology. The second group of products works by depolarising the nerve so that it cannot transmit the pain response.

Occlusion of dentinal tubules

Fluorides

Fluoride application is believed to work through a reaction between the fluoride ion and ionised calcium in the tubular fluid. This reaction forms an insoluble calcium fluoride precipitate in the tubule.¹⁸ Different fluorides show differing efficacies. Stannous fluoride is more effective than sodium fluoride in the concentrations used for toothpaste formulations (Fig. 3a & b).

Fluoride varnishes

Fluoride varnishes may be used for sensitivity relief but are chiefly indicated for caries control and remineralisation. The desensitisation effect is transient, since the material is abraded soon after placement. Many applications may be necessary for increased efficacy. It is thought that the benefit comes from the

physical blockage of the tubules by the varnish base rather than the fluoride itself.¹⁸

Tissue fixatives

Tissue-fixative desensitising products contain agents such as glutaraldehyde or HEMA. These agents bind to tissue fluid proteins in the dentinal tubules and the superficial cells of the subadjacent pulp and denature (coagulate) these proteins. These products cannot be placed near the gingival epithelium, since they may cause necrosis of the gingiva, as well as loss of the biological attachment.¹⁷

Oxalates

Desensitisers containing metallic salts, predominantly oxalates, form insoluble chemical precipitates in the peri-tubular dentine. No acid etch or light curing is needed. They cause no irritation of the gingival tissue. One example is Super Seal (Phoenix Dental). Super Seal forms a complex with the calcium-rich zone of the peri-tubular dentine to create a crystal plug. This effectively shuts down dentine sensitivity almost entirely (Fig. 4).¹⁹

Remineralising pastes

Remineralising pastes are used in the office or at home to restore the minerals that have leached out of patients' teeth owing to caries, diet, etc. These pastes have the added advantage of reducing sensitivity through tubule occlusion. Two active ingredients have been shown to be the most effective for this purpose:

1. Novamin (calcium sodium phosphosilicate bio-active glass) and amorphous calcium phosphate: Novamin-containing toothpastes have been shown to reduce dentine hypersensitivity significantly, with continued home use.^{20,21} The effect is cumulative up to about six weeks and then stabilises.
2. ACP: ACP forms a protective mineral barrier of hydroxyapatite that occludes the exposed dentinal tubules (Fig. 5a & b).²² ACP is most effective in the form called Recaldent (casein phosphopeptide-amorphous calcium phosphate) in which the casein portion (derived from milk) binds the ACP to the tooth surface, where it can do its job. Recaldent-containing pastes are placed on the affected areas after regular brushing.

Pro-Argin Technology

In healthy patients, saliva is normally very effective in reducing dentine hypersensitivity. Saliva provides calcium and phosphate, which over time occlude open dentine tubules. Pro-Argin Technology was developed based on this role that saliva plays in naturally reducing hypersensitivity.^{23,24}

The Pro-Argin formula contains arginine, an amino acid found in saliva. The positively charged arginine binds to the negatively charged dentine surface. This attracts a calcium-rich layer from the saliva to infiltrate and block the dentinal tubules (Fig. 6).¹⁶

This technology is available for in-office application, through a paste that is delivered by prophylaxis cup. There is also a toothpaste for at-home use. The in-office paste has been found to provide immediate and lasting relief of hypersensitivity for four weeks when it is applied as the final polishing step of a professional cleaning.²⁵ It has also been found to decrease dental prophylaxis discomfort when used prior to the procedure.²⁶

Depolarisation of the nerve

The second major group of desensitisation products works by depolarising the nerve that transmits the pain response. After the nerve has been depolarised, it cannot re-polarise and this diminishes its excitability. The ingredient that produces this effect is potassium nitrate.²⁷ According to the FDA, for a potassium nitrate toothpaste to claim to be desensitising it must contain 5% of the ingredient. Potassium nitrate penetrates the enamel and dentine to travel to the pulp and exerts a calming effect on the nerve. This effect can be thought of as anesthetic-like.²⁸

Potassium nitrate products are ideal for whitening sensitivity. Whitening sensitivity occurs due to the easy passage of peroxide through the enamel (a semi-permeable membrane) and dentine to the pulp. Desensitisation products that work by occluding the dentinal tubules are ineffective in preventing the passage of the tiny peroxide molecule, which can travel in the interstitial spaces between the tubules.²⁸

Potassium nitrate can be delivered in several effective ways to counteract whitening sensitivity:

1. Pre-brushing with a 5 % potassium nitrate toothpaste for two weeks pre-whitening and during whitening: It takes approximately two weeks for the potassium nitrate to be at peak desensitisation efficacy.²⁹
2. Whitening tray delivery of a potassium nitrate toothpaste for ten to 30 minutes during whitening treatment: This appears to be very effective for more acute sensitivity.²⁸ It is preferable to use a toothpaste without sodium lauryl sulphate, which is the primary ingredient in most toothpastes, and creates the effect of foaming. Sodium lauryl sulphate has been associated with increased gingival irritation, especially on prolonged contact.
3. Syringe delivery of potassium nitrate and fluoride: The material is applied as needed for specific areas of sensitivity.

4. Potassium nitrate incorporation into the whitening gel itself: Bleaching efficacy does not appear to be affected by this addition.³⁰

Conclusion

Treatment of dentine hypersensitivity is a simple, clear process. It starts with a differential diagnosis, ruling out other possible aetiologies like caries, pulpitis, cracks, marginal leakage, etc. Next, an attempt is made to eliminate predisposing factors such as periodontal disease, para-function, acidic diet and xerostomia.

At the same time, the patient is evaluated with respect to the potpourri of potential desensitisation ingredients and the products that contain them. It is essential for the dental practitioner to be familiar with these ingredients, their mechanisms of action, benefits and indications. Some patients may require more than one type of treatment. The treatment is fine-tuned until a successful solution is found. There is no longer a reason for any patient to endure dentine hypersensitivity. Simple answers have been found to this long-time problem, and the dentist has gained a patient for life.

Editorial note: A complete list of references is available from the publisher.




Fig. 5a & b ACP forms a mineral barrier of hydroxyapatite, which occludes the exposed dentinal tubules. (Courtesy of GC)

Fig. 6 The Pro-Argin formulation attracts a calcium-rich layer from the saliva to infiltrate and block the dentinal tubules. (Courtesy of Colgate)

about the author cosmetic dentistry



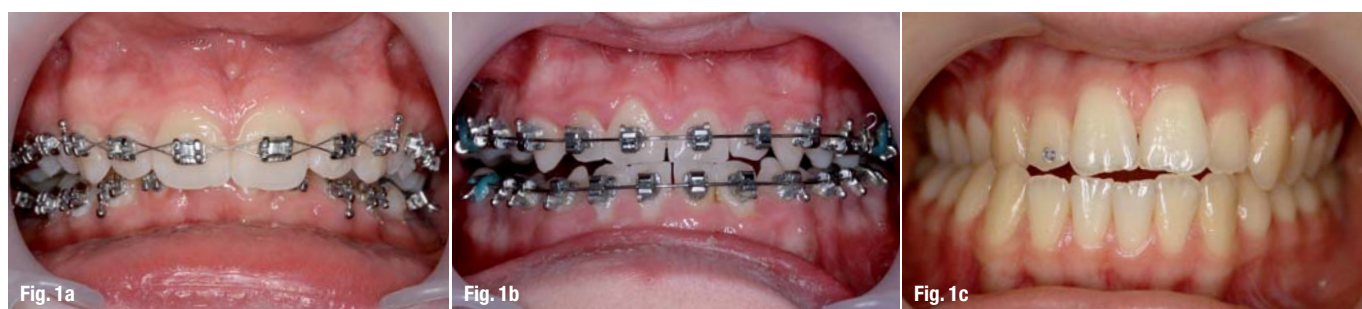Dr Fay Goldstep has been a featured speaker in the ADA Seminar Series, and has lectured at the American Dental Association, Yankee, American Academy of Cosmetic Dentistry, Academy of General Dentistry, and the Big Apple dental conferences.

She has lectured nationally and internationally on Conservative dentistry, innovations in hygiene, dentist health issues, magnification and office design. She has served on the teaching faculties of the postgraduate programmes in Aesthetic Dentistry at SUNY Buffalo, University of Florida, University of Minnesota and University of Missouri-Kansas City. She has been a contributing author to three textbooks and has published more than 20 articles. She is a Fellow of the American College of Dentists, International Academy for Dental-Facial Esthetics and Academy of Dentistry International.

She sits on the editorial boards of the *Oral Health Journal* (healing/preventive dentistry) and *Dental Tribune US Edition*. She has been listed as one of the leaders in continuing education by *Dentistry Today* since 2002. Dr Goldstep is a consultant to a number of dental companies and maintains a private practice in Toronto, Canada.

Aesthetics and function: Orthodontic–surgical collaboration as a key to success

Authors_Drs Martin Jaroch & Friedrich Bunz, Germany



Figs. 1a–c Deep bite, prognathism and latero-gnathia: according to clinical evaluation, they can be resolved only through interdisciplinary treatment.

_Oral surgery is an important cornerstone in orthodontic treatment of malocclusions. Tooth movement is only possible to a limited extent and always depends on the misalignment of the maxilla and mandible in relation to each other, as well as on deformities of the jaw in relation to the other facial bones. Abnormalities may be congenital or acquired and may affect patients in childhood already. If so, the focus of orthodontic treatment is not primarily in the aesthetic correction, but is guided by functional and prophylactic concerns.

Efficient occlusion and restoration of masticatory function are decisive factors for tooth preservation and prevention of secondary disorders (Figs. 1a–c). Without a doubt, aesthetic improvement, as well as the associated self-consciousness, is the main concern of most patients, which can be pursued through surgical correction.

_Causes of malocclusion

Generally, patients visit an orthodontic practice only after symptoms or significant abnor-

malities have already presented. Clinically, this results in late mixed dentition or permanent dentition, which can complicate an accurate mapping of the reasons for this malocclusion.

In the literature, the causes of malocclusion and the aetiological structure of the symptoms of malocclusion in orthodontic patients are controversial issues. No explicit information on the percentage of patients with acquired or congenital malocclusions can be found in a study by Schopf (1981) on the exogenous factors that are involved in the development of malocclusion. However, from the assessment of individual patients' symptoms, all symptoms of malocclusion could be associated with exogenous aetiological factors only in 48 % of patients. Brodmann and Saekel (2001) concluded from Schopf's report that only 20 % of the anomalies were hereditary and thus could not be affected by prophylactic interventions. Accordingly, 80 % of malocclusions could be resolved through prevention and better oral hygiene. This idea is contrary to the results of the German Oral Health Study. In this study, a decrease in childhood caries was observed. However, clinically these results were not



Fig. 2a

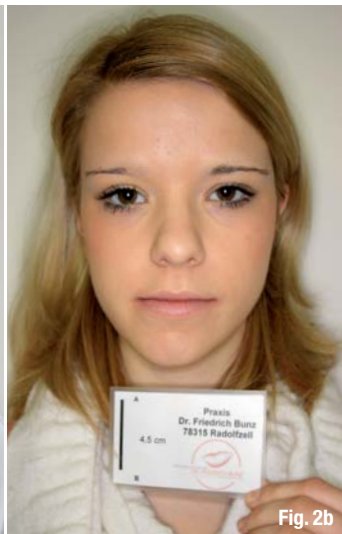

Fig. 2b

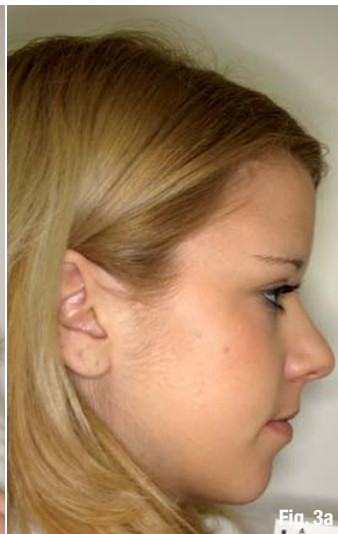

Fig. 3a



Fig. 3b

associated with a lower rate of and need for orthodontic treatment. The study at the University of Greifswald, Germany, found that 20.3% of the symptoms were genetically determined, 44.3% were exogenous and 35.3% were not precisely defined. Based on these results, the assumption that 80% of malocclusions can be resolved by prevention and better oral hygiene is very questionable (Hensel, DGKFO opinion, 2001).

The varying findings and remarks illustrate the difficulty of clear classification of malocclusion. Nonetheless, the demands of the patient have priority and he expects a symptom-based therapy with stable treatment results. This means that in malocclusion cases that cannot be resolved by functional orthodontics solely, orthodontic-surgical planning can be done before any treatment is attempted by pure dentoalveolar compensatory intervention. Compensatory dentoalveolar procedures could prevent a surgical operation. At the same time, patients may run the risk of protracted treatment without any long-lasting benefit. The decision for or against orthopaedic surgery requires interdisciplinary agreement and reliable treatment goals must be defined in advance (Figs. 2a & b).

Target group for orthopaedic surgery

Nowadays, adults make up the majority of patients in the orthodontic practice. They are generally motivated by high socio-cultural demands and the desire for perfect teeth. In adults who have an obvious discrepancy between their maxilla and mandible, it must be clarified whether the deformities are dentoalveolar or skeletal.

Owing to the limitations of conventional orthodontic treatment, skeletal discrepancies can rarely be entirely resolved. In those cases, combined orthodontic-surgical treatment is necessary. During growth, it is mostly possible to treat malocclusions successfully without surgery by purely orthodontic treatment using removable appliances or brackets.

Children and young people for whom functional orthodontic treatment has not led to the desired result are treated surgically after the growth period. Early surgery always carries the risk of unexpected growth pattern or unilateral abnormal hyperplasia and can affect the results of the operation.

Figs. 2a & b Significant changes between the initial assessment of latero-gnathia in 2007 (a) and the beginning of combined orthodontic-surgical treatment in 2011 (b; 19-year-old patient).

Fig. 3a Side view of a 19-year-old patient: latero-gnathia is visible in the lower lip area.

Fig. 3b Frontal view: latero-gnathia to the right and the resulting deviation is clearly visible.

Figs. 4a-c Orthodontic, prepared pre-op diagnostic radiology (orthopantomograph, cephalometric radiograph and antero-posterior projection) of the now 20-year-old patient.

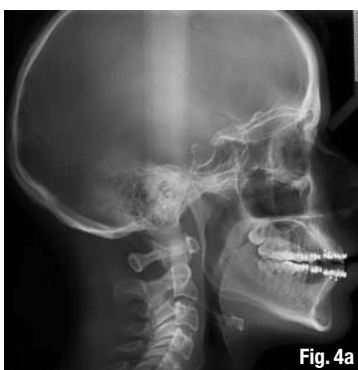

Fig. 4a

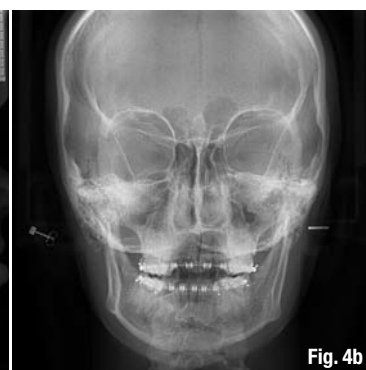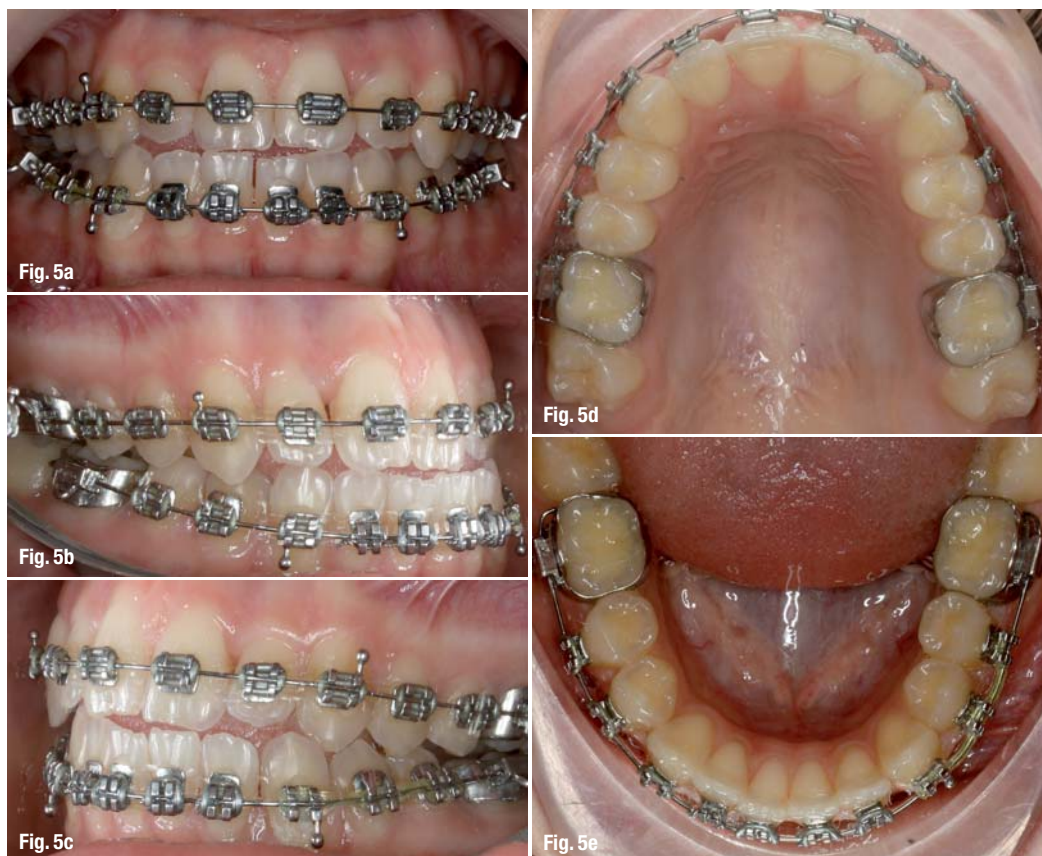


Fig. 4b

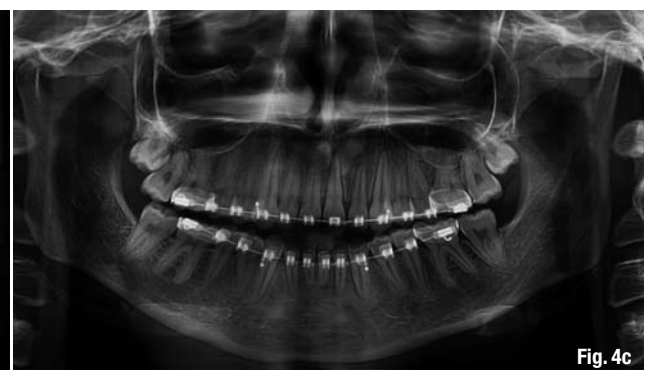

Fig. 4c

Figs. 5a–e_Pre-op clinical situation after orthodontic preparatory work.



Selection of patients

Combined orthodontic–surgical treatment requires not only strong and focused interdisciplinary collaboration, but also absolute acceptance of the treatment plan by patients and parents. The treatment is time-consuming and post-operative corrections cannot be excluded.

A detailed medical preoperative discussion should inform patients about the risks of combined treatment and the consequences of untreated malocclusions. Malocclusions can cause numerous side-effects, such as back pain and chronic headaches (Figs. 3a & b). In markedly dolichofacial face types, malocclusions can lead to a pharyngeal constriction, which can manifest as obstructive sleep apnoea syndrome (Hochban et al. 1997).

In adult patients, it is normally useful to determine the amount of malocclusion and force bite using a flat-plane bite splint. The splint is worn for six to eight weeks, and guarantees the identification of the physiological condylar position.

Pursuing orthodontic correction depends on the intended post-operative situation. Therefore, such correction is only dentoalveolar and

does not transfer bite forces (Figs. 4a–c & 5a–e). The most favourable position of the maxilla and mandible is assessed on the basis of simulated cast surgery in which the amount of shift is determined. Using these casts, a splint can be fabricated and placed during surgery to fix the determined physiological condylar position pre-operatively (Figs. 6a–c).

Teenagers with mandibular asymmetry that cannot be clearly classified should be treated with special care. Should clinical records be available only from the age of 16—whether as a result of erroneous dental records or simply owing to late initial assessment in a specialised practice—accurate early diagnosis of potential unilateral hyperplasia with further growth tendency is essential.

According to the German Society of Oromaxillofacial Surgery guidelines, a nuclear medicine diagnostic is necessary—in addition to inspection, palpation and radiography—to determine the risk of an abnormal growth in time. Through increased uptake in the affected region during scintigraphy, it is possible to draw conclusions about the growth's behaviour. If the jaw continues to change by abnormal bursts of growth, it is advisable to postpone surgical therapy until the cessation of growth.

Surgical technique

The choice of technique for the osteotomy depends on various factors. In displacement osteotomy, surgical access to the bone is created, which is split at fixed points. Correction of the bone and bone healing in the new fixed position is accomplished using simulated cast surgery and a fabricated splint.

Following surgical modification of the jaw area, it is important to consider the correct position of the jaw and optimal occlusion. This crucial step has to be performed by the orthodontist as accurately as possible because repositioning and the degree of displacement of the jaw depend on achievable occlusion. Furthermore, teeth have an influence on access to the surgical field and wisdom teeth must be removed before osteotomy in certain cases.

Osteotomy can be done on both jaws or can be limited to the maxilla or mandible. However, in many cases it is functional to perform bimaxillary osteotomy and to shift both jaws. Today, generally the entire tooth-bearing portions of the jaw are shifted.

Segmental osteotomy has not been proven to be very successful in the past and corrections of malocclusions are left to the orthodontic treatment partners. In this field of treatment, the Obwegeser–Dal Pont surgical technique is recommended. This procedure describes an intra-oral stepped osteotomy at the mandibular ramus (Figs. 7a & b). Since Bell and Epker described the possibility of bimaxillary surgery as the "down fracture" technique in 1975, it has been popular




Fig. 6a

and today you can find it mostly as a combination of Obwegeser–Dal Pont and Le Fort I osteotomy.

The bimaxillary approach seems reasonable, since the maxilla and mandible influence each other during growth. However, it is frequently only possible to obtain a very good and risk-free result by using Obwegeser–Dal Pont surgery. Fixation in split osteotomy of the mandible is usually realised by using minimally invasive plate osteosynthesis. In modified techniques of Obwegeser–Dal Pont surgery, a displaced ramus is fixed using osteosynthesis screws only (Hochban 1997; Figs. 8a & b). This modification avoids the complicated surgical removal of osteosynthesis plates.

Fig. 6a View of the casts in the articulator after successful simulation of surgery.

Figs. 6b & c Intra-op fixation of the splint for correction of latero-gnathia after osteotomy.

Figs. 7a & b Illustration of Obwegeser–Dal Pont osteotomy of the 20-year-old patient: split osteotomy of the intra-oral ramus is clearly visible.

Figs. 8a & b Intraoperative view of osteosynthesis screws inserted during surgery of the 20-year-old patient.

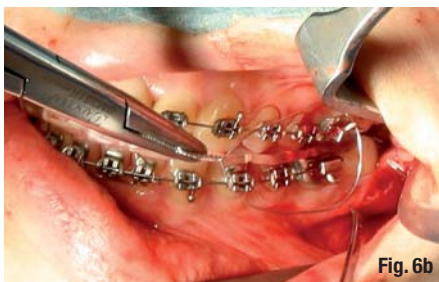

Fig. 6b

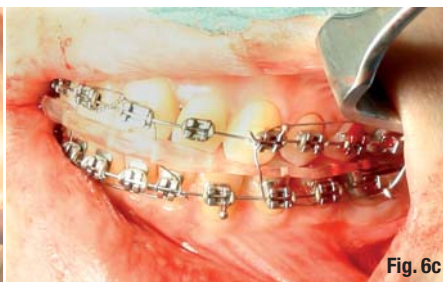

Fig. 6c

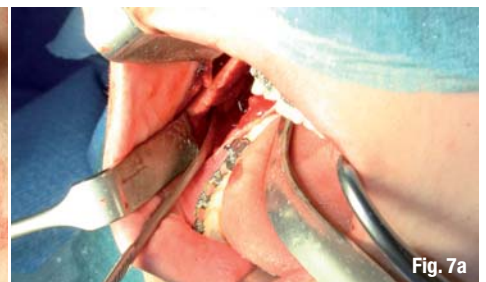

Fig. 7a

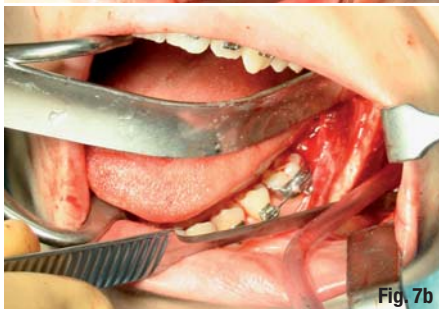

Fig. 7b

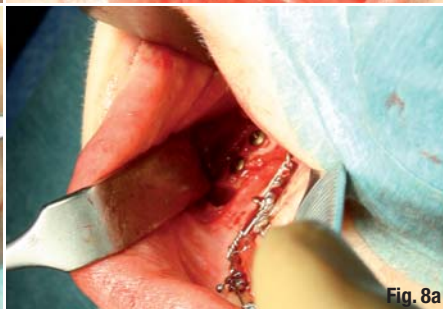
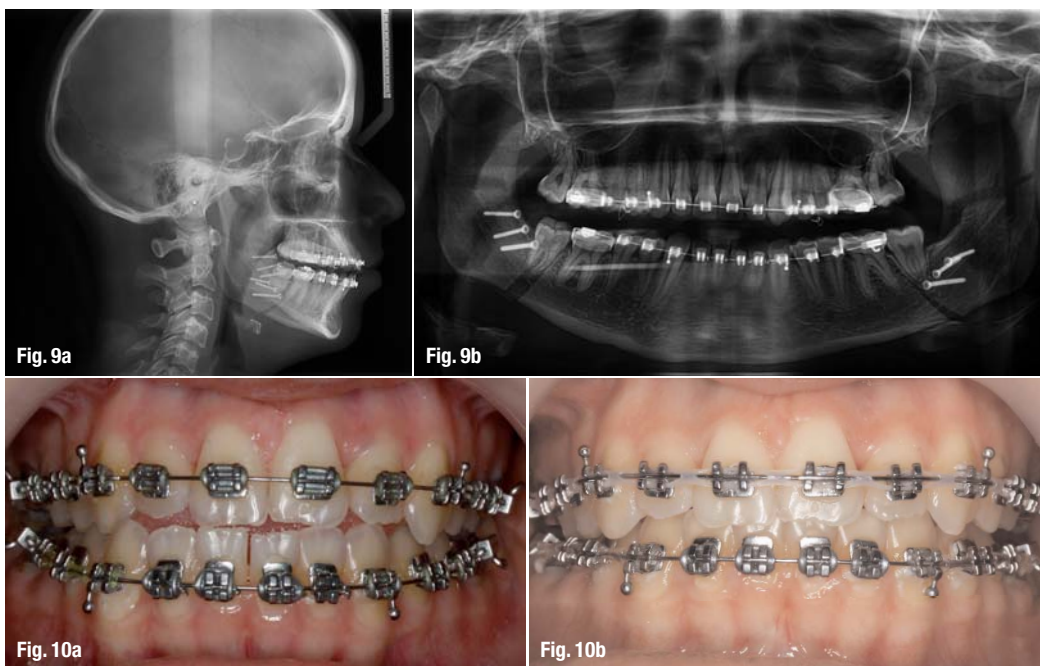


Fig. 8a

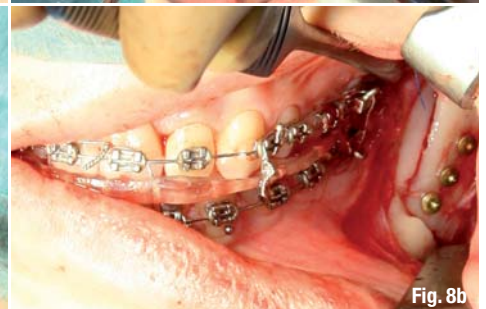

Fig. 8b

Figs. 9a & b_Post-op X-ray diagnostics (orthopantomograph, cephalometric radiograph). Intensive shift of the mandible can cause temporary sensitivity disturbances in the area of the lower lip and chin, which improves rapidly in most cases.
Figs. 10a & b_Pre-op view (a) and post-op view (b). Significant improvement in lateral occlusion and the elimination of latero-gnathia is clearly visible.



_Operation risk

Any surgical procedure can lead to unexpected complications, which must always be considered according to the risk-benefit principle. Today, the need for osteotomy remains controversial because a jaw deformity is not a serious illness like a tumour, abscess or bone fracture, which is necessarily treated by surgery.

Since deformities are often aesthetic corrections and can be classified as elective procedures, operation safety is a chief concern. Isolated osteotomies of the mandible, which present a significantly lower surgery risk, should be the first choice for orthodontic-surgical interventions.

The most significant risk of osteotomy of the mandible is a probability of about 5% of damaging the sensory nerve, called the inferior alveolar nerve. This can cause sensibility problems of the lower lip and chin area (Figs. 9a-c). Additional serious risks are not expected using Obwegeser-Dal Pont surgery and post-operative bleeding can be controlled very safely.

_Interdisciplinary collaboration

The literature review of work done in the 1970s makes clear that today's conscientious collaboration between surgeons and orthodontists is not a matter of course. Over the years, orthognathic surgery was considered to be the last option for treating orthodontic cases that could not be resolved using standard treatment techniques. Therefore, operations were carried

out based on tolerance of dentoalveolar compensation and likely made further corrective surgery more probable.

Today, in almost all cases of malocclusion, orthodontic treatment is preceded by surgical treatment. Nowadays, the planning of the operation based on simulated cast surgery and the creation of a splint is a very safe method by which to achieve predictable and stable long-term results (Figs. 10a & b). Individual dentoalveolar discrepancies in occlusion can be corrected preoperatively or post-operatively by orthodontic treatment. Therefore, interdisciplinary collaboration is always a benefit for the patient and treatment team.

_contact		cosmetic dentistry
	Dr Martin Jaroch Aesthetic and Function Dr Bunz—Dr Jaroch & Partner Professional Practice of Orthodontics Teggingerstr. 5 78315 Radolfzell, Germany	
	Dr Friedrich Bunz Aesthetic and Function Dr Bunz—Dr Jaroch & Partner Professional Practice of Orthodontics Teggingerstr. 5 78315 Radolfzell, Germany	

Cyprus
28-29/09/12

INTERNATIONAL CONGRESS IN IMPLANTOLOGY AND ESTHETIC DENTISTRY

LECTURERS

OLIVER BRIX

Germany

DANIEL EDELHOFF

Germany

EGON EUWE

Italy

VASILI KAITAS

Italy

ANGELO PUTIGNANO

Italy

ISTVAN URBAN

Hungary

PANOS BAZOS

Greece

GEORGE GOUMENOS

Greece

STAVROS PELEKANOS

Greece

ILIA ROUSSOU

Greece

Hilton Park Nicosia

Griva Dighenis Avenue,
Nicosia, Cyprus 1507

Web: nicosia.hilton.com

Information & Registration for Greece:

Omnipress

Tel: +30 210 222 2637 +30 210 213 2084

info@omnicongresses.gr

www.omnicongresses.gr www.omnipress.gr

ORGANIZED BY

FIDENTALMED Ltd

SPONSORS

**ivoclar
vivadent**

DENSPLY
FRIADENT

Hu-Friedy
How the best perform

W&H

MEDIA SPONSORS

dti Dental
Tribune
International

Smile
Dental
Magazine

Ethical smile design with the Inman Aligner— A case study

Author_Dr Andrew Wallace, UK

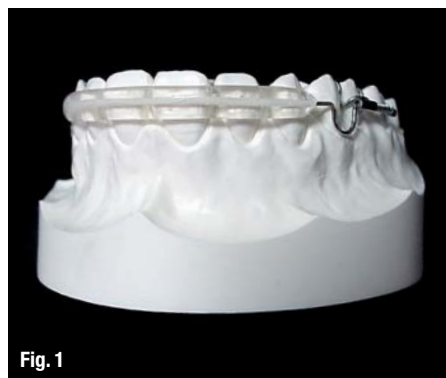

Fig. 1

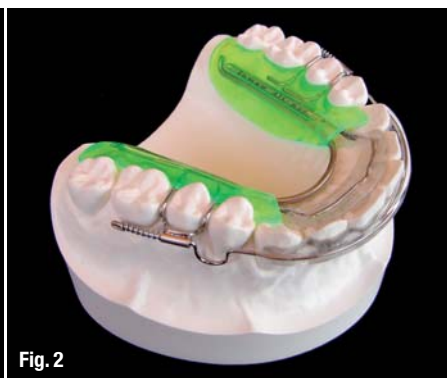

Fig. 2

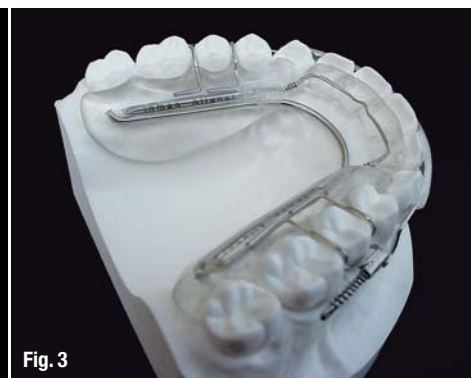

Fig. 3

Fig. 1 _Upper jaw model with Inman Aligner *in situ* (not the presented patient).

Fig. 2 _Coloured Inman Aligner on the model.

Fig. 3 _Inman Aligner on the model.

There has probably never been a better time to practise dentistry. However, dentists and patients are being bombarded with images of beautiful smiles and, for many years, practitioners have been pressured into believing that porcelain veneers are the answer. There are many situations for which veneers are the ideal treatment, and when well placed and properly bonded to enamel, they will last for many years. Layton and Walton, for example, showed 73 % survival at 16 years for veneers bonded to enamel.

Unfortunately, in my practice, these ideal cases rarely come through the door. Most of the patients coming in for cosmetic dentistry do so for more severe problems. Crowding of the upper and lower

teeth is a common condition that adult patients would like improved. Porcelain veneers and 'instant orthodontics' designed to treat this will often lead to excessive enamel removal, risking pulp vitality and compromising bond strengths, or over-contoured restorations, which can compromise plaque control.

Poor root position will also compromise the emergence profile. The patient, who by now has also entered the restorative cycle, will require the periodic replacement of these veneers with more invasive restorations. Burke and Lucarotti showed the survival rate of veneers in England and Wales to be approximately 10.5 years. The Inman Aligner has proved to be a valuable appliance to help patients with misaligned anterior teeth.

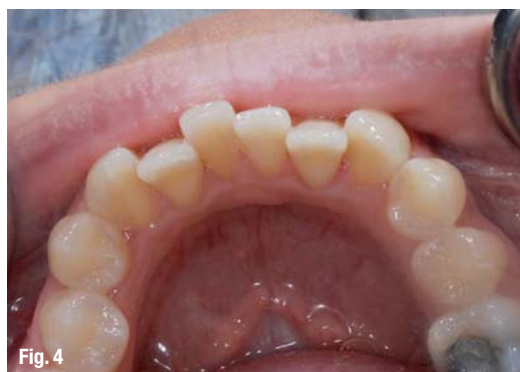

Fig. 4

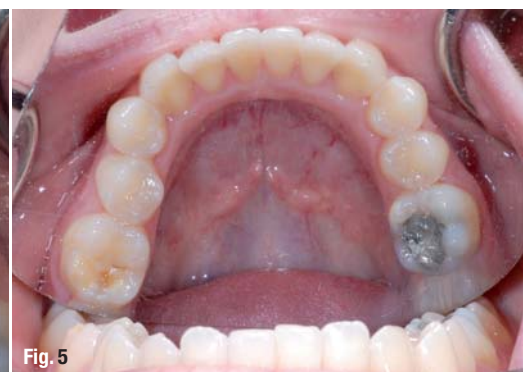

Fig. 5

Fig. 4 _Lower teeth initial situation.

Fig. 5 _Lower teeth view post-op.

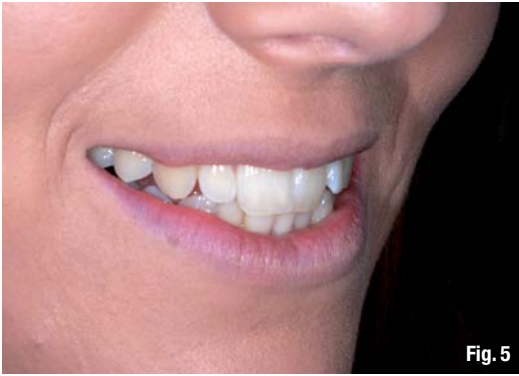

Fig. 5

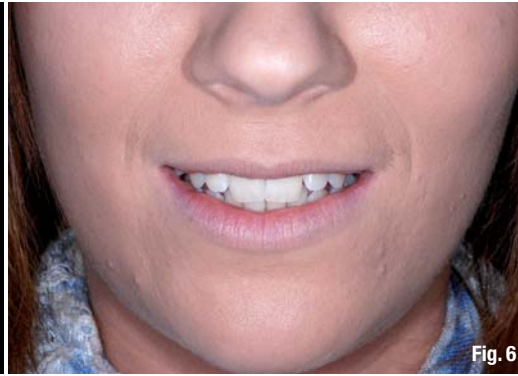

Fig. 6

Fig. 5_Side view pre-op.

Fig. 6_Partial face view pre-op.

The Inman Aligner works by employing dual forces –pushing and pulling simultaneously. The single, removable device utilises a lingual coil spring that exerts pressure on the teeth that need repositioning and a labial bar that reverses the same pressure. These components work together to squeeze teeth into place. Compared with traditional orthodontic braces, the Inman Aligner offers a more discreet, faster and less expensive way to achieve excellent results in the 'social six' region of the mouth, with average treatment times of between six and 18 weeks. The forces employed by the Aligner mean that it works a lot faster than the retainer-style treatment employed by other clear alignment systems, compensating for the fact that it is ever so slightly less discreet. However, the fact that the device is removable often makes up for this in the mind of the patient.

Of course, not every case is suitable for treatment in this way, and case selection is critical. The Inman Aligner is only suitable for correcting anterior teeth. Large side shifts, intrusions and extrusions cannot be treated in this way. However, rotations, tipping, buccolabial movements and diastema closures in protrusive cases are all possible, as long as case selection criteria have been met.

Patient

The patient, a 19-year-old woman, requested cosmetic improvement of her upper and lower teeth. Her chief complaint was that she was "unhappy

with her smile" and that her "front teeth were out of shape".

The patient attended her general dental practitioner regularly and had good oral health. Other than her aesthetic concerns, she displayed no dental complaints, and had no history of bleeding gums or sensitivity.

On further enquiry, she mentioned that she had considered having treatment to improve her smile for the last year and that she had a family wedding coming up in just over 12 months. The patient was happy with the shape of her upper and lower teeth but said that she would have liked them to be a little whiter and straighter.

On examination, it was ascertained that she had minimally restored dentition with a large silver amalgam filling in her lower left first molar, and some hypoplastic enamel in her upper right first molar. Her upper left first molar was missing, but there was no residual spacing owing to mesial movement of the second molar. Her lower third molars were unerupted with mesio-angular impaction. She had a thin scalloped gingival biotype.

The patient's lower incisor teeth had moderate crowding with good positioning of the canines. The upper incisors displayed mild crowding with the mesial edge of the upper right central incisor overlapping the upper left central incisor by 2 mm.

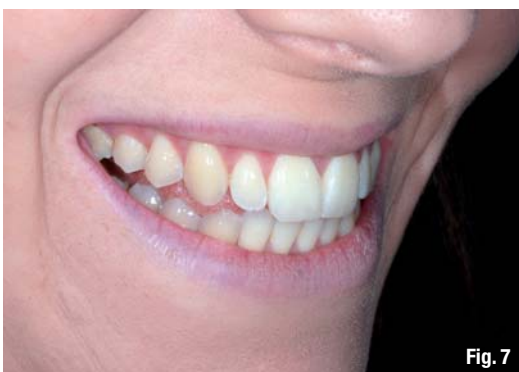

Fig. 7

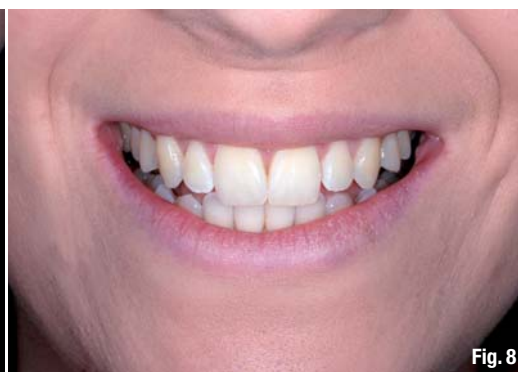
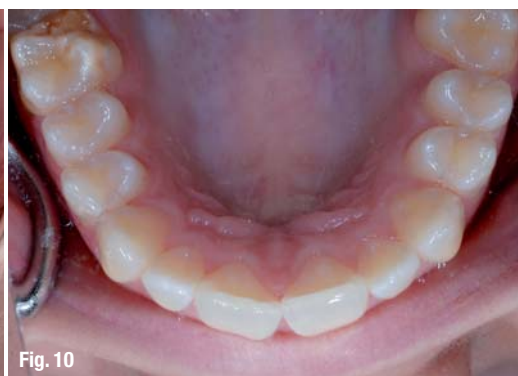
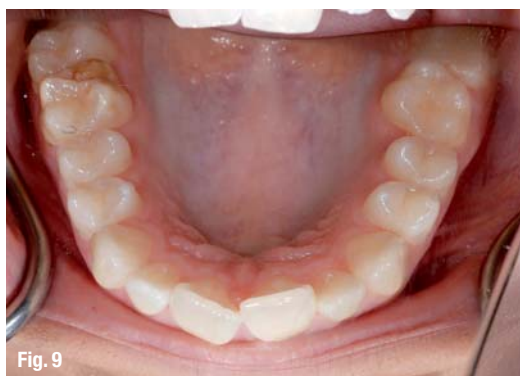Fig. 8

Fig. 7_Side view post-op.

Fig. 8_Partial face view post-op.

Fig. 9_Upper teeth view pre-op.
Fig. 10_Upper teeth mirror view after treatment.



A full discussion was undertaken about the possible treatment options, which were:

- _no treatment;
- _comprehensive orthodontic treatment;
- _fixed short-term orthodontic treatment;
- _removable alignment treatment; and
- _restorative treatment/instant orthodontics.

The patient did not want restorative treatment and dismissed the idea of crowns or veneers when we explained the excessive amount of enamel removal required. The patient was open to the idea of fixed bracket orthodontics but was much happier with a removable appliance for lifestyle reasons. We went into the specifics of interproximal enamel reduction (IPR) and the patient expressed that she was happy with this small amount of enamel removal to create space for tooth movement.

Treatment

A full set of clinical photographs was taken and upper and lower alginate impressions were recorded. The exact areas of the patient's smile that caused her concern were discussed using the photographs, and we discussed the tooth movements that would be possible with the alignment treatment.

Once the models had been cast from the impressions, we were able to assess the amount of crowding. This is done in a very simple fashion when using an Inman Aligner. The maximum width of each incisor and canine tooth is measured using a simple micrometer. Using an interproximal metal strip, the required space for the optimal arch form is then measured from the distal of one canine around to the contralateral canine. The difference is equal to the required amount of interproximal reduction and, for this young lady, it was found to be 1.21 mm.

Up to 3.5 mm of crowding can be treated with a standard Inman Aligner device just using IPR. More severe crowding can be addressed with an Inman Aligner incorporating a palatal expander.

An upper series of three clear aligners and a lower Inman Aligner were prescribed and the patient consented to the treatment as described. The models were sent to NimroDENTAL Orthodontic Laboratory, the UK's only Inman Aligner laboratory.

The Inman Aligner is fabricated on a Kessling model. The prescribed interproximal reduction is carried out on the plaster model. The teeth are removed and then replaced on the model in wax on the ideal arch form.

The first upper clear aligner and lower Inman Aligner were fitted on the same day. Extensive discussion was undertaken with the patient about what to expect over the coming days and weeks.

A small amount of interproximal reduction was undertaken using metal interproximal strips on all the interproximal surfaces of the lower teeth, from the mesial of the canines around to the contralateral canines, and on the upper teeth, as according to the laboratory instructions. IPR is carried out in this fashion to respect the anatomy of the tooth, simply making the teeth more slender.

The patient was seen every four weeks for the fitting of each of the upper aligners in the series, and to carry out further interproximal reduction on the lower teeth.

After three months, the upper alignment was complete and the lower teeth were almost straight. After four months, the alignment of the lower teeth was complete and impressions were taken for a fixed bonded retainer—a multi-strand stainless-steel retainer bonded to the palatal surface of the front six teeth with the aid of a custom placement jig. Owing to the type of occlusion, the patient continues to wear an Essix-type retainer on the upper teeth.

Discussion

This self-conscious young lady was concerned about the appearance of her teeth that were becom-

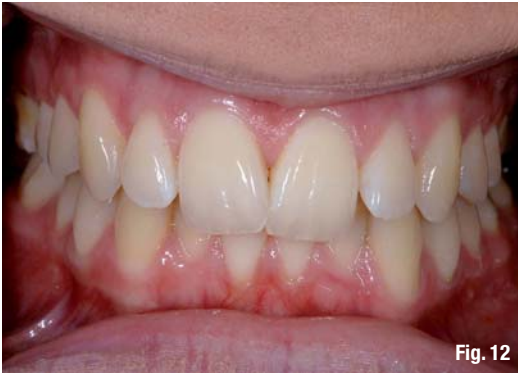

Fig. 12

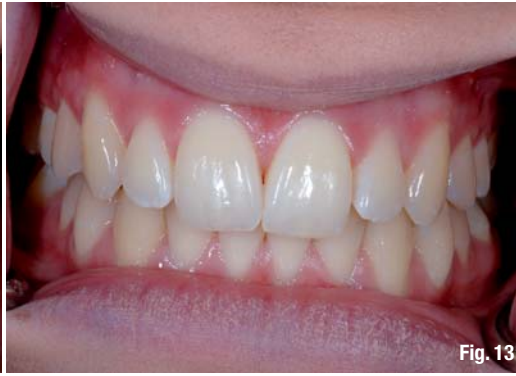

Fig. 13

Fig. 12_Retracted close up pre-op.

Fig. 13_Retracted view post-op.

ing increasingly more crowded. In four months, her upper and lower teeth were aligned for less than the cost of four porcelain veneers.

The photographs show the detail of the morphology and shade characteristics of the teeth—reproduction of this would have proved a challenge for even the most gifted dental technician.

Just a few years ago, the options open to the patient or her dental practitioner would have been limited to full orthodontic treatment or restorative treatment. The restorative options would have involved either excessive removal of enamel and dentine for porcelain veneers or excessively bulky and over-contoured restorations with poor interproximal contacts. Now, clinicians have the option of an altogether more satisfactory approach.

Alignment treatment such as that offered by the Inman Aligner can offer rapid cosmetic improvement of moderately crowded front teeth or orthodontic relapse. Because one appliance does almost all of the tooth movement, the reduced laboratory cost allows for a more affordable option for patients, increasing patient uptake.

Case selection is key and a full discussion with patients about their complaints and what they wish to have corrected is vital. Only correction of the front teeth is possible. Incisors can be rotated and tipped relatively easily, with limited movement of the canines possible.

The case study presented above was an ideal case. With others, it may be essential to talk the patient through what he or she can expect to be corrected and what will not be possible. Often, this form of treatment will be a precursor to restorative treatment. Pre-alignment can allow us to offer the ideal cosmetic result with a much-reduced biological cost in enamel and dentine removal, and an ideal emergence profile. Often only minor enameloplasty or enamel bonding is required after alignment to cor-

rect the differential wear we often see with crowded teeth.

IPR has been shown to be a safe way of creating space for tooth movement. Zachrisson followed up patients ten years after IPR and found no increased caries risk, bleeding on probing, gingival recession or periodontal bone loss in these patients.

The four-month treatment time required for this young lady is not unusual. The interdental space required is often created by rounding out the arch and moving teeth that are lingually placed, forward and placing them on a wider arc.

In conclusion, the Inman Aligner is not a replacement for conventional orthodontics but now clinicians can offer quick and affordable tooth alignment in general dental practice. My provision of cosmetic dentistry treatments has grown significantly since the introduction of the Inman Aligner to my practice.

Acknowledgements

I would like to thank Dr Tif Qureshi and Dr James Russell for their help in planning my early cases.

about the author

cosmetic
dentistry



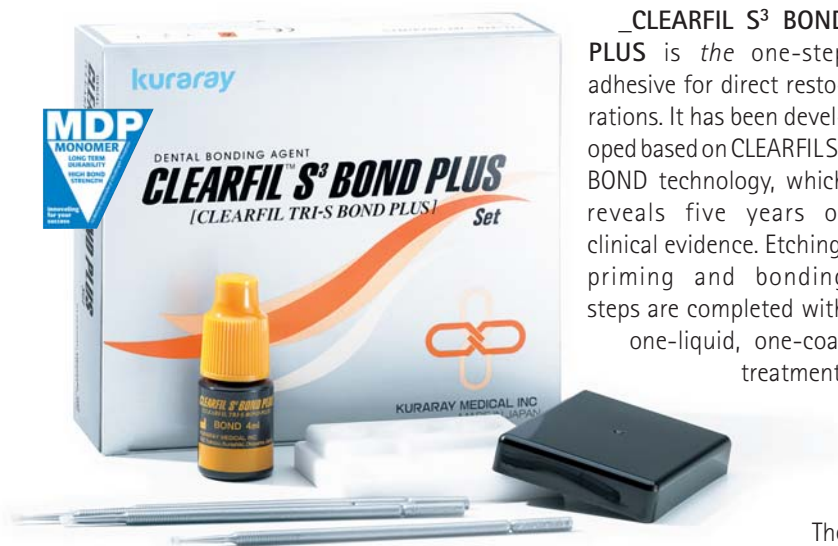Dr Andrew Wallace

gained his BDS from Queen's University Belfast in 1998. As well as practising full time in private practice in Bachelors Walk Dental Surgery, Lisburn, he is studying at King's College London for a Master of Clinical

Dentistry in Fixed and Removable Prosthodontics. He is a full member of the British Academy of Cosmetic Dentistry. He gained certification in Inman Aligner treatment through Straight Talk Seminars in January 2009.

CLEARFIL S³ BOND PLUS

High-tech and high speed for high performance



CLEARFIL S³ BOND PLUS is the one-step adhesive for direct restorations. It has been developed based on CLEARFIL S³ BOND technology, which reveals five years of clinical evidence. Etching, priming and bonding steps are completed with one-liquid, one-coat treatment.

CLEARFIL S³ BOND PLUS is easy and comfortable to use because time-intensive work steps, such as shaking the bottle, exact mixing and application of several components, multiple layering and rubbing in on the tooth surface, are no longer necessary.

The high bond strength of CLEARFIL S³ BOND PLUS is the result of two Kuraray innovative technologies: the high performance initiator and the proven MDP monomer. The new high performance initiator for light-curing improves clinical performance by building up more active radicals than conventional initiators and making the bond more impervious to water thanks to the increased polymerisation ratio.

The excellent bond strength to enamel and dentine of CLEARFIL S³ BOND PLUS marks a new standard among one-step adhesives, enabled by Kuraray's innovative adhesive technology, which has been successful for more than 30 years. Its fast and simple applica-

The integrated adhesive monomer MDP ensures a strong chemical bond to hydroxyapatite. In use for more than 25 years in successful products like PANAVIA F 2.0 and CLEARFIL SE BOND, the MDP monomer attains a high bond strength and reliable adhesive durability to tooth structure.

tion combined with its fluoride-releasing property makes CLEARFIL S³ BOND PLUS the ideal choice for all kinds of clinical situations, including paediatric therapy and core build-ups with the new CLEARFIL DC CORE PLUS. Furthermore, the system allows for precise and economic dosing.

The stable interface between tooth and composite resin is furthermore ensured by Kuraray's unique Molecular Dispersion Technology contained in CLEARFIL S³ BOND PLUS. The technology allows hydrophilic and hydrophobic components of the bond to be homogeneously combined—constantly. Thus, there is no phase separation, resulting in the formation of a homogenous layer on the preparation surface. The bond, showing no water voids, excels through its excellent bond performance.

CLEARFIL S³ BOND PLUS is always ready to use and will have users persuaded of its durable high bond strength.

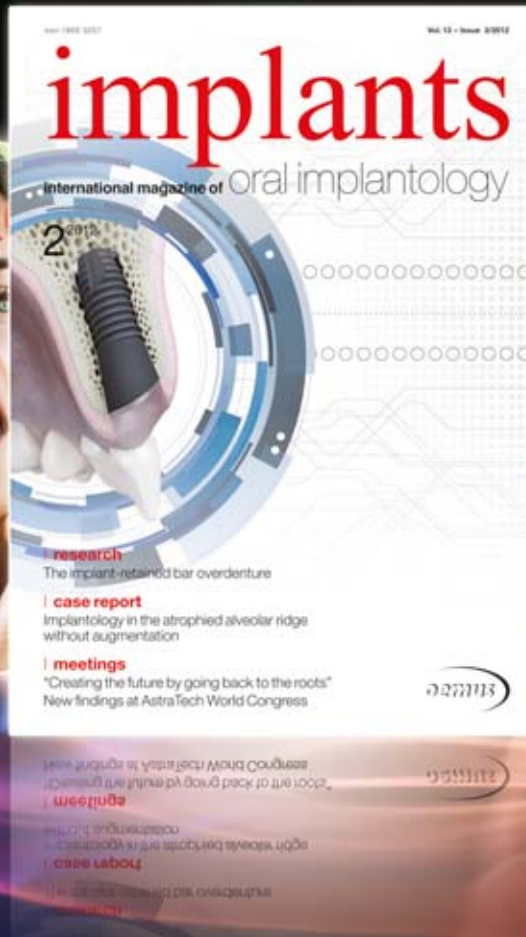
The main benefit of using one-step adhesives is to reduce technical errors, thanks to a short application time and simple handling. The time-saving procedure makes CLEARFIL S³ BOND PLUS ready for immediate use in only three short steps: apply, air-dry, light-cure—all done in less than 30 seconds.



_contact	cosmetic dentistry
<p>Kuraray Europe GmbH Industriepark Höchst, Building F 821 65926 Frankfurt/Main Germany</p> <p>dental@kuraray.eu www.kuraray-dental.eu (EU) www.kuraraydental.com (USA)</p>	

implants

international magazine of oral implantology



You can also subscribe via
www.oemus.com/abo

 **Subscribe now!**

I hereby agree to receive a free trial subscription of **implants international magazine of oral implantology** (4 issues per year).

I would like to subscribe to **implants** for € 44 including shipping and VAT for German customers, € 46 including shipping and VAT for customers outside of Germany, unless a written cancellation is sent within 14 days of the receipt of the trial subscription. The subscription will be renewed automatically every year until a written cancellation is sent to OEMUS MEDIA AG, Holbeinstr. 29, 04229 Leipzig, Germany, six weeks prior to the renewal date.

▶ **Reply** via Fax +49 341 48474-290 to OEMUS MEDIA AG or via E-mail to grasse@oemus-media.de

One issue free of charge!

Last Name, First Name

Company

Street

ZIP/City/County

E-mail

Signature

Notice of revocation: I am able to revoke the subscription within 14 days after my order by sending a written cancellation to OEMUS MEDIA AG, Holbeinstr. 29, 04229 Leipzig, Germany.

Signature

Mission: Passion, ethics and professionalism

Letter from Dr Luca L. Dalloca, new President of the European Society of Cosmetic Dentistry



Dear ESCD members, friends,

I am honoured and proud to have been elected to serve the European Society of Cosmetic Dentistry (ESCD) as its president. In assuming this role, I have looked back at the great achievements of our previous president, Dr Wolfgang Richter, from whom I have learned a great deal. I will do my best to achieve at least the same level of competence. I have also revisited the original goals and visions that we have had since the foundation of the society and I have found new inspiration to continue the growth of our society from a didactic point of view, while maintaining the friendly and pleasant atmosphere for which the ESCD is so well known.

The biggest challenge for me as the new president will be the annual meeting of the ESCD in 2013, which will be held in Verona. We have already begun to work

on the programme and I can promise you an outstanding calibre of speakers. The venue for the congress is a wonderful historic building—Verona itself being one of the most romantic cities in the world.

This year's meeting was held in Bucharest along with the ninth International Congress of Esthetic Dentistry, organised by the Society of Esthetic Dentistry in Romania. It was an amazing meeting, with over 1,200 participants and 32 speakers from all around the world, and three days of intensive learning and the exchange of experiences. A review of this fabulous event will be published in the next issue of **cosmetic dentistry**.

I have the pleasure of announcing that starting from June this year **cosmetic dentistry** will become the official magazine of the ESCD. The other great news for our members is that from now onwards they will receive **cosmetic dentistry** at their homes. I would like to encourage all our members to share their experiences and submit articles suitable for this publication.

The next project that we are working on is our Internet presence. Soon, we will be launching a new, more user-friendly website, which will be of great benefit to the members and the public. We are aware of the language barriers that many members might experience and have decided to create local websites in several languages for this reason. For the same reason, we are going to provide simultaneous interpretation in various languages at our international meetings. In the future, all the newsletters and other communications will also be translated to local languages.

In addition, we are considering holding at least one regional meeting (study club) each year in all the European nations in which the ESCD has a presence. If you are a member of the ESCD and wish to become involved, please contact your country chairpersons. If we do not yet have a country chairperson for your country and you are interested in becoming involved, please do not hesitate to contact us.

Let us all keep moving the ESCD forward as a beacon for our young colleagues, to become the greatest aesthetic dentists and technicians in Europe in order to better serve our profession.

Join the ESCD and you'll get:

A regular newsletter

Featuring the latest in cosmetic dentistry, upcoming events, news from members and much more. Got an interesting article you'd like published? News you think other members would like to hear about? Send it to us and we'll almost certainly include it!

Study clubs

Starting in 2012, we'll be arranging regional meetings all over Europe. An ideal place to meet other members from your district, obtain a little education and enjoy the company of like-minded professionals.

Special offers when attending our superb annual meeting, featuring internationally acclaimed speakers and fabulous social events

ESCD meetings are legendary! Consistently excellent speakers from all over the world offering top-class education to what many people agree is the friendliest dental society!

Your personal membership certificate

Hang it proudly on your wall. Membership of the ESCD demonstrates that you're serious about dental education and do everything to provide your patients with excellent service.

Listing on our website

Patients looking for a cosmetic dentist will find your details on our website. If you hold certification by the ESCD, they will have the confidence of knowing your work has been approved by your peers and is of a high standard.

The opportunity to obtain the valued ESCD Certificate in Cosmetic Dentistry

Certification by the ESCD demonstrates that you've completed a number of clinical cases to a very high standard and

have been examined on your knowledge of cosmetic dentistry. The opportunity to obtain certification is a valuable one, and all members should aim for certification. It provides great professional satisfaction and can help develop your practice.

The opportunity to meet dentists from all over the world and share in their professional experience

ESCD members love meeting each other! Exchanging views and comparing working practices in different countries is one of the most valuable benefits of membership. On top of that, everyone has a wonderful time!

Special subscription rates for your assistants, hygienists and other staff

We all work better as a team. That's why the ESCD encourages all members of the practice to join. Attending lectures with team members greatly improves the implementation of new ideas when you return to work.

Membership of a truly international group that always places members' interests first

The ESCD does everything it can to support its members. If you have questions about clinical dentistry, practice management or any other dental issue, ask our team and we'll find someone to help. Send your questions to info@escd.info. We're always open to suggestions about how we can improve the society and always try to act on our members' comments.

Superb value! Annual individual membership of the ESCD costs only €190.00 for dentists and €95.00 for dental team members! **The ESCD** really is for everyone. We're passionate about cosmetic dentistry. We know it's what more and more of our patients are asking for, so we're determined for our members to get the best possible support and education to be able to offer excellent services to the public. Whether you're completely new to cosmetic dentistry or whether you're already an experienced practitioner, the ESCD is for you. Join now at www.escdonline.eu!



The congress will be held at the spectacular Palazzo della Gran Guardia*

ESTHETICS
MEETS
AESTHETICS



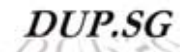VERONA

ITALY • May 31- June 1, 2013

*Venue subject to change

save the date

In Cooperation With



International Events

2012

AAAD & JAED Joint Meeting

19–22 July 2012
Sapporo, Japan
www.asiaaad.org

IACA 2012

26–28 July 2012
Hollywood, FL, USA
www.theiaca.com

AAED Annual Meeting

7–10 August 2012
Naples, FL, USA
www.estheticacademy.org

FDI Annual World Dental Congress

29 August–1 September 2012
Hong Kong, China
www.fdiworldental.org

BSAD International Meeting

19–22 September 2012
São Paulo, Brazil

SCAD Annual Conference

28 & 29 September 2012
Chicago, IL, USA
www.scadent.org

1st ASIA–PACIFIC EDITION

7th CAD/CAM & Computerized Dentistry
International Conference
6 & 7 October 2012
Singapore, Singapore
www.cappmea.com

Dental–Facial Cosmetic

International Conference
9 & 10 November 2012
Dubai, UAE
www.cappmea.com

AIOP International Congress

22–24 November 2012
Bologna, Italy
www.aiop.com

BACD Annual Conference

22–24 November 2012
Manchester, UK
www.bacd.com

2013

International Dental Show

12–16 March 2013
Cologne, Germany
www.ids-cologne.de

EAED Spring Meeting

30 May–1 June 2013
Crete, Greece
www.eaed.org

Esthetics meets Aesthetics

AACD, BACD, ESCD & DGKZ Joint Meeting
31 May–1 June 2013
Verona, Italy
www.escd.info

FDI Annual World Dental Congress

29 August–1 September 2013
Seoul, Korea
www.fdiworldental.org



submission guidelines:

Please note that all the textual components of your submission must be combined into one MS Word document. Please do not submit multiple files for each of these items:

- _ the complete article;
- _ all the image (tables, charts, photographs, etc.) captions;
- _ the complete list of sources consulted; and
- _ the author or contact information (biographical sketch, mailing address, e-mail address, etc.).

In addition, images must not be embedded into the MS Word document. All images must be submitted separately, and details about such submission follow below under image requirements.

Text length

Article lengths can vary greatly—from 1,500 to 5,500 words—depending on the subject matter. Our approach is that if you need more or less words to do the topic justice, then please make the article as long or as short as necessary.

We can run an unusually long article in multiple parts, but this usually entails a topic for which each part can stand alone because it contains so much information.

In short, we do not want to limit you in terms of article length, so please use the word count above as a general guideline and if you have specific questions, please do not hesitate to contact us.

Text formatting

We also ask that you forego any special formatting beyond the use of italics and boldface. If you would like to emphasise certain words within the text, please only use italics (do not use underlining or a larger font size). Boldface is reserved for article headers. Please do not use underlining.

Please use single spacing and make sure that the text is left justified. Please do not centre text on the page. Do not indent paragraphs, rather place a blank line between paragraphs. Please do not add tab stops.

Should you require a special layout, please let the word processing programme you are using help you do this formatting automatically. Similarly, should you need to make a list, or add footnotes or endnotes, please let the word processing programme do it for you automatically. There are menus in every programme that will enable you to do so. The fact is that no matter how carefully done, errors can creep in when you try to number footnotes yourself.

Any formatting contrary to stated above will require us to remove such formatting before layout, which is very time-consuming. Please consider this when formatting your document.

Image requirements

Please number images consecutively throughout the article by using a new number for each image. If it is imperative that certain images are grouped together, then use lowercase letters to designate these in a group (for example, 2a, 2b, 2c).

Please place image references in your article wherever they are appropriate, whether in the middle or at the end of a sentence. If you do not directly refer to the image, place the reference at the end of the sentence to which it relates enclosed within brackets and before the period.

In addition, please note:

- _ We require images in TIF or JPEG format.
- _ These images must be no smaller than 6x6 cm in size at 300 DPI.
- _ These image files must be no smaller than 80 KB in size (or they will print the size of a postage stamp!).

Larger image files are always better, and those approximately the size of 1 MB are best. Thus, do not size large image files down to meet our requirements but send us the largest files available. (The larger the starting image is in terms of bytes, the more leeway the designer has for resizing the image in order to fill up more space should there be room available.)

Also, please remember that images must not be embedded into the body of the article submitted. Images must be submitted separately to the textual submission.

You may submit images via e-mail, via our FTP server or post a CD containing your images directly to us (please contact us for the mailing address, as this will depend upon the country from which you will be mailing).

Please also send us a head shot of yourself that is in accordance with the requirements stated above so that it can be printed with your article.

Abstracts

An abstract of your article is not required.

Author or contact information

The author's contact information and a head shot of the author are included at the end of every article. Please note the exact information you would like to appear in this section and format it according to the requirements stated above. A short biographical sketch may precede the contact information if you provide us with the necessary information (60 words or less).

Questions?

Magda Wojtkiewicz (Managing Editor)
m.wojtkiewicz@oemus-media.de

cosmetic dentistry

_ beauty & science

Publisher

Torsten R. Oemus
oemus@oemus-media.de

CEO

Ingolf Döbbecke
doebbecke@oemus-media.de

Members of the Board

Jürgen Isbaner
isbaner@oemus-media.de

Lutz V. Hiller

hiller@oemus-media.de

Editor-in-Chief

Dr Sushil Koirala
skoirala@wlink.com.np

Co-Editor-in-Chief

Dr So Ran Kwon
smileksr@hotmail.com

Managing Editor

Magda Wojtkiewicz
m.wojtkiewicz@oemus-media.de

Executive Producer

Gernot Meyer
meyer@oemus-media.de

Designer

Franziska Dachsel
f.dachsel@oemus-media.de

Copy Editors

Sabrina Raaff
Hans Motschmann

Published by

Oemus Media AG
Holbeinstraße 29
04229 Leipzig, Germany
Tel.: +49 341 48474-0
Fax: +49 341 48474-290
kontakt@oemus-media.de
www.oemus.com

Printed by

Löhnert Druck
Handelsstraße 12
04420 Markranstädt, Germany

Advisory Board

Dr Michael Miller, USA
Dr Seok-Hoon Ko, Korea

Editorial Board

Dr Anthony Au, Australia
Dr Bao Baicheng, China
Dr Helena Lee, Singapore
Dr Hisashi Hisamitsu, Japan
Dr Jiraporn Charudilaka, Thailand
Dr Mostaque H. Sattar, Bangladesh
Dr Ratnadeep Patil, India
Dr Sim Tang Eng, Malaysia
Dr Suhit Raj Adhikari, Nepal
Dr Takashi Nakamura, Japan
Dr Vijayaratnam Vijayakumaran, Sri Lanka



Magda Wojtkiewicz, Managing Editor

cosmetic
dentistry _ beauty & science
is the official publication of:



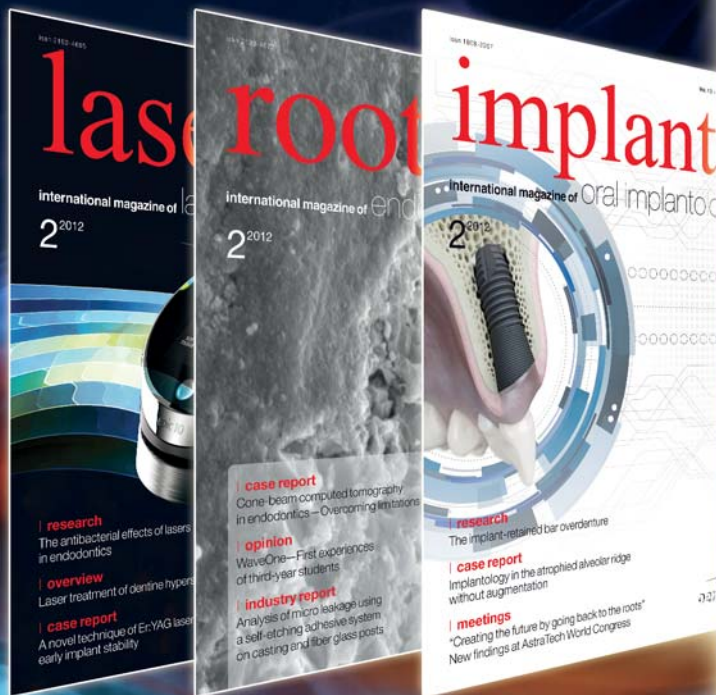Copyright Regulations

cosmetic dentistry beauty & science is published by Oemus Media AG and will appear in 2012 with one issue every quarter. The magazine and all articles and illustrations therein are protected by copyright. Any utilisation without the prior consent of editor and publisher is inadmissible and liable to prosecution. This applies in particular to duplicate copies, translations, microfilms, and storage and processing in electronic systems.

Reproductions, including extracts, may only be made with the permission of the publisher. Given no statement to the contrary, any submissions to the editorial department are understood to be in agreement with a full or partial publishing of said submission. The editorial department reserves the right to check all submitted articles for formal errors and factual authority, and to make amendments if necessary. No responsibility shall be taken for unsolicited books and manuscripts. Articles bearing symbols other than that of the editorial department, or which are distinguished by the name of the author, represent the opinion of the afore-mentioned, and do not have to comply with the views of Oemus Media AG. Responsibility for such articles shall be borne by the author. Responsibility for advertisements and other specially labeled items shall not be borne by the editorial department. Likewise, no responsibility shall be assumed for information published about associations, companies and commercial markets. All cases of consequential liability arising from inaccurate or faulty representation are excluded. General terms and conditions apply, legal venue is Leipzig, Germany.

cosmetic

dentistry _ beauty & science



You can also subscribe via
www.oemus.com/abo

 **Subscribe now!**

I would like to subscribe to **cosmetic dentistry** for € 44 including shipping and VAT for German customers, € 46 including shipping and VAT for customers outside Germany, unless a written cancellation is sent within 14 days of the receipt of the trial subscription. The subscription will be renewed automatically every year until a written cancellation is sent to OEMUS MEDIA AG, Holbeinstr. 29, 04229 Leipzig, Germany, six weeks prior to the renewal date.

▶ **Reply** via Fax +49 341 48474-290
 or via E-mail to grasse@oemus-media.de

Last Name, First Name

Company

Street

ZIP/City/County

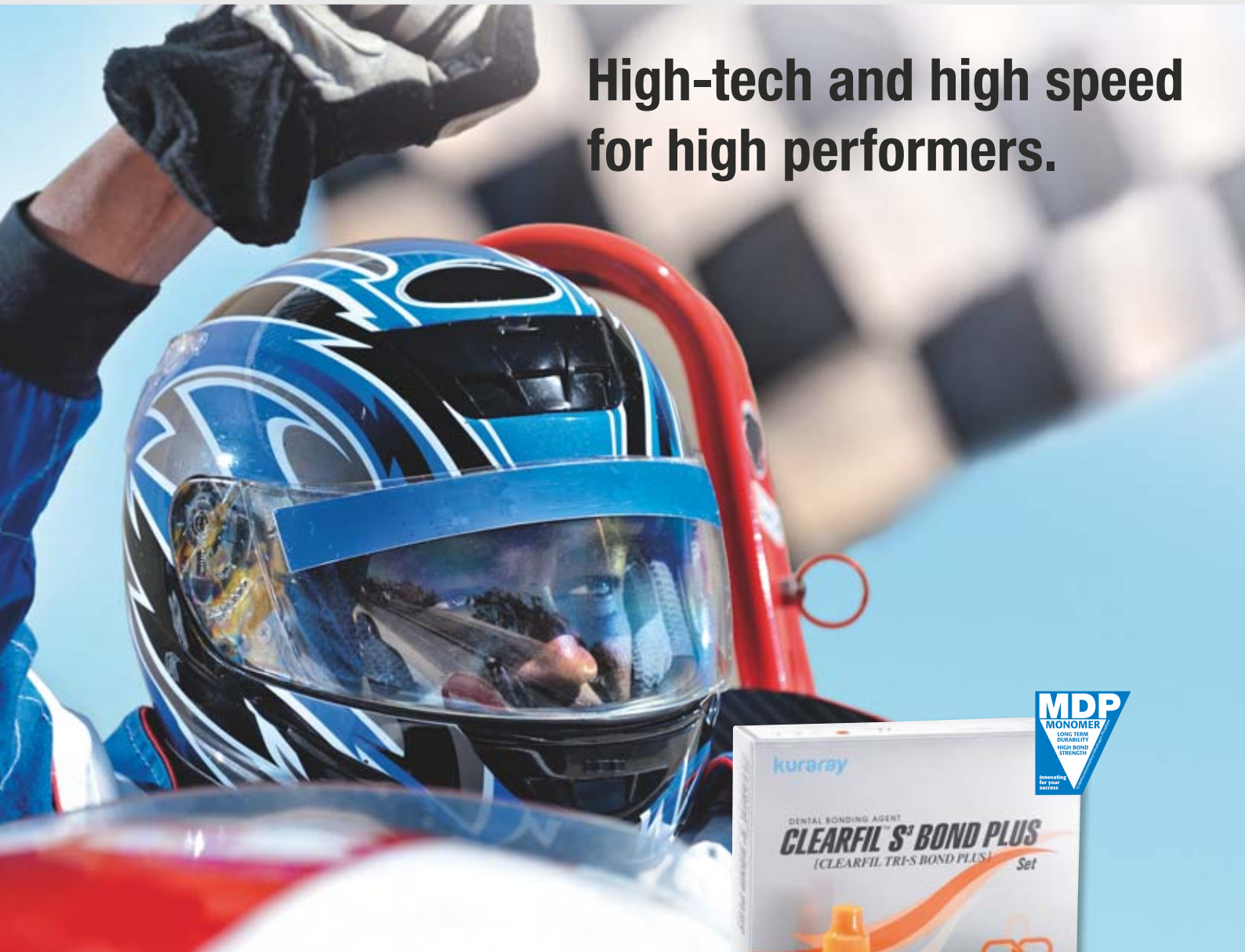E-mail

Signature

Notice of revocation: I am able to revoke the subscription within 14 days after my order by sending a written cancellation to OEMUS MEDIA AG, Holbeinstr. 29, 04229 Leipzig, Germany.

Signature

High-tech and high speed
for high performers.



CLEARFIL™ S³ BOND PLUS

The time saving one-step adhesive –
your solution for fast and simple application

Are you looking for a one-step adhesive that ensures “Speed – Simplicity – Strength”? Then CLEARFIL™ S³ BOND PLUS, Kuraray’s time-saving adhesive for fast and simple application, is the ideal solution for you.

Thanks to its short application time and very simple procedure compared with other recent one-step products CLEARFIL™ S³ BOND PLUS allows a high error tolerance while creating excellent bond strength to enamel and dentin.



Furthermore CLEARFIL™ S³ BOND PLUS ensures a stable interface between tooth and composite resin due to Kuraray’s new high performance initiator for light-curing, the original adhesive monomer MDP and the innovative Molecular Dispersion Technology.

**CLEARFIL™ S³ BOND PLUS –
it’s your choice for a fast and easy bond!**